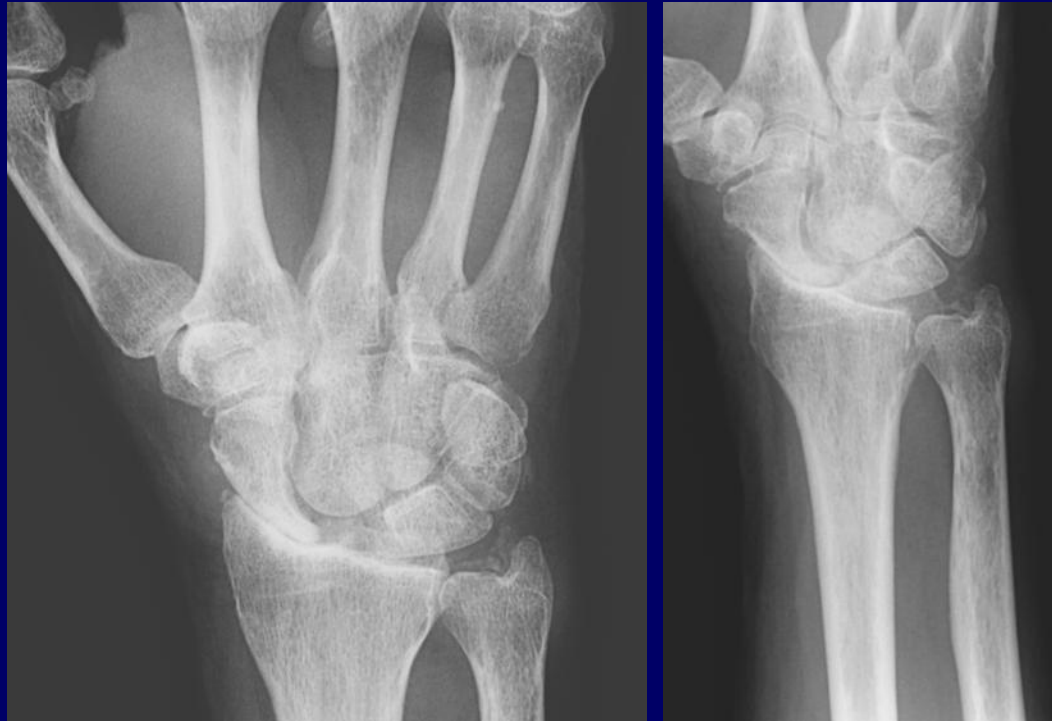

SEPTEMBER 13, 2007

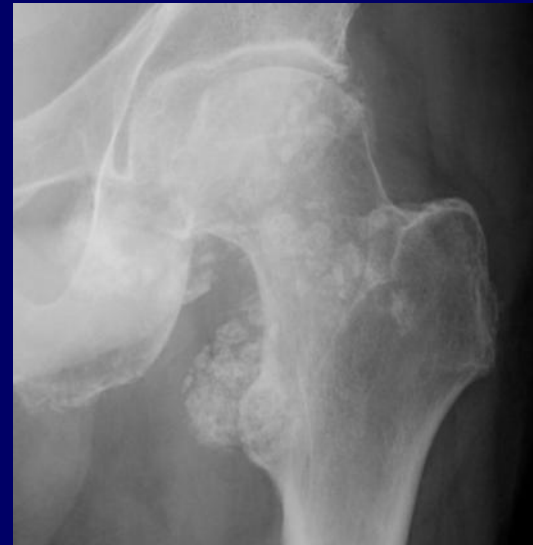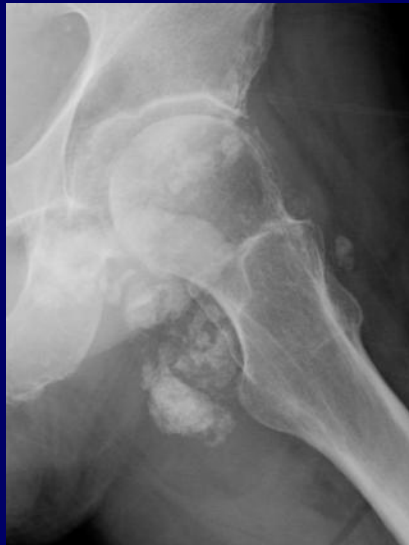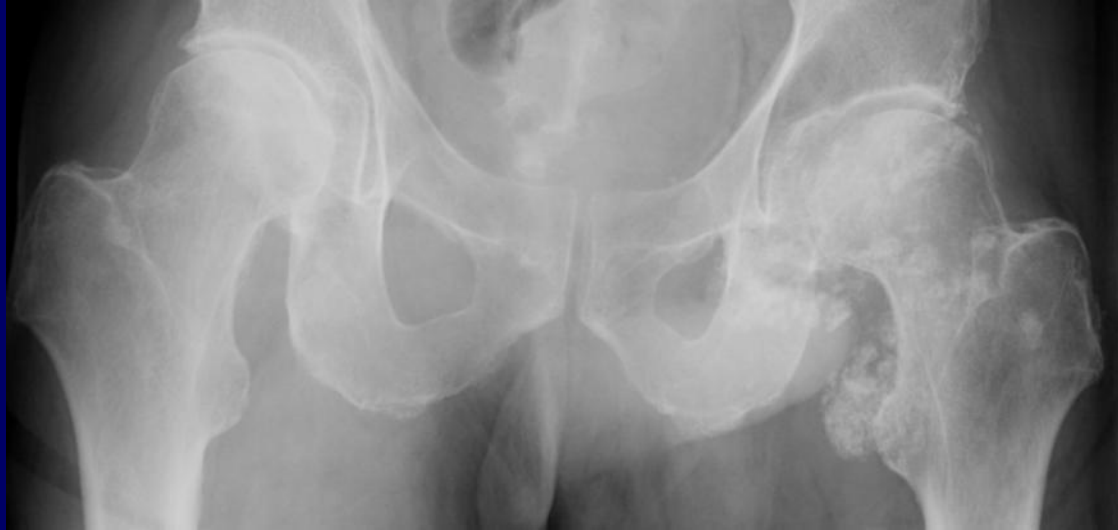# CASE



SLAC WRIST - CPPD

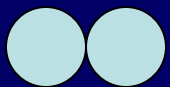
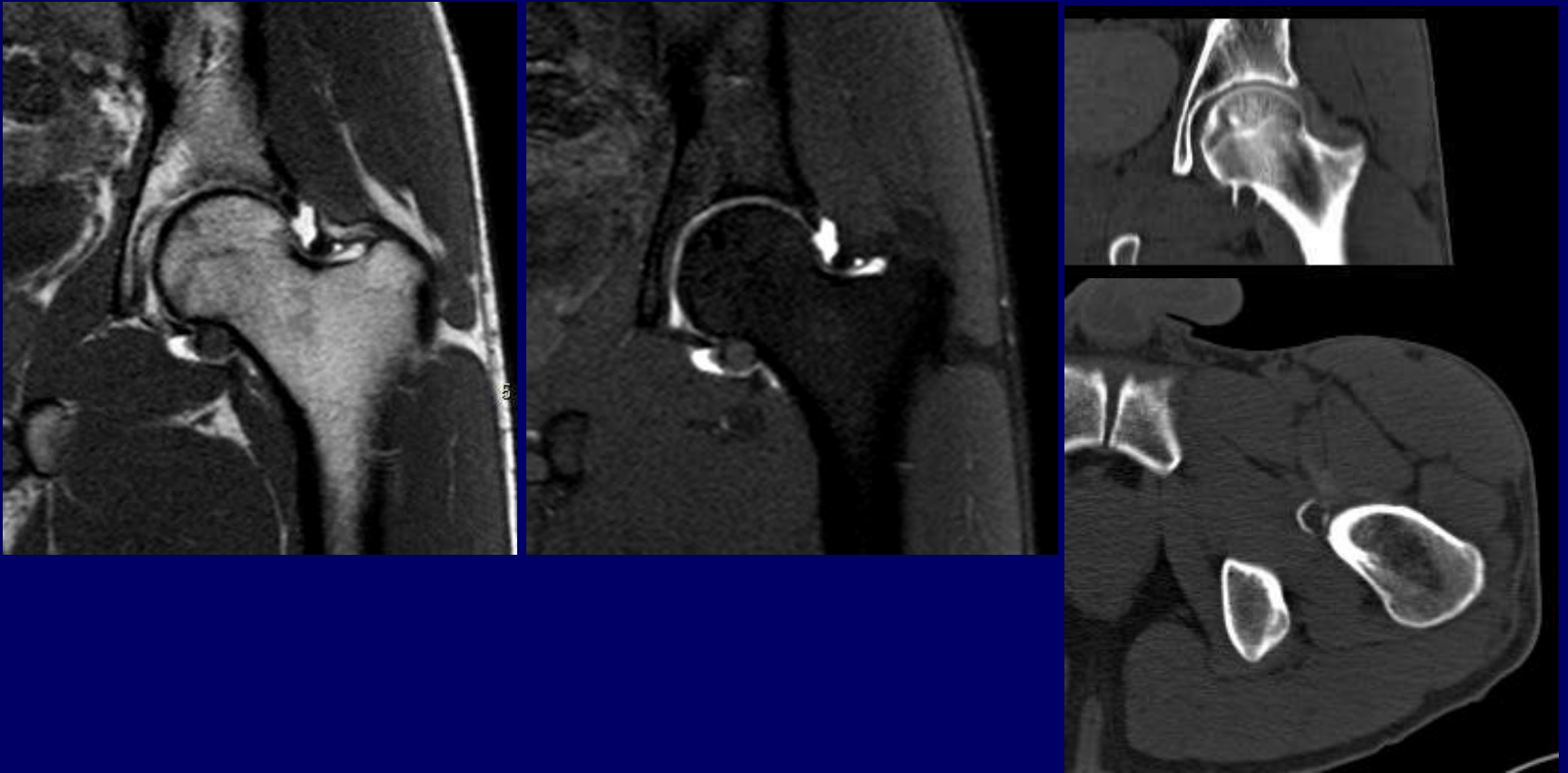# CASE

68 year old male with hip pain



**IDIOPATHIC SYNOVIAL OSTEOCHONDROMATOSIS**

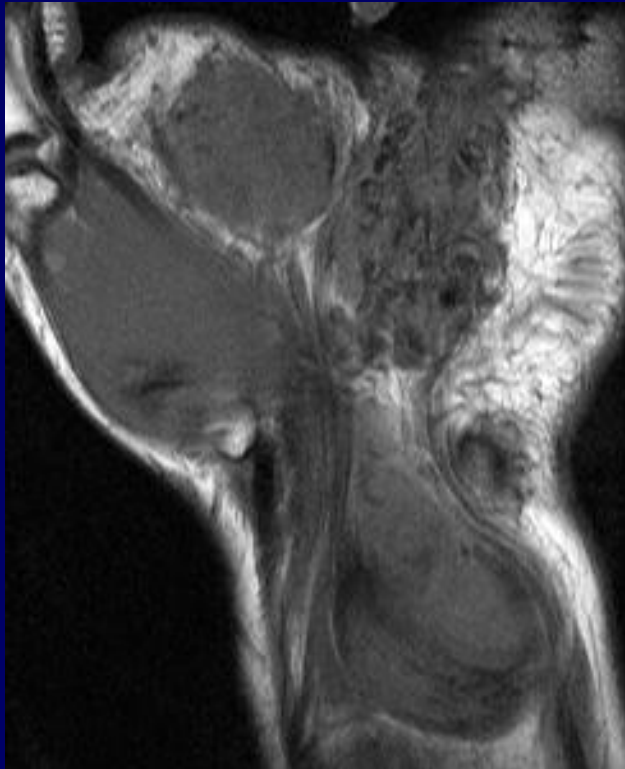
# CASE



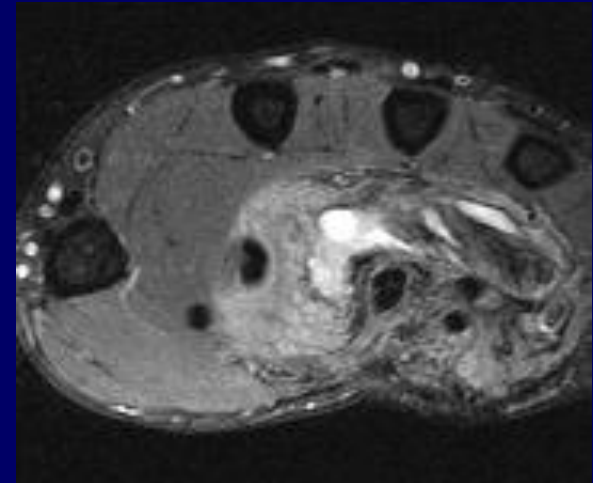
JUXTACORTICAL CHONDROMA

# CASE

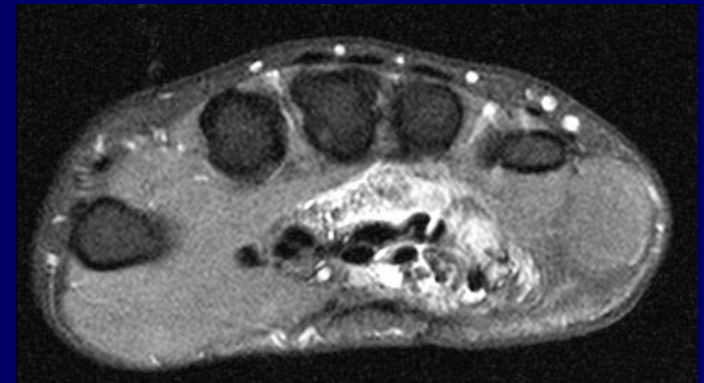
- Hx – 29 y.o. woman with hx of prior excision of tumor



T1 SE



T2FS  
FSE

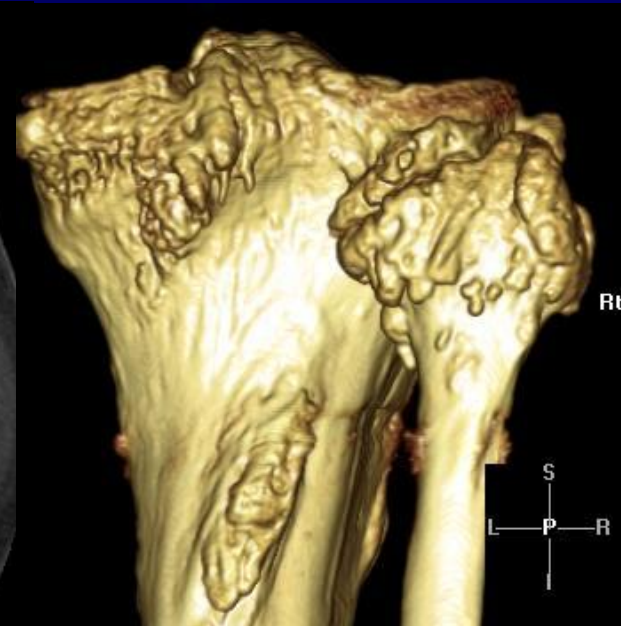
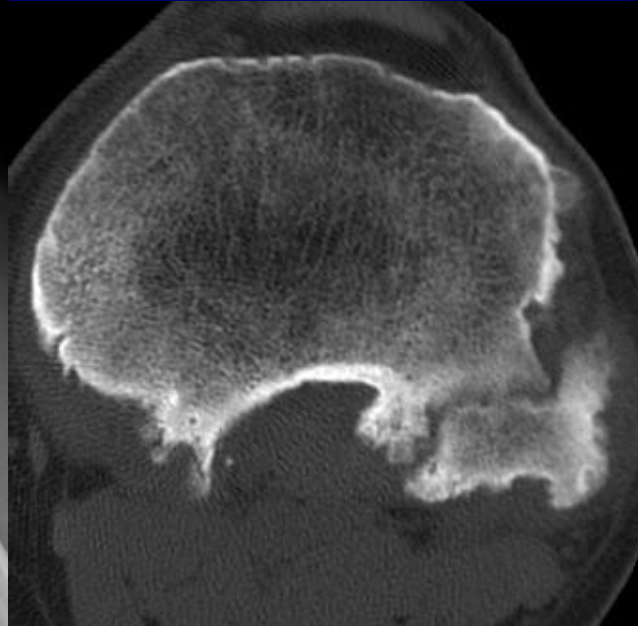
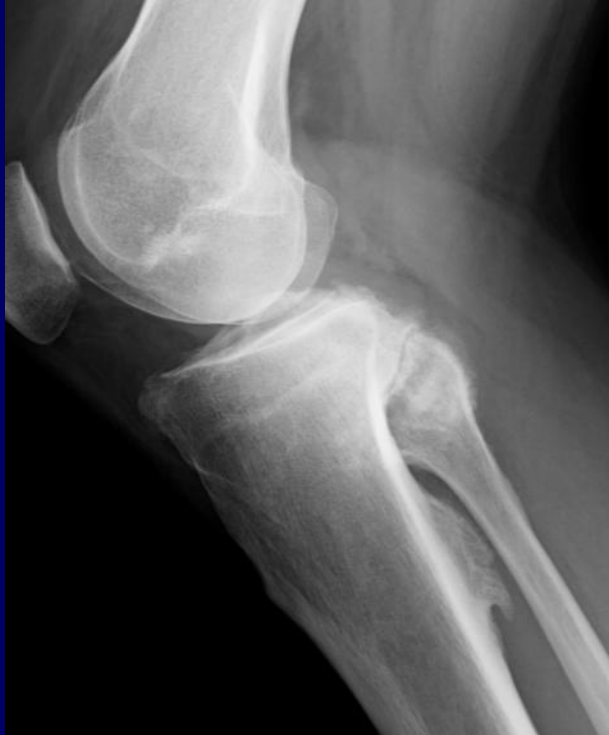

T1 FS FSE IV Gd

PIGMENTED VILLONODULAR BURSIITIS

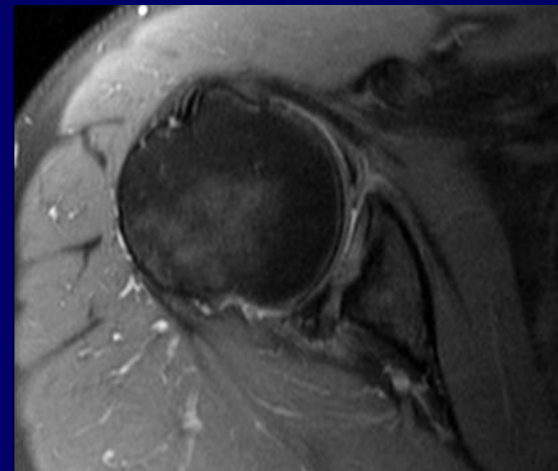
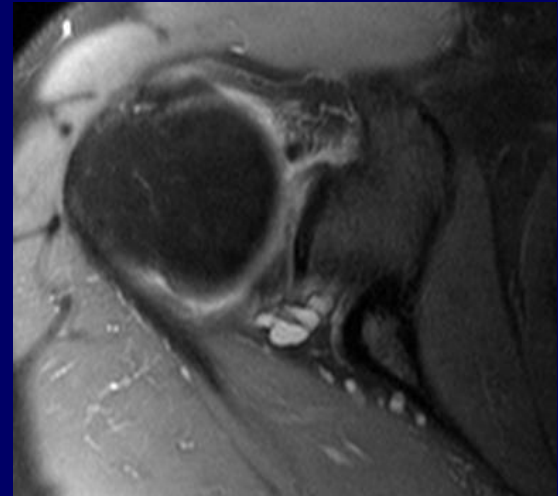
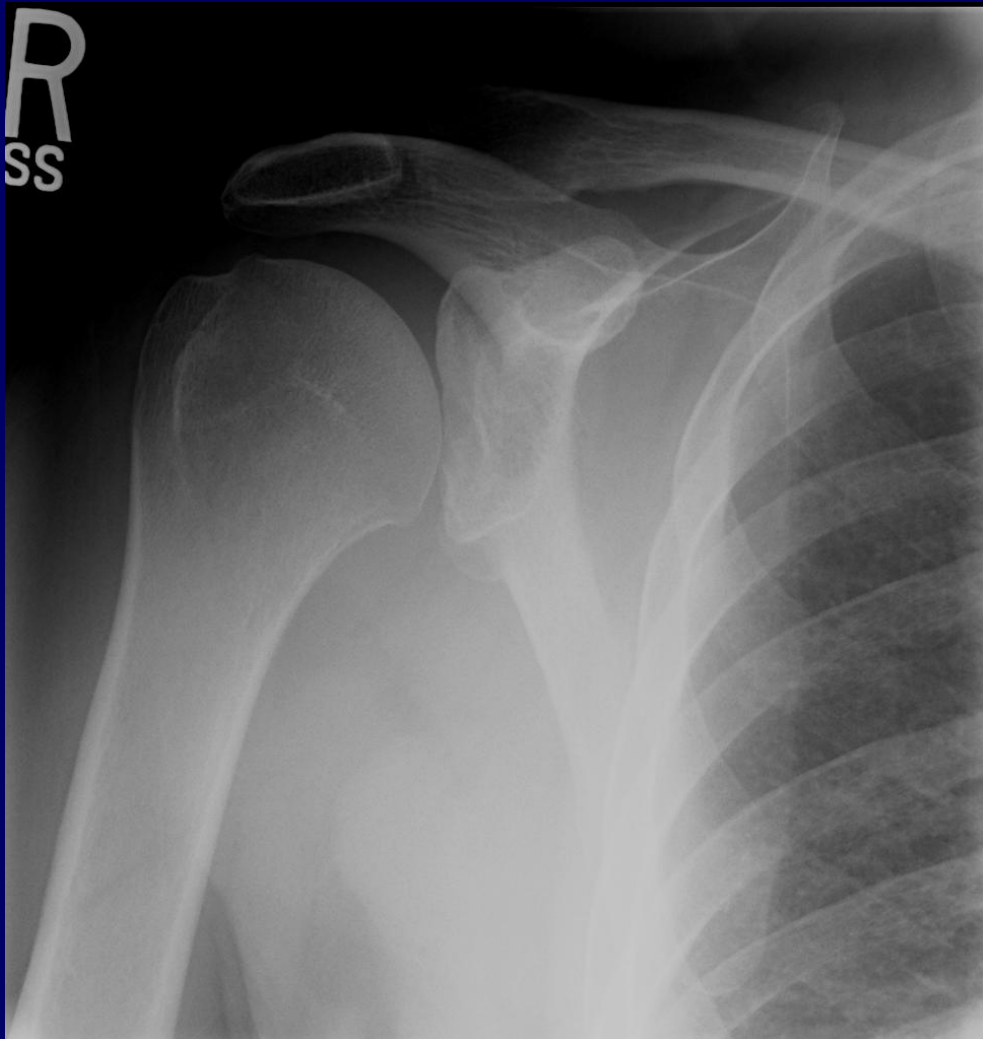
# CASE

- Hx – 38 YO man with known diagnosis



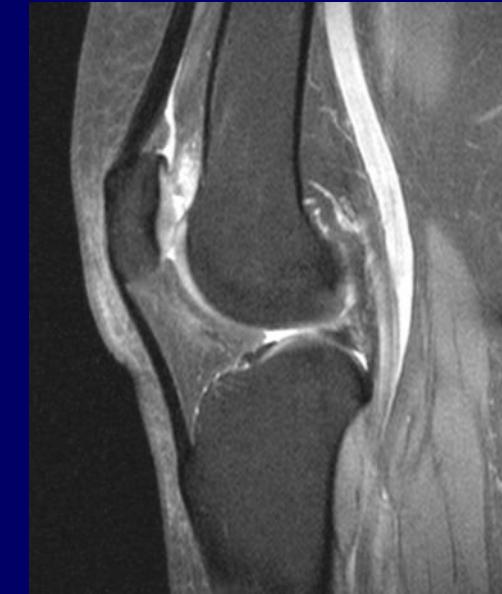
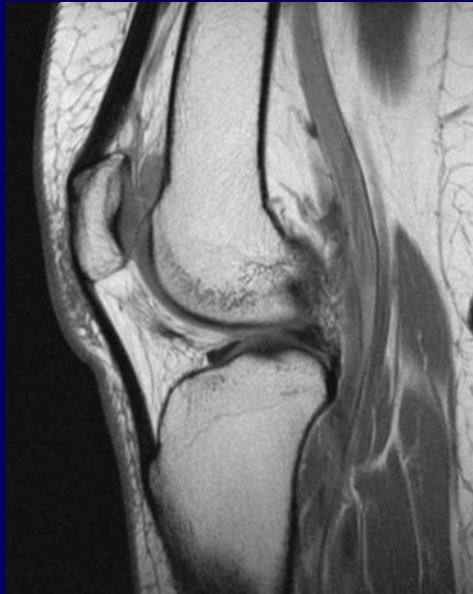
PSORIATIC ARTHRITIS

# CASE

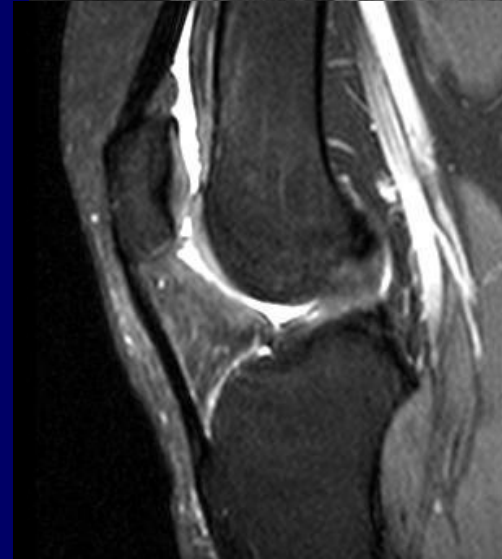
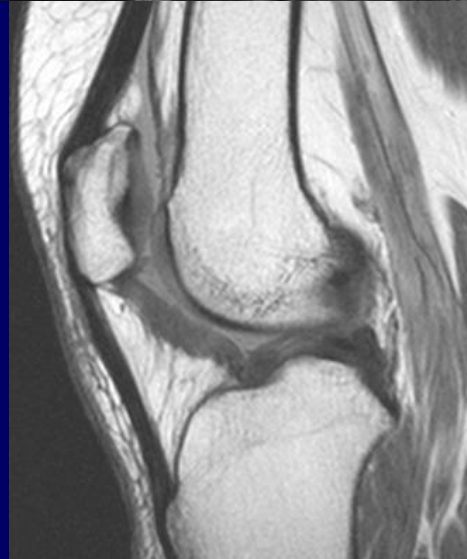


**HYPOPLASTIC GLENOID NECK**

# CASE



IMMEDIATELY  
AFTER ARTHRO-  
SCOPY FOR  
PLICA



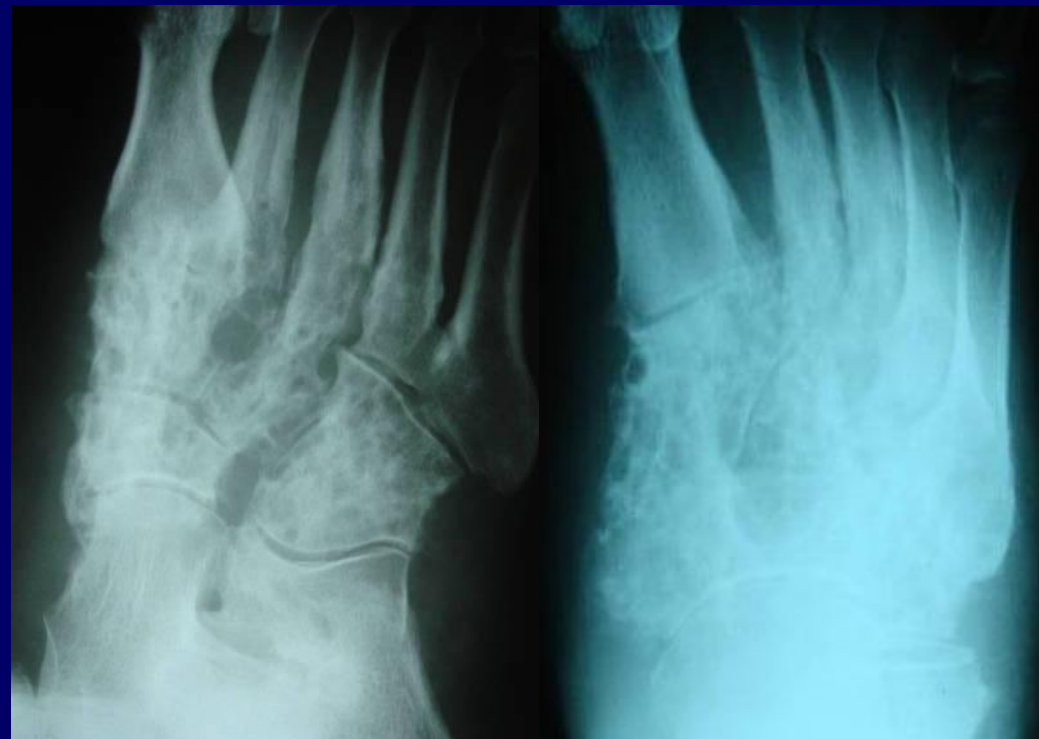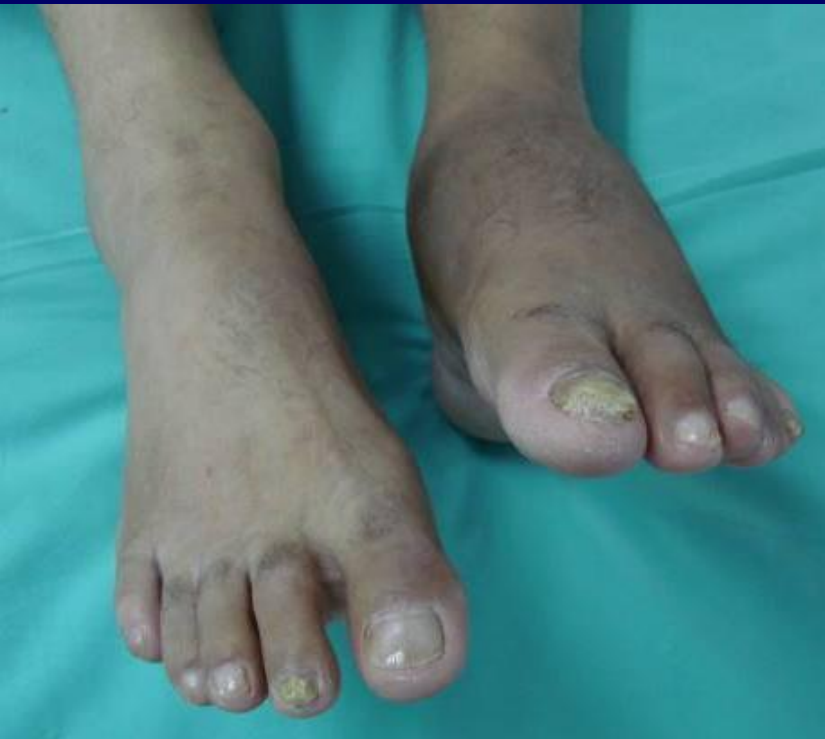ONE YEAR  
LATER

POSTOPERATIVE ARTHROFIBROSIS



# CASE

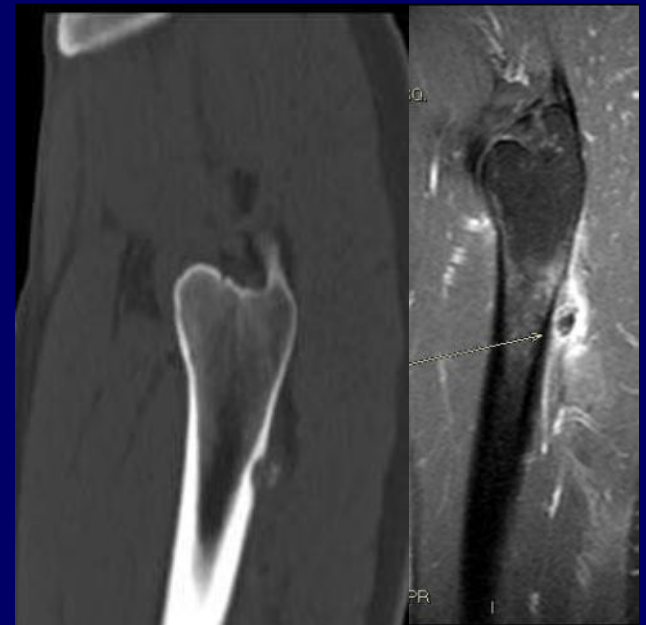
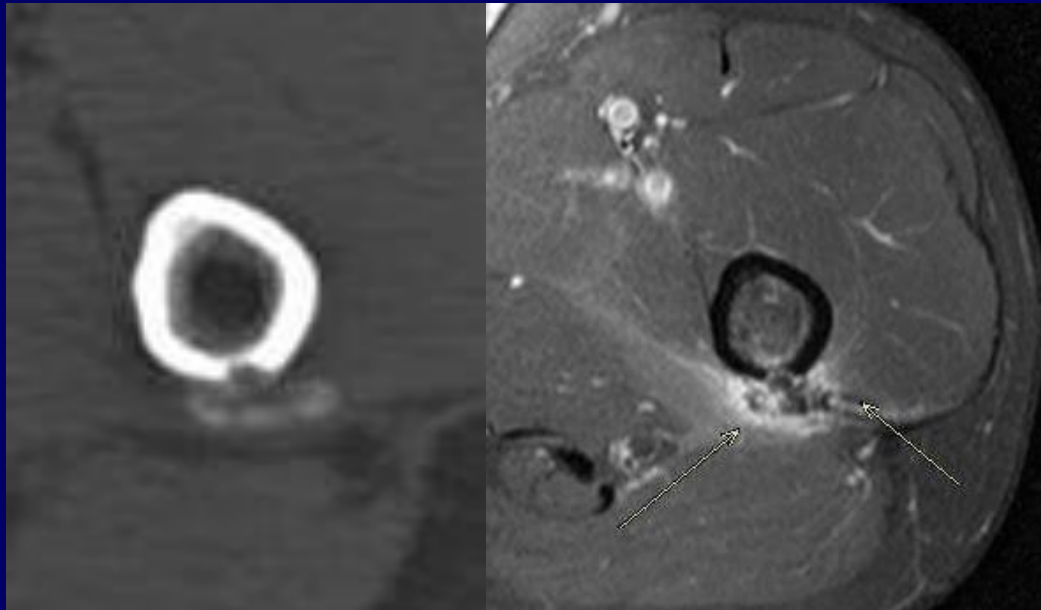
- 57 years old patient with 15 years of pain and edema at the hindfoot.



M ESTRADA

MADURA FOOT

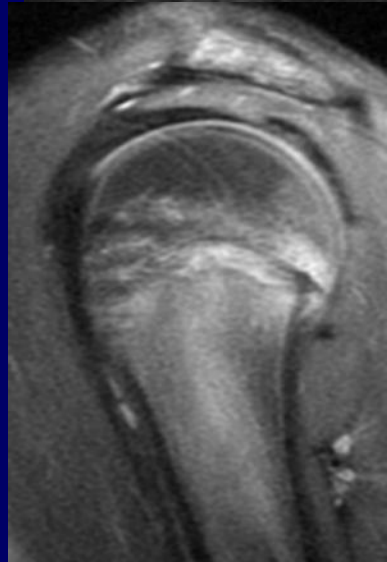
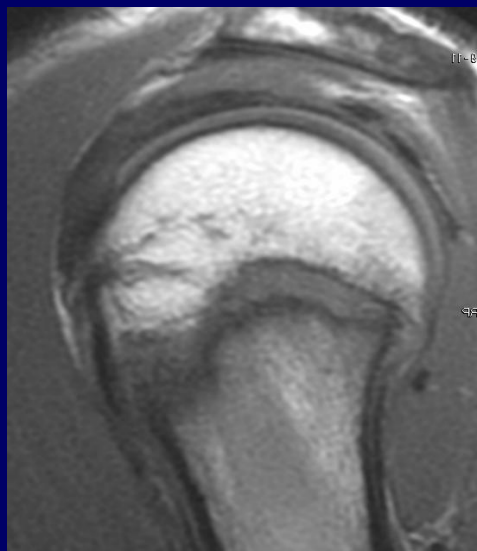
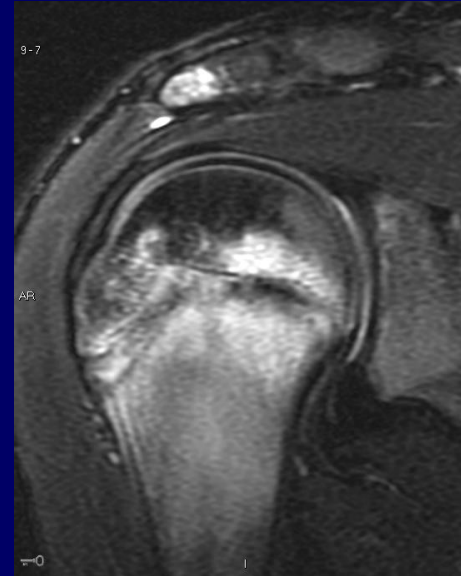
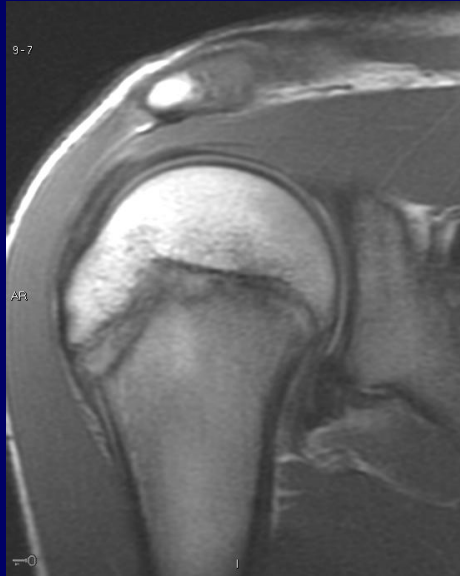
# CASE



HADD GLUTEUS MAXIMUS TENDON

# CASE

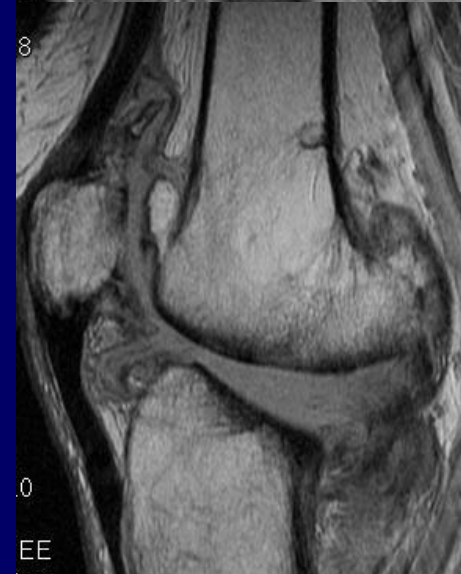
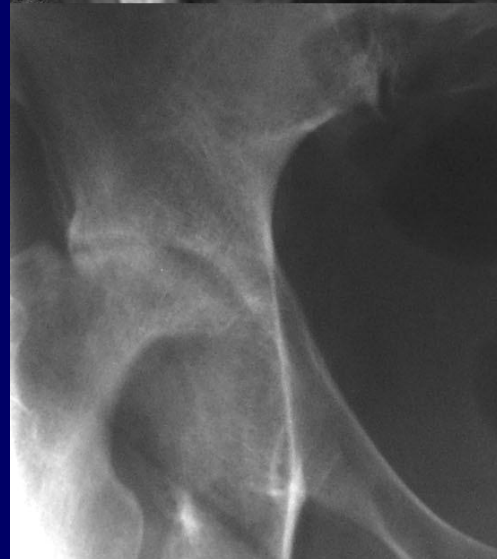
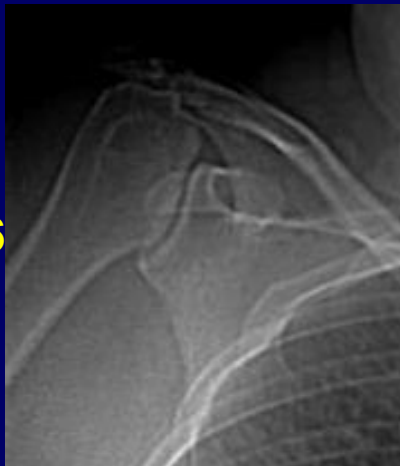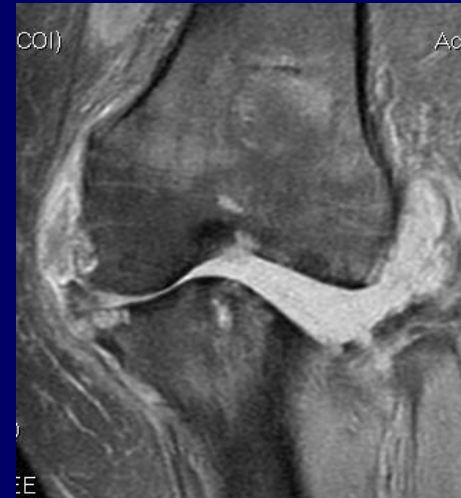
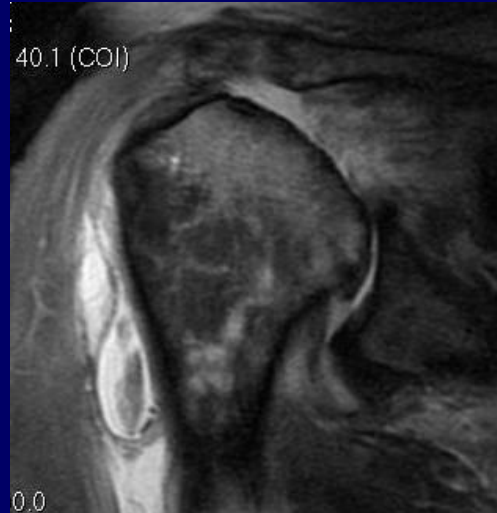
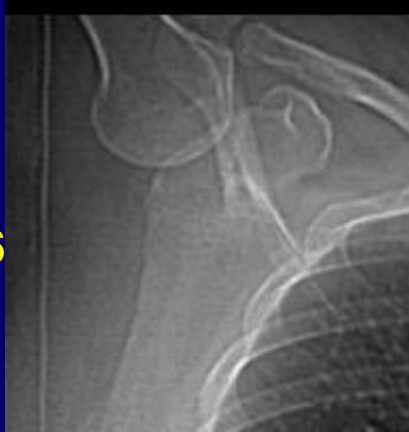- Hx – LITTLE LEAGUE PLAYER WITH SHOULDER PAIN



LITTLE LEAGUE  
SHOULDER

# CASE

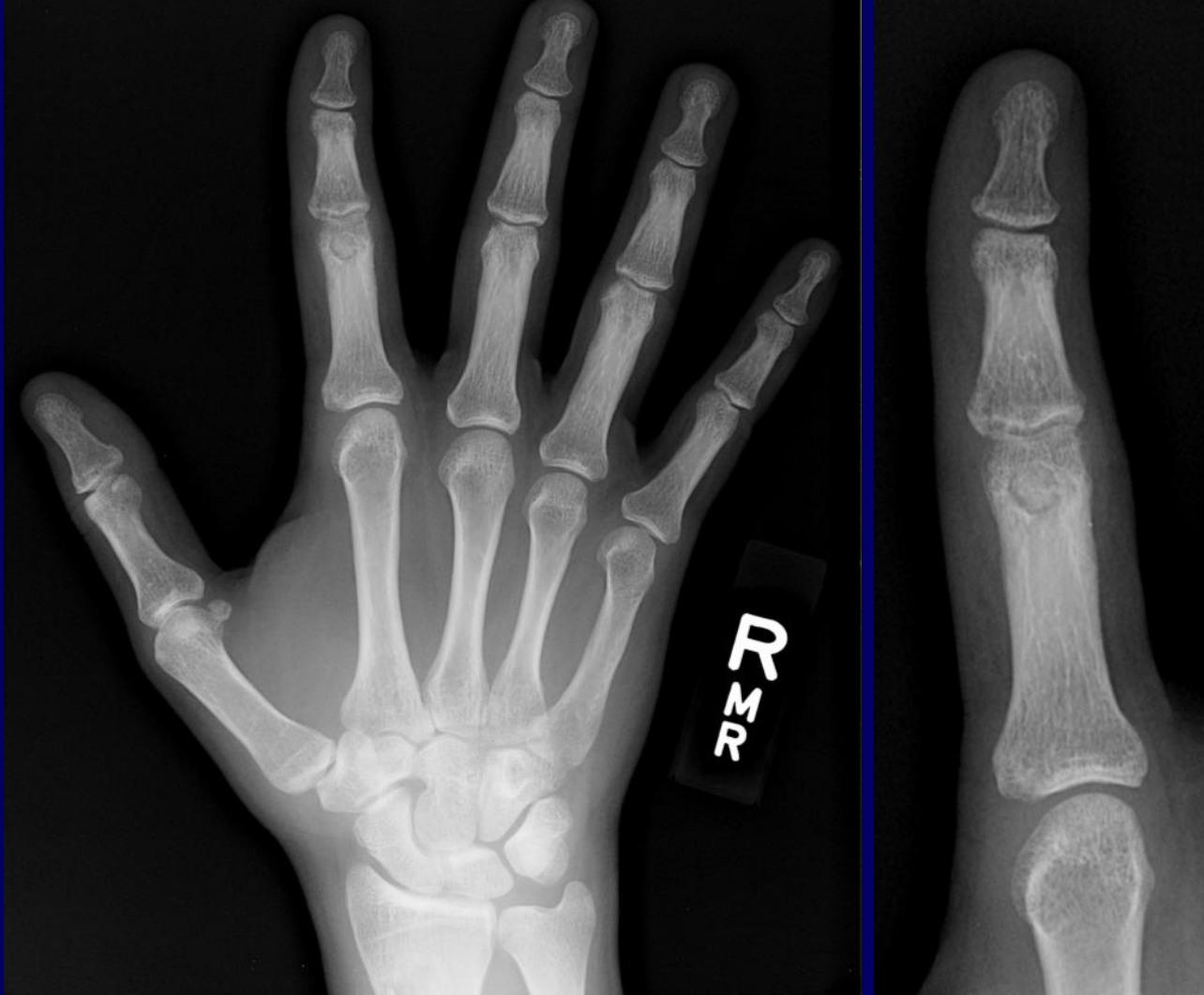
- Hx – 50 YO WOMAN WITH MULTIPLE JOINT COMPLAINTS



**BASIC CALCIUM  
PHOSPHATE  
DEPOSITION?**

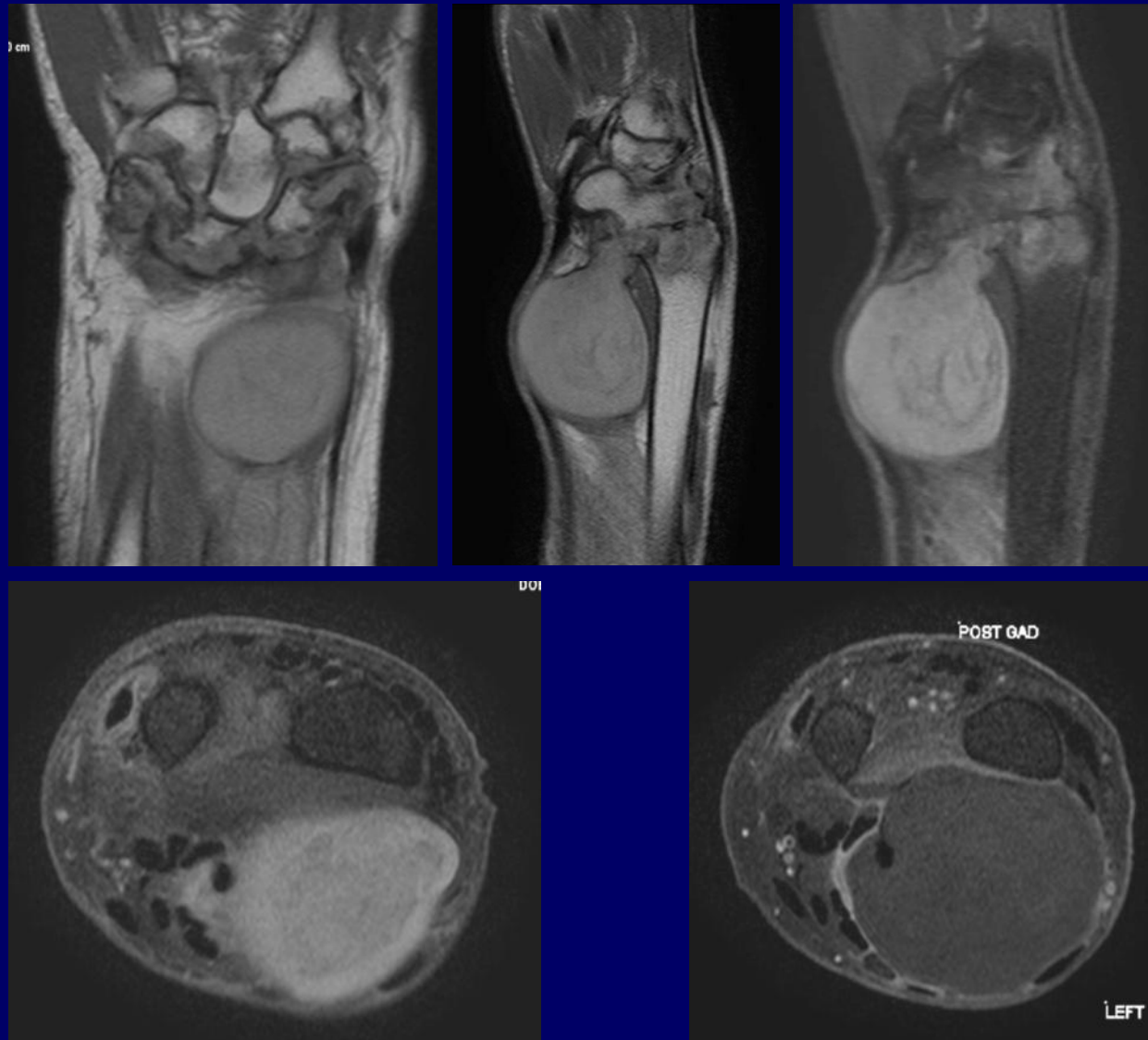
# CASE

- Hx – YOUNG PATIENT WITH FINGER PAIN



OSTEOID  
OSTEOMA?

# CASE

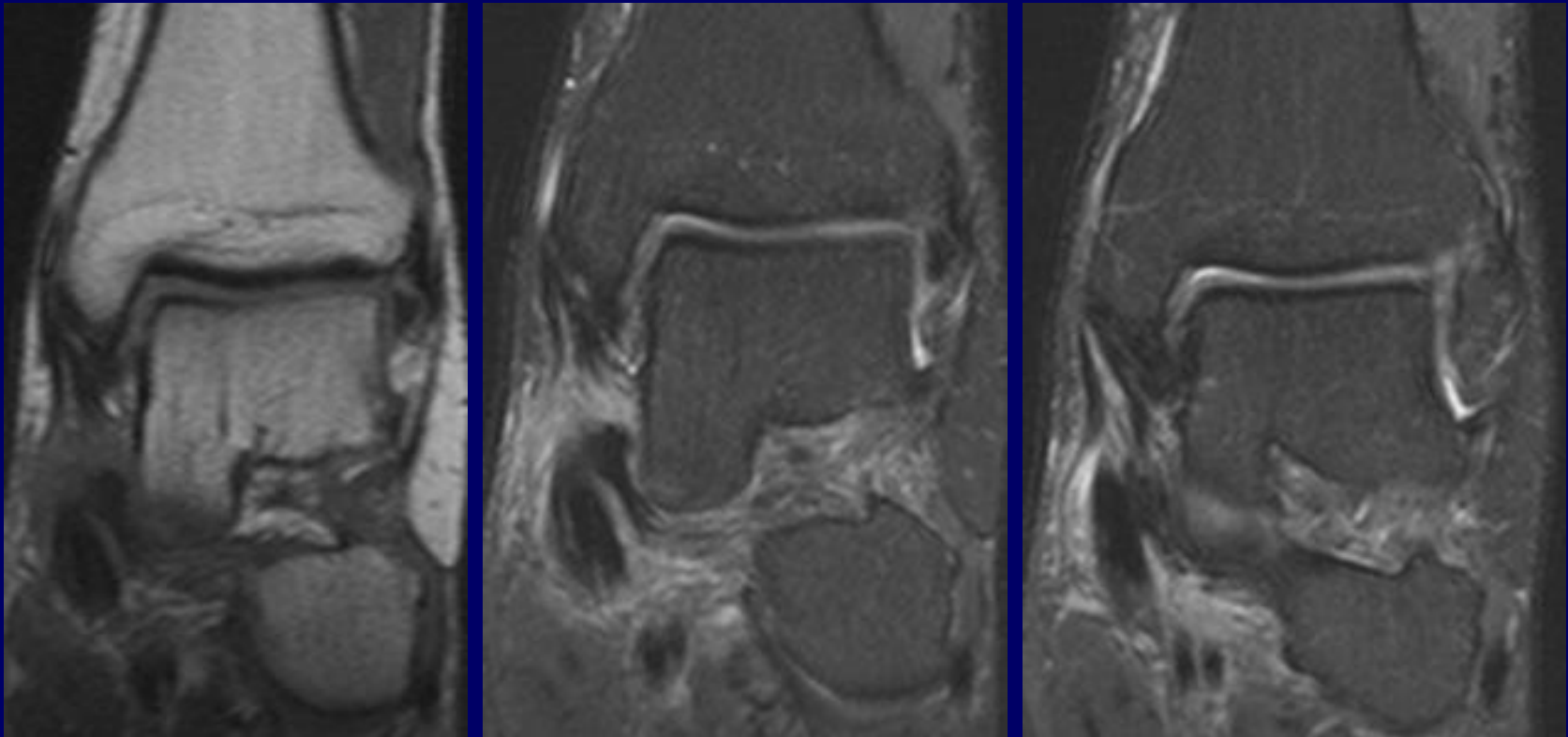


E SMITH

RA WITH SYNOVIAL CYST

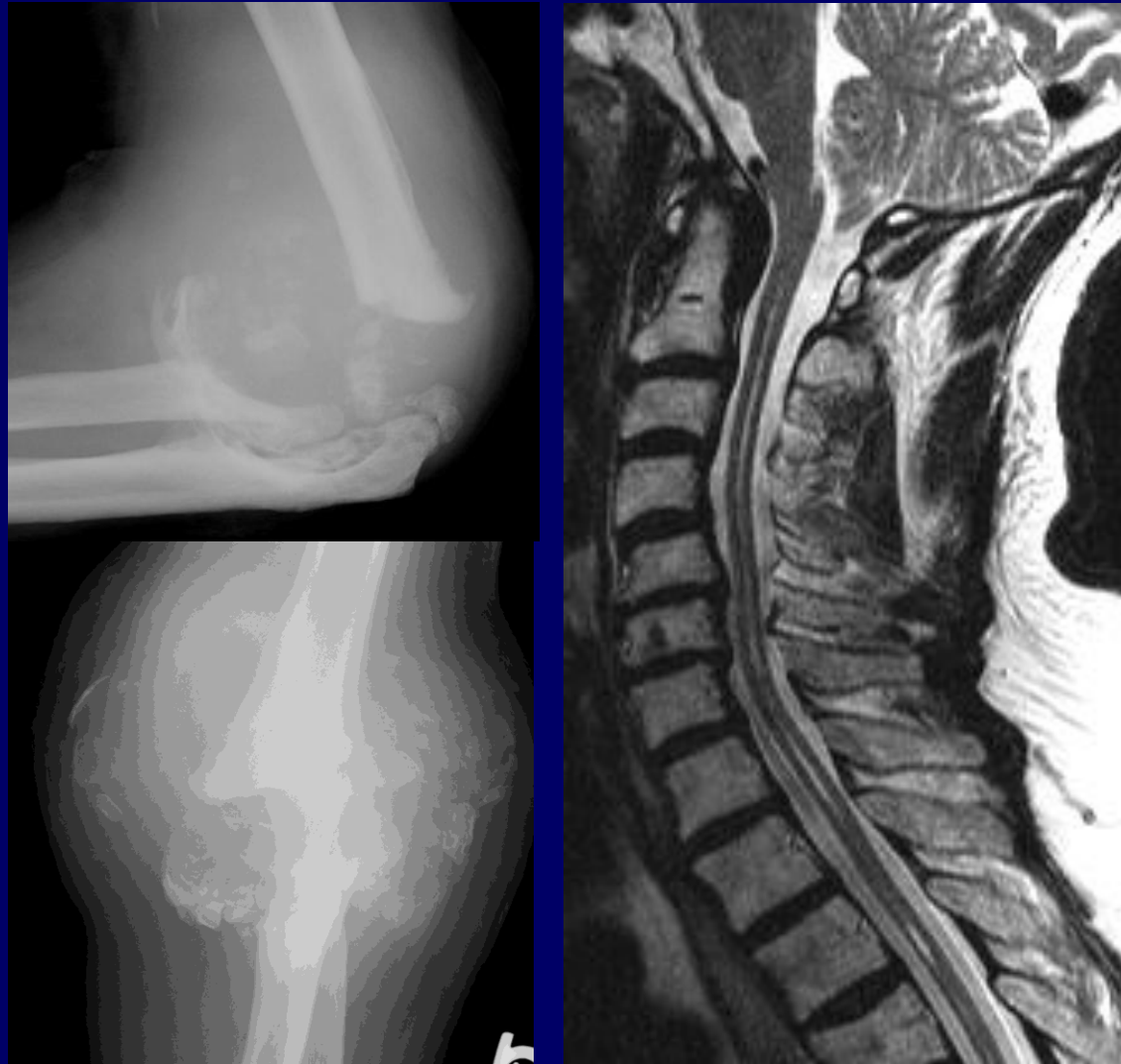
# CASE

50 year old male with medial ankle pain and flatfoot



PTT TEAR, HINDFOOT VALGUS, SPRING AND DELTOID  
LIGAMENT ABNORMALITIES, SINUS TARSI SYNDROME

# CASE

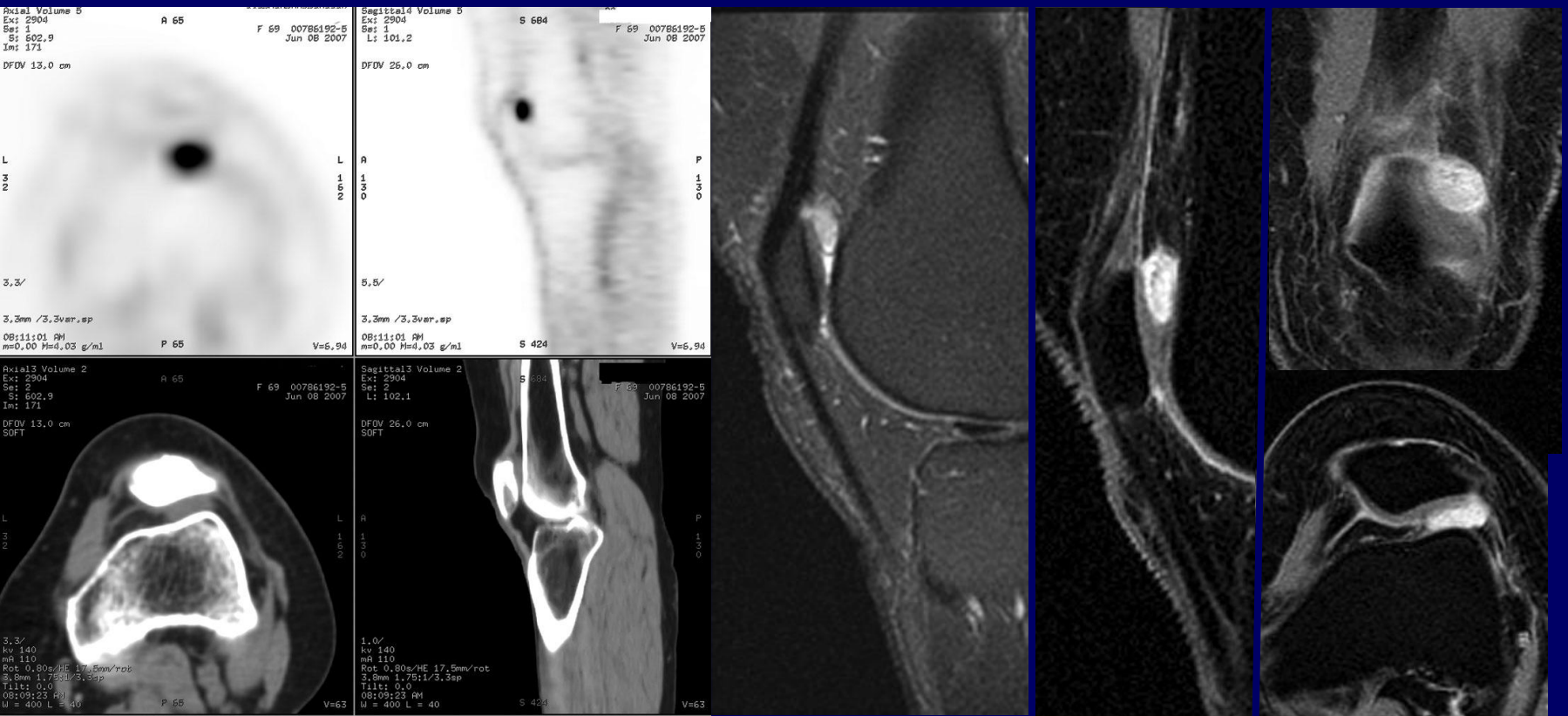


SYRINGOMYELIA WITH NEUROPATHIC CHANGES



# CASE

- Hx – YOUNG PATIENT WITH KNEE PAIN



T2 FS FSE

T1 FS FSE IV Gd

**METASTATIC MELANOMA**