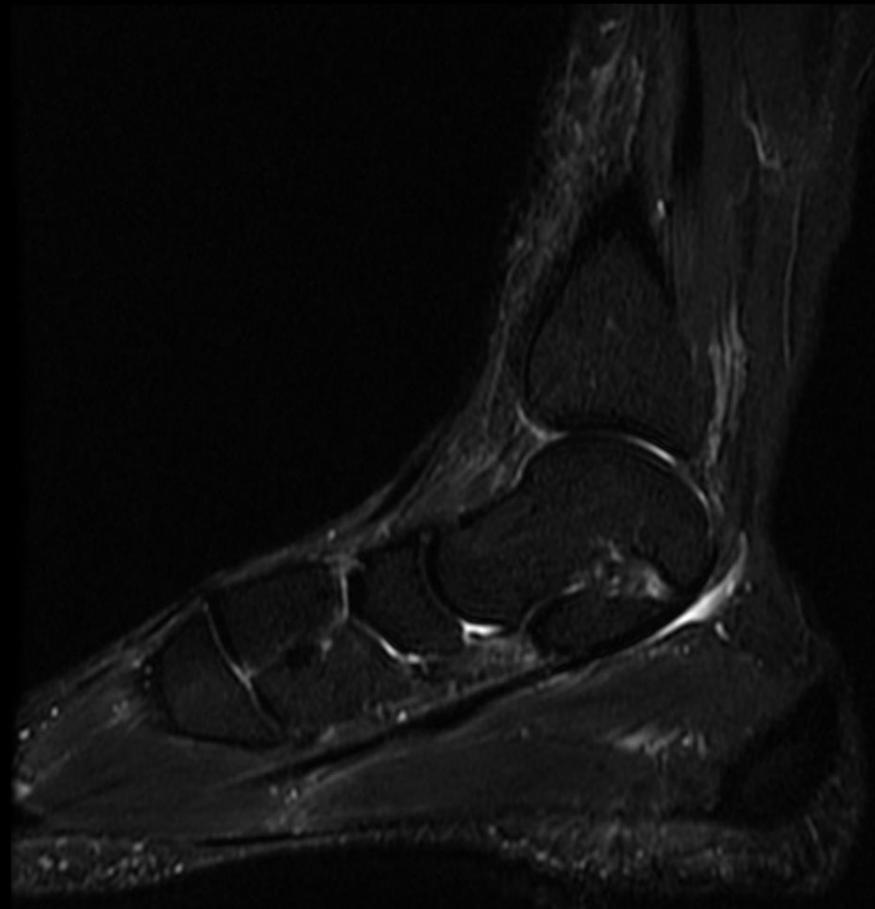
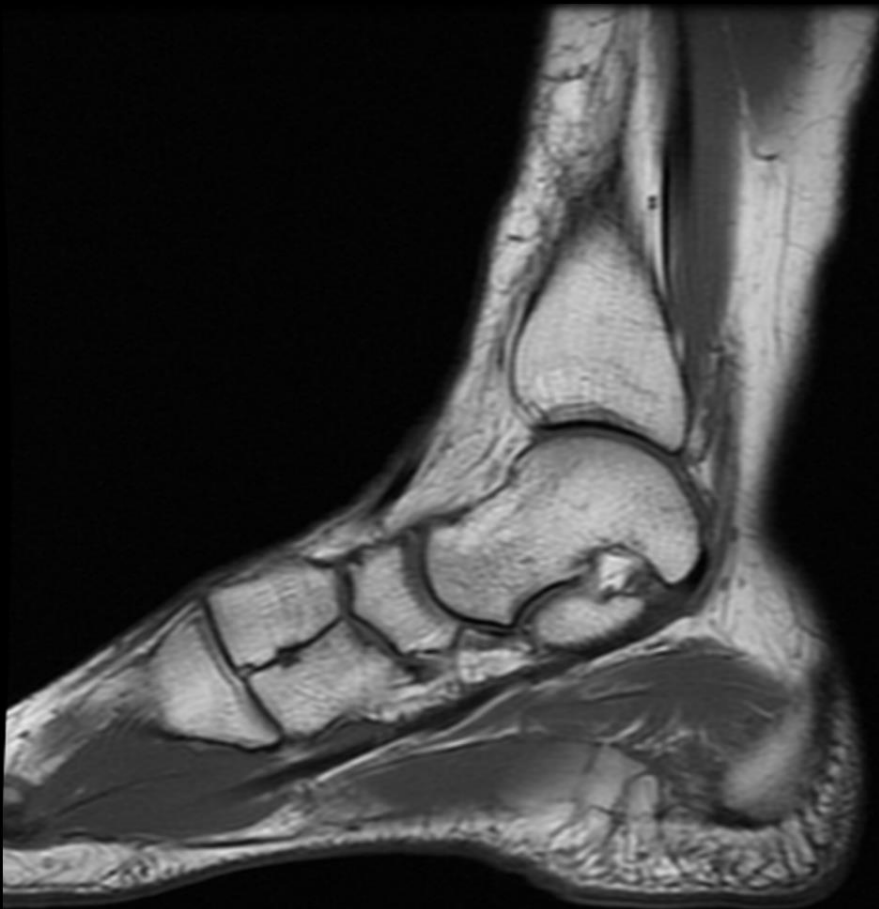

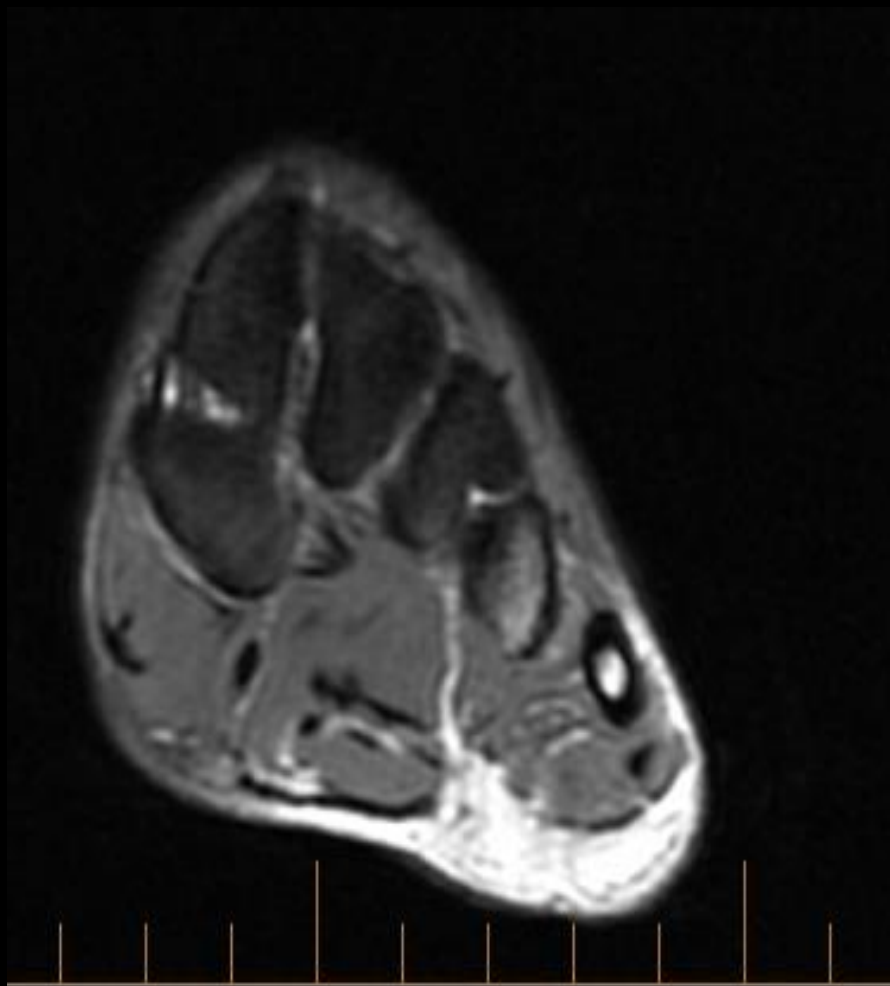
# History

38 yo F w dorsal ankle pain  
(Incidental Finding)

# MRI



# MRI

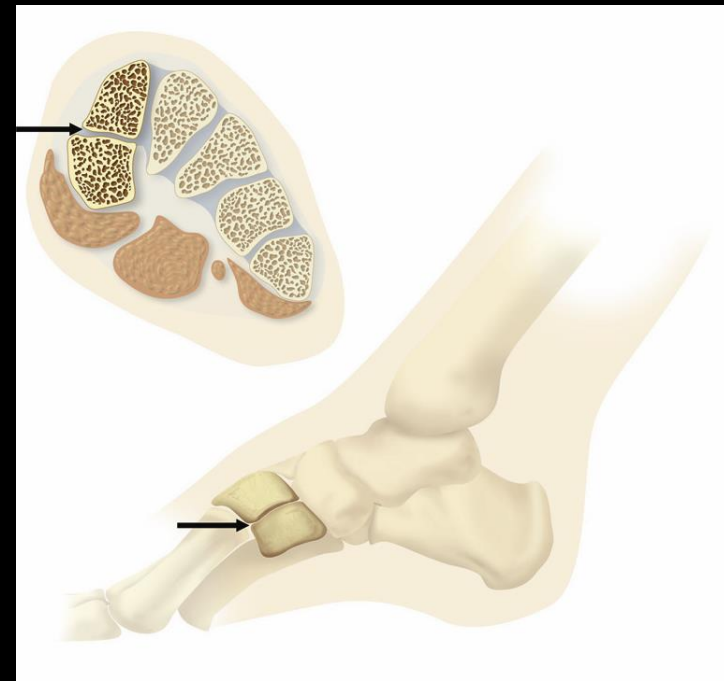


# Findings

- Medial cuneiform divided horizontally by synchondrosis
- Plantar segment larger
- No marrow or soft tissue edema
- Dx: Bipartite Medial Cuneiform

# Bipartite Medial Cuneiform

- Barlow (1942)
- Dmanisi D4111a / b
- 0.3-2.4% Incidence



# Bibliography

- Fulwadhva U, Parker RJ: Symptomatic Bipartite Medial Cuneiform. Appl Radiol 2007, 3(7):42-44.
- Elias I, Dheer S, et al. MRI findings in bipartite medial cuneiform – a potential pitfall in diagnosis of midfoot injuries: a case series. Journal of Medical Case Reports 2008, 2:272
- Chang GH, Chang EY, et al. Bipartite medial cuneiform: case report and retrospective review of 1000 MR imaging studies. Case Rep Med. 2014: