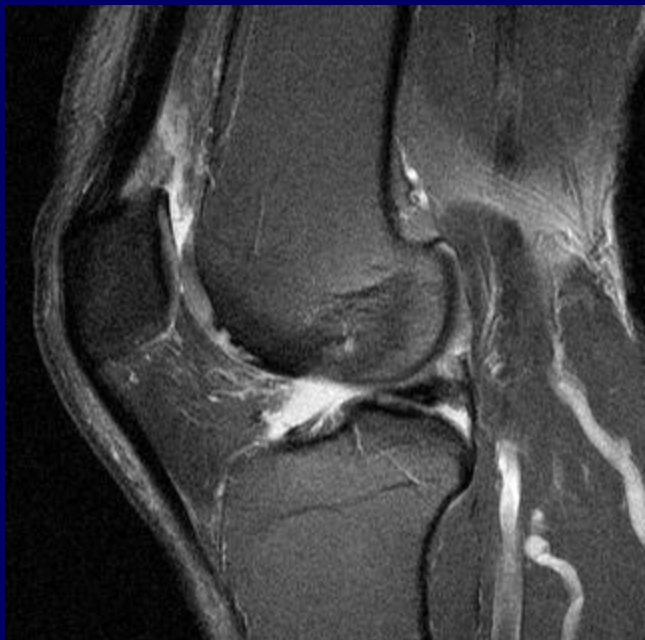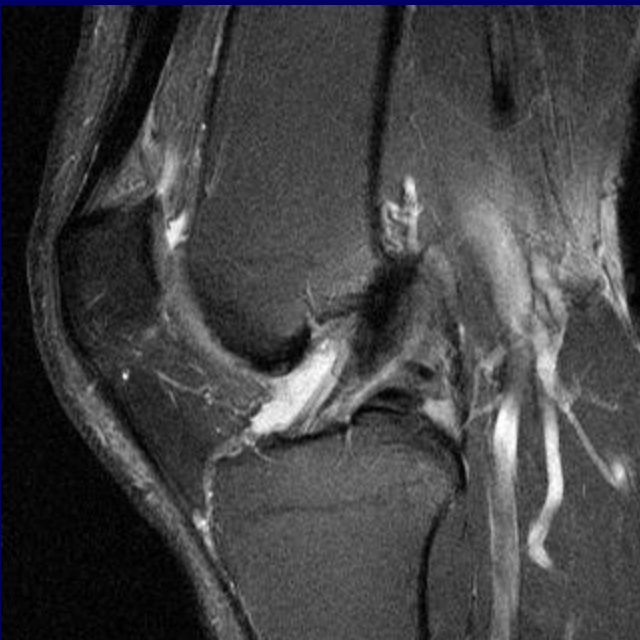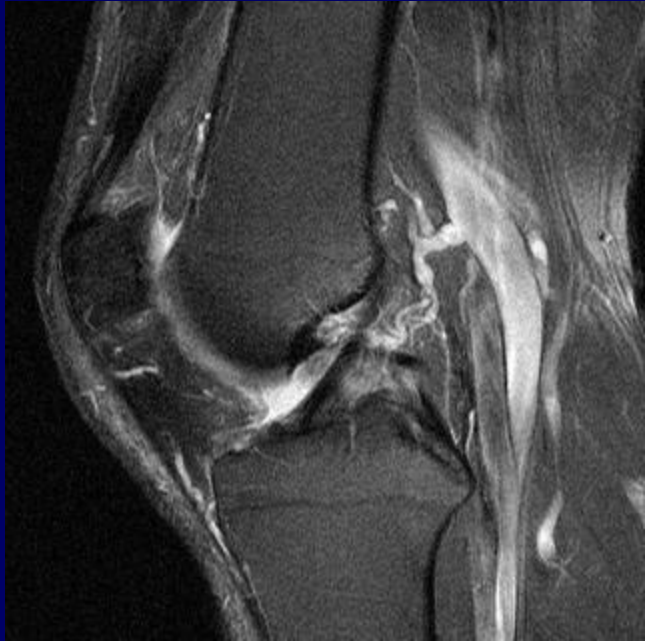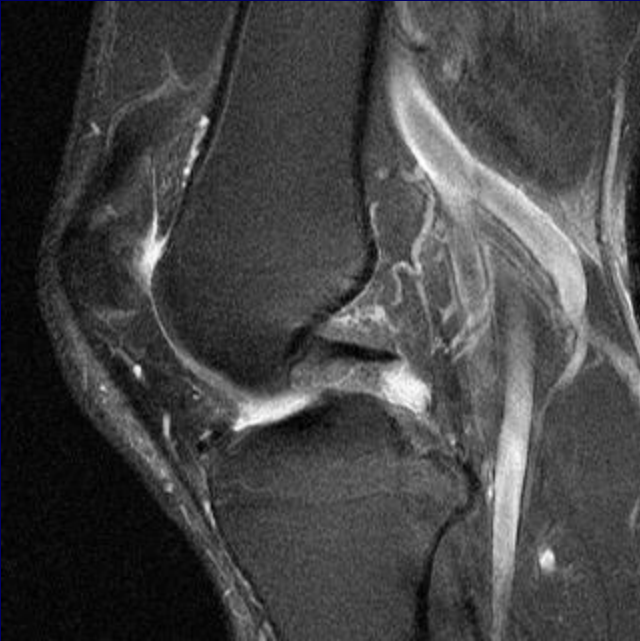


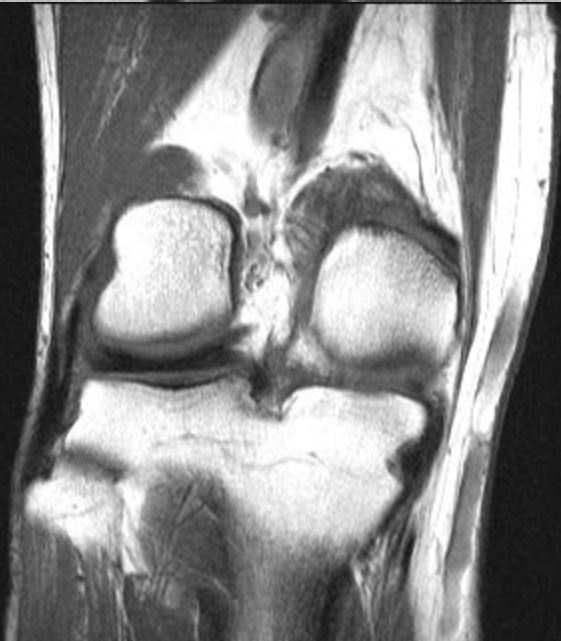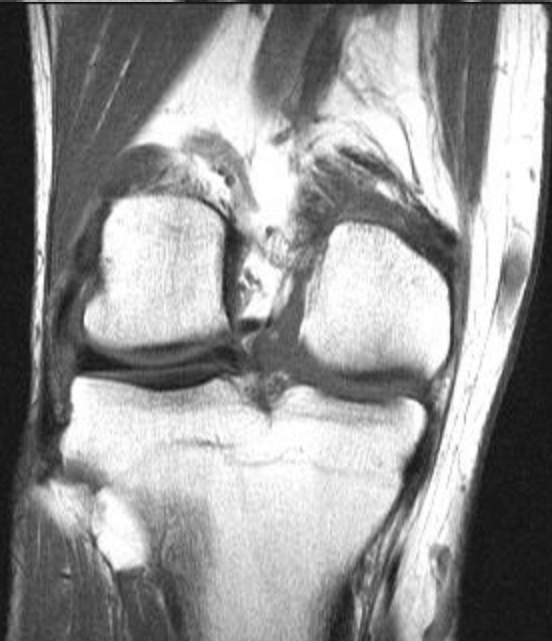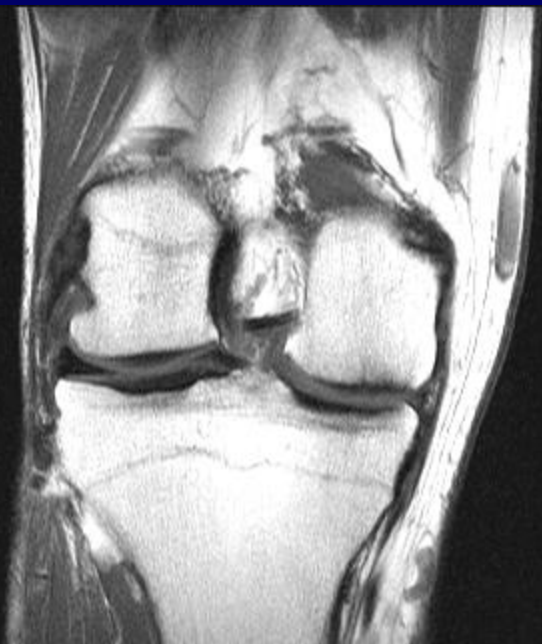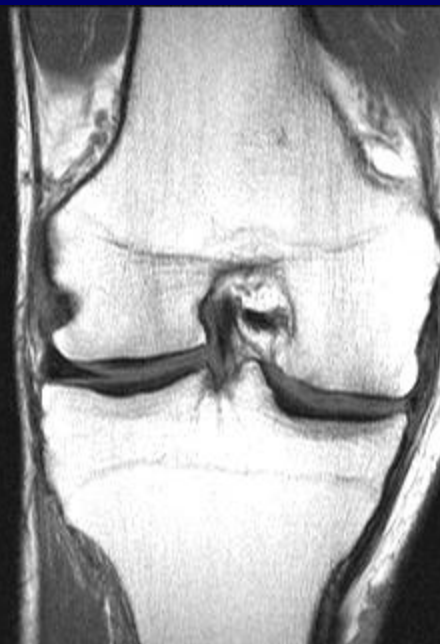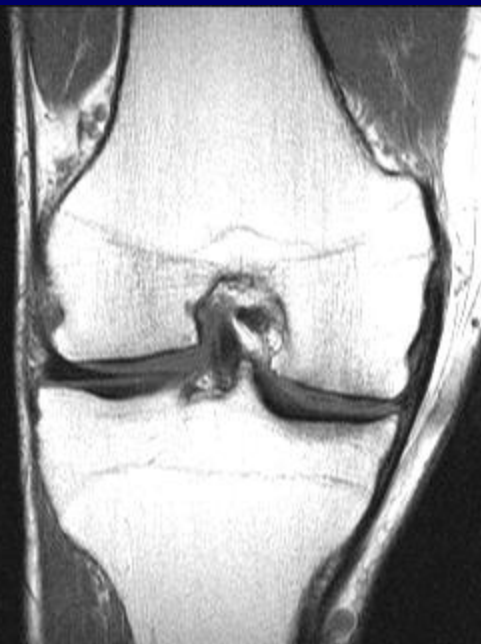October 12th, 2006

Case

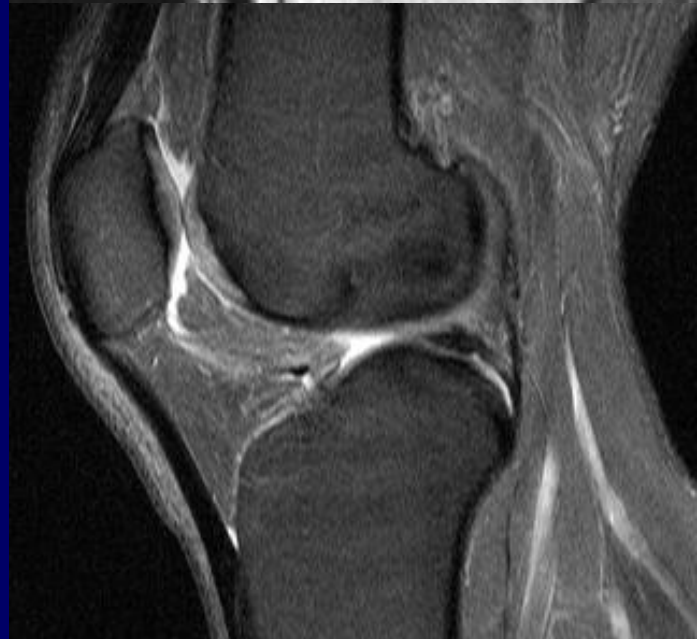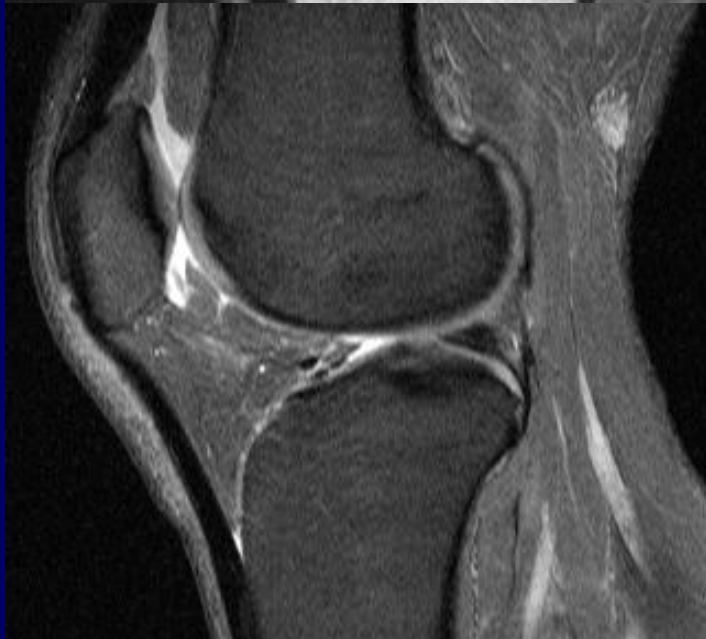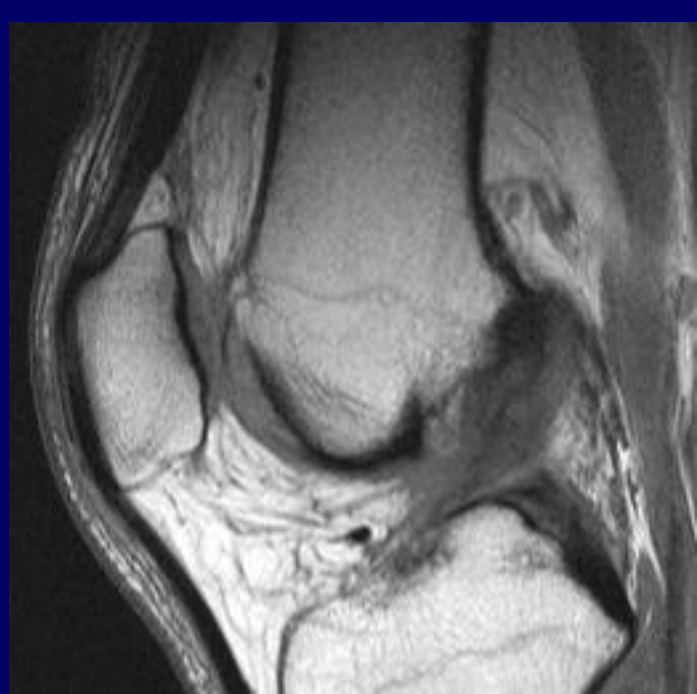
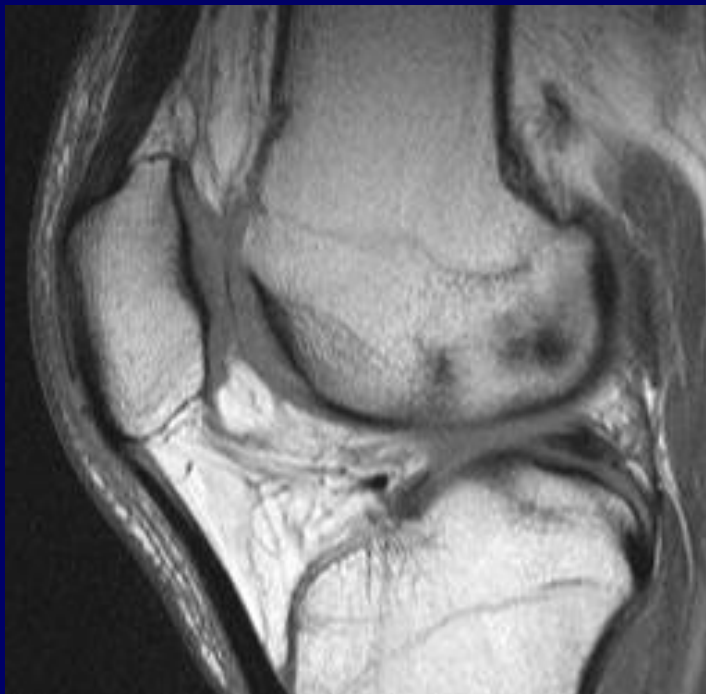- Hx: 58 year-old with chronic knee pain and history of a remote football injury almost 30 years ago where he felt a “pop”
- Findings: PCL tear with prominent ligament of Wrisberg.





Case

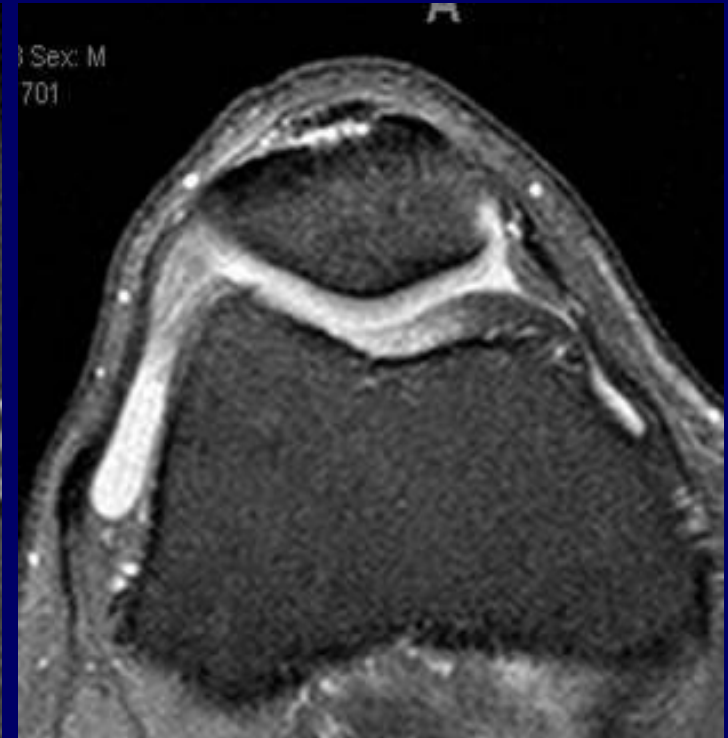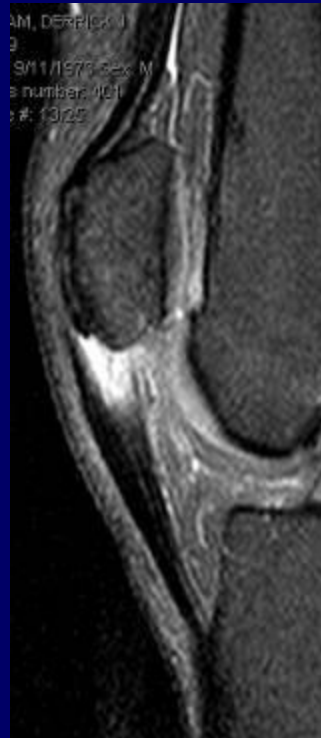
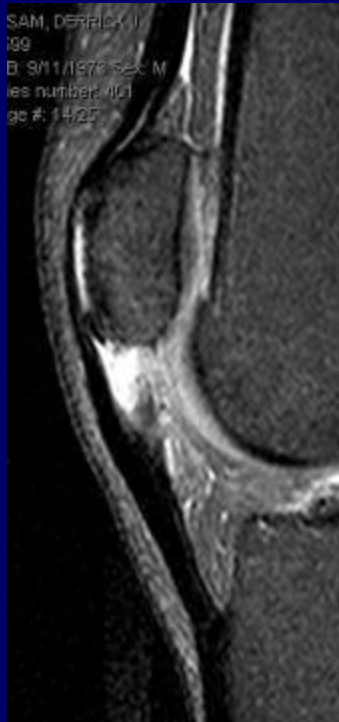
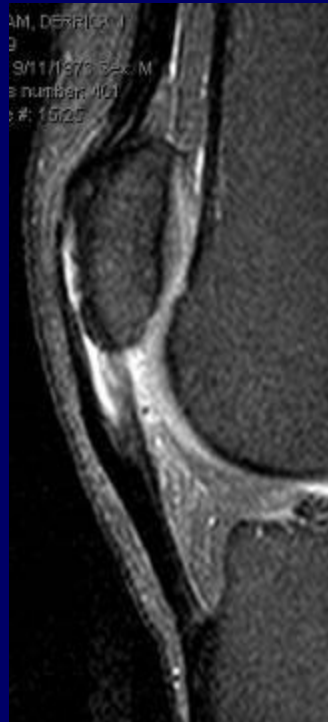
- Hx: Anterior knee pain
- Findings: Disruption of the fibers of the rectus femorus attachment.



Case

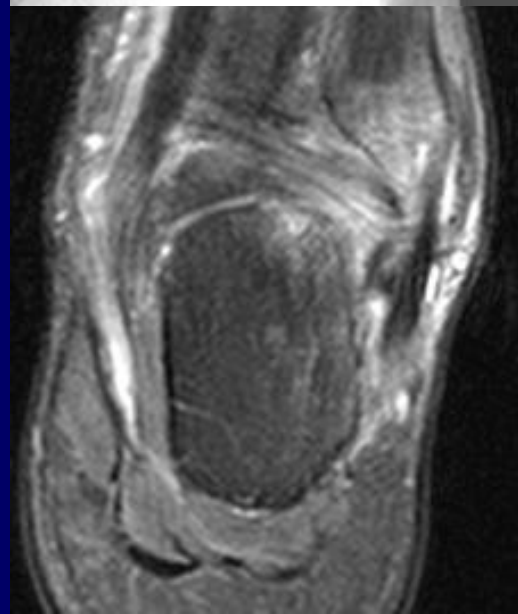
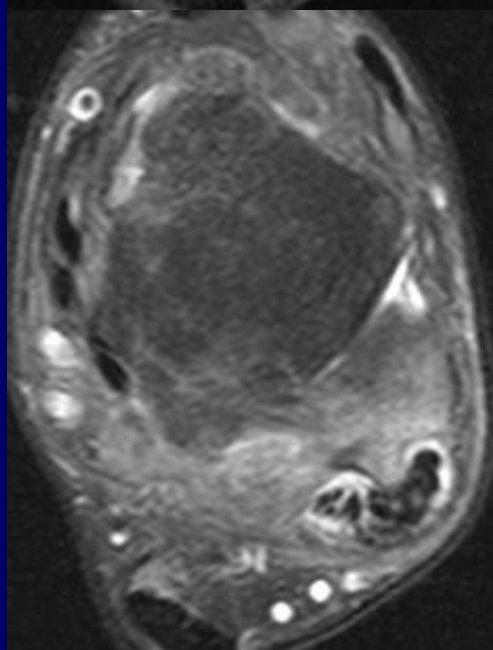
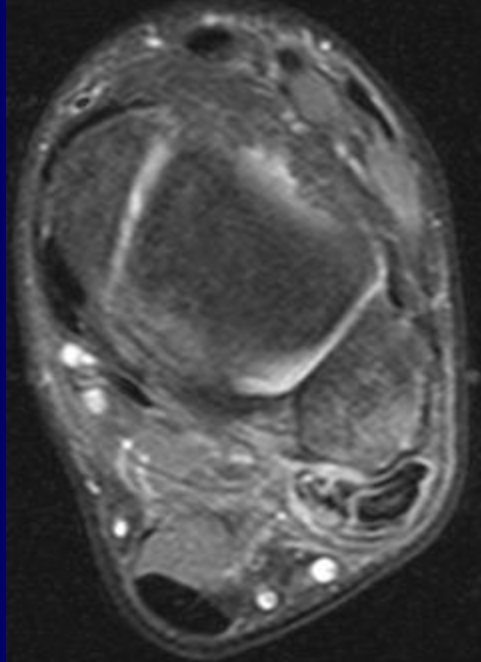
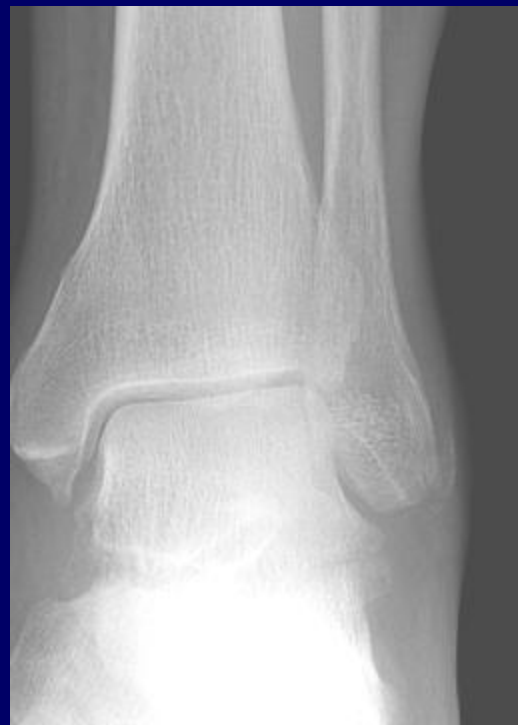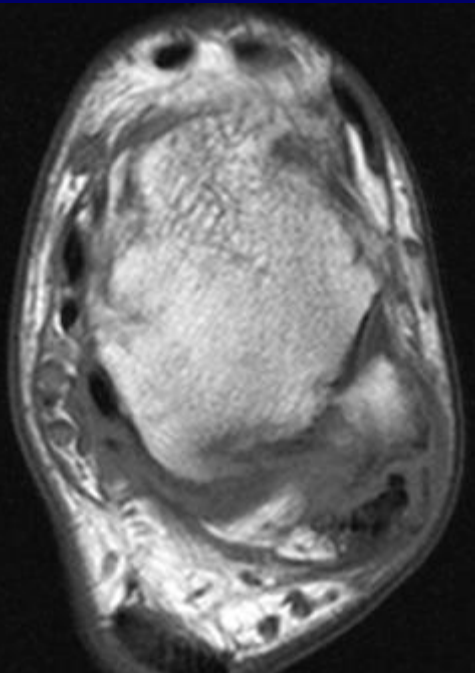
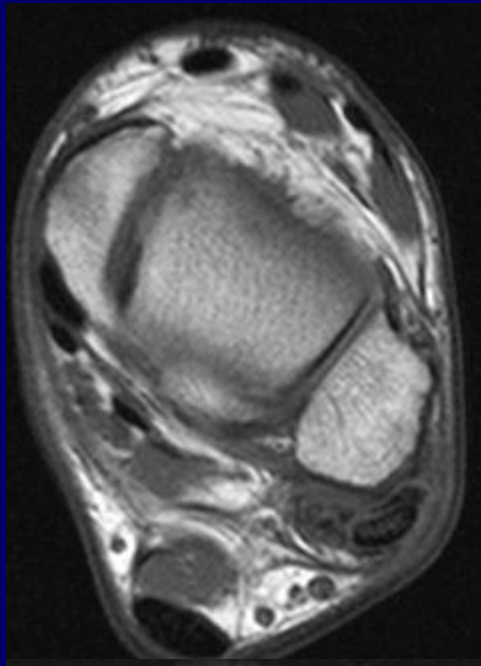
32-year-old male with right knee pain after softball injury 2 mos ago. Now presents with anterior knee pain and soreness.

Delaminating partial tear of patellar tendon, extending to prepatellar quadriceps reflection

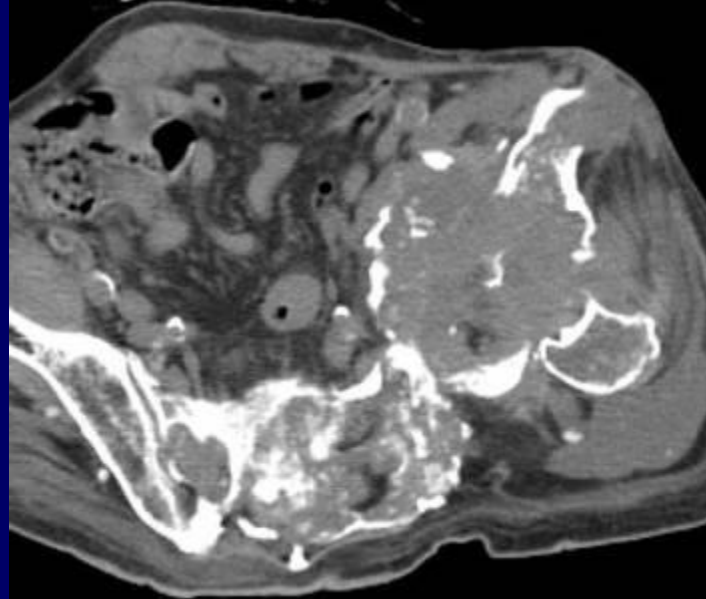
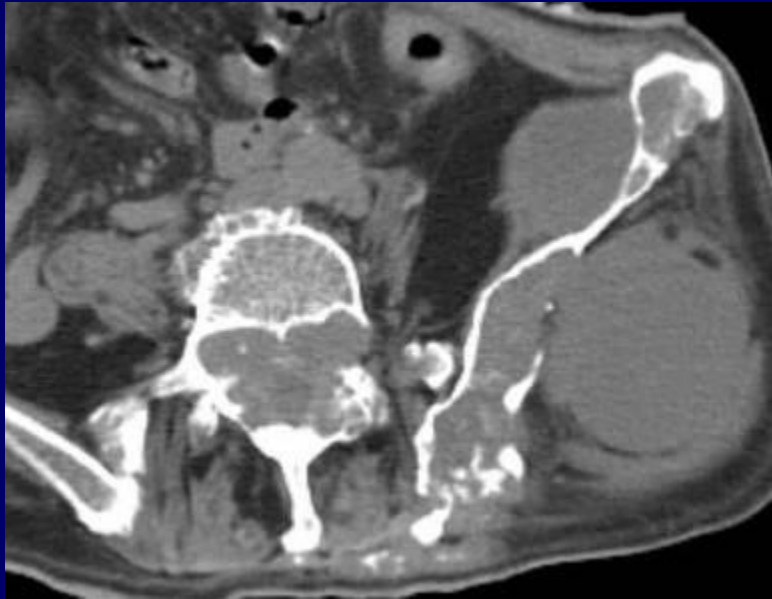


Case

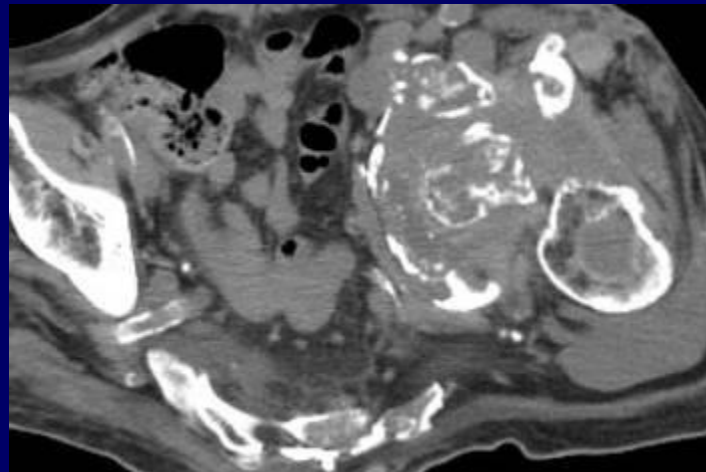
- Hx: Lateral ankle pain. Fracture of fibula on 3 months prior.
- Findings: Tear of the superior peroneal retinaculum with subluxation and tear of the peroneal tendons



Case

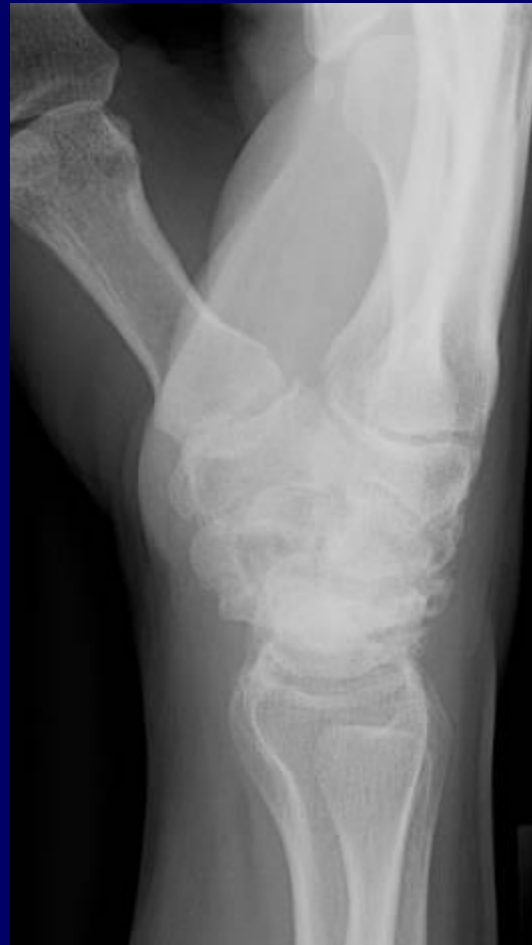
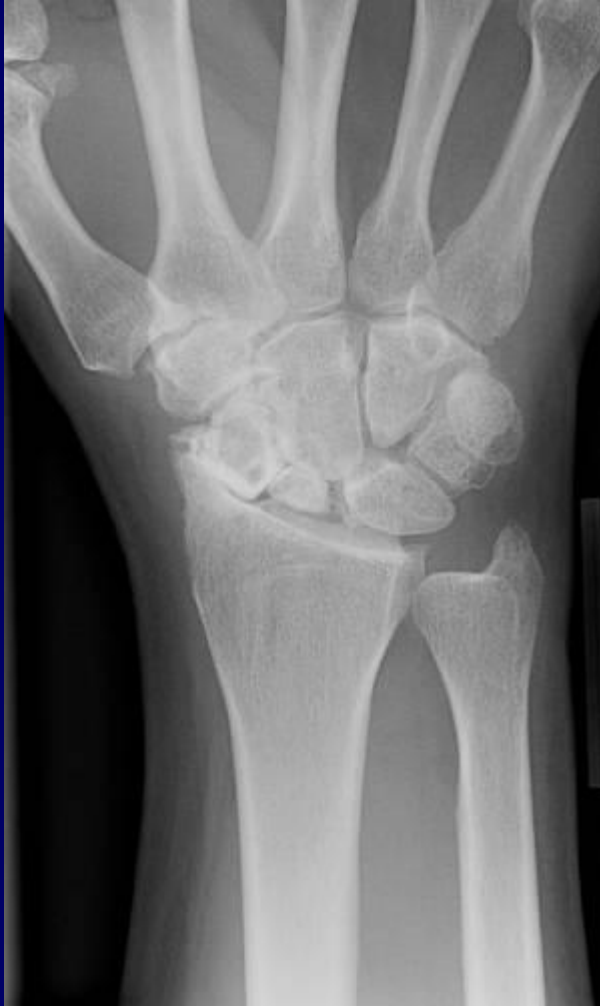
Echinococcus



Case

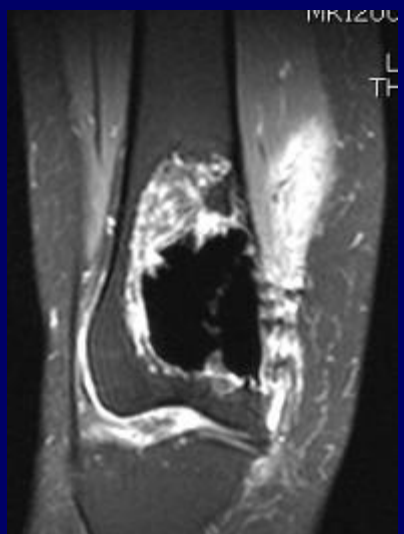
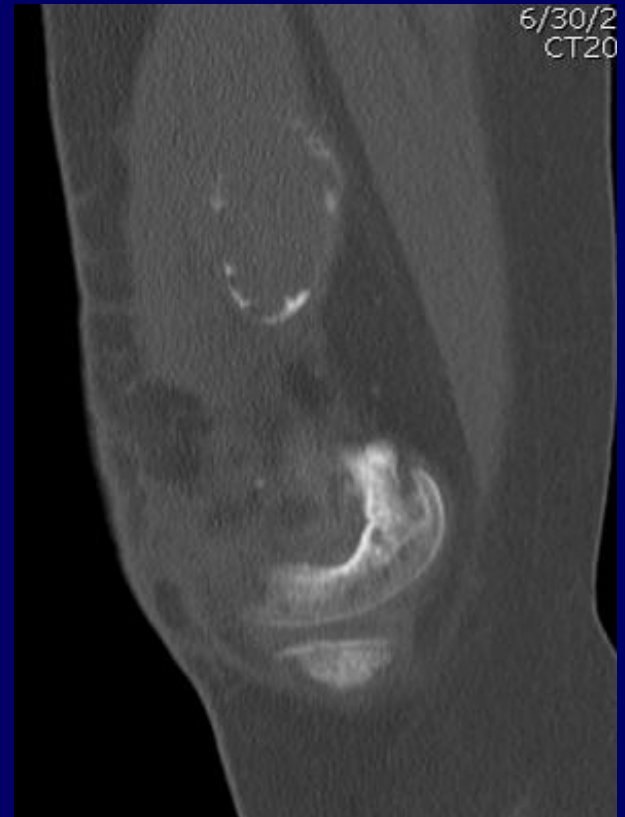
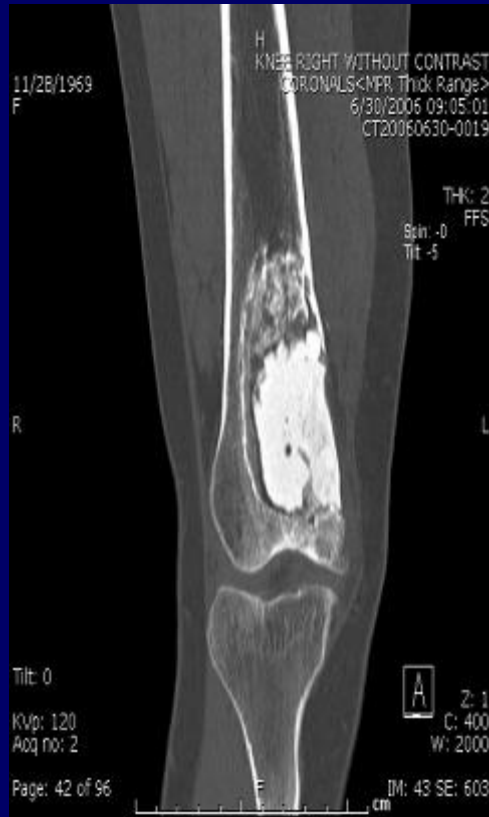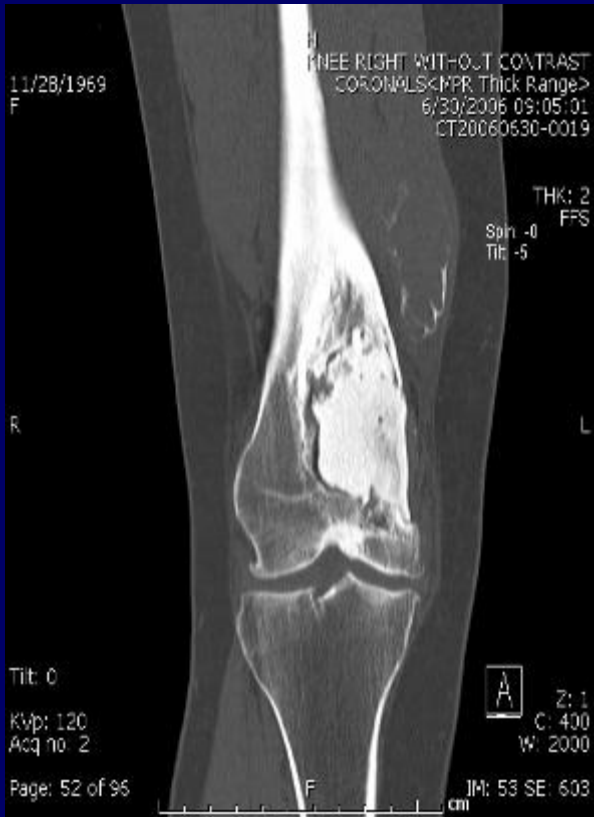SNAC wrist



Case

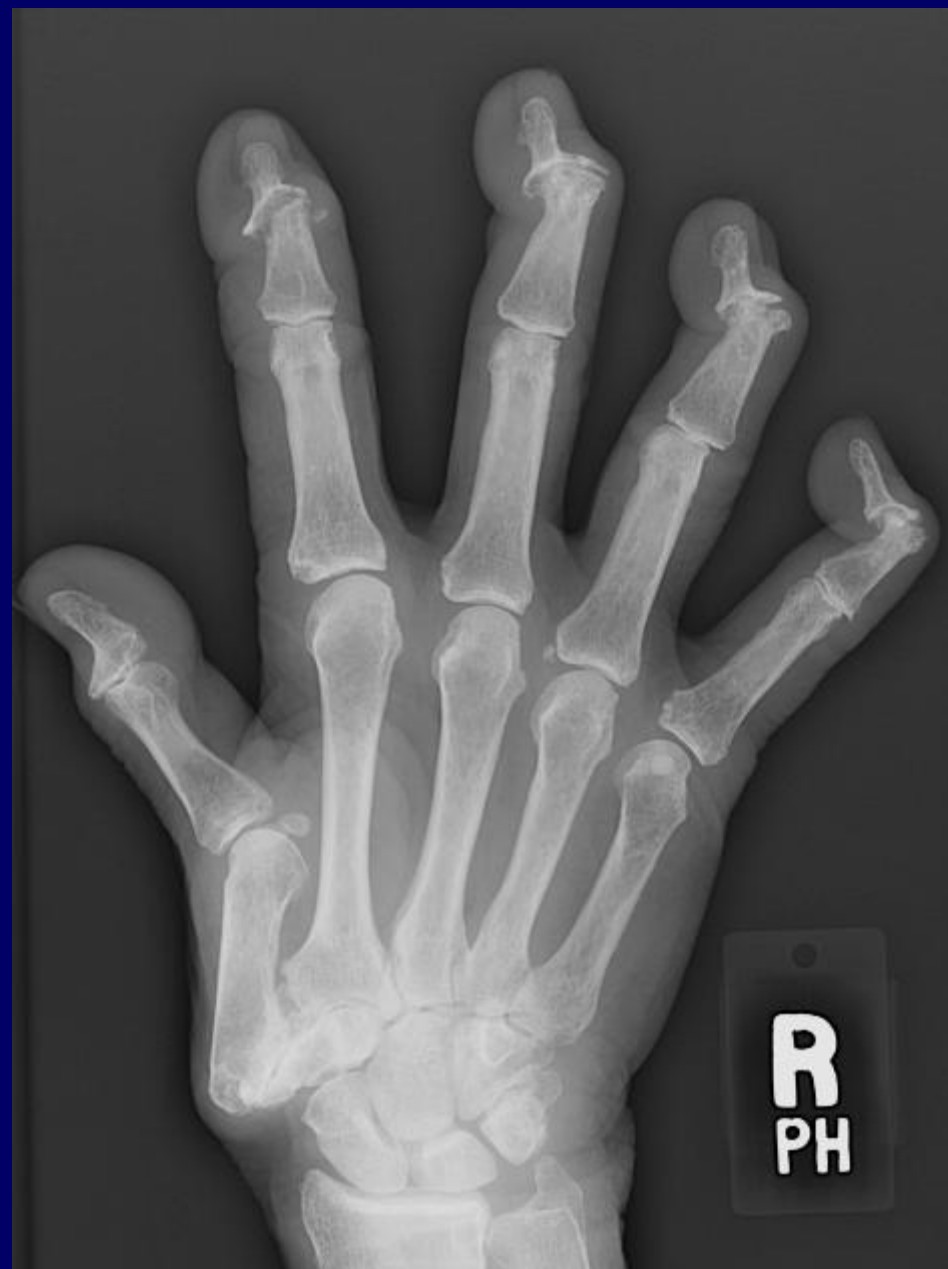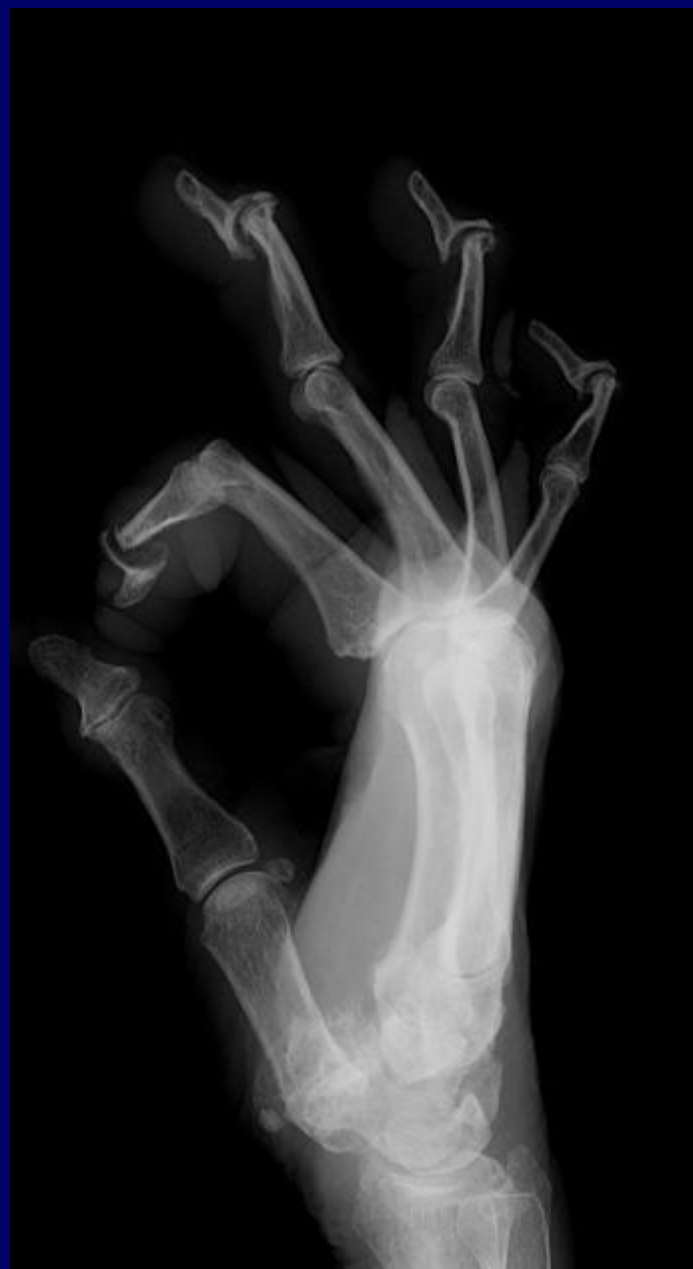37yo female

Giant Cell s/p resection 11/00,
also h/o Lung CA and Sarcoid



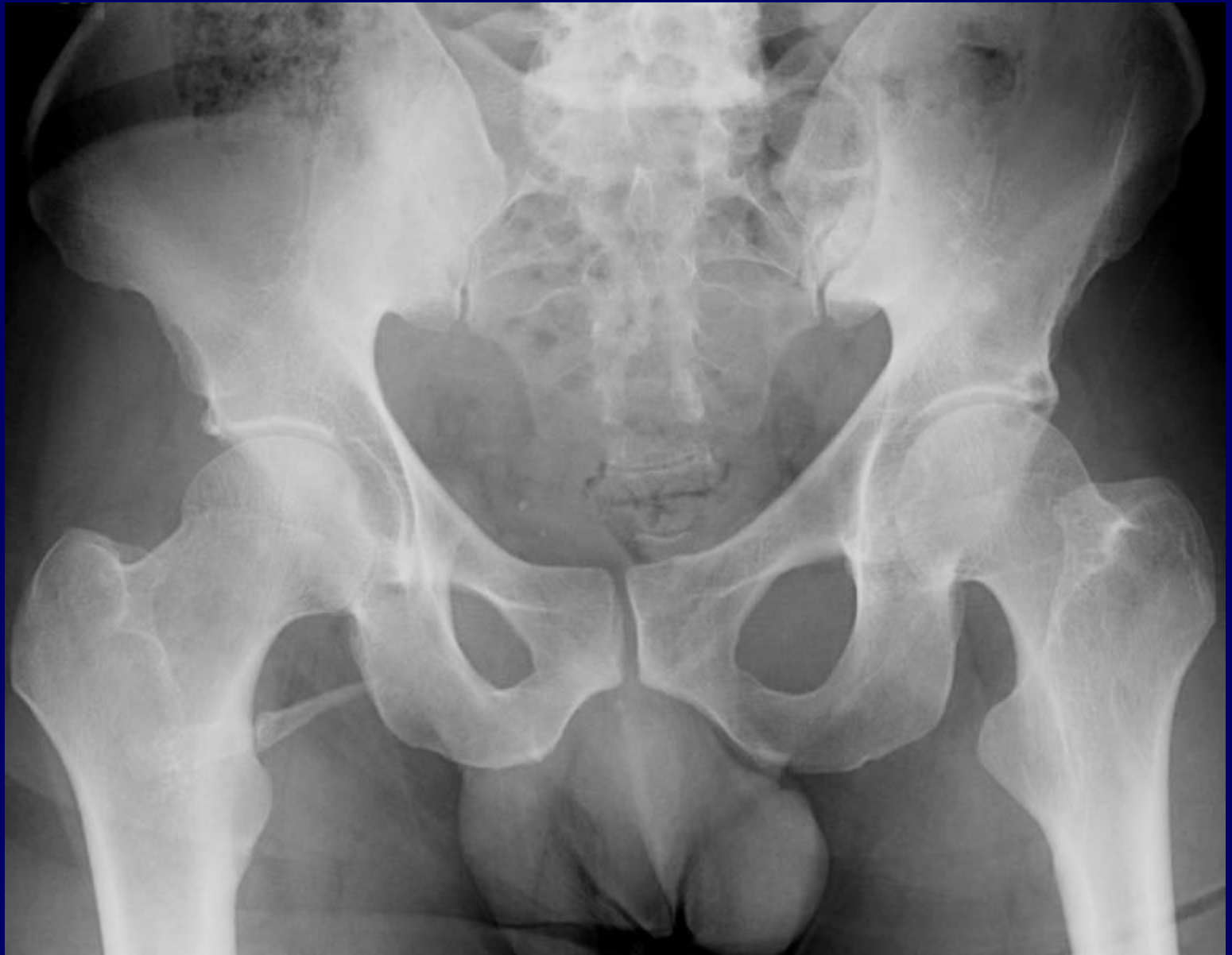Case

81 YEARS OLD COMPLAINS OF
HANDS PAIN



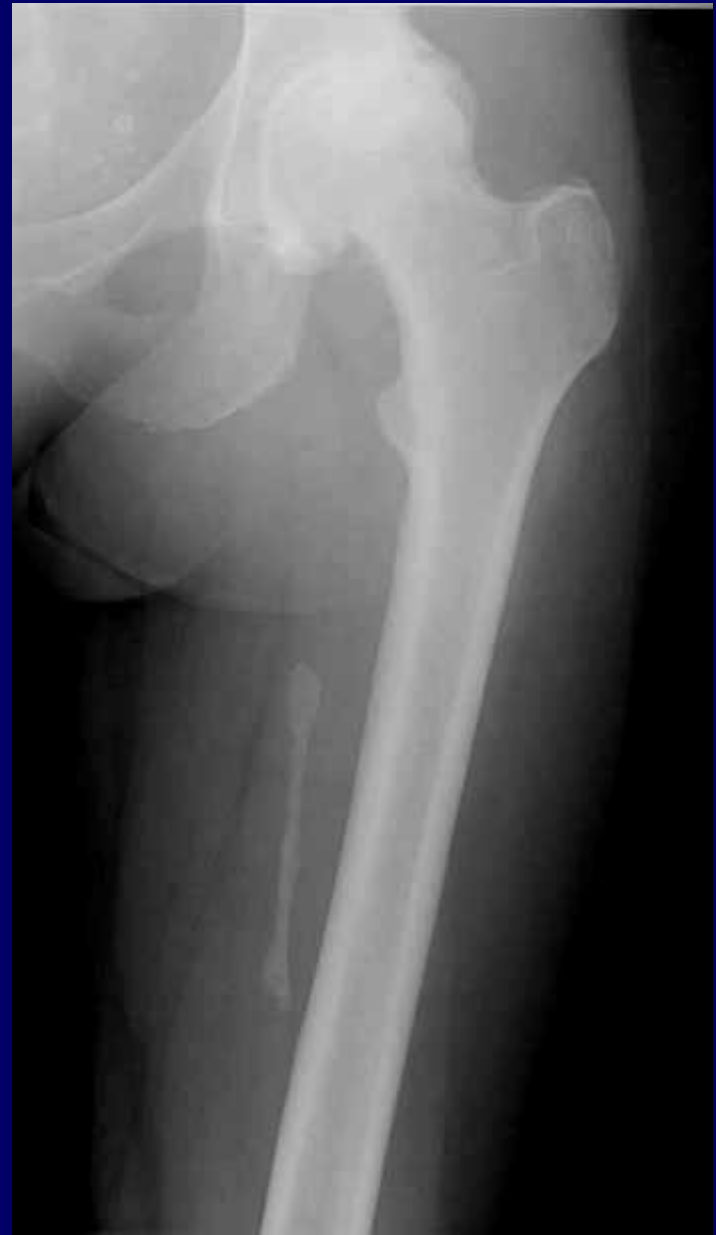Case

Pelvic digit



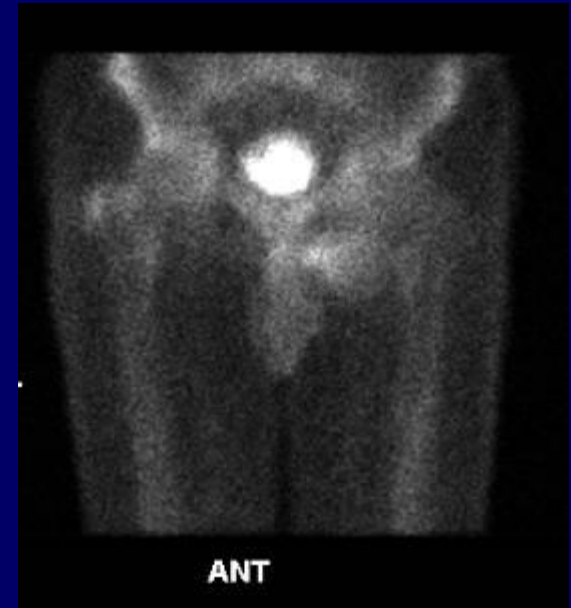
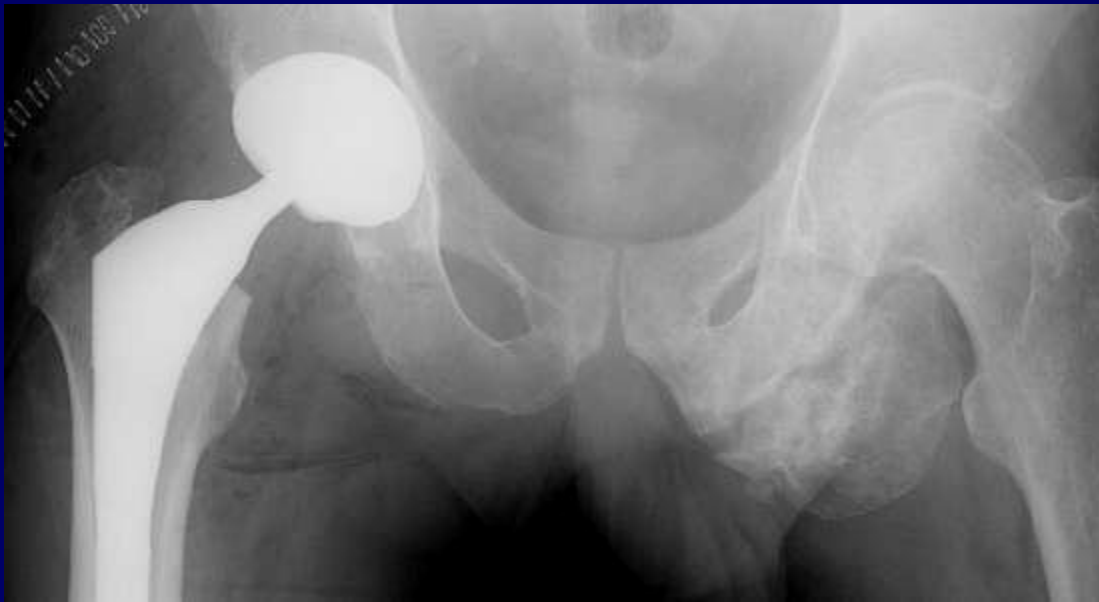Case

Myositis Ossificans
Rider's Bone

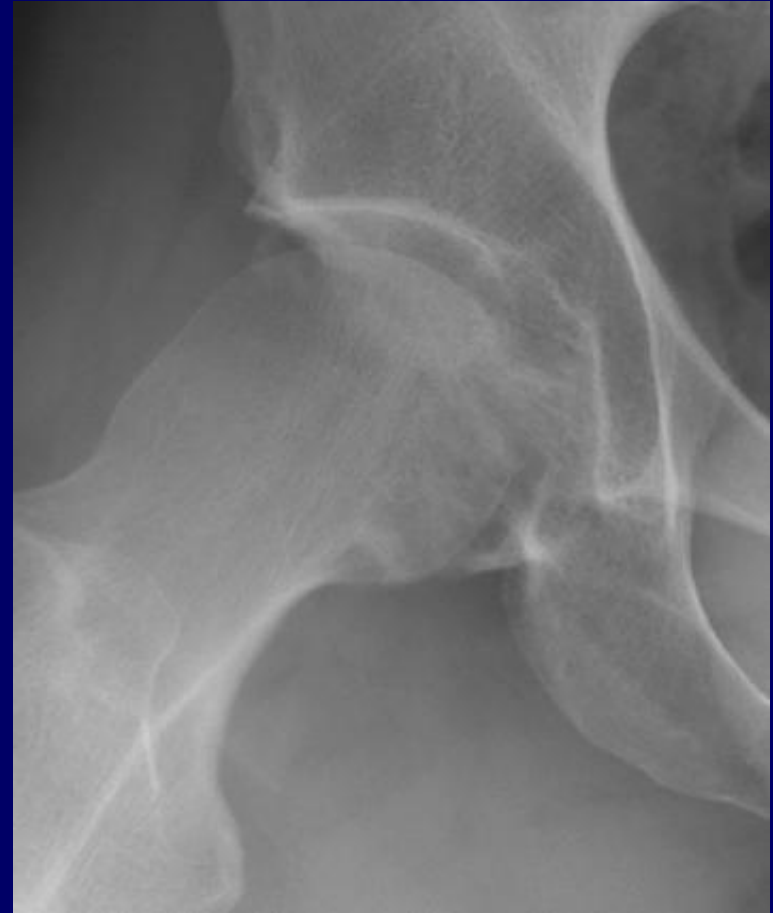
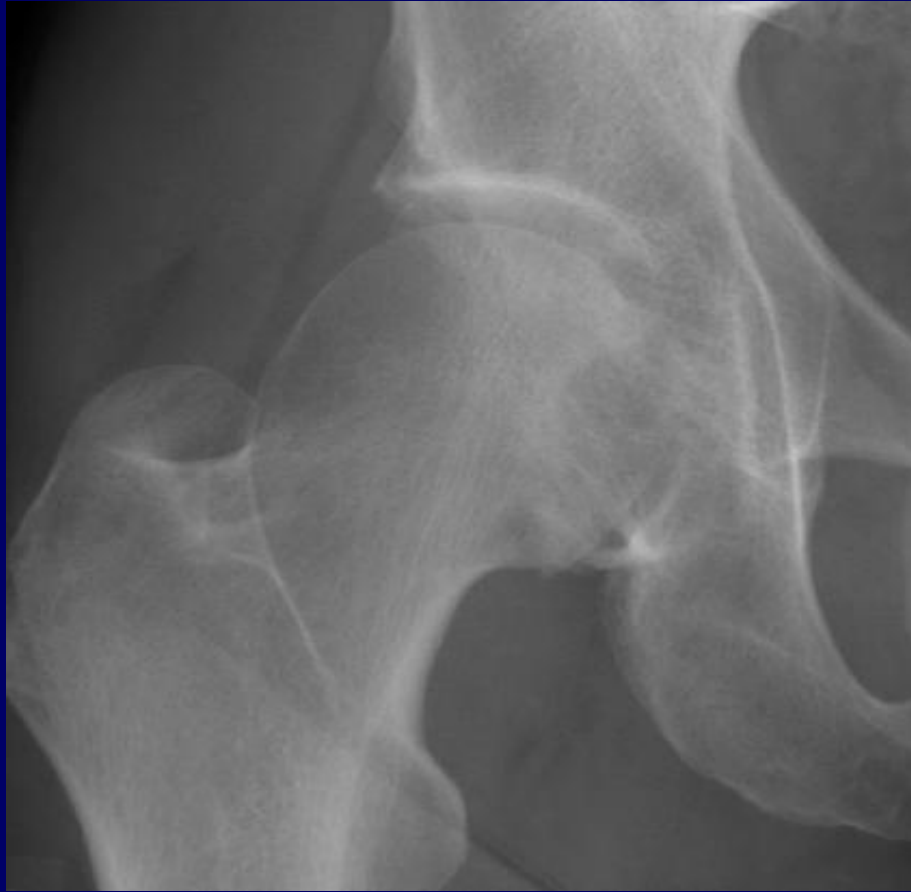
Case

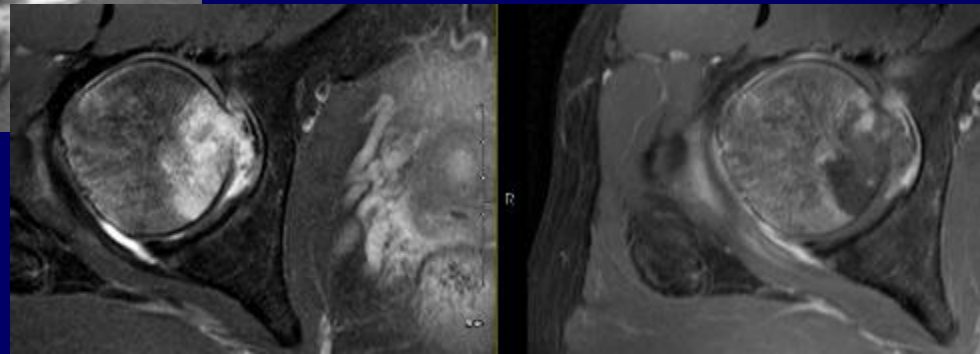
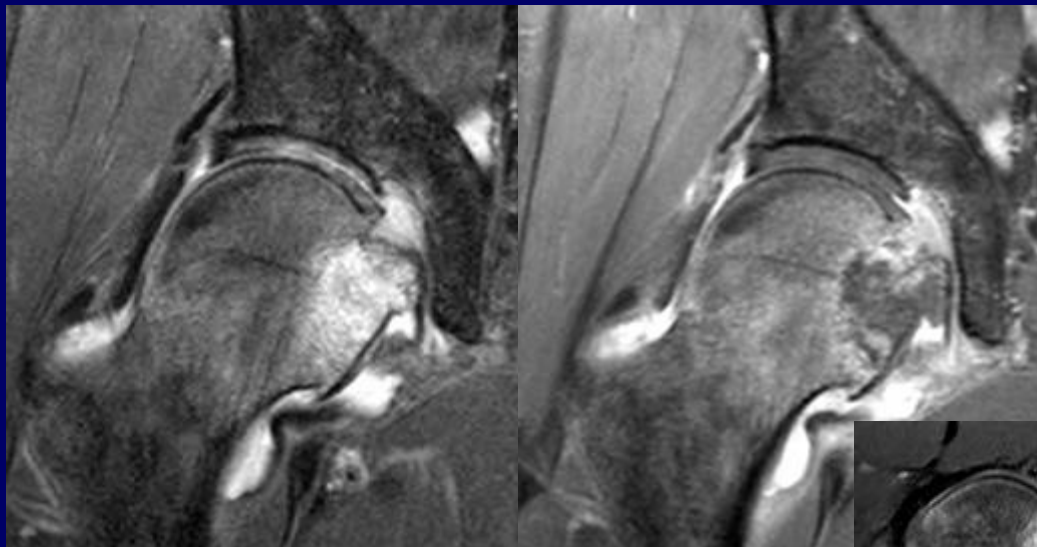
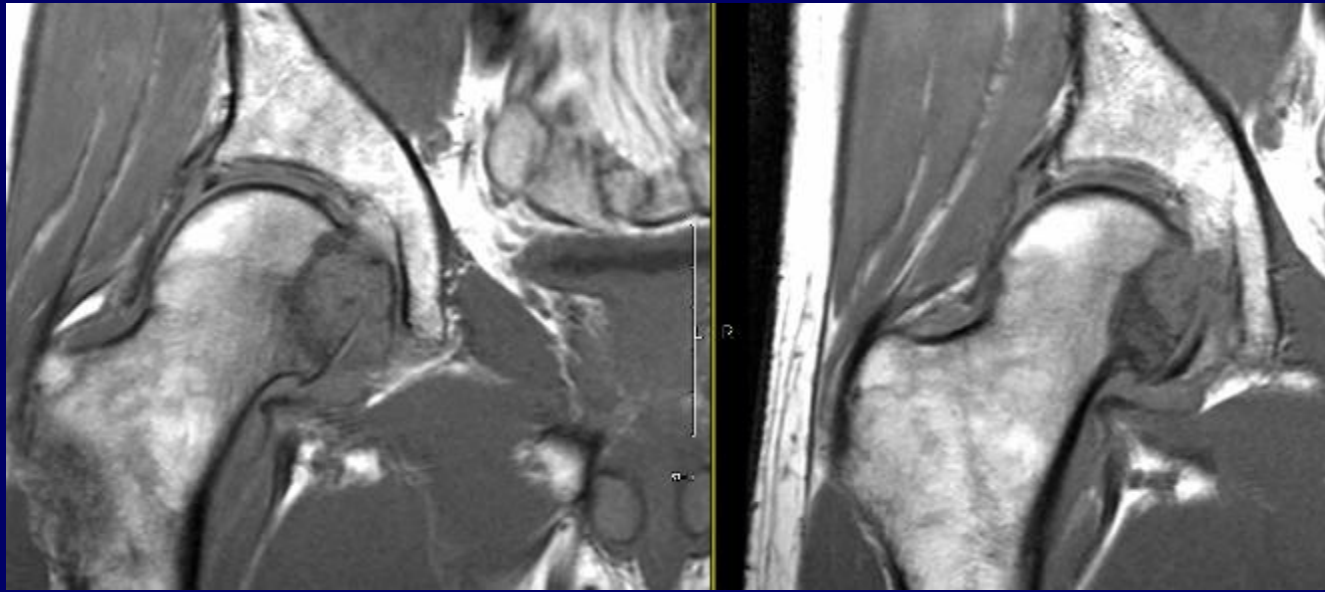
52 year old male with hip pain.
Avulsion ischial tuberosity



Case



Courtesy of E. Fliczar, M.D.

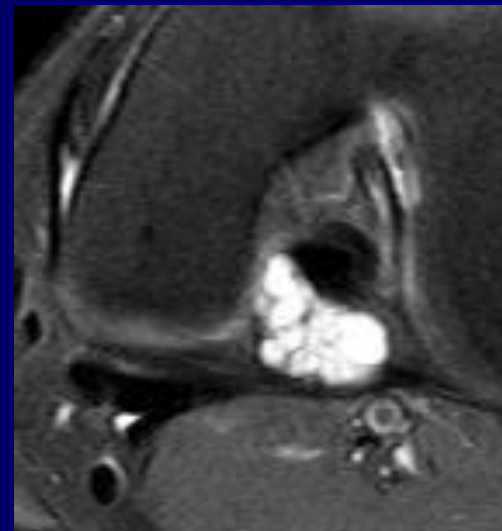
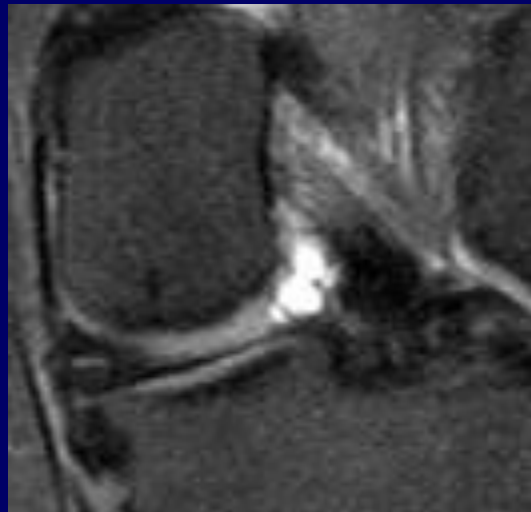
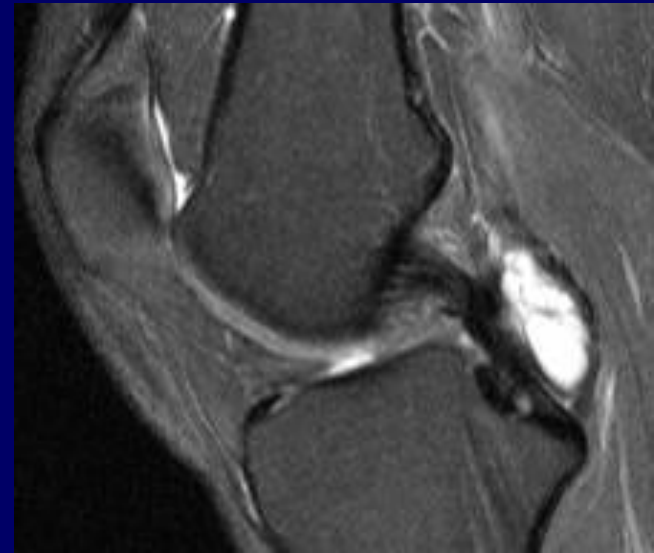
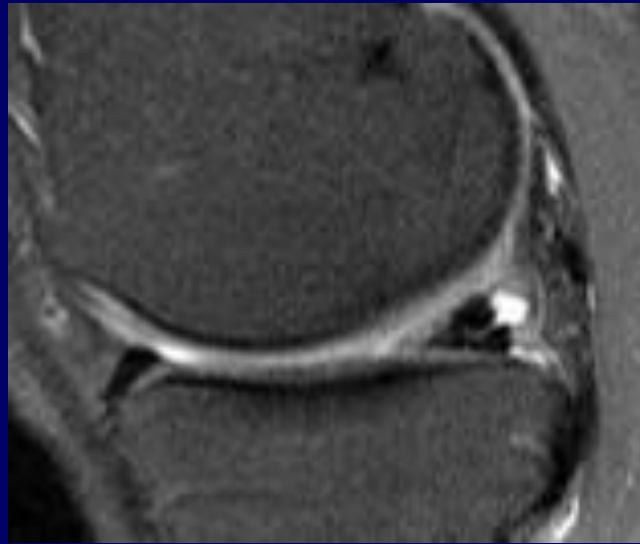


Clear-cell chondrosarcoma

Case

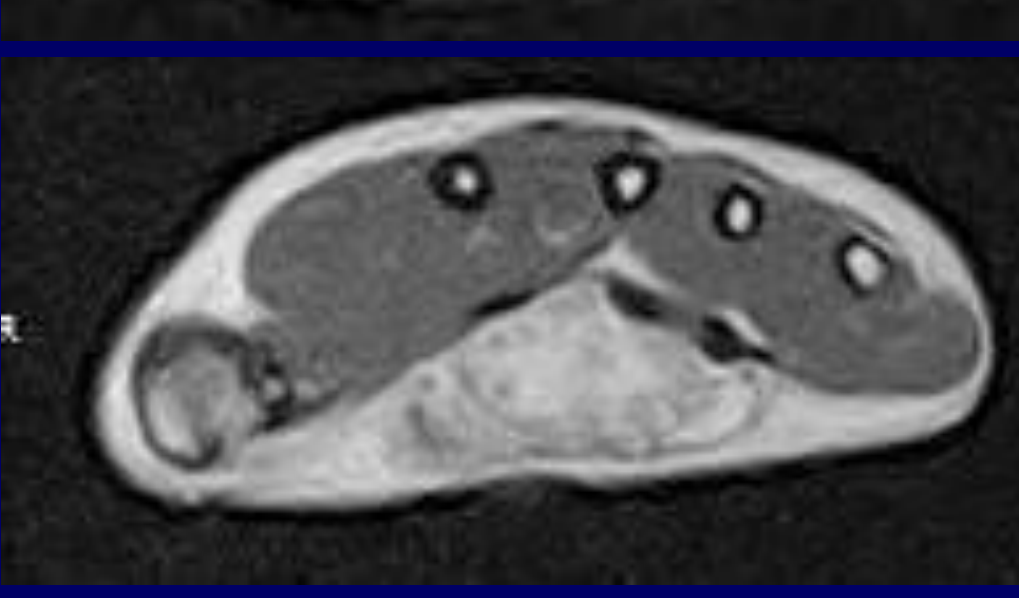
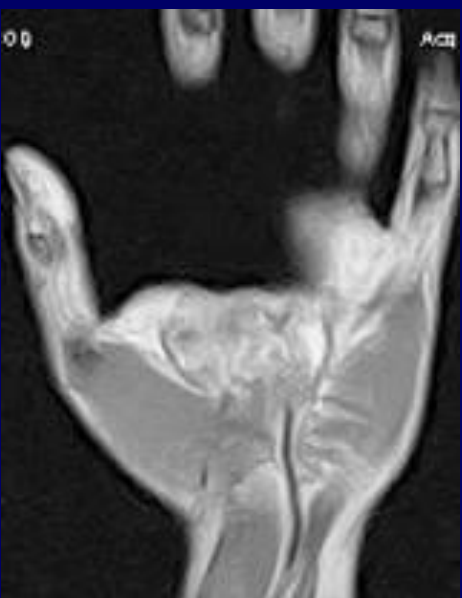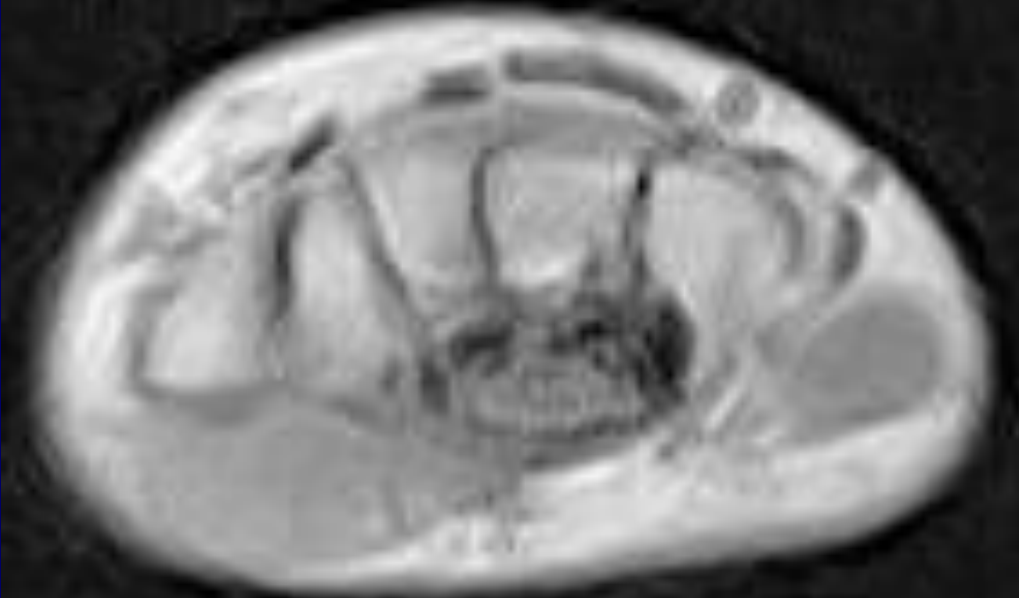
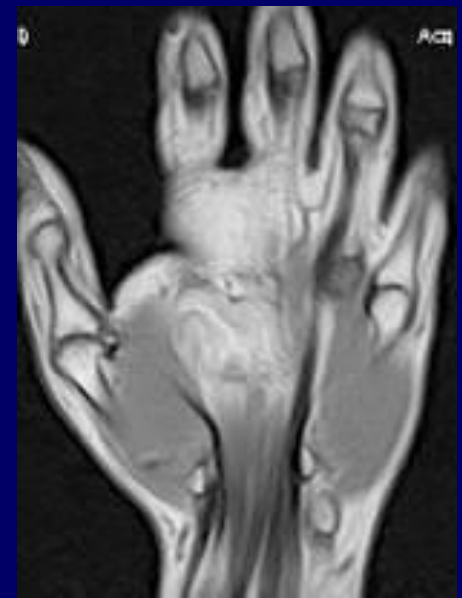
29 yo Female six weeks post snowboarding injury, twisted knee.

Meniscal Cyst



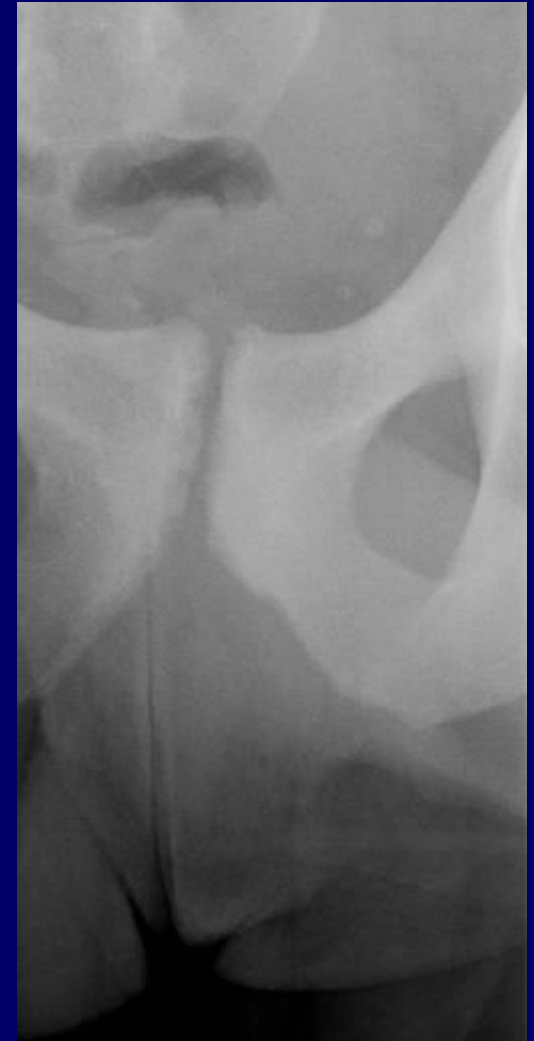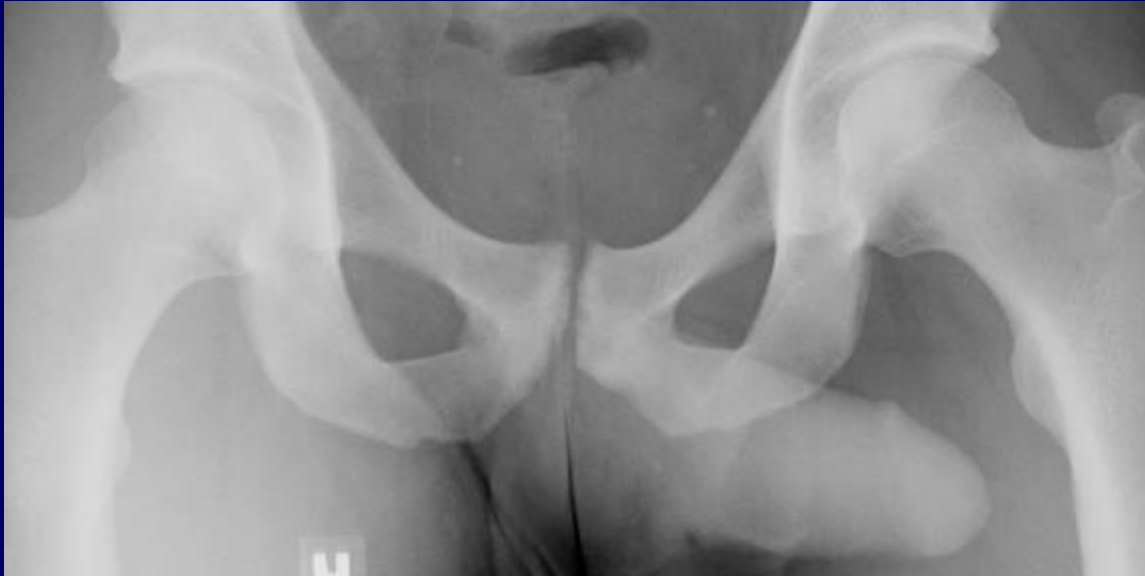Case

- 30 Years, mechanic with carpal tunnel syndrome.
- Soft tissue mass in the palm.



Fibrolipomatous Hamartoma

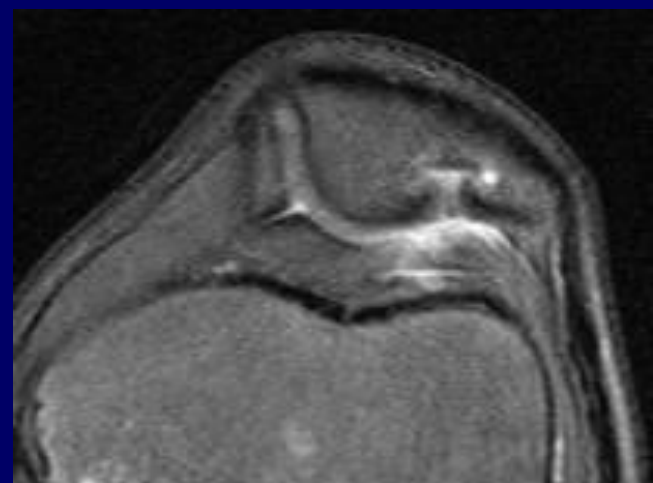
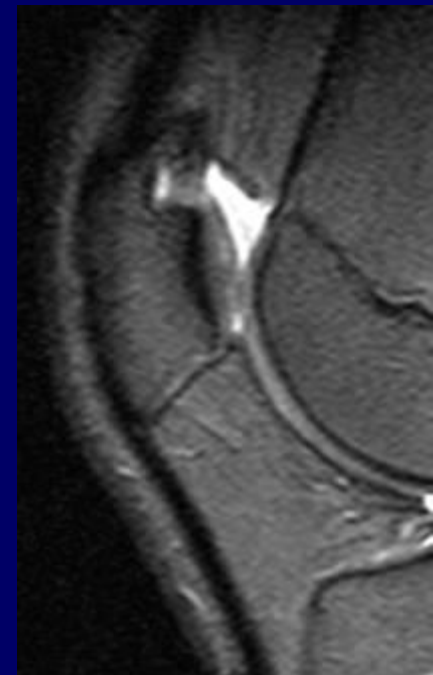
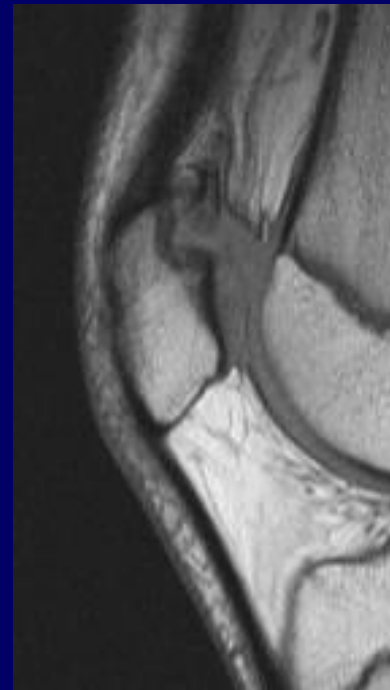
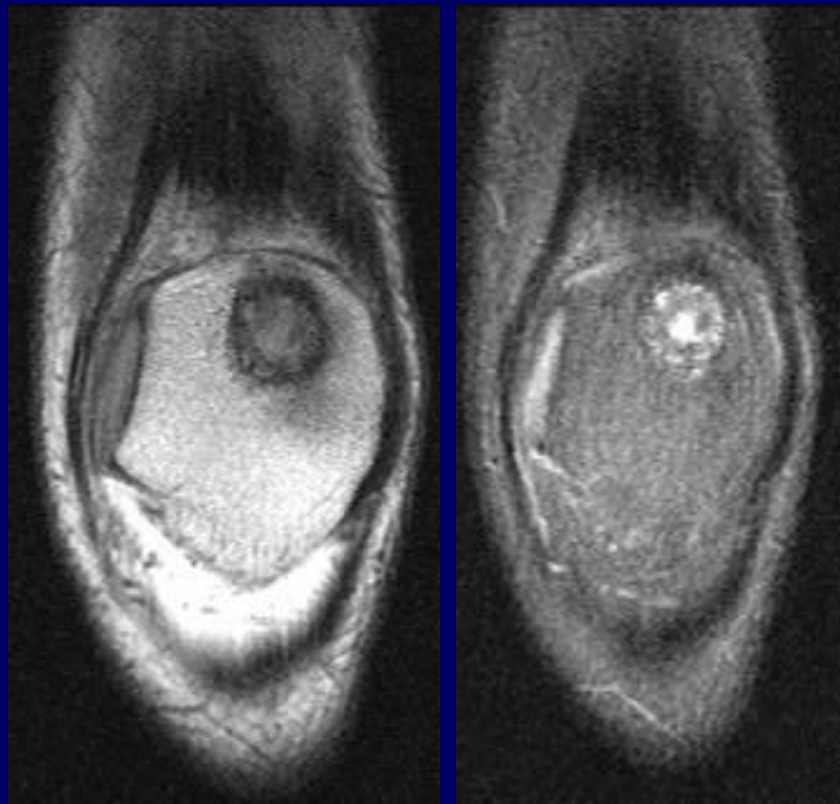
Case



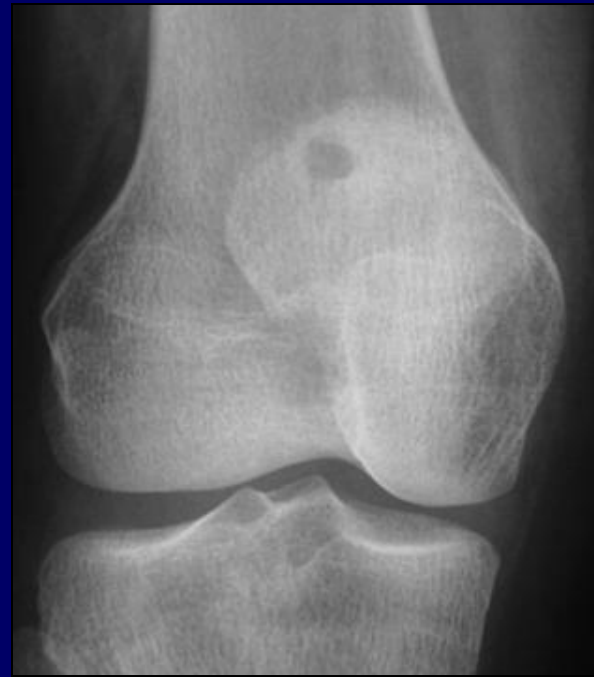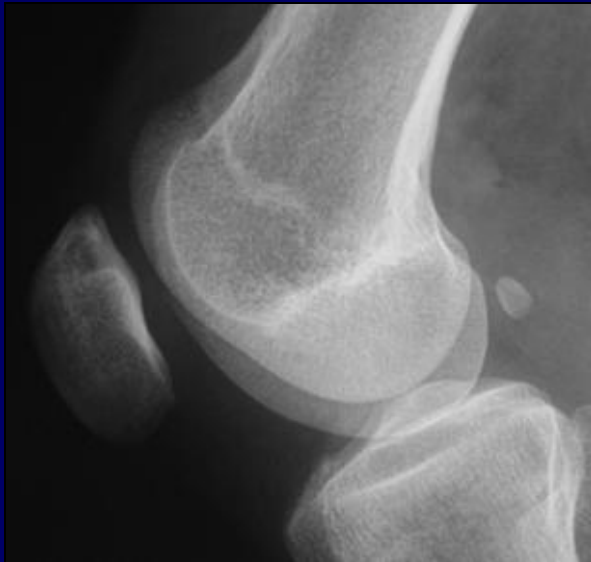
Young pt with pain – adductor avulsion injury

Case

- 16 year old boy with history of Langerhan's cell histiocytosis status post EG lesion excision from skull in October, 2004. Now complains of left knee pain which is mostly after running and jumping and straight leg raises.

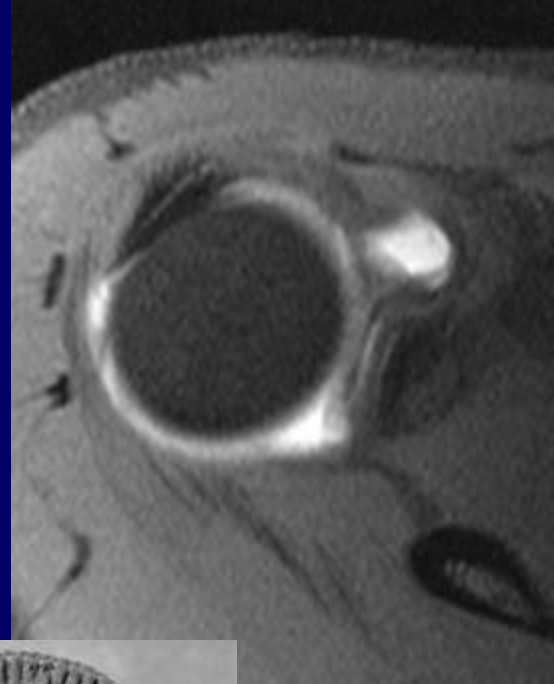
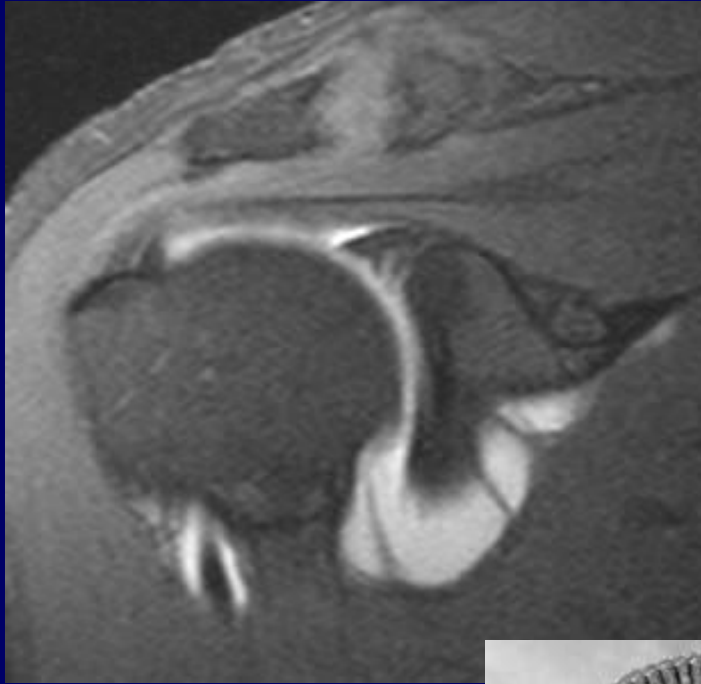


CASE



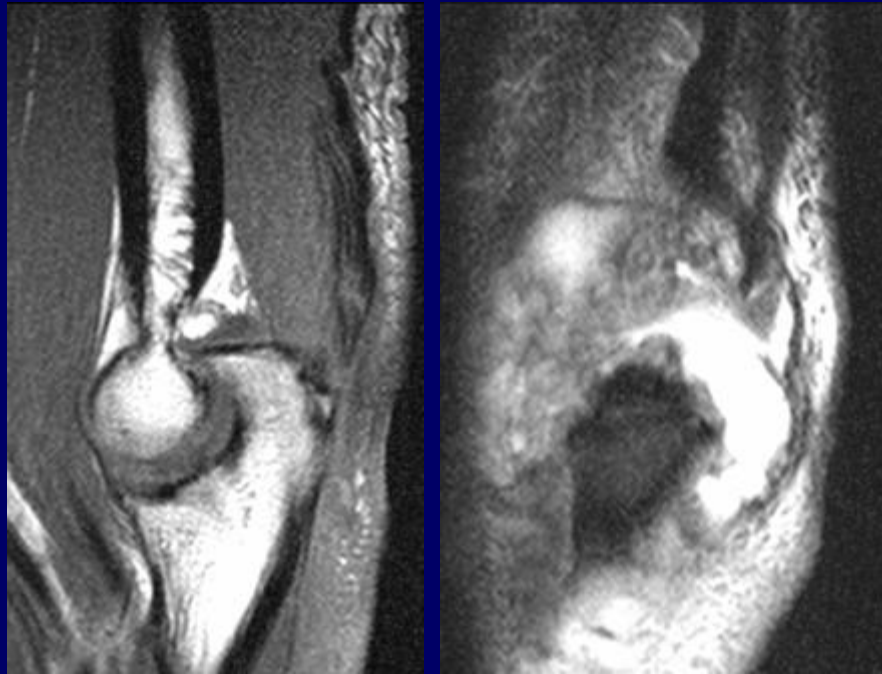
Case

- 46 year old male with shoulder pain. No trauma history per patient.



Case

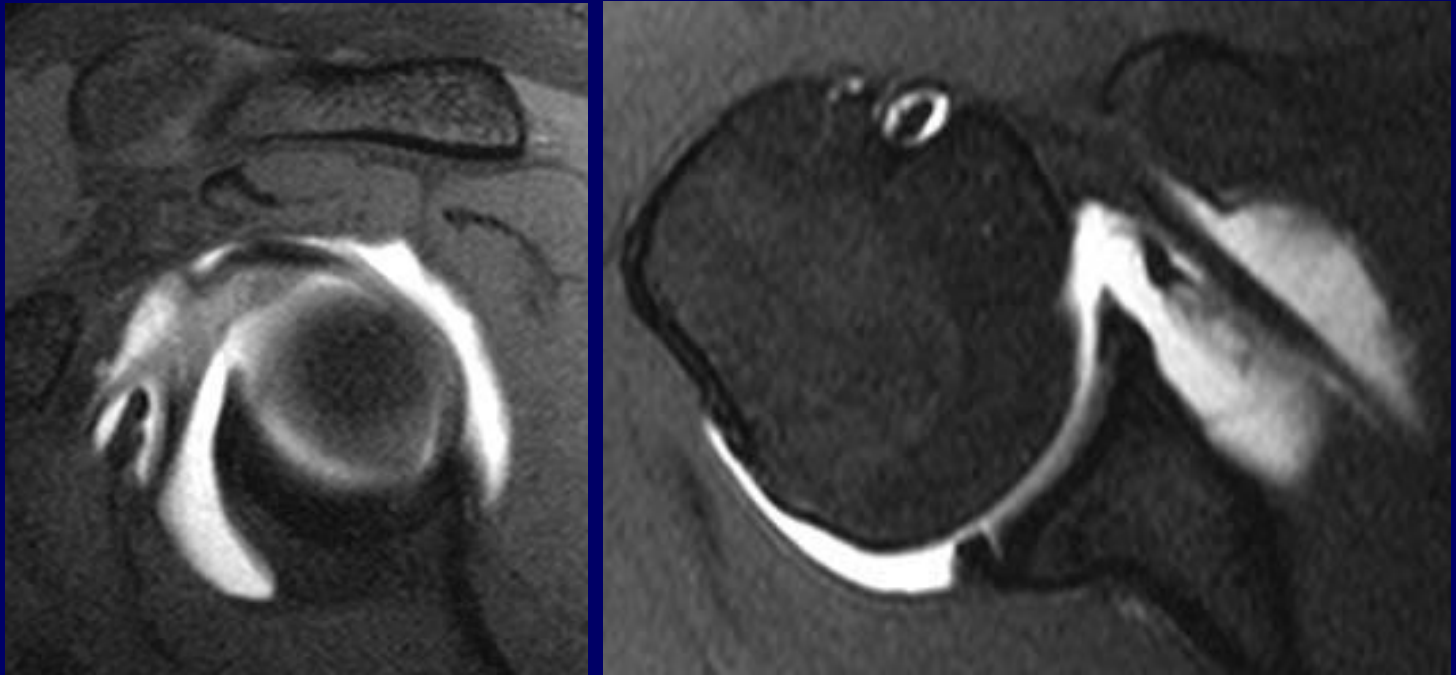
70 year old male avid horseman who fell from horse and injured his right elbow two weeks prior to this study.



Triceps tendon rupture

Case

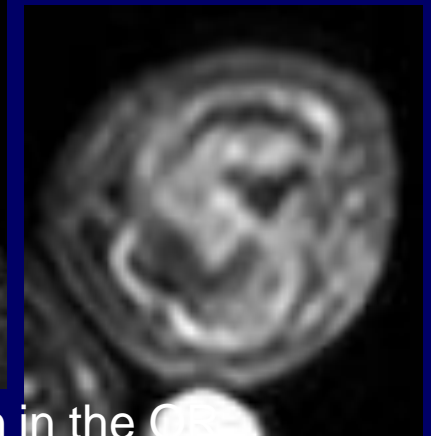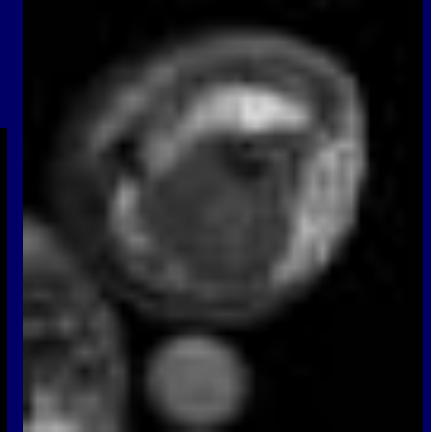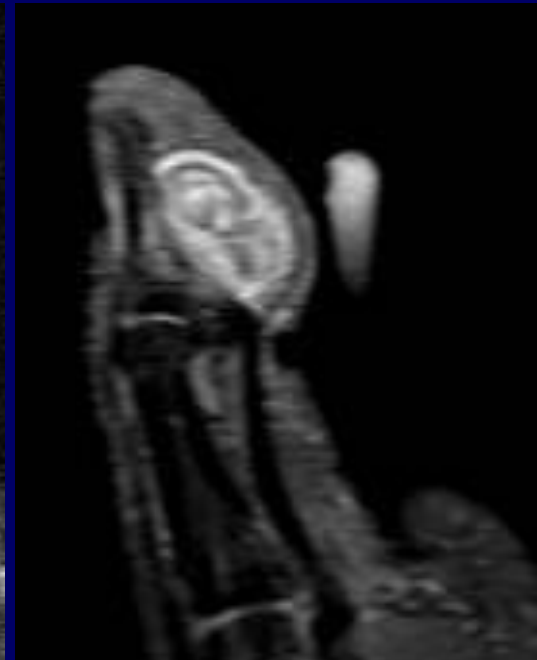
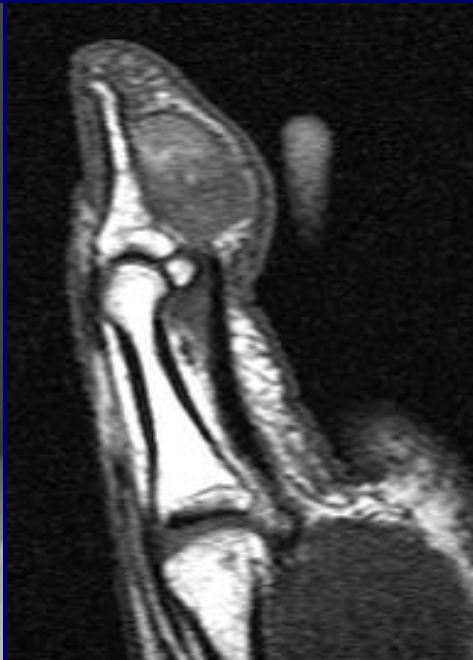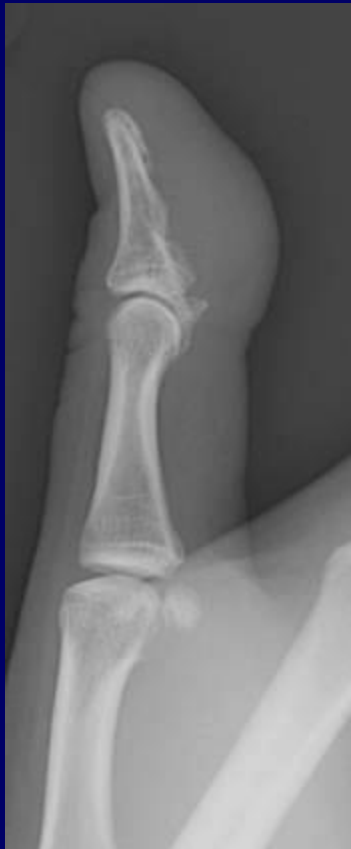12 yo male pain only when throwing the football.



Buford Complex

Case

- 40 yo with soft tissue mass in thumb



Pathology reported as ganglion cyst
Dr. Hamer thought it was an AV malformation in the CM
(reddish/brown)

Intimate with FPL tendon but easily dissected out