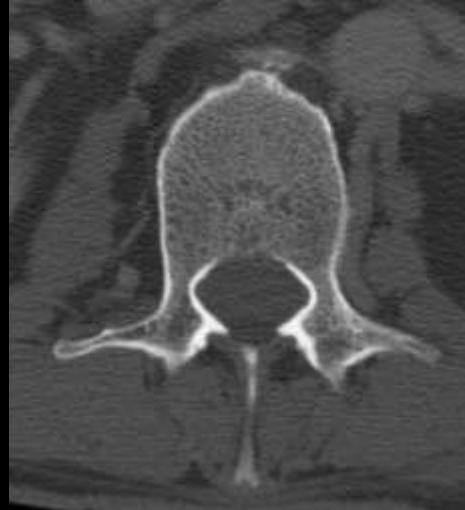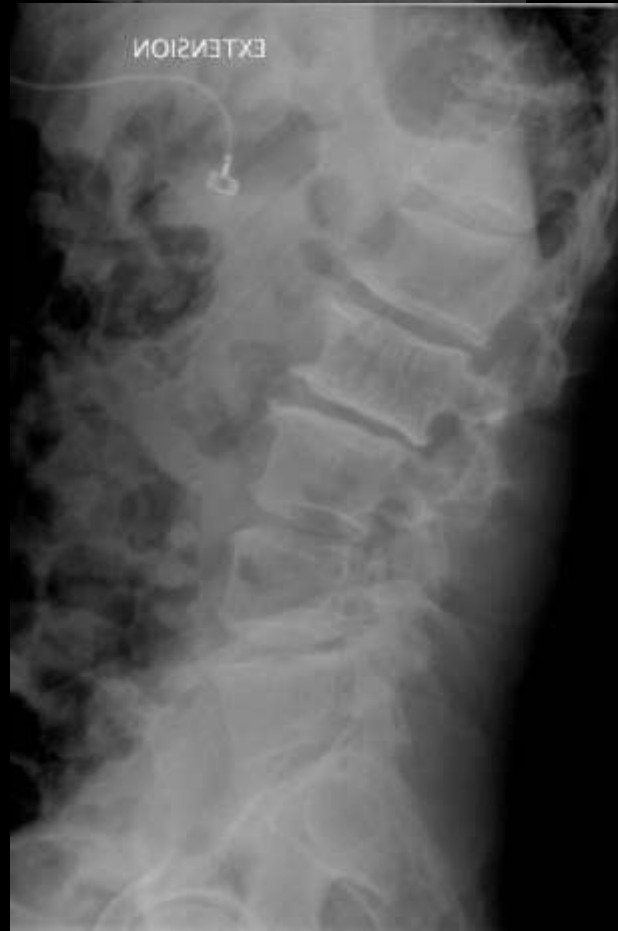
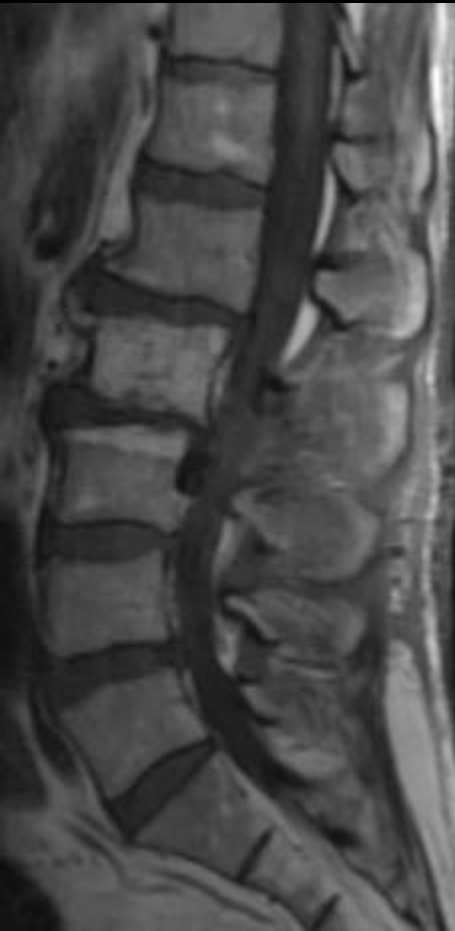
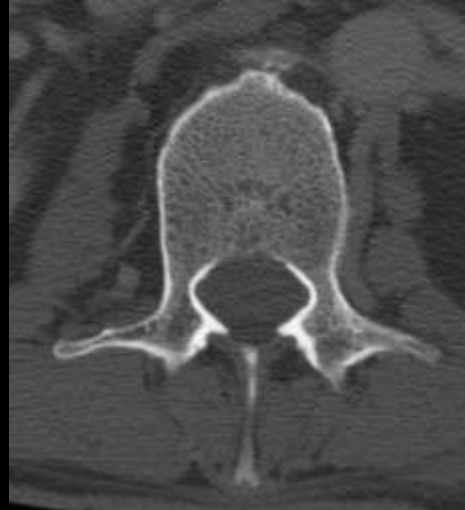
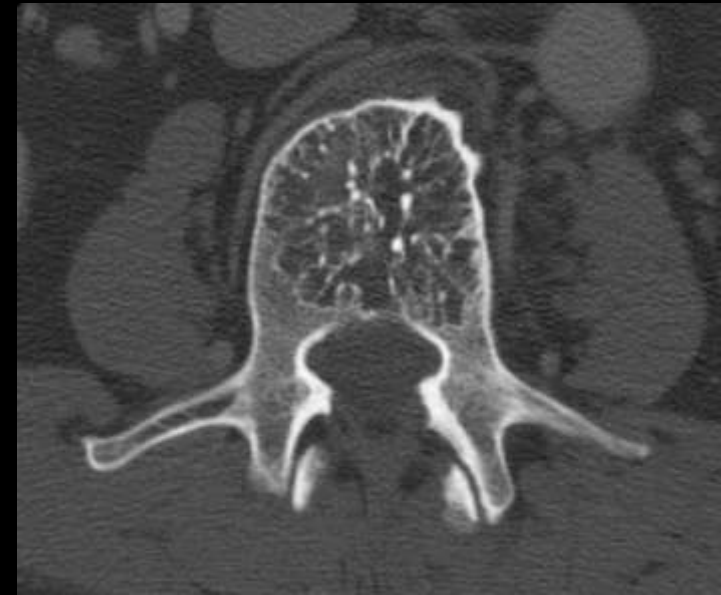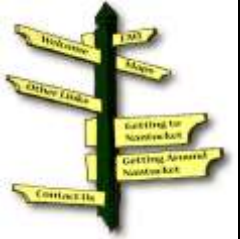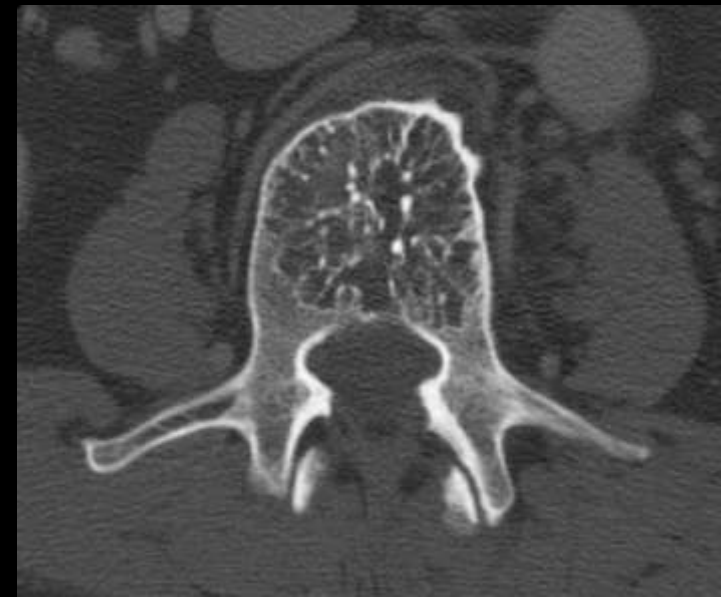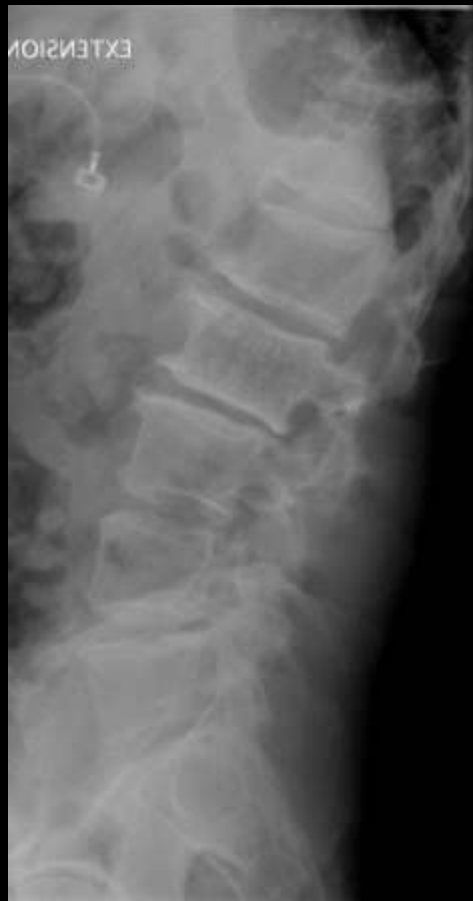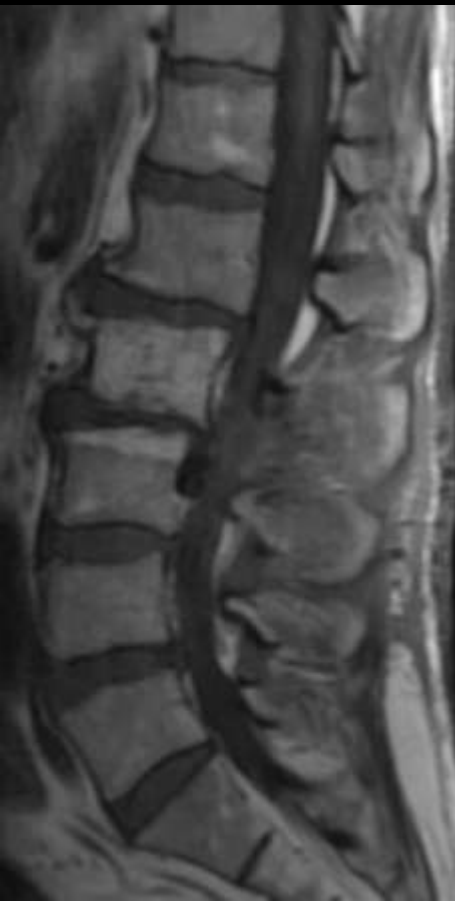## Corduroy Sign Hemangioma





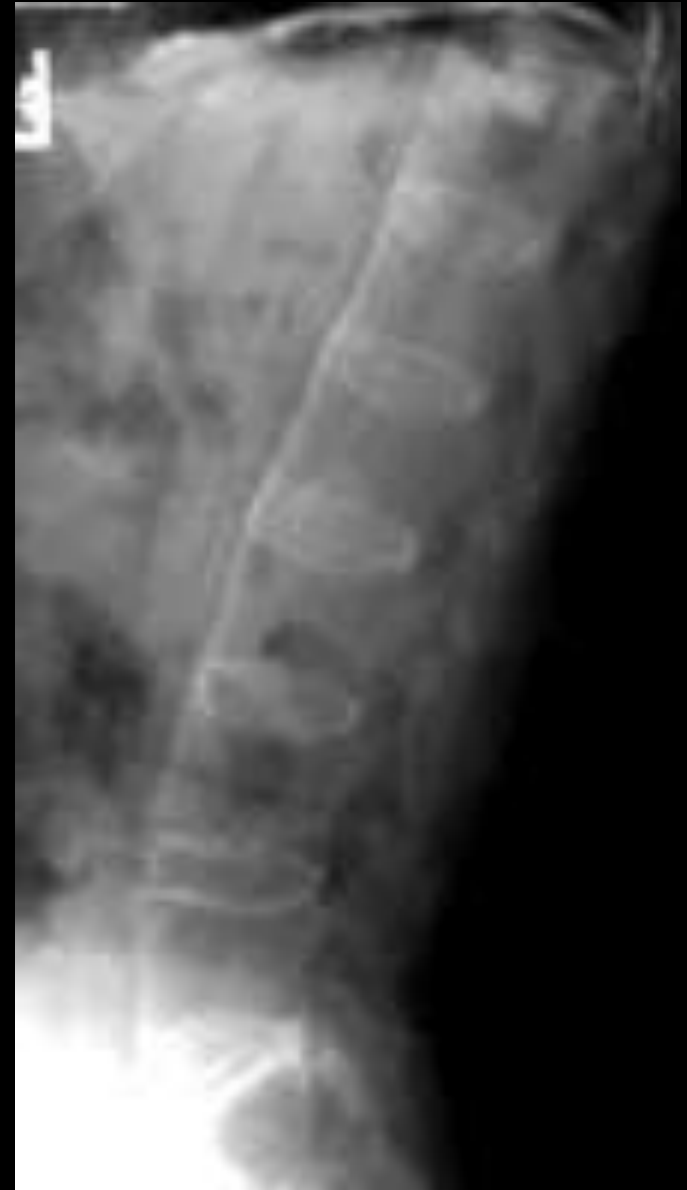Polkadot Sign  
Hemangioma





# Bamboo spine

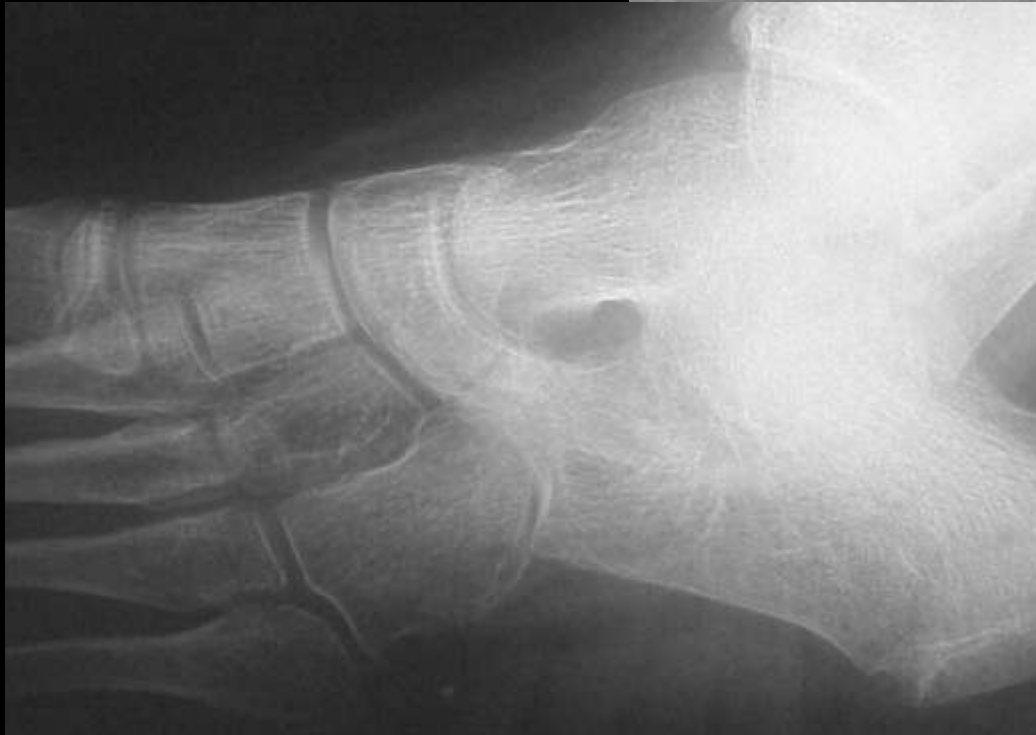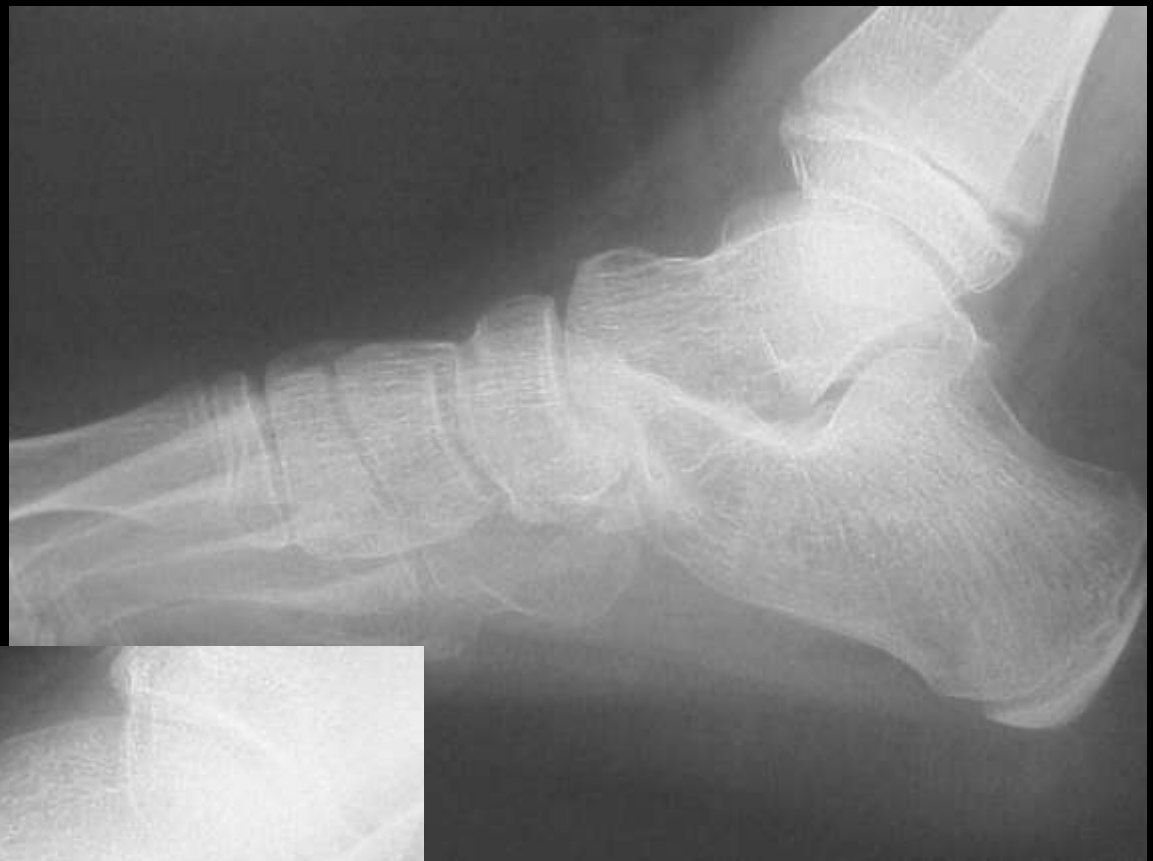## Ankylosing spondylitis





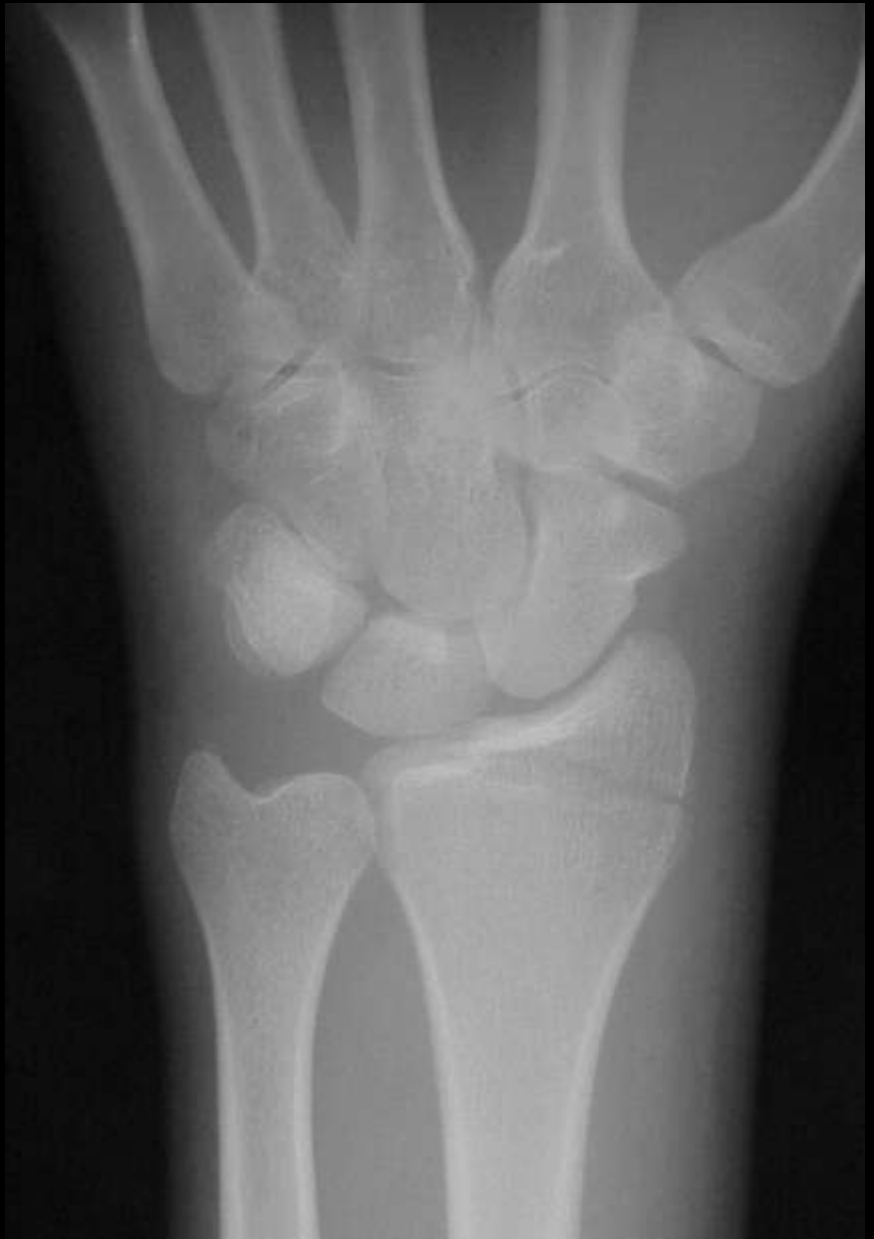

Anteater sign  
Calcaneonavicular  
coalition



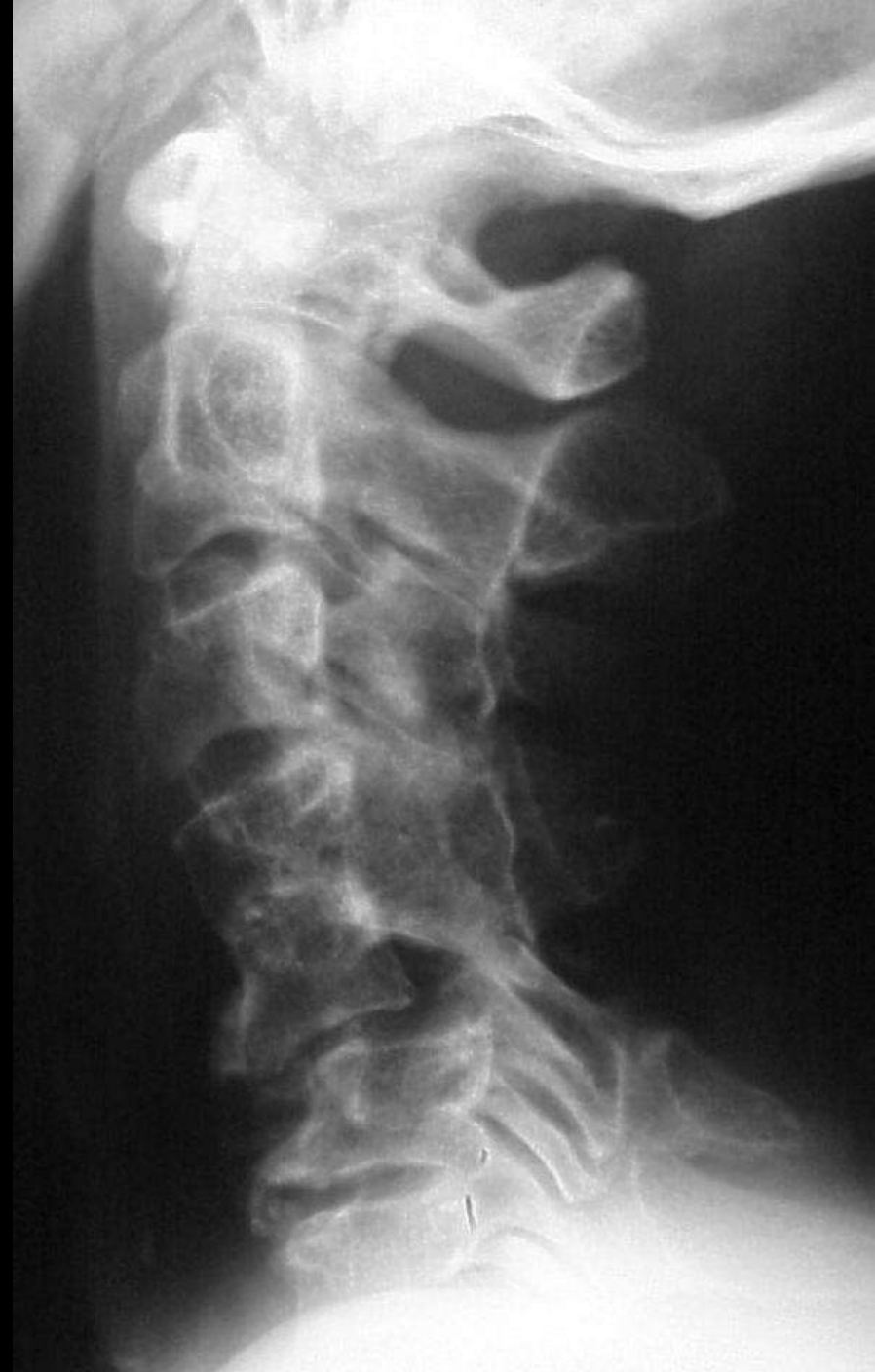

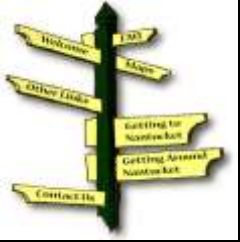# Chauffeur fracture



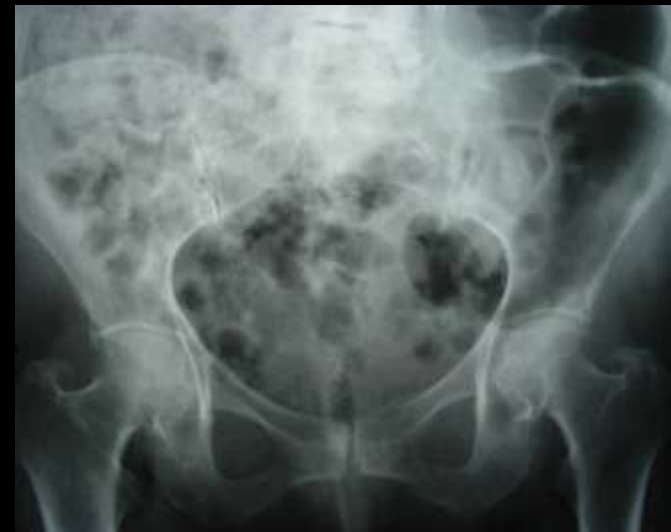
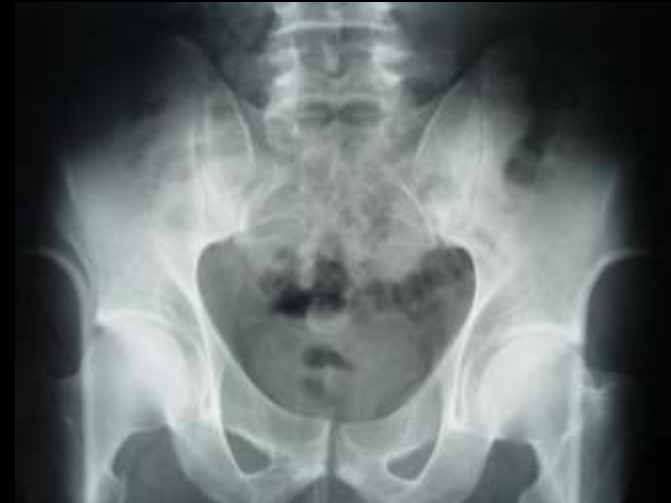
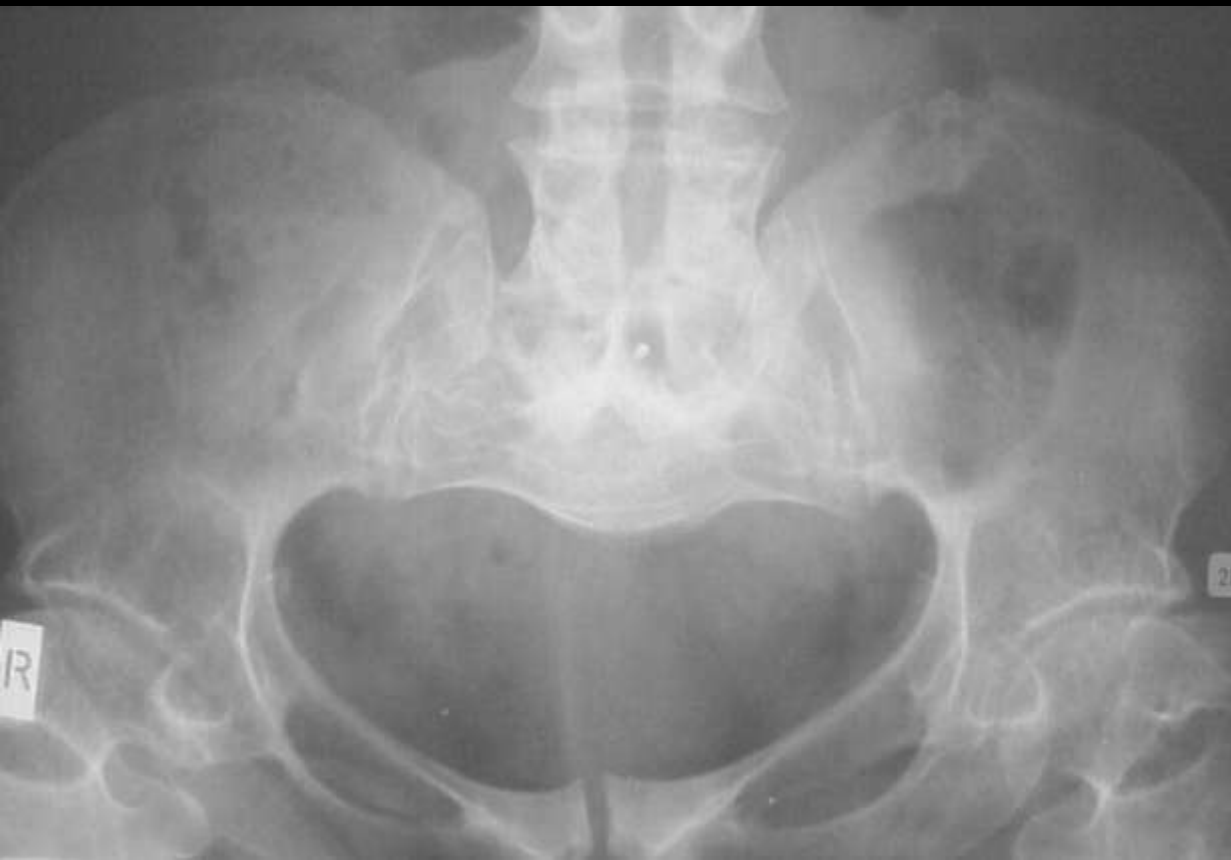# Wasp waist sign Congenital cervical fusion





# Champagne pelvis Achondroplasia

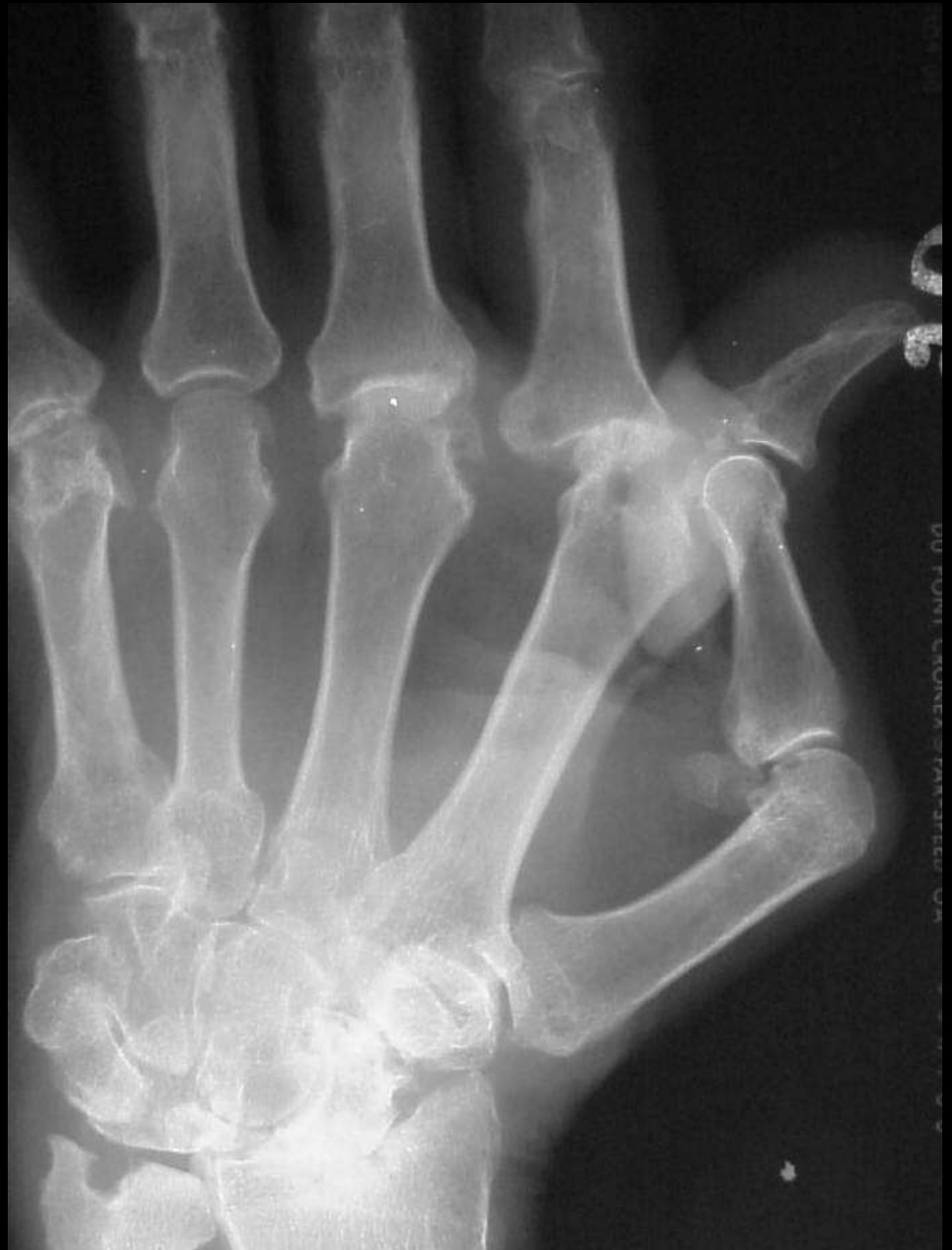





# Hitchhiker thumb

## RhA

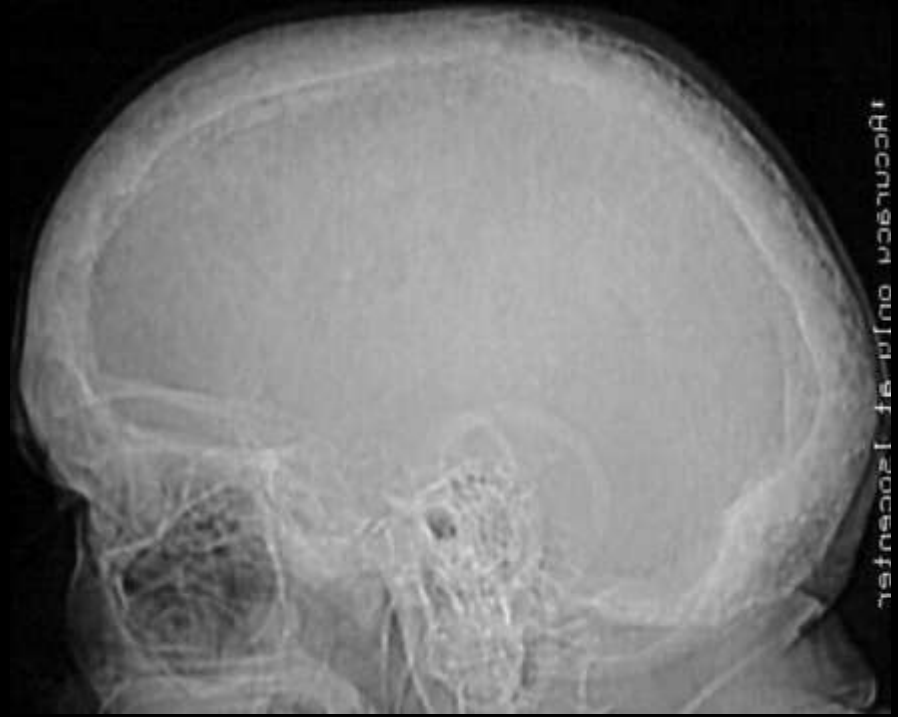



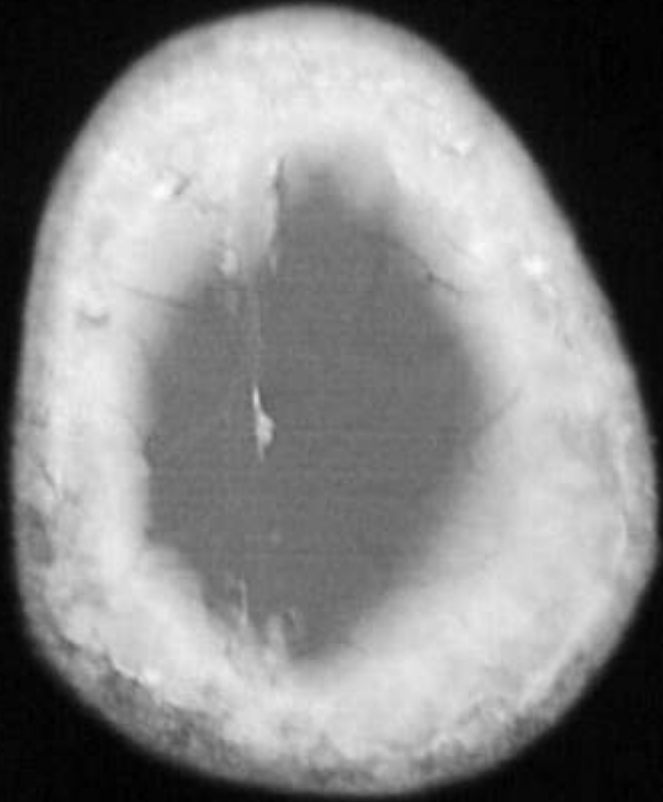


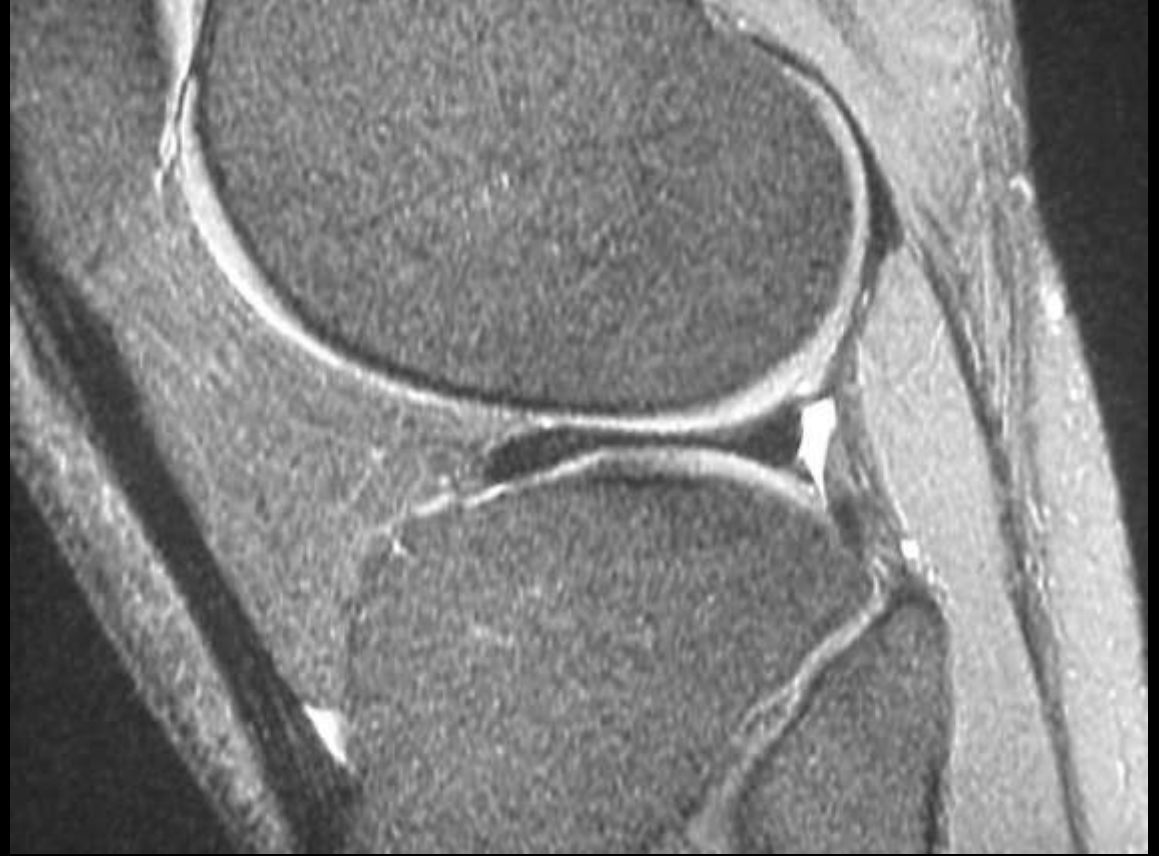Cotton wool sign

Pagets



1Accurruca onlv af 1200cntrfr





Bow tie sign of  
Discoid meniscus

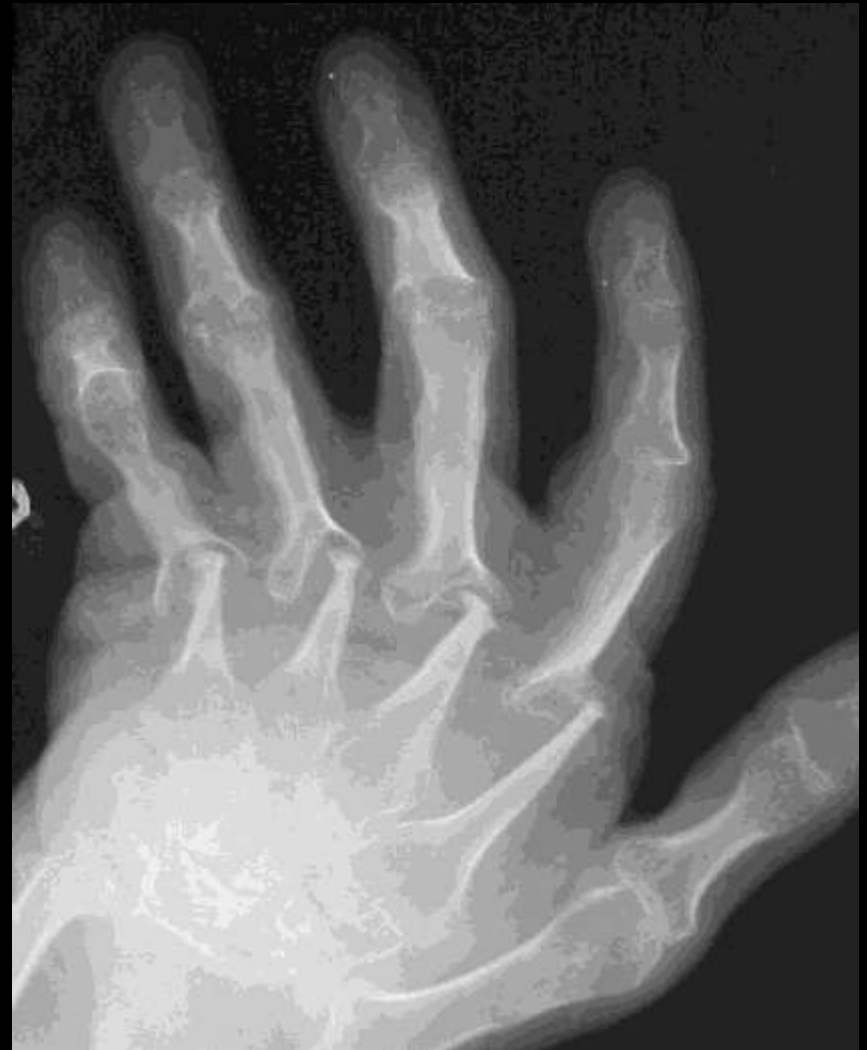

# Pencil in cup deformity

Psoriasis

Gout

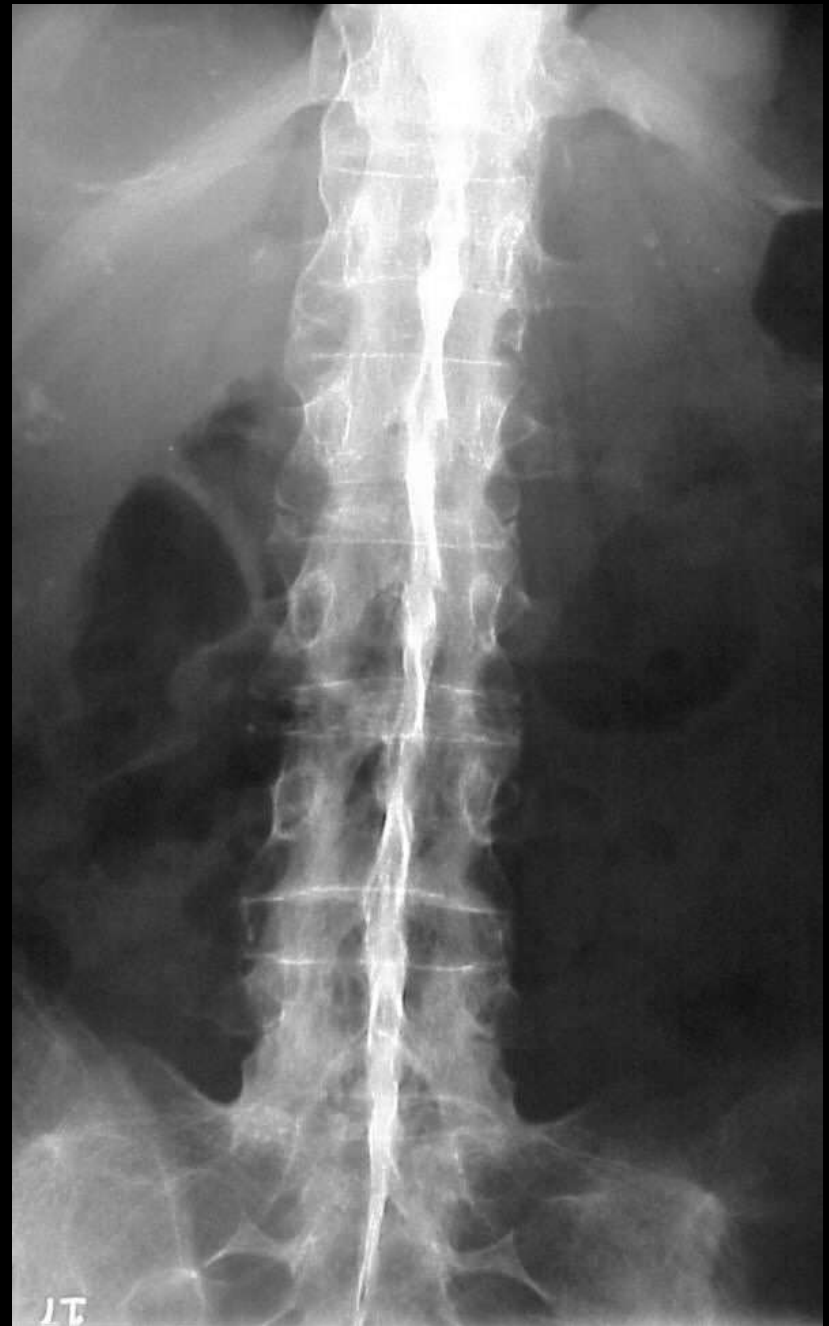RhA



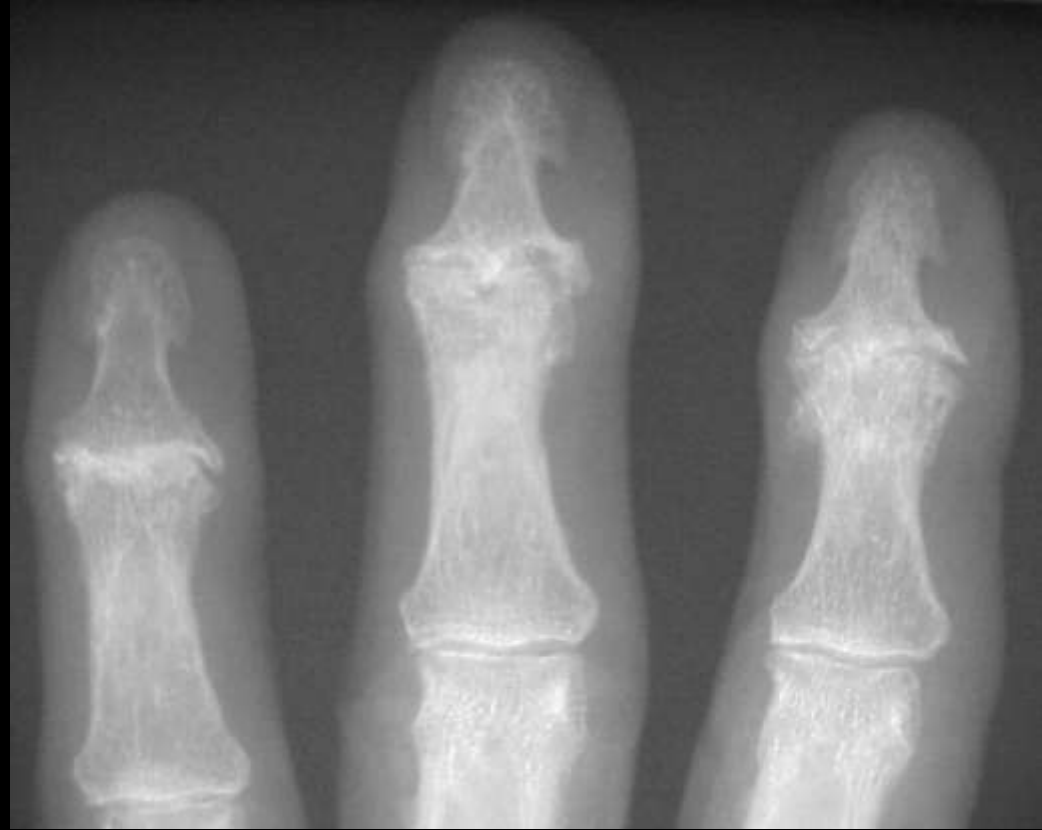

Dagger sign

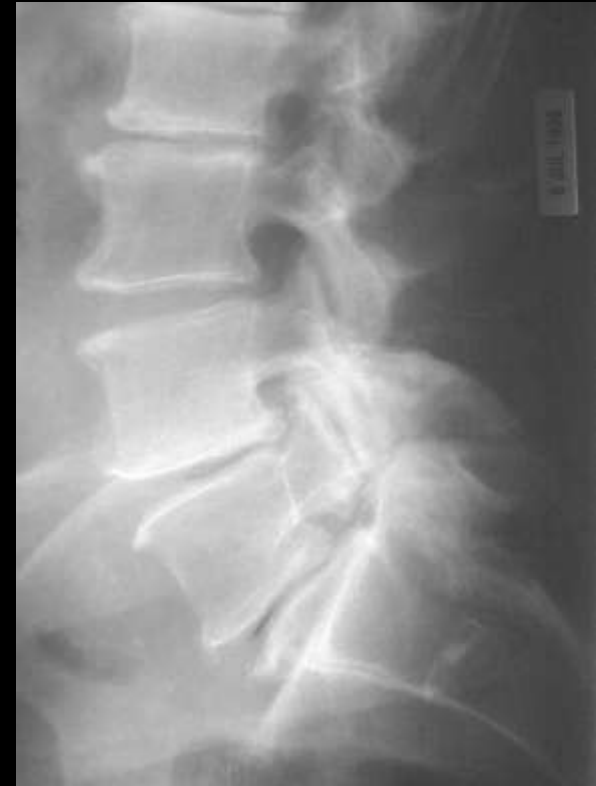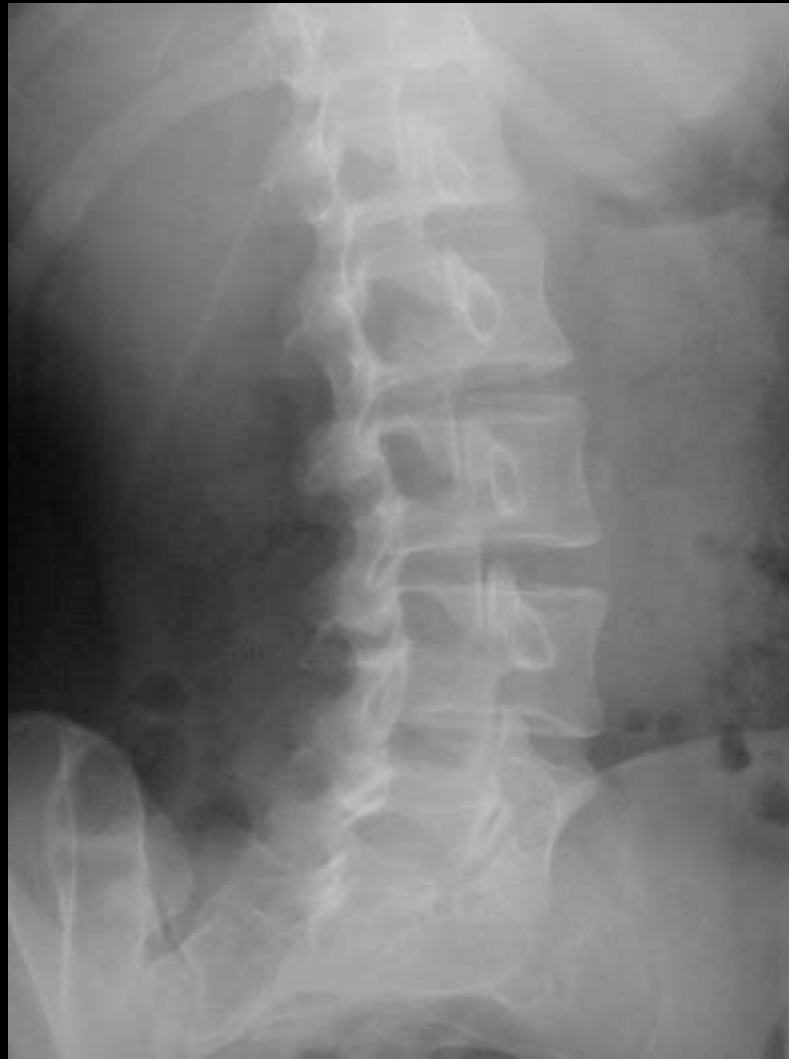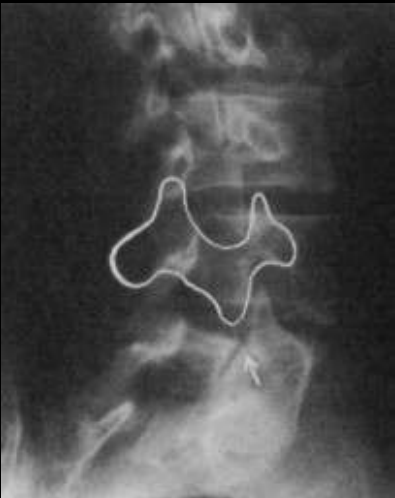Ankylosing spondylitis







Seagull deformity of  
inflammatory/erosive OA

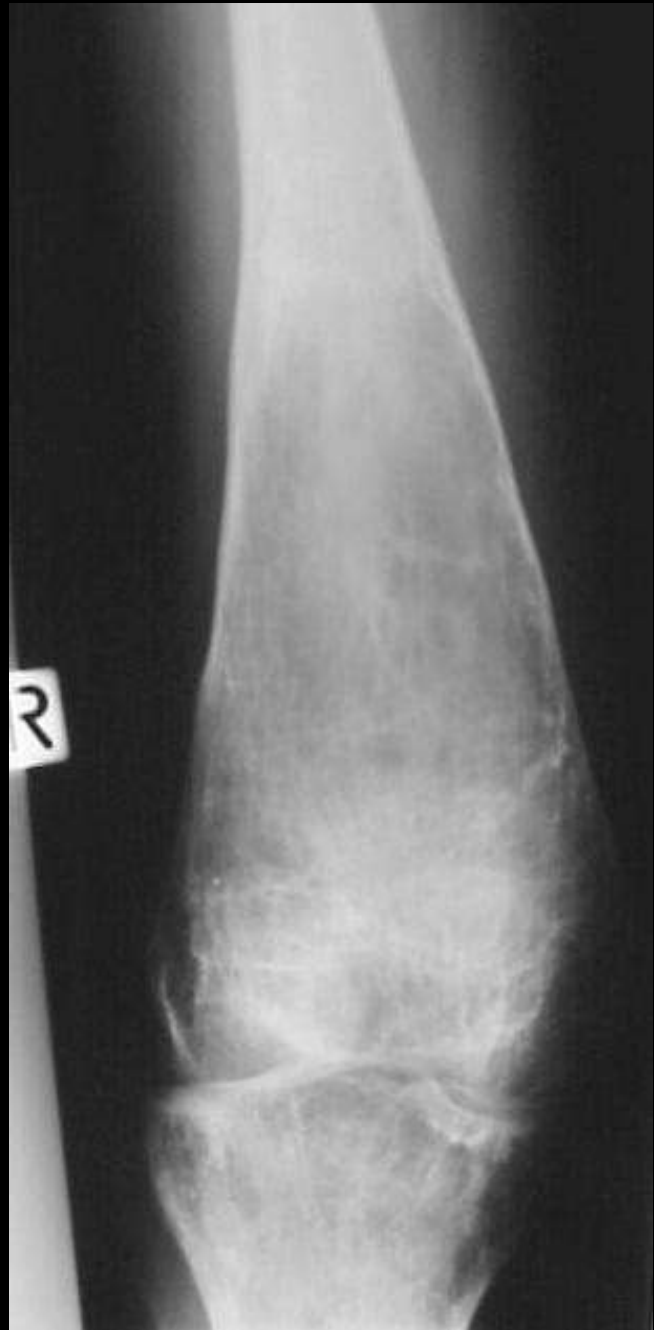
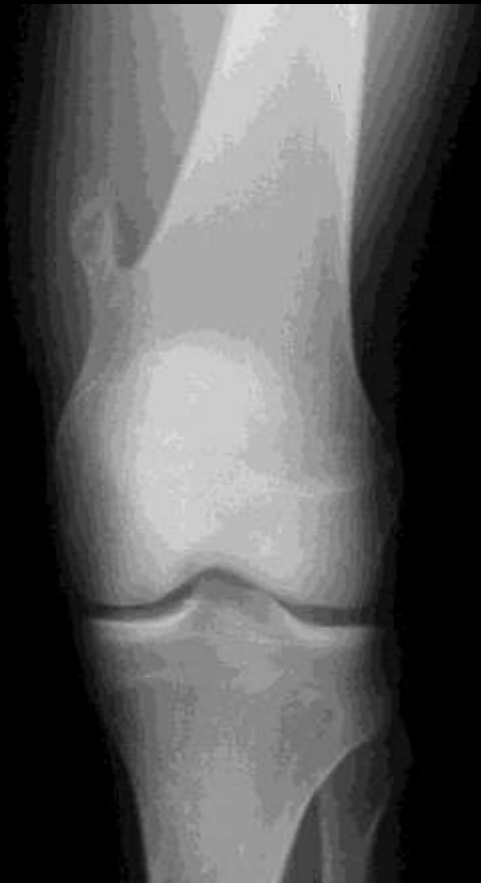
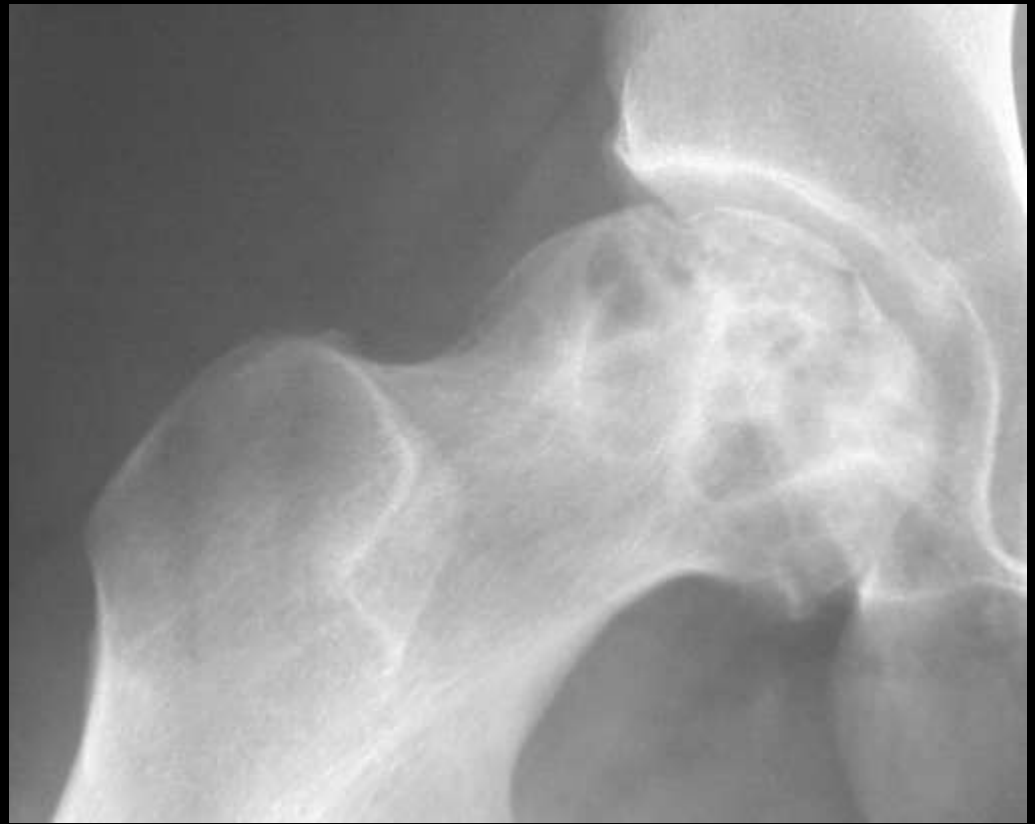Scotty dog  
Pars defects



# Erlenmyer flask

Gaucher's  
Osteopetrosis  
Thalasaemia

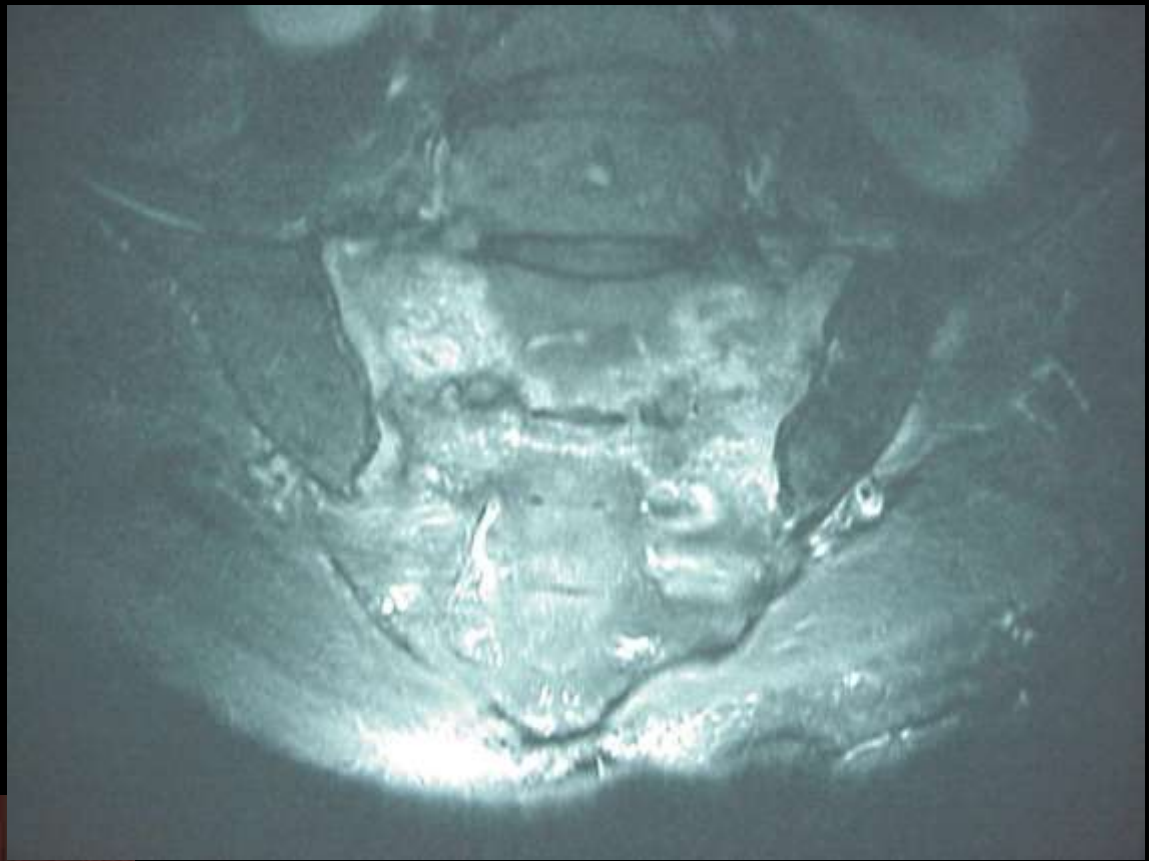



Grade III AVN hip  
Crescent sign

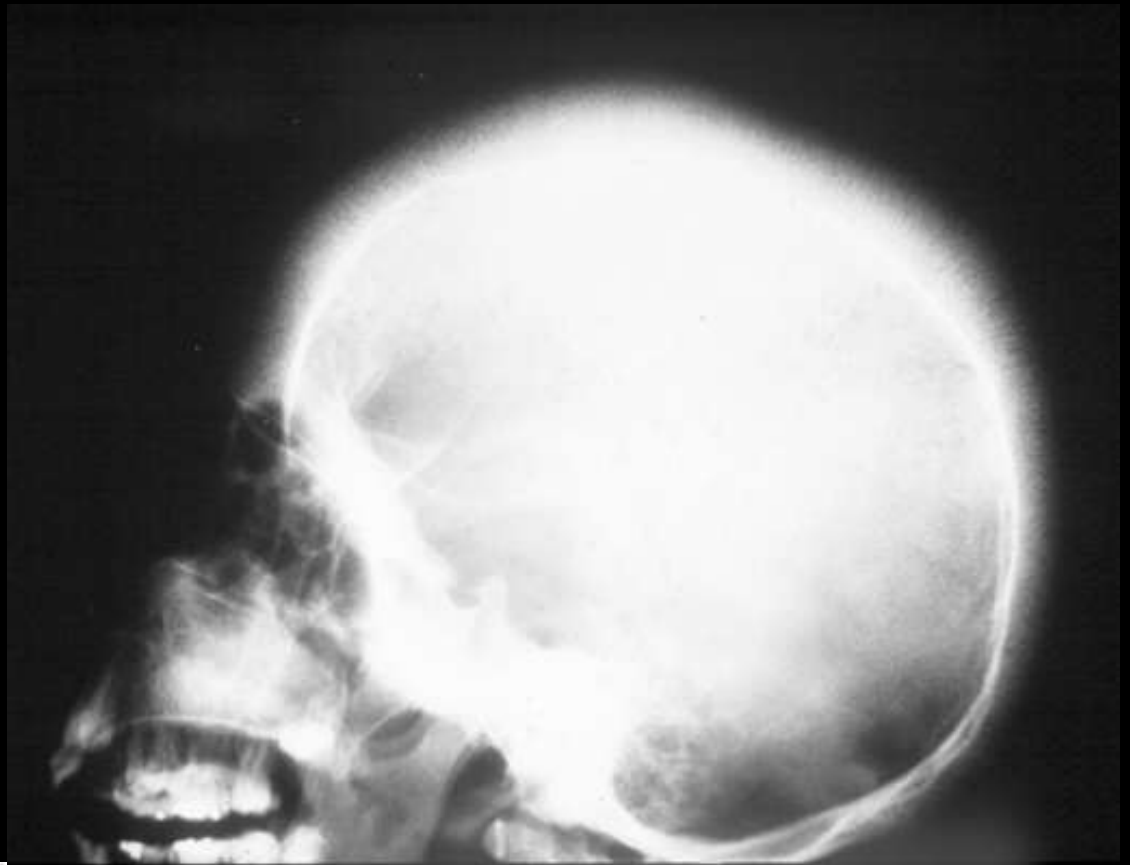




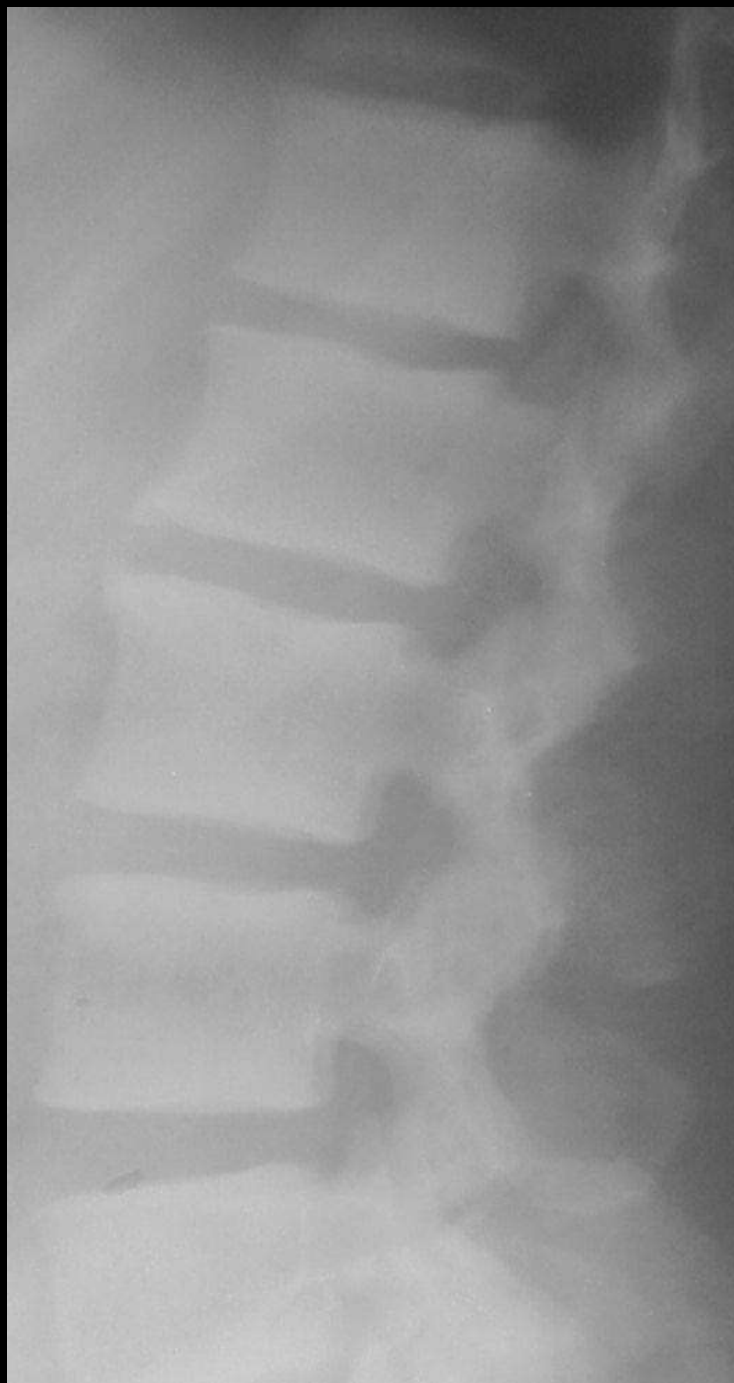

Honda sign

Sacral insufficiency fracture

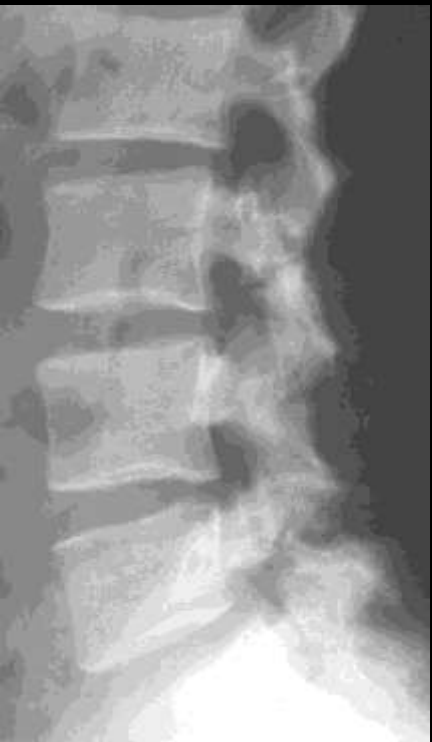

Hair on end  
Thalassemia



Rugger jersey spine

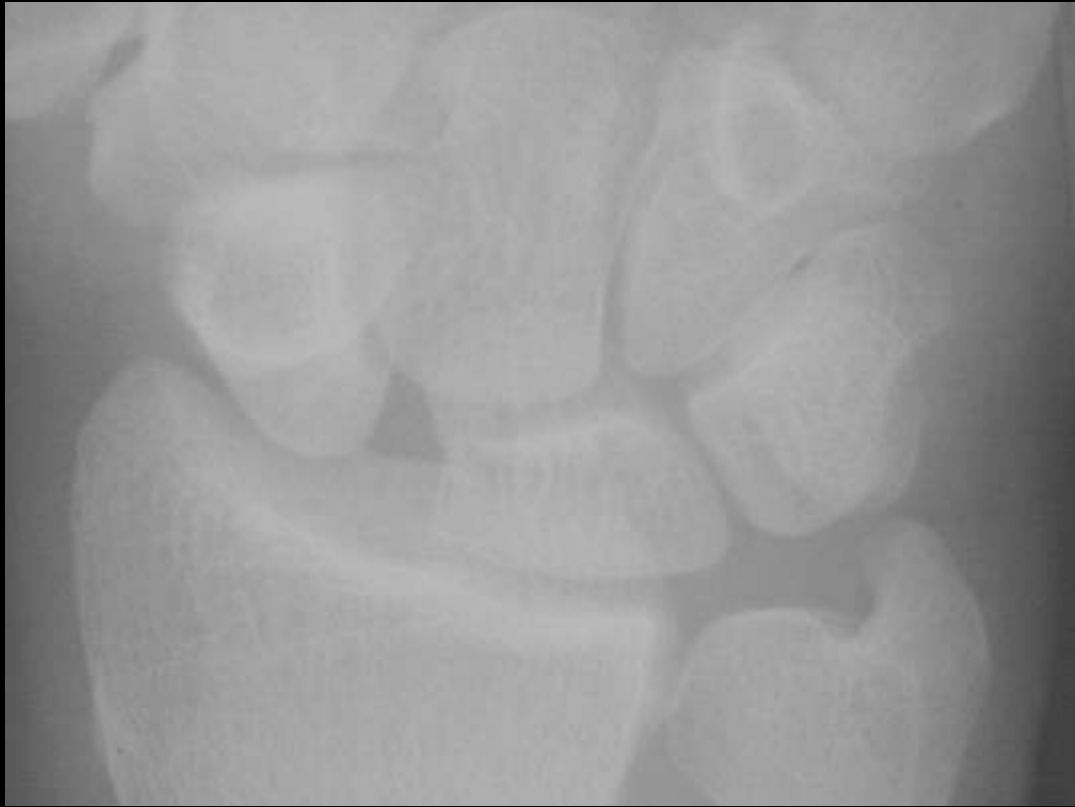

Renal  
Osteodystrophy





Terry Thomas sign

Scapholunate ligament  
disruption

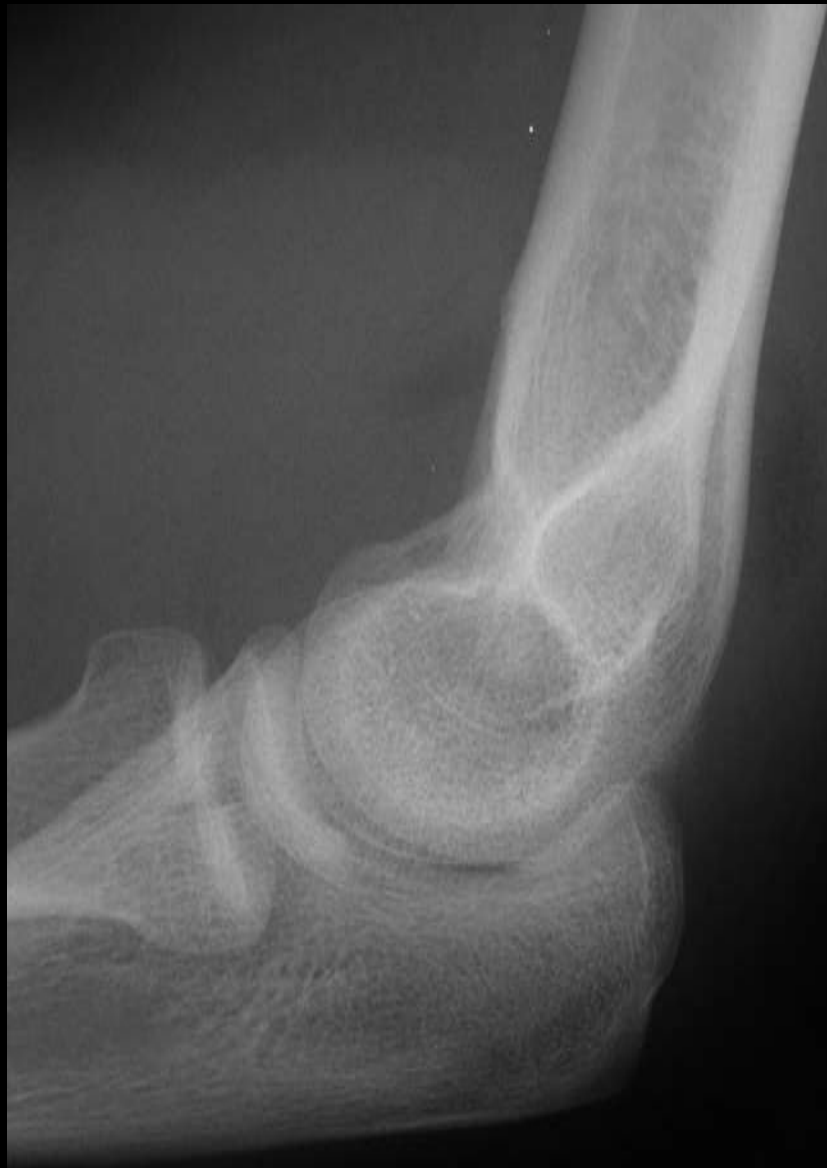





Sail sign

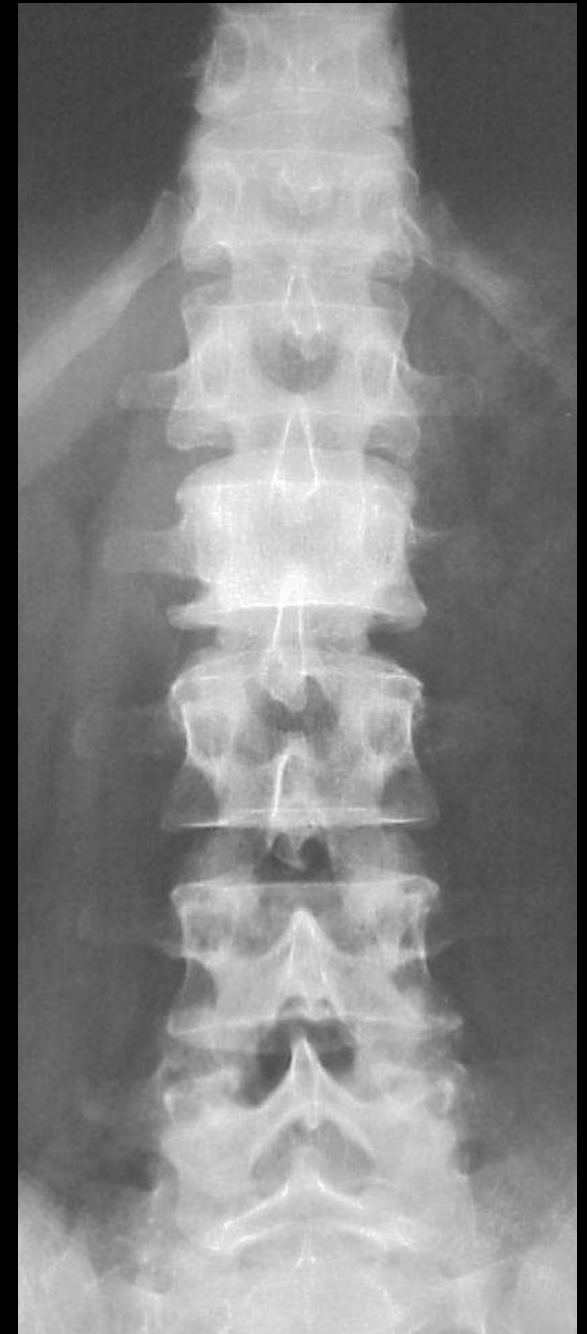Elbow effusion





Ivory vertebrae

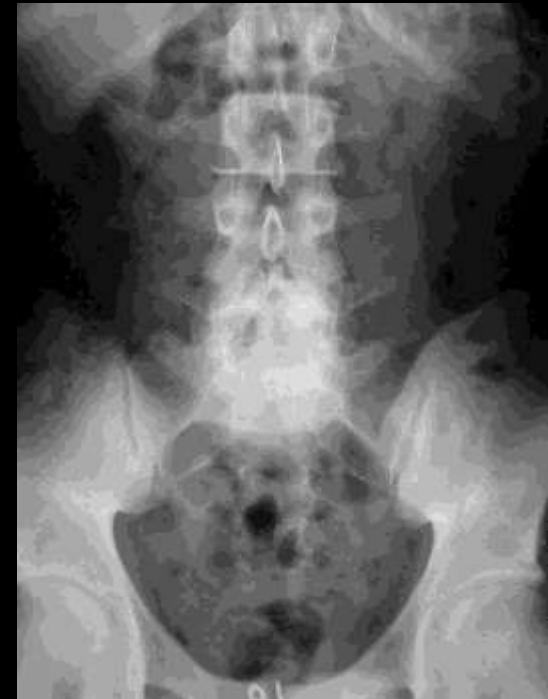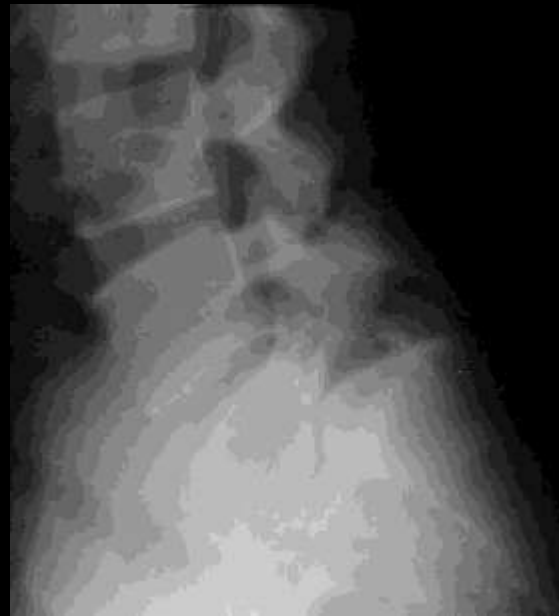Hodgkin's  
Mets  
Osteosarcoma





# Inverted Napoleon hat sign

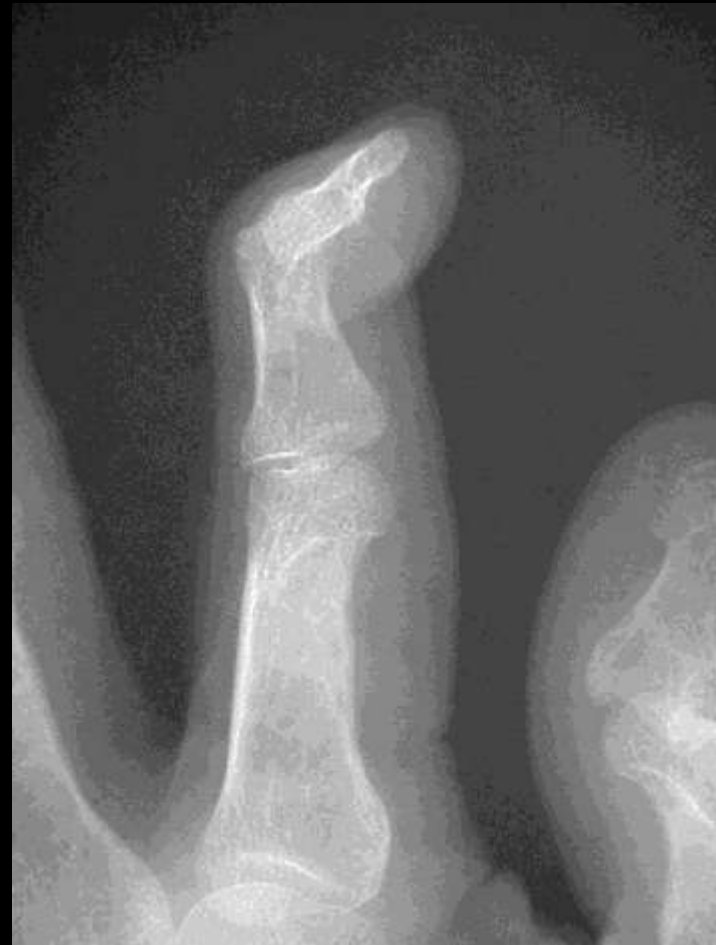## Spondylolisthesis





# Swan neck deformity

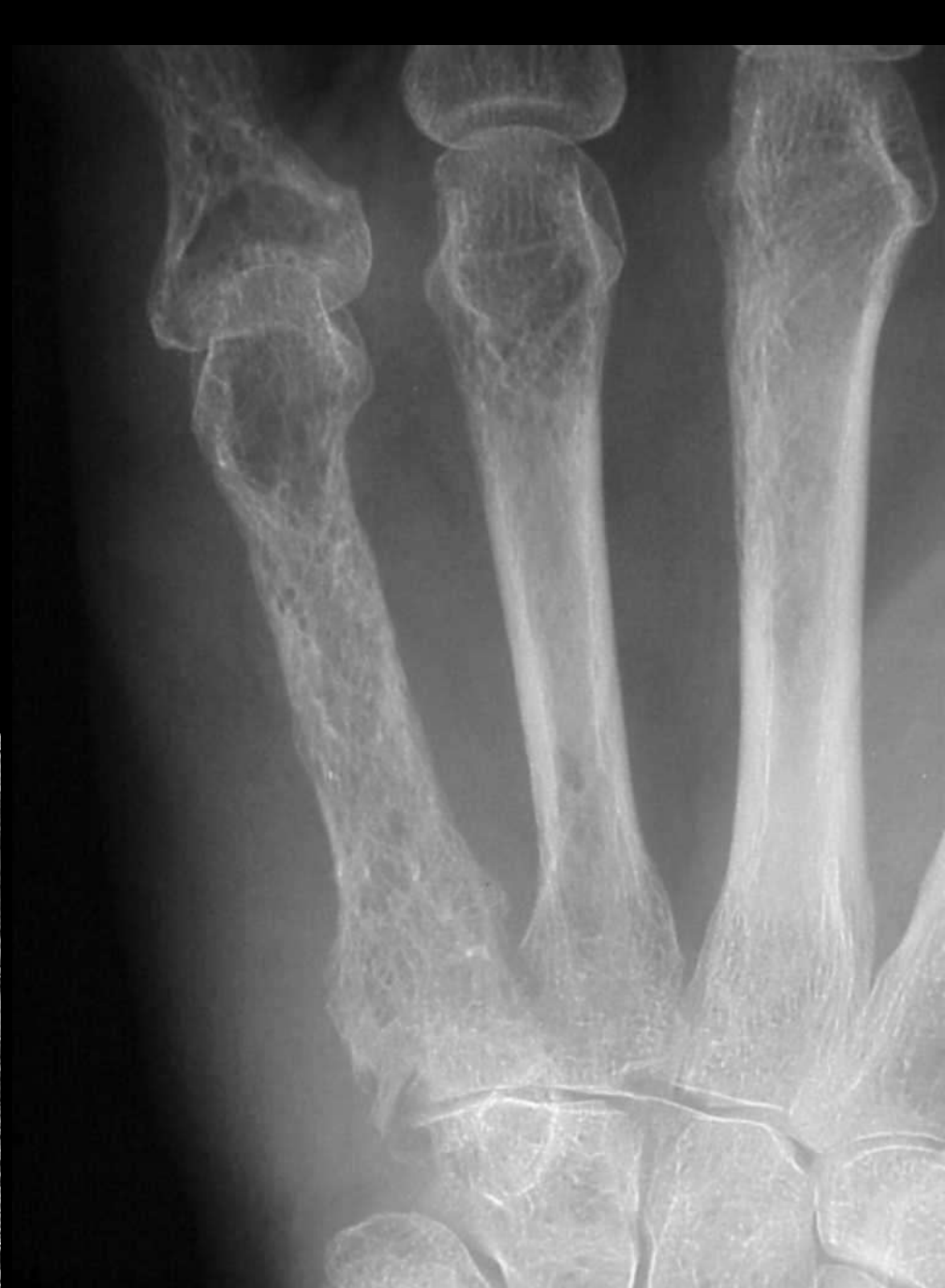## Rheumatoid arthritis





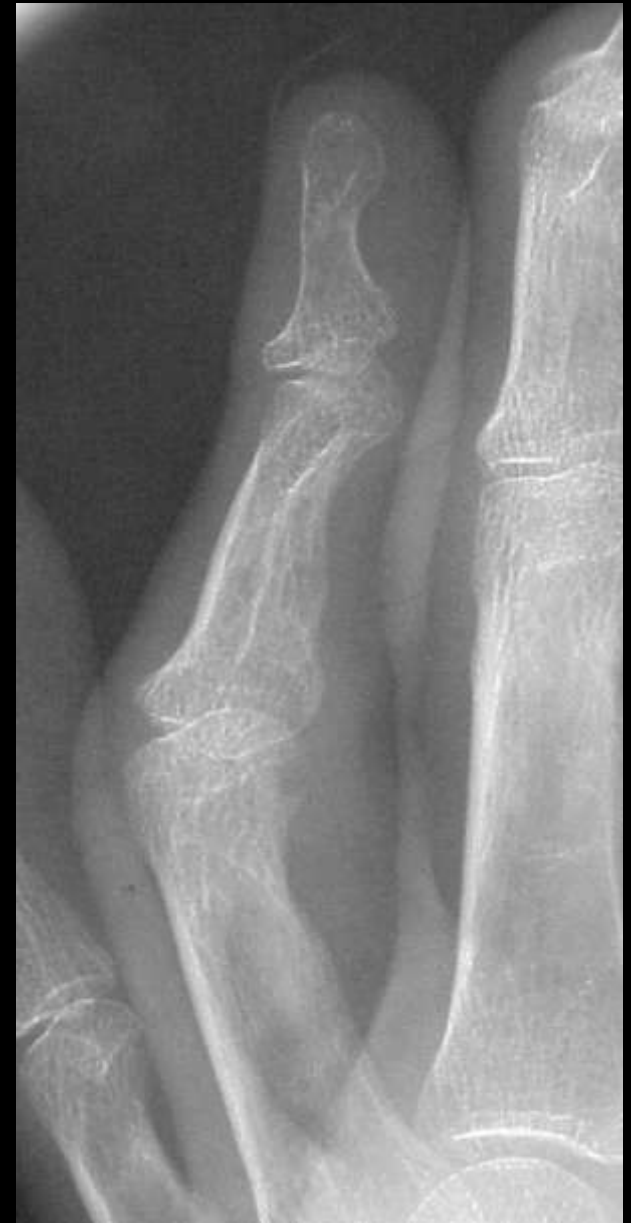

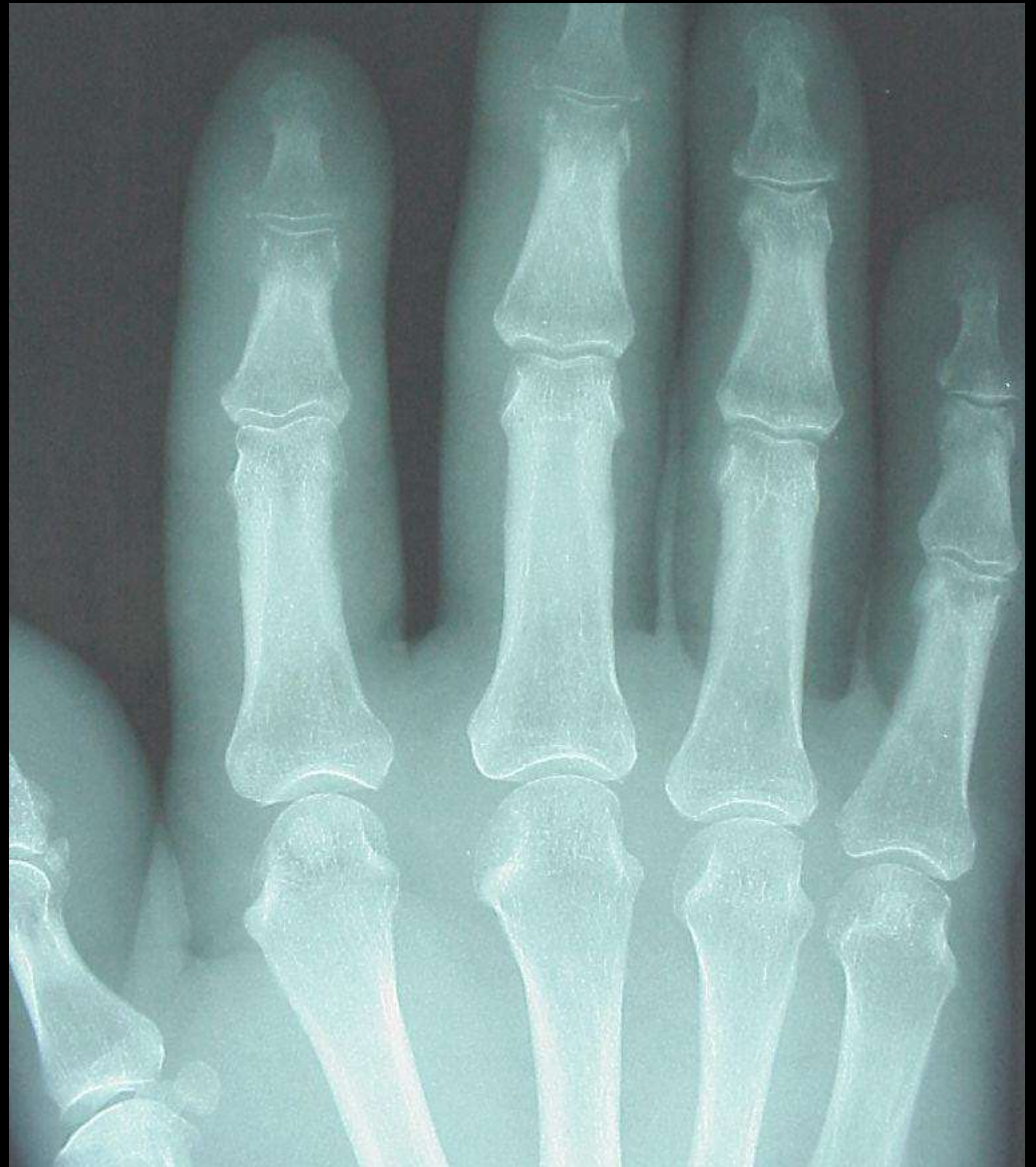Lace like  
Sarcoidosis





# Boutonniere deformity

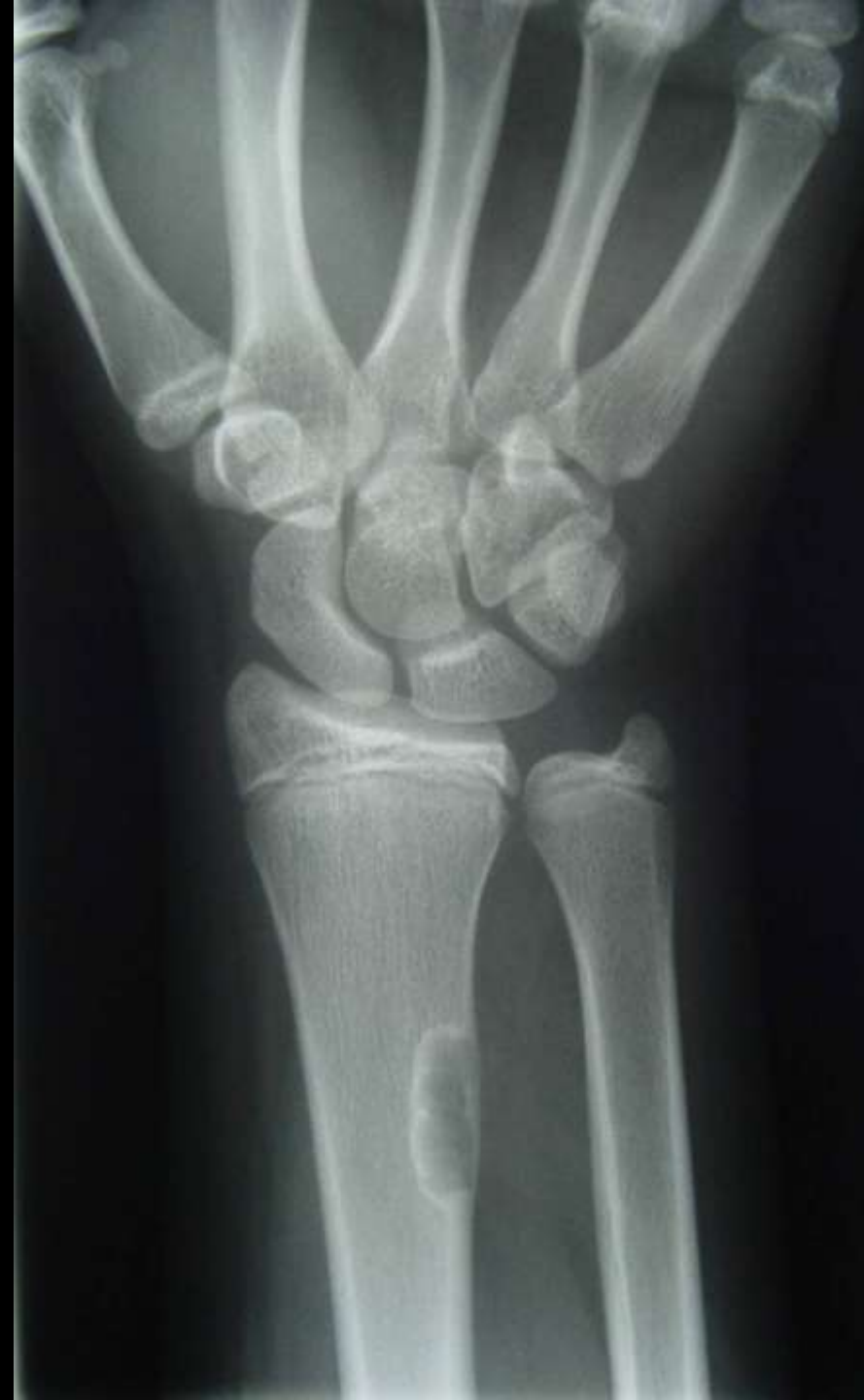
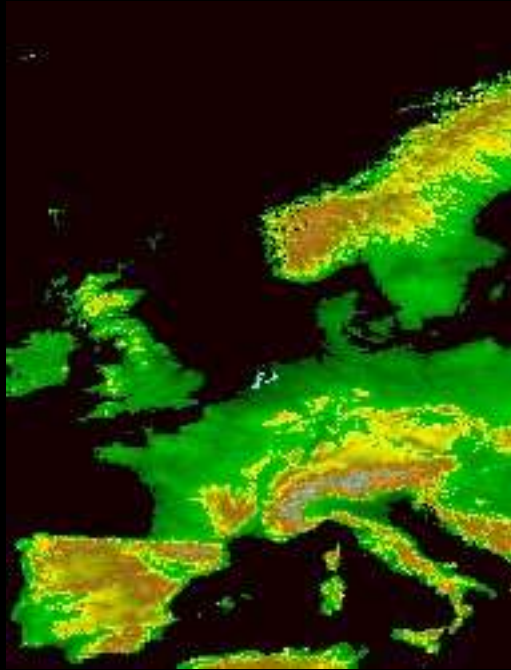


Sausage digit  
Psoriasis



# Geographic Benign

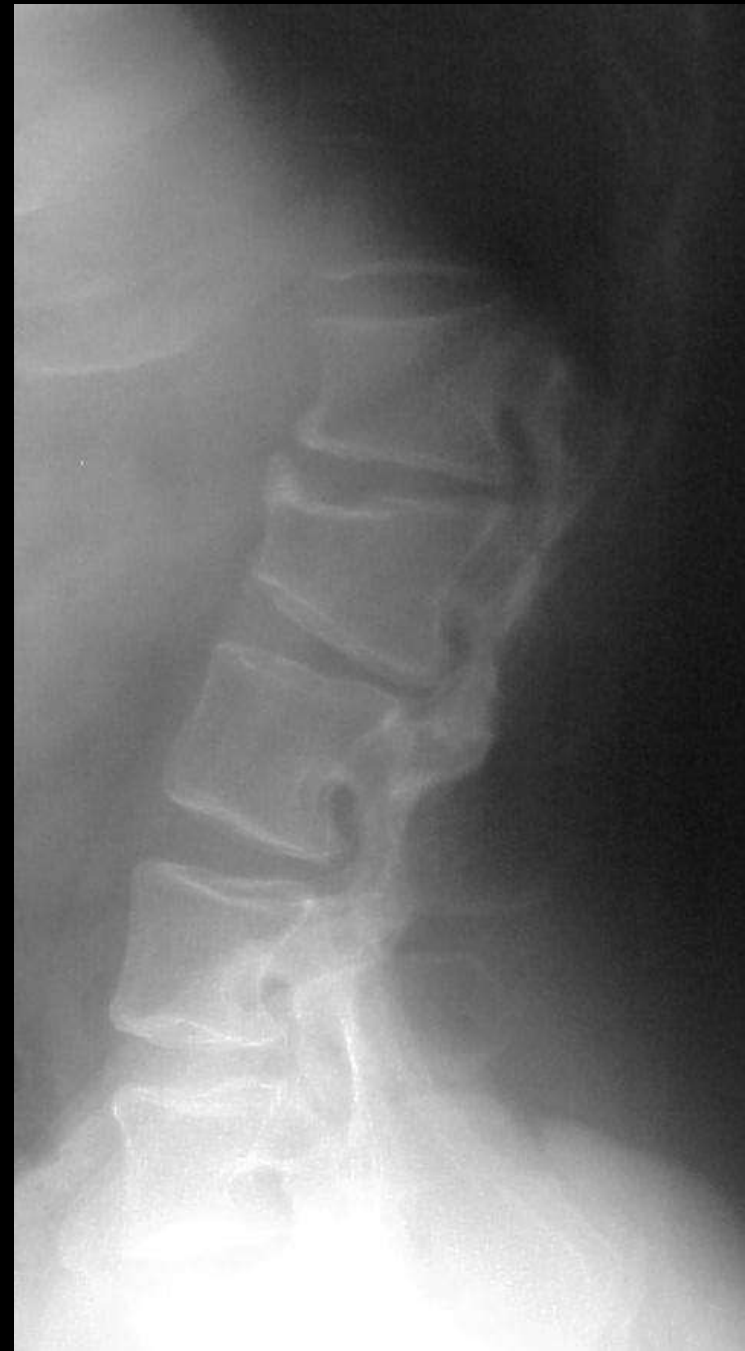





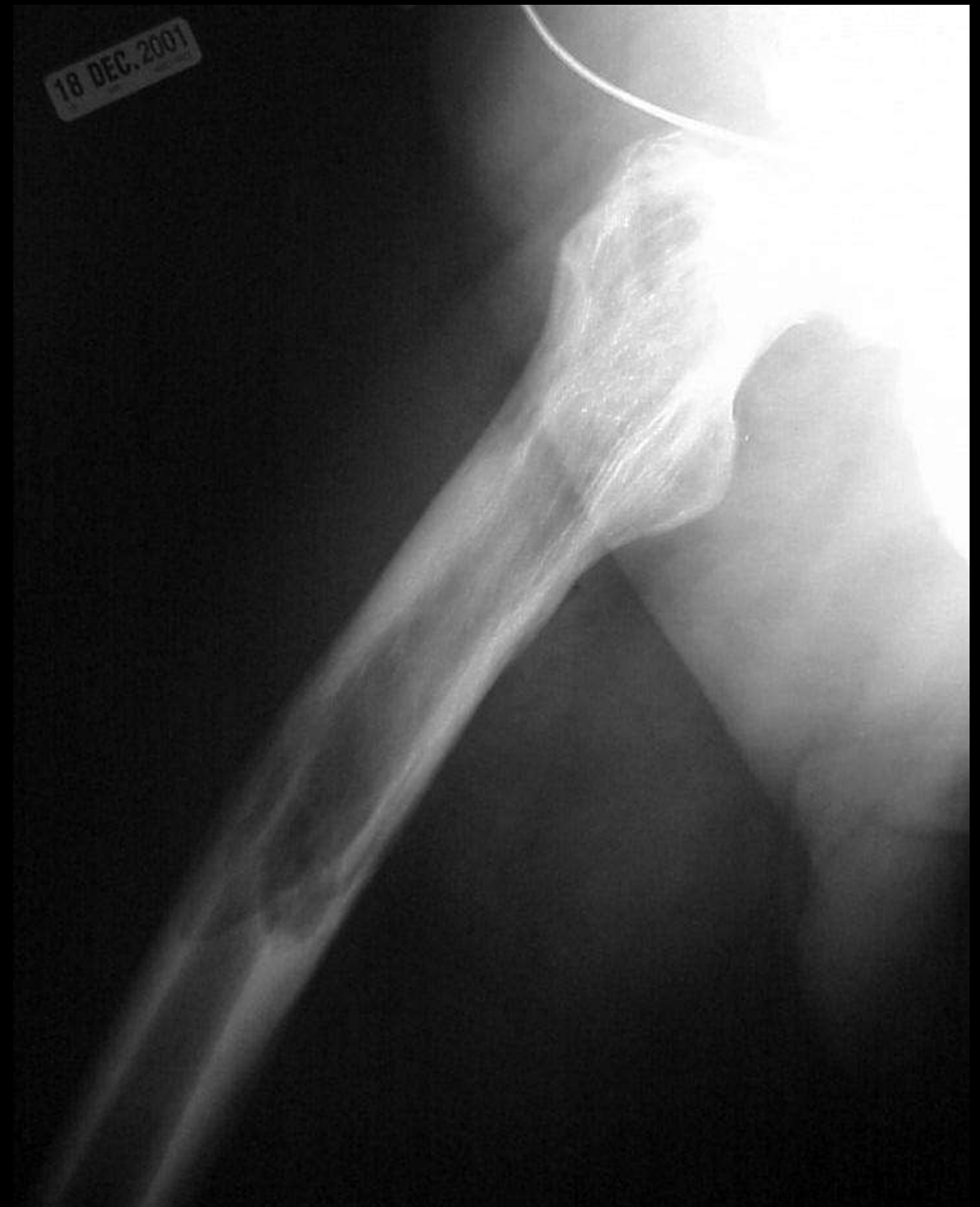# Vertebral Scallop

Achondroplasia  
Neurofibromatosis





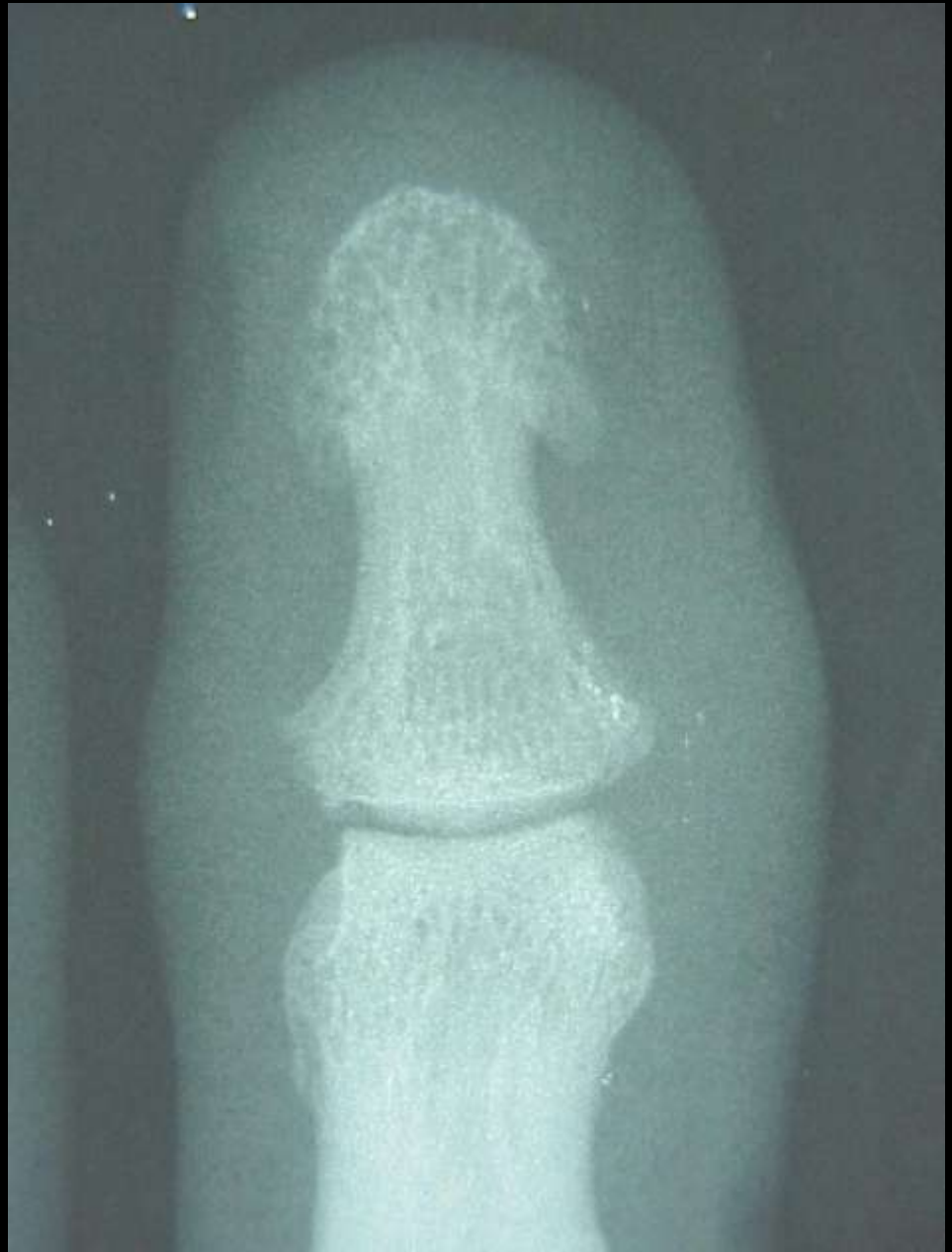
# Blade of grass Pagets





# Whiskering

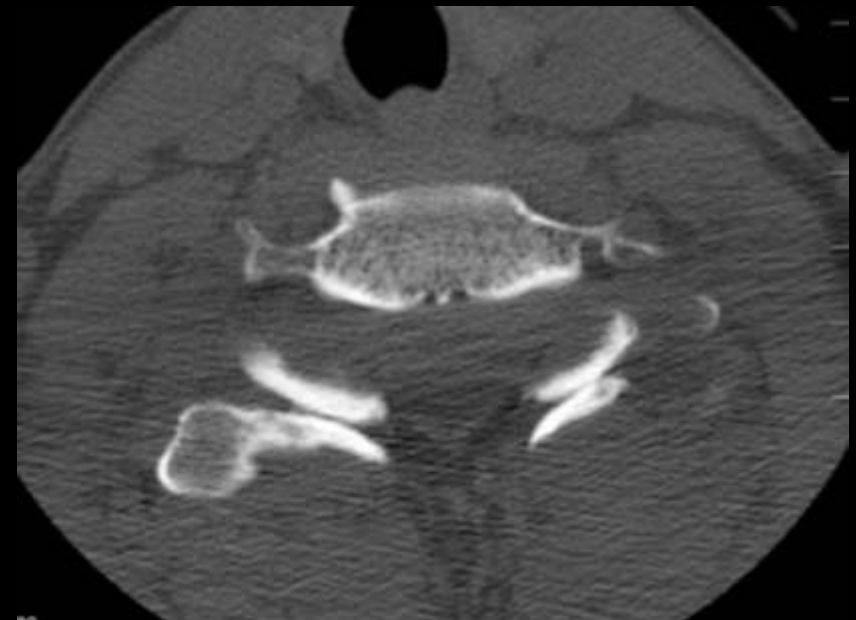
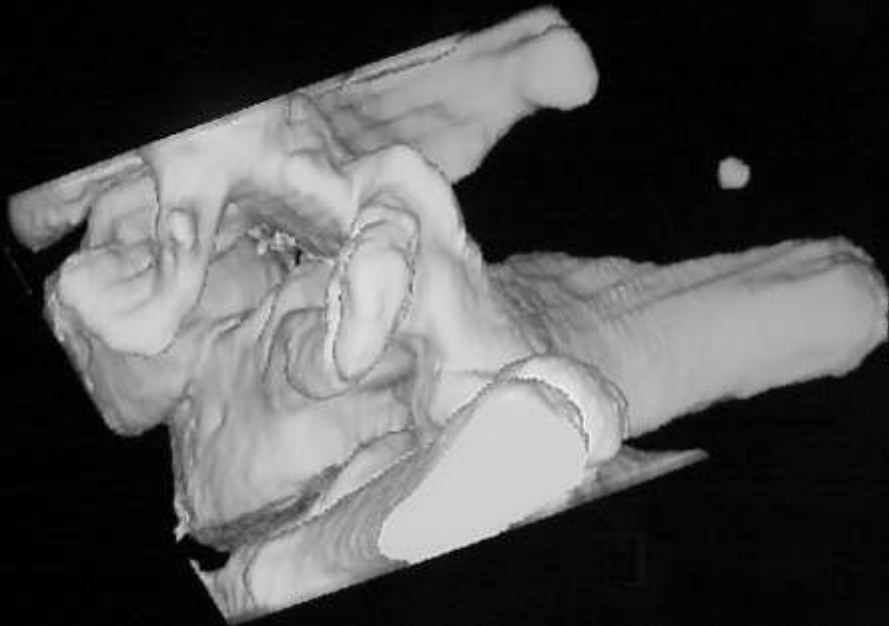
Psoriasis  
Reiter's



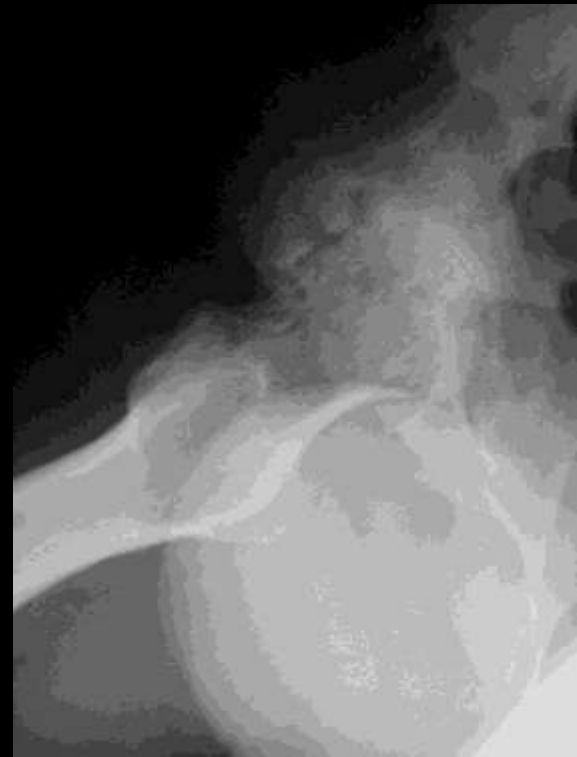
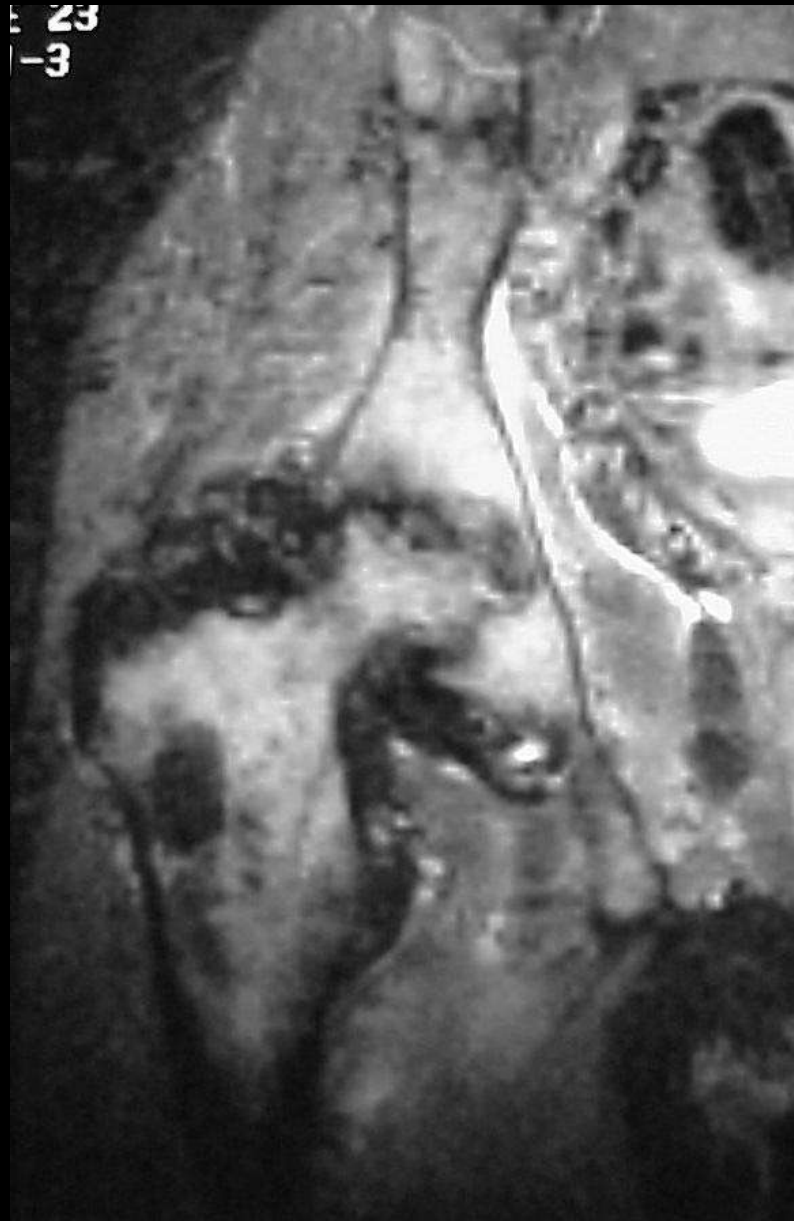


Burger sign  
Normal facet alignment  
Lost with facet dislocation





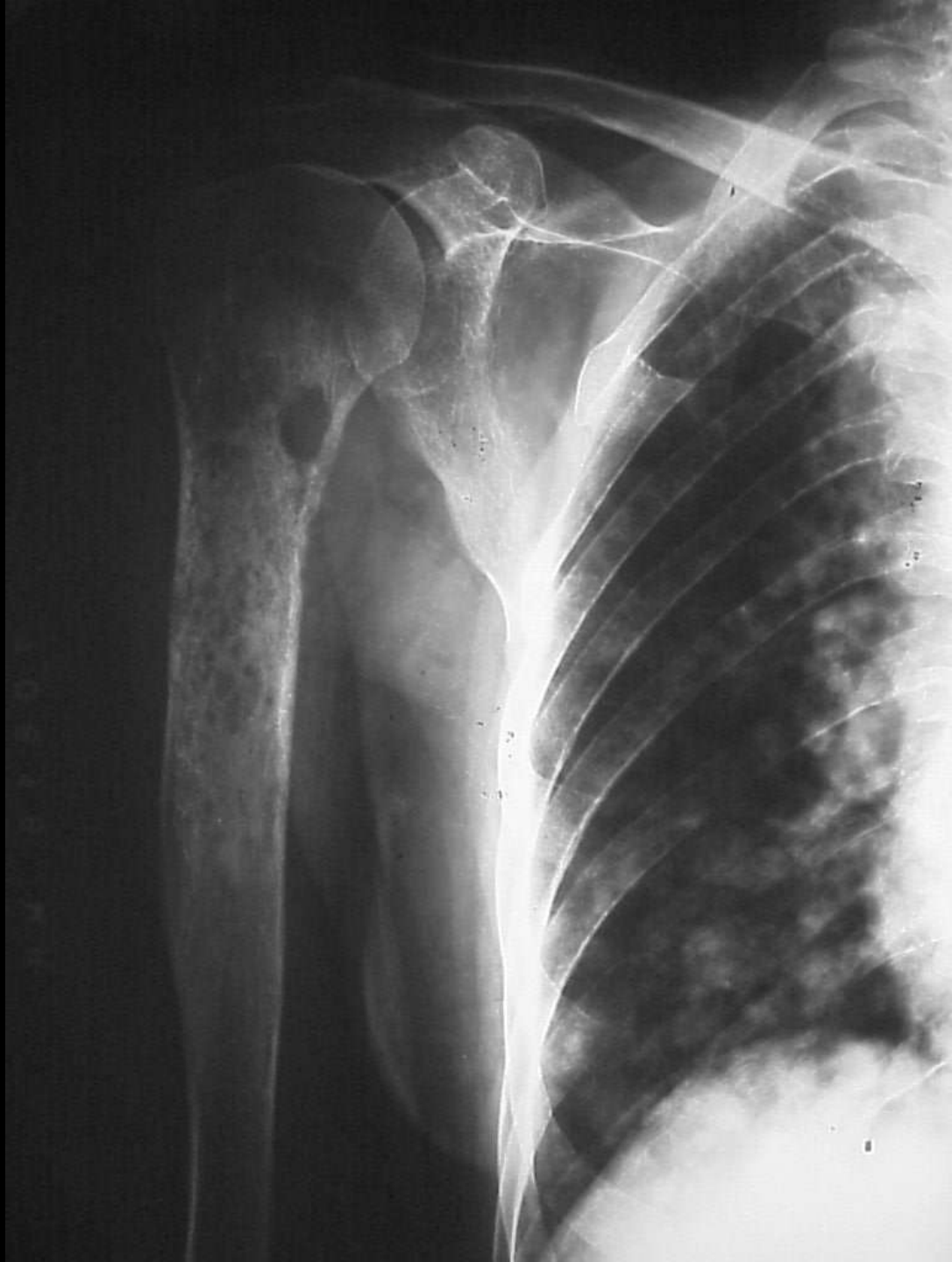

Apple core sign

PVNS



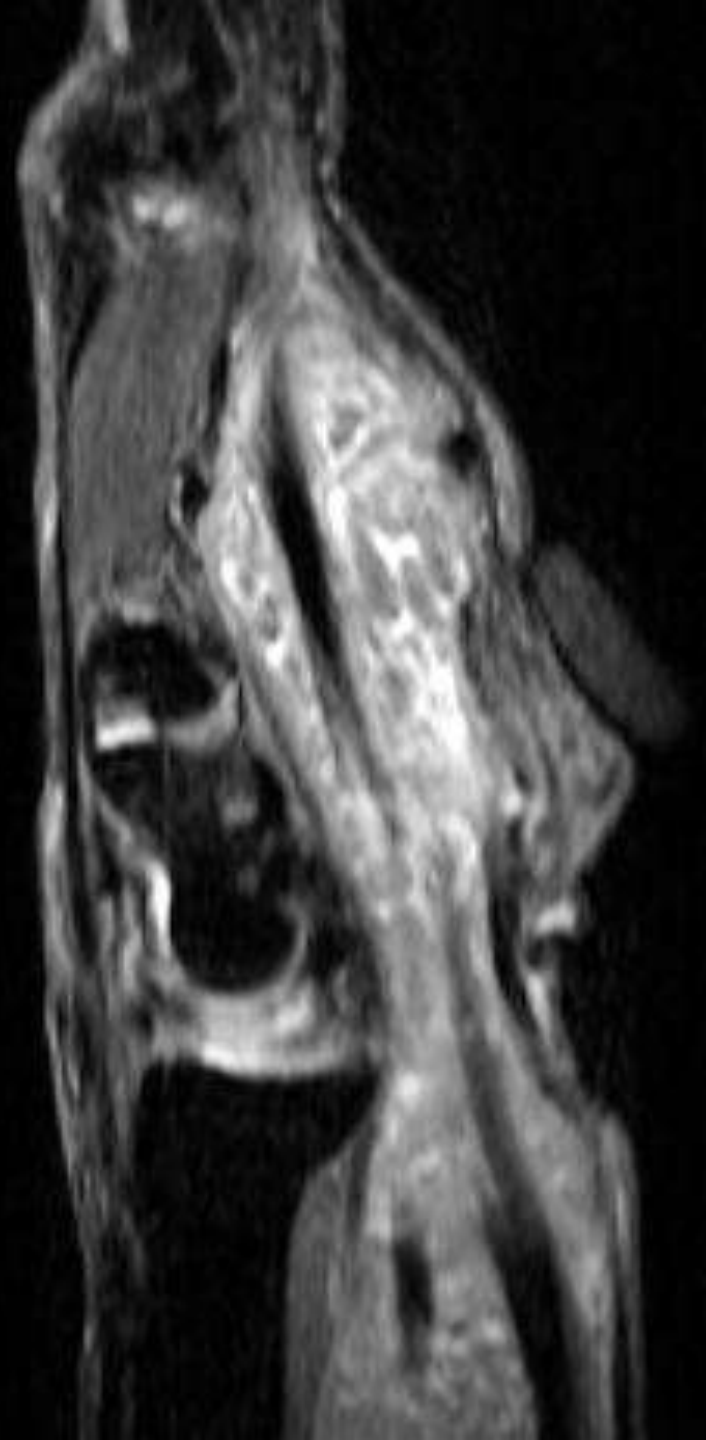
Moth eaten  
Intermediate aggressive  
Mets





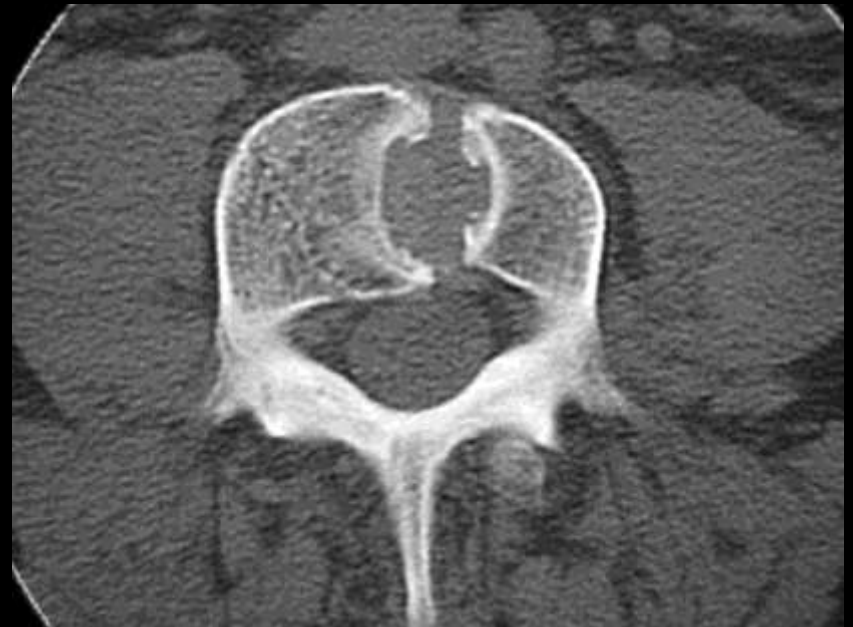# Rice bodies

TB  
RhA





# Butterfly vertebrae Congenital segmentation anomaly

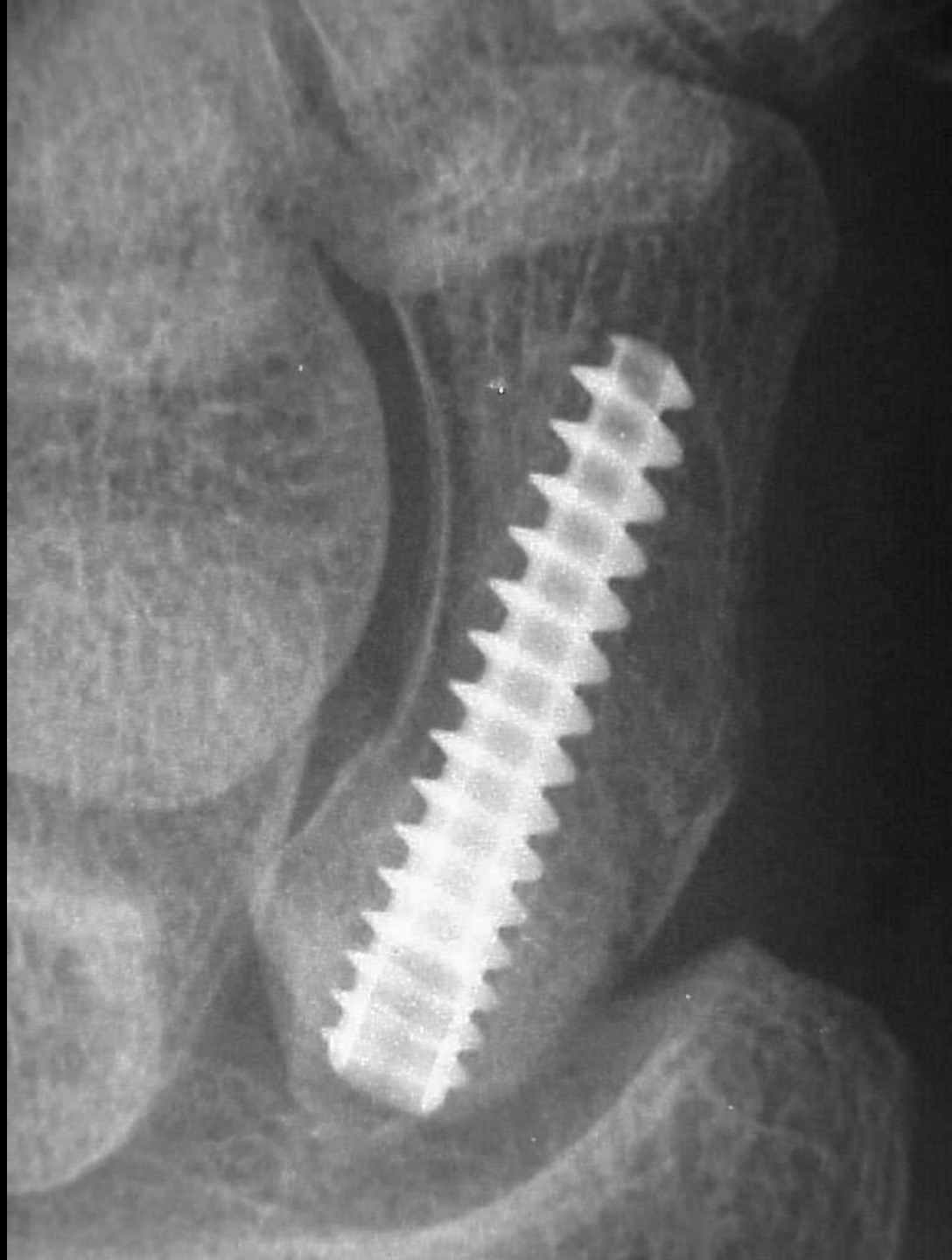


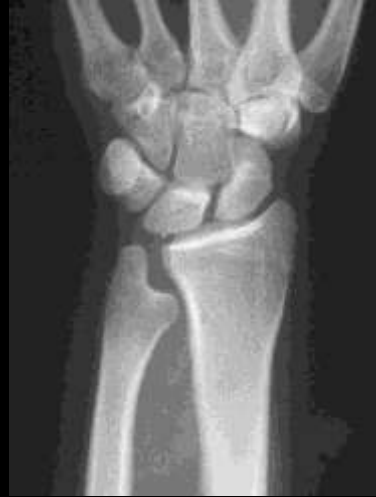



Happy Hawkin's sign

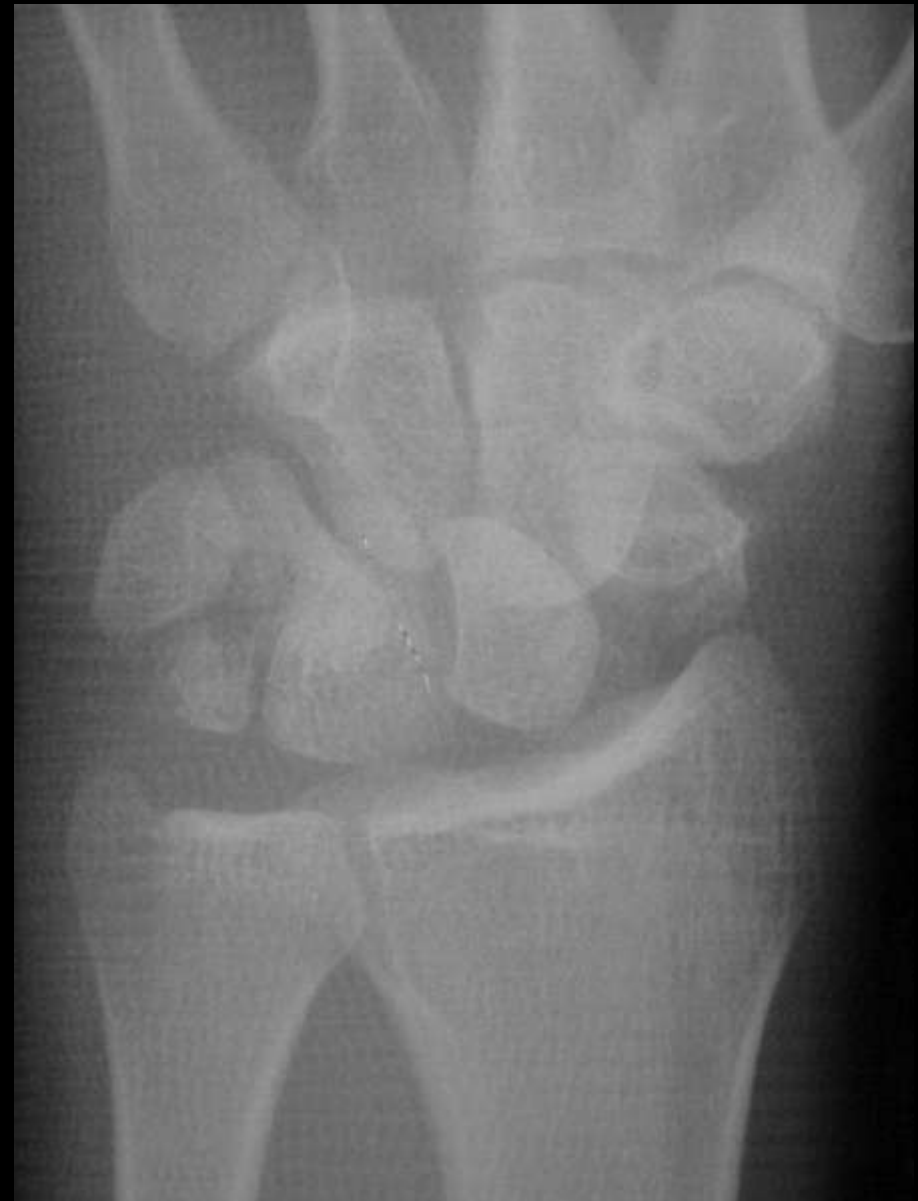Lunate subluxation





Pie shaped lunate

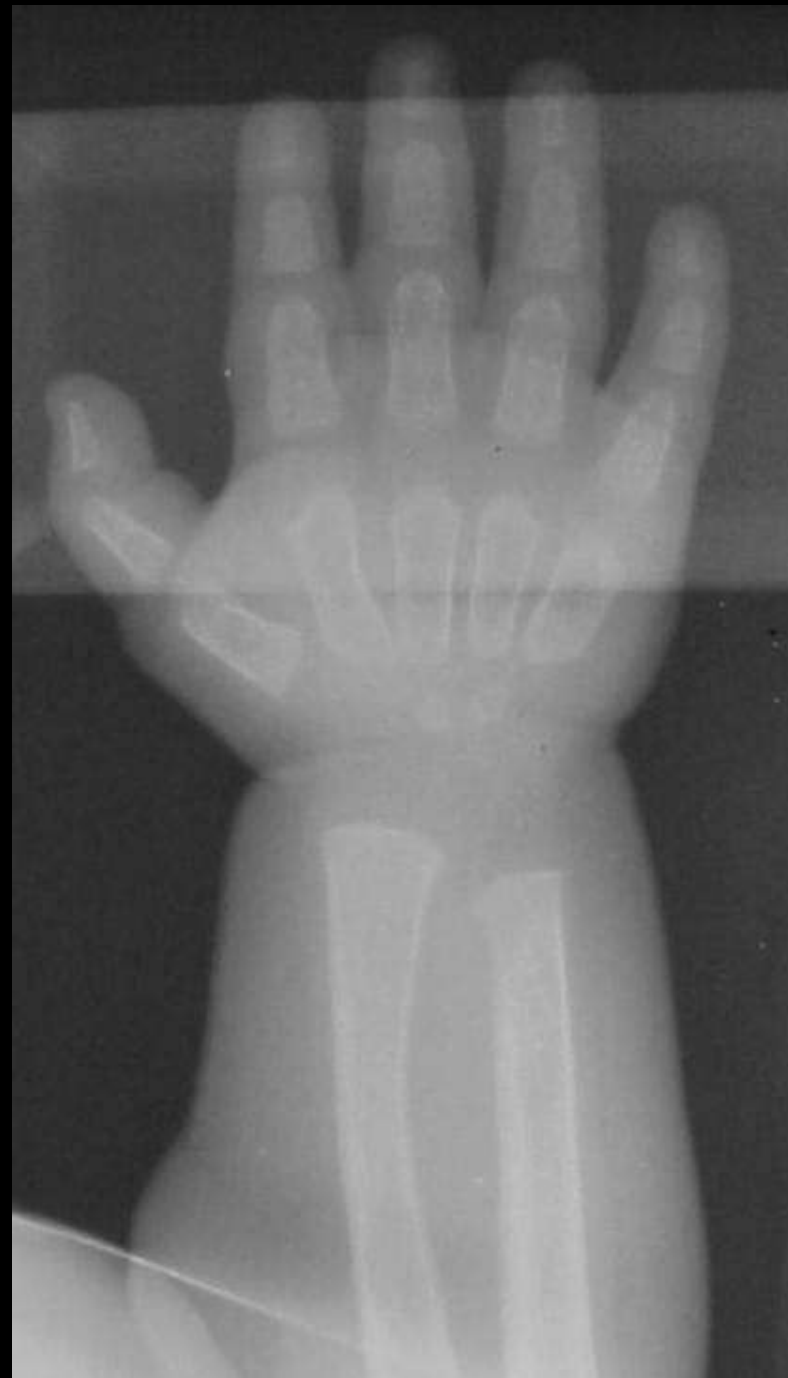Lunate subluxation





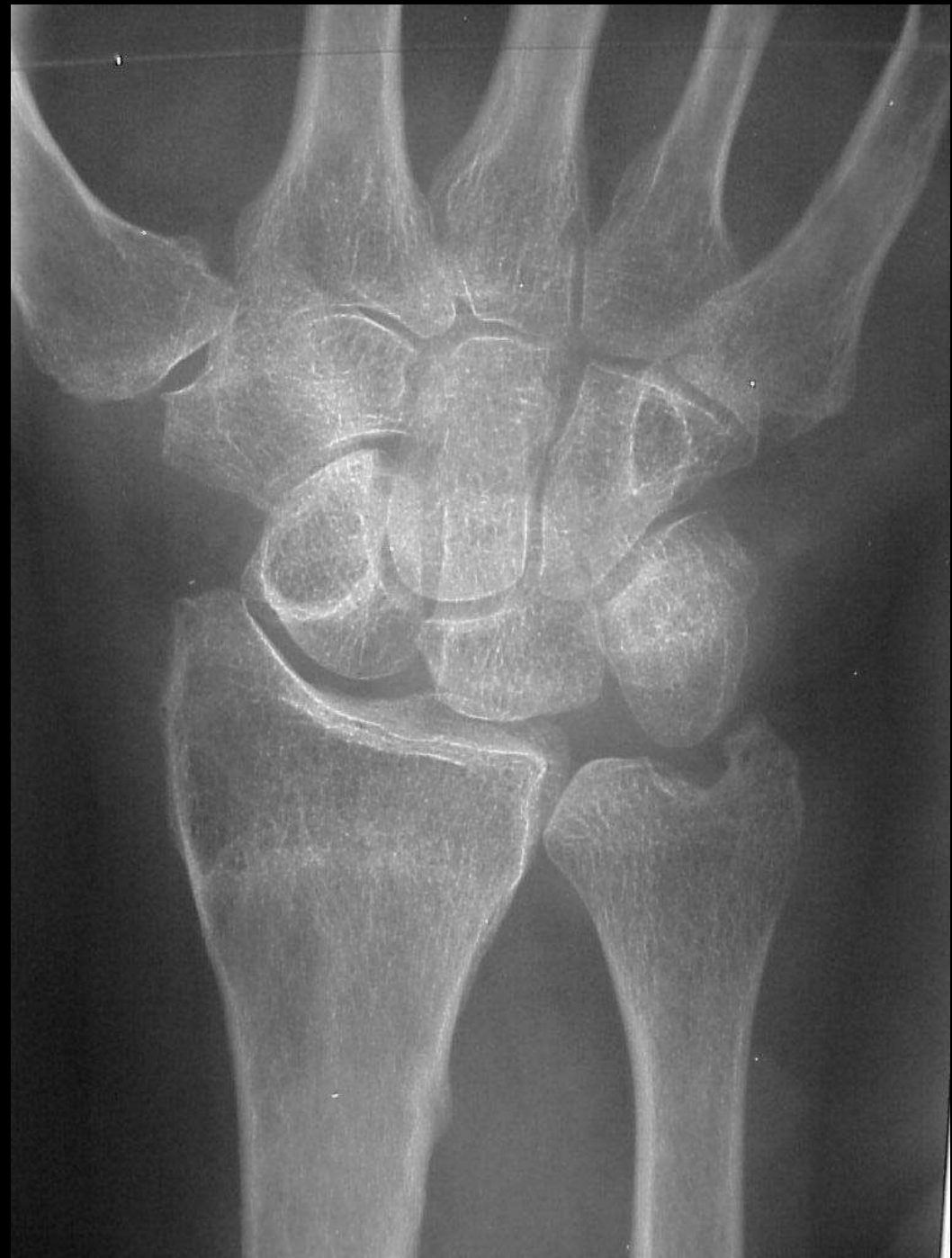Bullet shaped metacarpal

Dysostosis multiplex





Signet ring Scaphoid  
Scaphoid seen near end on  
Fx of waist  
DISI

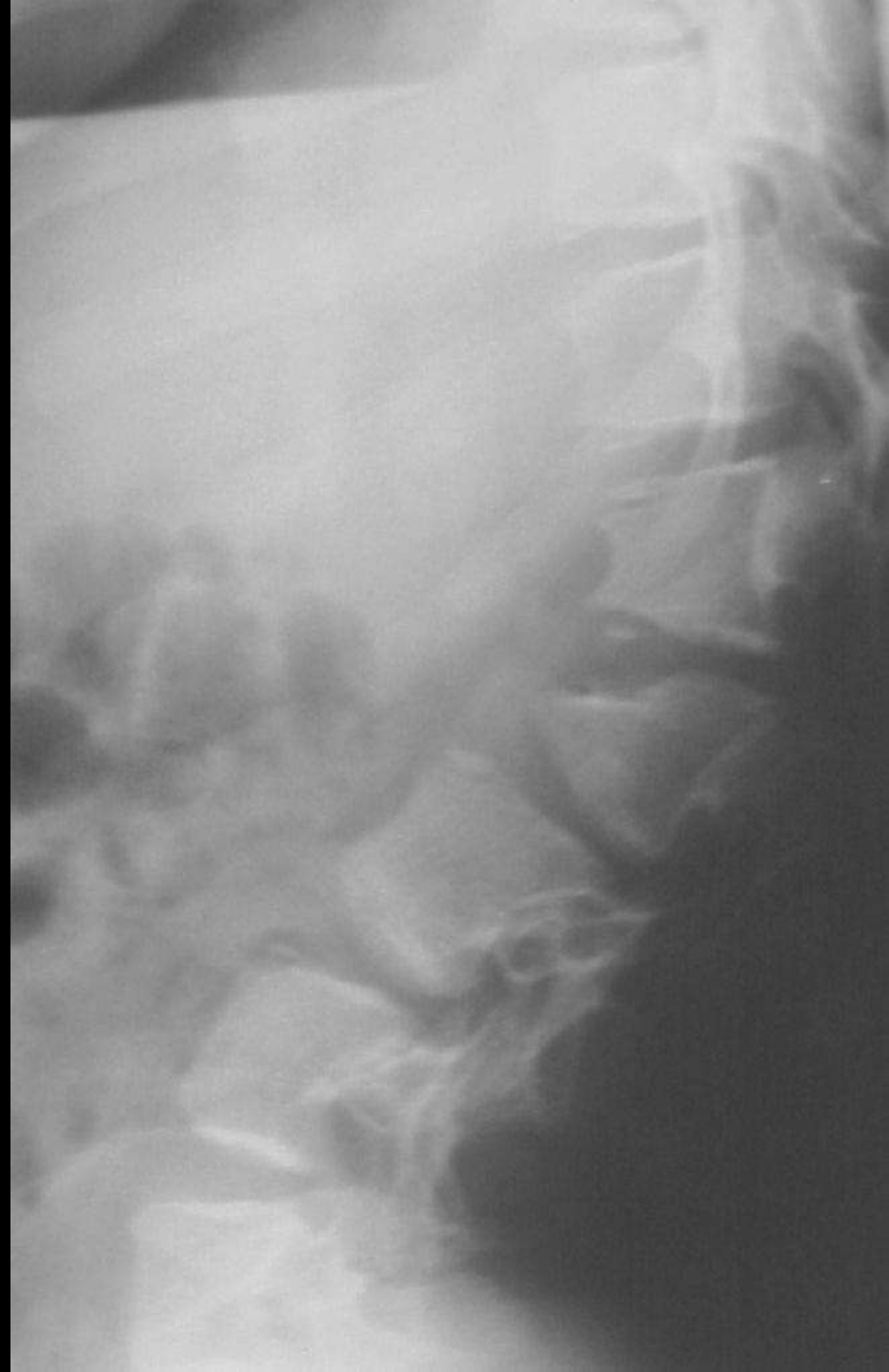


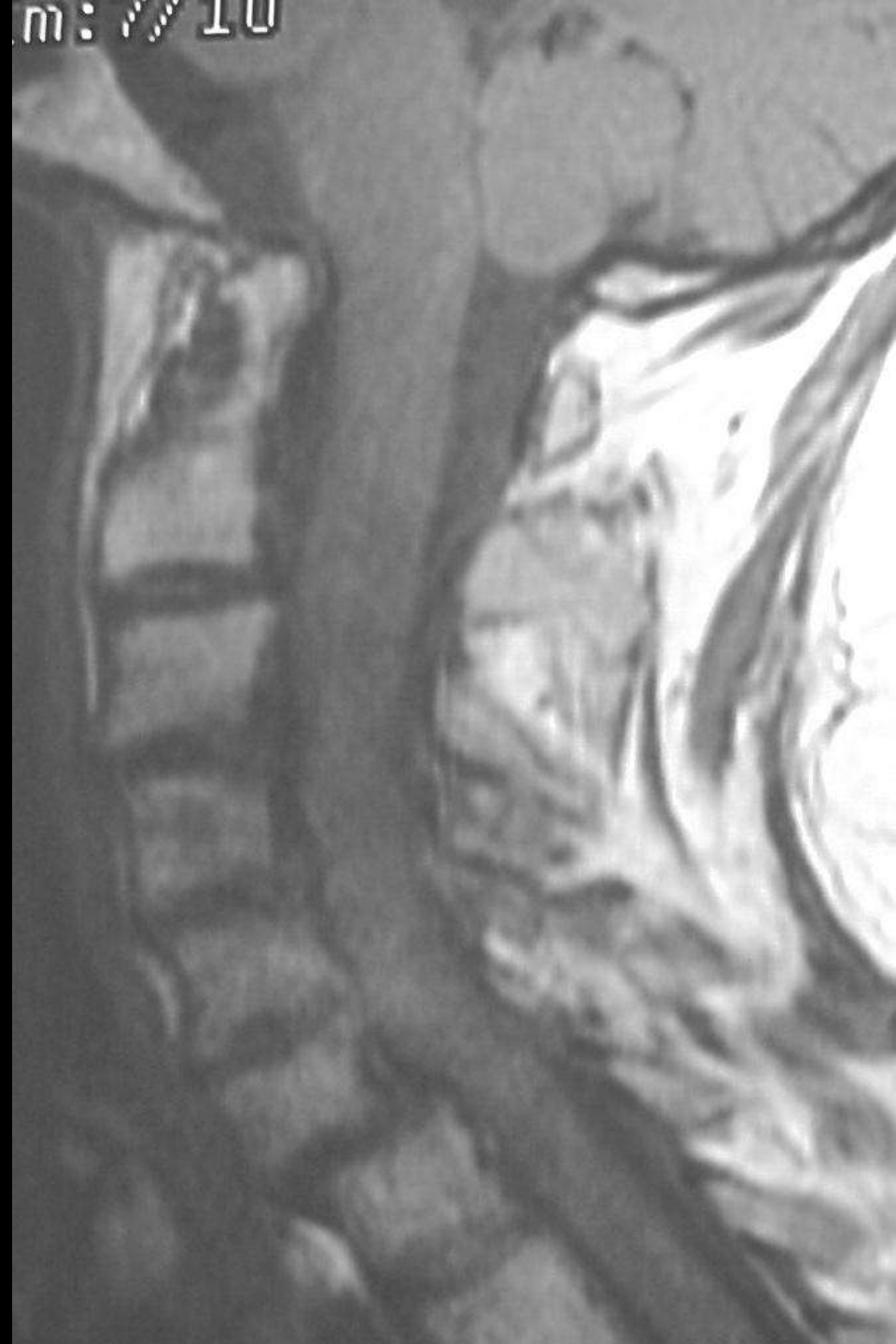


Bullet shaped vertebrae

Achondroplasia  
Hurler's syndrome

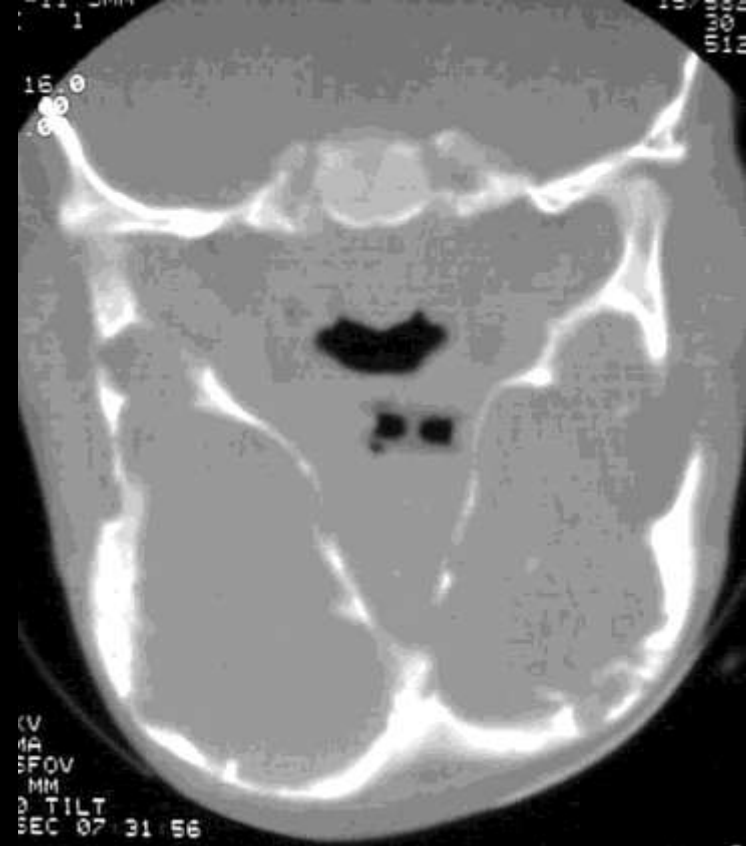
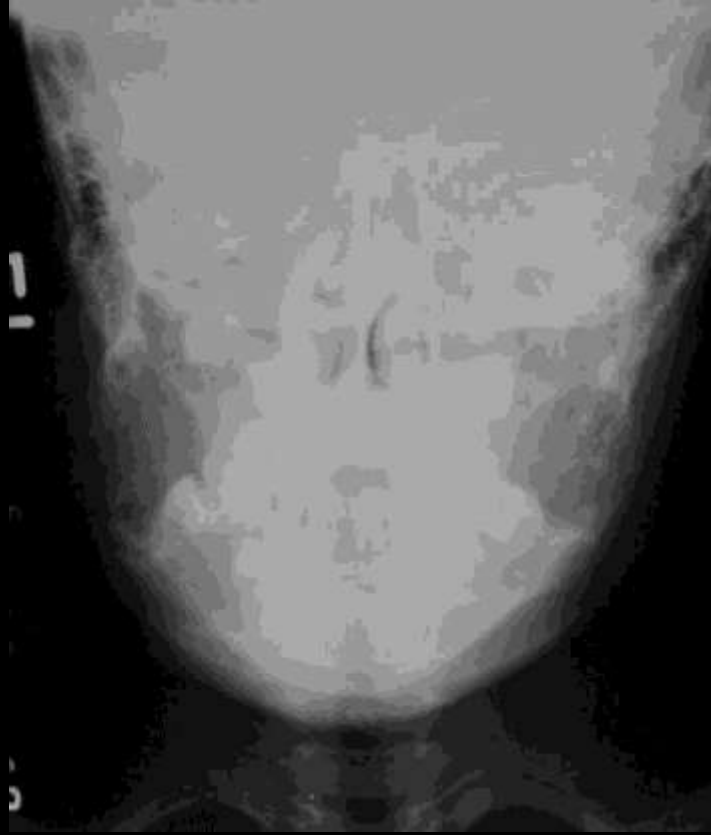




Stepladder spine

RhA of Cx spine



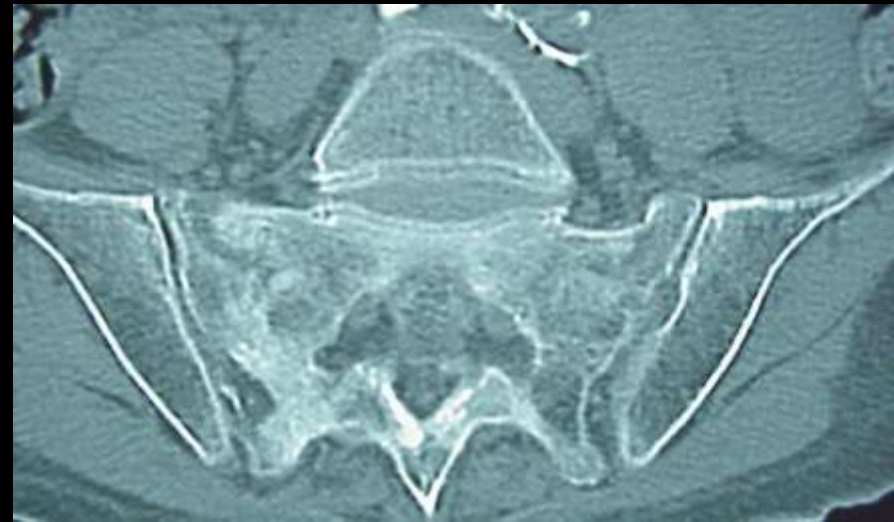
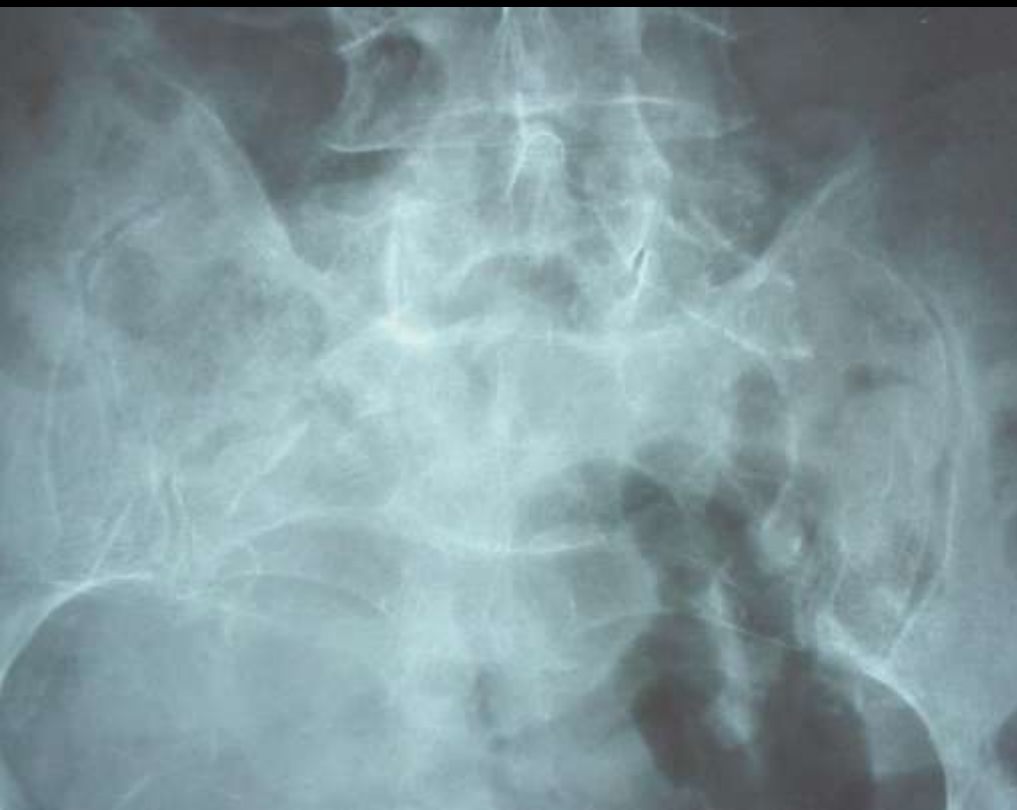
Cherubism  
Fibrous dysplasia





# Butterfly sacral Fx Insufficiency Fx

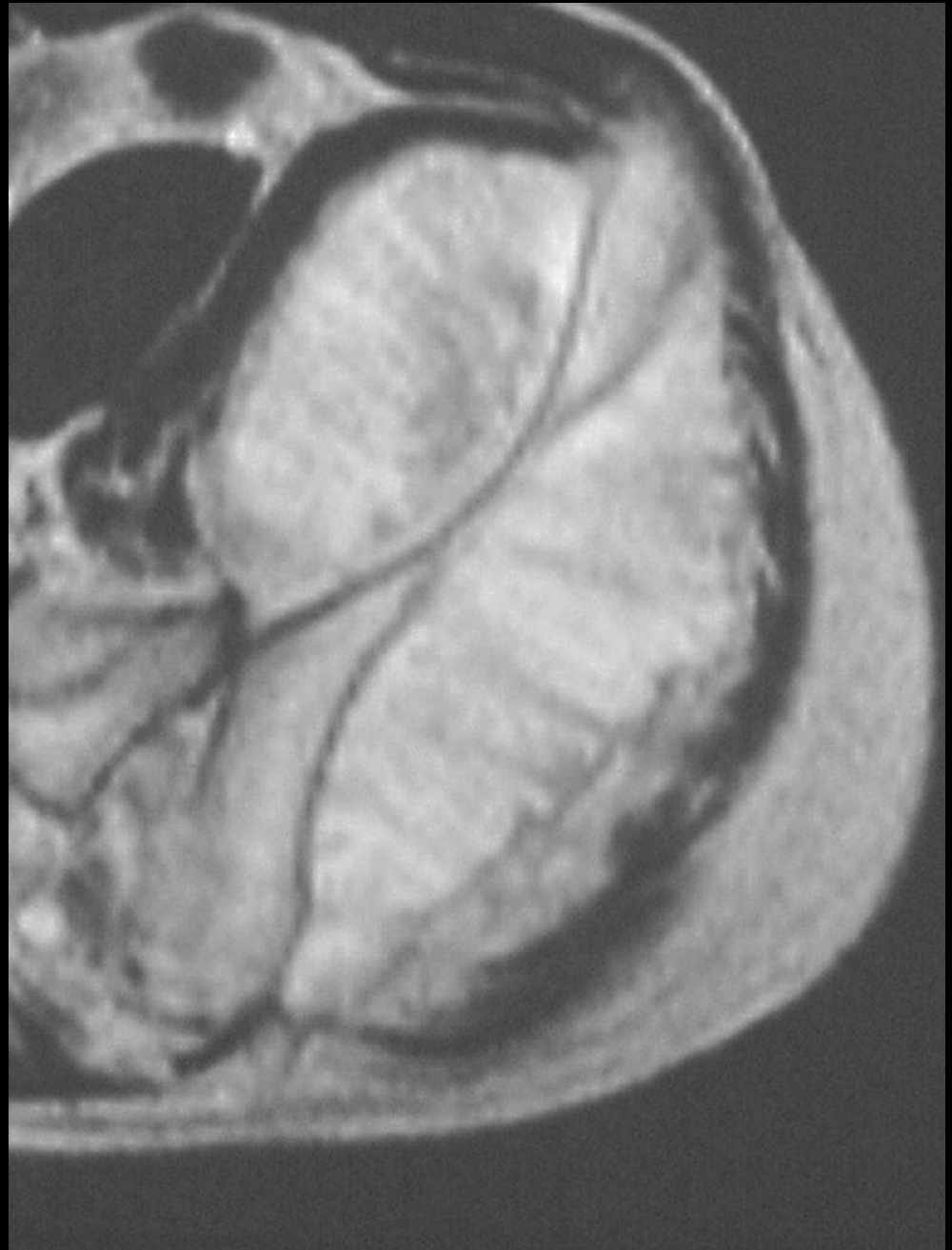





Sunburst

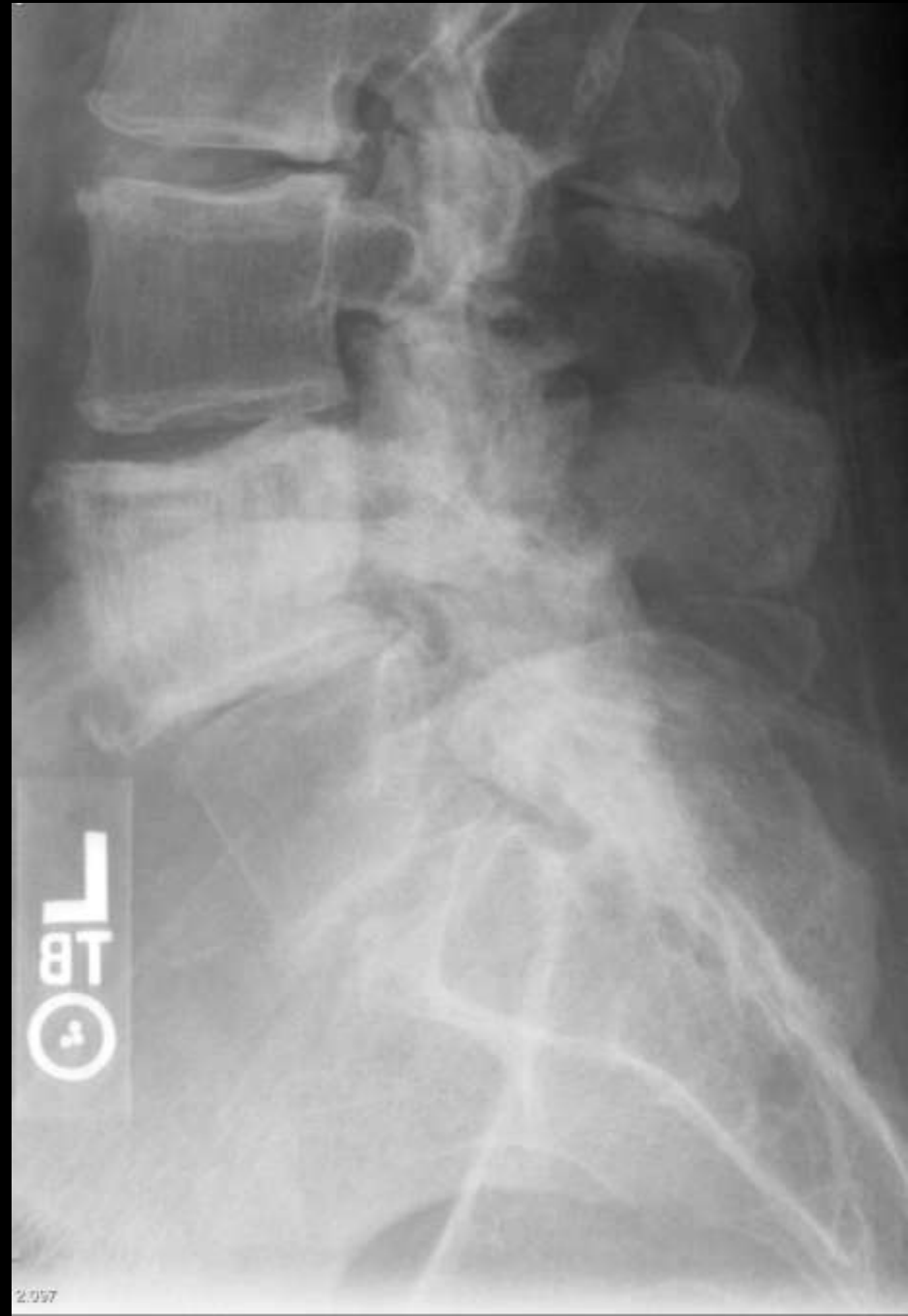Osteosarcoma





Picture frame

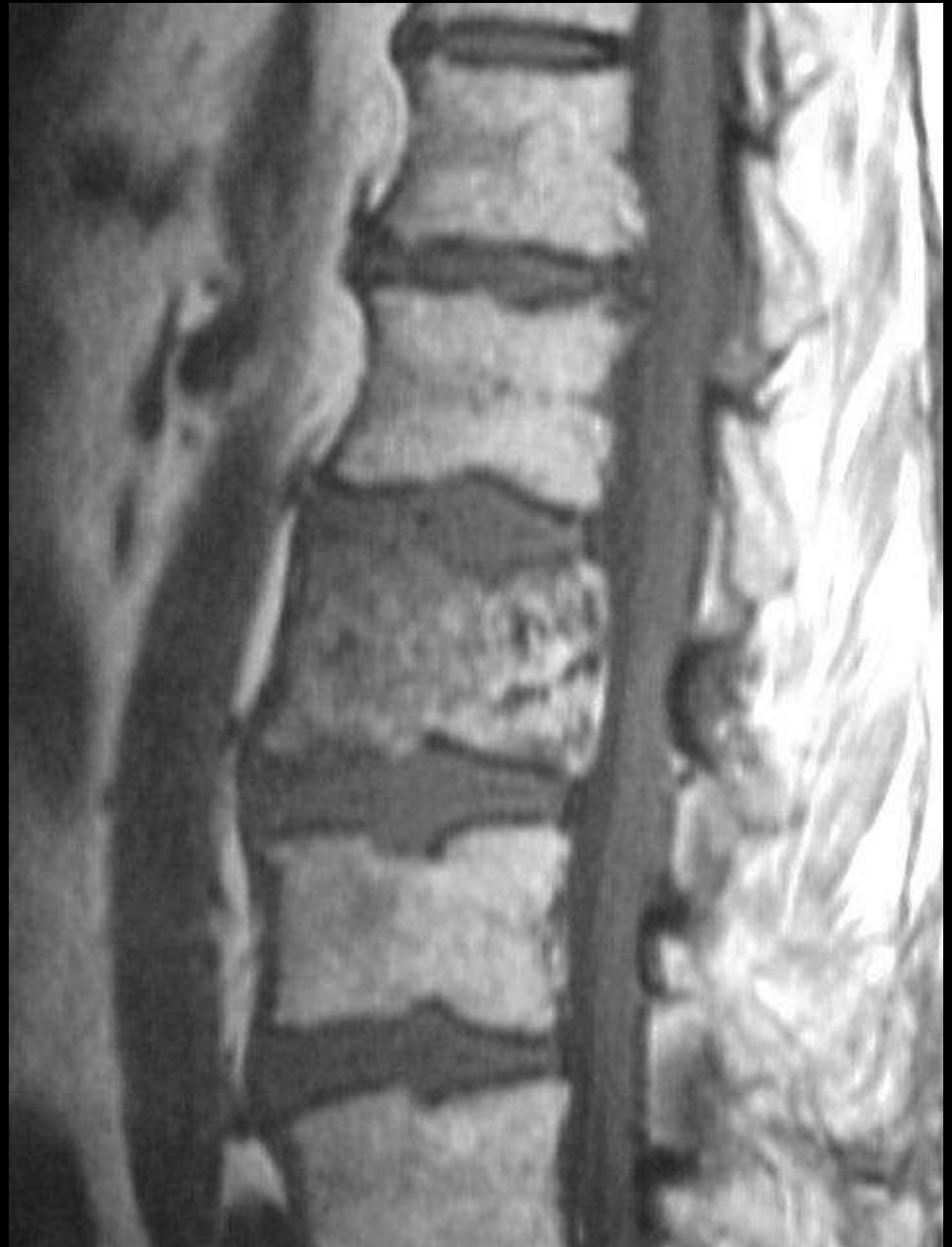Paget's spine





Picture frame

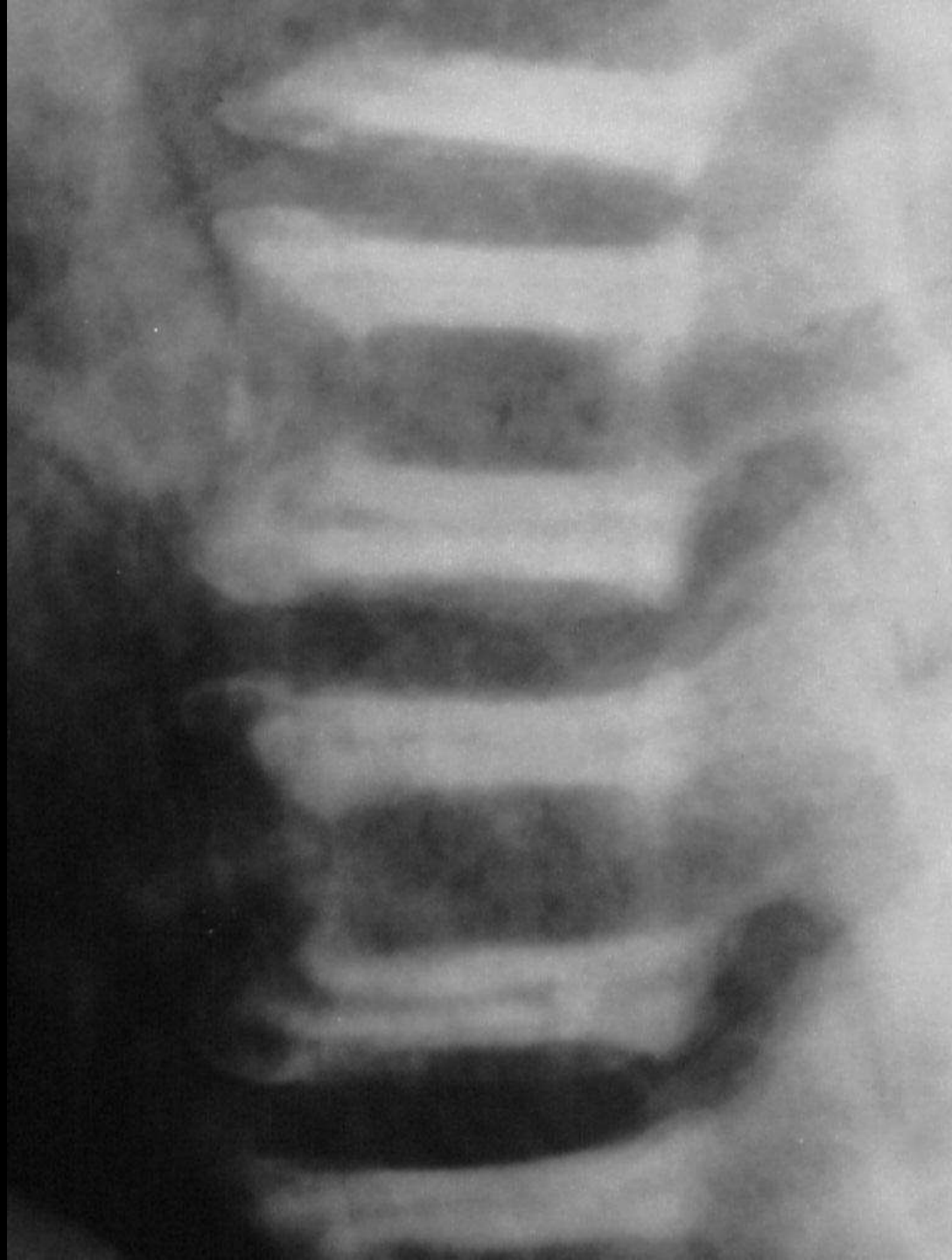
Paget's spine







# Sandwich vertebrae Osteopetrosis

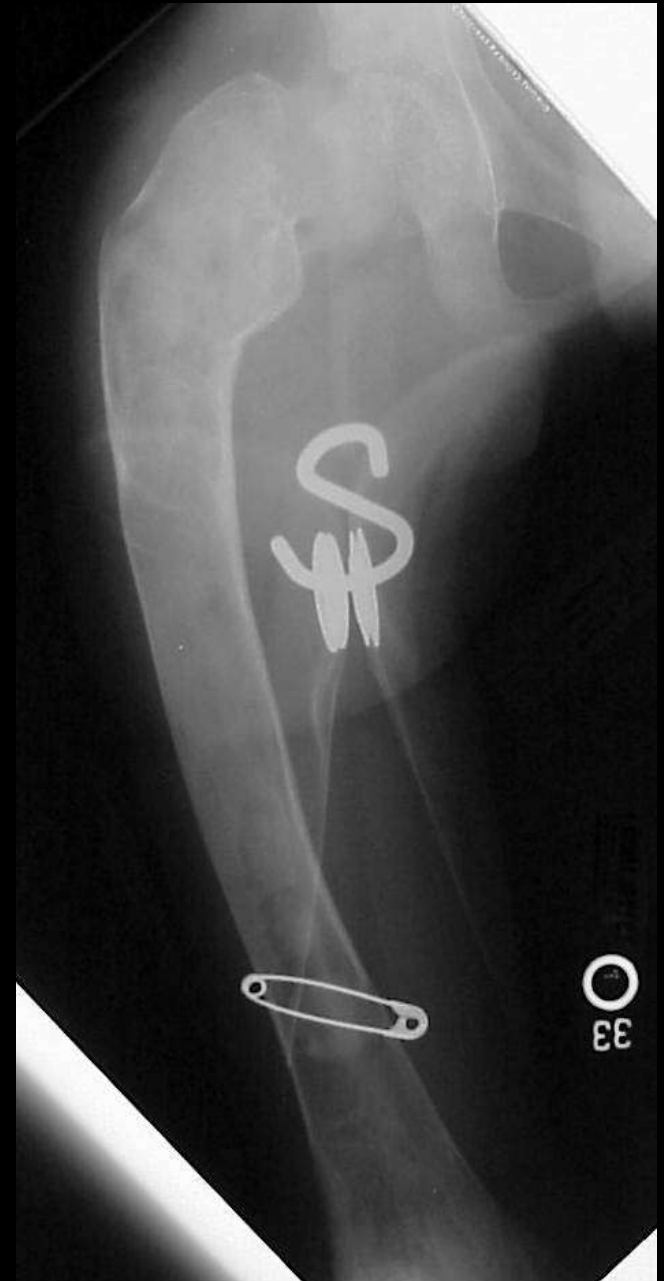





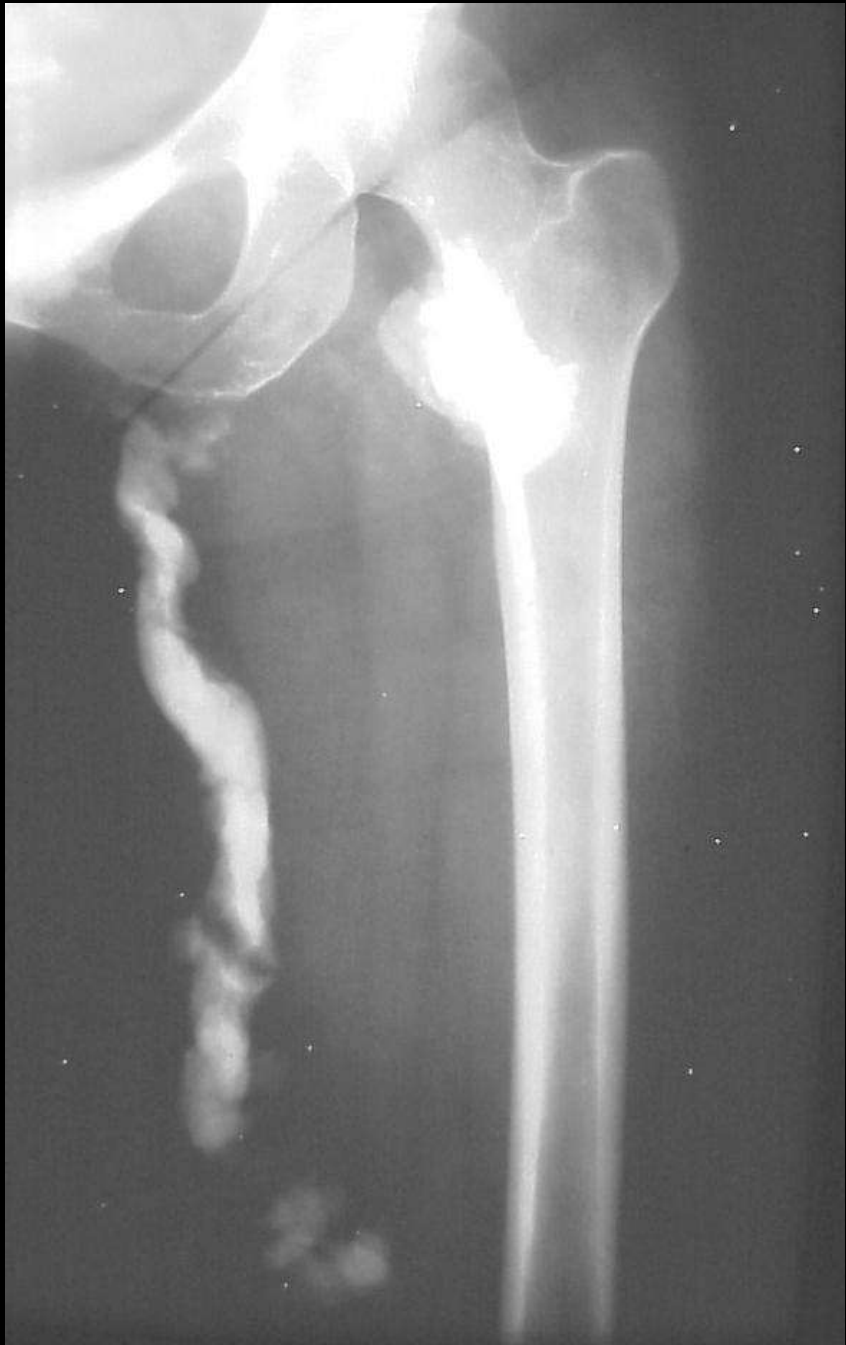# Shepherds Crook deformity

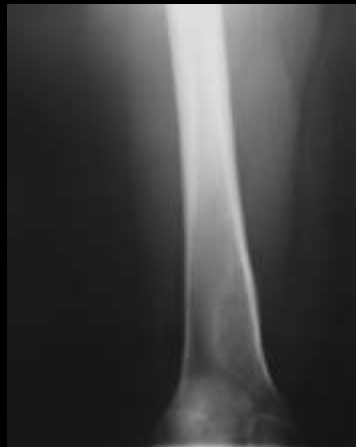Fibrous dysplasia





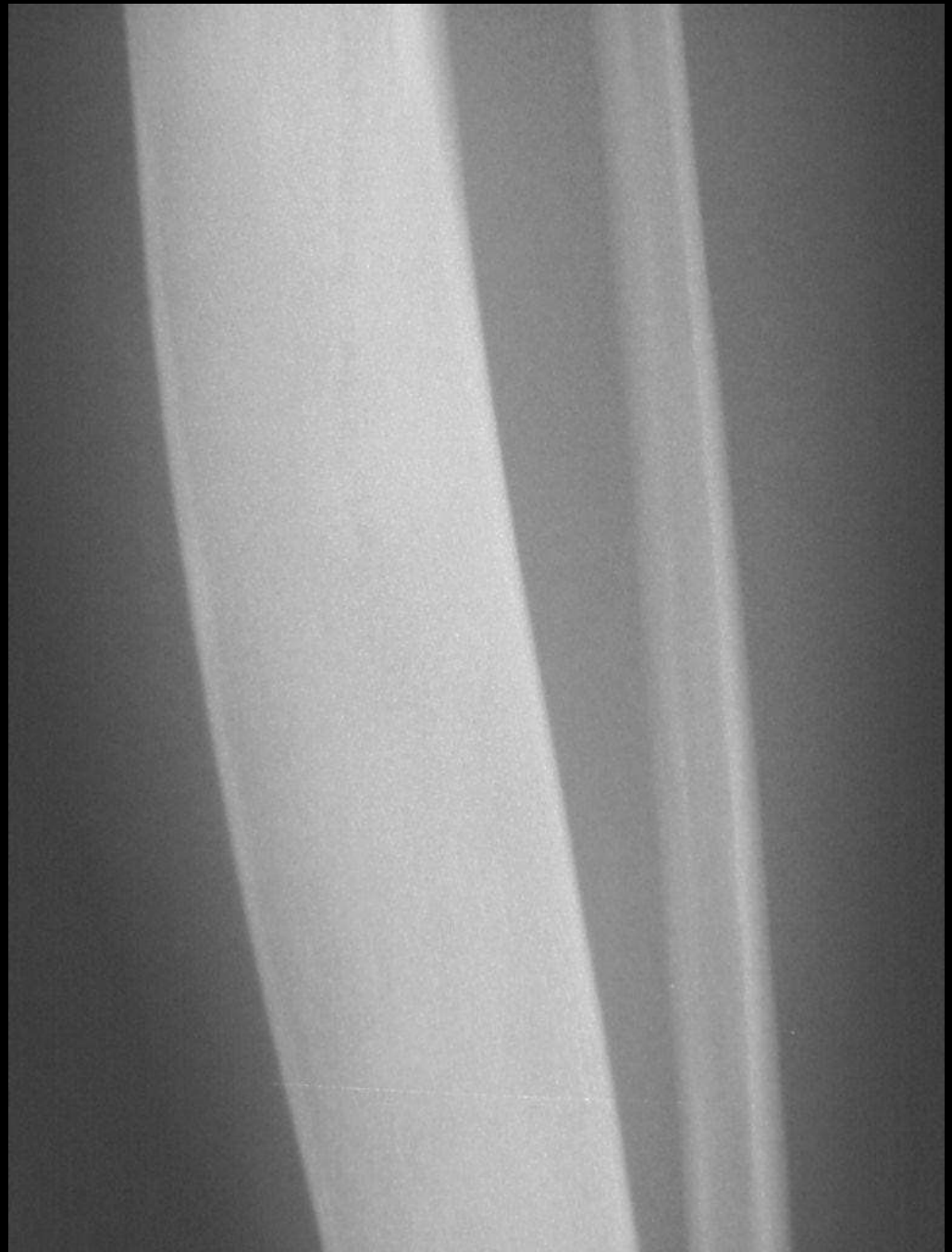Dripping candle wax  
Melorrrheostosis

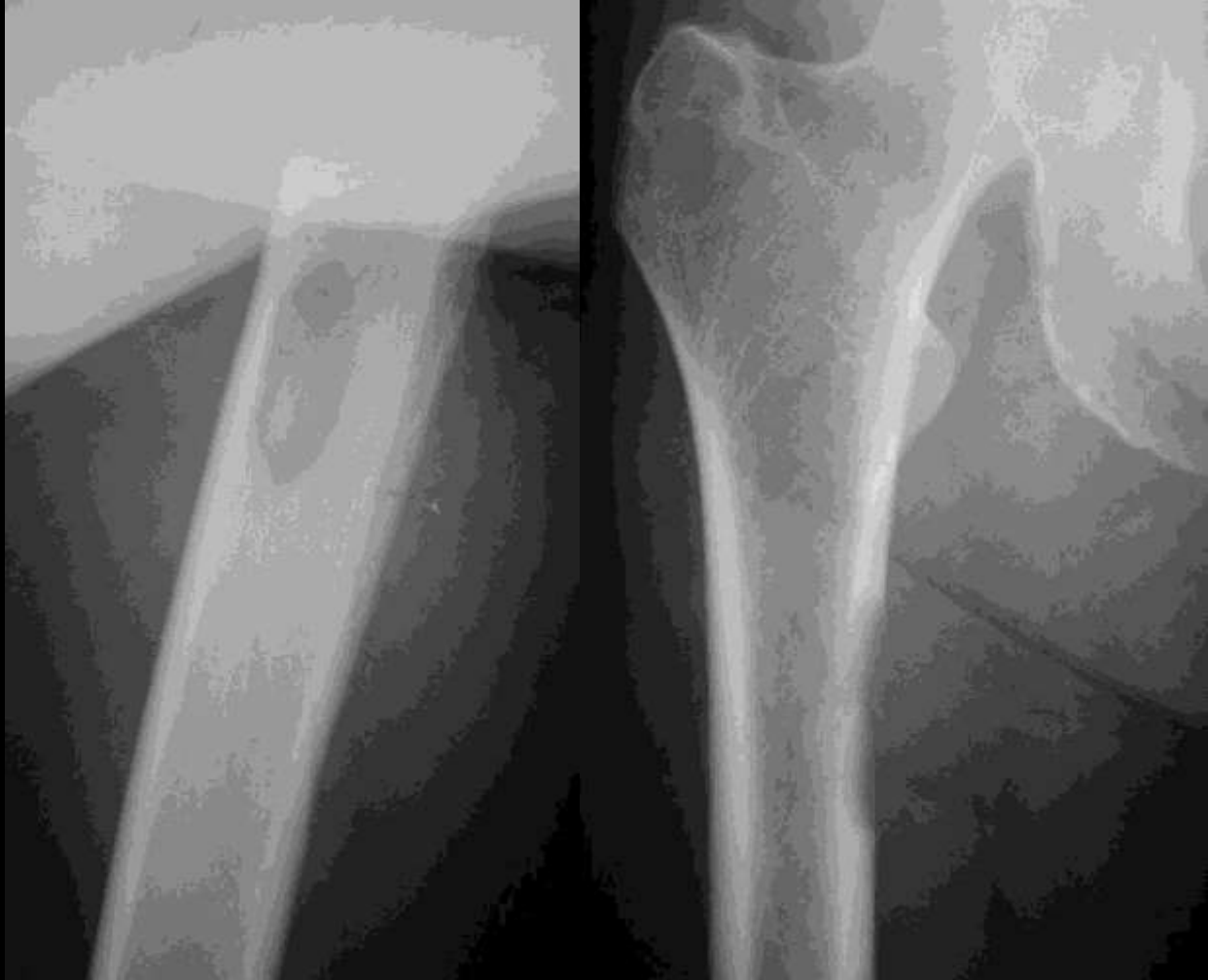



Ground glass

Fibrous dysplasia



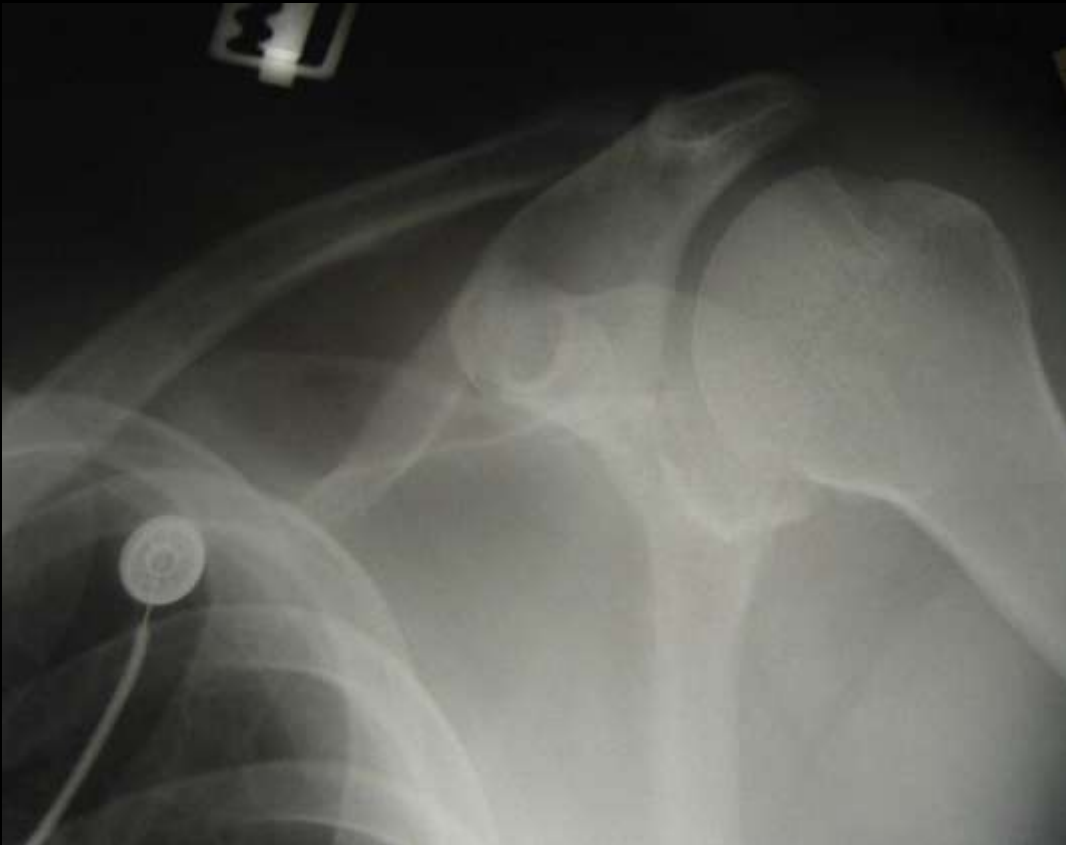
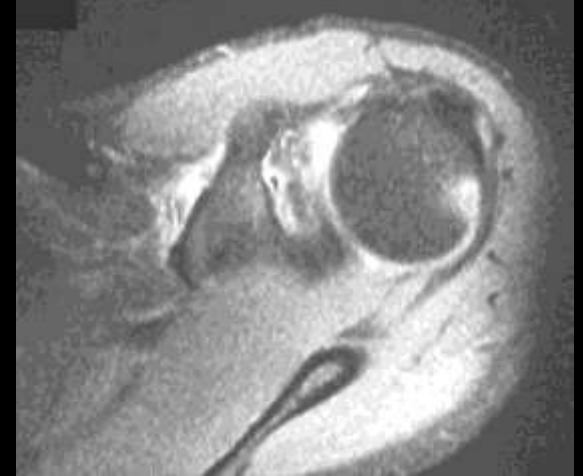
Cookie bite lesion  
Cortical mets  
Lung or adeno



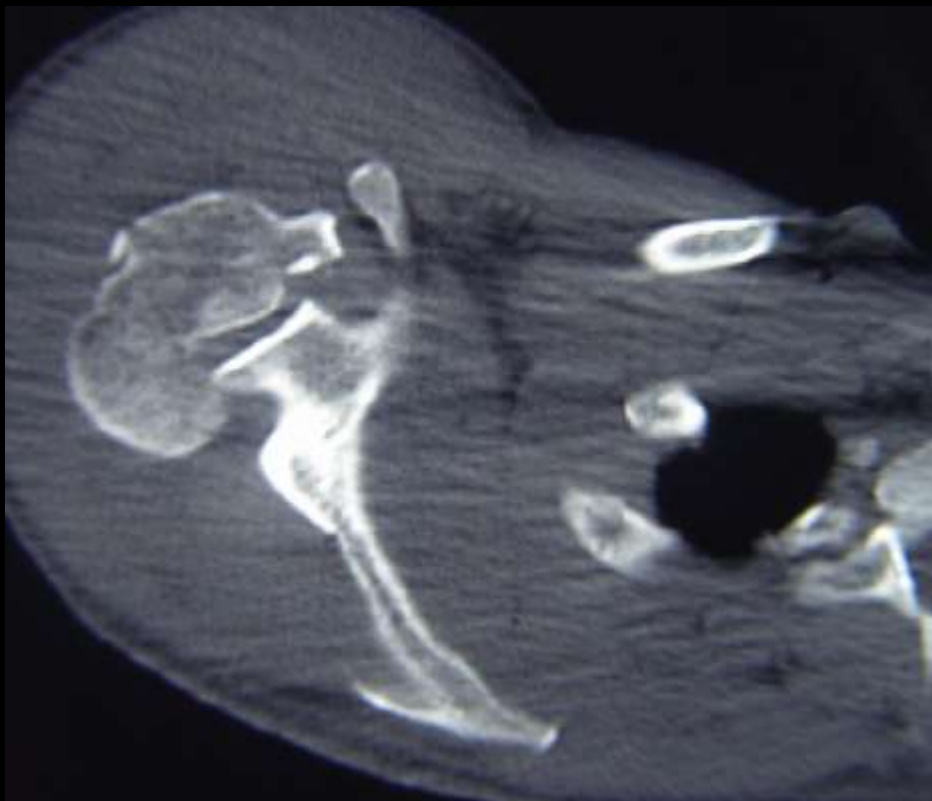


# Hatchet deformity Hill Sachs Anterior Dislocation



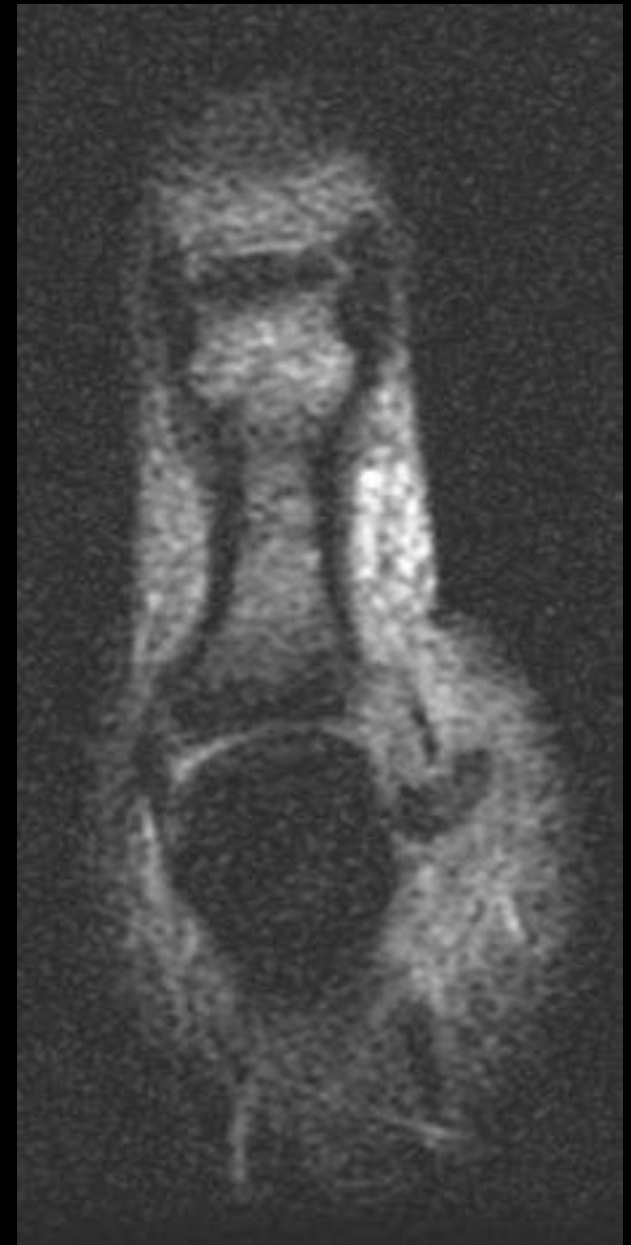


# Trough Fracture Posterior Dislocation





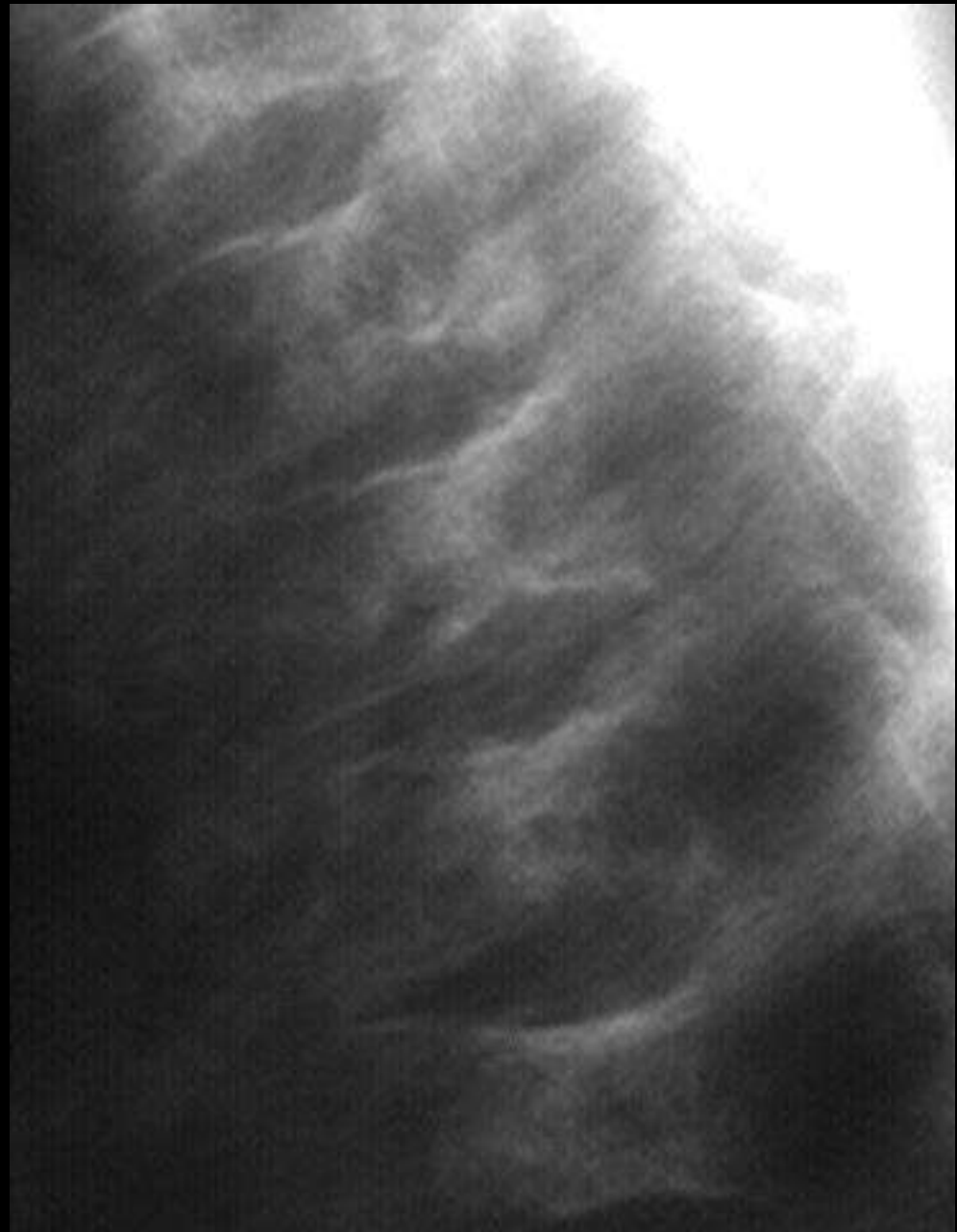# Yo Yo on a string Stenners lesion





H shaped vertebrae

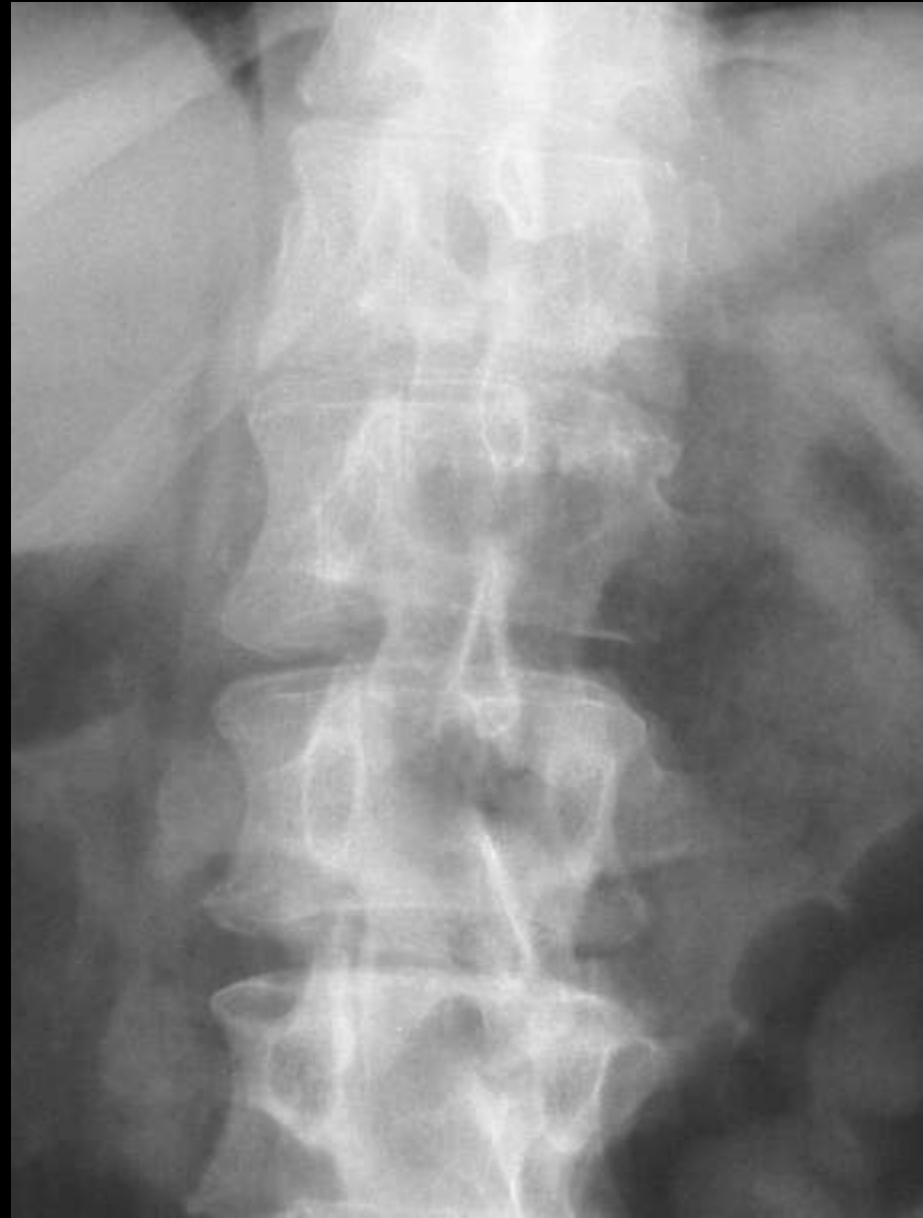Sickle cell disease

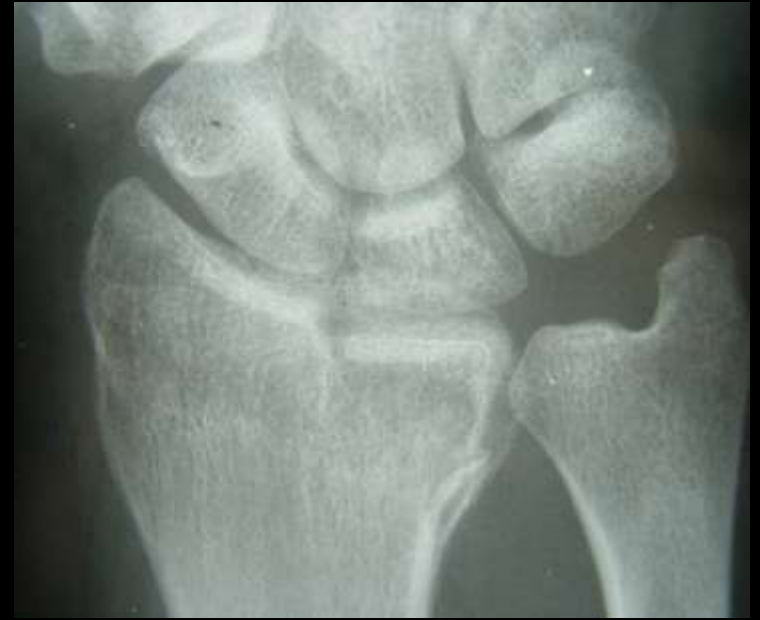




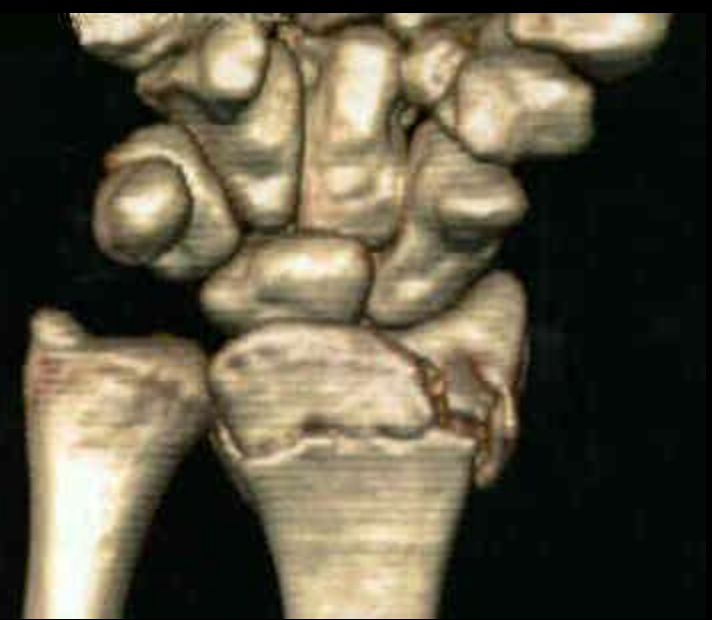
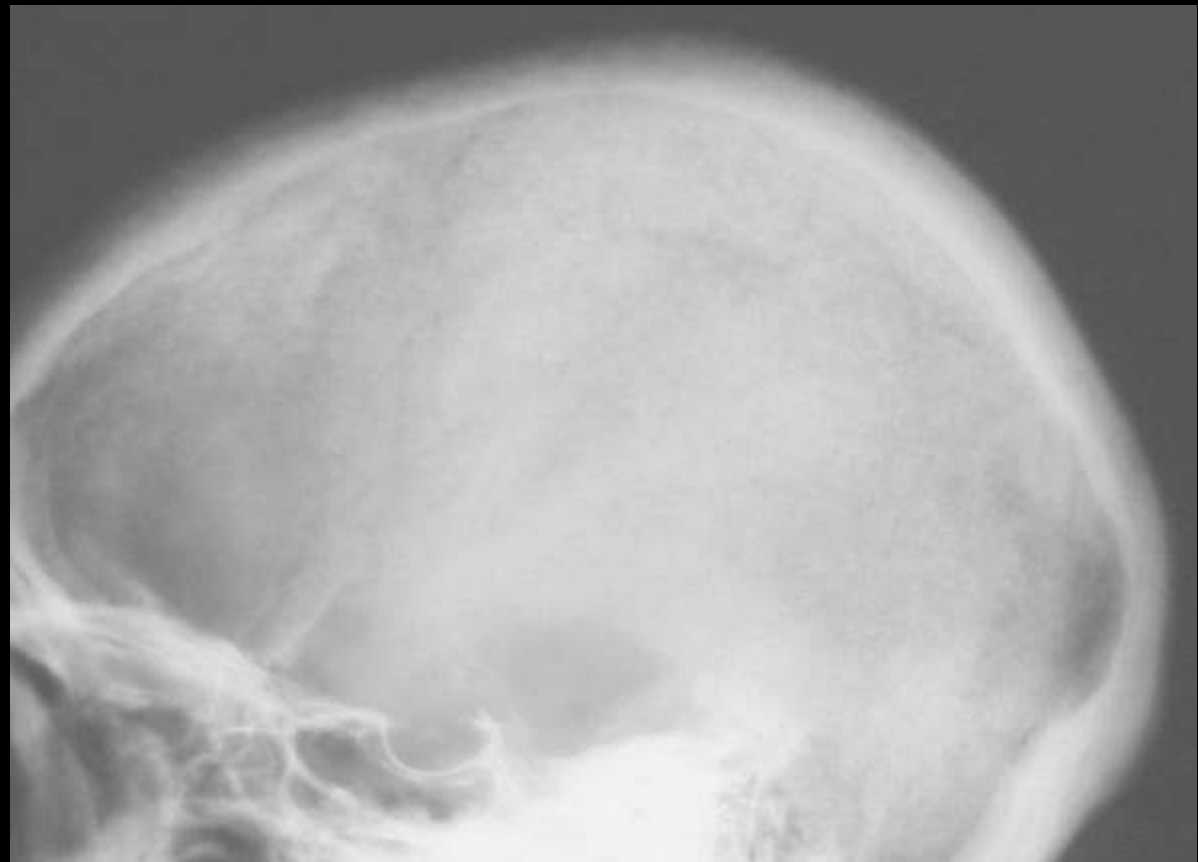
# Winking Owl Pedicle metastasis





Die punch fracture  
Lunate into radius





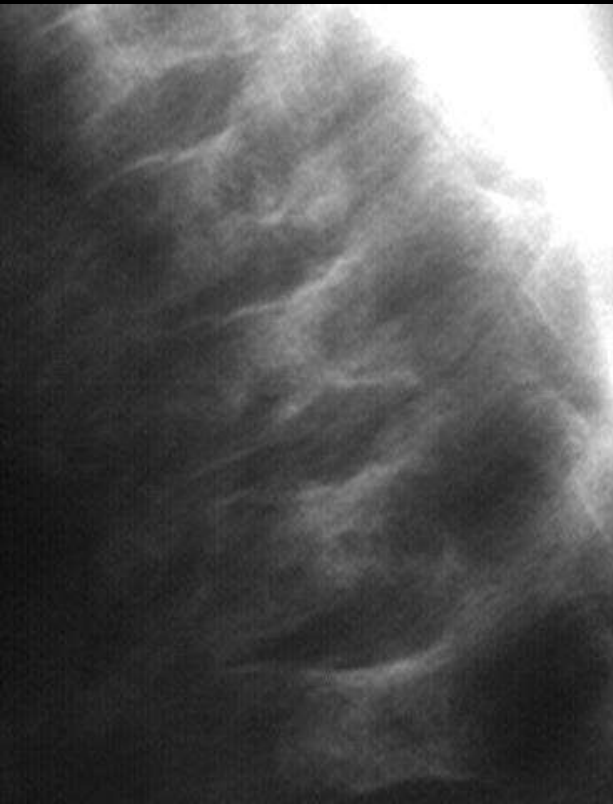
Salt and Pepper skull

Hyperparathyroidism



# Lincoln log deformity

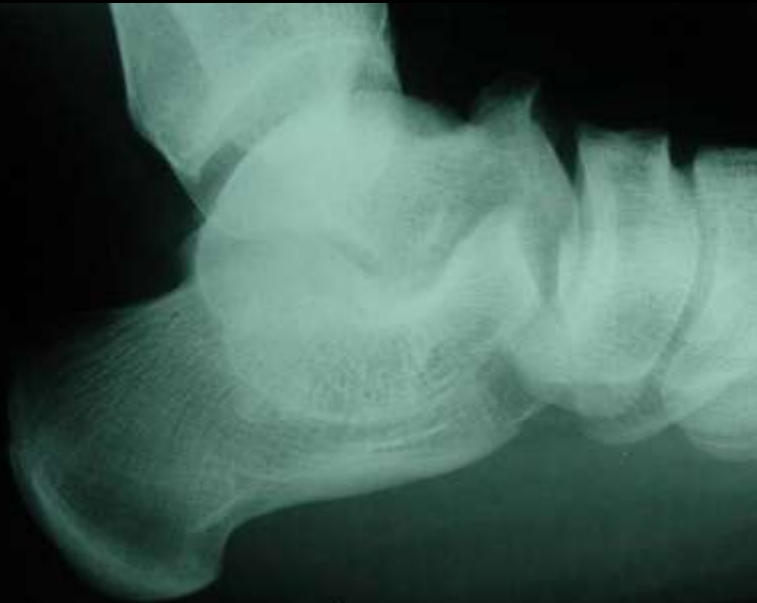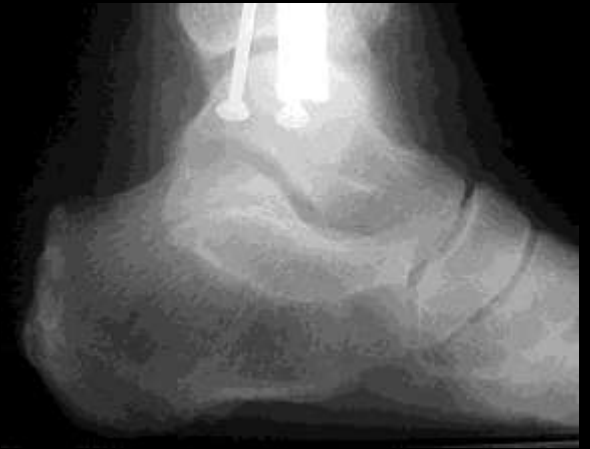## Sickle cell end plate infarctions





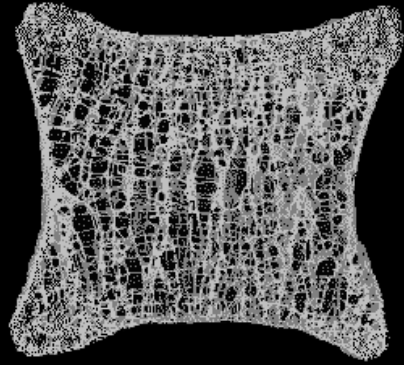


## Continuous C sign Talocalcaneal coalition



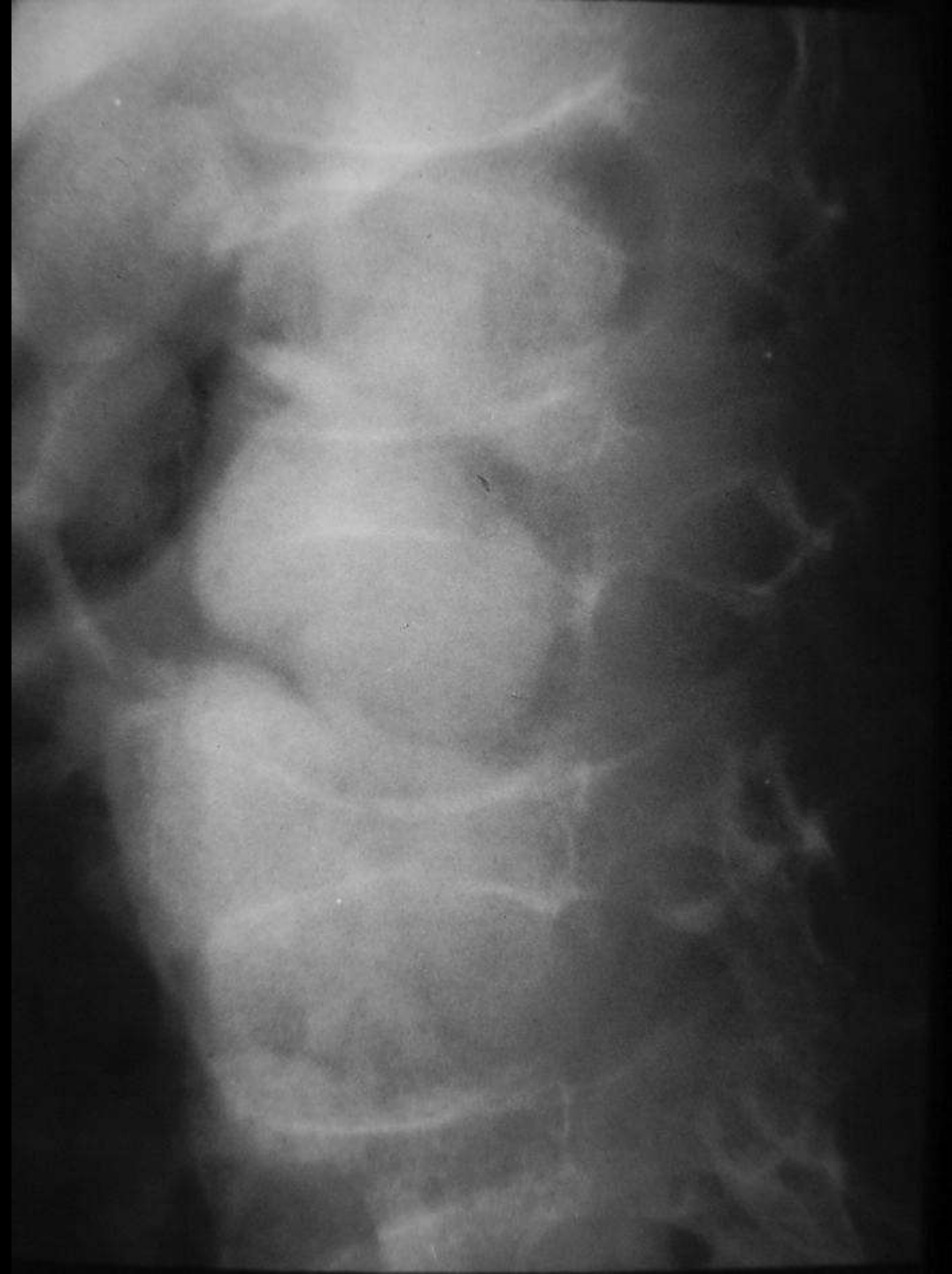

*Syntarsus* (sin-TAR-sus) was a Late Triassic theropod. It got its name, which means "fused ankle," because some of its ankle bones had grown together. Only two feet tall, *Syntarsus* had to avoid being eaten by larger theropods while it searched for smaller prey.

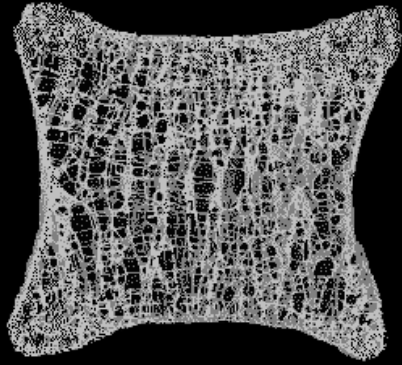




Codfish vertebrae

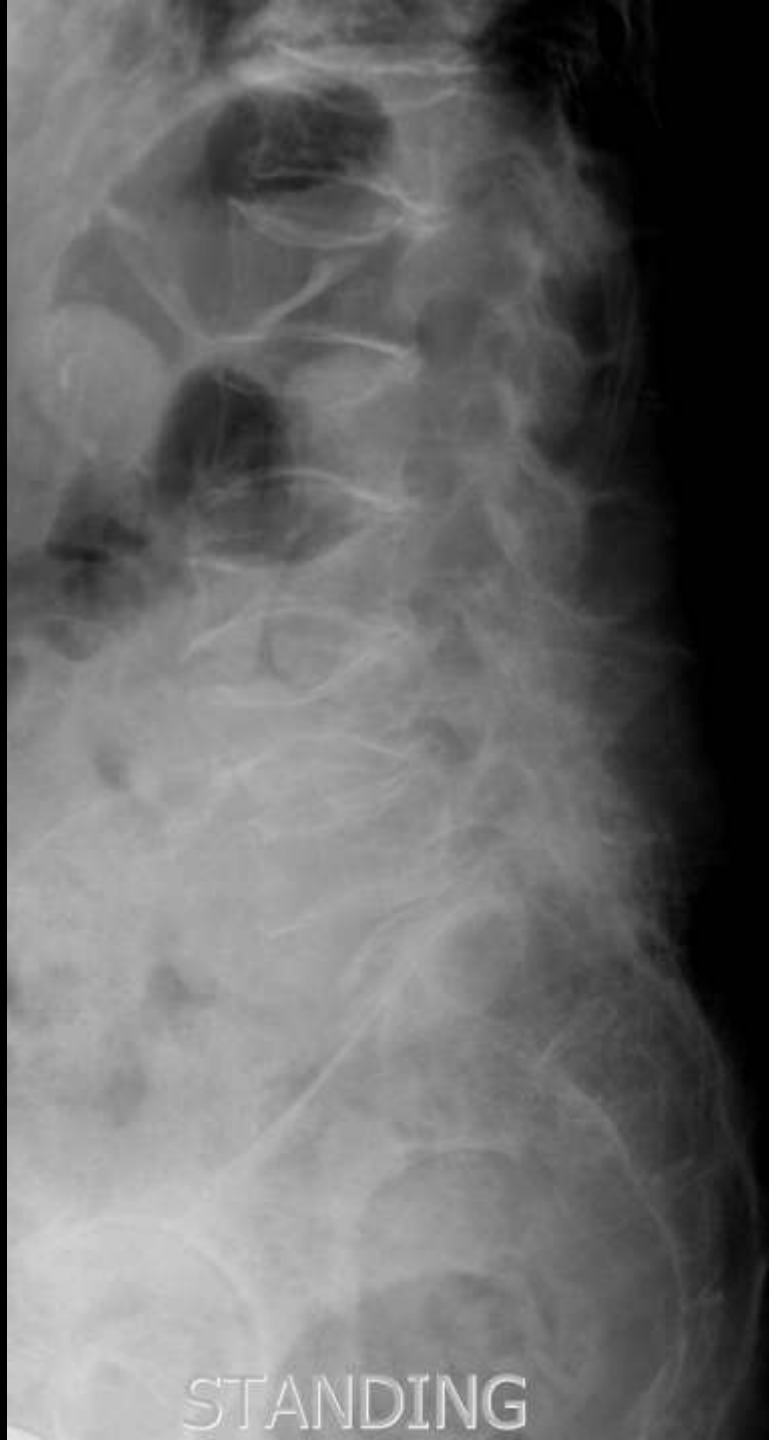
Osteoporosis





Codfish vertebrae

Osteoporosis

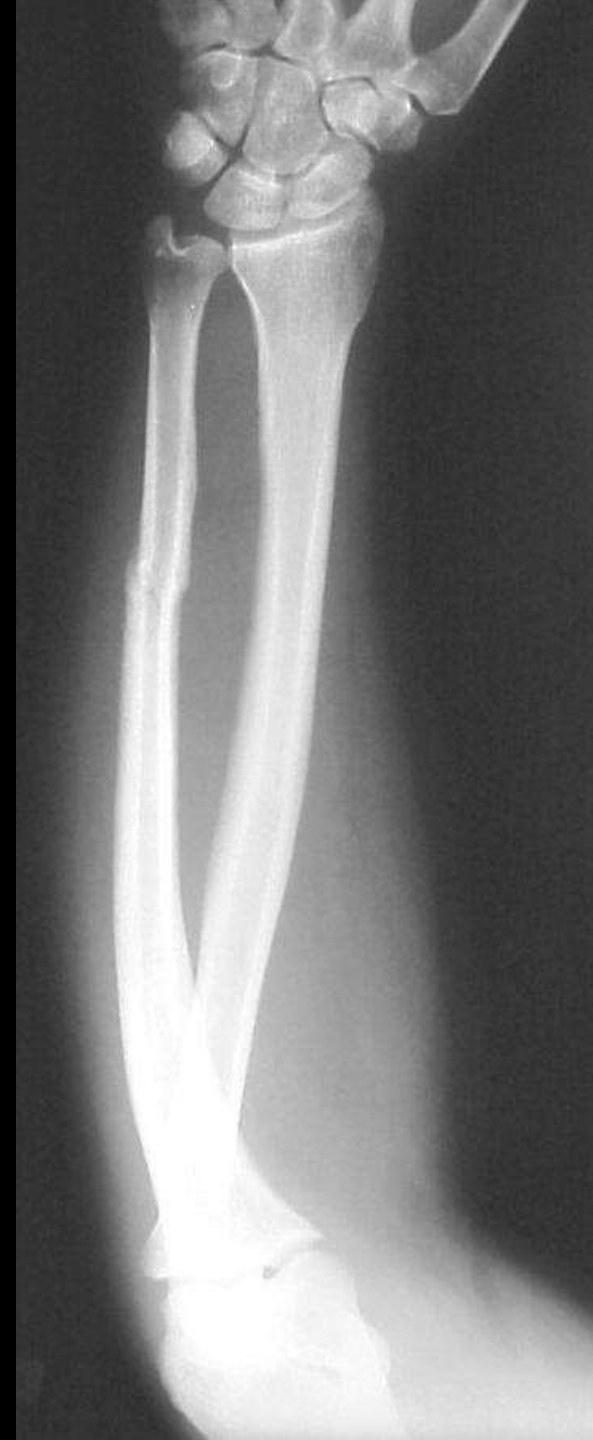

STANDING



# Nightstick fracture

## Direct trauma

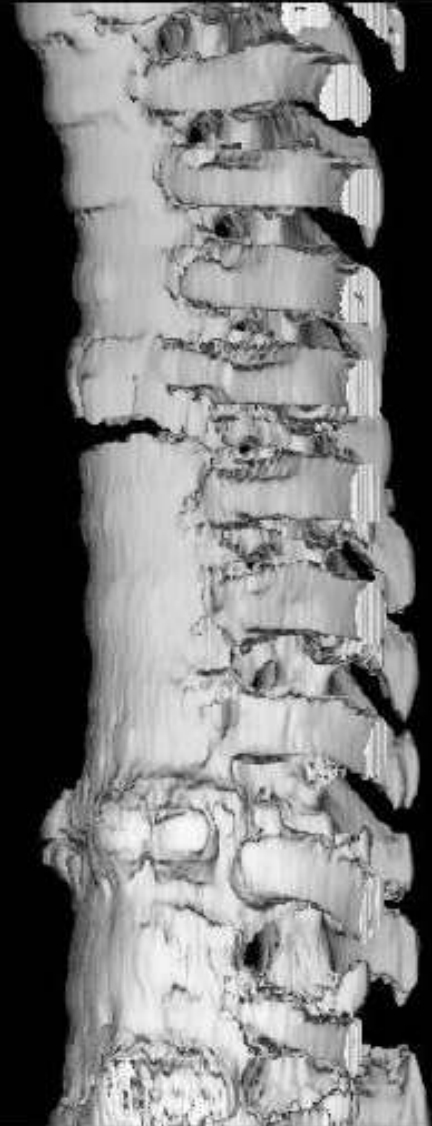
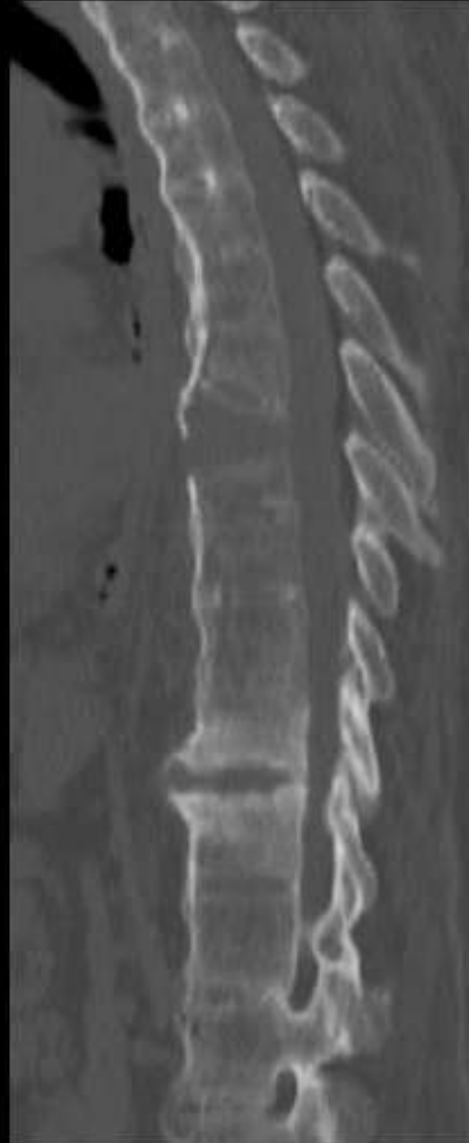






# Chalk stick fracture

## Ankylosing Spondylitis

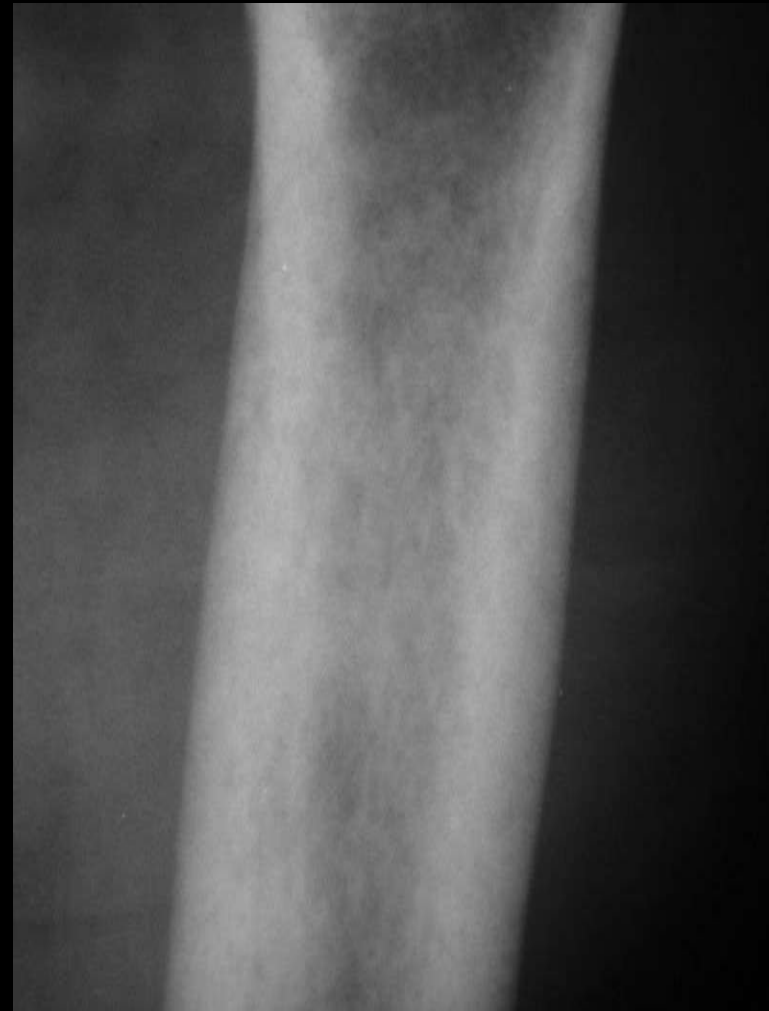


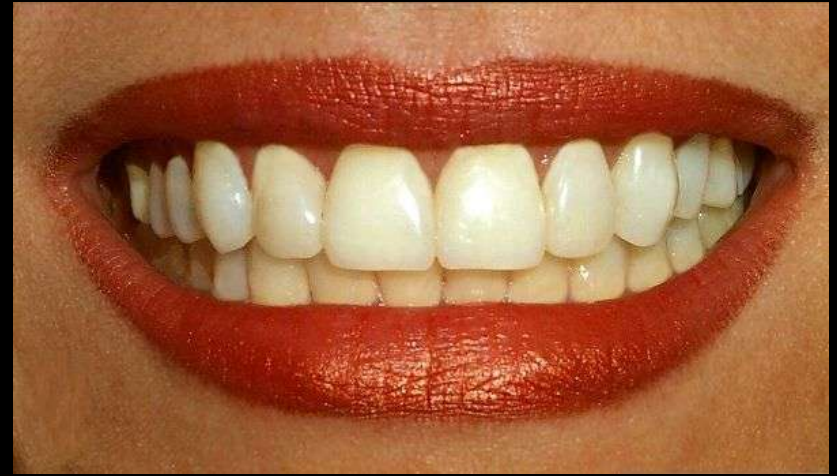
# Rotting Fence Post

## Rubella

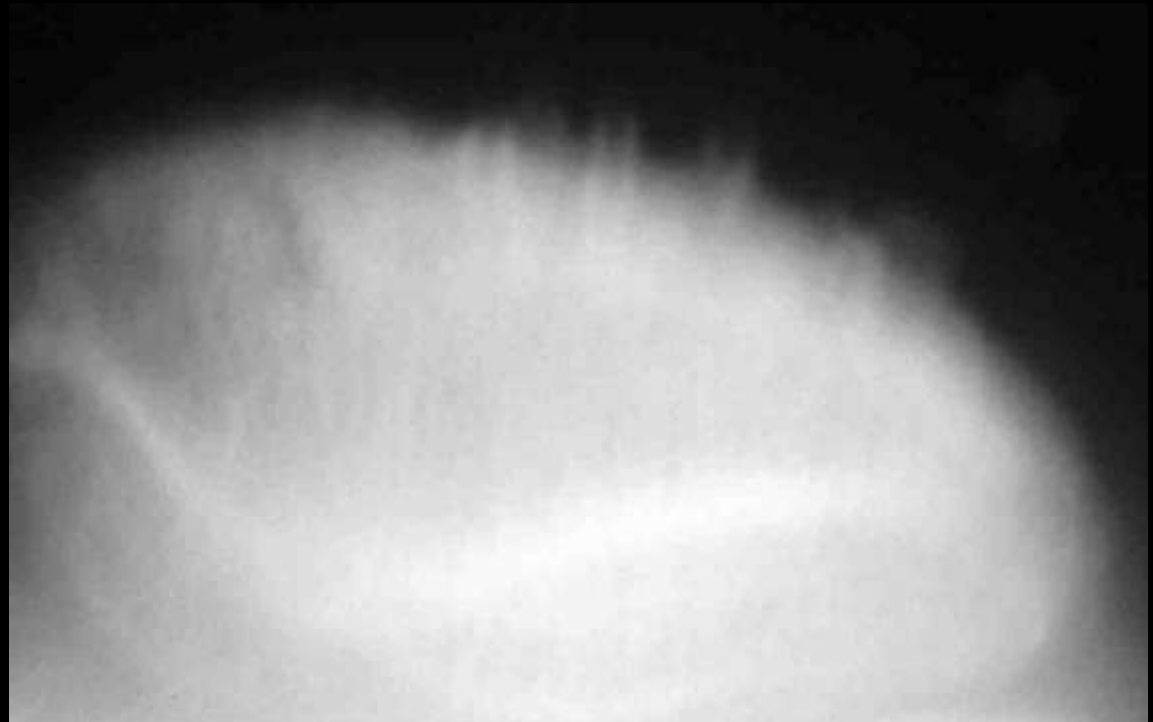
## HPT





# Patella Teeth

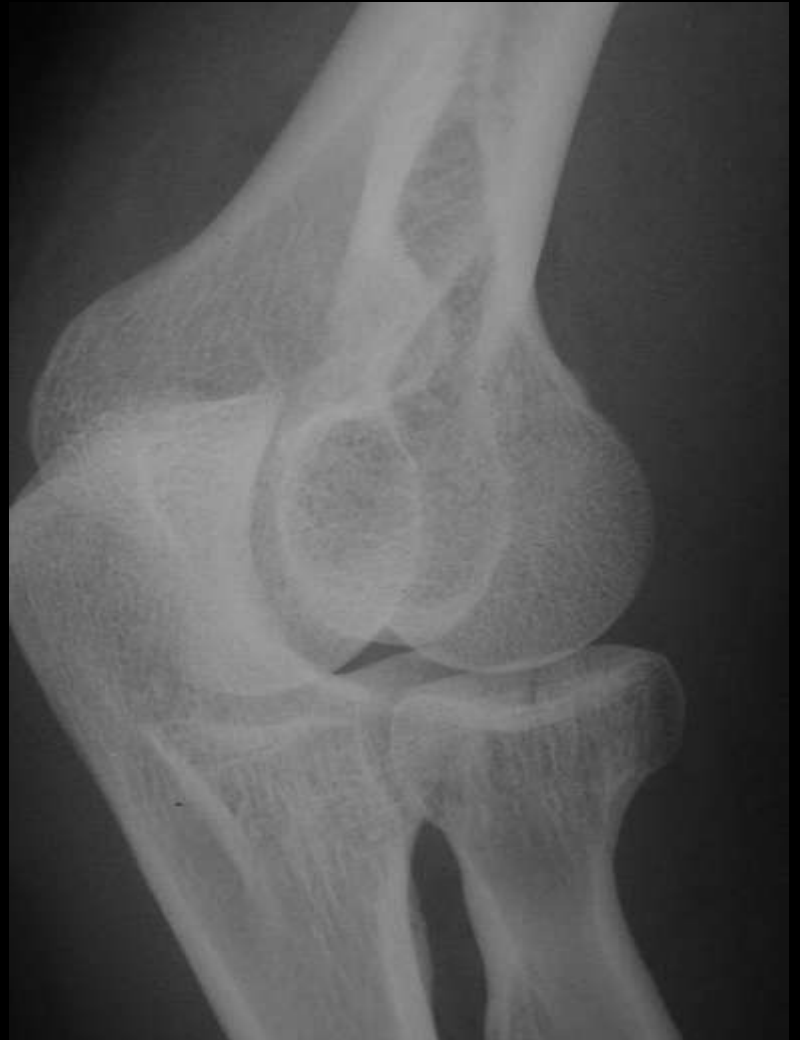## Degenerative enthesopathy





# Chisel Fracture

## Radial head fracture

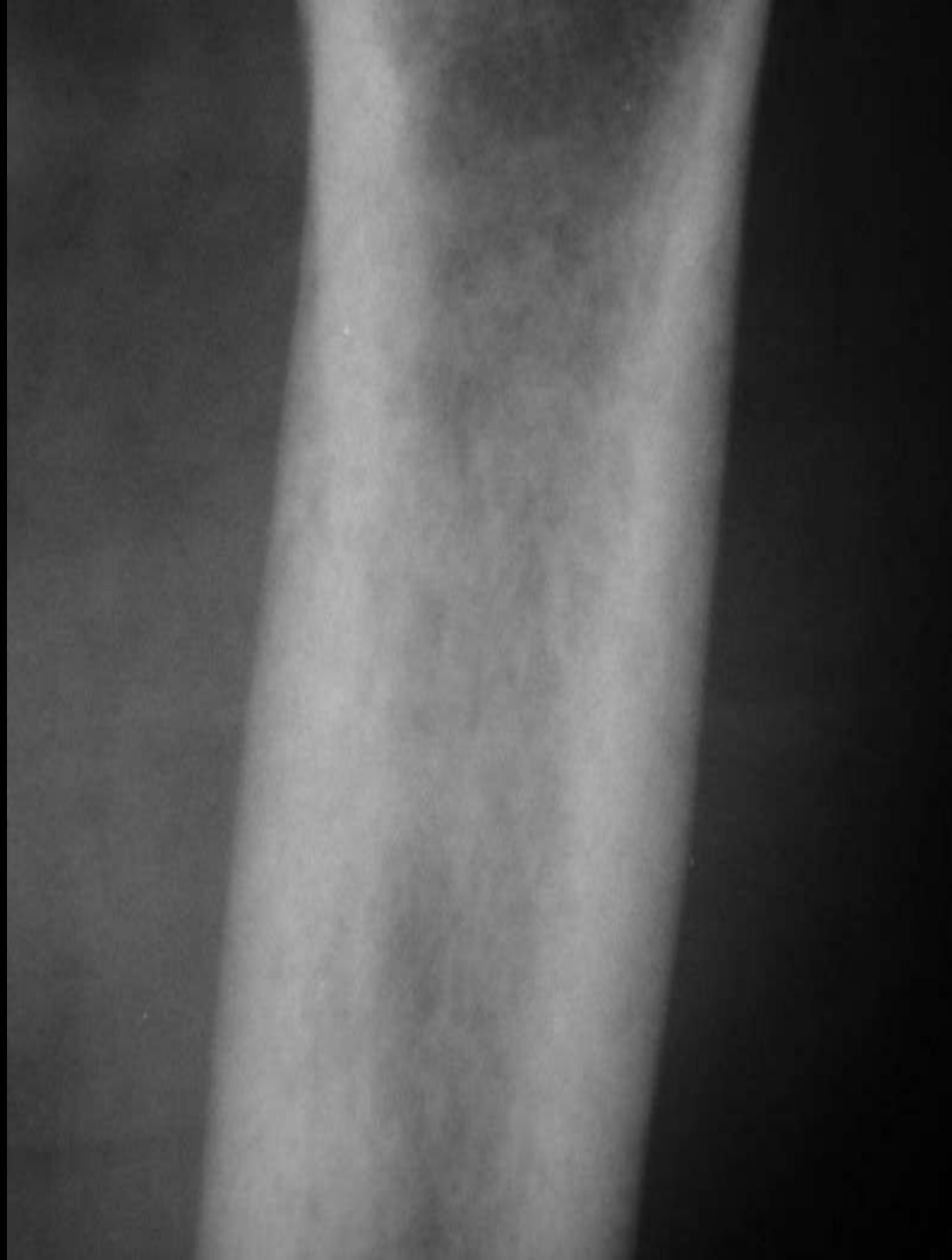





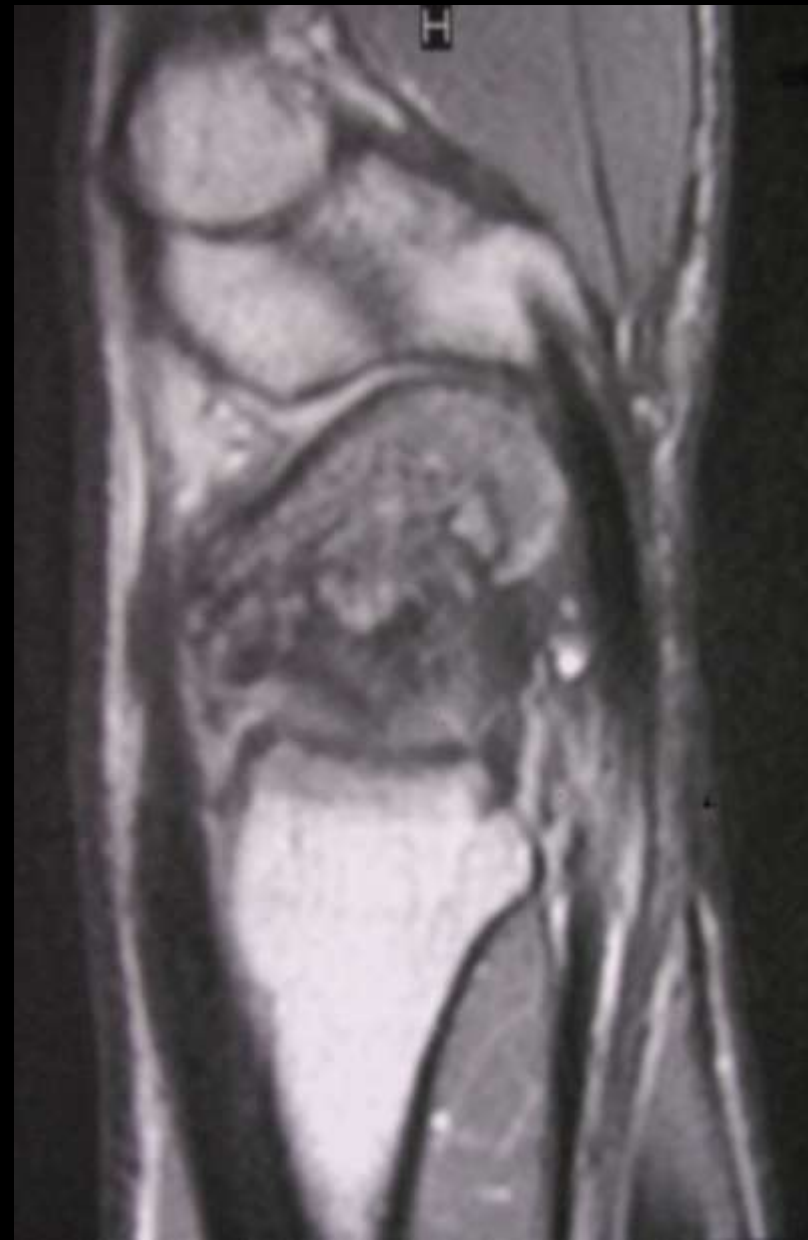Celery stalk sign

Congenital Rubella





# Humpback deformity Scaphoid malunion



© Mik Wilkens 1992



# Hourglass sign

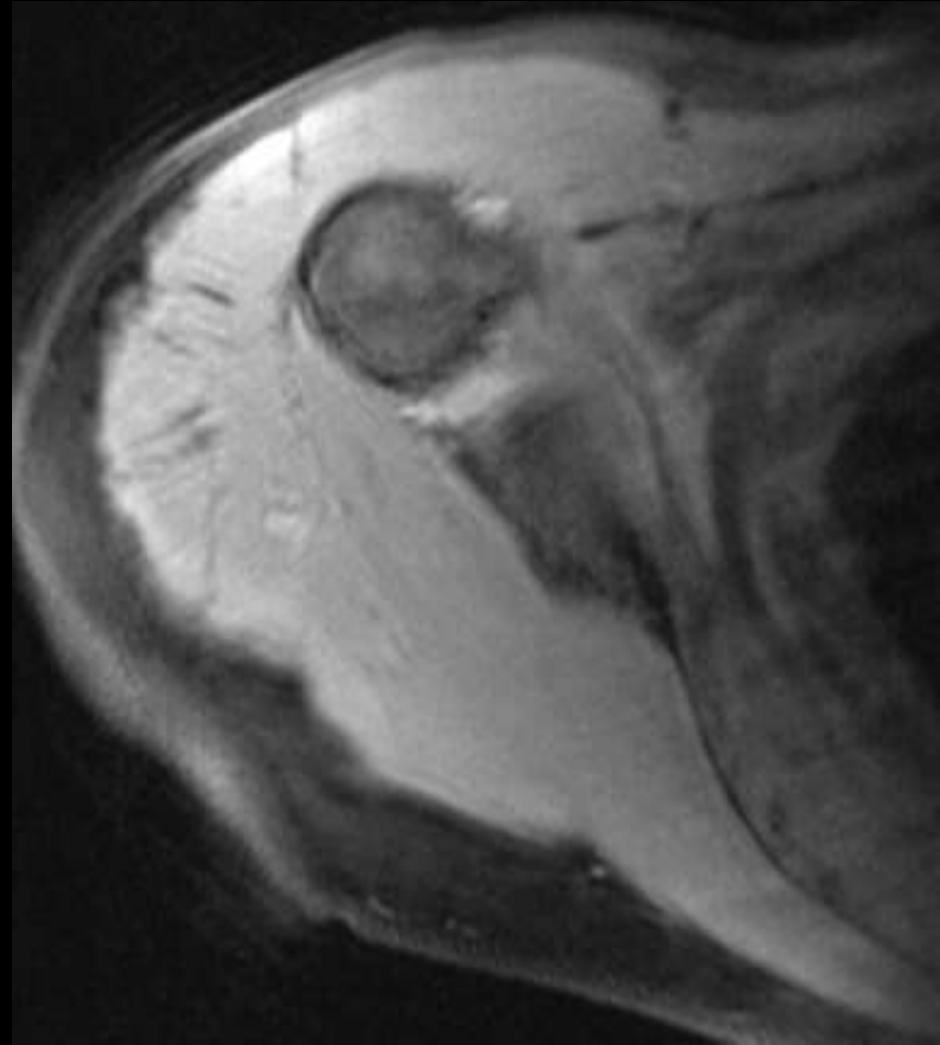
Tapered biceps in bicipital groove





# Popeye sign

## Torn long head of biceps







# Bell Clapper

## Muscle tear in hematoma



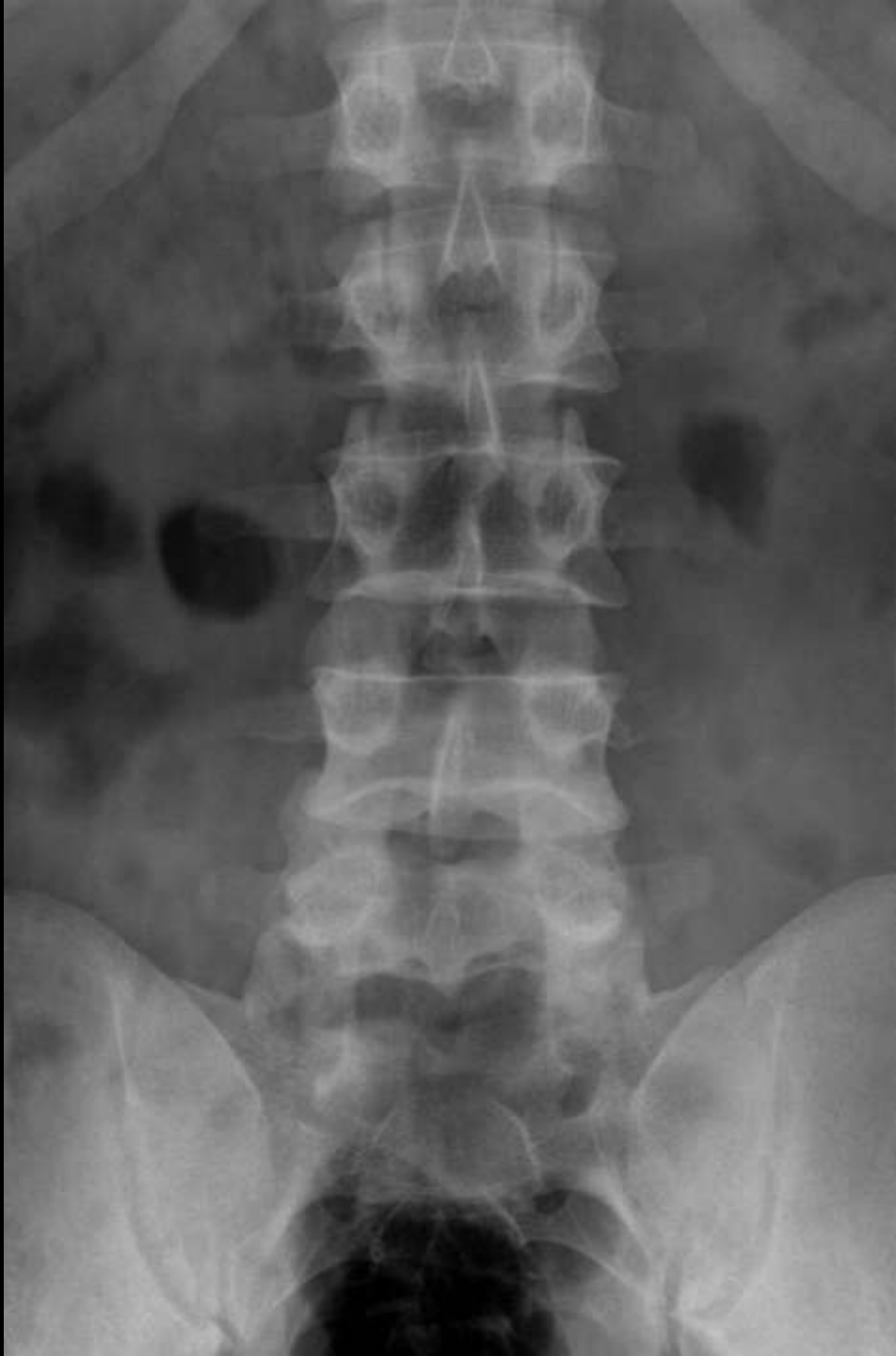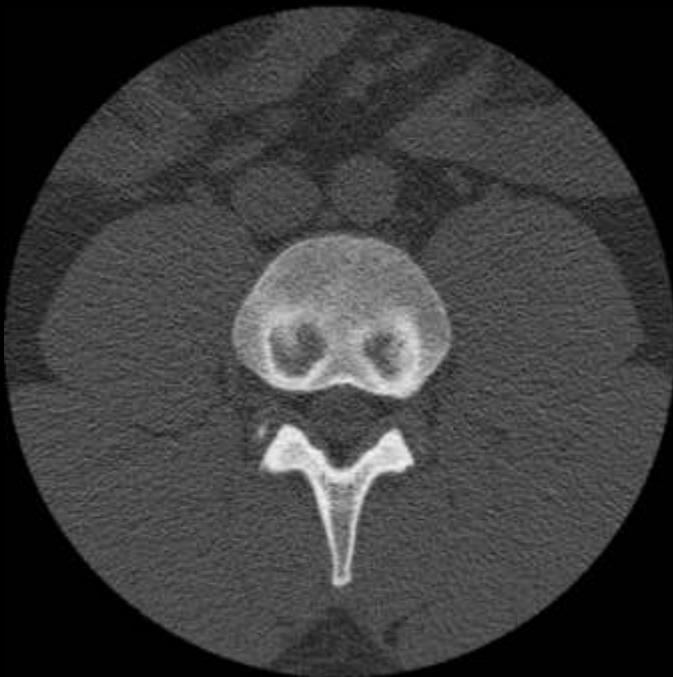Spilt tea sign





# Cupids bow sign Normal vertebrae

93





# Fireman's hat sign

## Discogenic hemispherical sclerosis







# Sagging rope sign

## Legg Calve Perthes



# Trolley tract sign Ankylosing Spondylitis



# Shinny corner sign Ankylosing spondylitis



# Opera glass Psoriasis





# Opera glass

## Multicentric reticulohistiocytosis



# Bayonet deformity

## Clavicle fracture



Accordian hand

RhA

SLE

MCRH



# Button osteophyte

## Osteoarthritis





# Mickey Mouse sign Pagets disease of spine with NM



# Mickey Mouse sign Psoriasis



# Curtain osteophyte