



The thumb: anatomy and pathology with a focus on the CMC and MCP joints

Teddy Su

14 April 2016



- Congratulations to the 2015-2016 Golden State Warriors!
- Record 73 wins
- Stephen Curry record 402 three point baskets in one season



- Congratulations on retirement!

UCSD bone fellow, beginning of fellowship



Outline

- CMC = Trapeziometacarpal joint (TMC) anatomy
- TMC joint common injuries
- TMC osteoarthritis and treatment with specific attention to LRTI (ligament reconstruction and tendon interposition)
- MCP joint anatomy
- MCP joint common injuries
- pulley system and trigger thumb anatomy and pathology
- Other miscellaneous thumb pathology

The thumb

- “In the absence of any other proof, the thumb alone would convince me of God’s existence” – Sir Isaac Newton
- Humans are the only ones with fully opposable thumbs
- **Power grip** -- gripping a hammer, doing a pull up, wielding a club
- **Precision grip** – fingertips and thumb press against each other, like writing with a pen, opening a jar with fingertips alone
- Although other primates have opposable thumbs, few have precision grip, only in degrees significantly more restricted

The thumb

- Latest issue in the journal Nature has shown that a new species, “**Felidae**” has a usable thumb



The thumb

The maximum compensation for one

Thumb

in

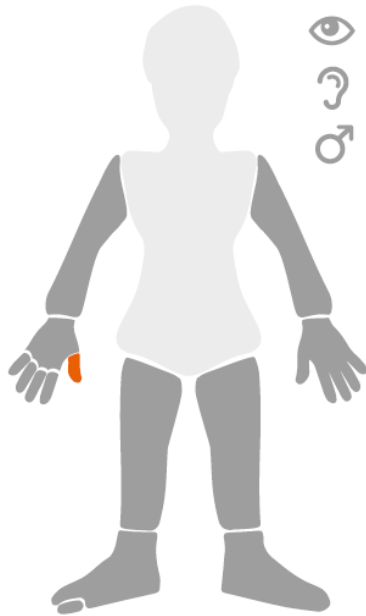
California

is

\$42,050

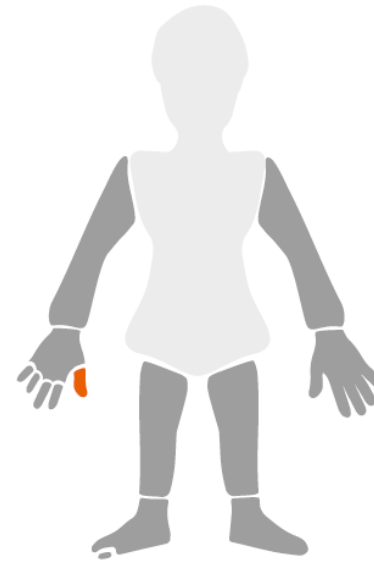
National Average

\$42,432



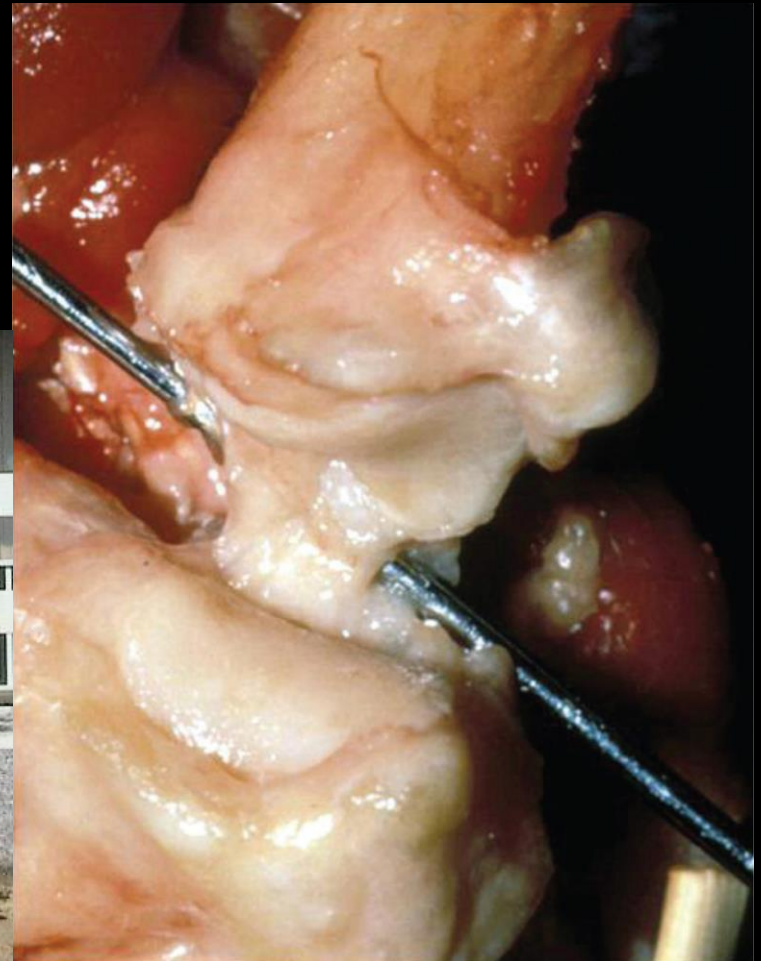
California

\$42,050



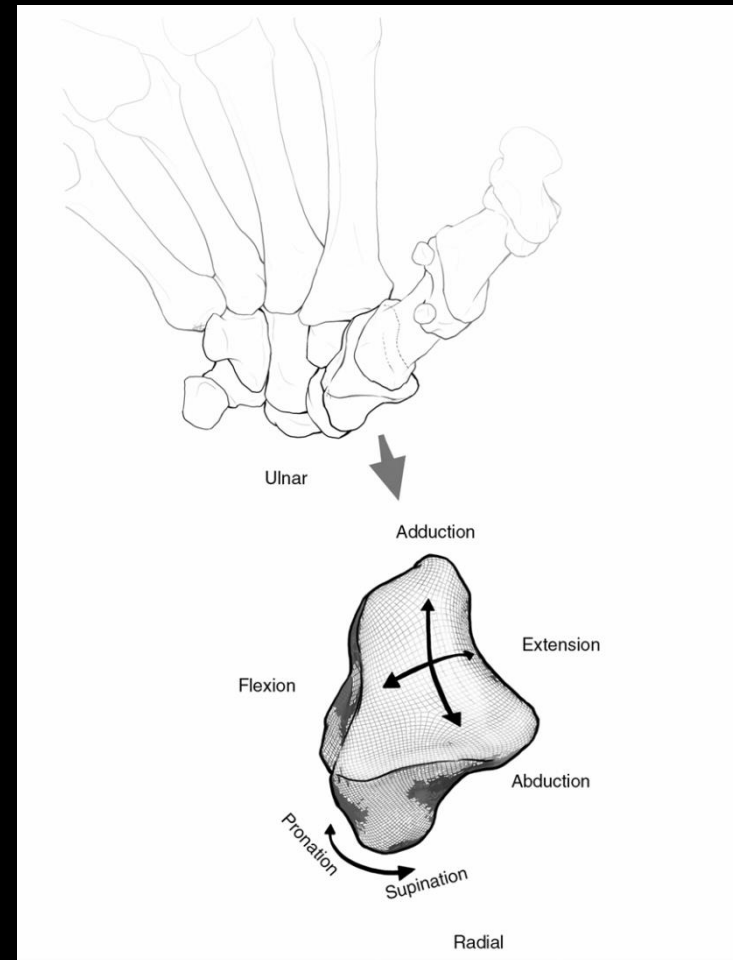
Thumb anatomy—TMC joint

- Note convex radioulnar and concave dorsoradial arc of 1st MC base



TMC joint anatomy

- paradoxical demands of stability and mobility
- Unique concavo-convex saddle design allowing various motions
- disparate radii of curvature
- lax at rest, congruent at extremes of motion



TMC joint anatomy

- Recent hand surgery literature (Ladd 2012) indicates 7 principle ligaments, previously as many as 16 ligaments identified (Bettinger)
- **Dorsal:**
 - Dorsal radial ligament (DRL)
 - Dorsal central ligament (DCL)
 - Posterior oblique ligament (POL)
- **Volar:**
 - Anterior oblique ligament (AOL)
 - Ulnar collateral ligament (UCL)
- **Ulnar:**
 - First dorsal trapeziometacarpal ligament (DTM 1)
 - Intermetacarpal ligament (IML)

TMC joint anatomy

- 5 of the ligaments recognized as most important in the radiology literature (Cardoso 2009, Hirschmann 2013)
- **Dorsal:**
 - Dorsal radial ligament (DRL)
 - Posterior oblique ligament (POL)
- **Volar:**
 - Anterior oblique ligament (AOL)
 - Ulnar collateral ligament (UCL)
- **Ulnar:**
 - Intermetacarpal ligament (IML)

TMC joint anatomy: AOL

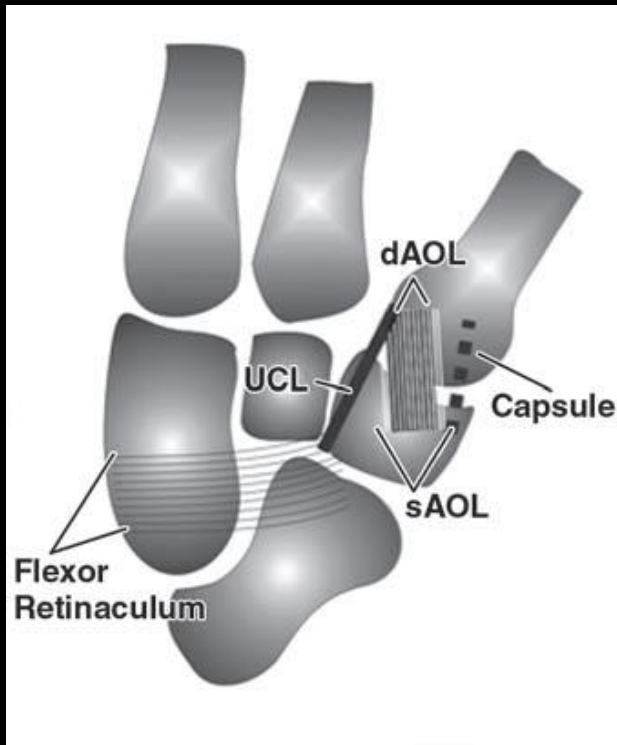
- two parts
- **Superficial AOL (sAOL)**: capsular
- sAOL origin: volar tubercle of trapezium 0.5 mm proximal to articular surface
- sAOL attachment: volar **beak** of first metacarpal base 2 mm distal to articular margin
- Wraps volar aspect of TMC in a “curtainlike” fashion

TMC joint anatomy: AOL

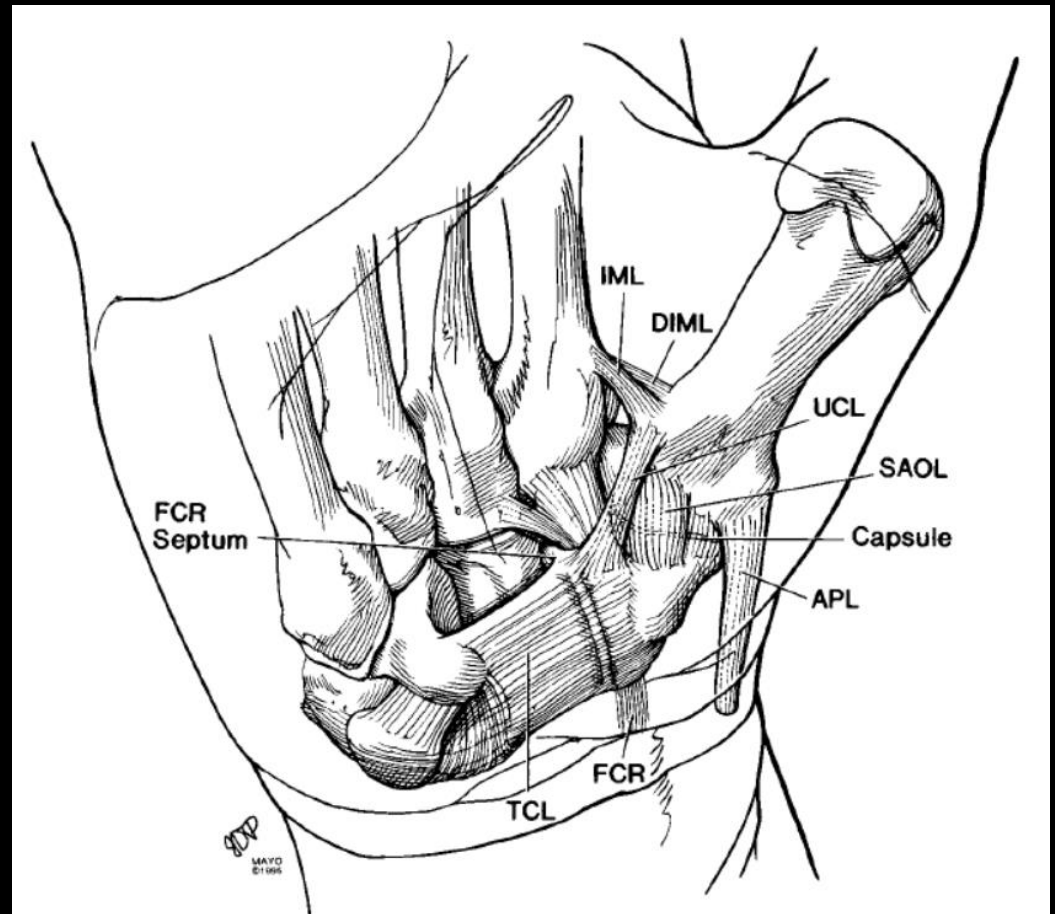
- **Deep AOL (dAOL):** intracapsular, just deep to the sAOL, “beak ligament”
- Best seen on sagittals
- Runs diagonally from proximal radial to distal ulnar
- 2 components not distinguishable by MRI
- Stabilizes against volar subluxation
- Zhang et al (Journal of Wrist Surgery 2013), on arthroscopy (5 specimens), did not find convincing evidence that these were two separate structures—proposed calling this the AOL complex
- Ladd et al (JBJS 2012) studied 30 specimens, found the dAOL only 3 times

TMC joint anatomy: AOL

- Volar view



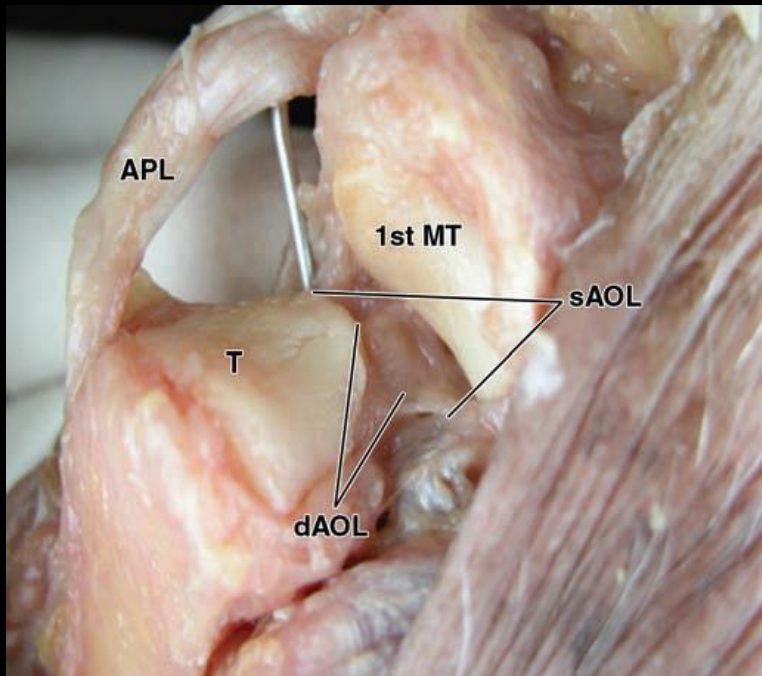
Cardoso et al. AJR 2009



Bettinger et al. Journal of Hand Surgery 1999

TMC joint anatomy: AOL

- Dorsal view (right)
- Dorsoradial (below)



Cardoso et al. AJR 2009

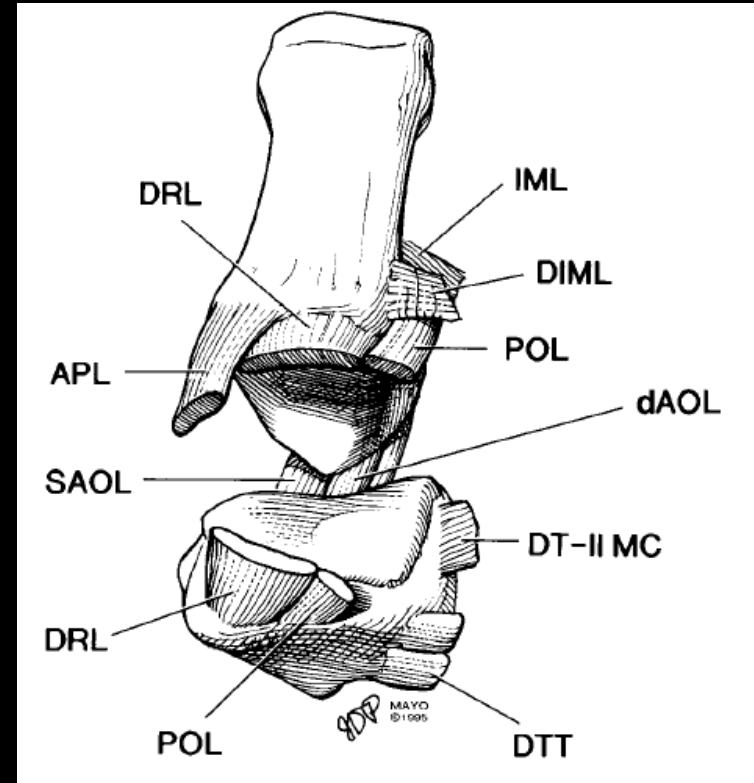
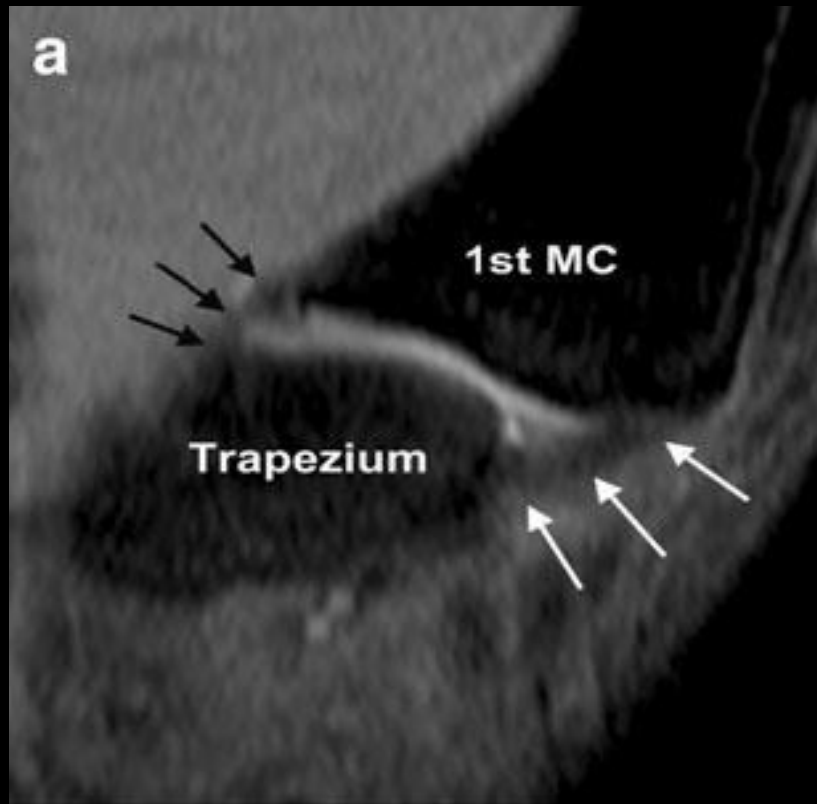


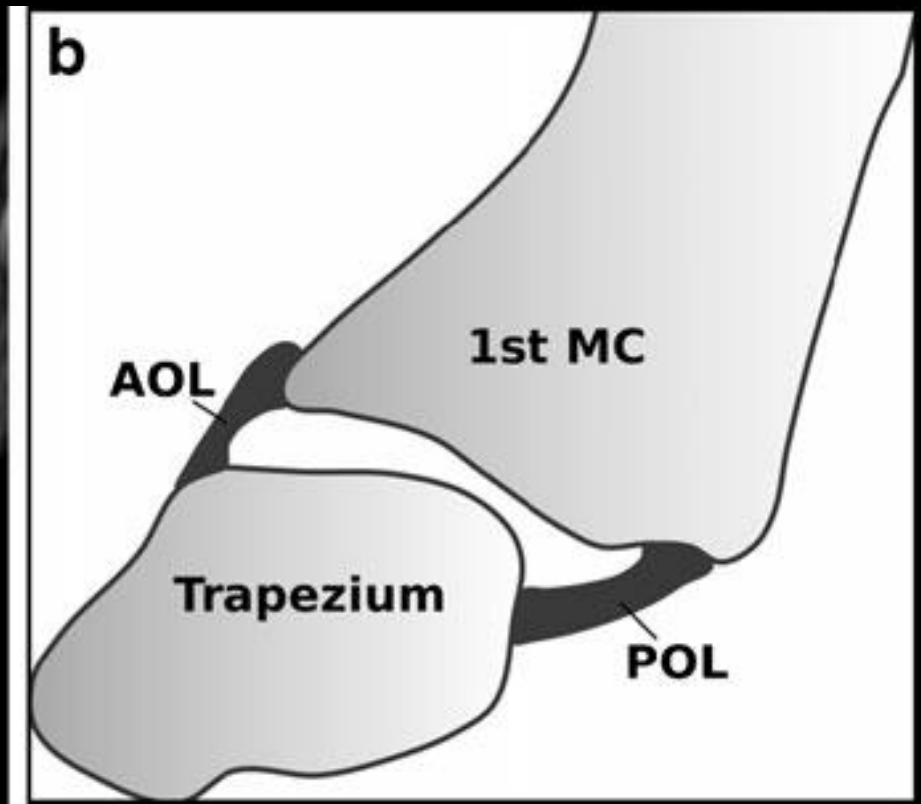
Figure 3. The TMC joint has been hinged open from the dorsum to reveal the dAOL (beak ligament) lying within the joint just ulnar to the volar tubercle of the metacarpal. (Used by permission of Mayo Foundation.)

Bettinger et al. Journal of Hand Surgery 1999

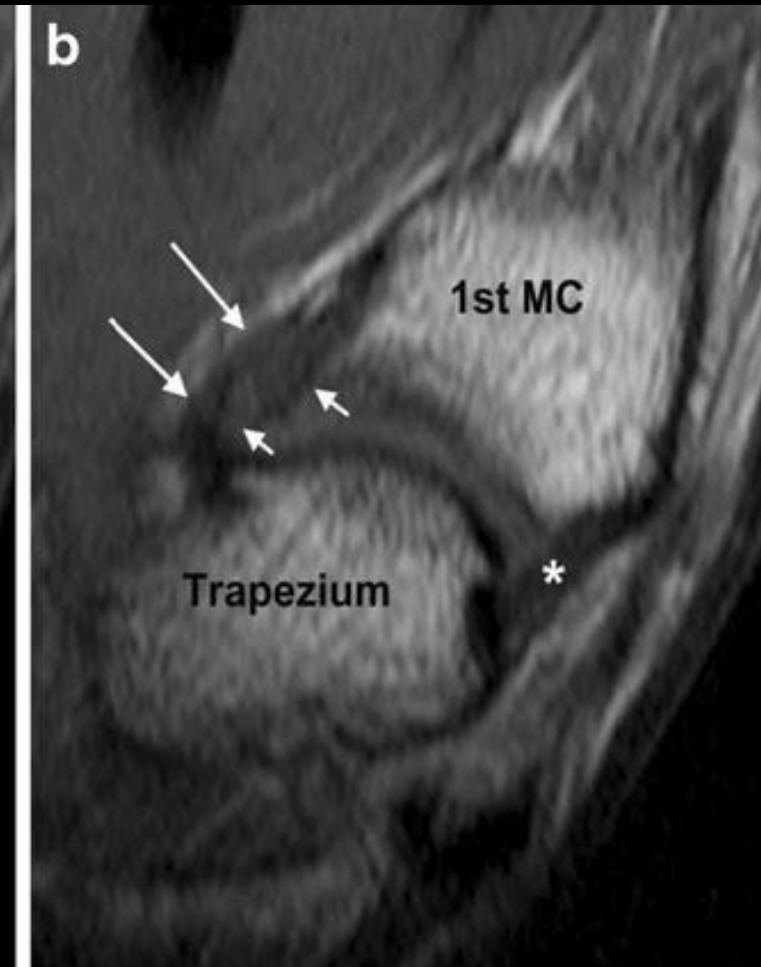
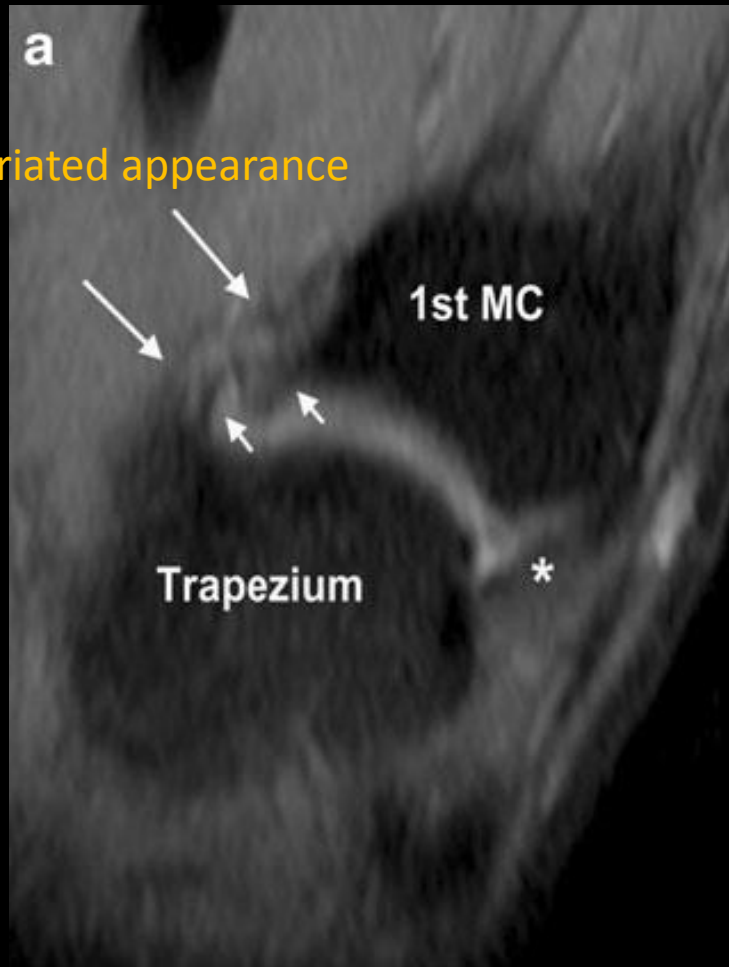
TMC joint anatomy: AOL



Sagittal intermediate-weight FS

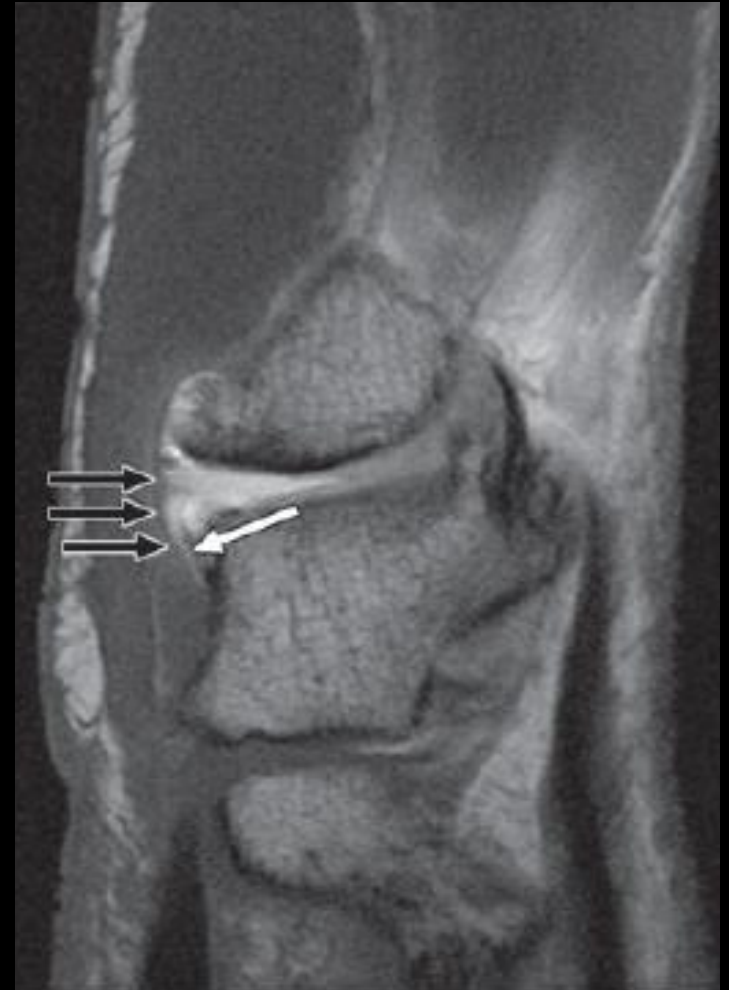

TMC joint anatomy: AOL



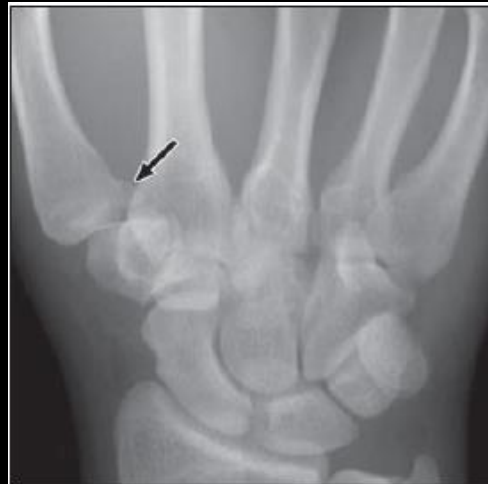TMC joint anatomy: AOL

- Sagittal T2, dAOL torn (white arrow), sAOL (black arrows)

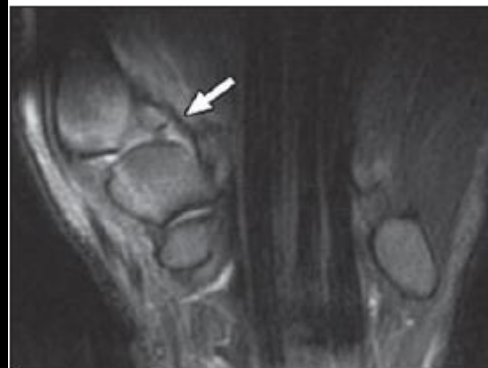


TMC joint anatomy: AOL

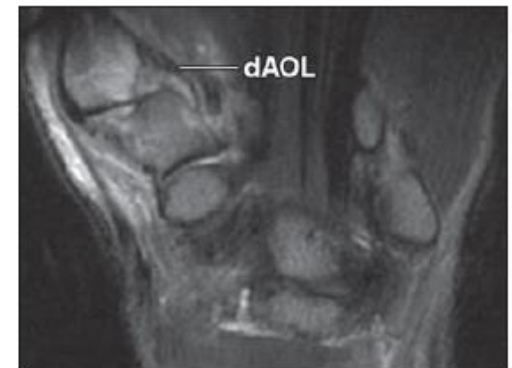
- Bennett fracture
- Note intact dAOL



A



B



C

Fig. 9—26-year-old man who presented with Bennett fracture after fist fight.

A, Radiograph shows typical oblique fracture (*arrow*) of volar lip of first metacarpal base.

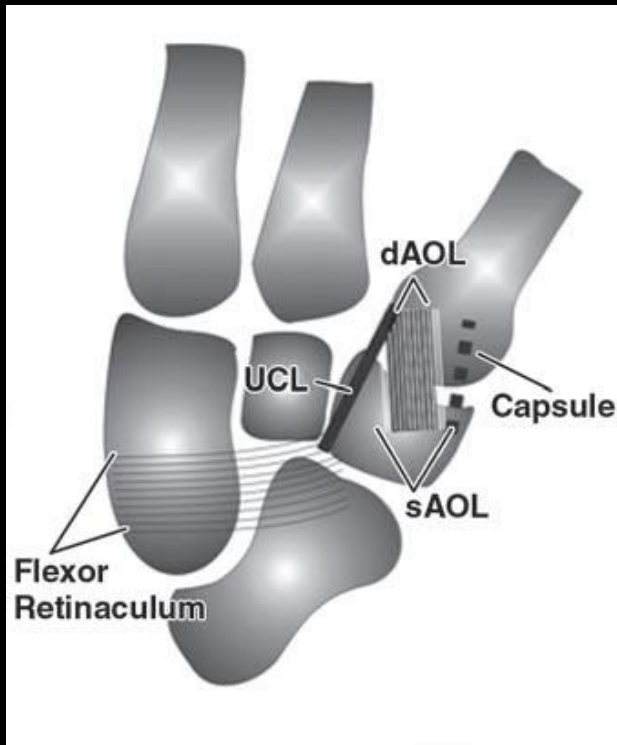
B and C, Consecutive coronal T2-weighted MR images (TR/TE, 2,000/80) show volar fracture fragment remains attached to trapeziometacarpal joint by deep anterior oblique ligament (*arrow*, B). Deep anterior oblique ligament (dAOL) anchors volar lip of first metacarpal to trapezium. Small amount of fluid can also be detected.

TMC joint anatomy: UCL

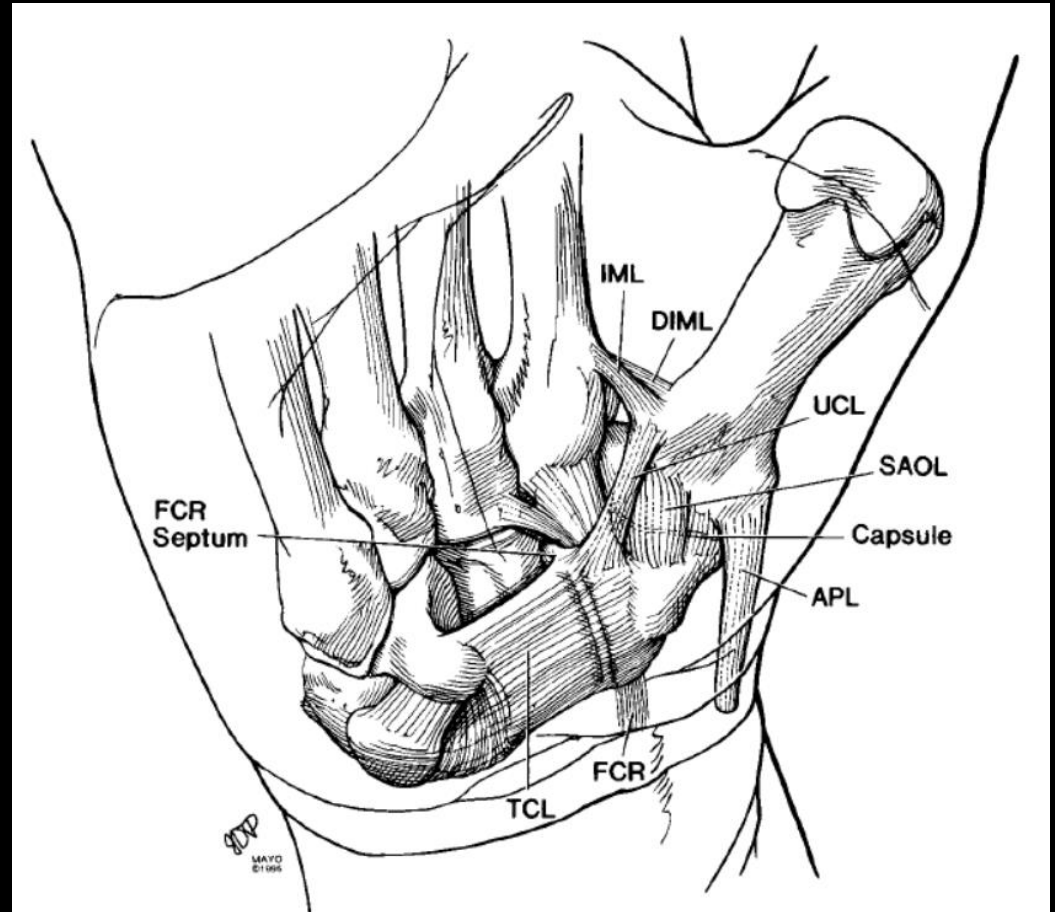
- In hand surgery literature aka first volar trapeziometacarpal ligament (VTM1)
- Origin: **distal margin of flexor retinaculum** at its ulnar aspect
- Attachment: volar ulnar tubercle of first metacarpal base (along with POL and IML), **superficial and ulnar to sAOL** (typically overlaps sAOL by 2-3 mm)
- Extracapsular
- Best seen on coronals

TMC joint anatomy: UCL

- Volar view



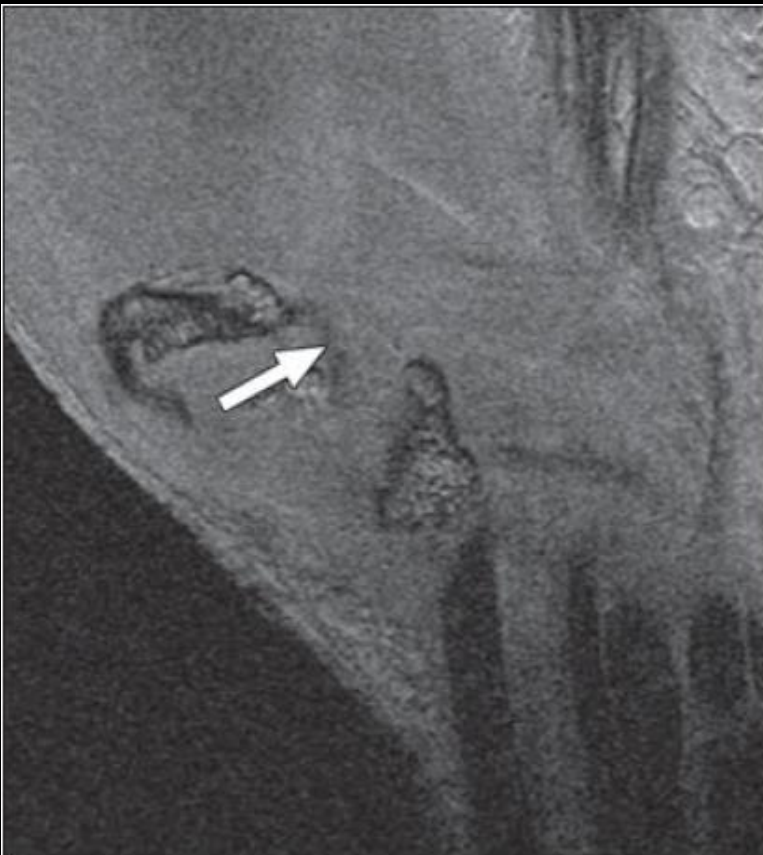
Cardoso et al. AJR 2009



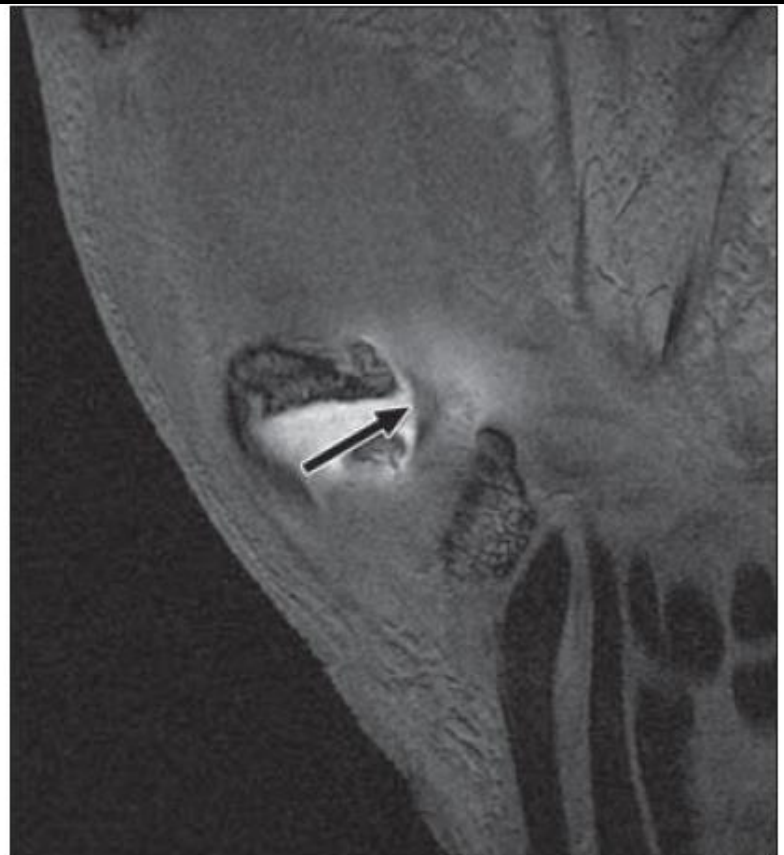
Bettinger et al. Journal of Hand Surgery 1999

TMC joint anatomy: UCL

- Before (left) and after (right) arthrography



A

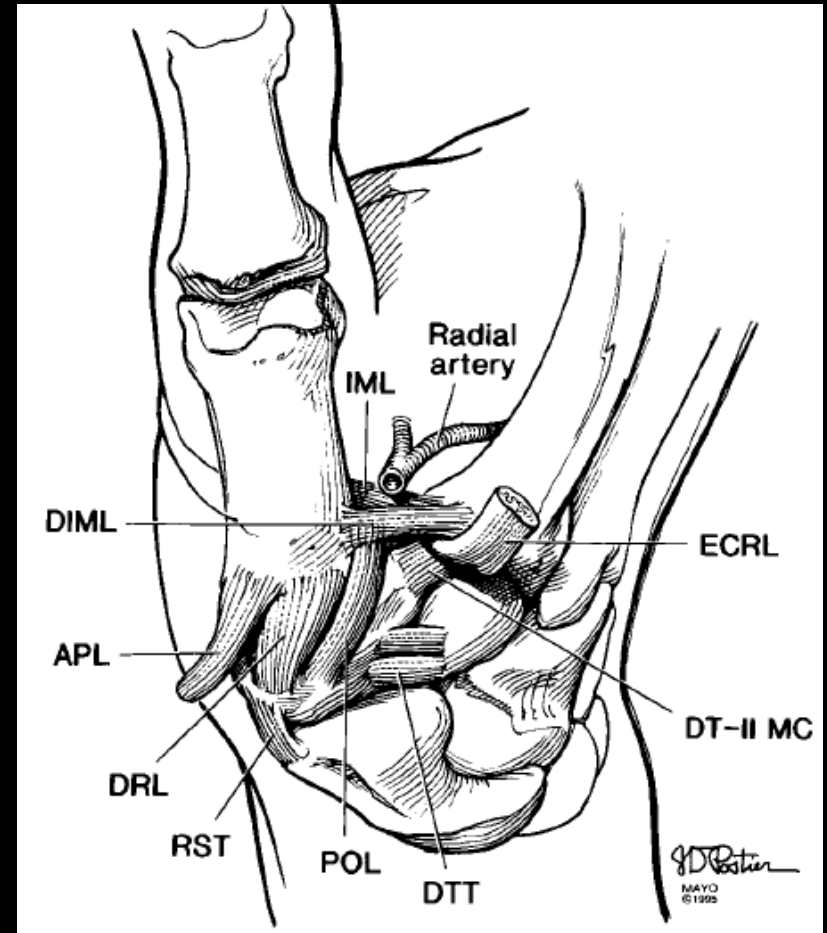
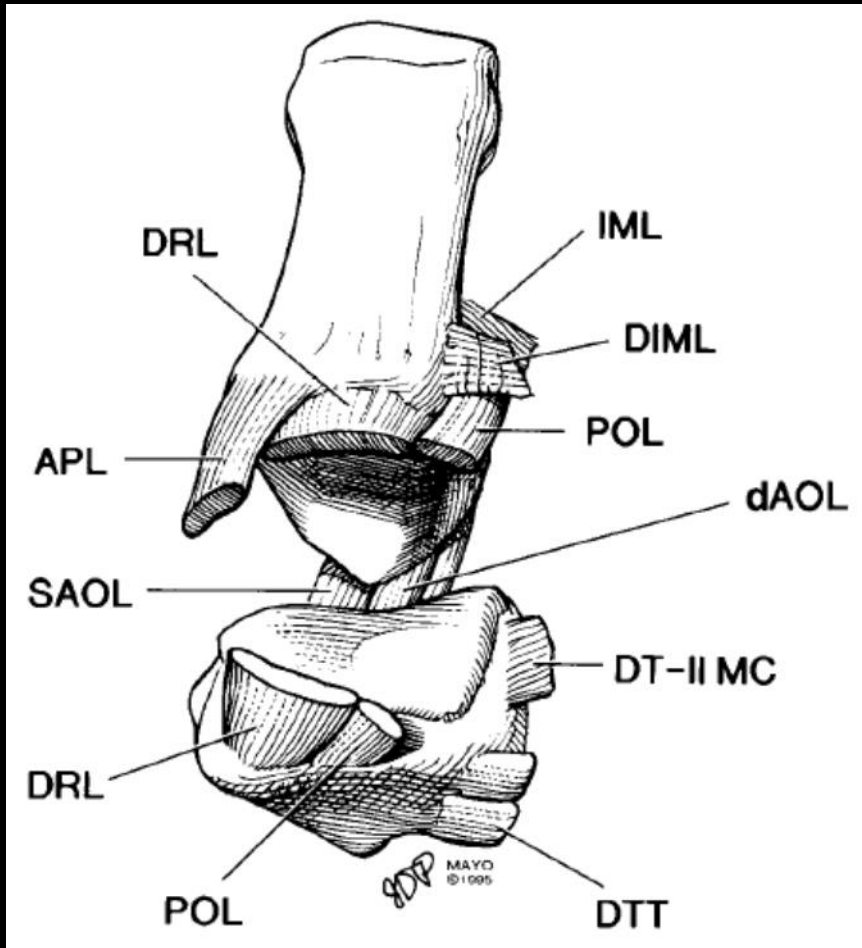


B

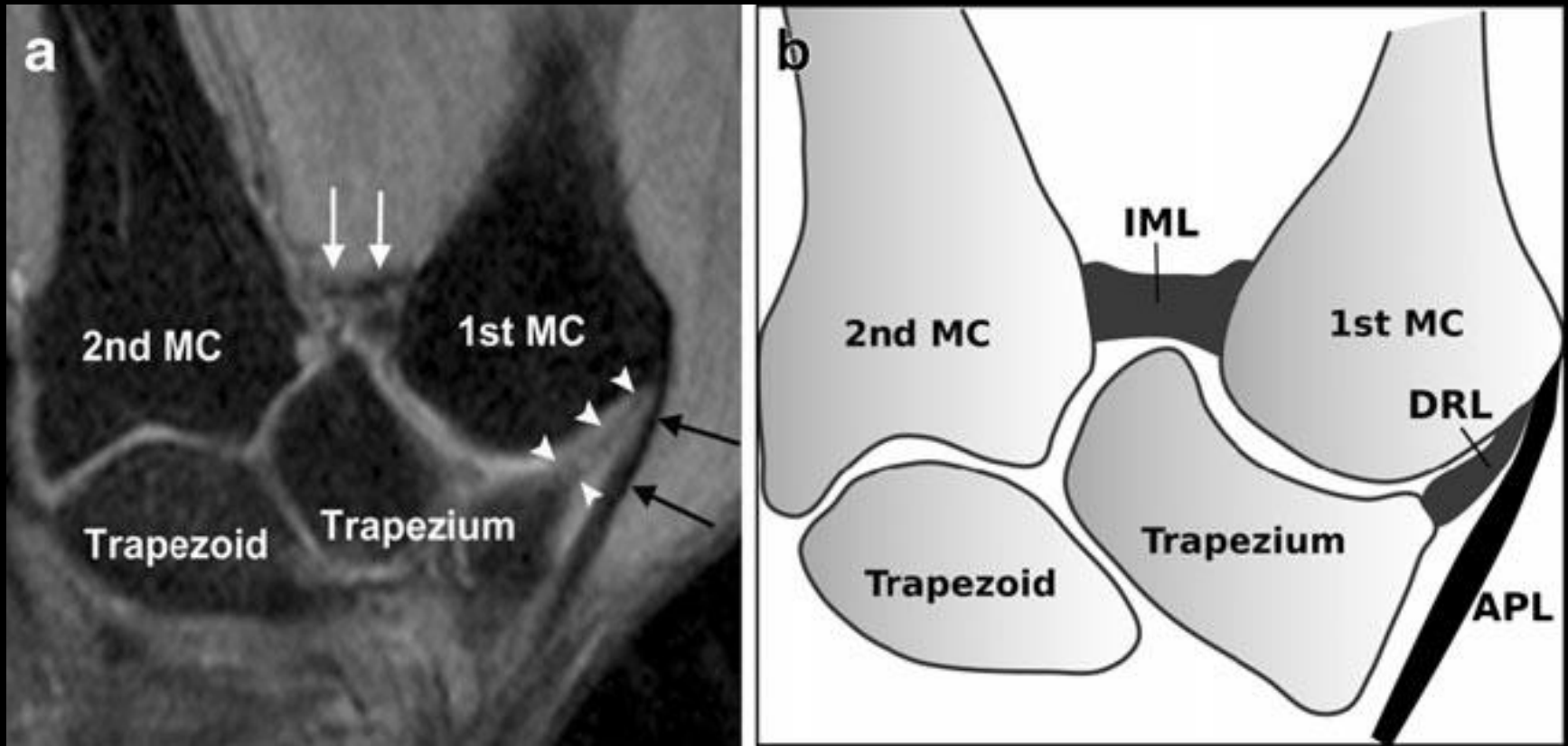
TMC joint anatomy: DRL

- Origin: dorsoradial tubercle of trapezium (adjacent to POL)
- Attachment: broadly inserts on dorsal edge of first metacarpal base
- Capsular
- Best seen on sagittals
- Thickest, widest ligament that attaches to trapezium with exception of flexor retinaculum (aka transverse carpal ligament)
- Together with POL forms “dorsal ligament complex”
- Considered primary restraint to dorsal dislocation, so disruption will lead to dorsal subluxation/instability
- (Remember from earlier the AOL stabilizes against volar subluxation/instability)

TMC joint anatomy: DRL



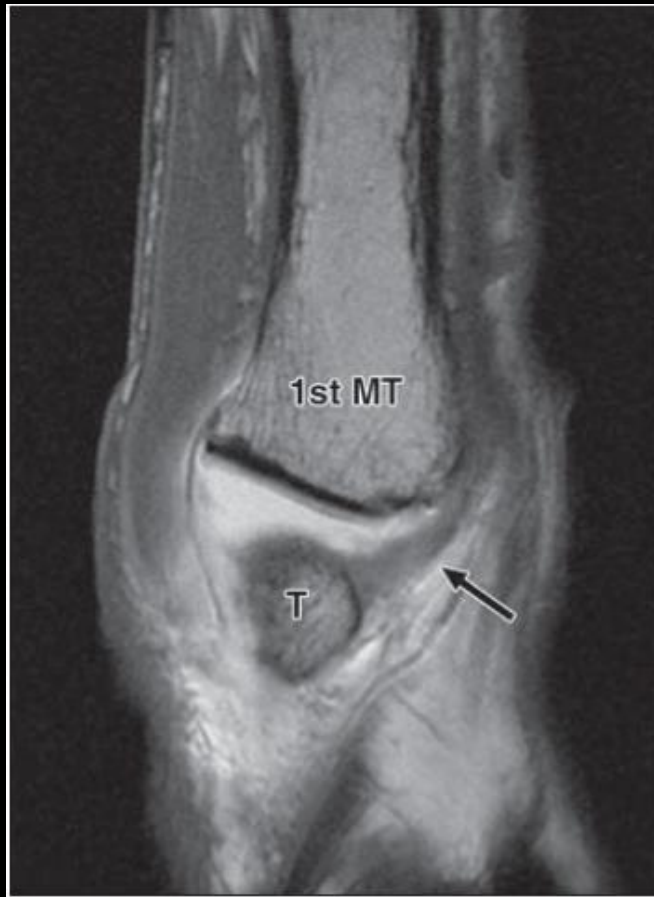TMC joint anatomy: DRL



Coronal intermediate-weight FS

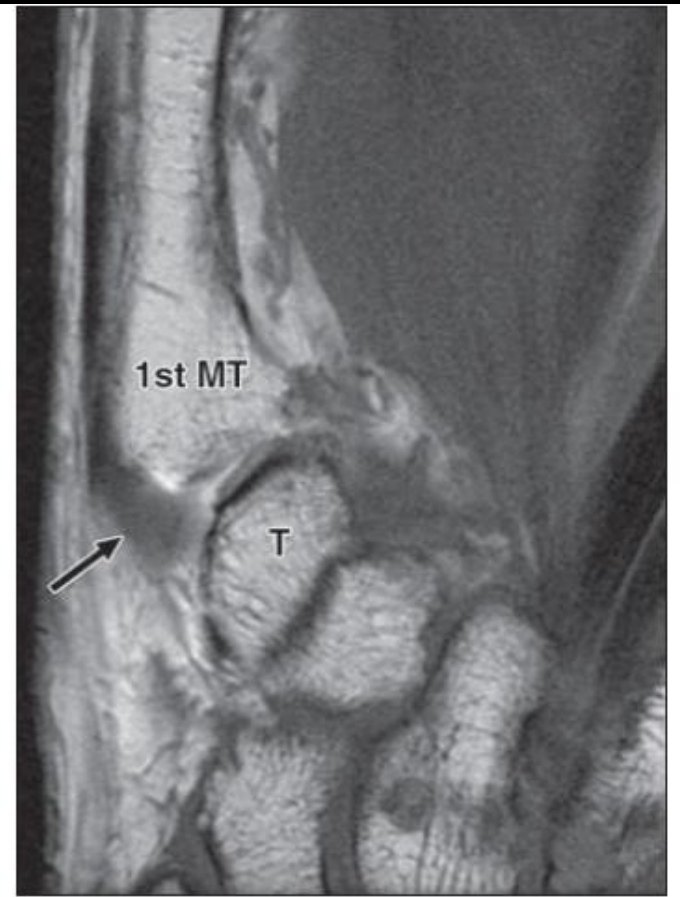
Hirshmann et al. Skeletal Radiology. 2013

TMC joint anatomy: DRL



A

sagittal



B

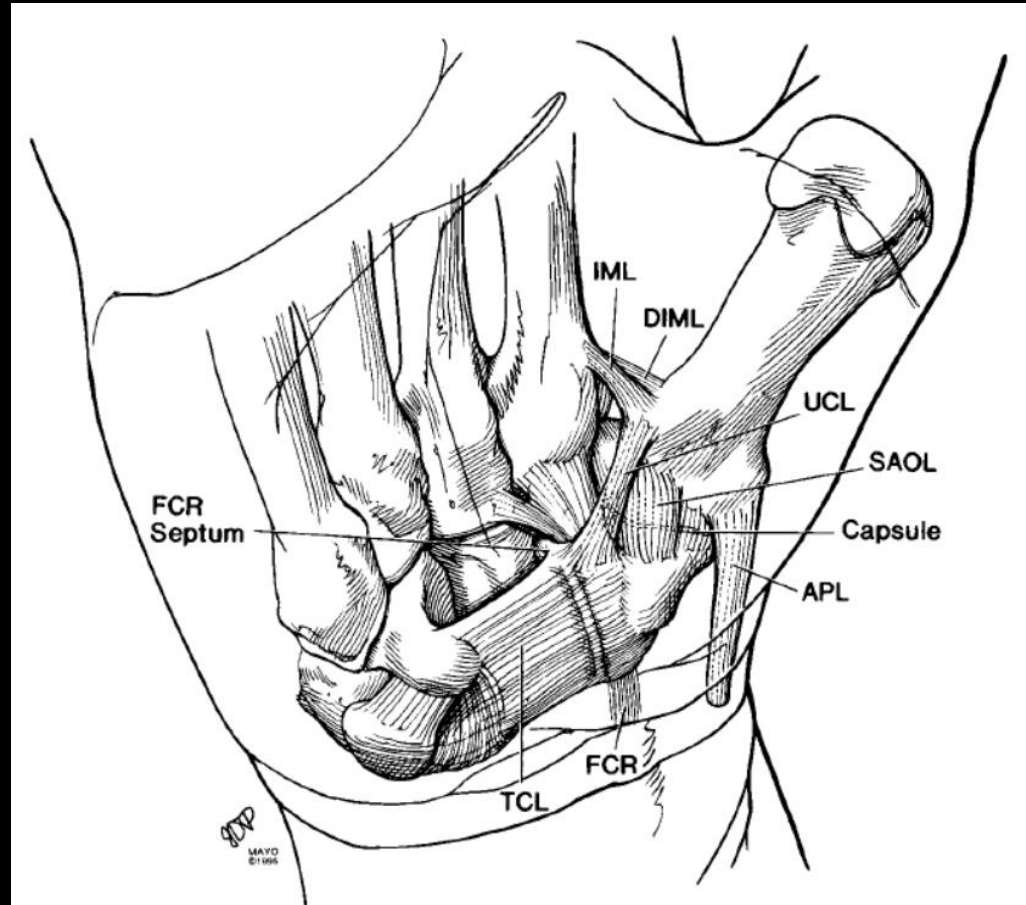
coronal

Cardoso. AJR 2012.

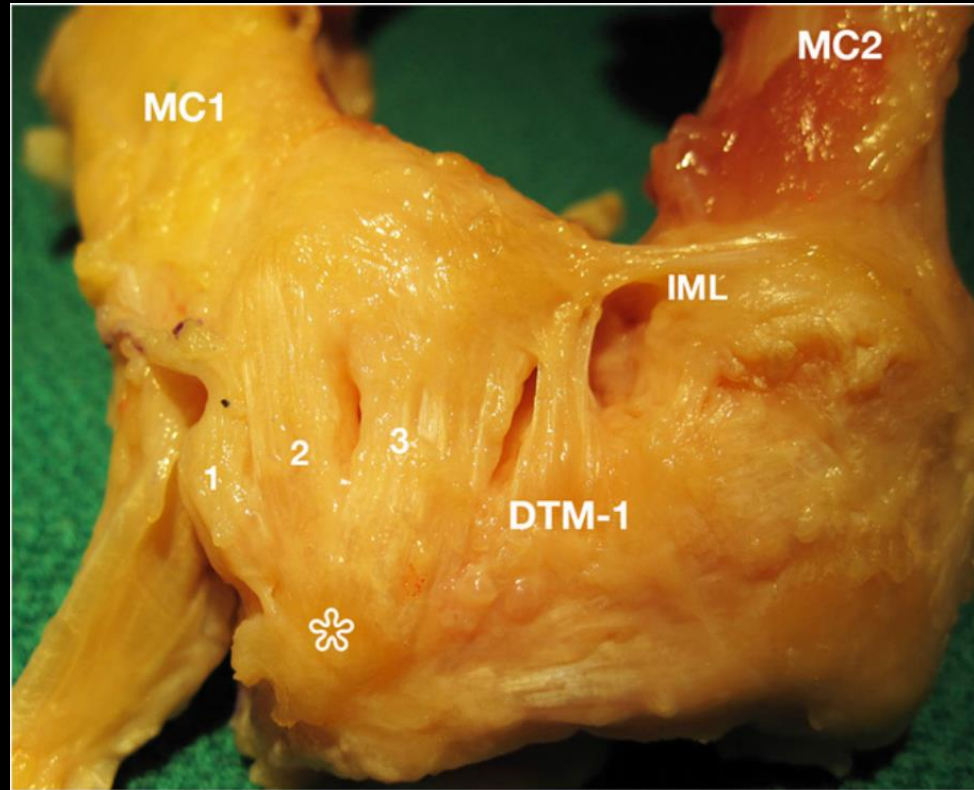
TMC joint anatomy: IML

- Origin: dorsoradial aspect of second metacarpal (radial to extensor carpi radialis longus tendon insertion)
- Attachment: volar ulnar tubercle of first metacarpal base (typically along with POL and UCL)
- Extracapsular
- Best seen on sagittals

TMC joint anatomy: IML

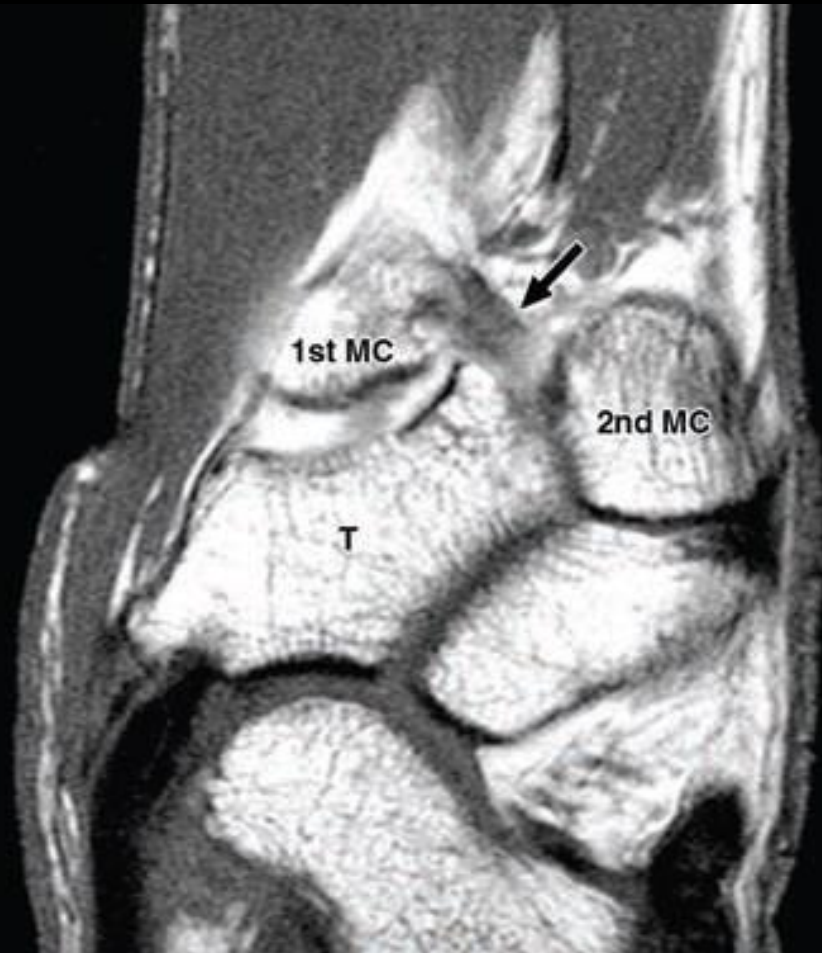


TMC joint anatomy: IML

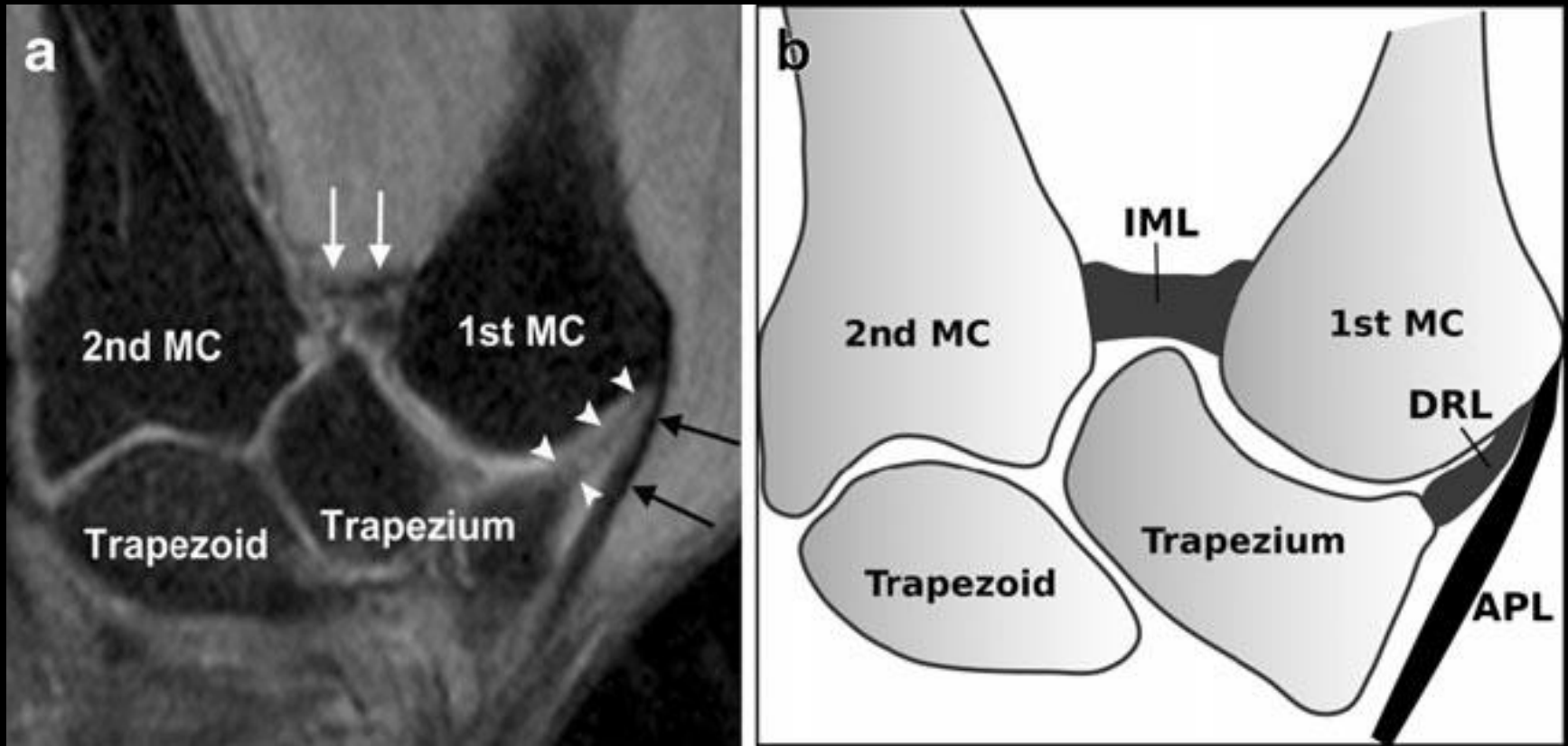


TMC joint anatomy: IML

Sagittal T1



TMC joint anatomy: IML



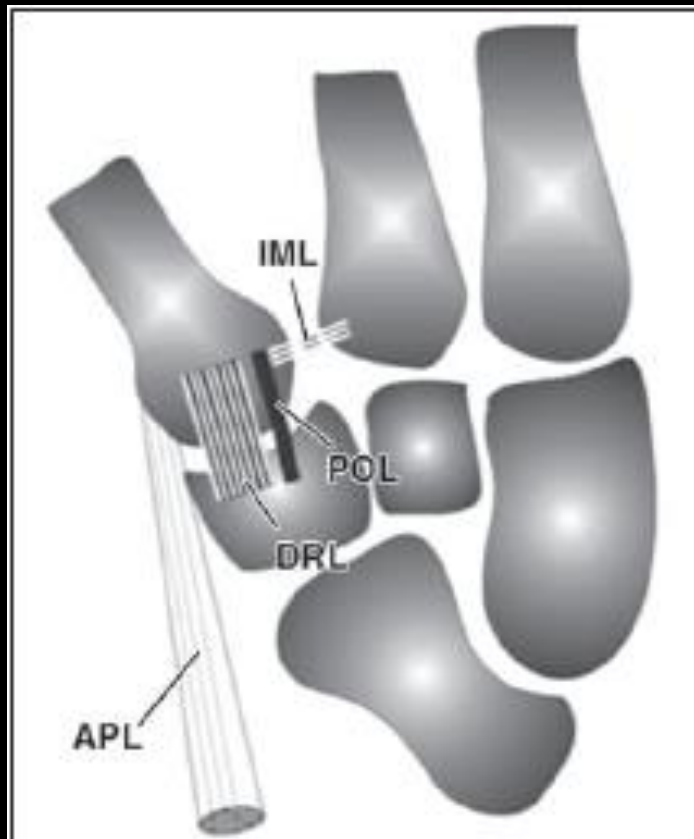
Coronal intermediate-weight FS

Hirshmann et al. Skeletal Radiology. 2013

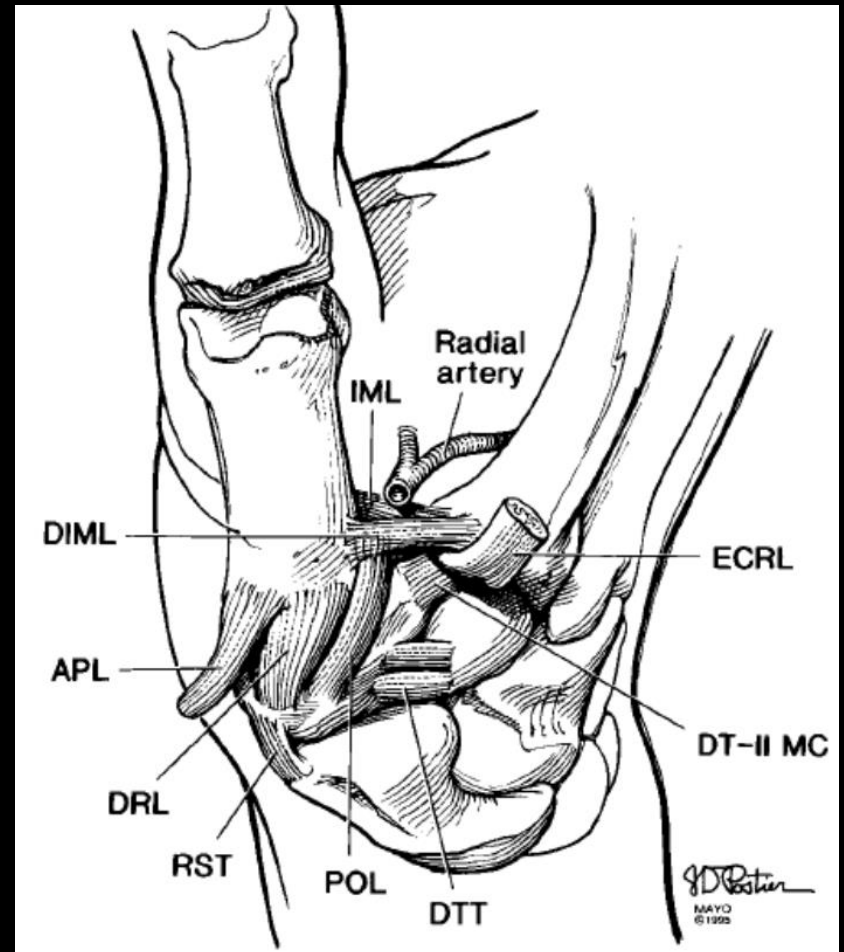
TMC joint anatomy: POL

- Origin: dorsal tubercle of trapezium (dorsoulnar side **immediately adjacent to the DRL**)
- Attachment: dorsal ulnar aspect of thumb (**along with IML**)
- Capsular
- Best seen on sagittals
- Deep to **extensor pollicis longus tendon**

TMC joint anatomy: POL

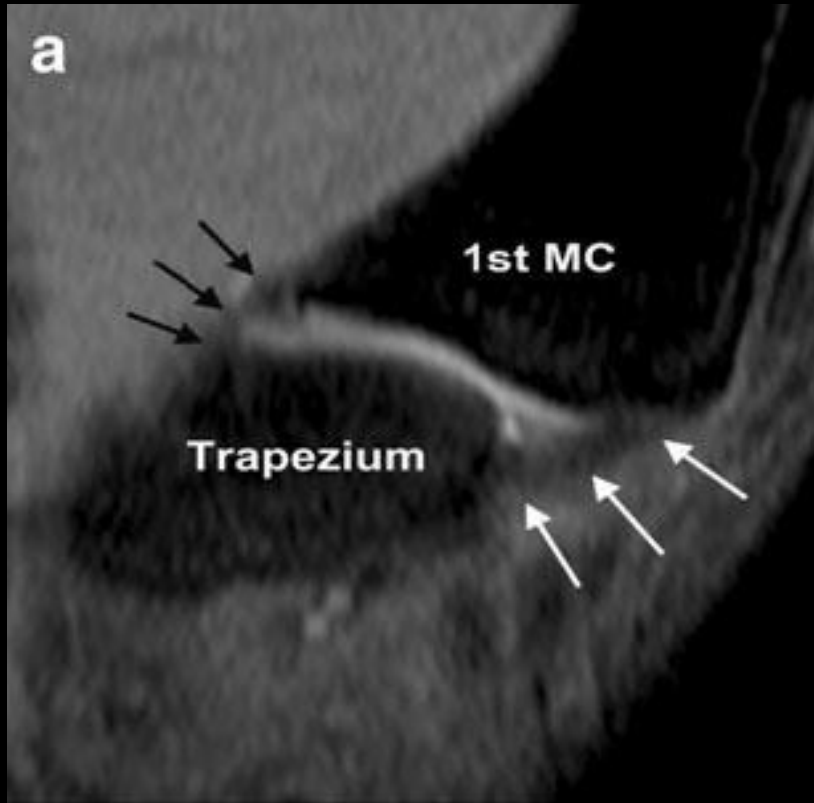


Cardoso et al. AJR. 2009

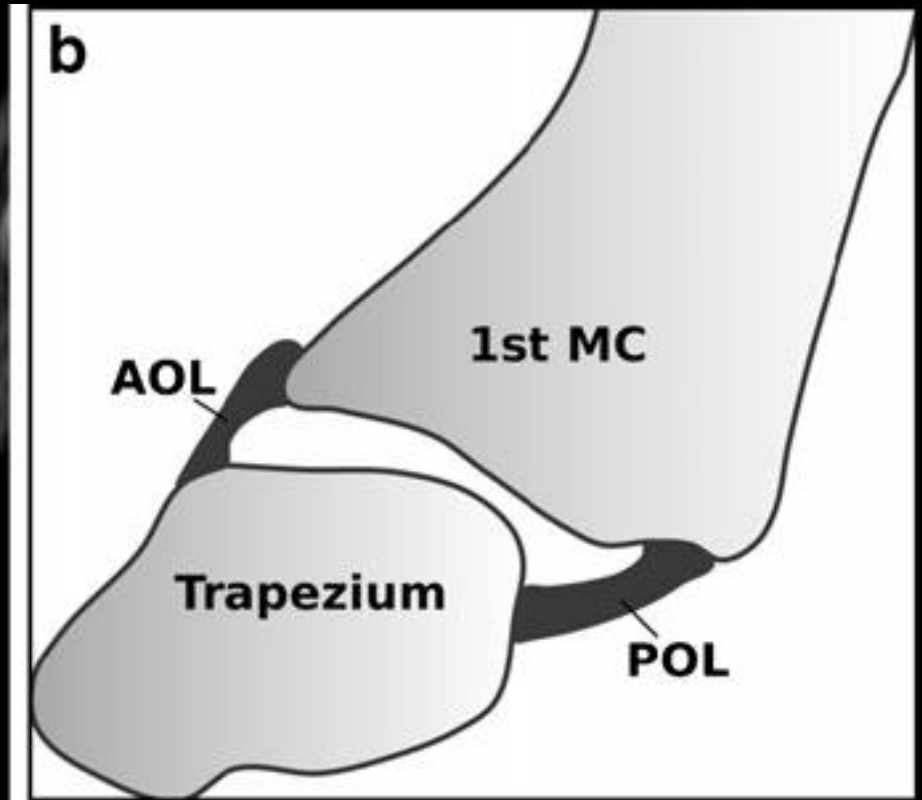


Bettinger et al. Journal of Hand Surgery 1999

TMC joint anatomy: POL

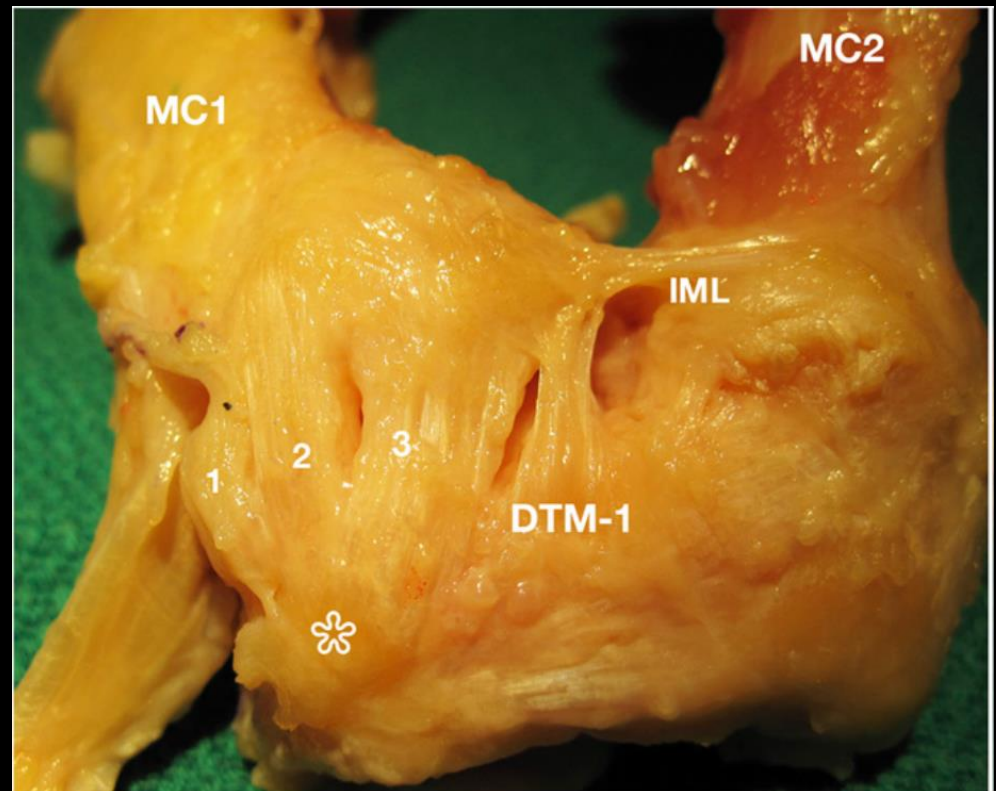


Sagittal intermediate-weight FS



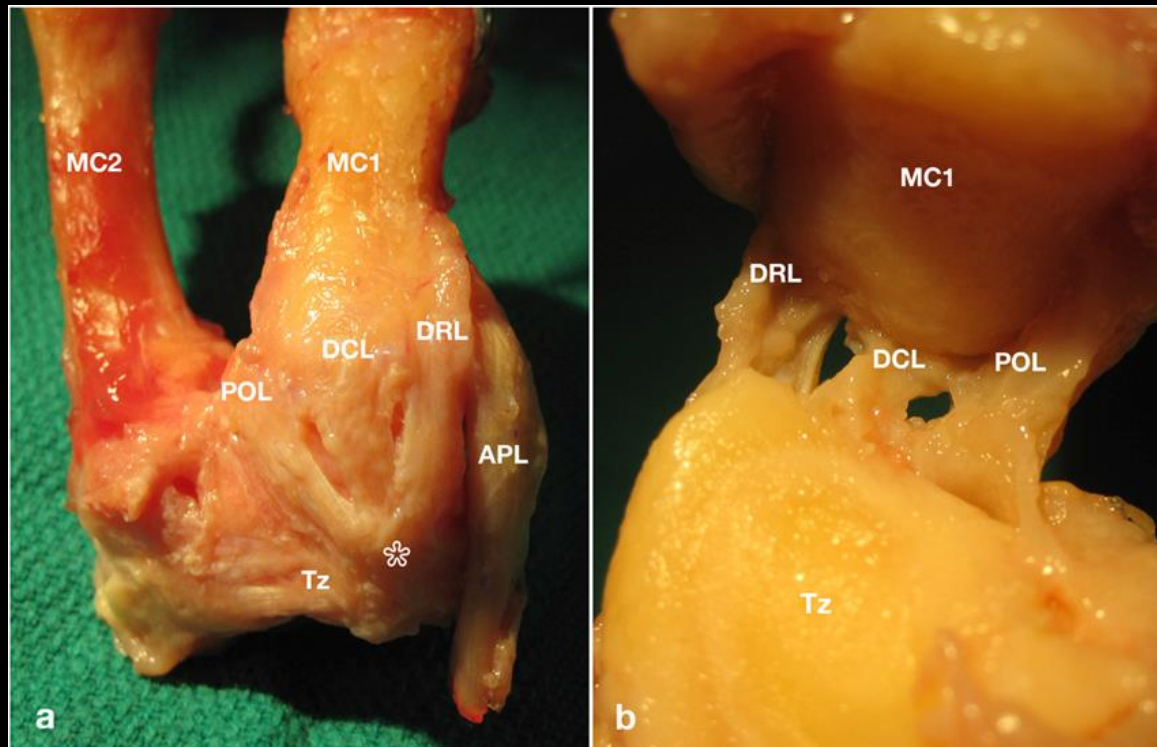
TMC joint anatomy: DCL, DTM1

- DCL between the DRL and POL, together these form the **deltoid ligament complex**
- 1 DRL
- 2 DCL
- 3 POL



TMC joint anatomy: DCL

- Described as the shortest and thickest of ligaments stabilizing the thumb CMC joint
- Left hand, dorsal view on left, volar view on right after



TMC joint: questions

- Thickness of ligaments varies, not necessarily a sign of injury or OA
- Controversy as to which ligament is most important
- Can DRL and POL be consistently distinguished on MRI?
- DCL shortest and thickest
- **Should we use start using the term dorsal ligament complex?
Or dorsal deltoid ligament complex?**

UCSD bone fellow, 6:30 pm at Hillcrest

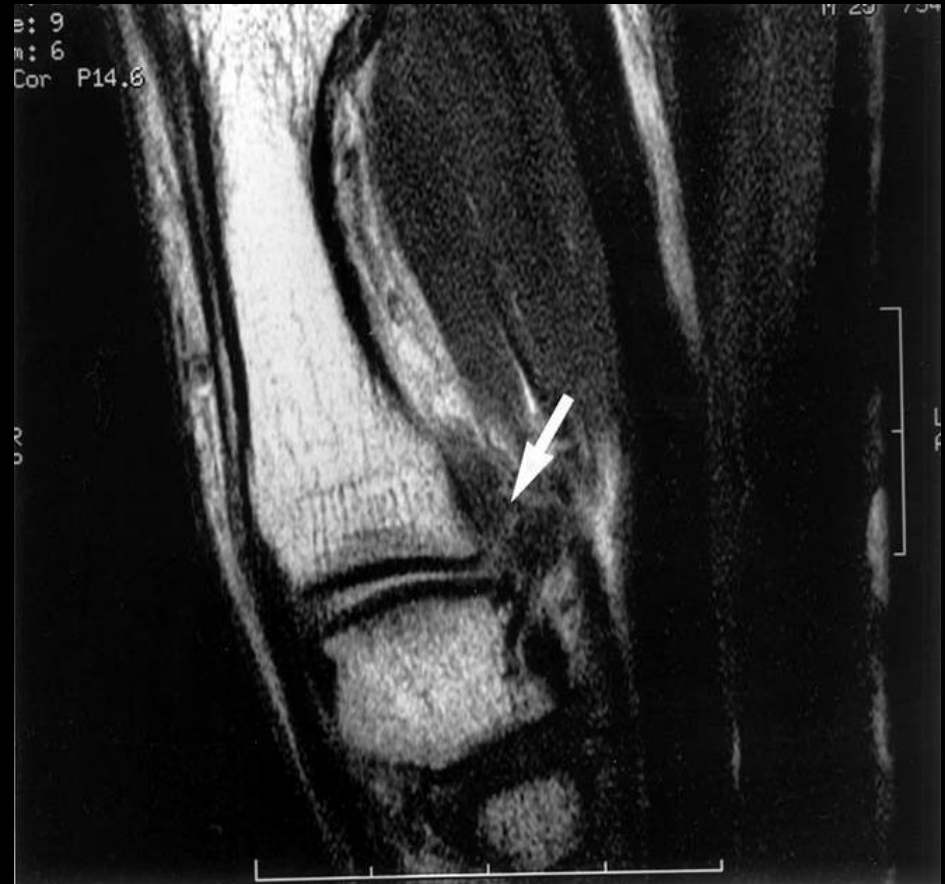

INDIFFERENCE

IT TAKES 43 MUSCLES TO FROWN AND 17 TO SMILE,
BUT IT DOESN'T TAKE ANY TO JUST SIT THERE WITH A DUMB LOOK ON YOUR FACE.

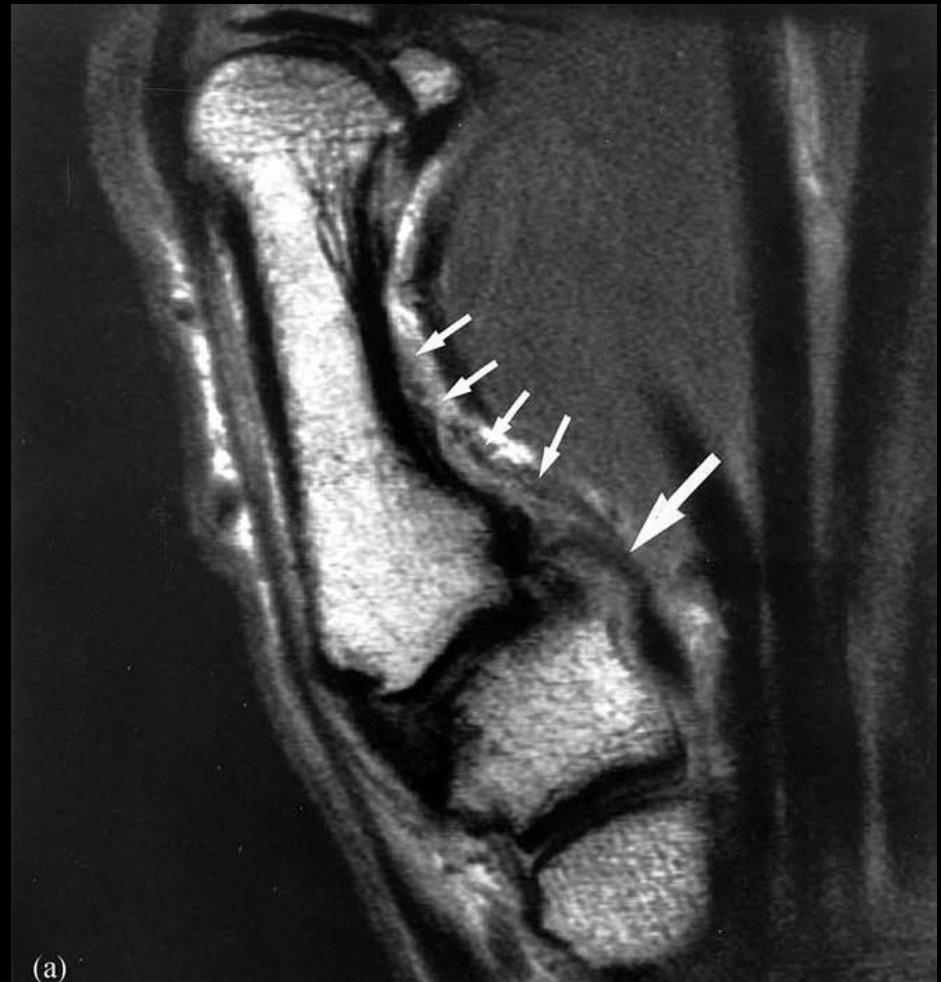TMC joint injuries

- 25 yo basketball player
- Complete AOL tear



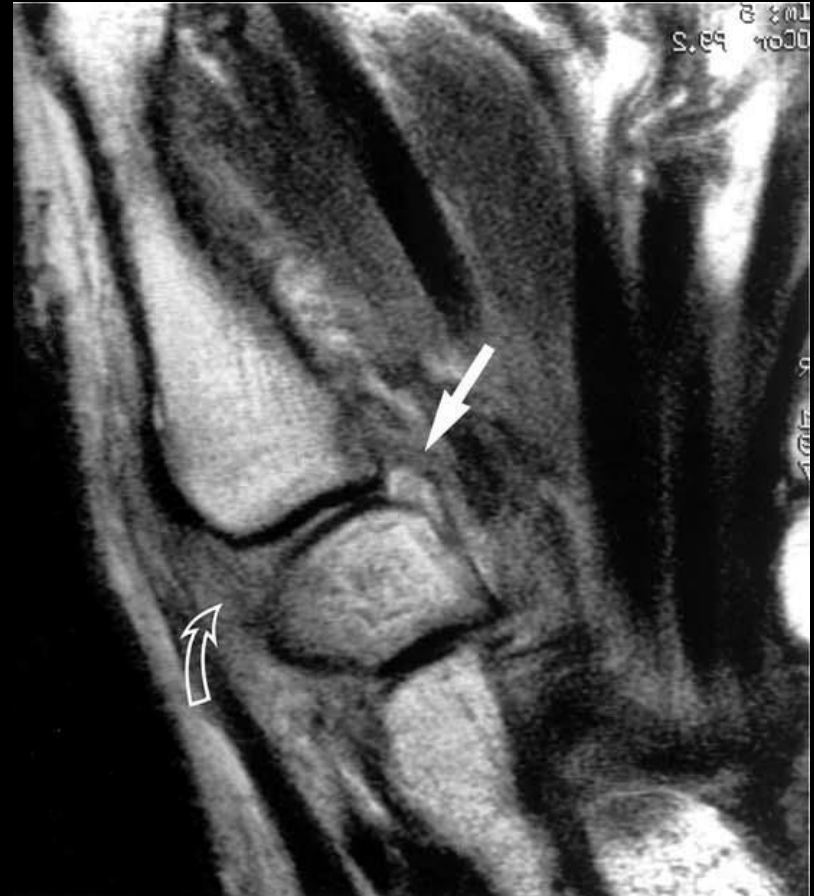TMC joint injuries

- Diver, injured diving
- High grade partial tear of AOL with periosteal stripping



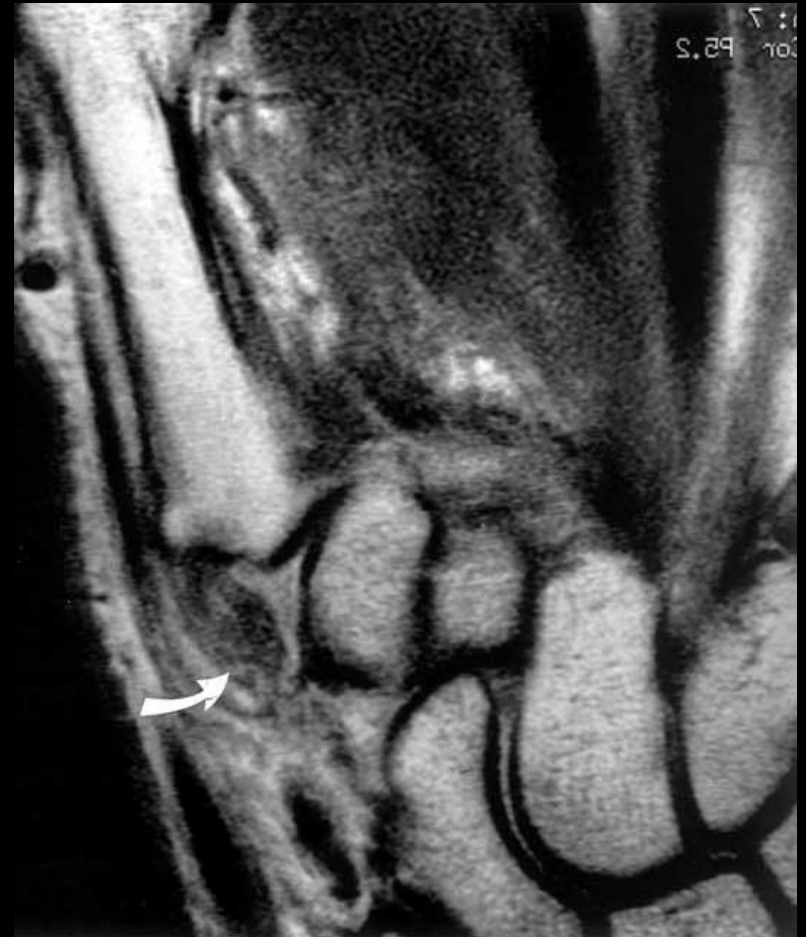TMC joint injuries

- 4 year old, fell
- Near complete tear of AOL (straight)
- Maceration of DRL (curved arrow)



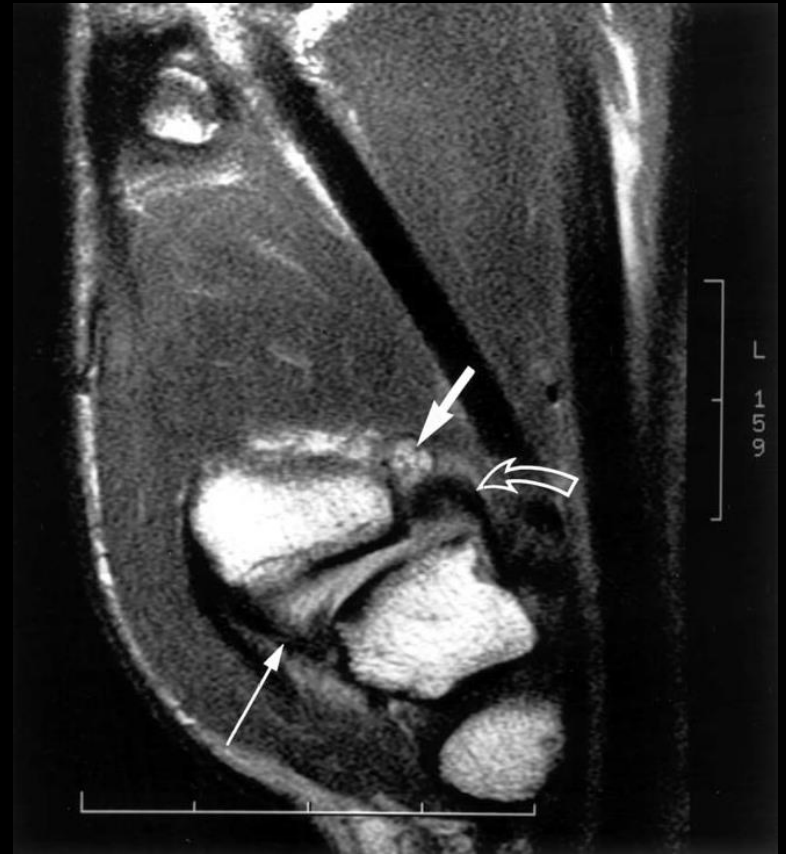TMC joint injuries

- 4 year old fell
- avulsion of the POL from the trapezium



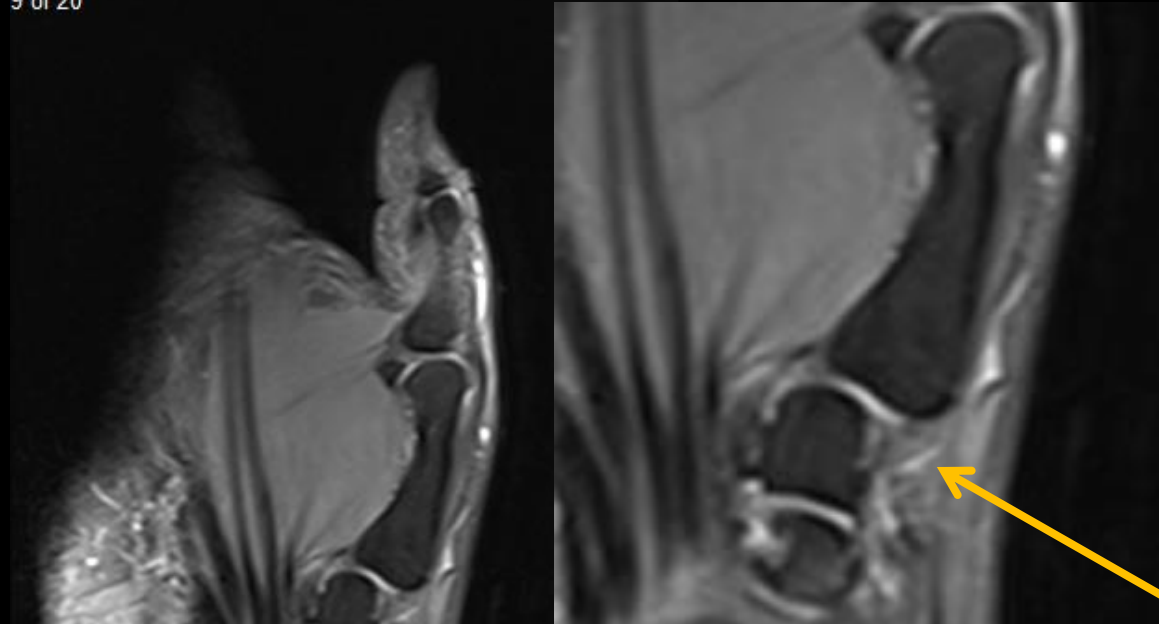
TMC joint injuries

- 52 year old male fist fight 6 mos ago
- Remote AOL injury, laxity of AOL with a small ganglion cyst



TMC joint injuries

9 of 20

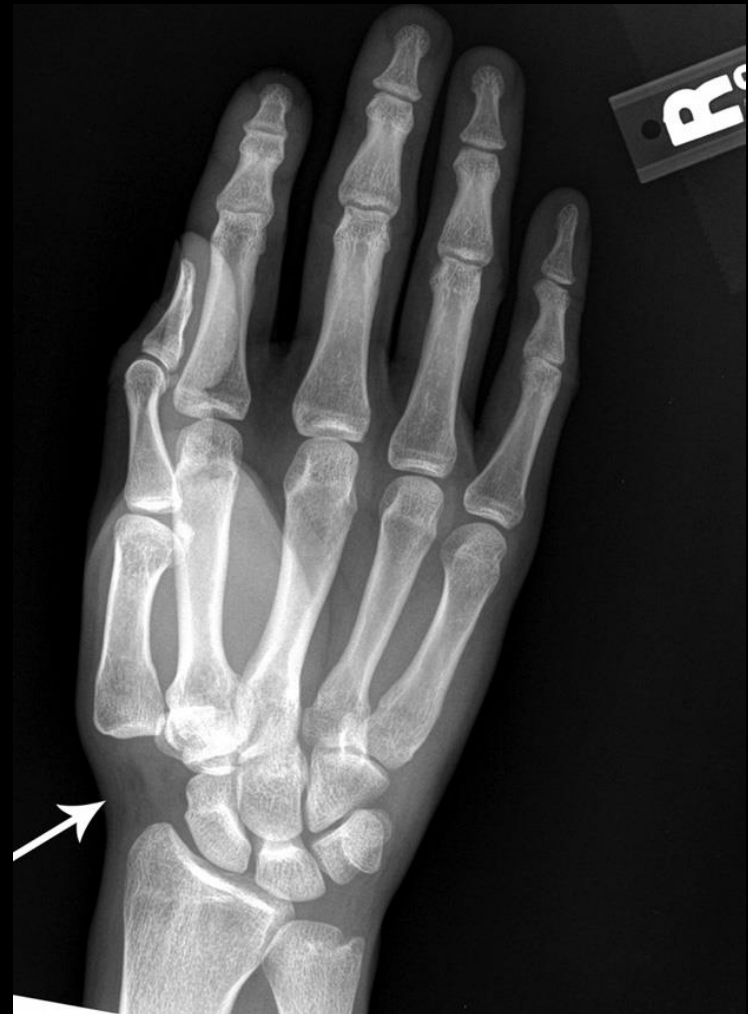

Dorsoradial ligament sprain

Impression: Sprain of the dorsoradial ligament of the trapeziometacarpal joint. No fracture or contusion of the left thumb. Stress radiography may be helpful to assess for any underlying ligament laxity.

TMC joint injuries

- 39 year old male,
FOOSH injury
- **CMC dislocation**



TMC joint injuries: Bennett fracture

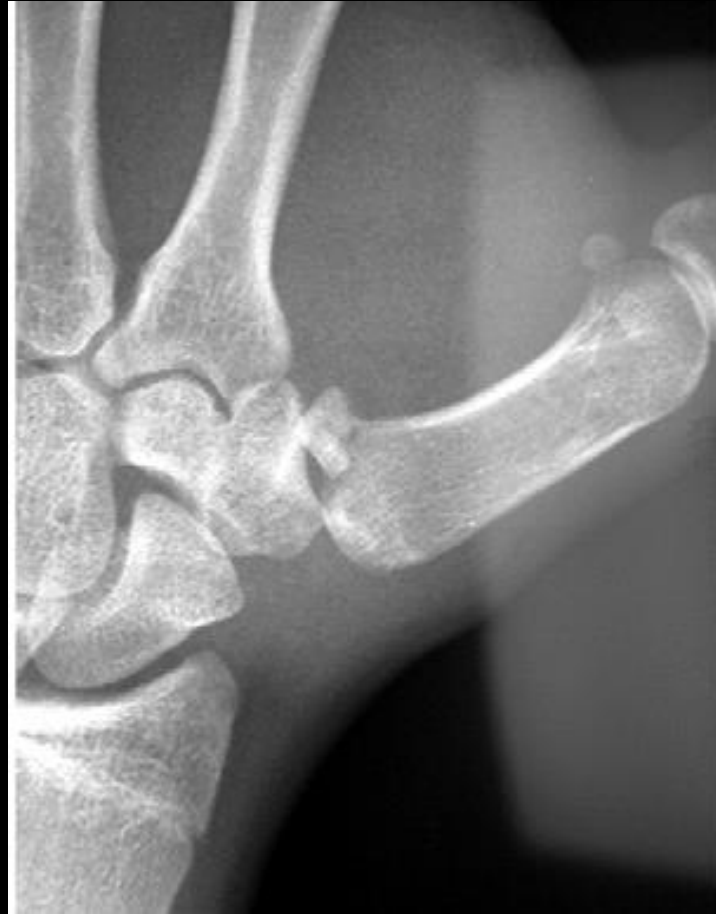- 1882 Irish surgeon EH Bennett
- 2 part intra-articular fracture
- Small fragment of first metacarpal continues to articulate with trapezium, connected by the anterior oblique ligament (AOL)
- AOL is why you get a Bennett fracture not dislocation of first metacarpal
- Rest of metacarpal shaft subluxes dorsal, proximal, and radial (due to pull of abductor pollicis longus, extensor pollicis longus, extensor pollicis brevis, and adductor pollicis longus tendons)
- unstable

TMC joint injuries: Bennett fracture

- Gedda classified into 3 types:
- **Type 1**: fracture with large ulnar fragment and subluxation of metacarpal base
- **Type 2**: impaction fracture without subluxation
- **Type 3**: small ulnar avulsion fracture with metacarpal dislocation

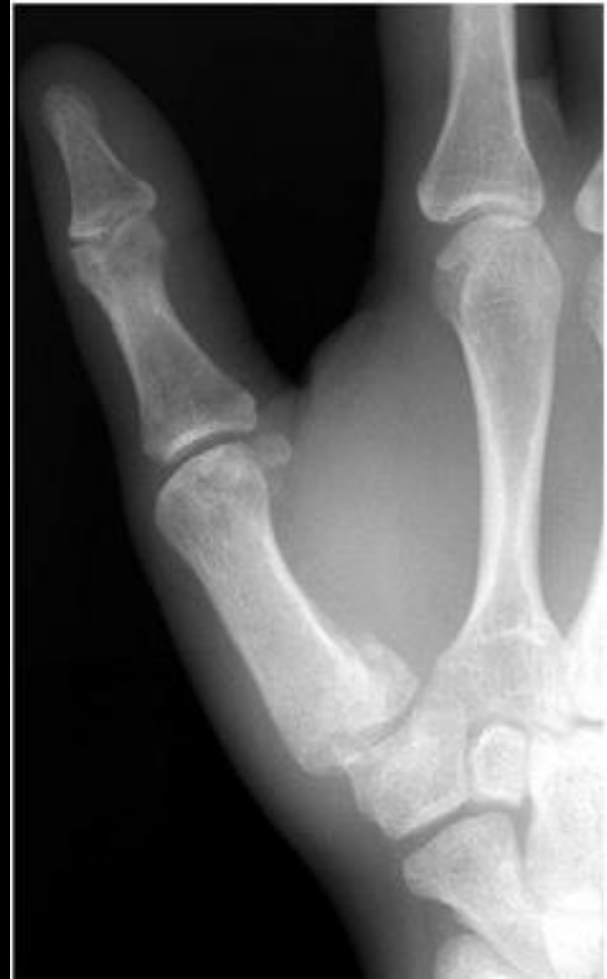TMC joint injuries: Bennett fracture

- **Type 1:** fracture with large ulnar fragment and subluxation of metacarpal base



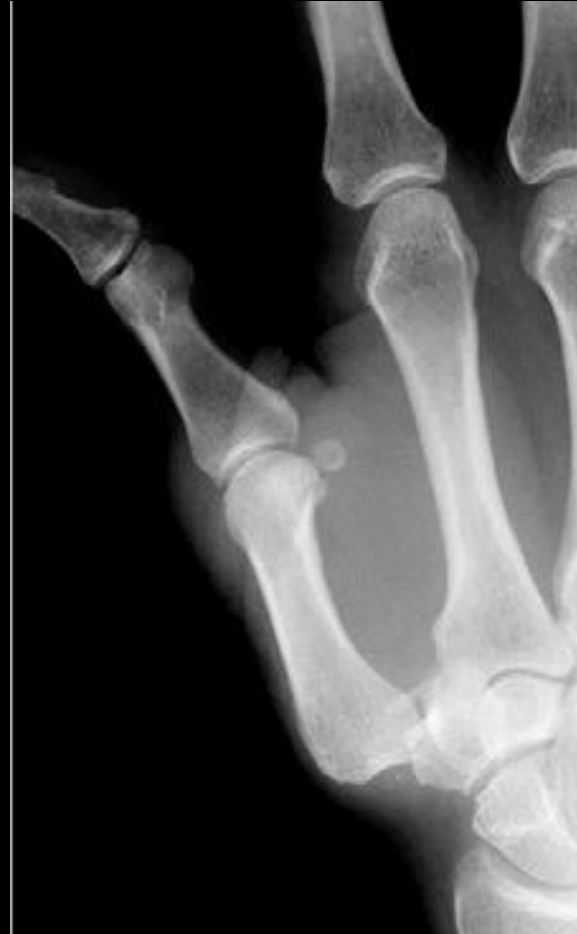TMC joint injuries: Bennett fracture

- **Type 2:** impaction fracture without subluxation



TMC joint injuries: Bennett fracture

- **Type 3**: small ulnar avulsion fracture with metacarpal dislocation



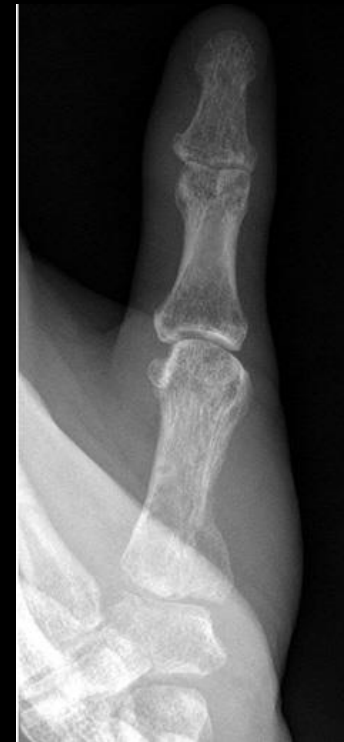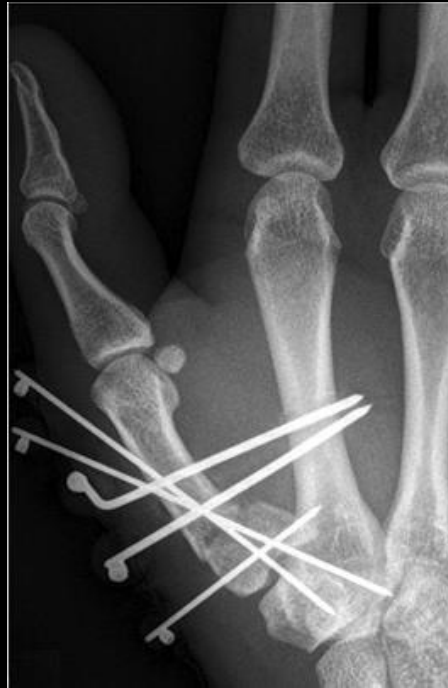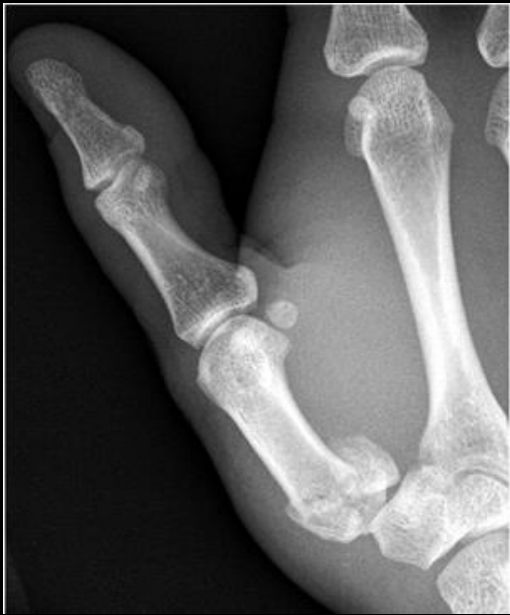Carlsen et al. Journal of Hand Surgery 2009.

TMC joint injuries: Rolando fracture

- 1910 Silvio Rolando—Y pattern fracture of metacarpal base
- Should be reserved for Y or T pattern fracture that include volar ulnar **Bennett fragment plus dorsal radial fragment**
- More difficult to treat, worse prognosis than Bennett
- Open and closed reduction with goal of maintaining articular congruity

TMC joint injuries: Rolando fracture

- Before and after fixation
- 3 months postop showing adequate articular congruity



HELP WANTED SEPT 2, 2005

NINTENDO EXPERT NEEDED
\$50,000 salary + bonus
Equal opportunity employer 55-111

LOOKING FOR GOOD MARIO
BROTHERS PLAYER \$100,000
plus your own car. 55-111

CAN YOU SAVE THE PRINCESS?
We need skilled men & women
Retirement. 11-111

Company needs skilled
operator. Call

IF YOU HAVE 50,000 HOURS
OR MORE OF VIDEO GAME
EXPERIENCE, WE NEED YOU!

DO YOU LAUGH IN THE
FACE OF KILLER GOOMBAS?
CALL US. \$80,000 yr.
plus a free house. 11-111

SUPER MARIO BROS. Expert
\$95,000 yr. Four-day
work week + Ferrari


DO YOU KNOW A NINTENDO
EXPERT? Please read
him or her this ad

VIDEO PLAY
design slayr
\$150,000

NINTENDO
OFFERED
salary

NA

UCSD bone fellow, as a little kid



Hopeful parents

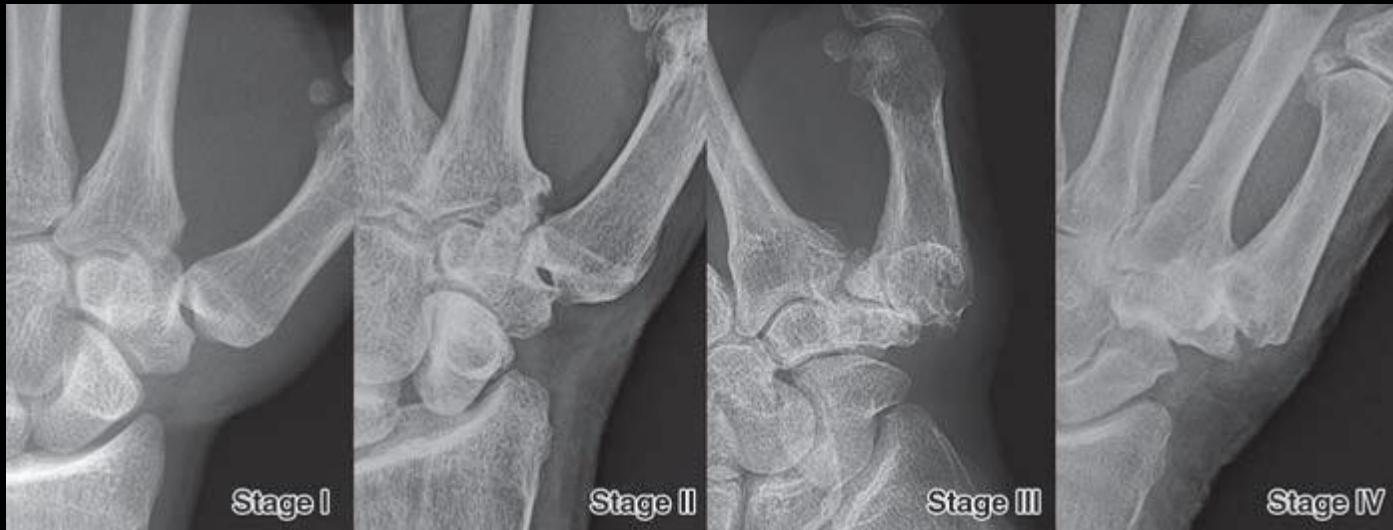TMC joint osteoarthritis

- Most commonly affects postmenopausal women
- In women over 75, incidence of ~40% (vs 20% men)
- Anatomically CMC joint less congruent in women
- Eaton classification system for thumb CMC OA 1973, revised 1987
- Relies solely on radiographic findings (not clinical)
- In females AOL is thinner, possibly explaining the increased (6:1) incidence of CMC OA in women?
- Could hormonal factors play a role? Possibly.

TMC joint osteoarthritis

TABLE 2: Eaton Staging of First Carpometacarpal Joint Osteoarthritis

| Stage | Radiographic Findings |
|-------|---|
| I | Normal joint space or contour or slightly widened trapeziometacarpal joint. If present, < 1/3 trapeziometacarpal articular surface subluxation. |
| II | Decreased trapeziometacarpal joint space. Small (< 2 mm) osteophytes or loose bodies. If present, < 1/3 trapeziometacarpal articular surface subluxation. |
| III | Further decrease in trapeziometacarpal joint space. Presence of subchondral cysts or sclerosis. Osteophytes or loose bodies \geq 2 mm in diameter. At least 1/3 trapeziometacarpal articular surface subluxation. |
| IV | Findings in stage III in addition to involvement of the scaphotrapezial joint or less commonly the trapeziotrapezoid and trapeziometacarpal joint of the second digit. |

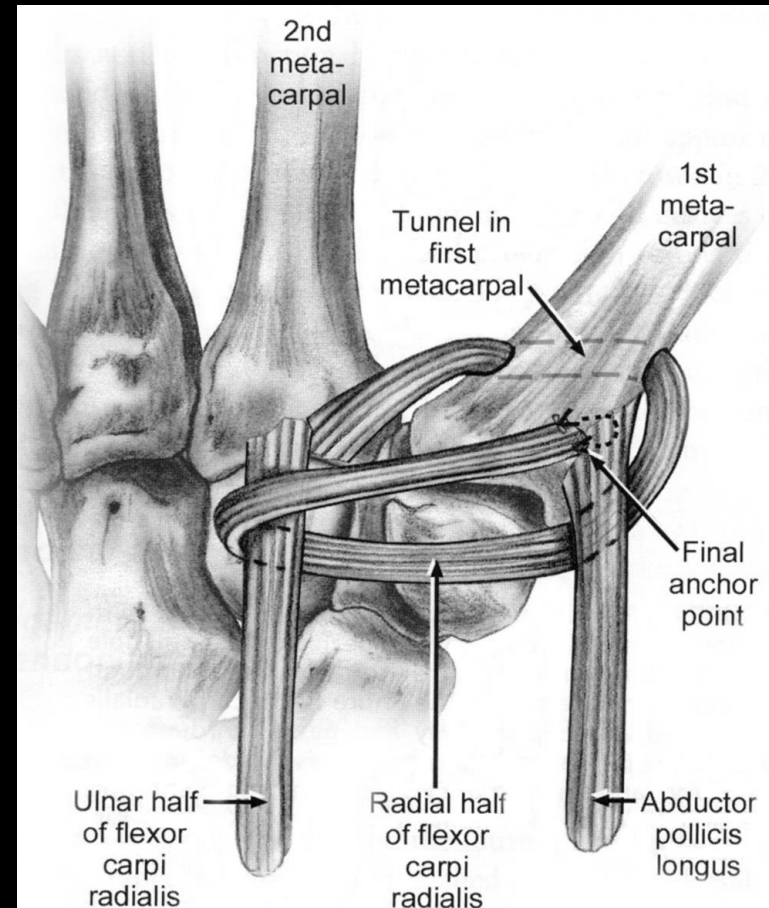


TMC joint osteoarthritis: Treatment

- Wide range of treatment options
- Most common site for which surgery is sought due to its disabling symptoms
- Treatment broken down between those for stage I vs stage II-IV

TMC joint osteoarthritis: Treatment

- **Stage I** – treatment of choice is volar ligament reconstruction, developed by Eaton and Littler 1973
- Halts radiographic progression of disease



TMC joint osteoarthritis: Treatment

- Stage II-IV
- Has changed a lot over the last 50 years
- 1949 Gervis— trapeziectomy only (loss of pinch strength, cosmetically short thumb)
- 1949 Muller – arthrodesis (loss of mobility, and now really only used for post-traumatic and salvage procedures)
- 1972 Swanson –silicone implant (wear debris, foreign body synovitis, dislocation)

TMC joint osteoarthritis: Treatment

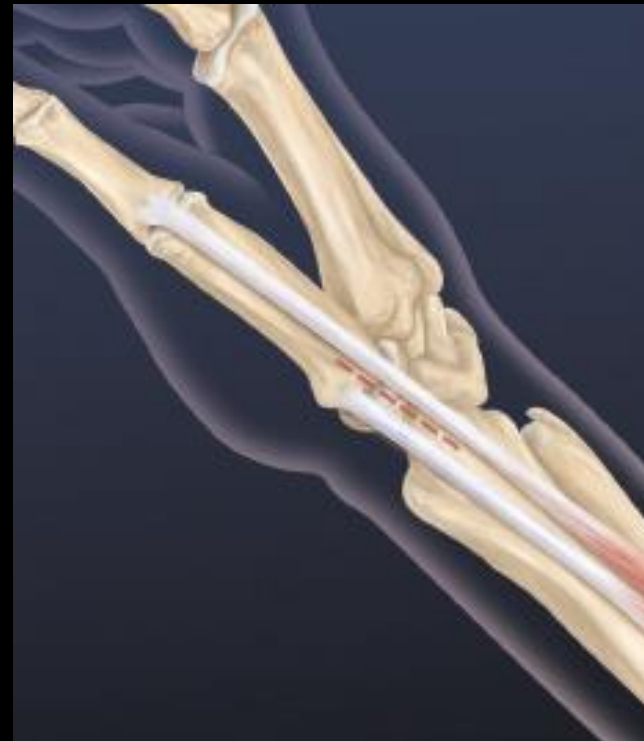- **1970 Froimson** – trapezectomy with FCR tendon interposition, later modified to hemi-trapezectomy with FCR tendon interposition (did not address volar ligament laxity)
- Trapezium is removed to remove pain from bony contact
- 5 cm strip of FCR tendon harvested, distal attachment preserved
- FCR rolled into a ball, into the trapezectomy space, nicknamed the “**anchovy procedure**”



TMC joint osteoarthritis: LRTI

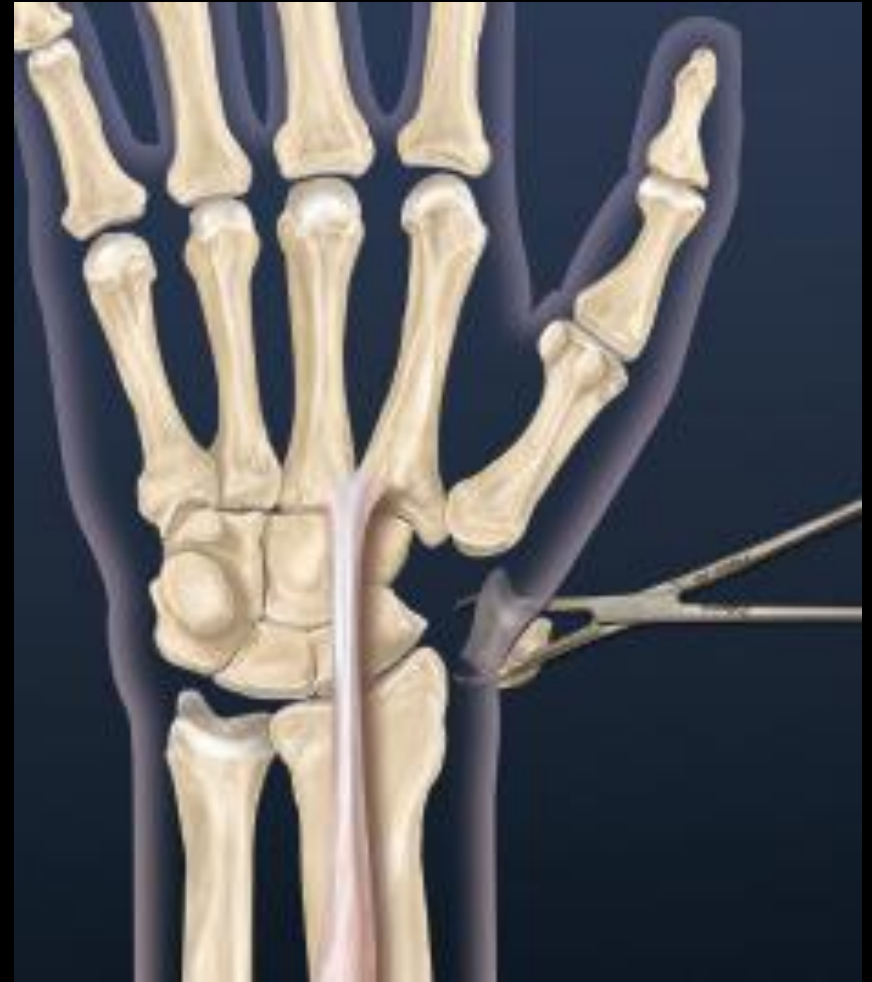- **1986 Burton and Pelligrini** combined reconstruction of the beak ligament with tendon interposition—LRTI
- Standard by which others are compared against

Longitudinal incision at CMC joint
Between abductor pollicis longus and
Extensor pollicis brevis tendons



LRTI

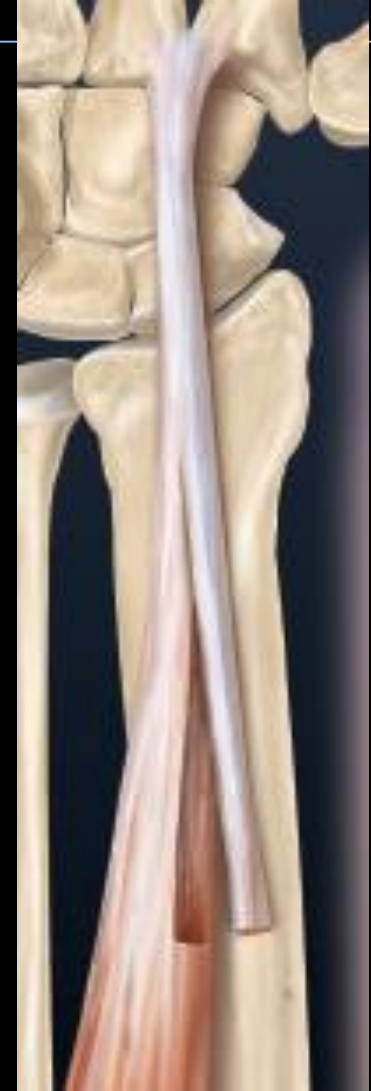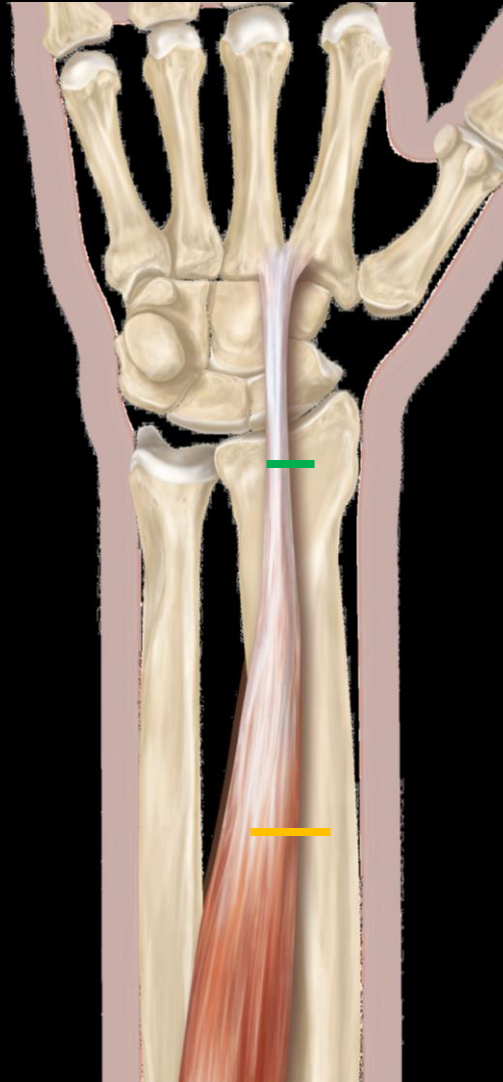
Trapezium excised



LRTI

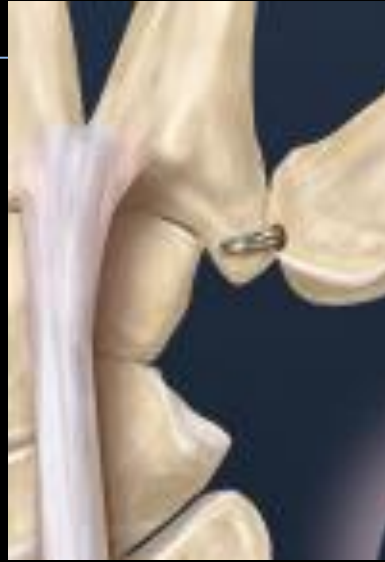Second incision over the FCR at the wrist crease, cut tendon withdrawn distally into the wound

Transverse incision made over FCR approximately 10 cm proximal to wrist crease

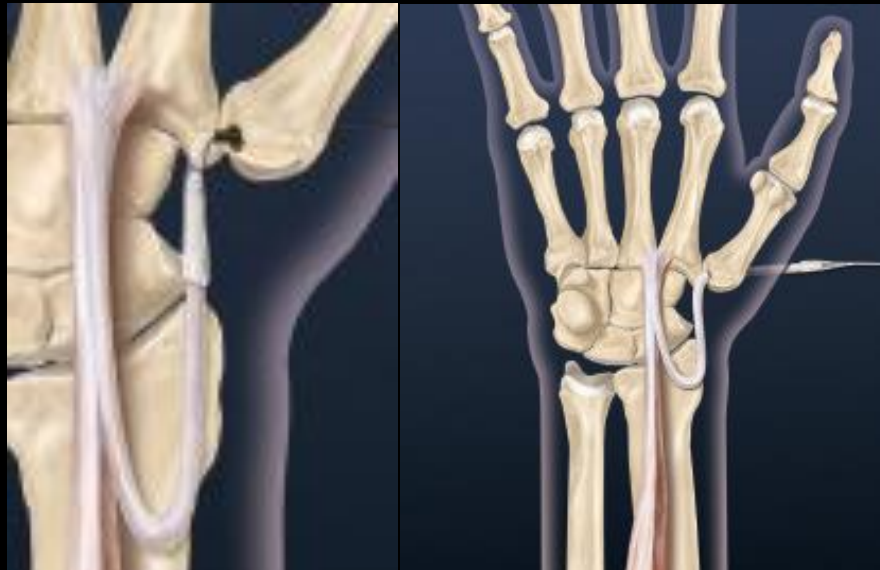

LRTI

Short guide pin, 4 mm drill used to create a hole from the dorsal metacarpal into the volar beak

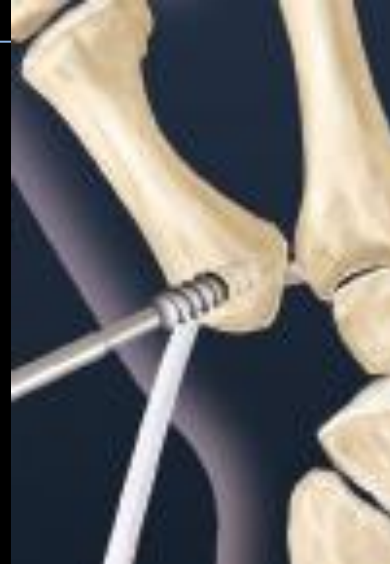

Tendon passed through the hole

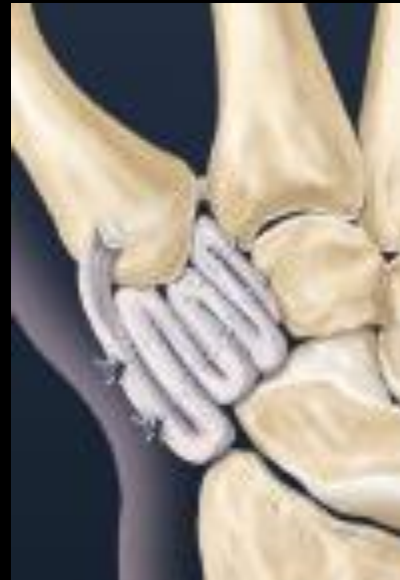

LRTI

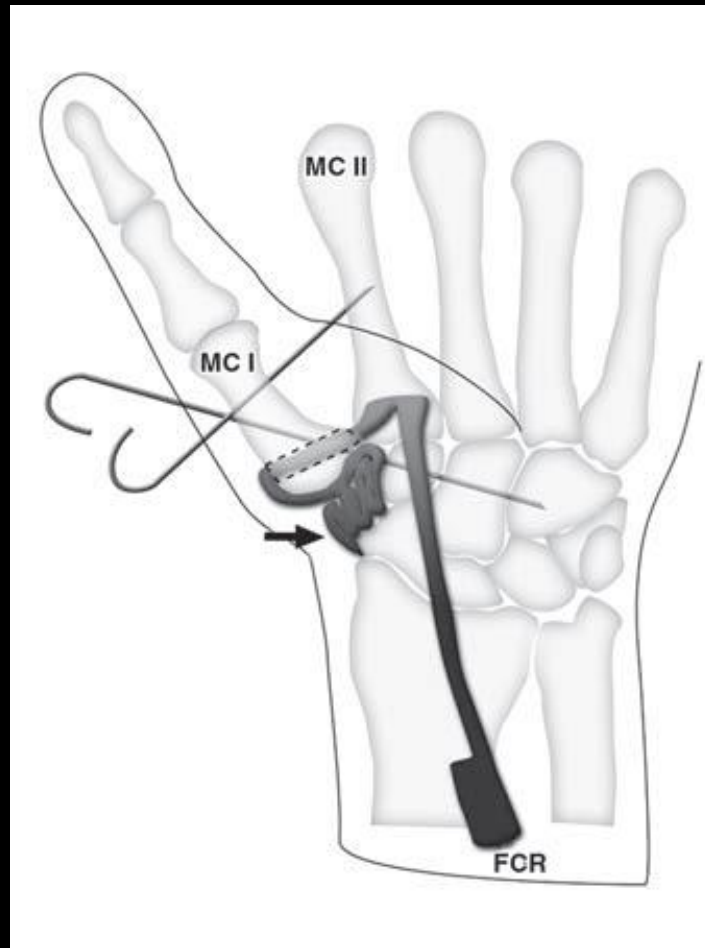
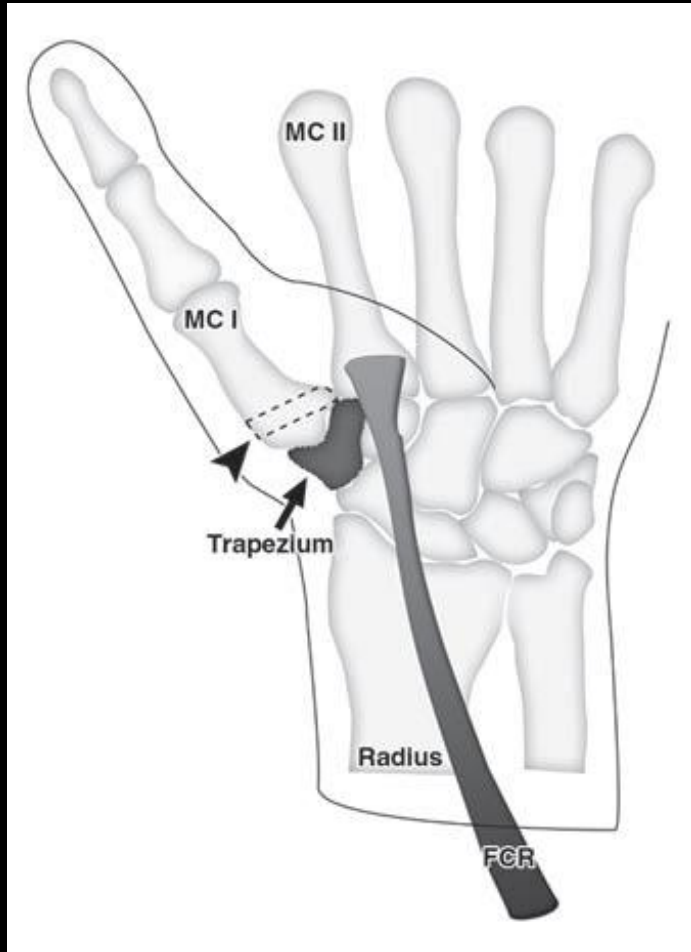
Tenodesis screw placed into drill hole to secure the FCR tendon to bone



Remaining FCR is folded on itself, sutured and put back into the trapezial cavity

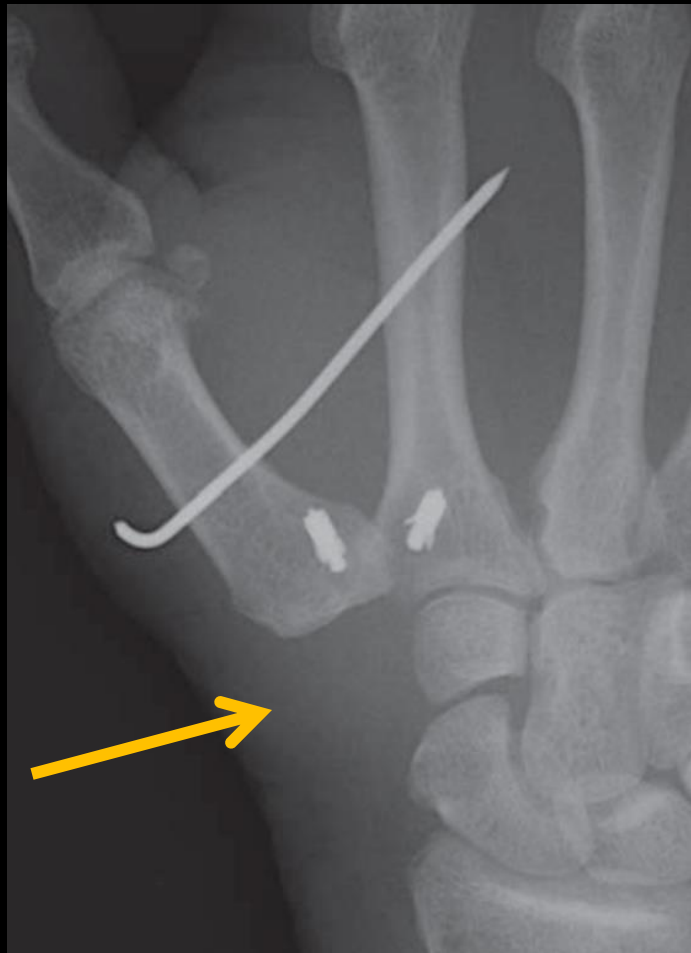

LRTI

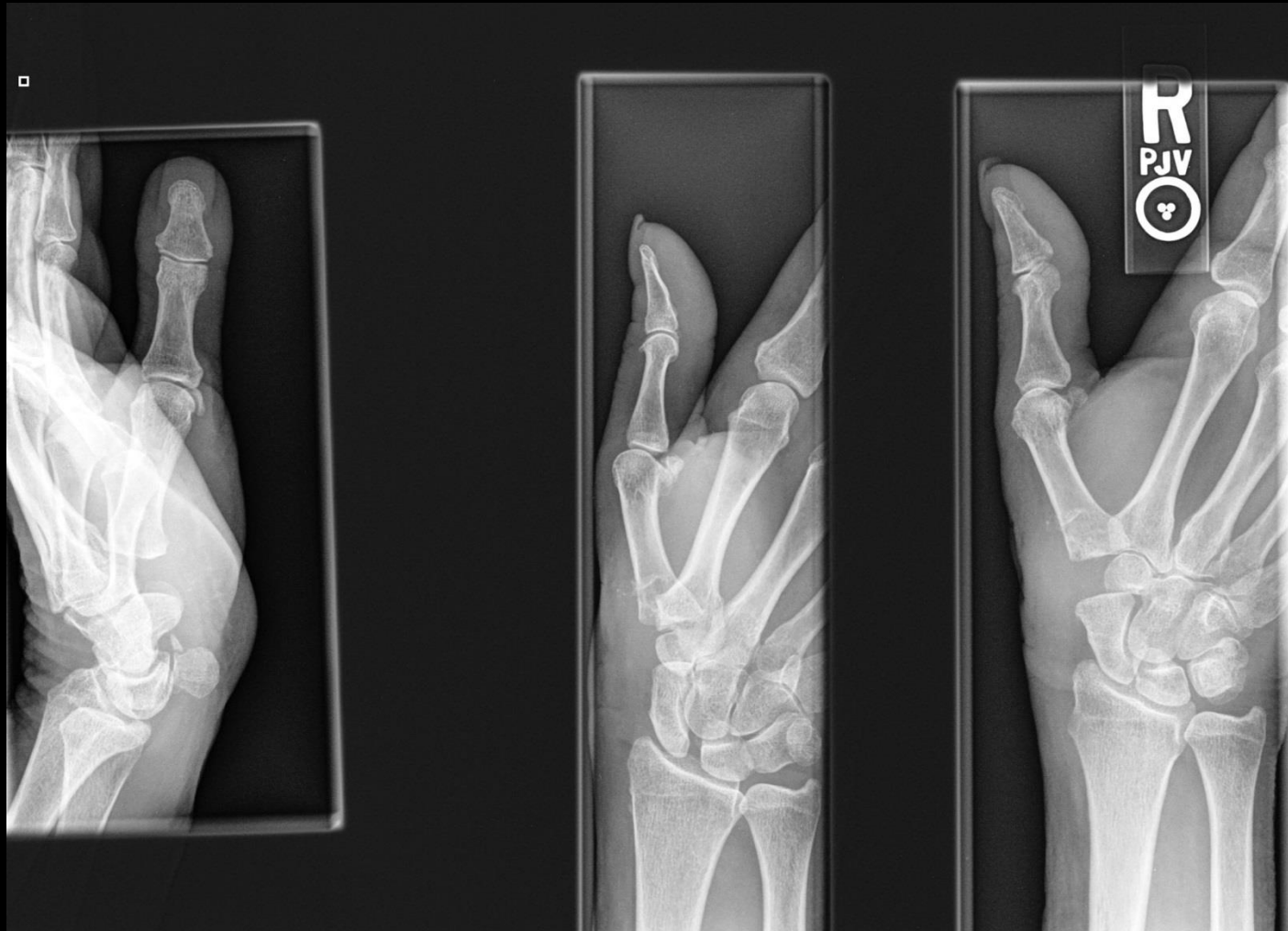

LRTI normal

Note radiolucent gap of the rolled up FCR tendon

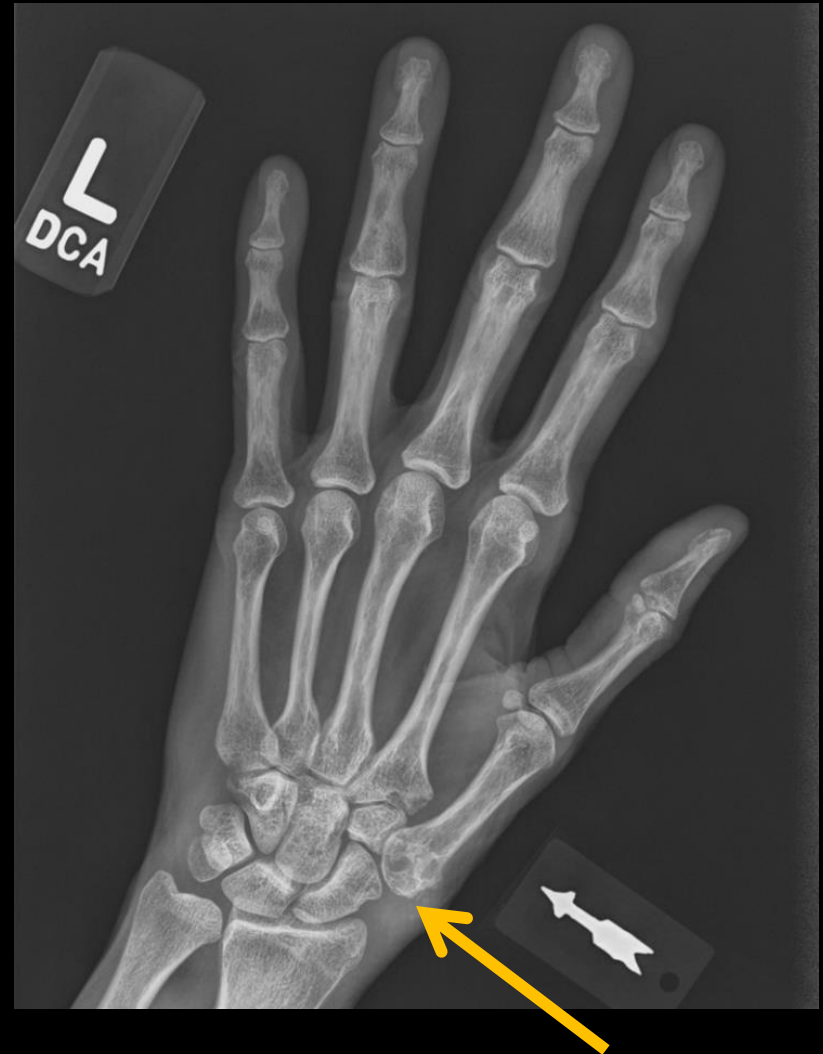

LRTI normal

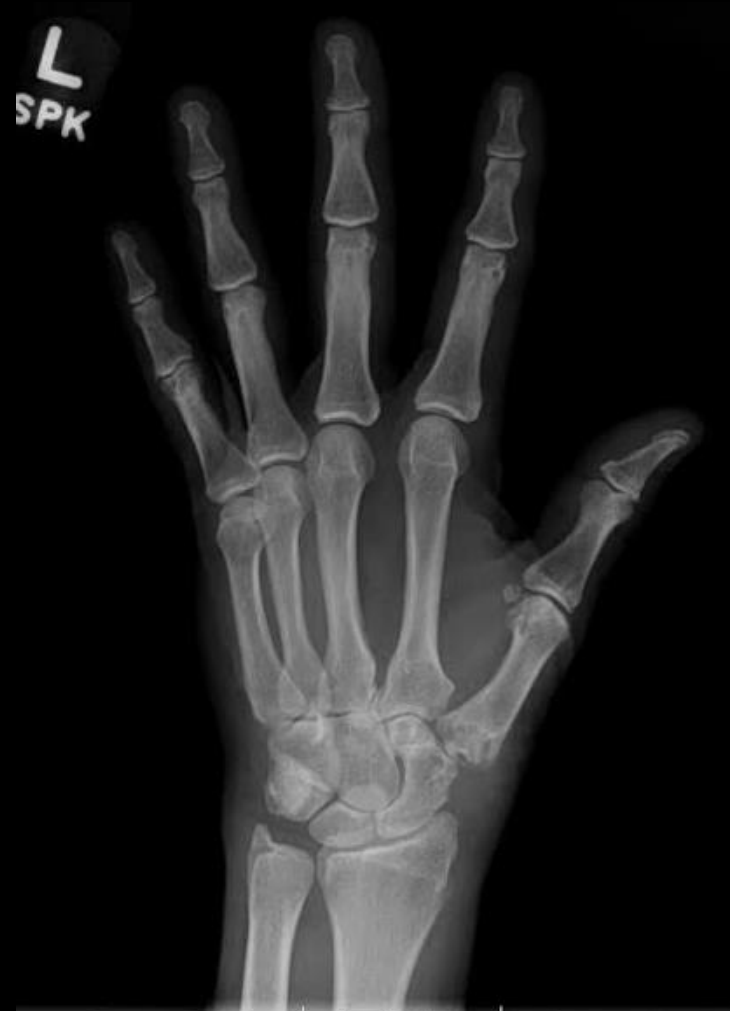
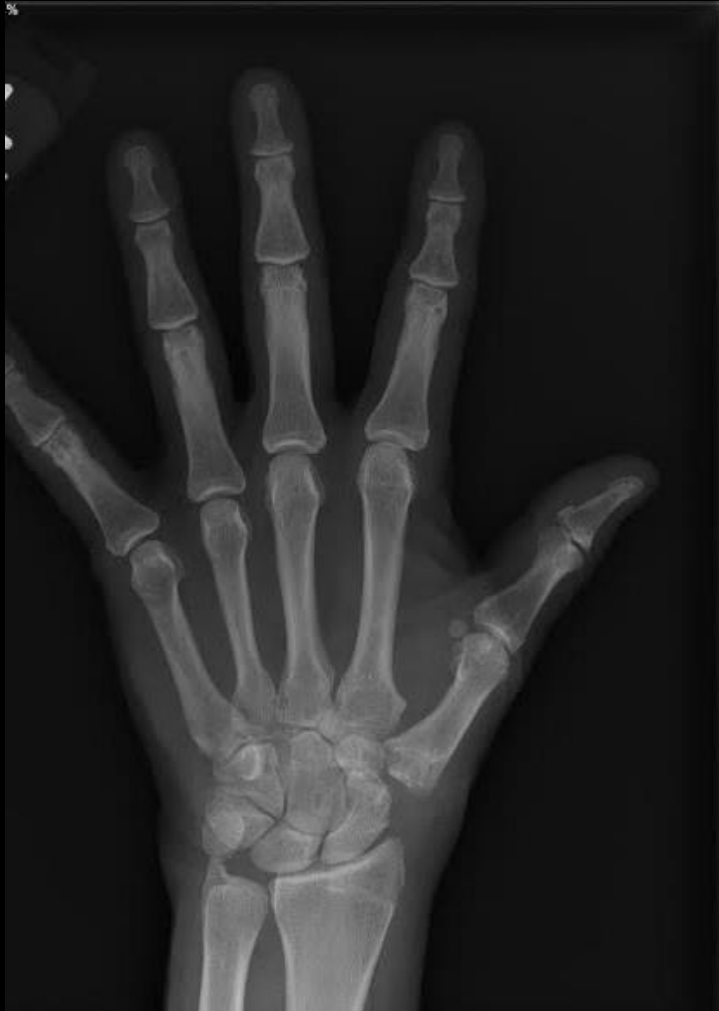
LRTI failure

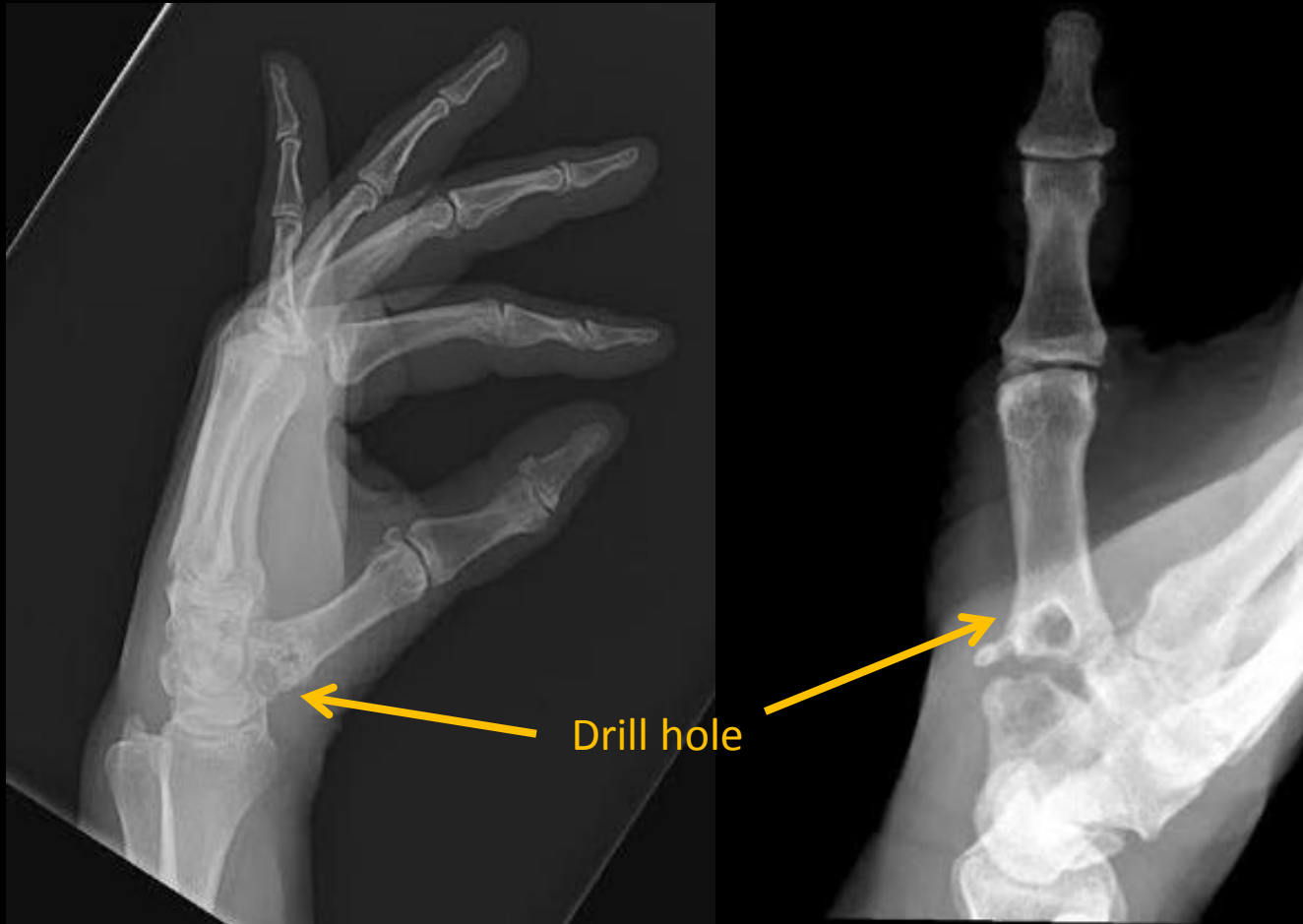Note proximal migration of the thumb metacarpal and loss of the gap



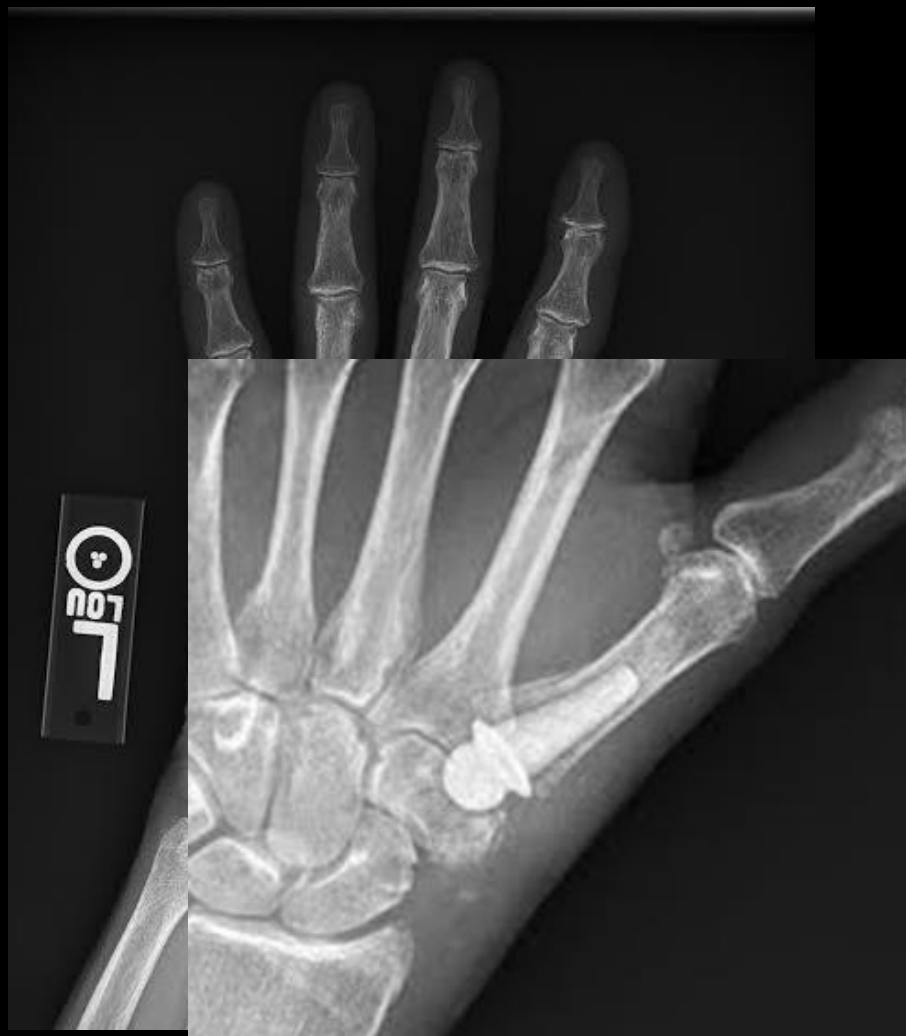LRTI failure



LRTI failure




NuGrip Pyrocarbon Implant



Hematoma and Distraction Arthroplasty (HDA)

- **1997 Kuhns** - hematoma and distraction arthroplasty
- **Trapeziectomy** (Gervis 1949)
- K-wire after surgery, thumb spica cast, left in for 2.5-5 weeks
- Allows hematoma and fibrosis to form in the trapeziectomy bed
- Allows fibrosis in the anterior oblique ligament
- Better strength and mobility results when compared two other LRTI series
- Reported 0% compliant of late onset symptoms or request for revision



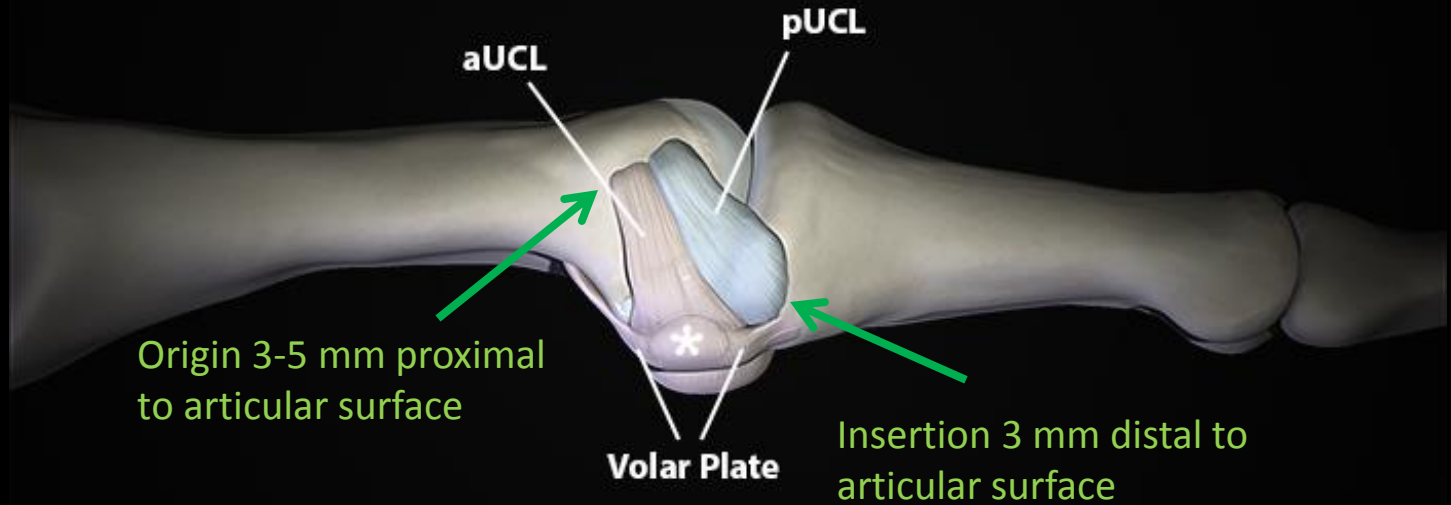
"Say . . . What's a mountain goat doing way up here in a cloud bank?"

MCP joint anatomy

- Unique anatomy
- Requirements for stability more important than mobility
- Thumb metacarpal head less spherical → more stability
- Two sesamoids confer stability – situated at lateral aspect of volar plate, within tendinous insertion of flexor pollicis brevis tendon (FPB)
- Stronger tendinous and aponeurotic insertions than fingers

MCP joint anatomy

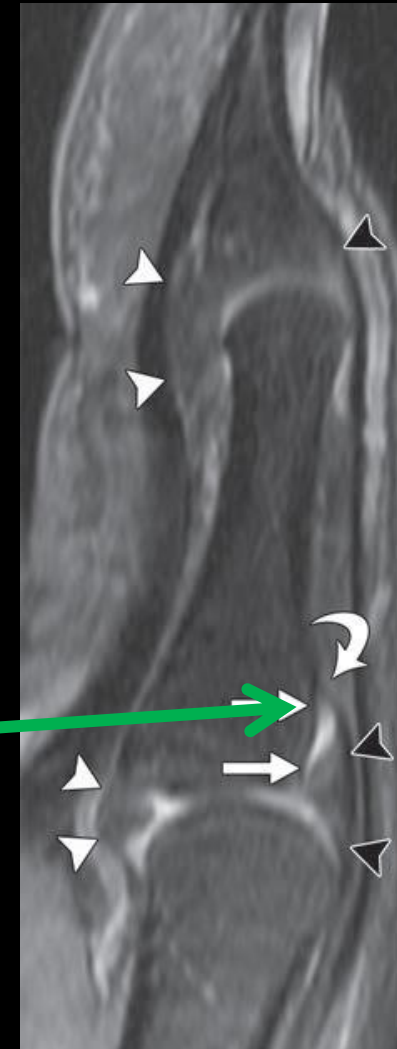
- Ulnar collateral and radial collateral ligaments are comprised of two bundles, proper and accessory collateral ligaments
- Accessory collateral ligament continuous with proper collateral ligament and volar plate and sesamoid



MCP joint anatomy

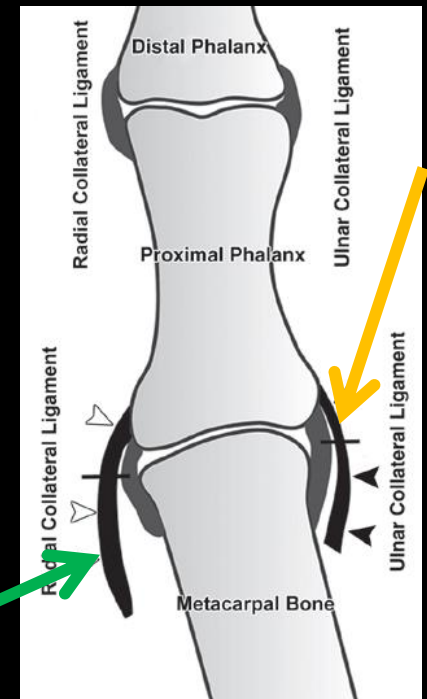
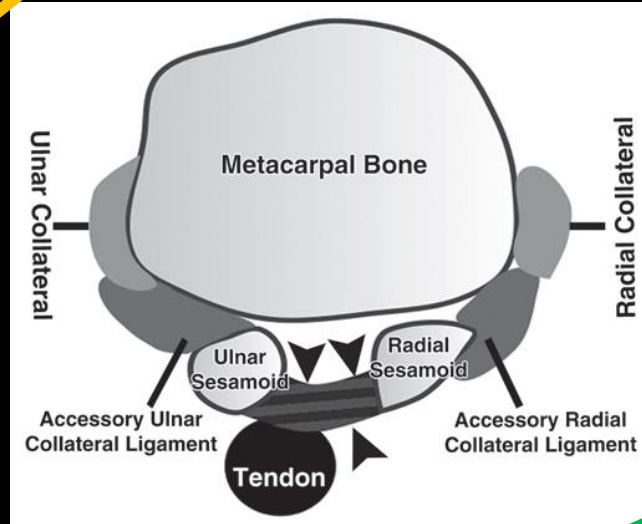
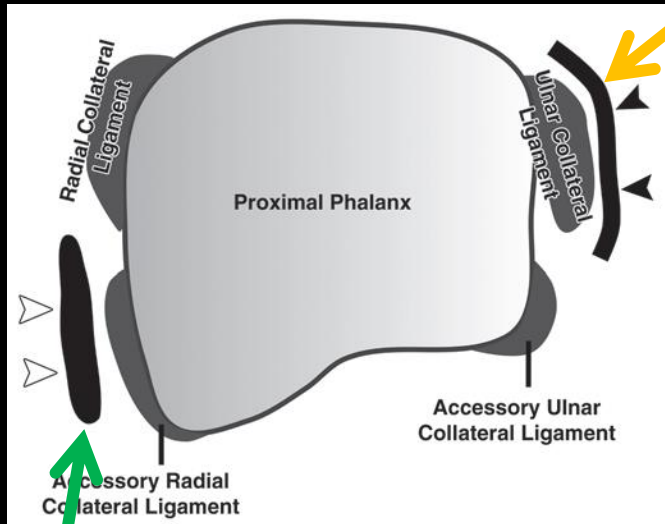
- Dorsal and volar plate—prominent portions of wedge shaped fibrocartilagenous capsule surrounding the joint
- Dorsal plate synovial recess seen in 91%
- Volar plate synovial recess seen in 18-24%

Dorsal plate recess extends distally to attachment of dorsal plate, adjacent to the insertion of extensor pollicis brevis tendon

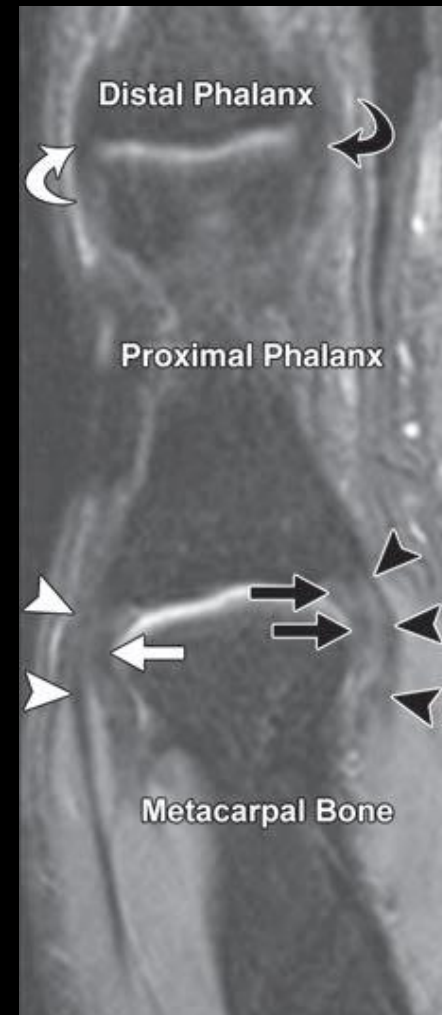
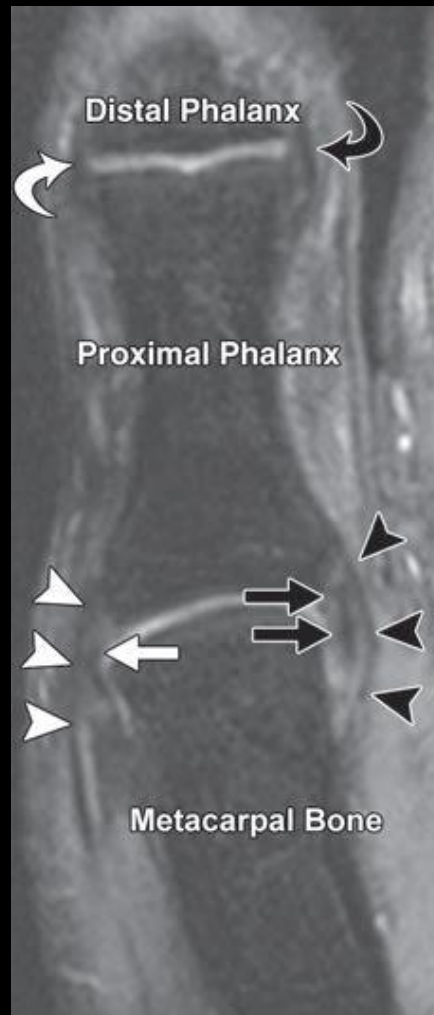
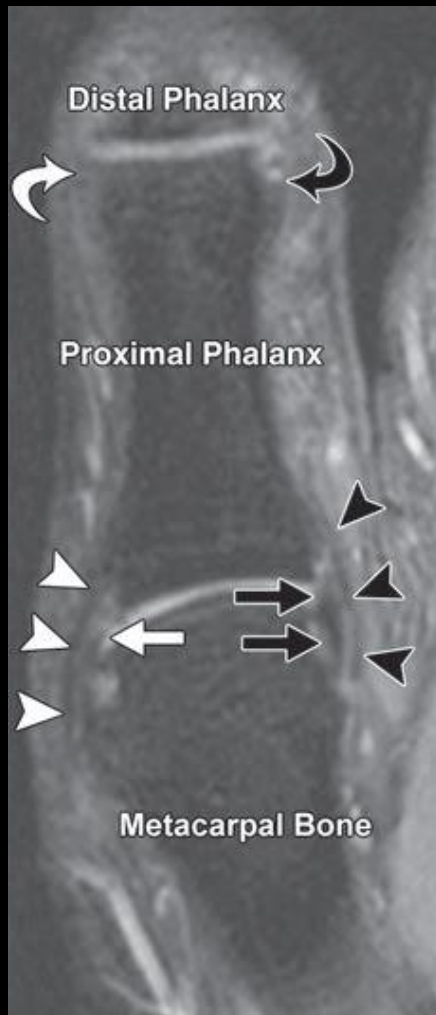


MCP joint anatomy

- **Aponeurosis of the adductor pollicis muscle** – overlies and strengthens the UCL, joins dorsally with fibers of extensor hood and inserts on flexor pollicis longus tendon
- **Aponeurosis of the abductor pollicis brevis muscle** — overlies the RCL



MCP joint anatomy



MCP joint anatomy

- UCL/RCL—primary static stabilizers – both contribute to dorsal support and lateral stability
- Proper UCL — primary support when MCP flexed > 20 degrees
- Accessory UCL — primary support when finger is straight

- Adductor pollicis muscle – primary dynamic stabilizer resisting valgus stress, inserts onto ulnar tubercle of proximal phalanx, volar plate, ulnar sesamoid, and adductor aponeurosis

MCP joint injuries: UCL—how?

- Gamekeeper's thumb for chronic injuries
- Skier's thumb for more acute injuries
- UCL injured from forced valgus stress at the thumb MCP, such as from a ski pole, catching a ball, or fall with thumb abducted
 - Stretching and rupture of the proper UCL and joint capsule
 - Volar plate and embedded sesamoid rotate radially
 - Finally disruption of the accessory ACL
- **Grading :**
 - Grade 1: incomplete tear, no instability
 - Grade 2: incomplete tear, some laxity
 - Grade 3: complete tear, instability

MCP joint injuries: UCL



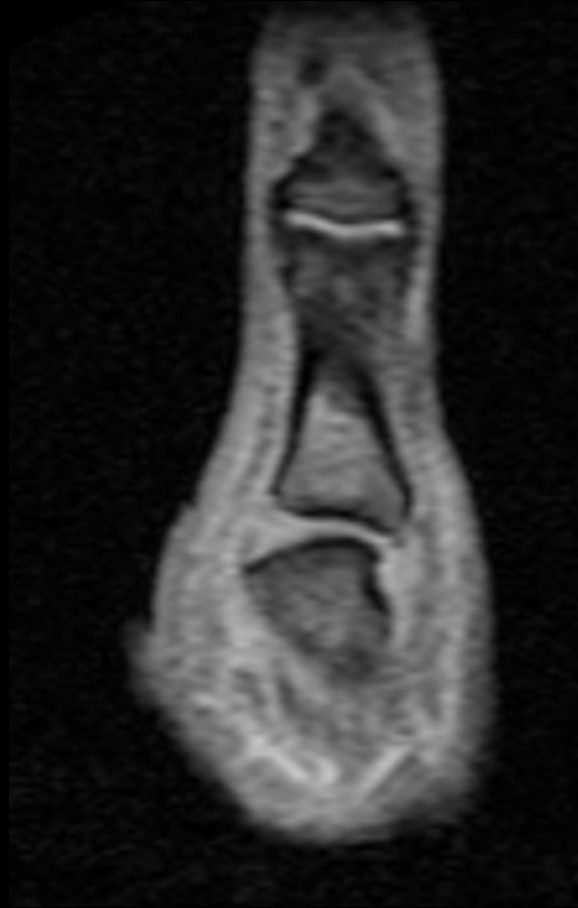Dustin Pedroia head-first slide into first base, UCL tear – 2013

MCP joint injuries: UCL

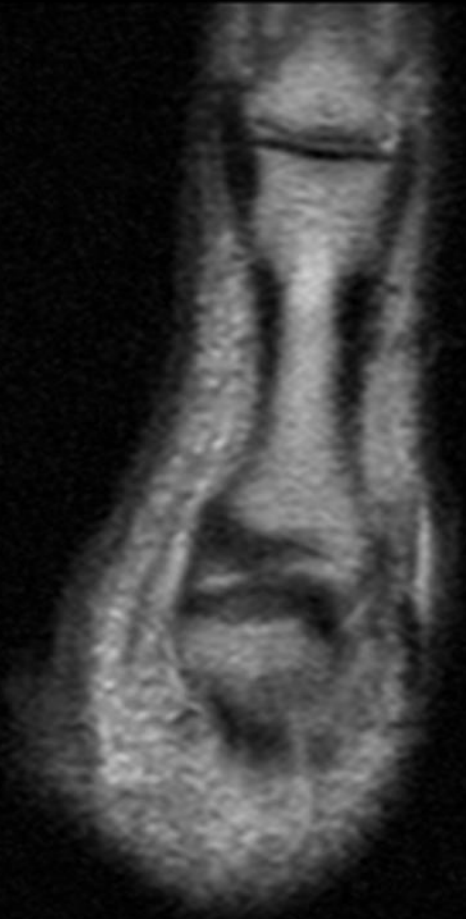


Bryce Harper head-first slide into second base, UCL tear -- 2014

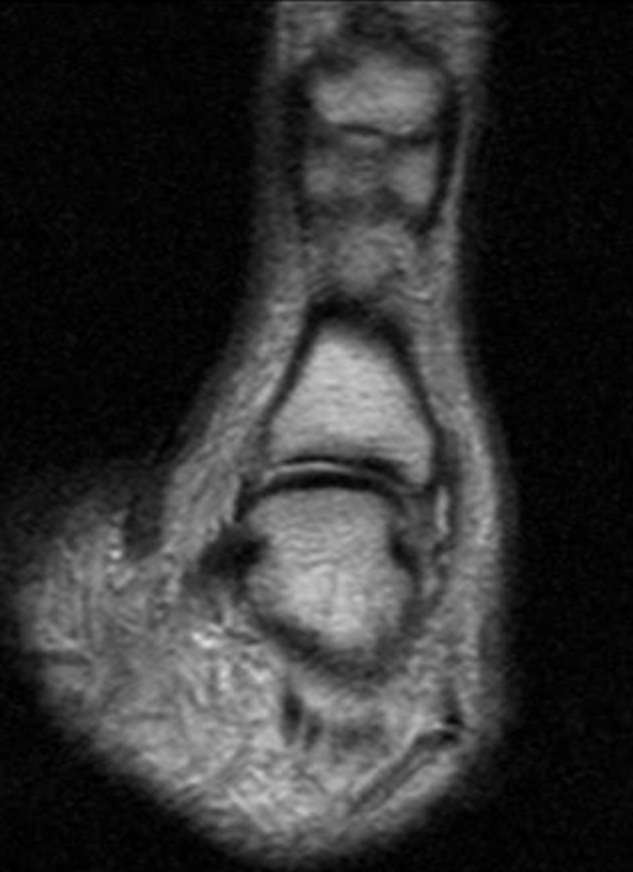
MCP joint injuries: UCL



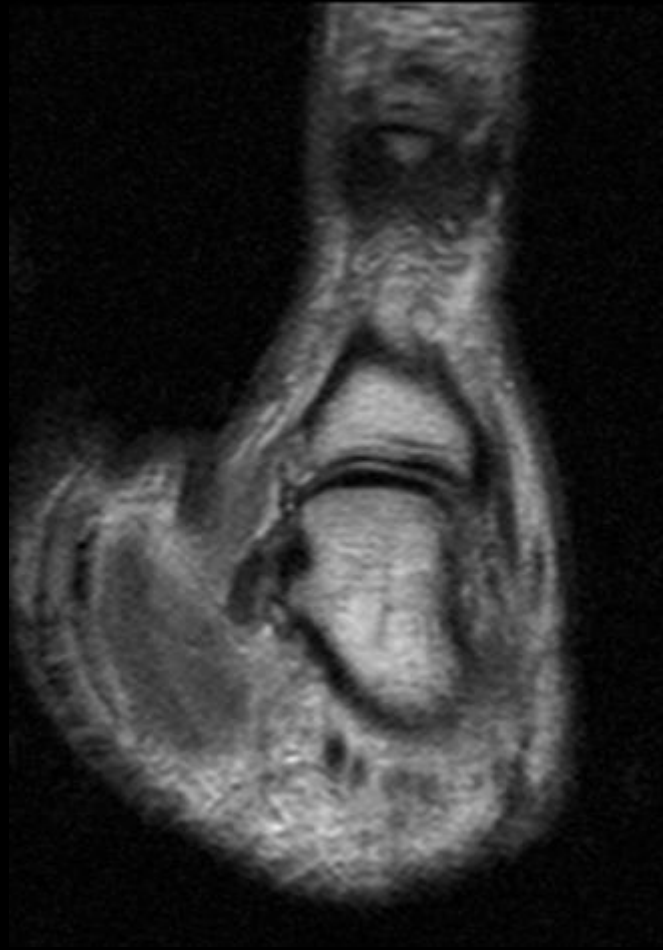
MCP joint injuries: UCL



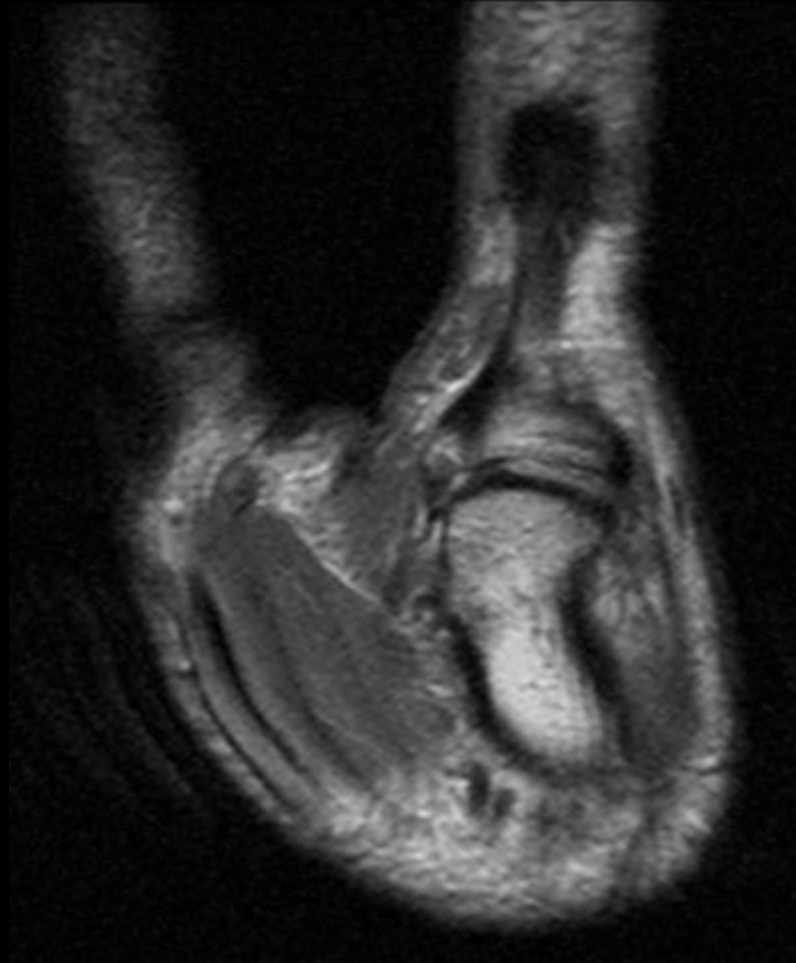
MCP joint injuries: UCL



MCP joint injuries: UCL



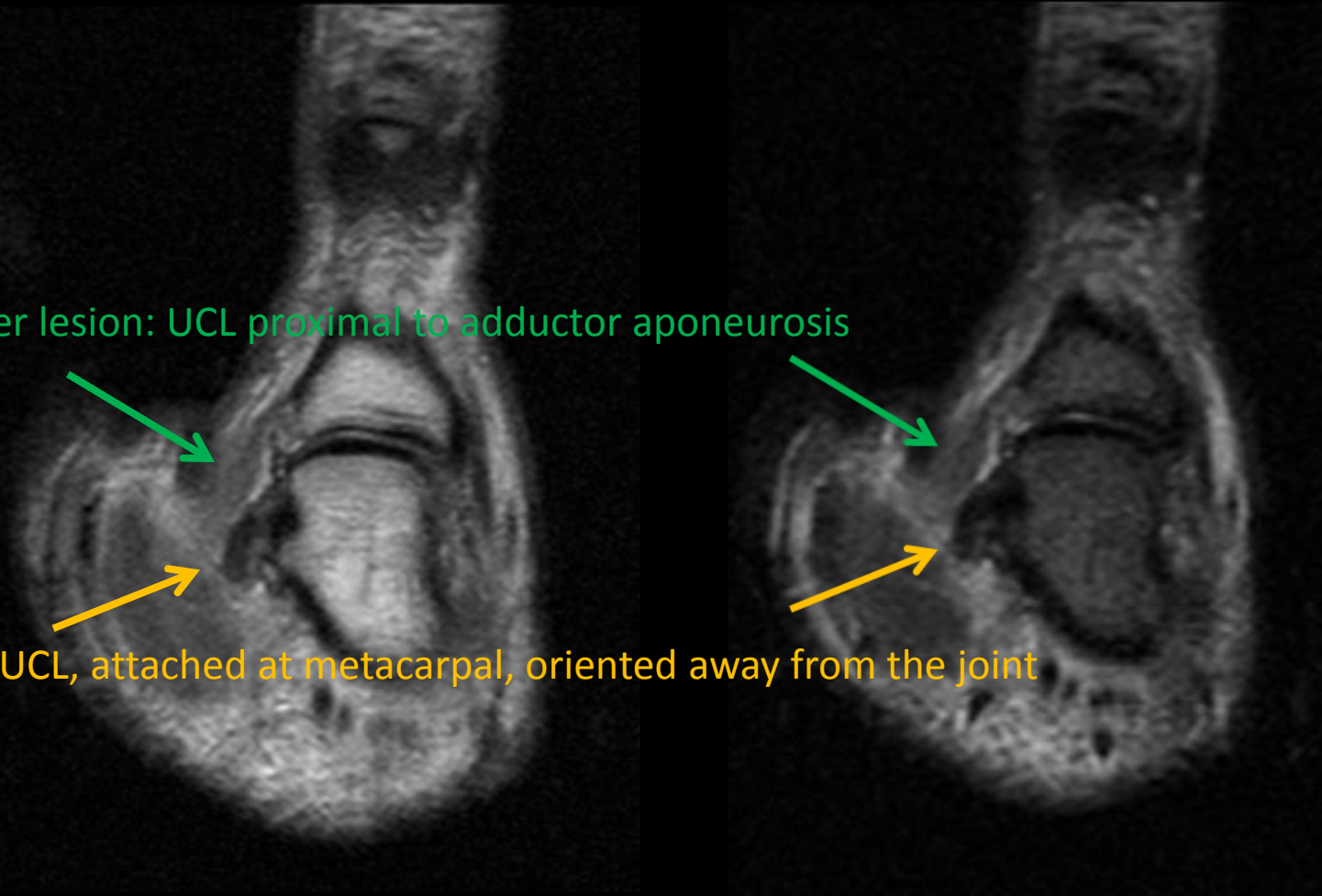
MCP joint injuries: UCL



MCP joint injuries

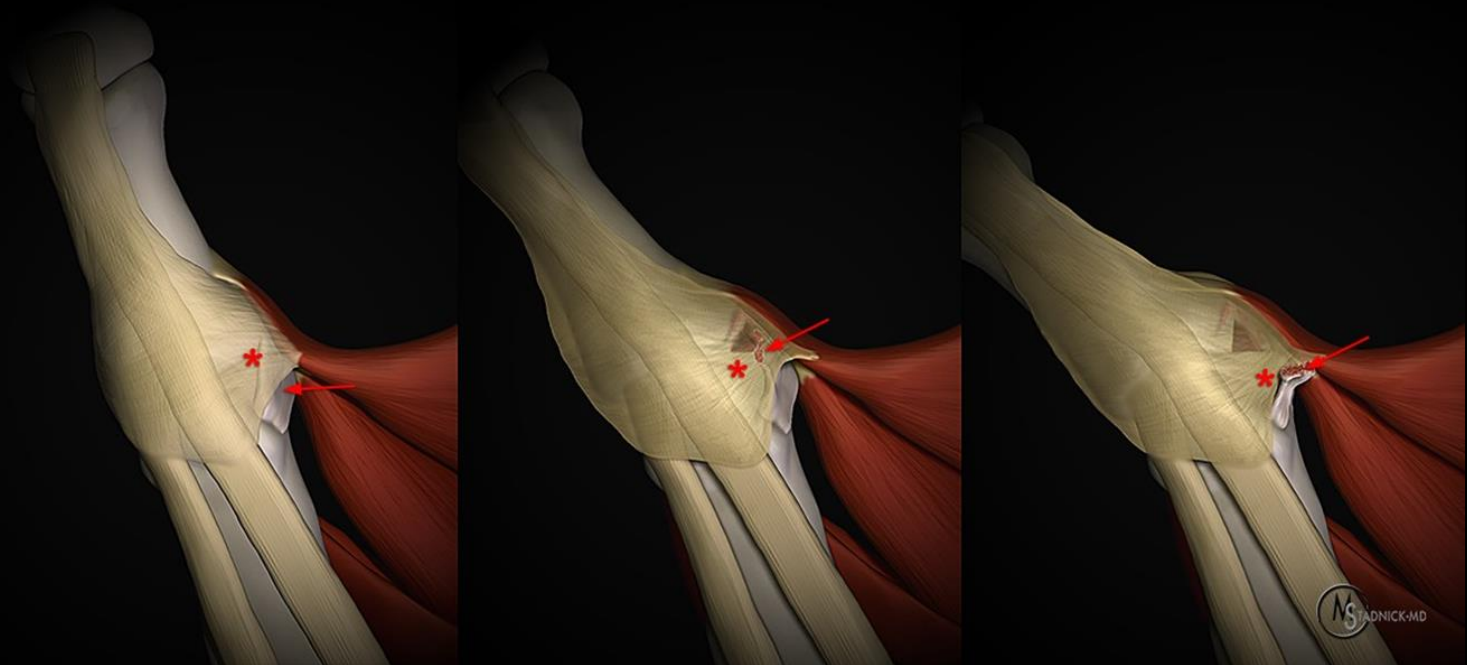
Stener lesion: UCL proximal to adductor aponeurosis

Torn UCL, attached at metacarpal, oriented away from the joint



MCP joint injuries: Stener lesion

- Stener lesion: UCL torn and retracted, folded proximal to the proximal aspect of the adductor aponeurosis – spontaneous ligament healing is inhibited

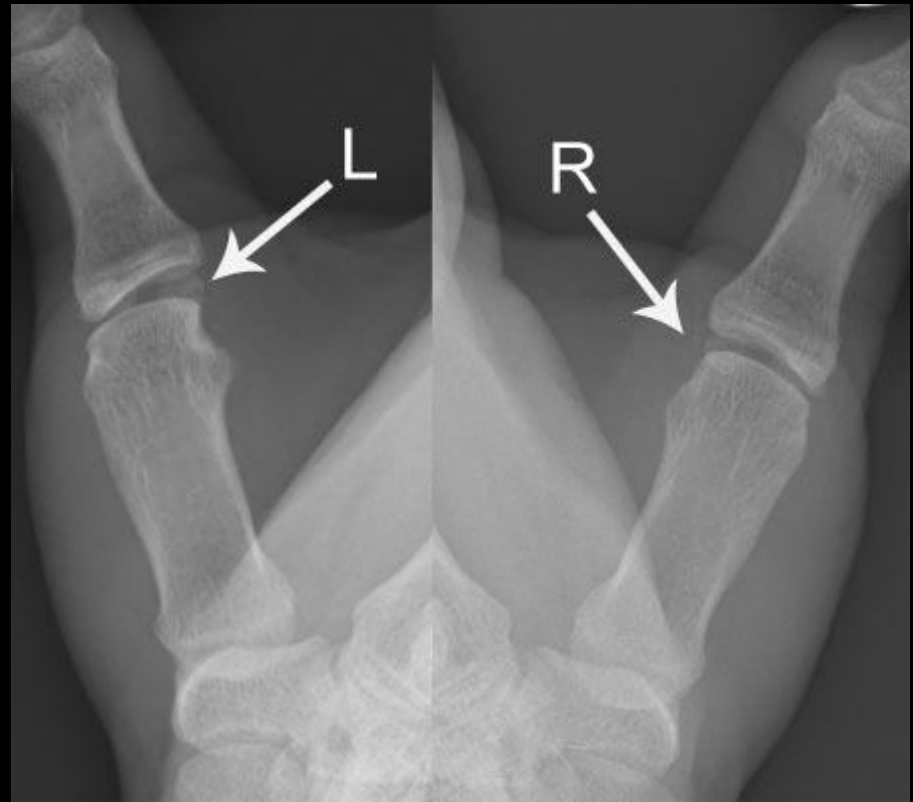

MCP joint injuries: UCL—presentation, clinical exam

- Swelling, tenderness, redness, pain with key grip and pincer grip
- Palpable nodule may suggest Stener lesion (64-88% of complete UCL tears will have one)
- Valgus stress to assess stability, lack of consensus on what constitutes abnormal
- Not necessarily a good idea as it can convert a nonsurgical lesion into a surgical lesion (eg, a non-Stener lesion into Stener lesion)
- Don't allow your techs to do these stress views, if ordered maybe ask the orthopedic surgeon to do it

MCP joint injuries: UCL—presentation, clinical exam

- Stress views showing asymmetric widening of the MCP joints, L greater than R



Ebrahim. Radiographics. 2006

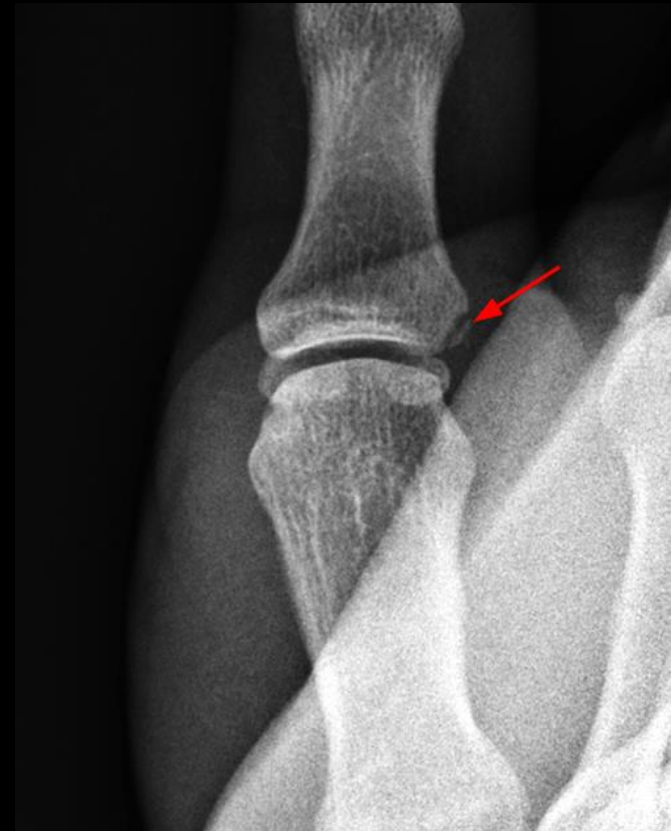MCP joint injuries: UCL—presentation, clinical exam

Table 1 A table demonstrating wide variability in different authors' definition of clinical evidence of a complete ligamentous tear

| Study | Collateral ligament | Position of thumb | Diagnosis of injury |
|-------------------------|---------------------|----------------------------|---|
| Frank and Dobyns [5] | UCL and RCL | Not stated | For UCL: >45° For RCL: >30° for men, >25° for women and children |
| Smith [25] | UCL and RCL | Full flexion and extension | >45° than the normal side |
| Bowers [52] | UCL | 25° flexion and extension | >20° absolute or >10° than the normal side |
| Palmer and Louis [53] | UCL | Full flexion | >35° absolute |
| Louis et al. [22] | UCL | Full flexion | >35° absolute |
| Derkash et al. [54] | UCL | Not stated | >45° than the normal side |
| Hintermann et al. [23] | UCL | Full flexion | >30° absolute |
| Musharafieh et al. [55] | UCL | 30° flexion and extension | >30° than the normal side |

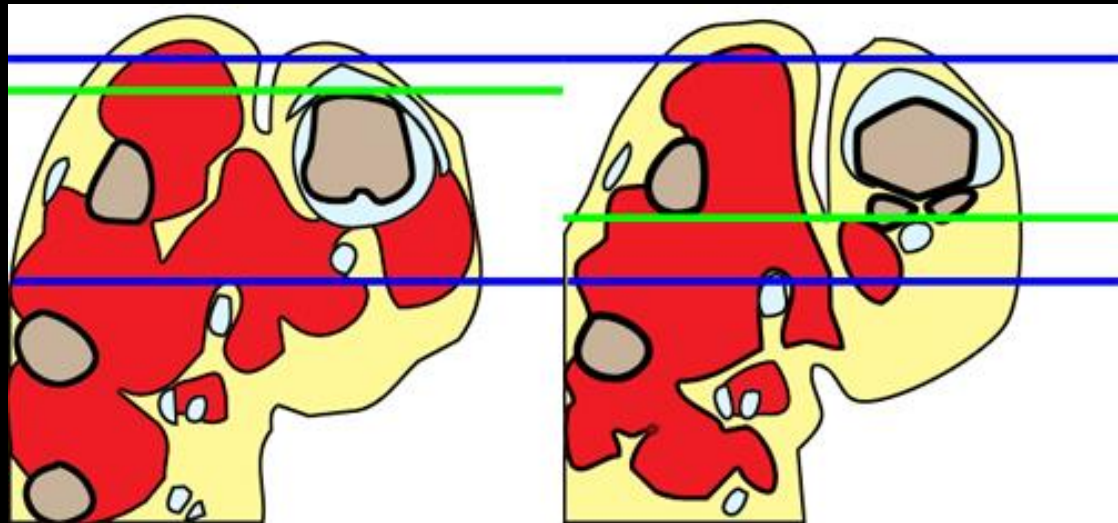
MCP joint injuries: UCL – imaging

- X-rays: avulsion fracture in up to 29-40%
- Even though they can be nondisplaced, cannot rule out complete UCL tear or Stener lesion
- Look for dislocation (lateral or longitudinal) of ulnar sesamoid



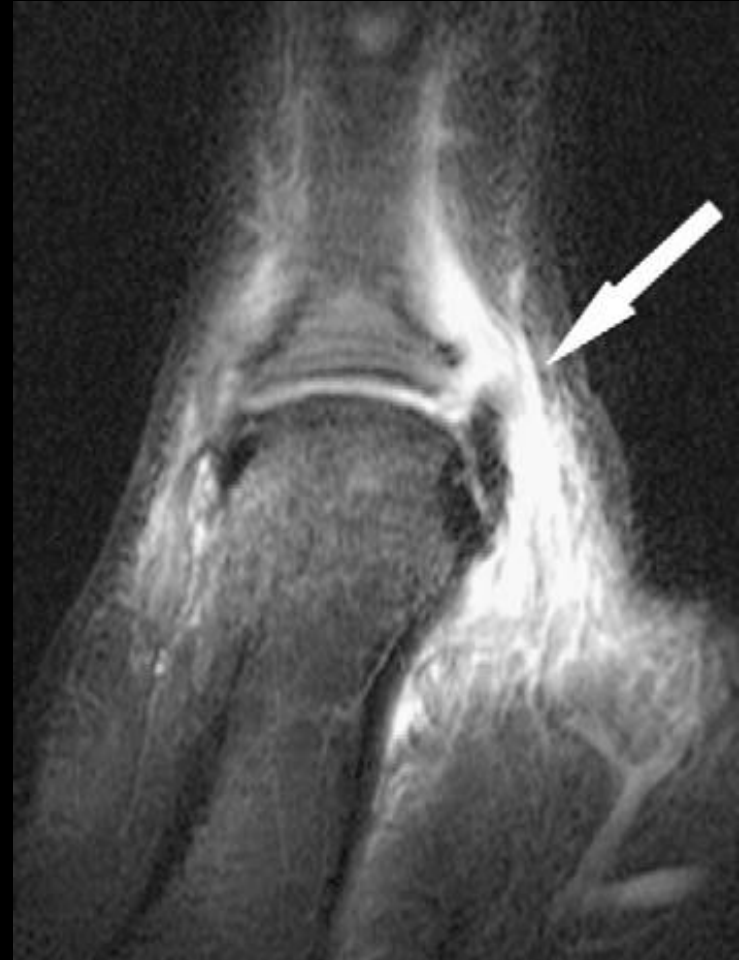MCP joint injuries: UCL – imaging

- MRI most sensitive
- Technique is important, coronals should be parallel to dorsal cortex
- US ok but operator dependent, not as sensitive



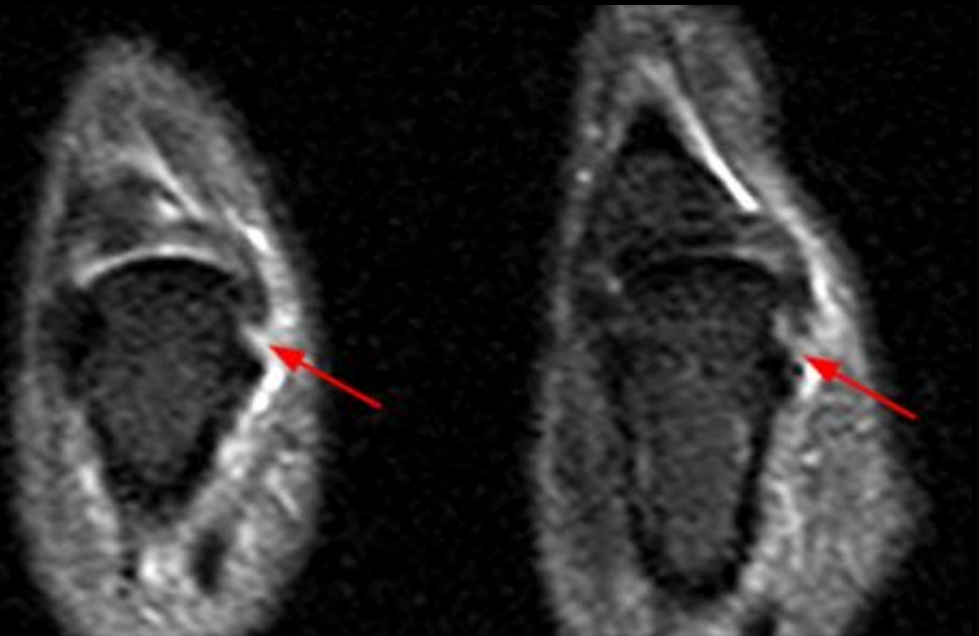
MCP joint injuries: UCL – imaging

- UCL tear most common at proximal phalanx



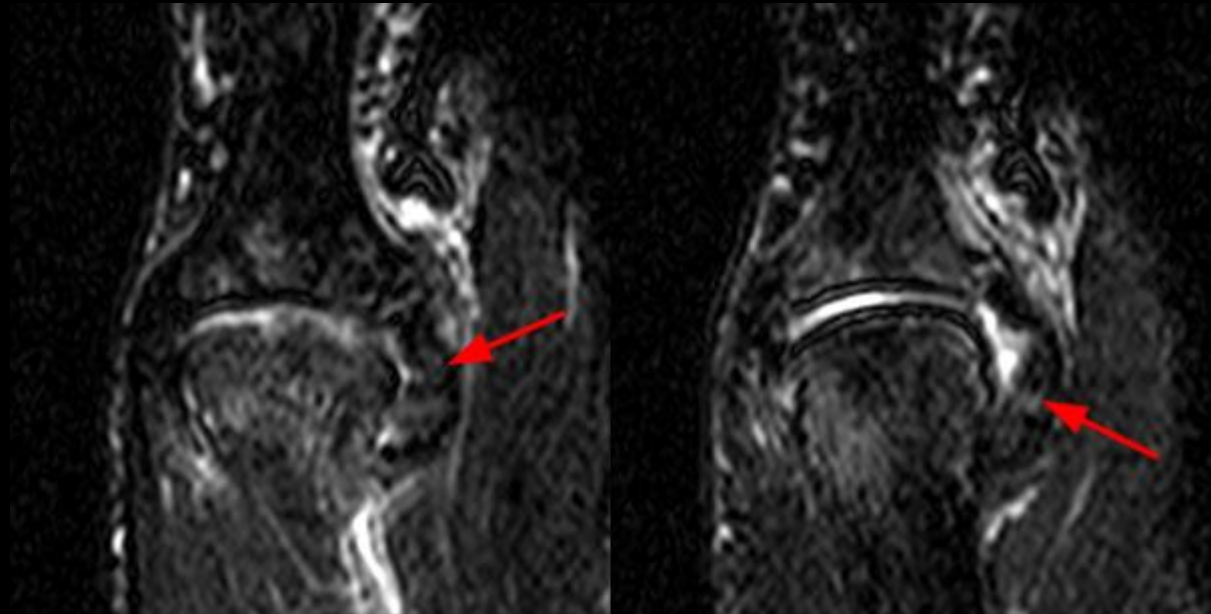
MCP joint injuries: UCL – imaging

- Tear of the UCL at metacarpal attachment



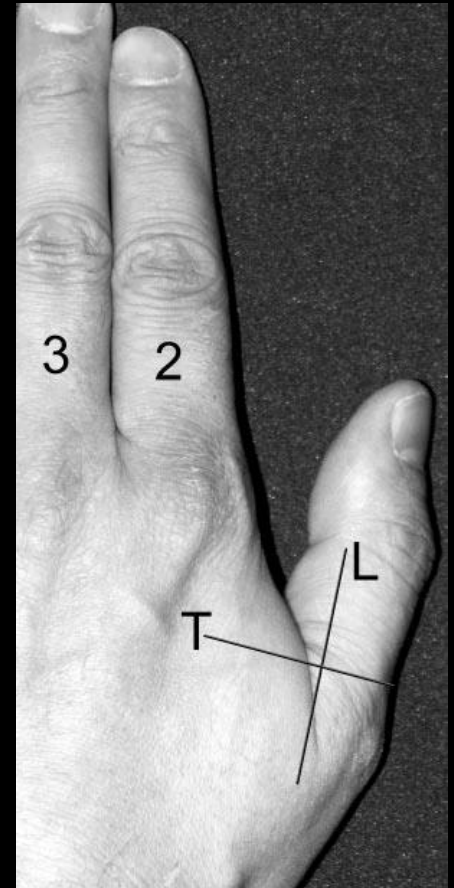
MCP joint injuries: UCL – imaging

- Chronic tear of the UCL



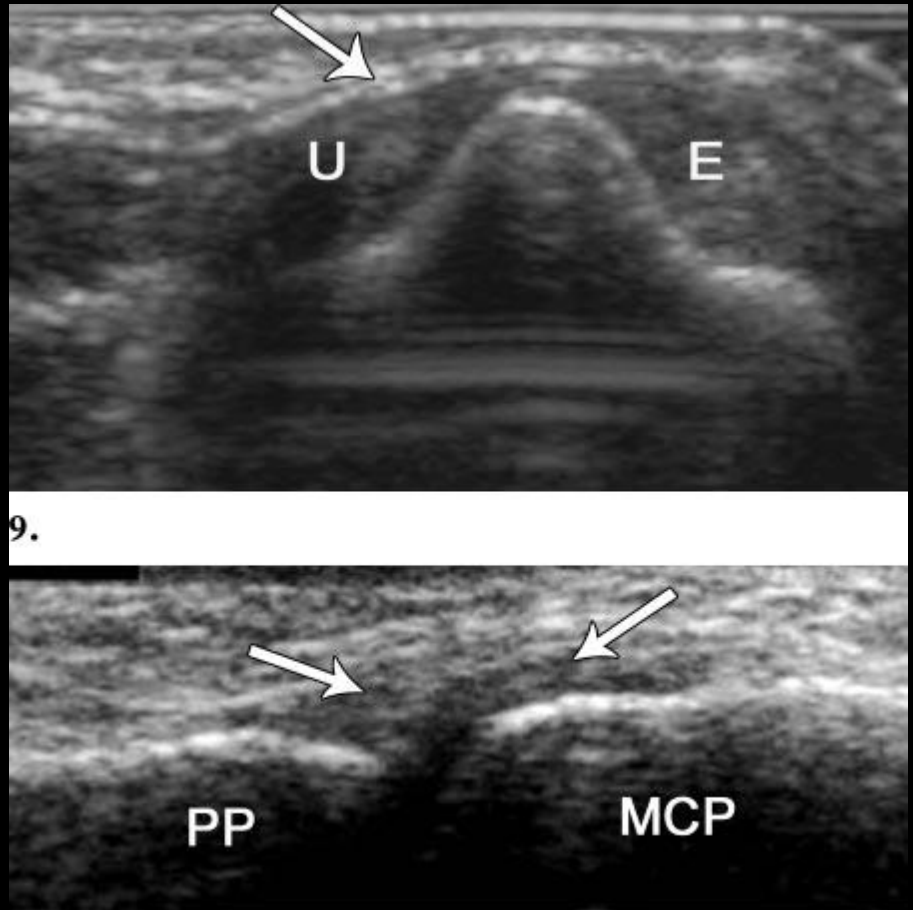
MCP joint injuries: UCL – imaging

- Ultrasound: 12-13 hz linear probe
- Hand flat on table



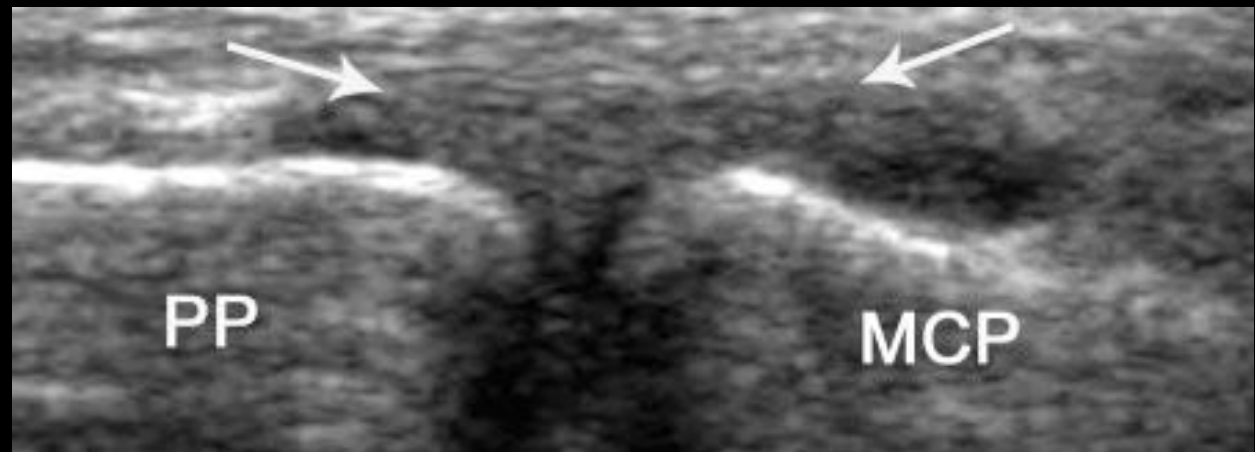
MCP joint injuries: UCL – imaging

- Normal axial and sagittal



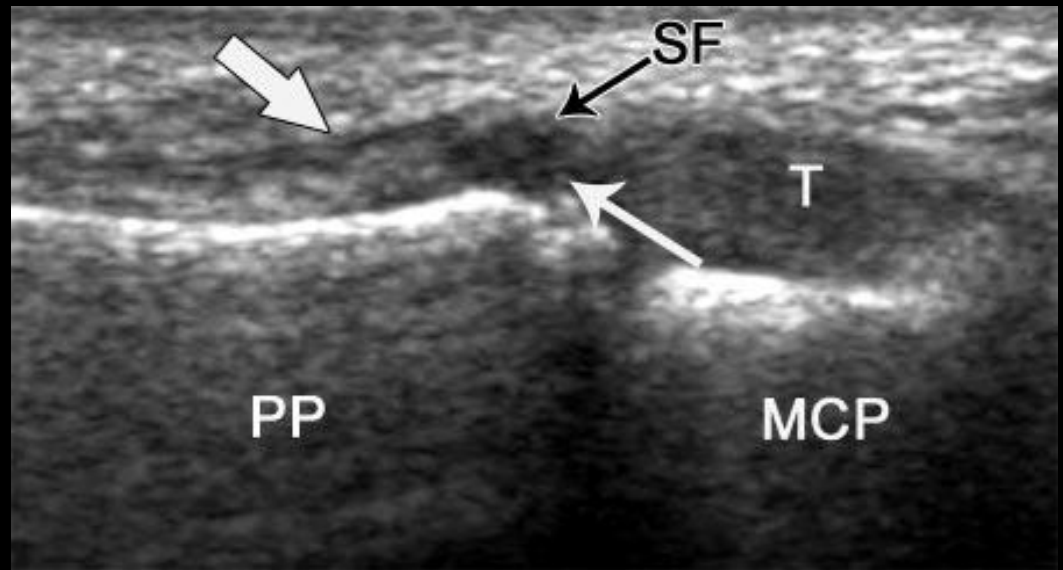
MCP joint injuries: UCL – imaging

- UCL strain
- Thickening of the UCL without a tear



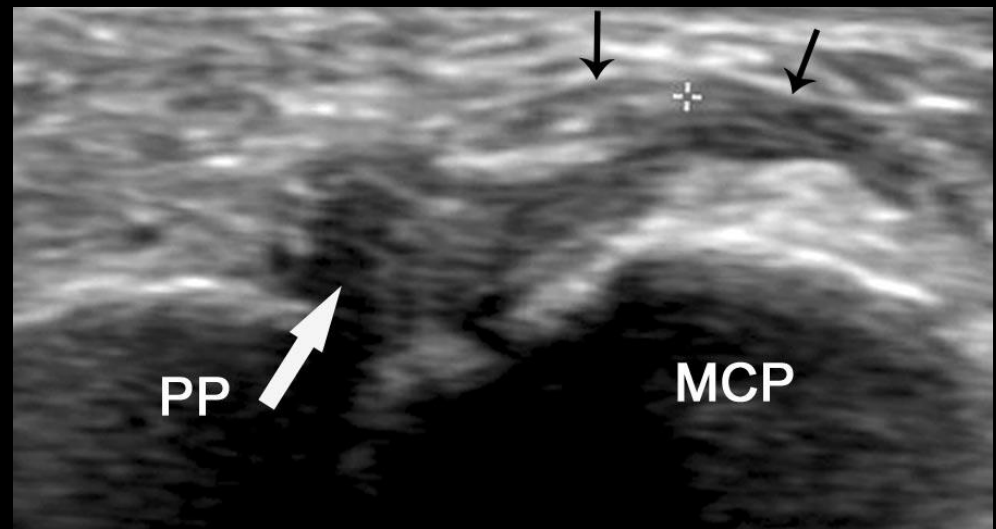
MCP joint injuries: UCL – imaging

- **partial tear UCL** (thin white arrow)
- Superficial fibers intact



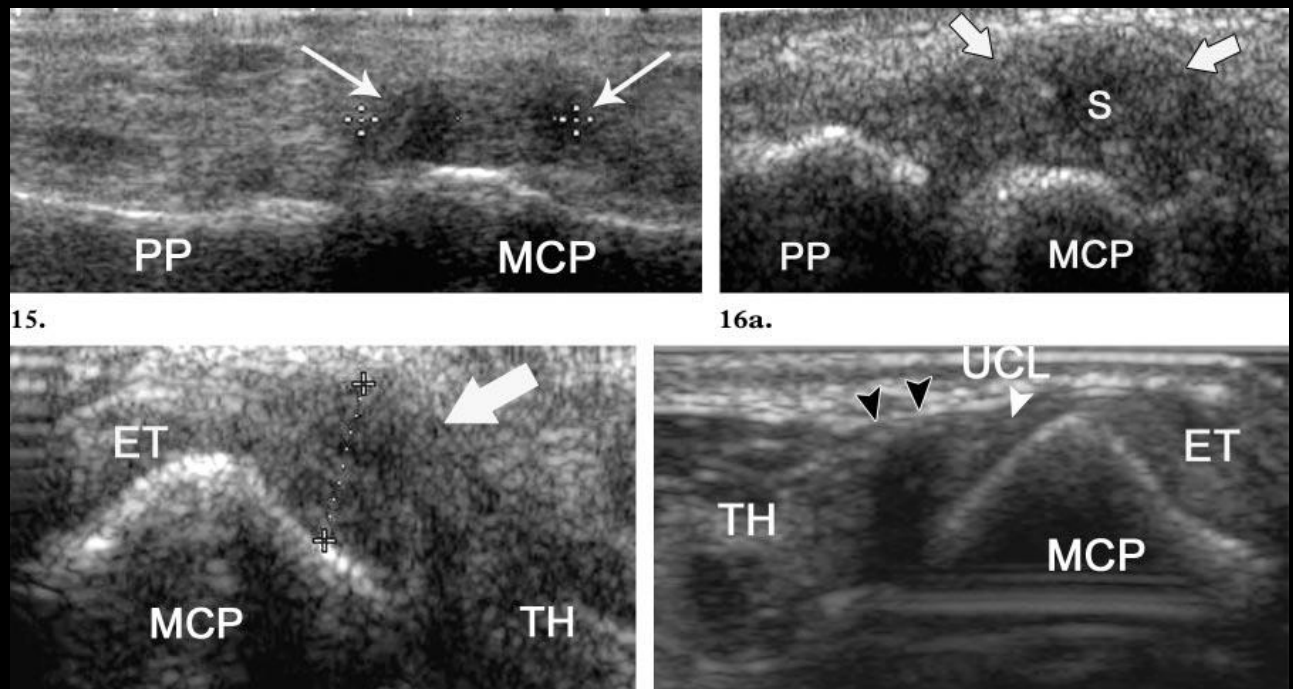
MCP joint injuries: UCL – imaging

- complete tear UCL
- Thin black arrows are the adductor aponeurosis



MCP joint injuries: UCL – imaging

- Stener lesion
- Bottom right image is the normal contralateral thumb



MCP joint anatomy – radial side

- Radial side has different anatomy as ulnar side
- Musculotendinous insertions weaker: 3 components
- 2 from flexor pollicis brevis tendon (FPB), and abductor pollicis brevis
- Although there are reported cases of “**Stener equivalent lesions**” in RCL they are extremely rare
- At ulnar side, adductor aponeurosis is more palmar in location, and UCL tears go proximal and dorsal with more ease
- At radial side, abductor aponeurosis is more dorsal and completely overlies the RCL

MCP joint anatomy – radial

- At radial side, abductor aponeurosis is more dorsal and completely overlies the RCL

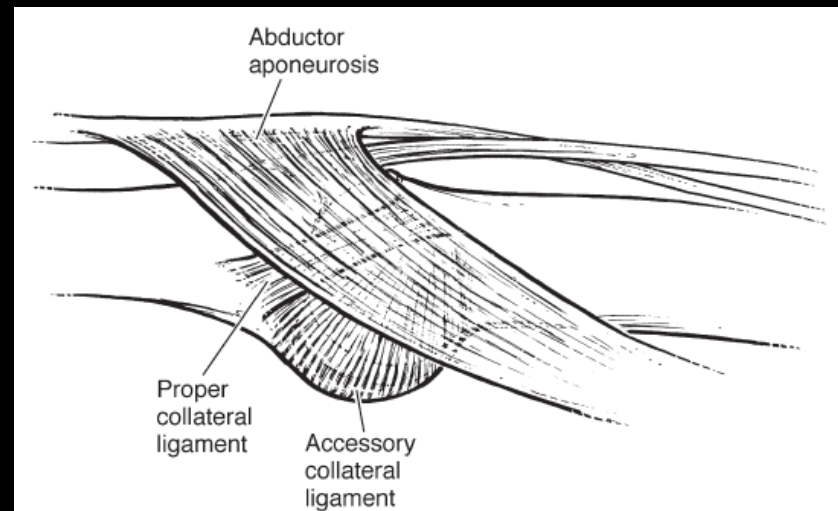


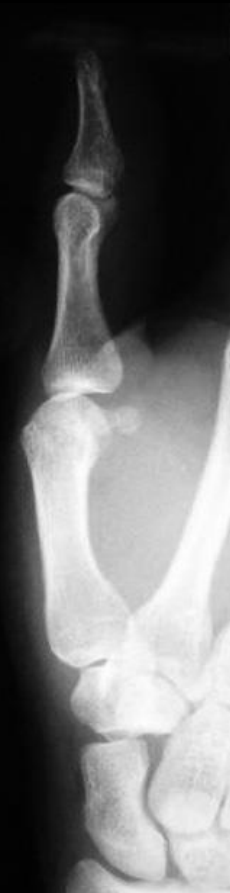FIGURE 1: Anatomy of the RCL. Note that abductor aponeurosis lies over the RCL, precluding Stener lesion formation.

MCP injuries: RCL – how?

- Forced and sudden adduction at MCP joint
- Fall on radial aspect of thumb, ball or player strikes thumb
- Radial instability results in volar and ulnar subluxation of proximal phalanx (adductor pollicis pulls)
- However, radial subluxation does not = RCL injury/instability due to normal variability
- Grading follows that of UCL:
 - Grade 1: incomplete tear, no instability
 - Grade 2: incomplete tear, some laxity
 - Grade 3: complete tear, instability

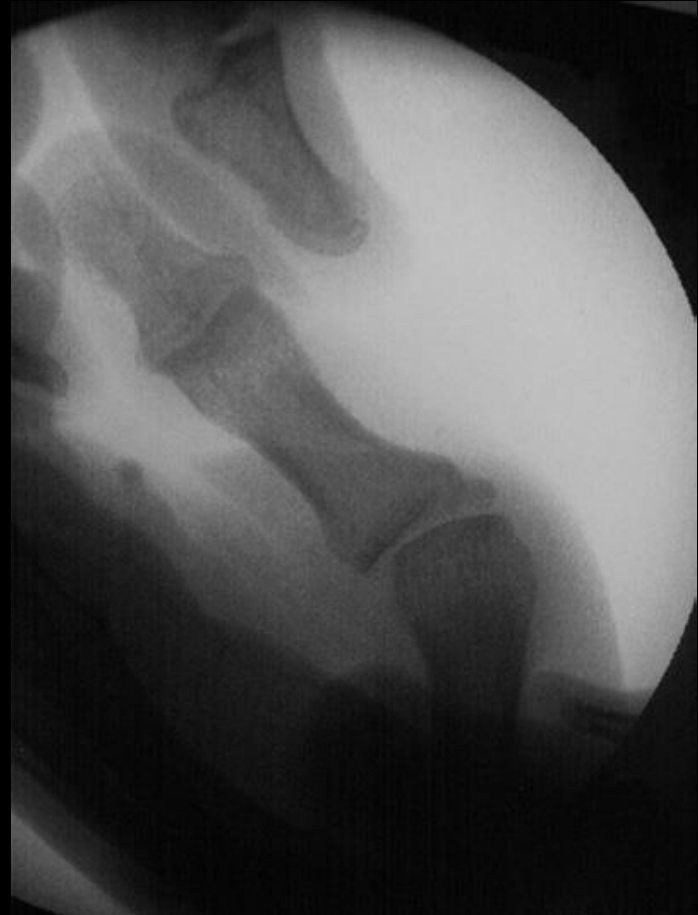MCP injuries: RCL – imaging

- RCL injury with volar subluxation of the thumb proximal phalanx
- > 3 mm usually means complete tear



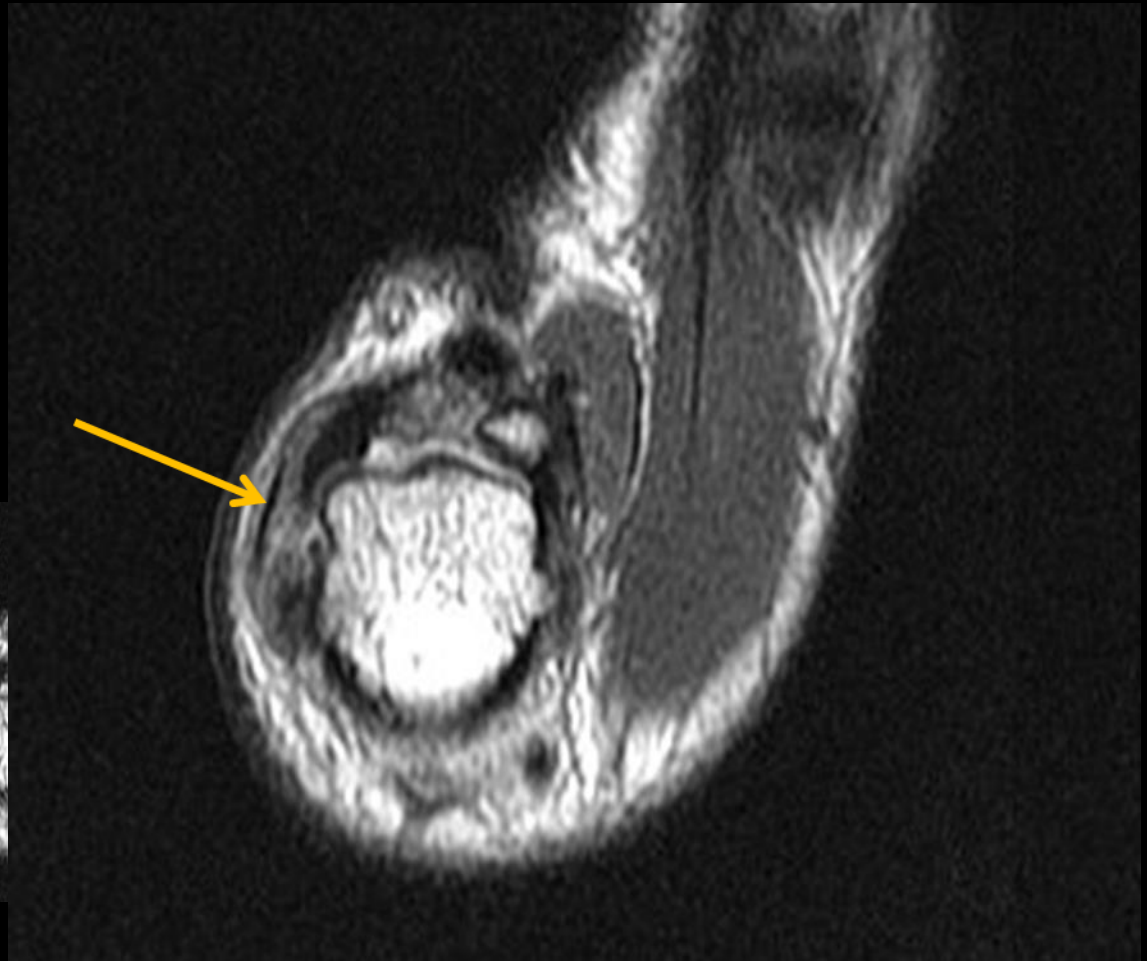
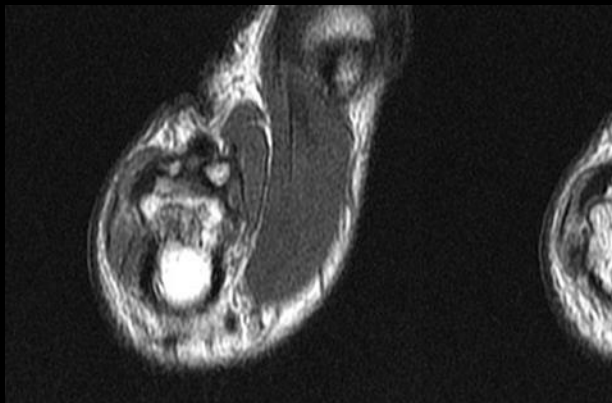
MCP injuries: RCL – imaging

- Fluoroscopy spot image showing **radial instability**
- > 30 degrees, or 15 degrees more than contralateral side usually means complete tear (for this author)
- MRI, US usually not needed



MCP injuries: RCL – imaging

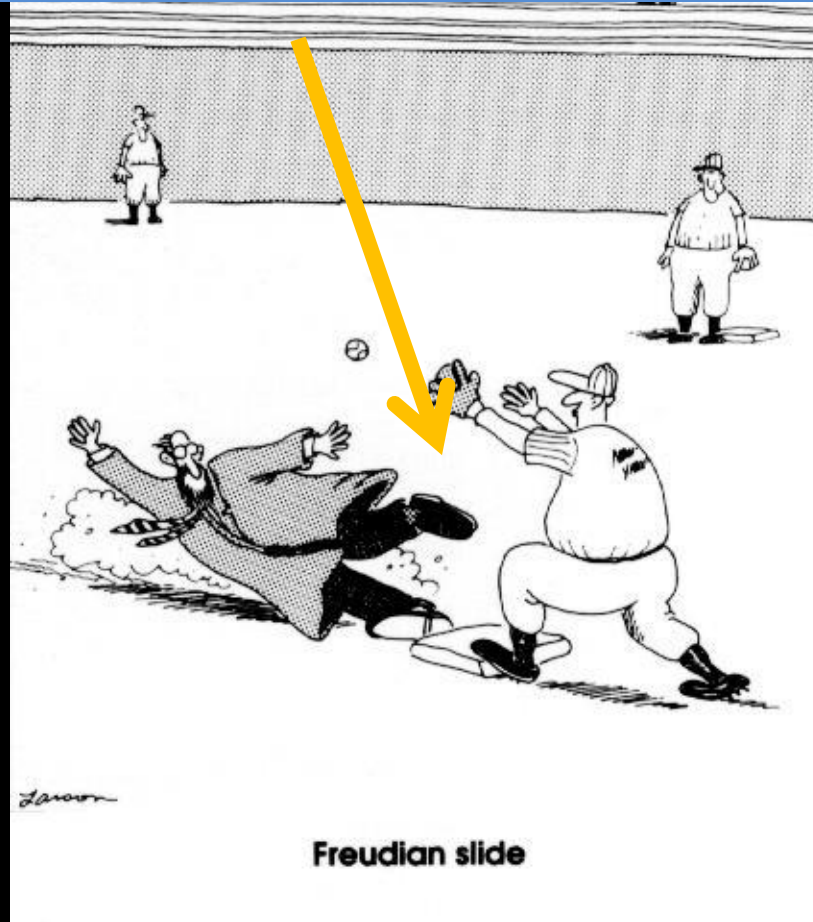
- Complete RCL tear



MCP injuries: RCL – treatment

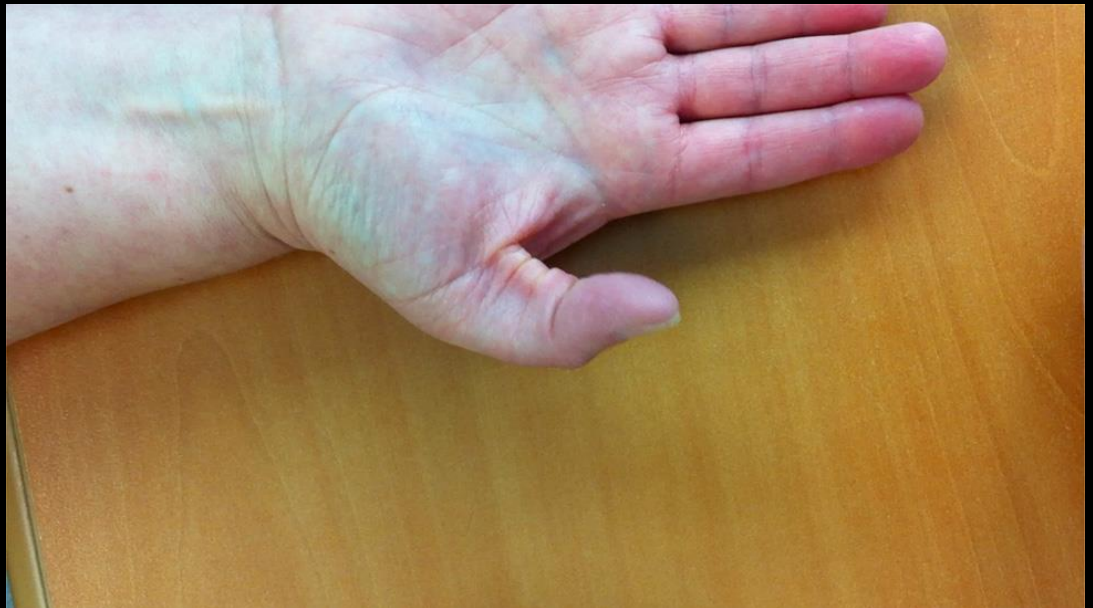- **Incomplete** – usually conservative
- **Complete** – should do surgery as ulnar pull of EPL maintains ulnar deviation and will cause RCL to heal in an elongated fashion
- Leads to instability and osteoarthritis
- Although Stener lesion exceedingly unlikely, these should still be repaired
- Many techniques including direct repair or ligament reconstruction

What the UCSD bone fellow wants to do to the orthopedic surgery resident for calling him at 4 am for a non-stat MRI request “just to make sure it gets done the next day”



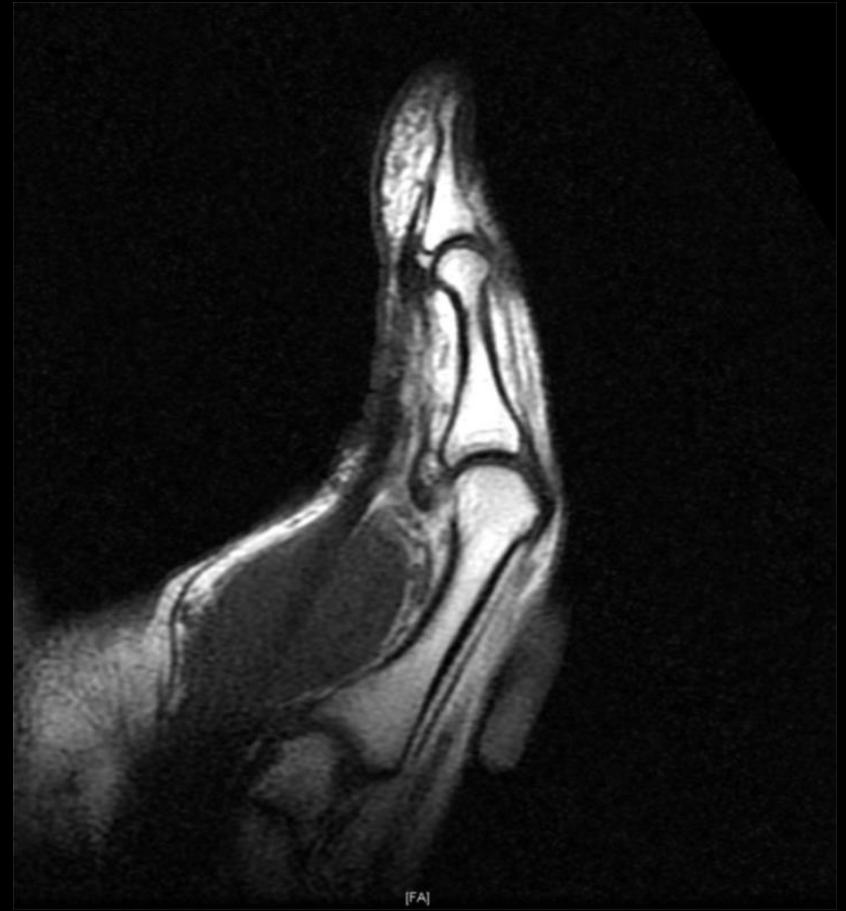Thumb case

- 48 year old female with pain, consulted hand surgery service after loss of IP flexion for 2 years after tenosynovitis
- Not a rock climber



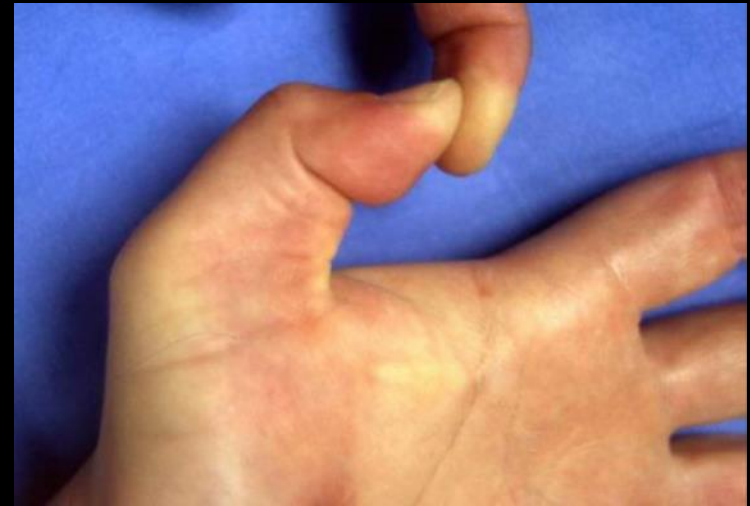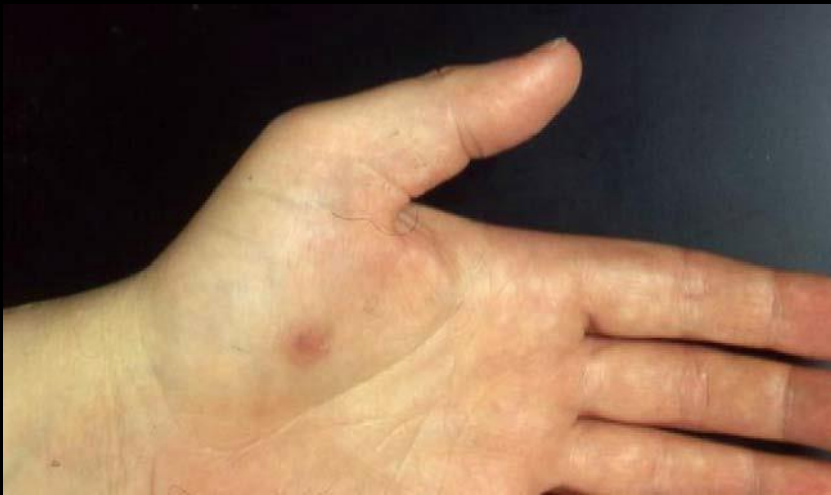Thumb case

- MRI was performed
- Tear of A1, oblique pulleys with bowstringing of the flexor pollicis longus tendon



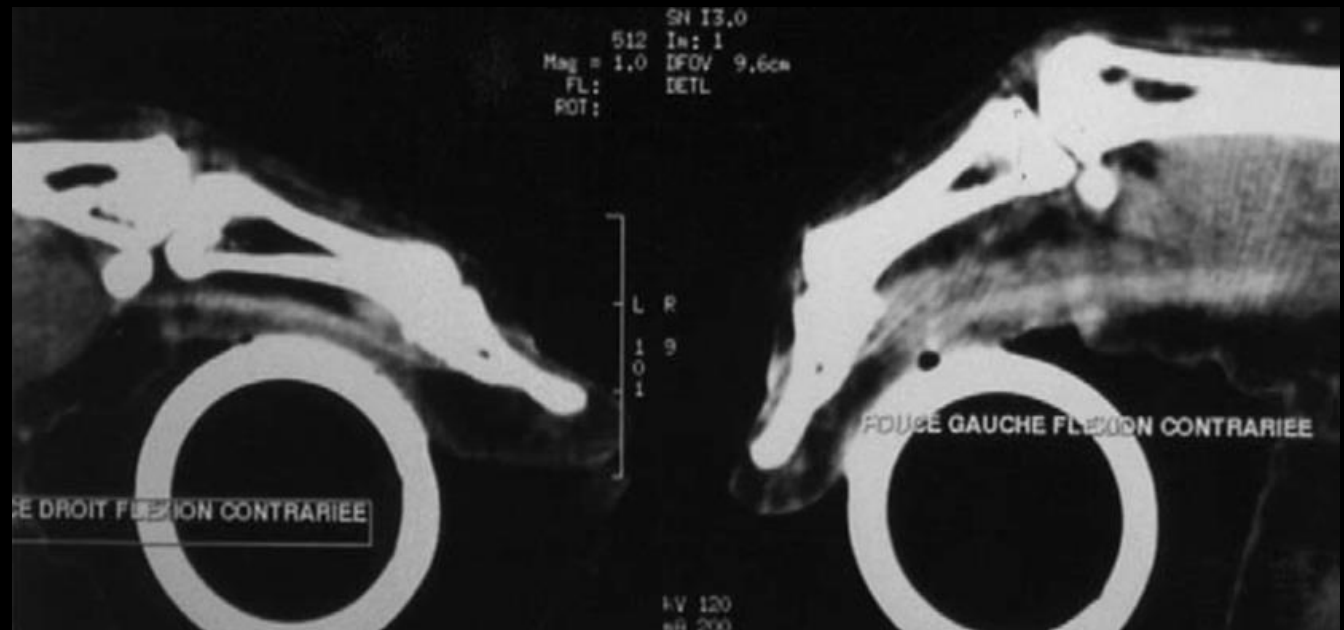
Thumb case

- 37 year old female with 2 month history of pain in left dominant thumb, flexion at the IP joint, and weak grip. Steroid injection by rheumatologist in left carpal tunnel, 3 weeks later heard a clicking sound while opening push chair.



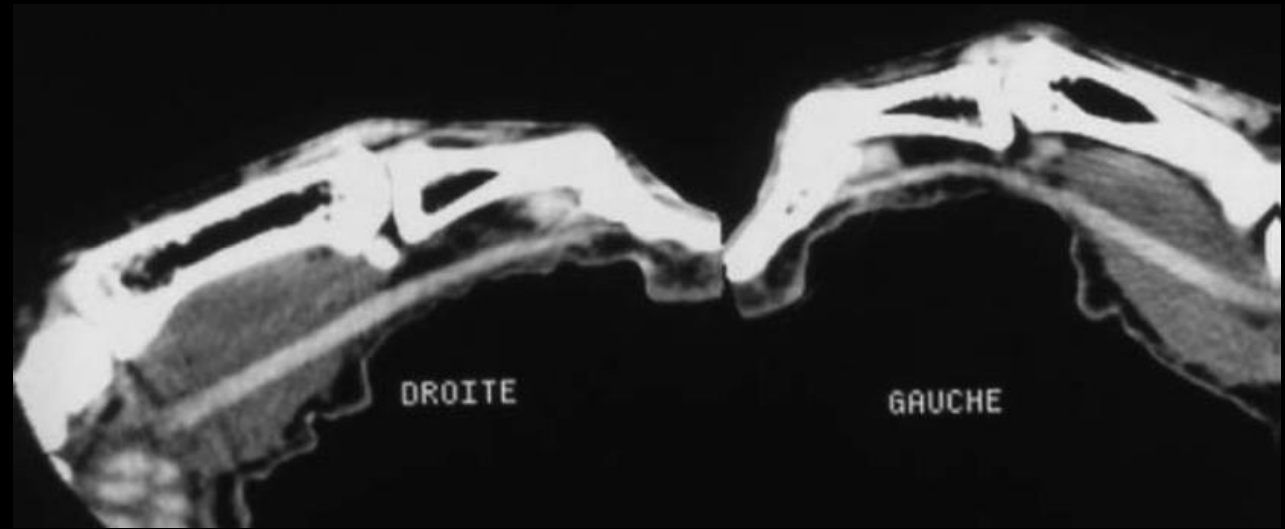Thumb case

- CT scan was performed with active flexion against resistance, including the contralateral normal hand
- Tears of all thumb pulleys with bowstringing



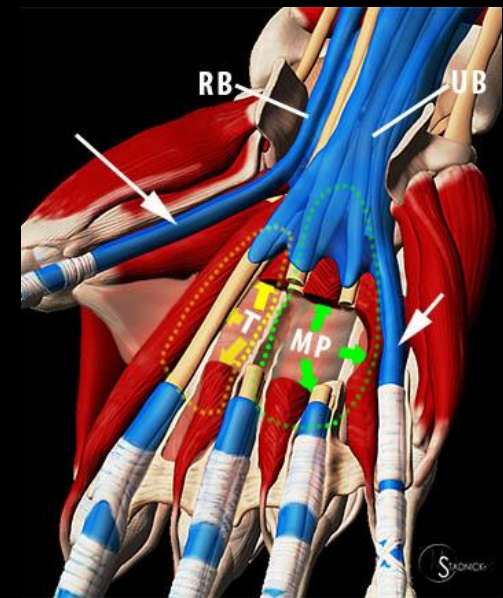
Thumb case

- Postoperative CT scan was performed with active flexion showing resolution of bowstringing after pulley repair



pulley system injury

- Thumb pulley injuries are very uncommon, with very few cases reported
- First case reported by Tropet in 1990 in a rock climber
- 3 cases shown by 2 authors were all **related to tenosynovitis**, without trauma
- 2 cases by Wilson—both associated with **steroid injections** (carpal tunnel, thumb MCP joint)

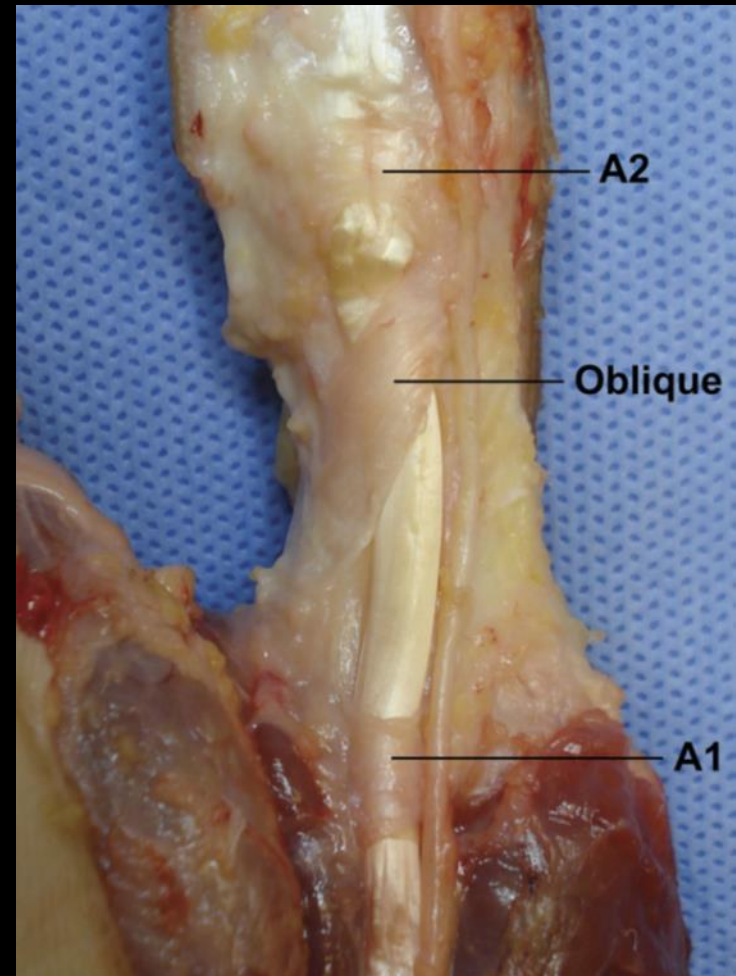
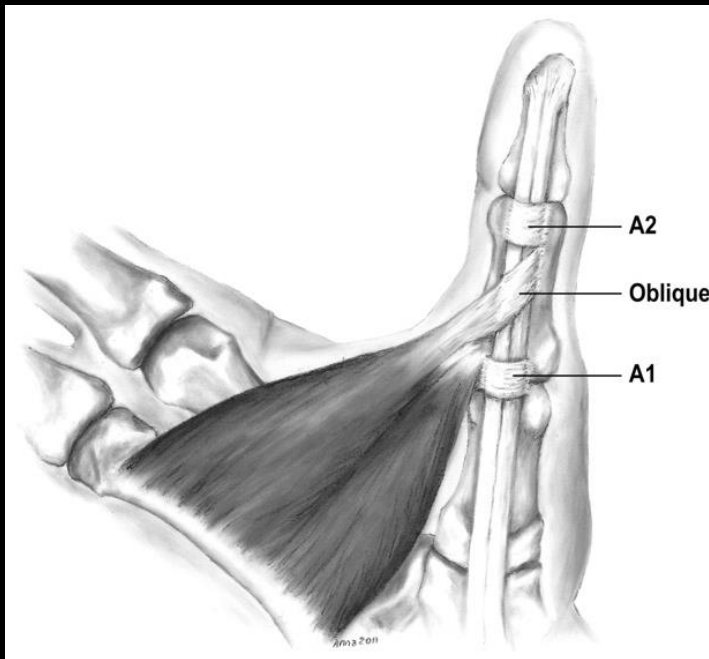


Pulley system anatomy

- Differs from that of the fingers
- 4 pulleys: A1, A2, oblique, and variable annular (Av)
- Av pulley more recently described by Schubert 2012
- Schubert studied 75 hands
 - A1 and A2 present in all hands
 - oblique pulley in 74 hands
 - Av pulley in 70 hands
- 4 different types of arrangements: Type 1-4

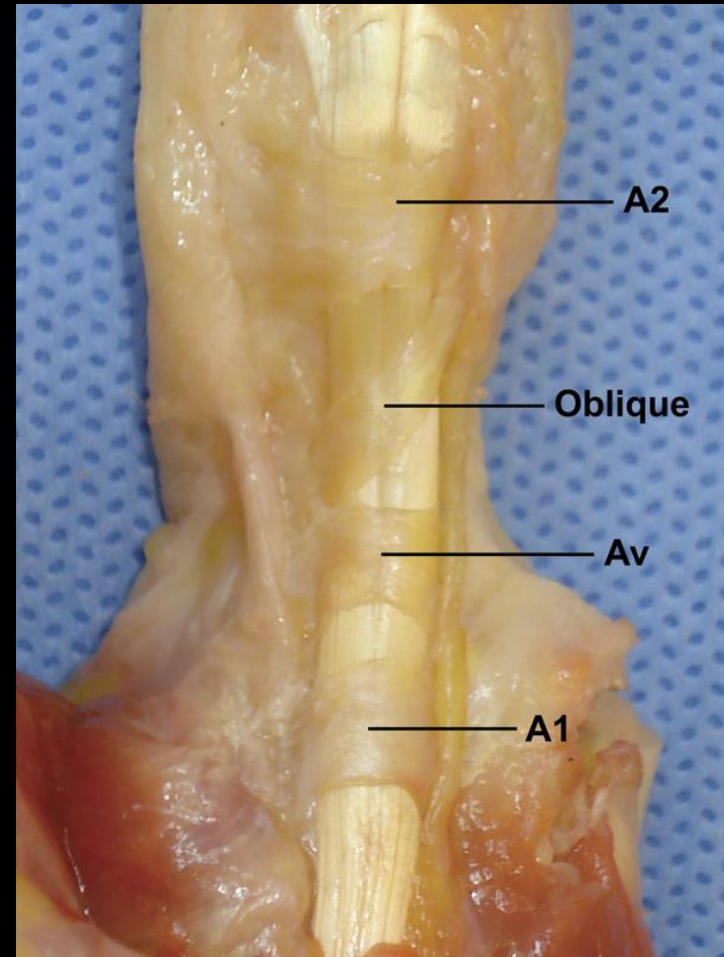
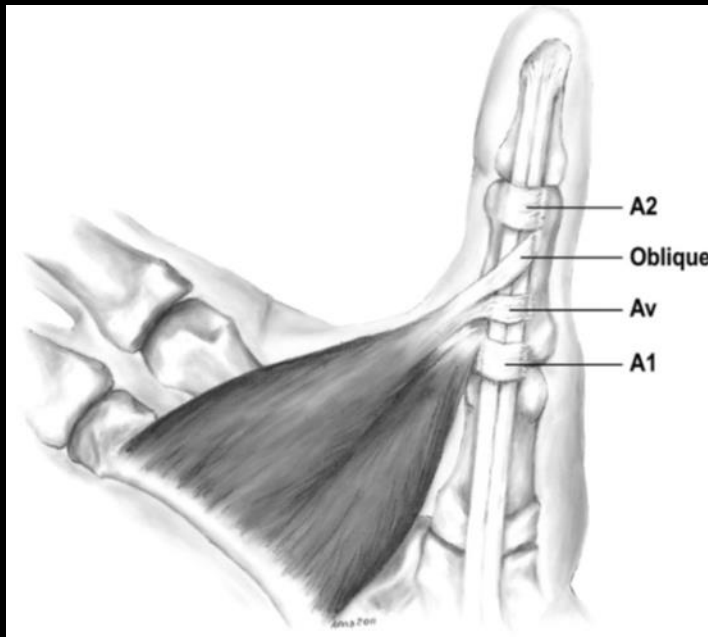
Pulley system anatomy

- **Type 1: 7%**
- A1, A2, oblique



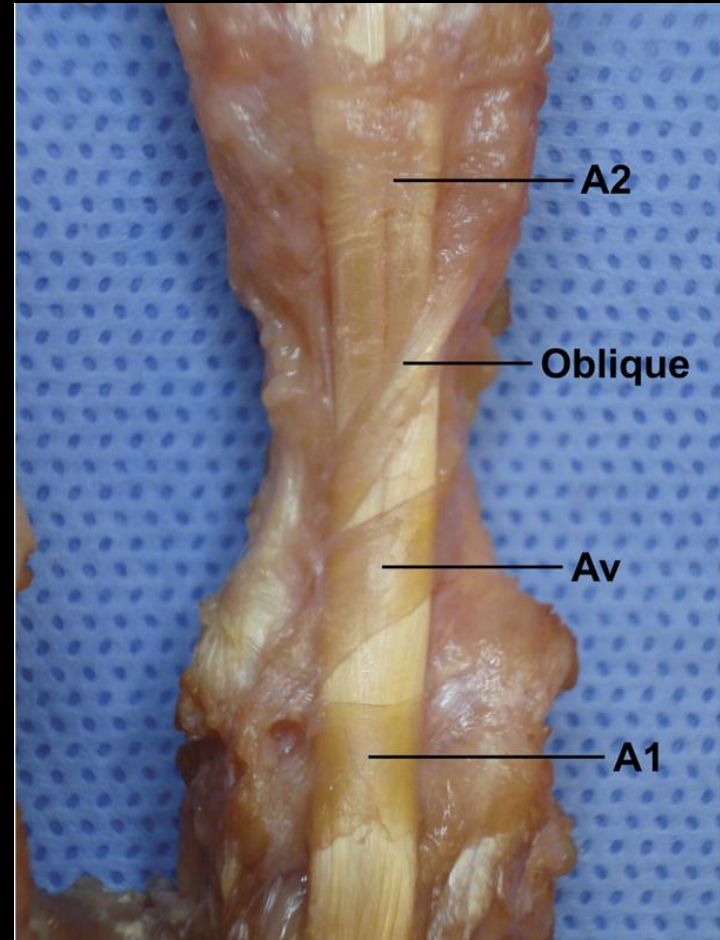
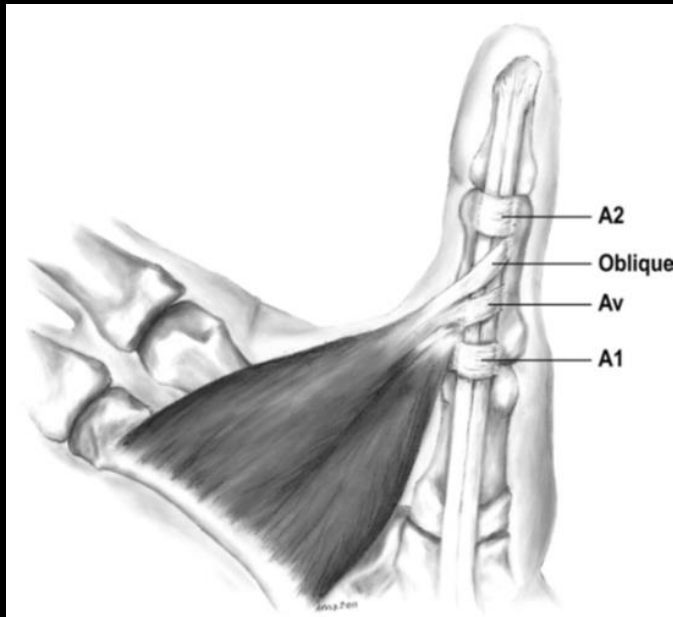
Pulley system anatomy

- **Type 2:** 39%
- A1, A2, oblique, Av (fibers parallel and separate from A1)



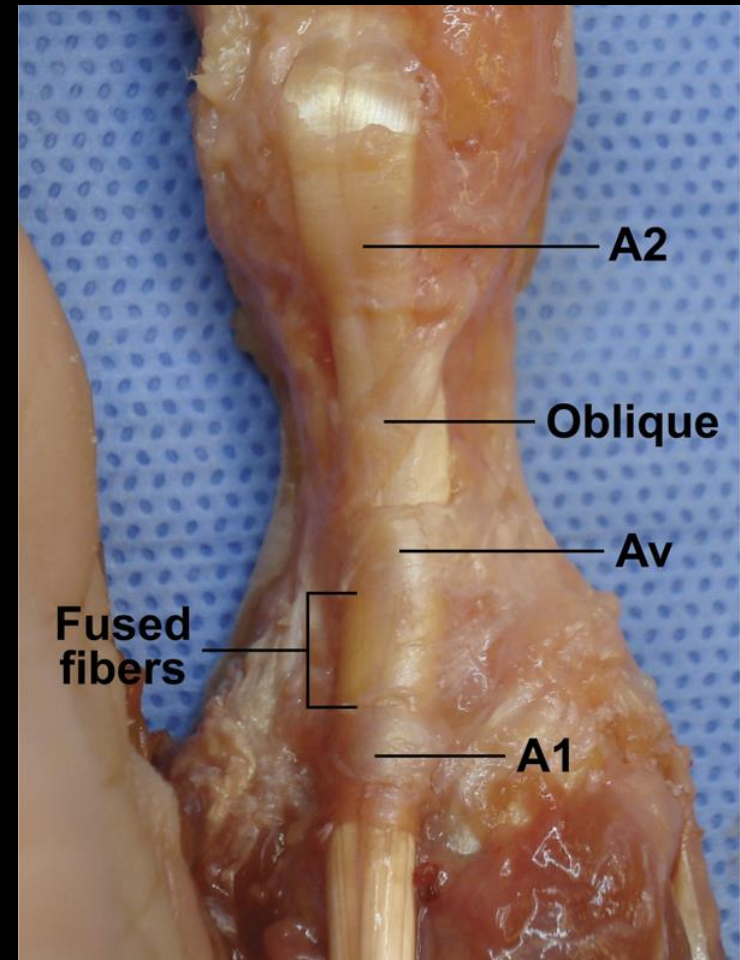
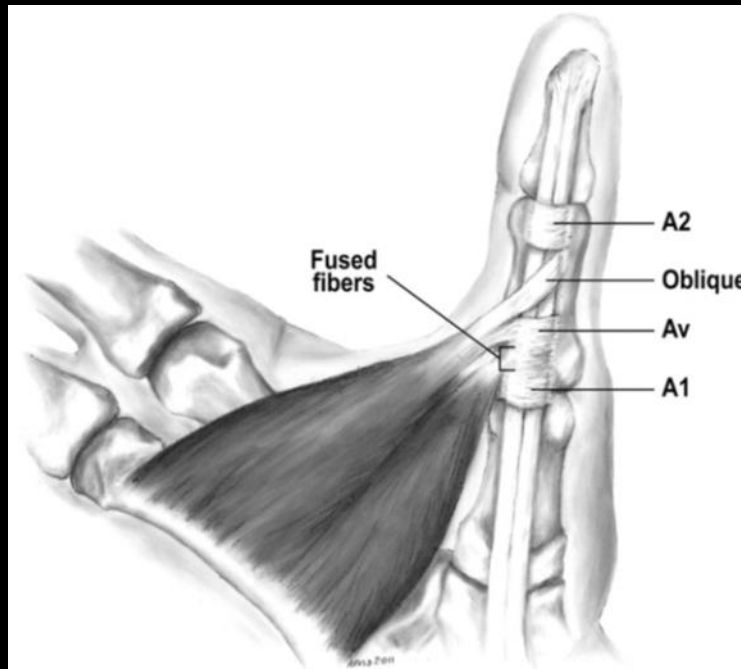
Pulley system anatomy

- **Type 3: 39%**
- A1, A2, oblique, Av (oblique fibers that span distal from ulnar to radial, or Av pulley with a triangle shape with transverse and oblique heads)



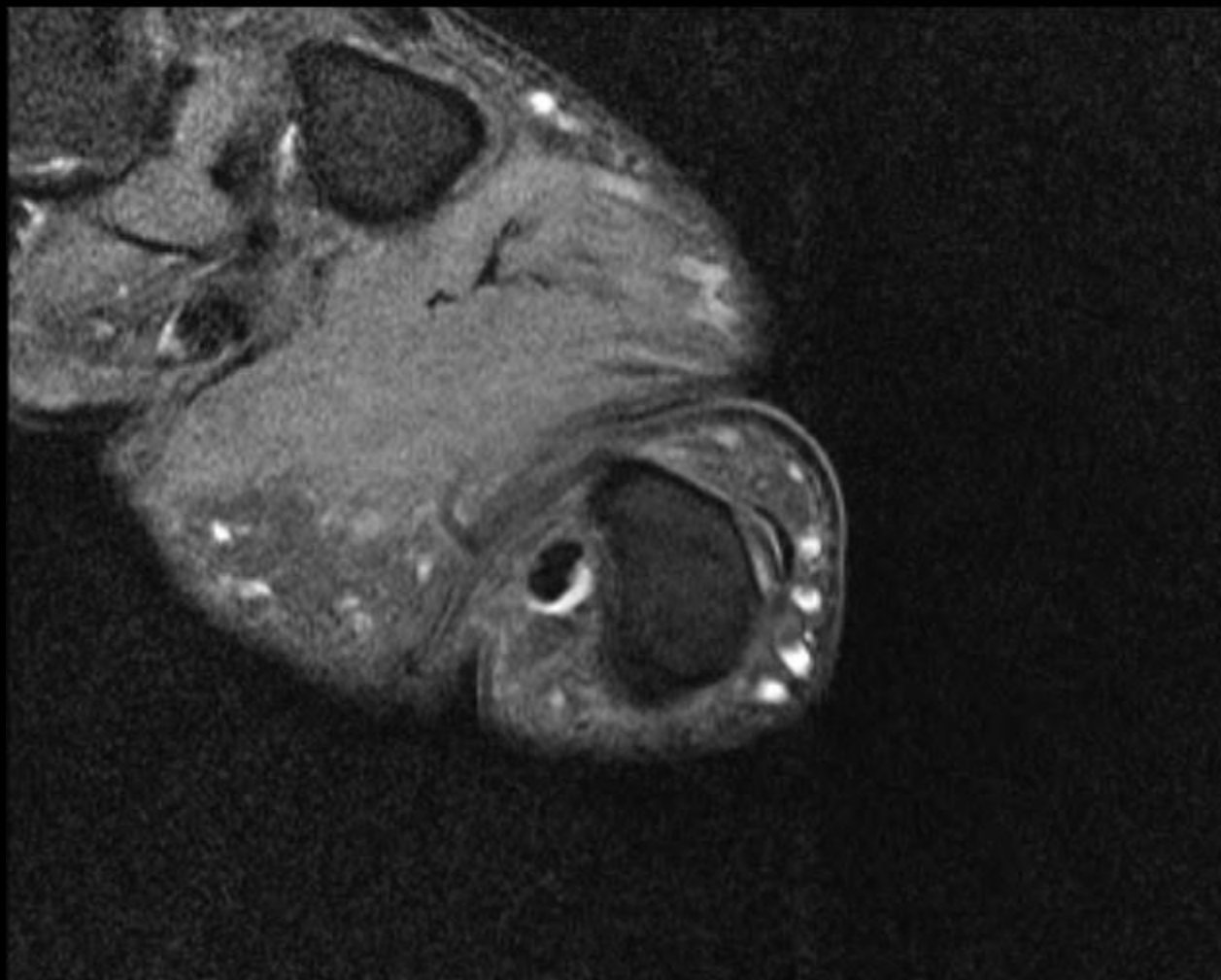
Pulley system anatomy

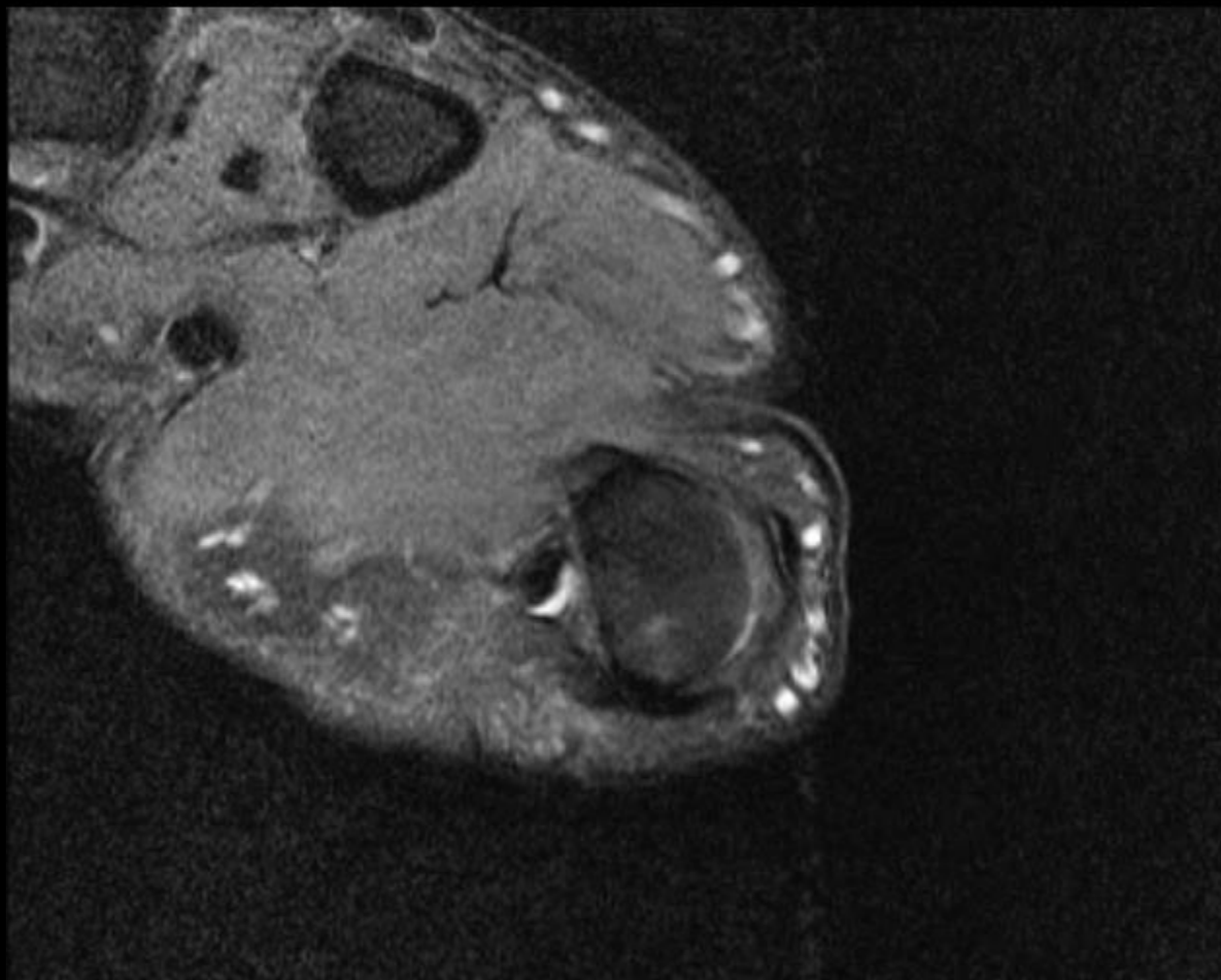
- **Type 4:** 16%
- A1, A2, oblique, Av (Av fused to A1 pulley, line of demarcation is present)

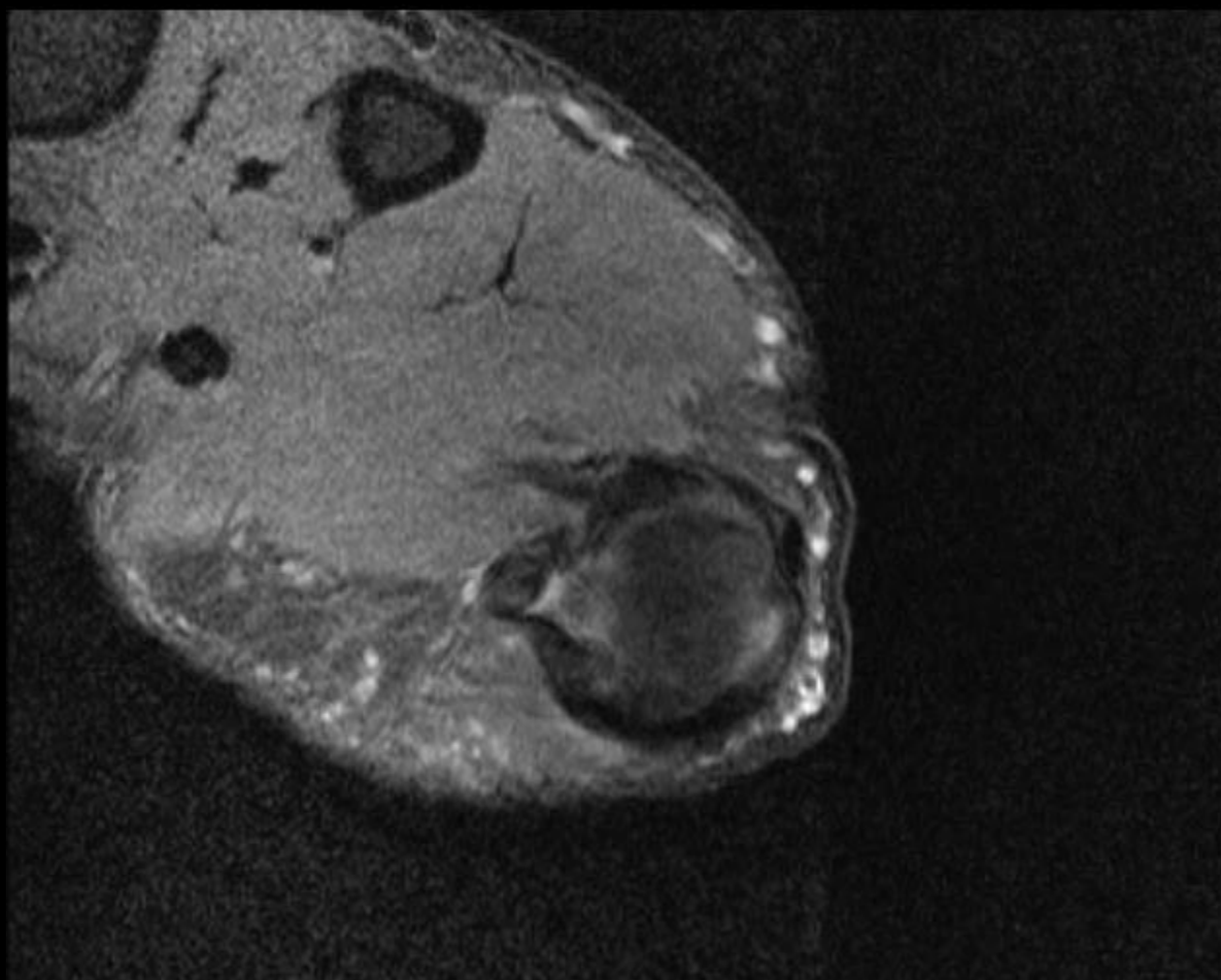


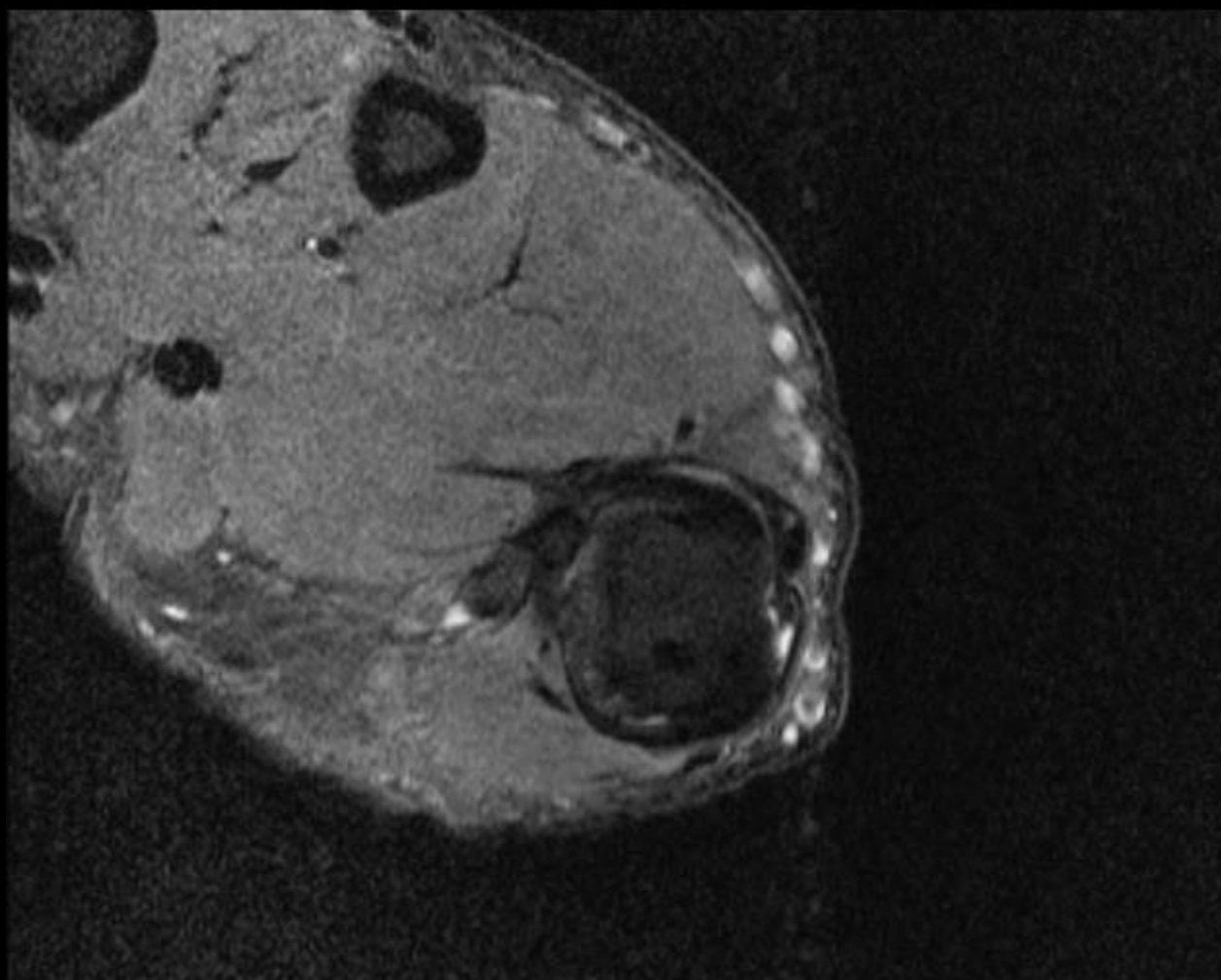
Thumb case

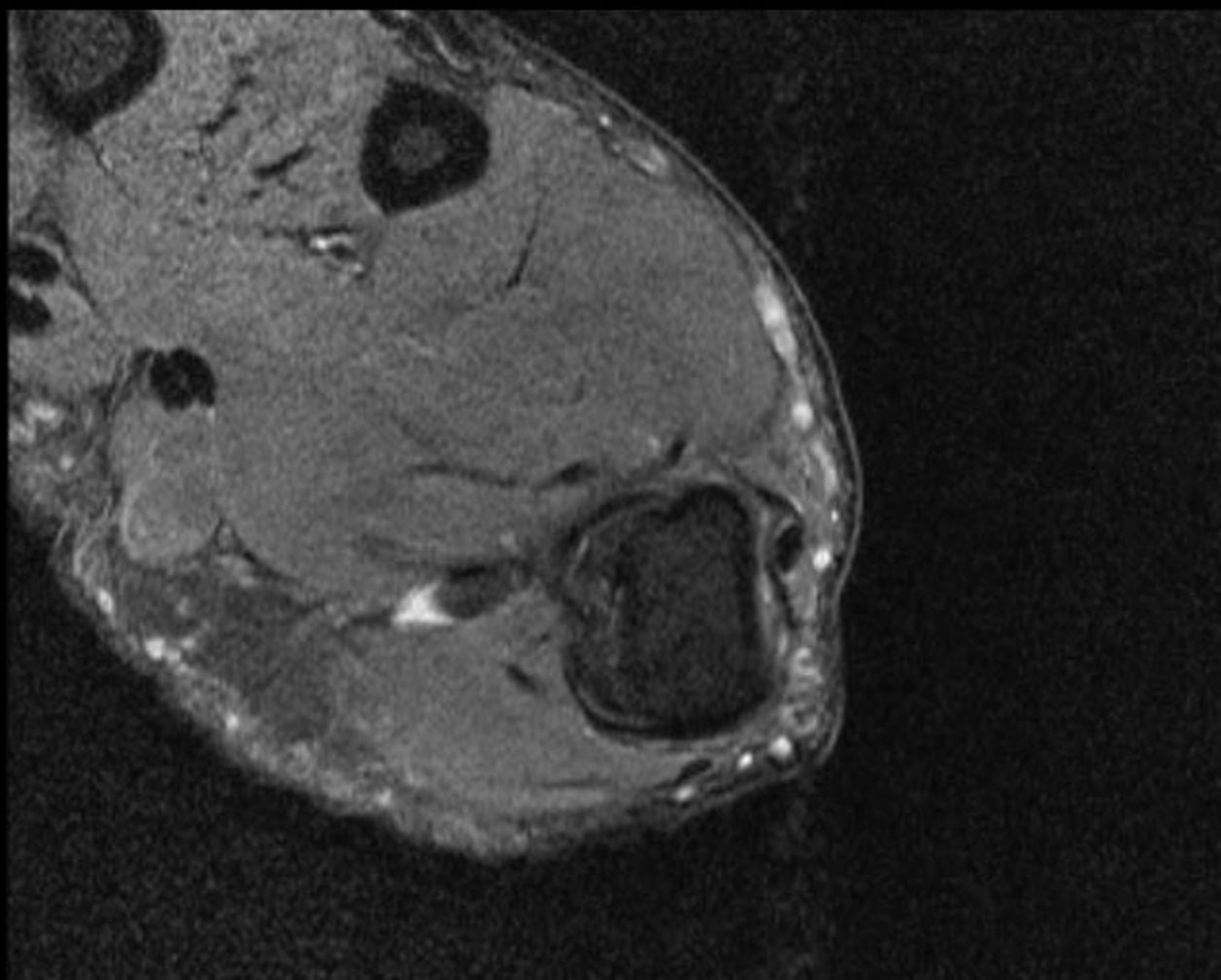
- 41 year old male with pain in left wrist and thumb as well as clicking and decreased strength. Symptoms were brought on by recent hyperextension injury.

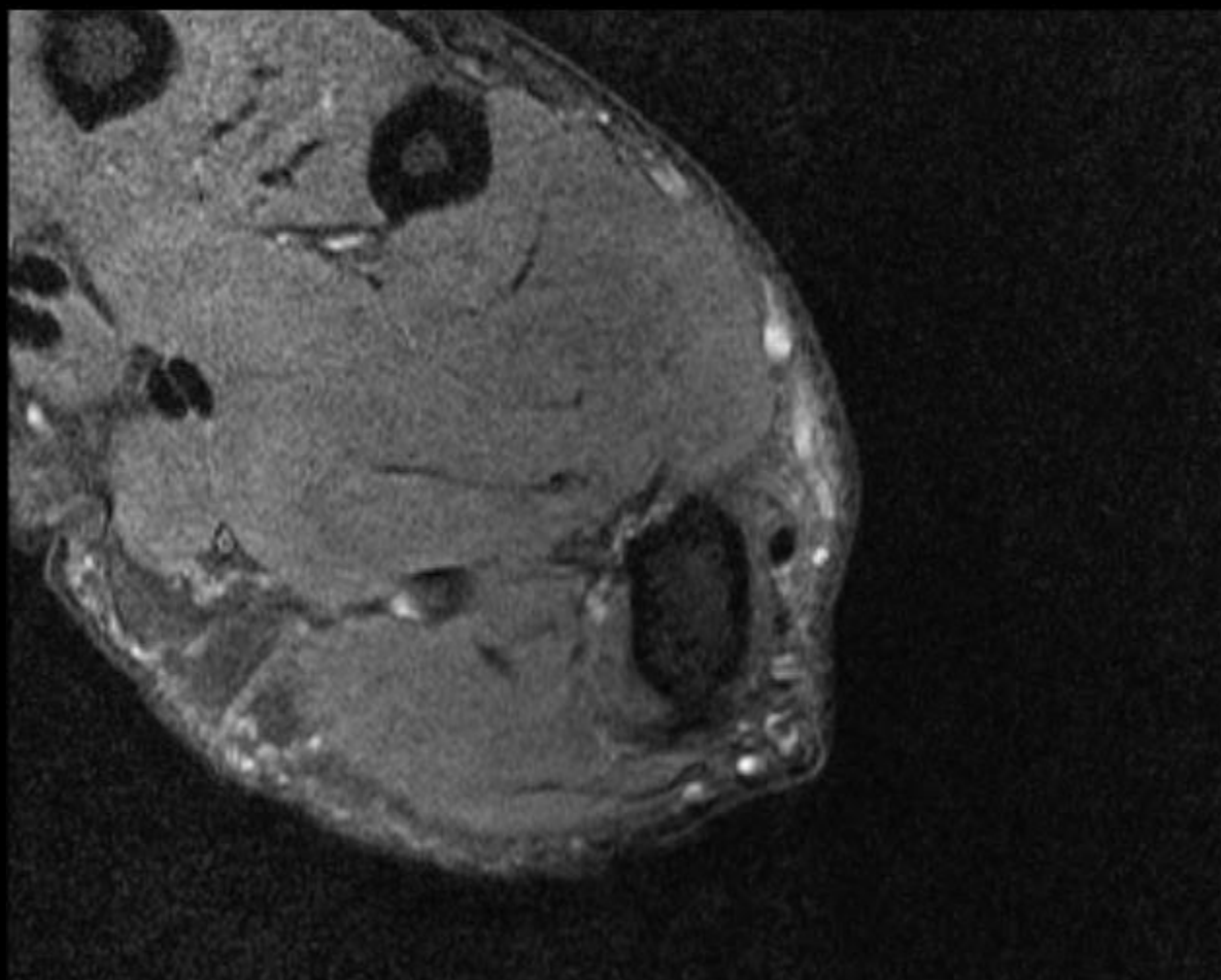


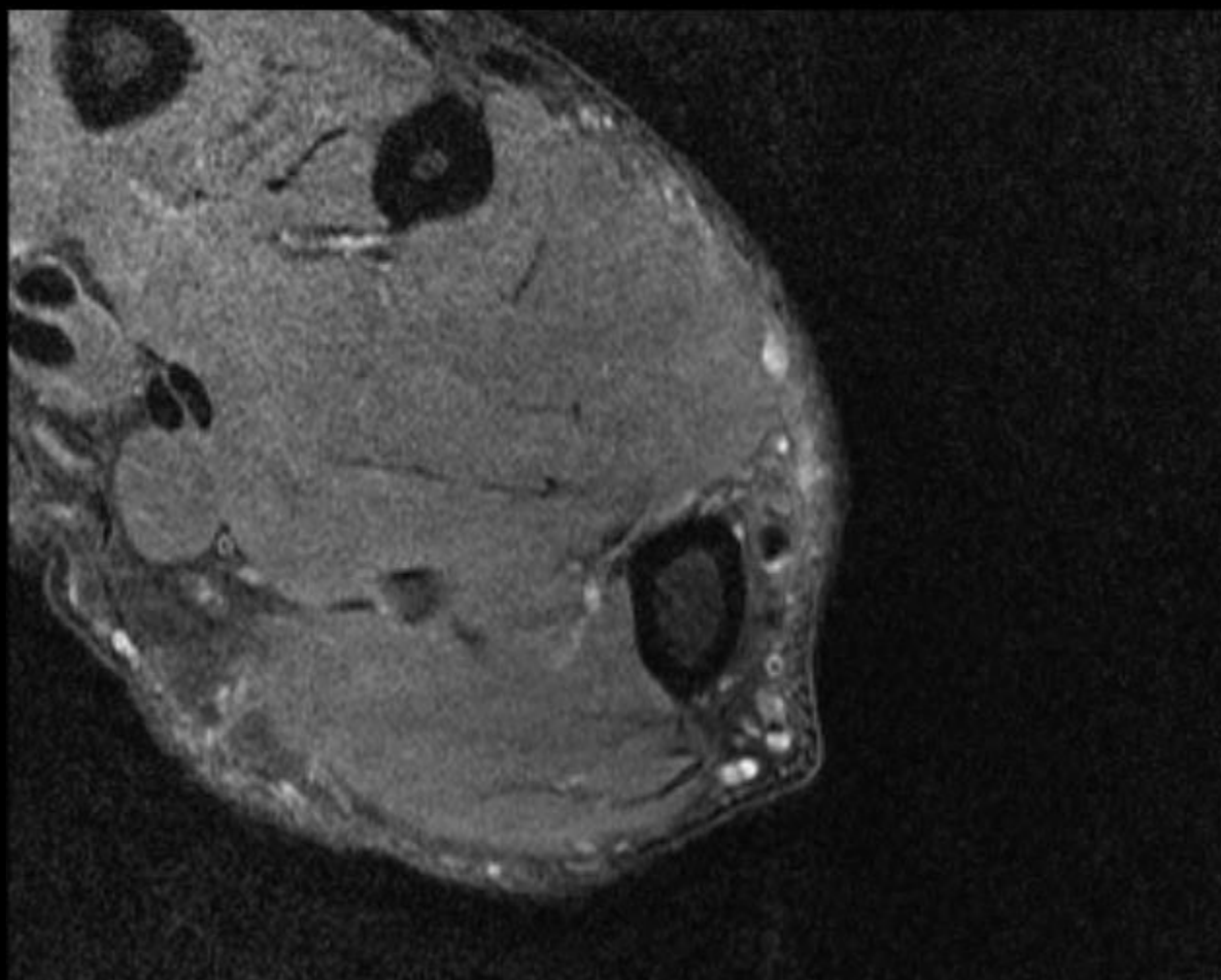


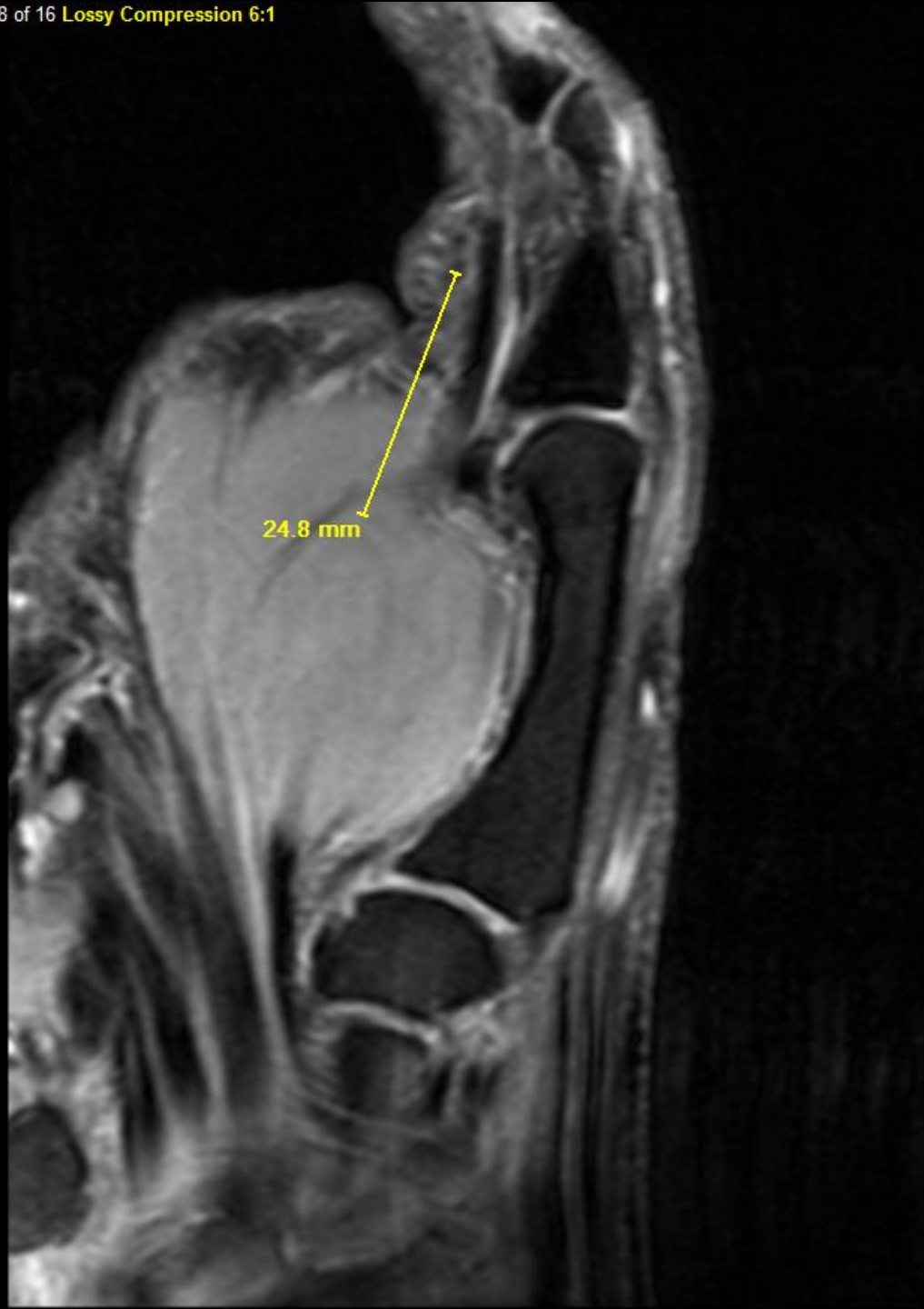





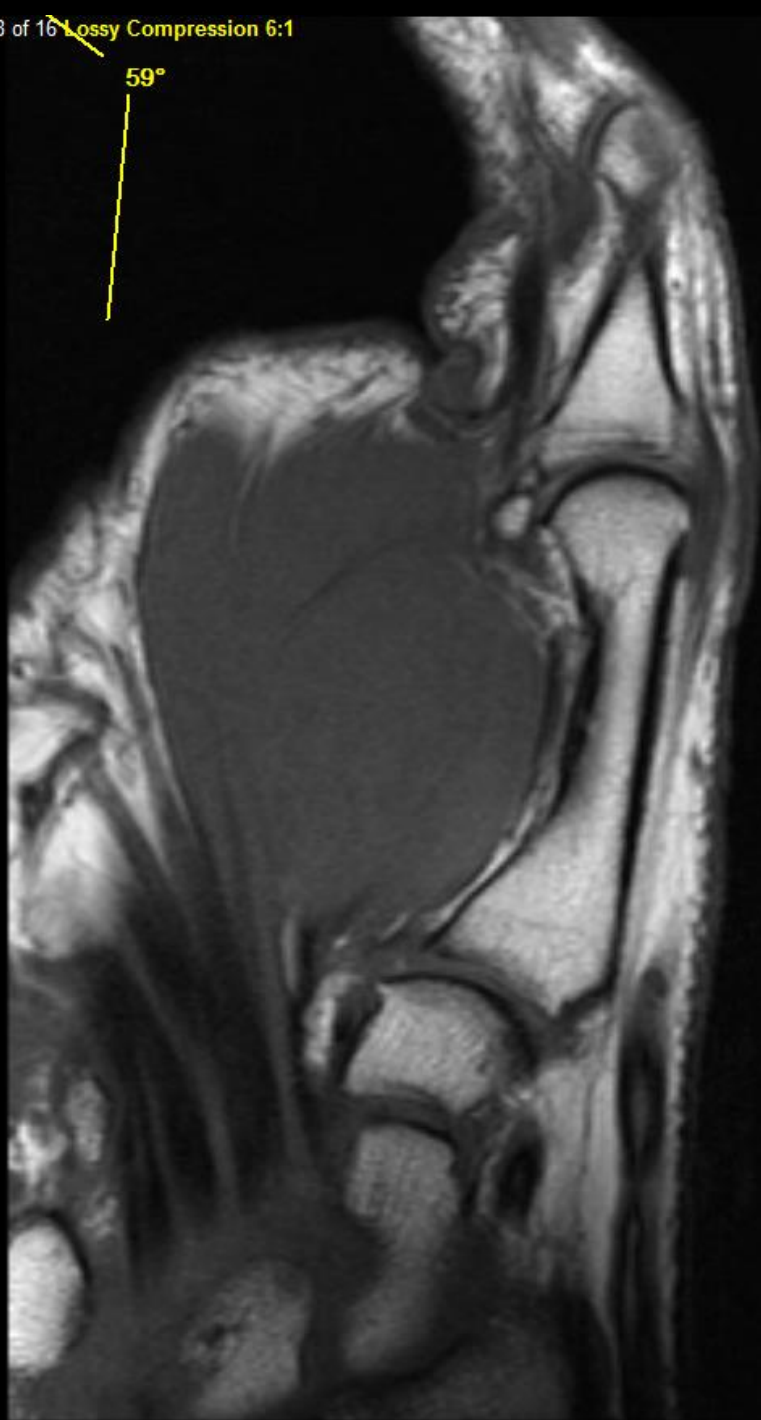


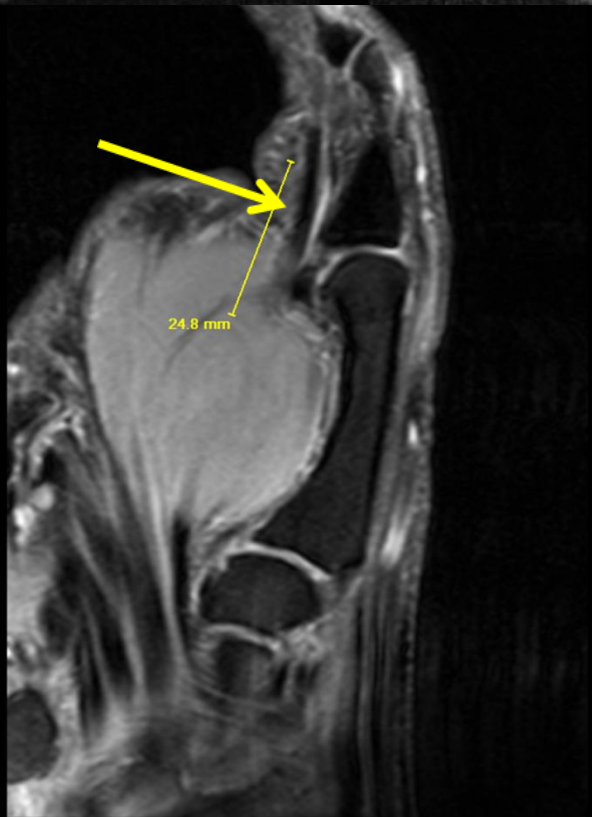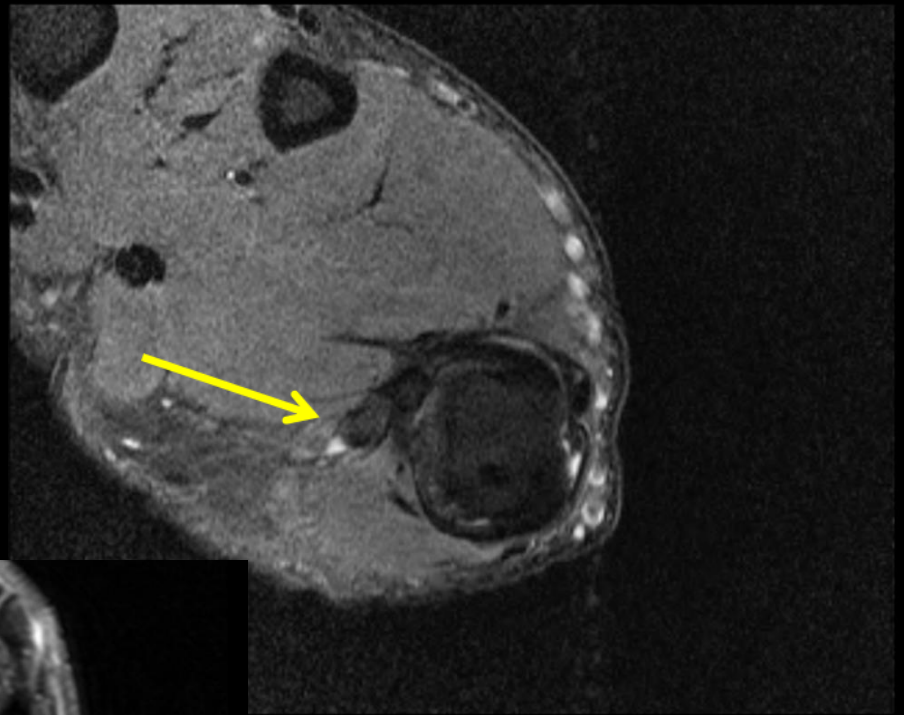
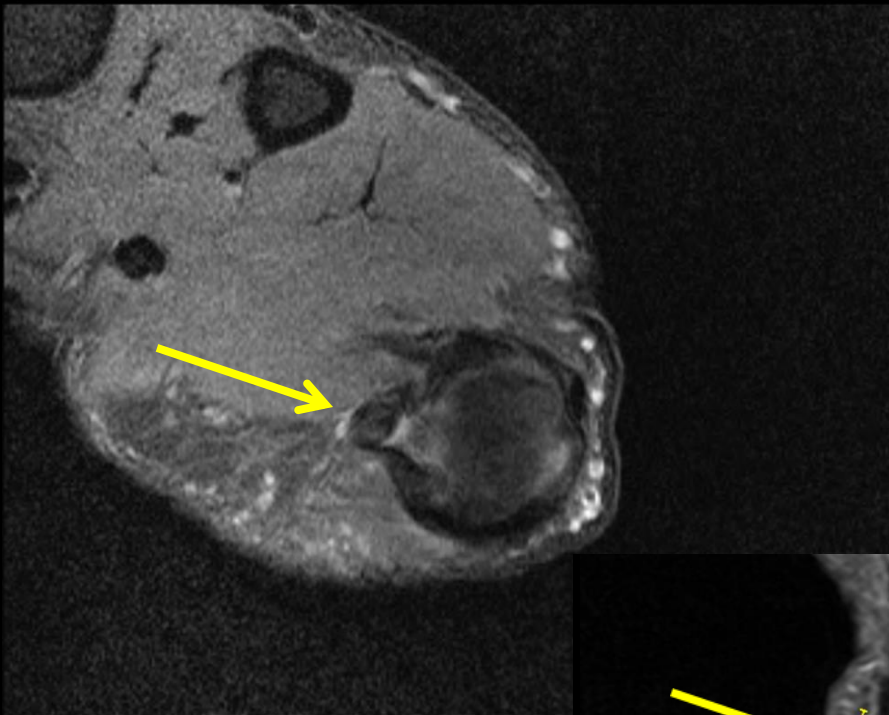




24.8 mm

59°

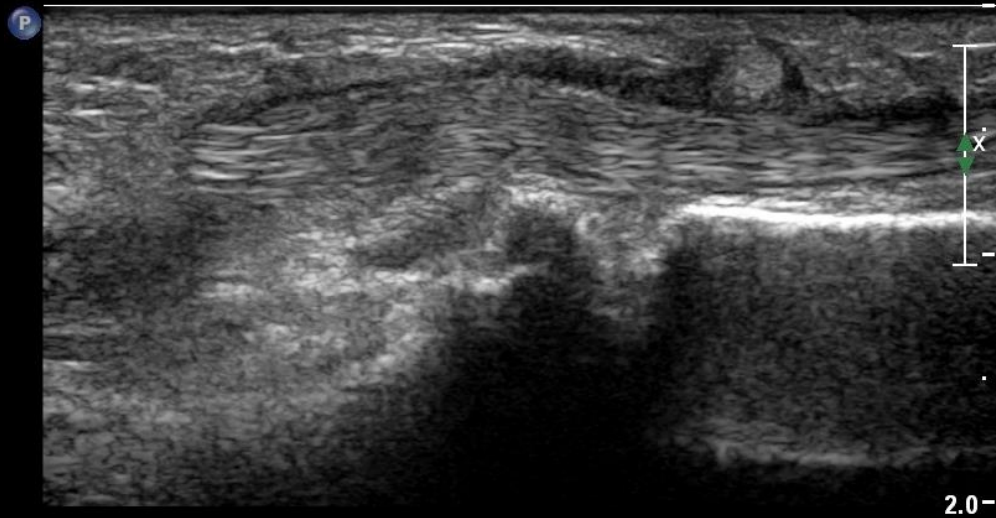




Impression

- Findings suggestive of trigger thumb, with localized thickening of the **flexor pollicis longus tendon** at the level of the metacarpal head (**Notta's nodule**) with accompanying **tenosynovitis**. These findings may explain in part the fixed flexion of the thumb.

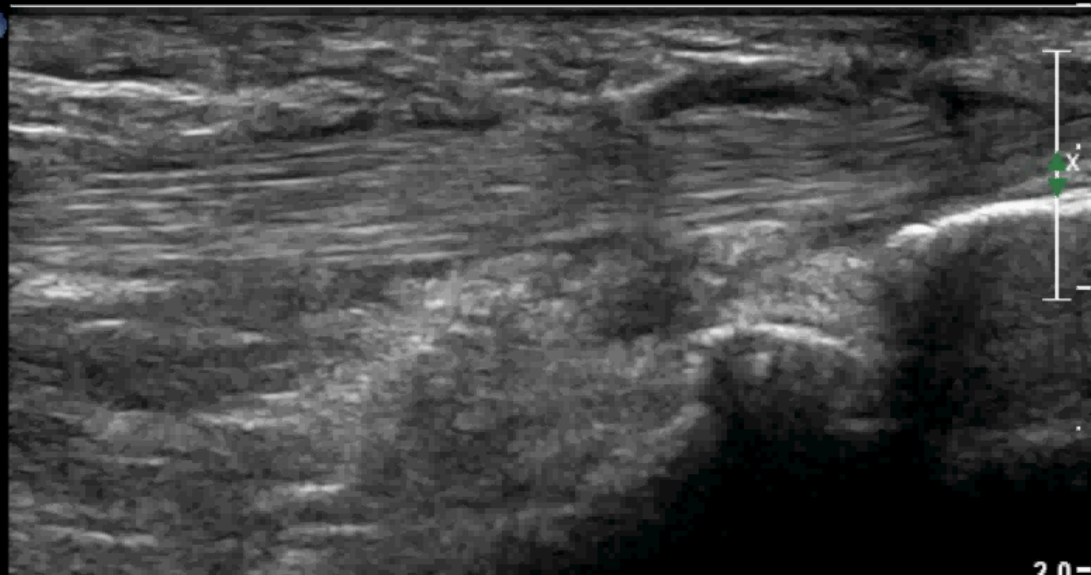Thumb case



LT THUMB VOLAR MCP

P Med
Res

P



2.0-

LT FPL

JPEG

*** bpm

Impression


- Findings consistent with **trigger thumb**, with localized tendinosis and thickening involving the **flexor pollicis longus tendon** at the level the metacarpophalangeal joint, with associated tenosynovitis and slight **thickening of the A1 pulley** at the level of the MCP joint.

trigger thumb—what is it?

- Sclerosing tenosynovitis
- Painful snapping, locking, or contracture
- Due to size mismatch between **flexor pollicis longus tendon** and **annular pulley (usually A1)**
- Any digit, most commonly thumb
- Mostly idiopathic (also RA, tumor, connective tissue disorders)
- Rarely presents for imaging

trigger thumb—what is it?

- Orthopedic literature indicates MRI imaging may not be necessary
- But primary docs may order MRIs for this
- 2-3% population, most commonly 50s-60s
- Palpable nodule may be present “**Notta’s nodule**”, focal tendinosis of flexor pollicis longus (FPL)
- Occurs at level of **A1 pulley (possibly also Av pulley)**
- Originates at FPL or A1 pulley? Chicken or egg?

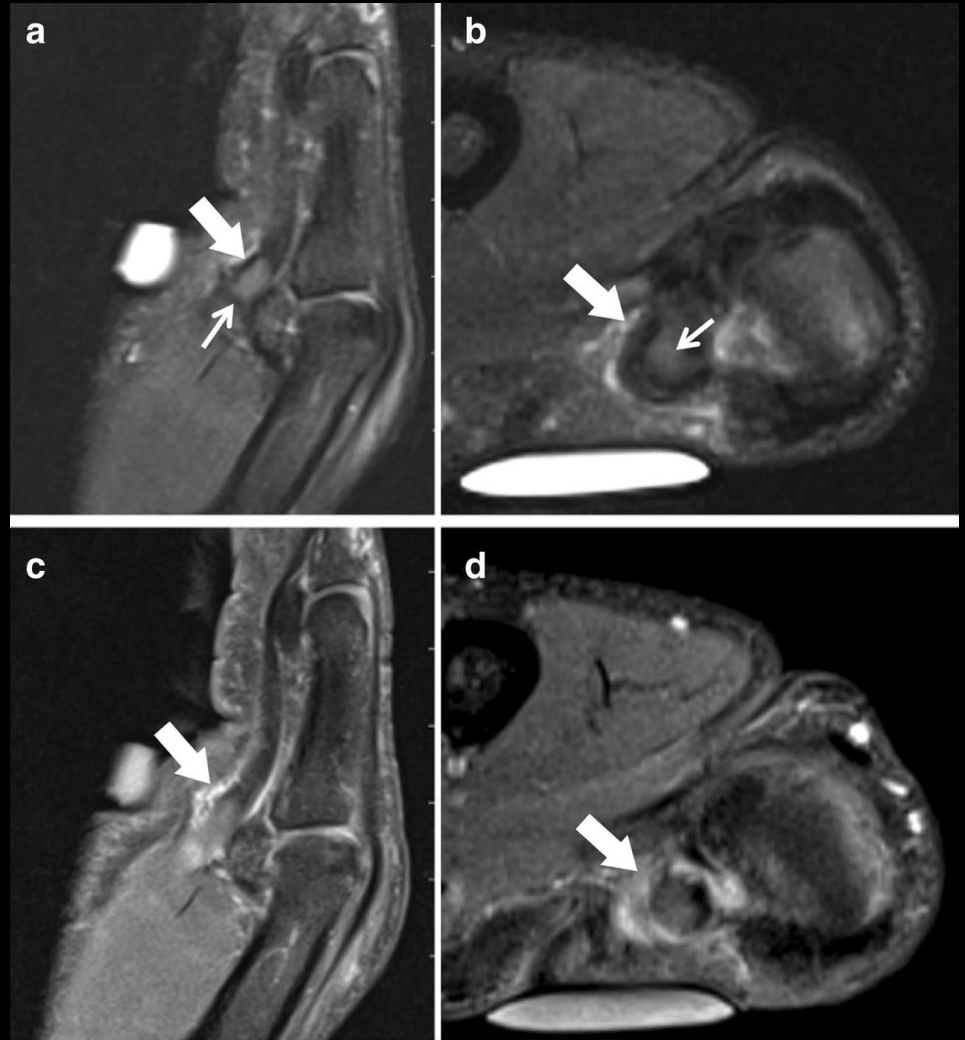

trigger thumb—what is it?

- Most have associated tenosynovitis
- Pulley system is important in treatment of a trigger thumb
- A1 and Av can contribute
- Partial resection of Av may be necessary
- Complete resection of A1 and Av can lead to bowstringing

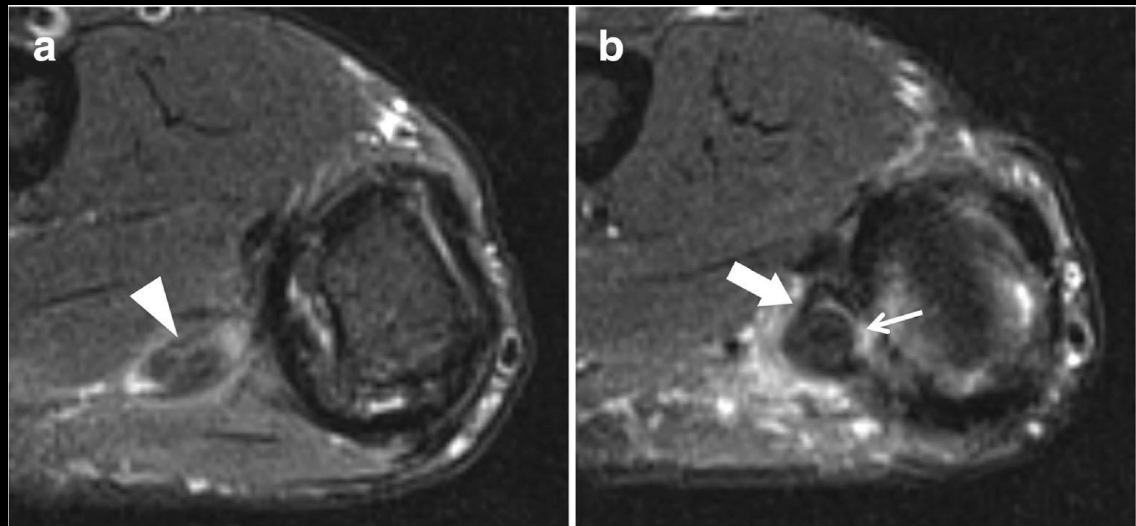
trigger thumb—imaging

- FPL –hypertrophic tendinosis with palpable nodule
- Abnormal A1 pulley, thick and irregular
- Enhancing A1 pulley
- tenosynovitis



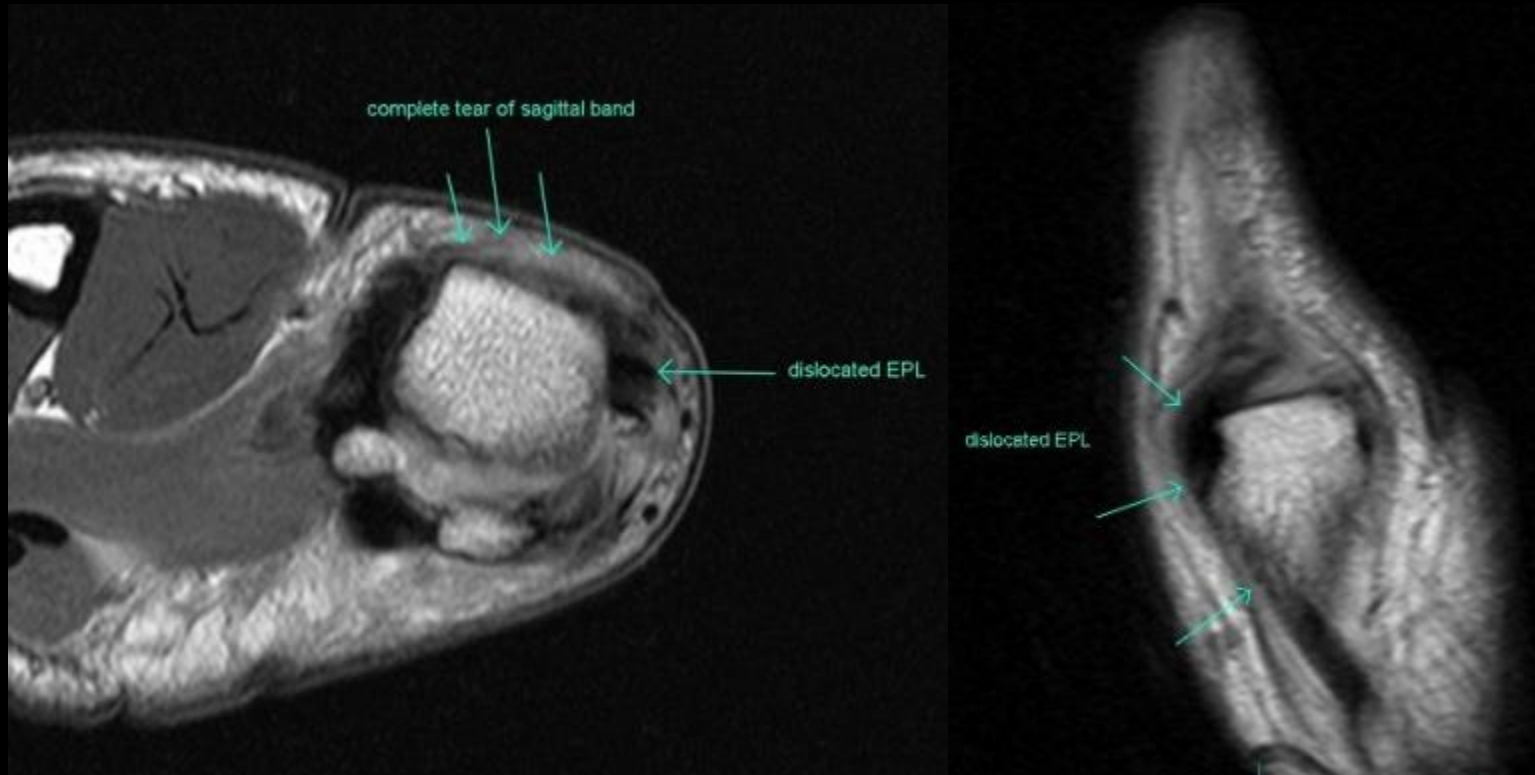
trigger thumb—imaging

- FPL –hypertrophic tendinosis with palpable nodule
- Abnormal A1 pulley, thick and irregular
- tenosynovitis



Misc thumb case


- Sagittal band tear with EPL dislocation



Summary

- CMC = Trapeziometacarpal joint (TMC) anatomy
- TMC joint common injuries
- TMC osteoarthritis and treatment with specific attention to LRTI (ligament reconstruction and tendon interposition)
- MCP joint anatomy
- MCP joint common injuries
- pulley system and trigger thumb anatomy and pathology
- Other miscellaneous thumb pathology

UCSD bone fellow, end of fellowship



**" Dr.Resnick, may I be excused?
My brain is full."**

References

- Bayat, A et al. The Pulley System of the Thumb: Anatomic and Biomechanical Study. *Journal of Hand Surgery* 2002; 27A:628-635
- Bettinger, PC et al. An Anatomic Study of the Stabilizing Ligaments of the Trapezium and Trapeziometacarpal Joint. *The Journal of Hand Surgery* 1999; 24A:4:786-798.
- Cardoso, FN et al. Imaging the Ligaments of the Trapeziometacarpal Joint: MRI Compared with MR Arthrography in Cadaveric Specimens. *AJR* 2009; 192 web exclusive content
- Carlsen, BT et al. Thumb Trauma: Bennett Fractures, Rolando Fractures, and Ulnar Collateral Ligament Injuries. *Journal of Hand Surgery* 2009; 34A:945-952.
- Chang, EY et al. MR Imaging Findings of Trigger Thumb. *Skeletal Radiology* 2015; 44:1201-1207.
- Croog, AS et al. Newest Advances in the Operative Treatment of Basal Joint Arthritis. *Bulletin of the NYU Hospital for Joint Diseases* 2007; 65(1):78-86
- Connell, DA et al. MR Imaging of Thumb Carpometacarpal Ligament Injuries. *Journal of Hand Surgery (British and European volume)* 2004; 29B:1:46-54
- Ebrahim, FS et al. US Diagnosis of UCL Tears of Thumb and Stener Lesions: Technique, Pattern-based Approach, and Differential Diagnosis. *Radiographics* 2006; 26:1007-1020
- Edelstein, DM et al. Radial Collateral Ligament Injuries of the Thumb. *Journal of Hand Surgery* 2008; 33A: 760-770
- Fazileau F et al. Reconstruction of closed rupture of thumb flexor tendon pulleys with a single free palmaris longus tendon graft: A case report and review of literature. *Chirurgie de la Main*. 2014; 33 (51-54)

References

- Hirschmann, A et al. MRI of the Thumb: Anatomy and Spectrum of Findings in Asymptomatic Volunteers. *AJR* 2014; 202:819-827.
- Hirschmann, A et al. The Carpometacarpal Joint of the Thumb: MR appearance in asymptomatic volunteers. *Skeletal Radiology* 2013; 42:1105-1112
- Khorashadi, L et al. Radiologic Guide to Surgical Treatment of the First Carpometacarpal Joint Osteoarthritis. *AJR* 2012; 198:1152-1160.
- Kuhns, CA et al. Hematoma and Distraction Arthroplasty for Thumb Basal Joint Osteoarthritis: A Prospective, Single-Surgeon Study Including Outcomes Measures. *Journal of Hand surgery* 2003; 28A:381-389
- Ladd, AL et al. The Thumb Carpometacarpal Joint: Anatomy, Hormones, and Biomechanics. *Instr Course Lecture* 2013; 62:165-179
- Ladd, AL et al. Macroscopic and Microscopic Analysis of the Thumb Carpometacarpal Ligaments. *Journal of Bone and Joint Surgery*. 2012; 94:1468-1477
- Matullo, KS et al. CMC Arthroplasty of the Thumb: A Review. *Hand* 2007; 2:232-239
- Patel S et al. Collateral ligament injuries of the MCP joint of the thumb: a treatment algorithm. *Strat Trauma Limb Recon* 2010; 5:1-10
- Peterson, JJ et al. Injuries of the Fingers and Thumb in the Athlete. *Clinics in Sports Medicine*. 2006; 527-42
- Pizon A. Carpometacarpal Dislocation of the Thumb. *Visual Diagnosis in Emergency Medicine* 2007; 38(3): 376-377
- Schubert, MF et al. Varied Anatomy of the Thumb Pulley System: Implications for Successful Trigger Thumb Release. *Journal of Hand Surgery* 2012; 37A:2278-2285
- Wilson, SM et al. Closed Rupture of the Thumb Flexor Tendon Pulleys. *Journal of Hand Surgery* 2005; 30B:6:621-623