

# Synovial Plicae of the Knee

James Koenig MD

January 6, 2011

# Outline

- Briefly discuss the history of plica research
- Discuss the embryology of the synovial plicae of the knee
- Discuss the anatomy, incidence, and classification systems for all four synovial plicae
- Show examples of plicae on multiple imaging modalities
- Discuss the various plica syndromes

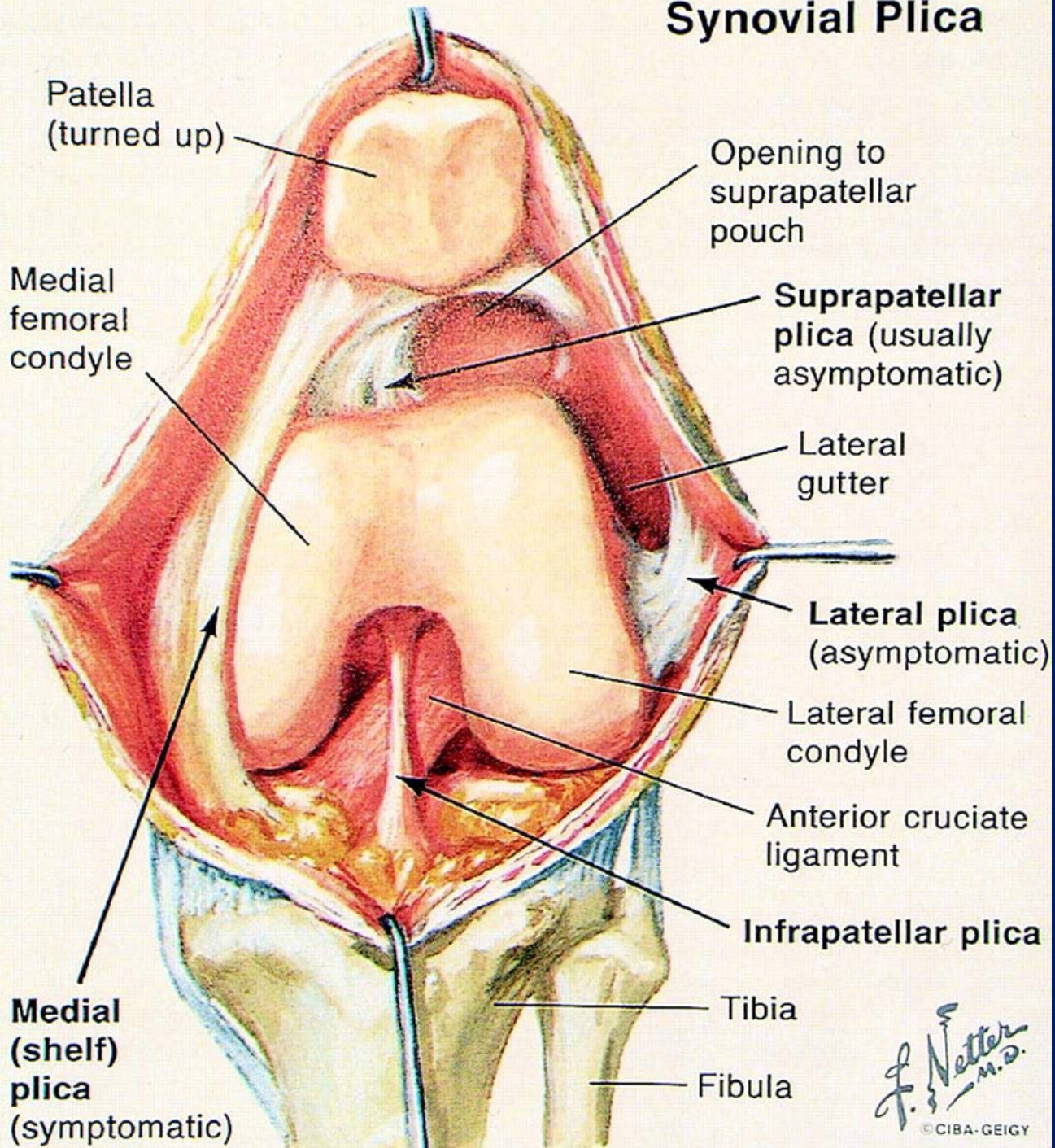
# Definitions

- What is a plica?
  - Definition: a fold or ridge
- In the body:
  - A plica is a fold of synovial tissue found in the lining of a joint<sup>1</sup>

# The Basics


- There are FOUR synovial plicae in the knee:
  - Suprapatellar plica (55%)
  - Infrapatellar plica (65%)
  - Medial patellar plica (25%)
  - Lateral patellar plica (<1%)
- Each plica has variable size and shape
- Various combinations of plicae may exist simultaneously<sup>8</sup>
- Plica may be observed on:
  - Arthrography
  - CT arthrography
  - MRI or MR arthrography
  - Arthroscopy
  - Ultrasound

# Synovial Plica



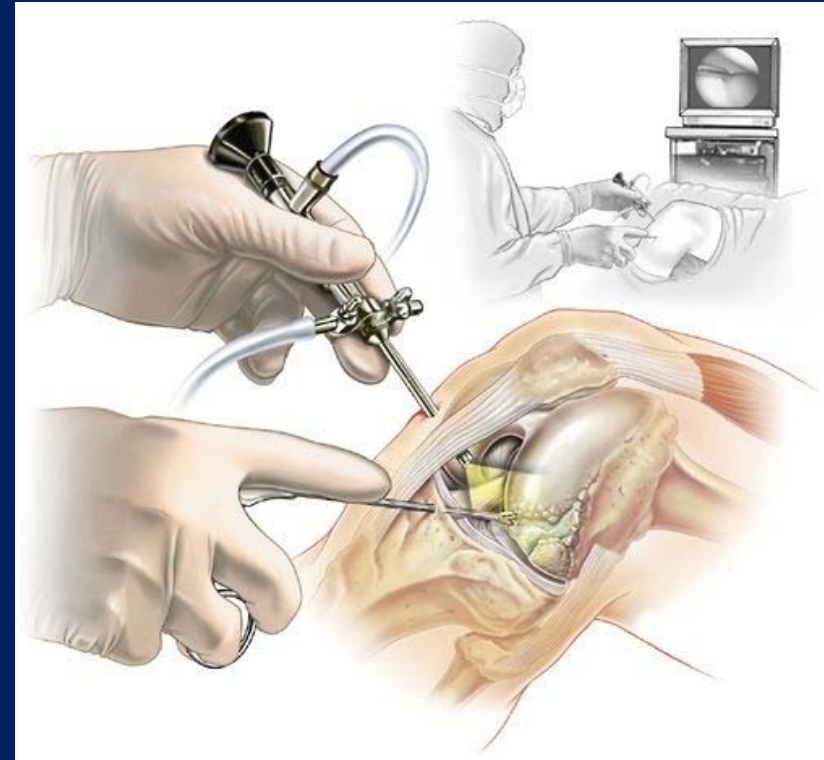
# History of Plicae Research

- 1555
  - Vesalius identified a “synovial pleat” in the knee
  - Was referring to the infrapatellar plica
  - Named it the ligamentum mucosum<sup>2</sup>
- Late 1800’s and Early 1900’s
  - Mayeda from Japan and Hohlbaum from Germany described the medial and lateral patellar plicae<sup>3</sup>
  - These early descriptions were purely anatomic (cadaver based)
  - Mayeda first to suggest the possibility that plicae may be responsible for internal derangements<sup>3</sup>
- 1939
  - Iino classified medial patellar plica into four types



# History of Plicae Research

- 1950
  - Pipkin
  - First article linking clinical signs to the presence of a plica
  - He described two cases of post-traumatic, symptomatic suprapatellar plicae treated by surgical excision and with subsequent healing
- 1960's
  - Interest in orthopedic community grew with the advent of arthroscopy
  - Early focus was on the suprapatellar plica and it was felt to be the most common cause of symptoms
  - Later authors realize the medial plica is more often involved in producing clinical symptoms



# How do plicae form?

- An understanding of knee embryology is key to understanding the existence of plicae.
- Knee joint forms between the 7<sup>th</sup> to 10<sup>th</sup> week of fetal development.
- No consensus about the way the knee joint cavity forms<sup>6</sup>
- Widely believed that the knee is originally composed of three separate compartments:
  - Medial and lateral synovial compartments
  - Suprapatellar bursa
- Incomplete resorption of the septa between the compartments leads to the formation of synovial plica
  - Explains the existence of the suprapatellar and infrapatellar plicae
  - However, no coronally orientated septum exists in the fetus
    - How does the medial and lateral plica form?

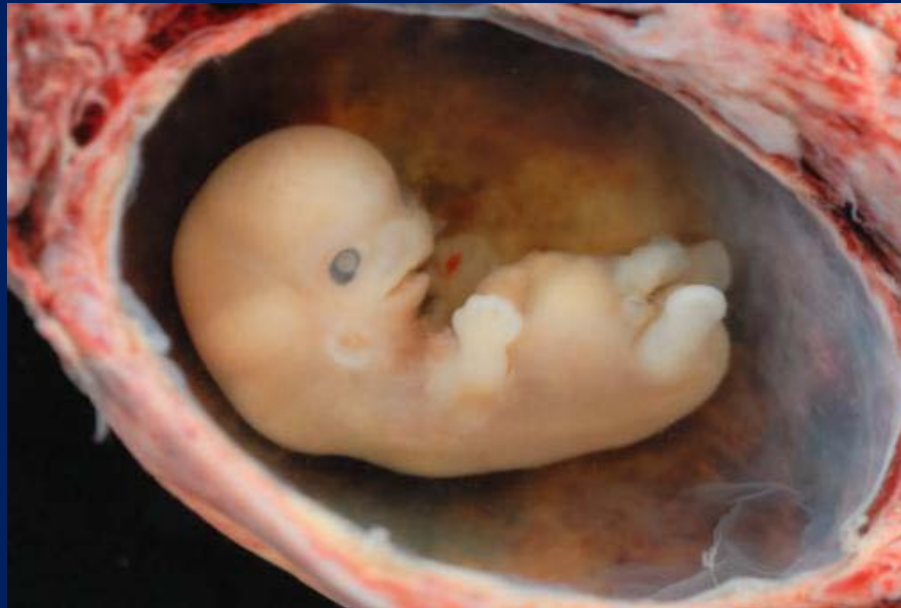

# How do plicae form?

- 1990 Ogata and Uthoff<sup>6</sup>
  - Most complete study of the embryology of the human knee
  - Studied 116 knees from 112 embryos and fetuses ranging from 6-20 weeks gestational age
  - Purpose:
    - To elucidate the process of formation of the knee joint cavity
    - Determine the incidence of synovial plica during the fetal stage

# How do plicae form?

- Knee development:
  - 6 weeks gestational age<sup>6</sup>
    - Cartilaginous anlagen of femur, tibia, and patella visible
    - Mesenchymal tissue fills the space between the distal femur and proximal tibia
    - No intra-articular structures are visible



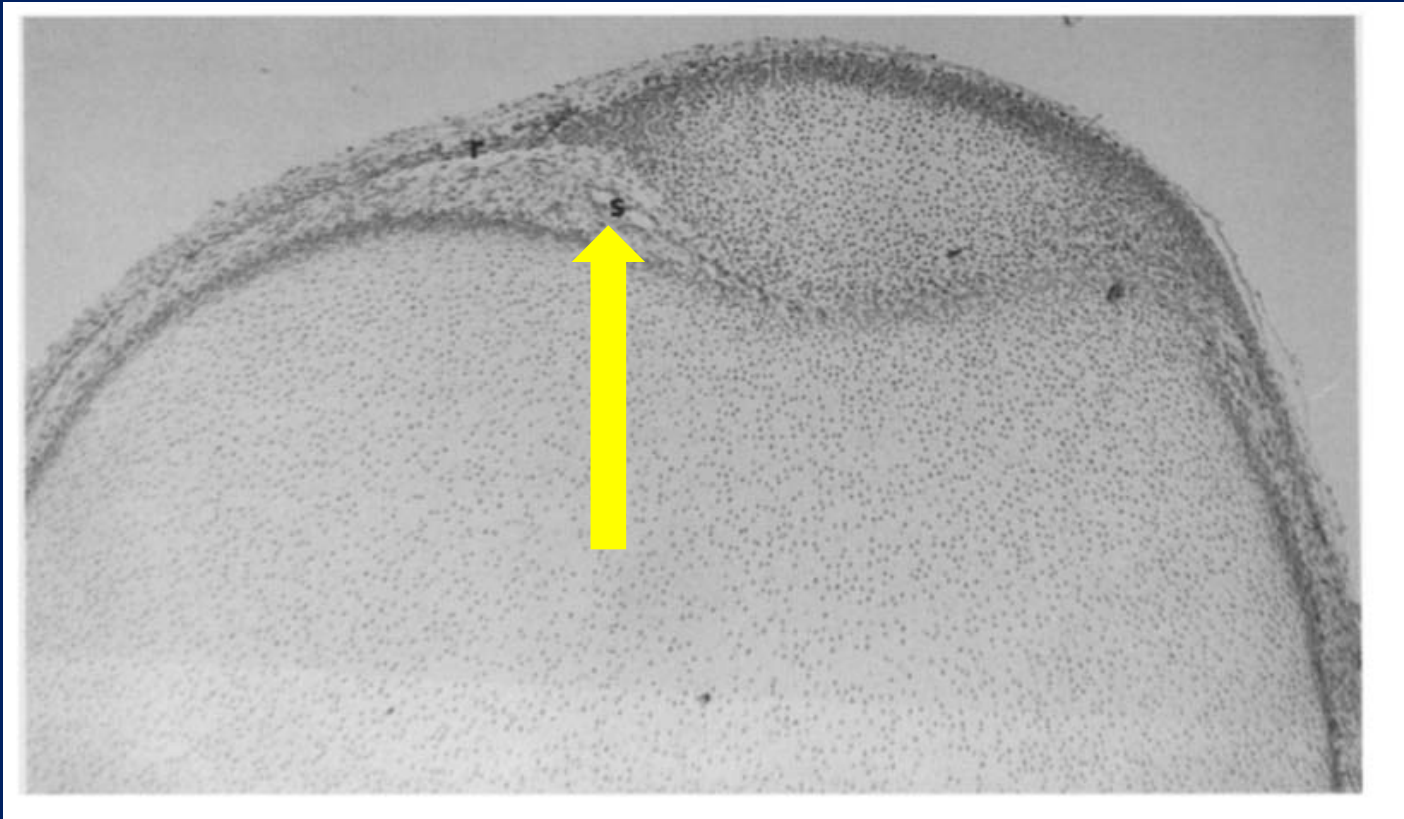
Embryo at 6 weeks gestational age

# How do plicae form?

- Knee development:
  - 7 weeks gestational age<sup>6</sup>
    - Shapes of skeletal elements already similar to adult
    - Early mesenchymal condensations representing the menisci and cruciate ligaments visible
  - 8 weeks gestational age<sup>6</sup>
    - Joint space begins to form
    - Multiple small cavities form in menisco-femoral and patellofemoral region
    - No cavitation in the menisco-tibial regions identified

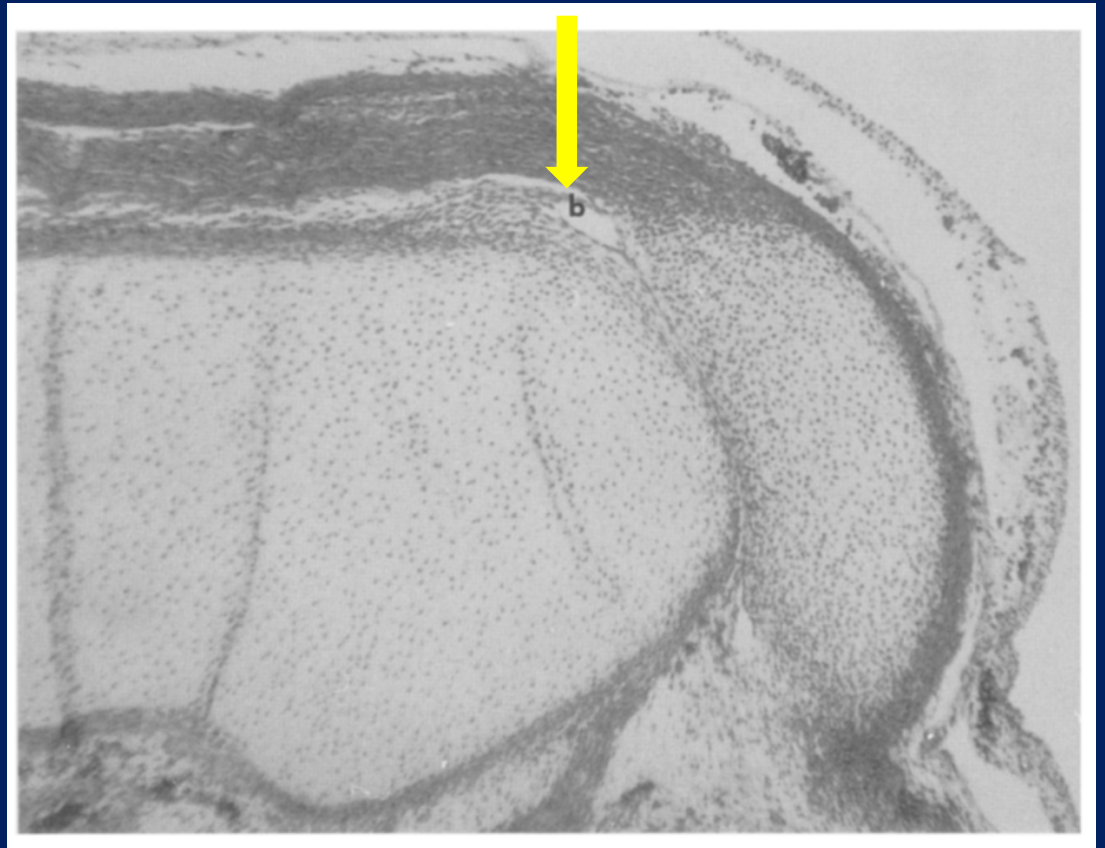
# How do plicae form?

- Transverse section: 8.5 week-old fetus
  - Cavity beginning to form in mesenchyme at medial aspect of patellofemoral joint



# How do plicae form?

- Sagittal section: 8.5 week-old fetus
  - Cavities identified beneath quadriceps tendon
  - Mesenchymal band separates suprapatellar pouch from patellofemoral joint
  - Early suprapatellar plica



# How do plicae form?

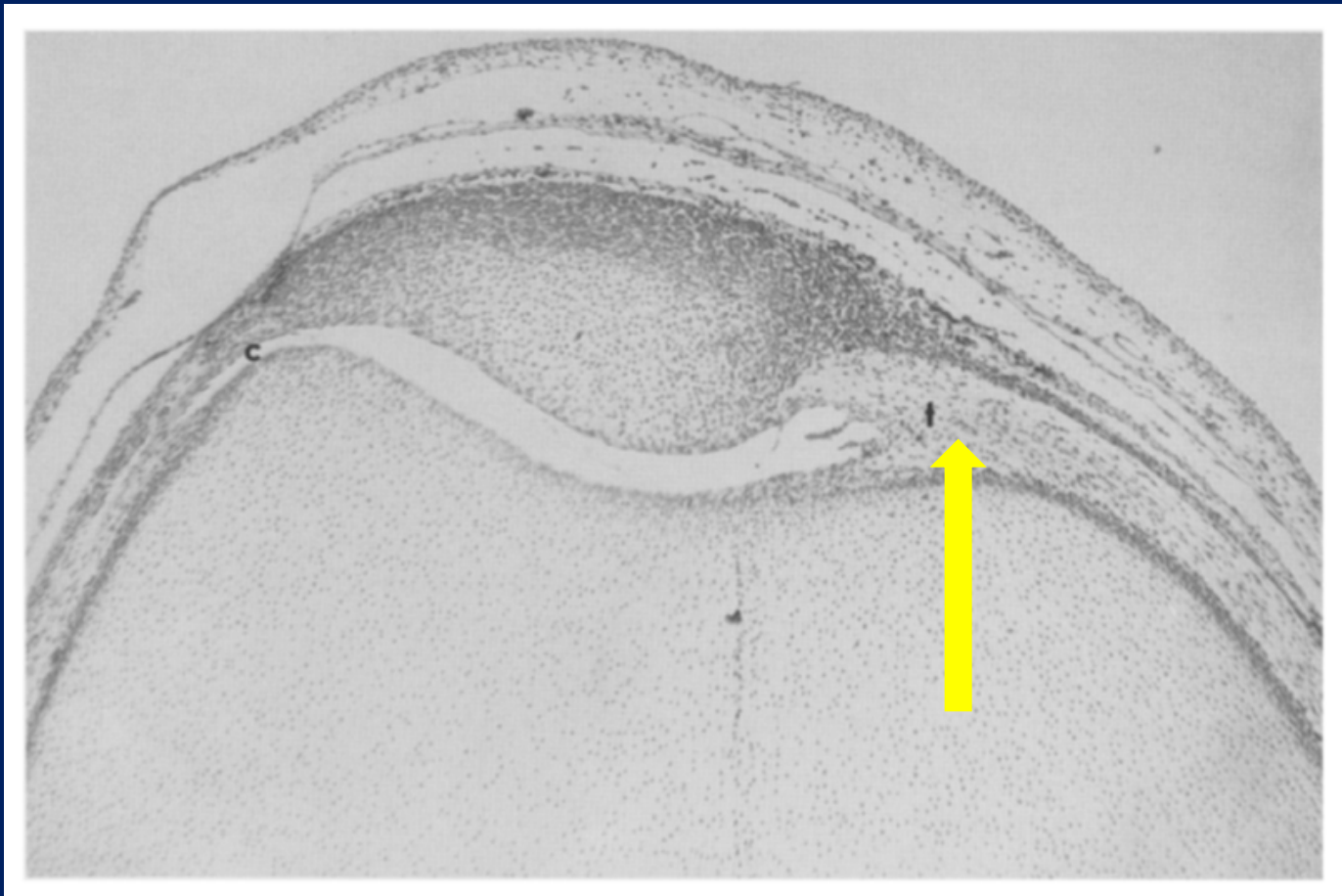
- 9 weeks GA<sup>6</sup>
  - Multiple small cavities begin to form in the menisco-tibial regions
- 10 weeks GA<sup>6</sup>
  - Cavities coalesce to form the knee joint
  - A small amount of mesenchymal tissue separating the cavities remains unresolved
    - Especially in the suprapatellar, infrapatellar and medial patellar regions
  - Residual mesenchymal tissue forms the plicae

# How do plicae form?

- Why are medial plica far more common than lateral plica?
  - The fetal patella articulates mainly with the lateral facet and the lateral aspect of the trochlea<sup>6</sup>
  - Lateralization of the patella results in larger amount of residual mesenchymal tissue on the medial side of the knee relative to the lateral<sup>6</sup>
  - Less mesenchymal tissue means less likelihood of a plica

# How do plica form?

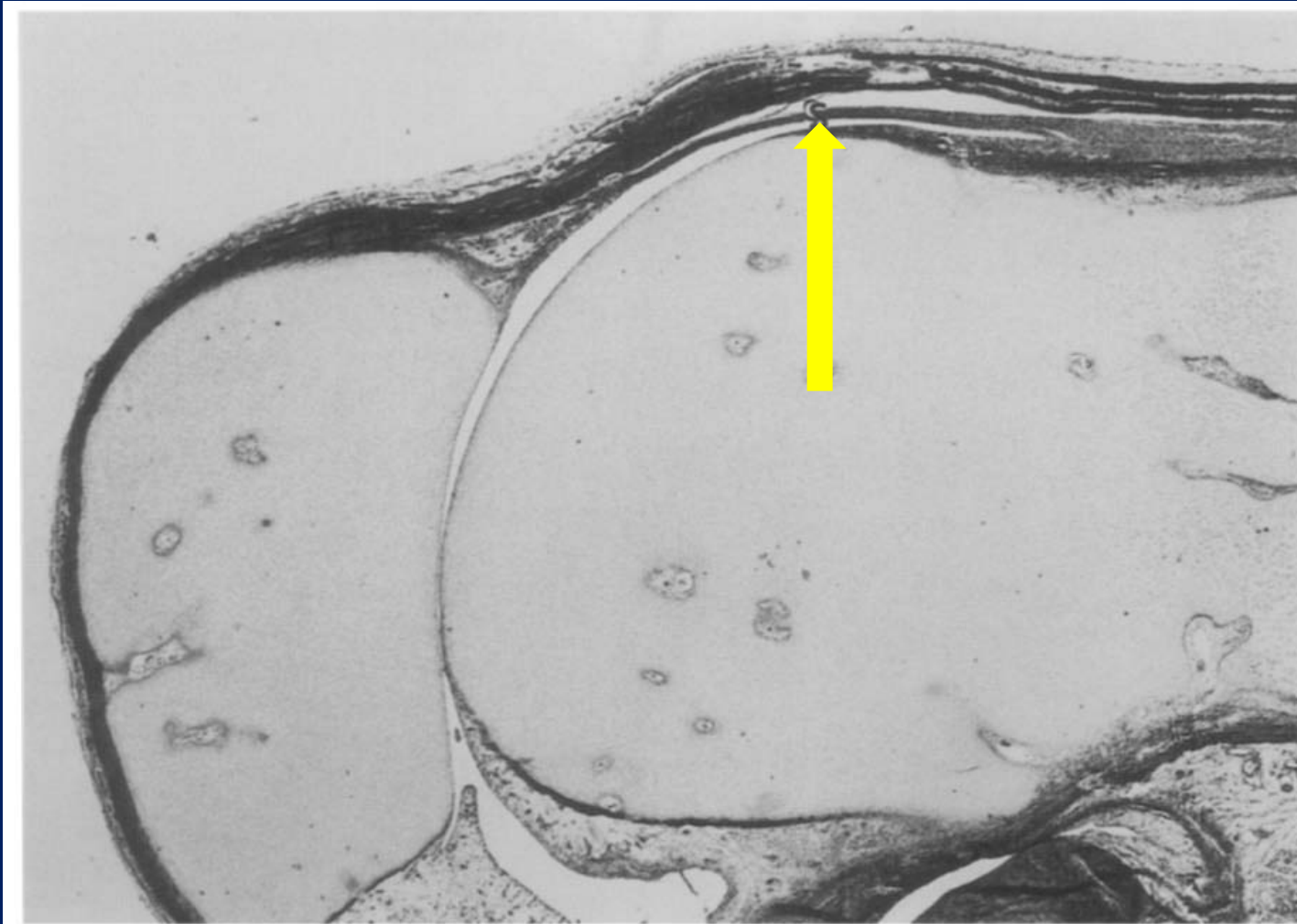- 9.5 week-old fetus demonstrating asymmetric mesenchymal tissue on the medial side of the patellofemoral joint





# How do plica form?

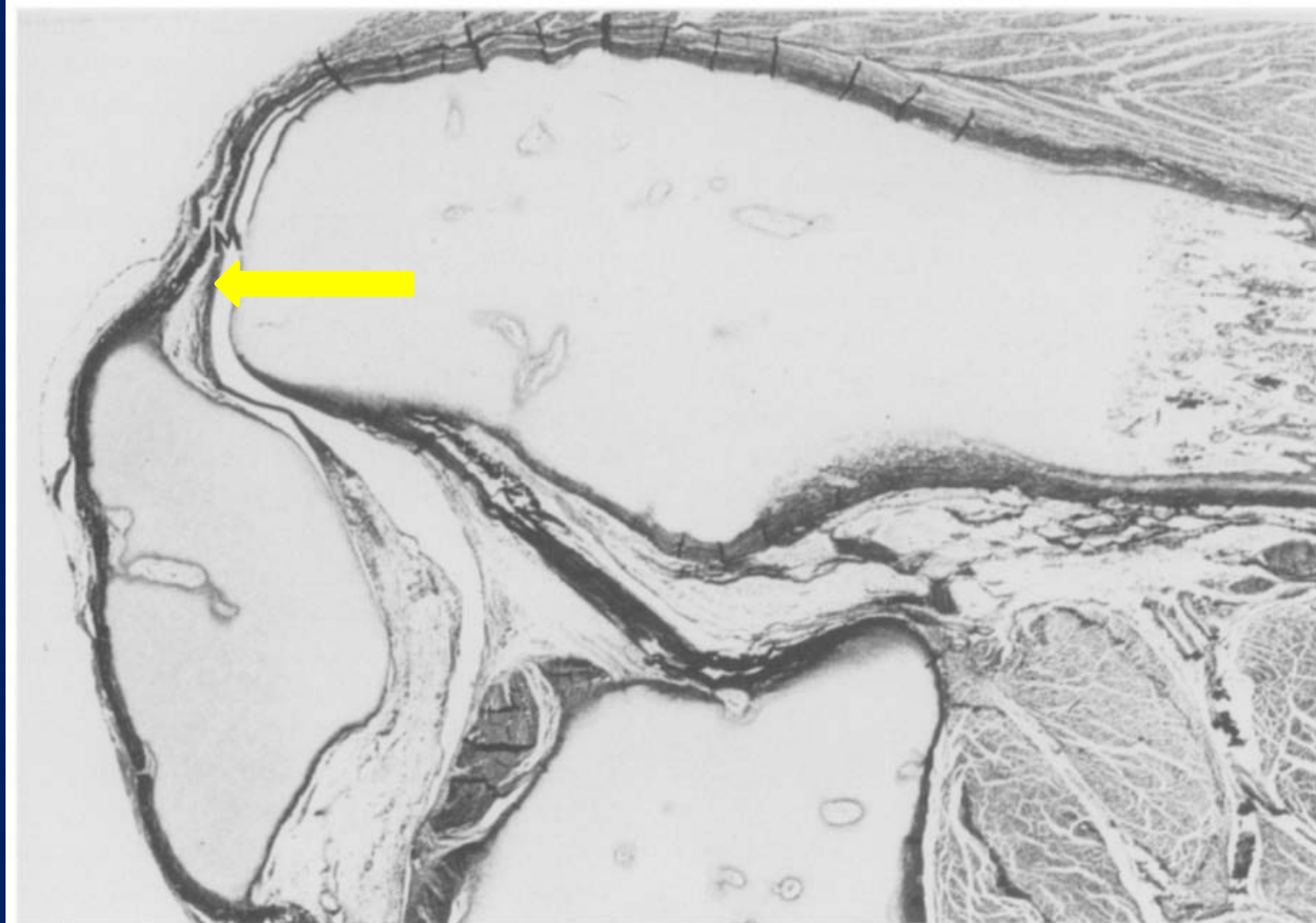
- 17 week-old fetus showing suprapatellar plica
- Sagittal section



**FIG. 5.** Sagittal section of a 17-week-old fetus showing a suprapatellar plica (s). Goldner,  $\times 8$ .

# How do plica form?

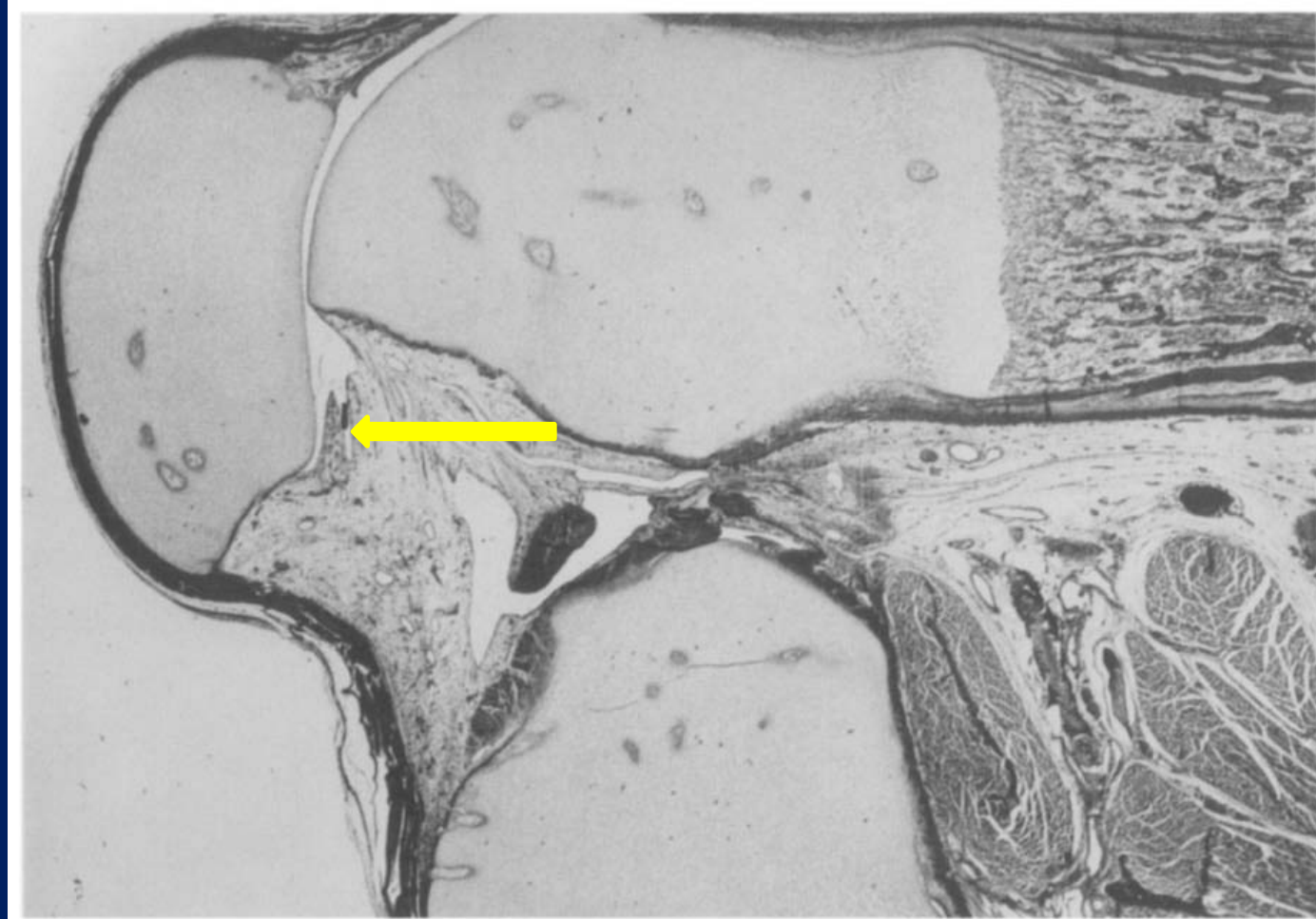
- 17 week-old fetus showing medial patellar plica
- Sagittal section



**FIG. 6.** Sagittal section of a 17-week-old fetus showing a mediopatellar plica (M). Goldner,  $\times 5\frac{1}{2}$ .

# How do plica form?

- 17 week-old fetus showing infrapatellar plica
- Sagittal section



**FIG. 7.** Sagittal section of a 17-week-old fetus showing an infrapatellar plica (I). Goldner,  $\times 5\frac{1}{2}$ .

# How do plica form?

- Conclusions<sup>6</sup>:
  - Suprapatellar plica
    - Residual septum between the suprapatellar bursa and patellofemoral cavity
  - Infrapatellar plica
    - Residual septum between the medial and lateral femorotibial cavitations
  - Medial and lateral plica
    - Not a remnant of a septum
    - Remnant mesenchymal tissue
    - Lateralization of the patella during fetal period results in far more medial plica

# Plicae

- The following will be discussed for each plica:
  - Anatomy of each plica
  - Incidence of the plica
    - Incidences stated in the literature are highly variable and depend on if study was cadaveric or arthroscopic
  - Classification system(s) that exist
  - Examples of plica on various imaging modalities will be shown

# Suprapatellar Plica

# Suprapatellar plica

- Synonyms in the literature<sup>2</sup>:
  - Superior plica
  - Plica synovialis suprapatellaris
  - Superomedial plica
  - Medial suprapatellar plica

# Suprapatellar plica

- Anatomy<sup>2</sup>:
  - Located approximately 2 cm above the patella
  - Courses from the synovium overlying anterior aspect of the distal femoral metaphysis to the synovium posterior to the distal quadriceps tendon
  - Oblique course from posterosuperior to anteroinferior
  - With knee flexed it lies parallel to the quadriceps
  - Thickness variable: thin and transparent to thick and fibrotic (rare)

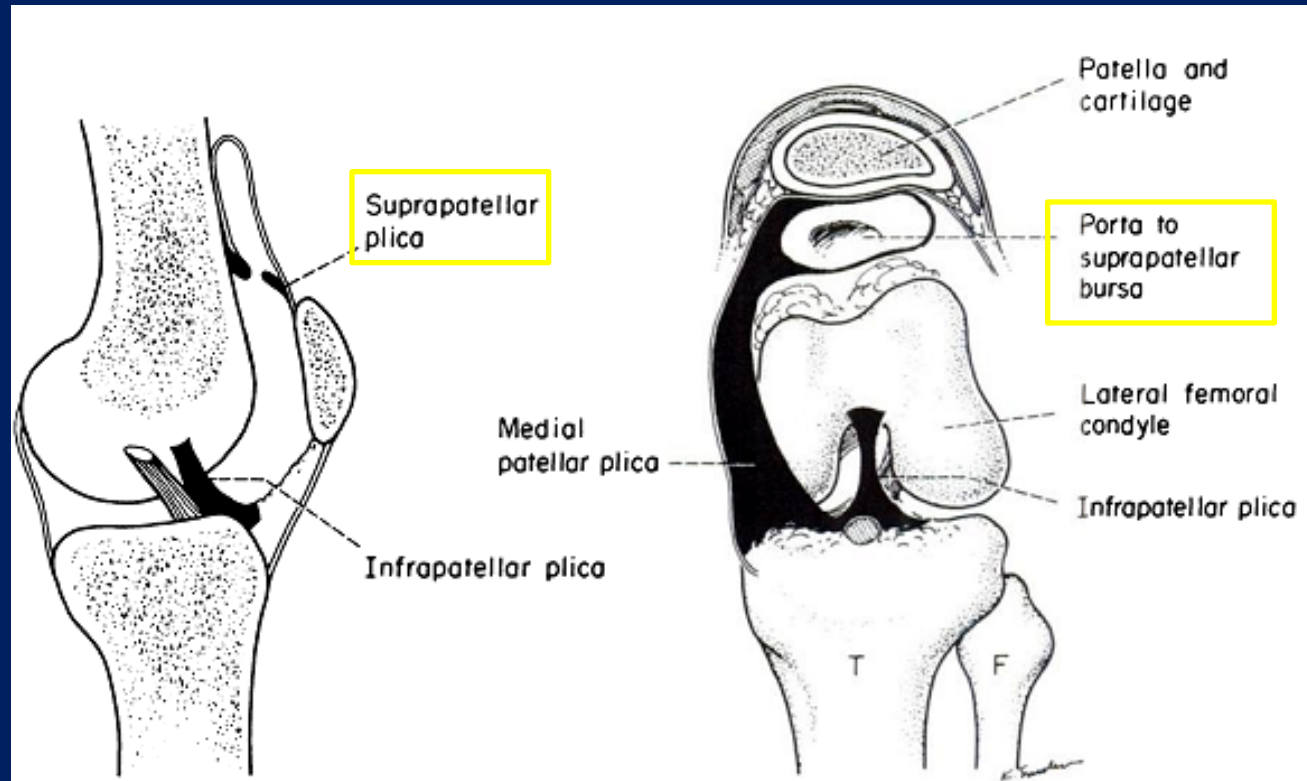


# Suprapatellar plica

- Incidence:
  - Second most common plica
  - Incidence approximately 55%<sup>8</sup>
  - Arthroscopic studies report incidence between 70-91%<sup>5</sup>
  - Embryologic study found 25 superior plicae in 72 embryos of 11-20 weeks gestation<sup>6</sup>

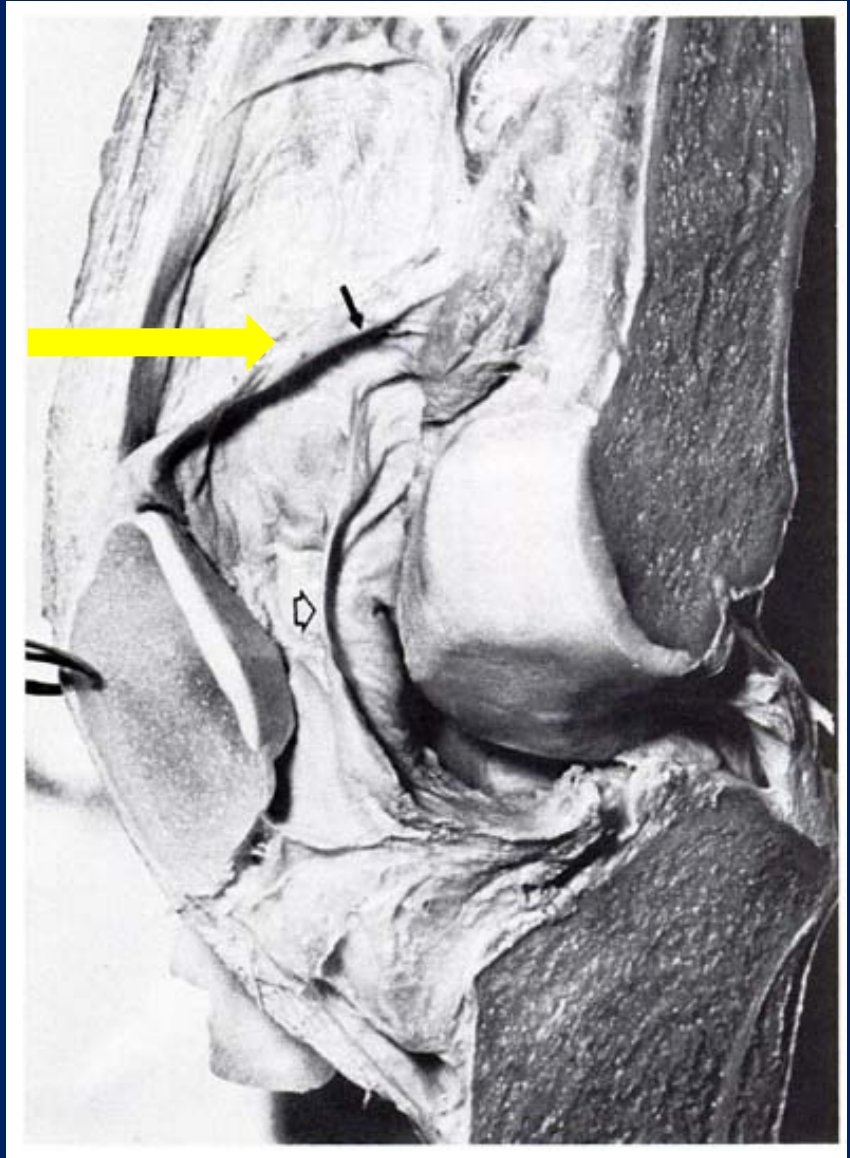
# Suprapatellar Plica

- Schematic diagram demonstrating the suprapatellar plica



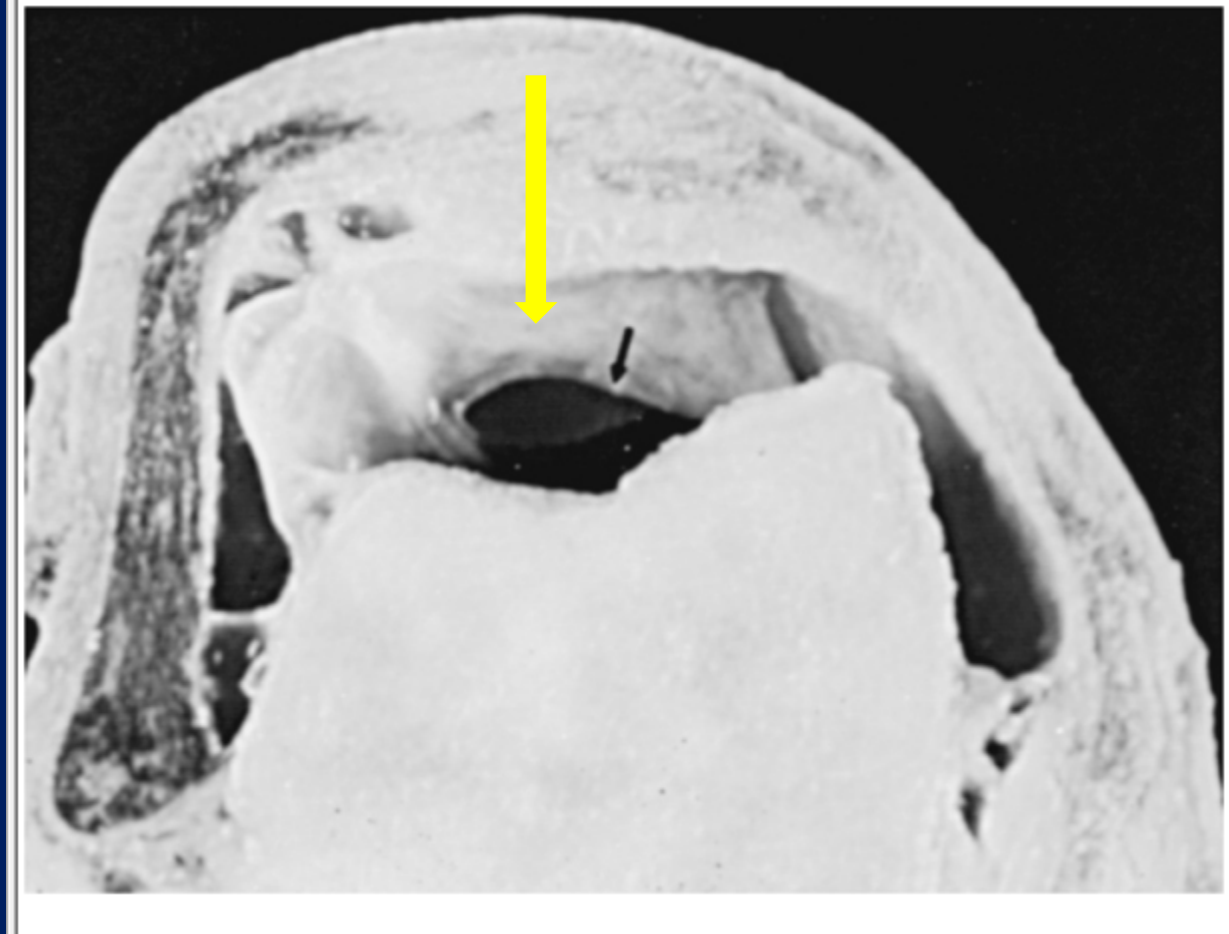
# Suprapatellar plica

- Sagittal section through the knee of cadaver demonstrating the suprapatellar plicae (Solid arrow)<sup>7</sup>



# Suprapatellar Plica

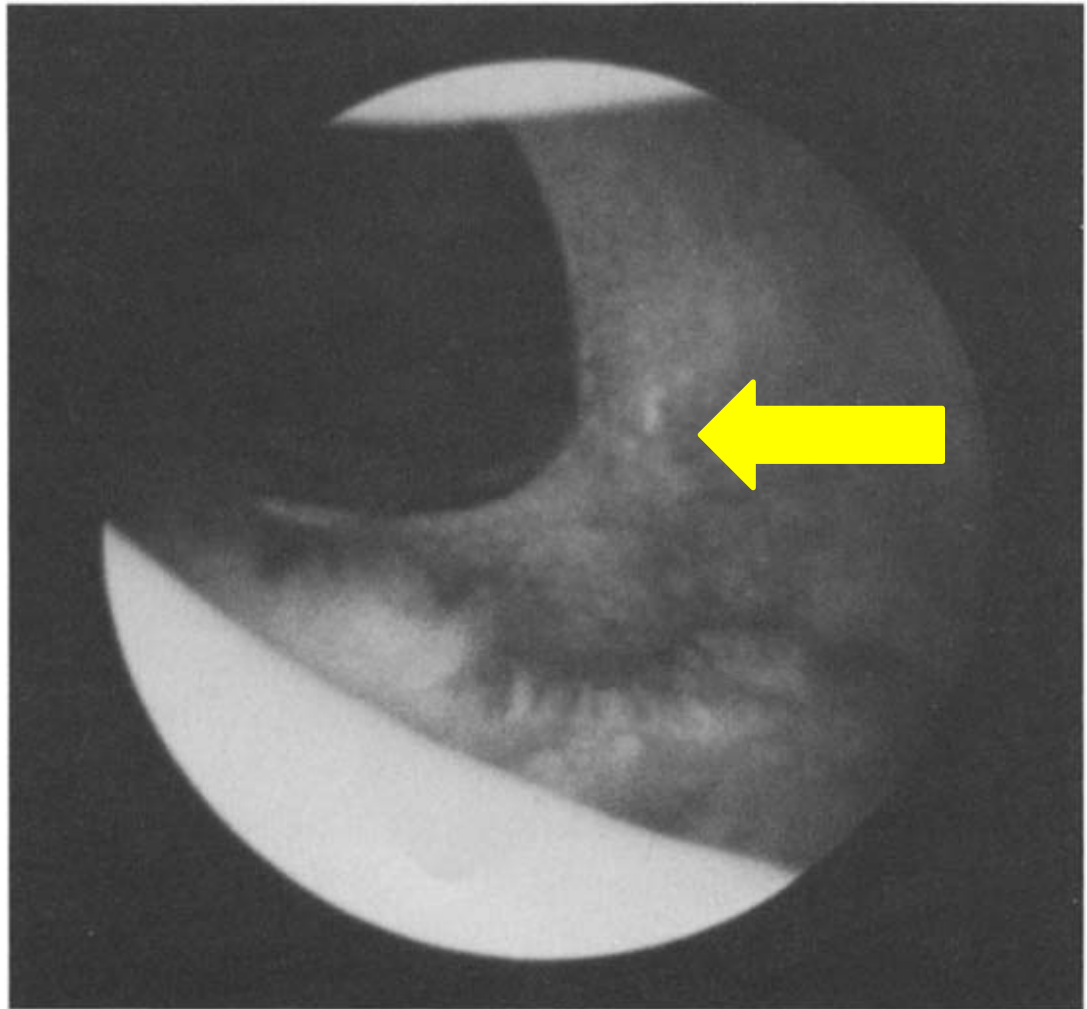
- Transverse section through suprapatellar pouch of cadaver demonstrating suprapatellar plica with porta



Deutsch A, Resnick D, Dalinka M, et al: Synovial plicae of the knee. *Radiology* 141: 627-634, 1981.

# Suprapatellar Plica

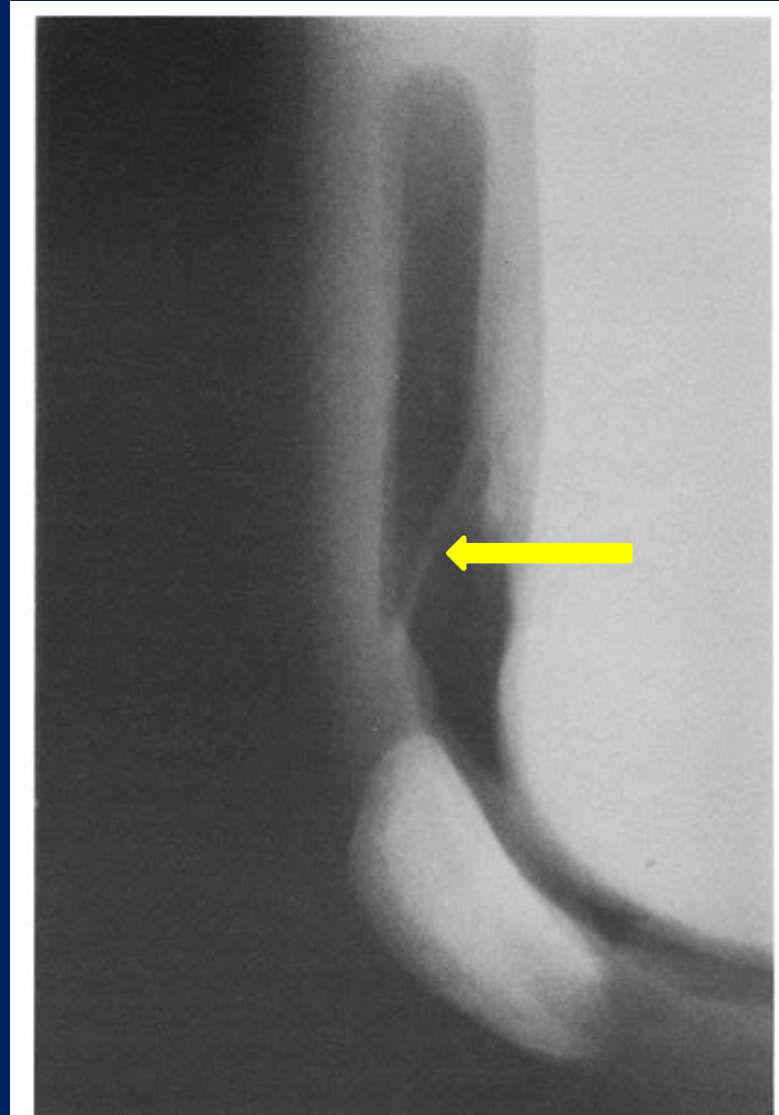
- Suprapatellar plica seen at arthroscopy<sup>2</sup>



**Figure 2.** Superior plica, seen as a crescent in the superomedial part of the pouch (right knee).

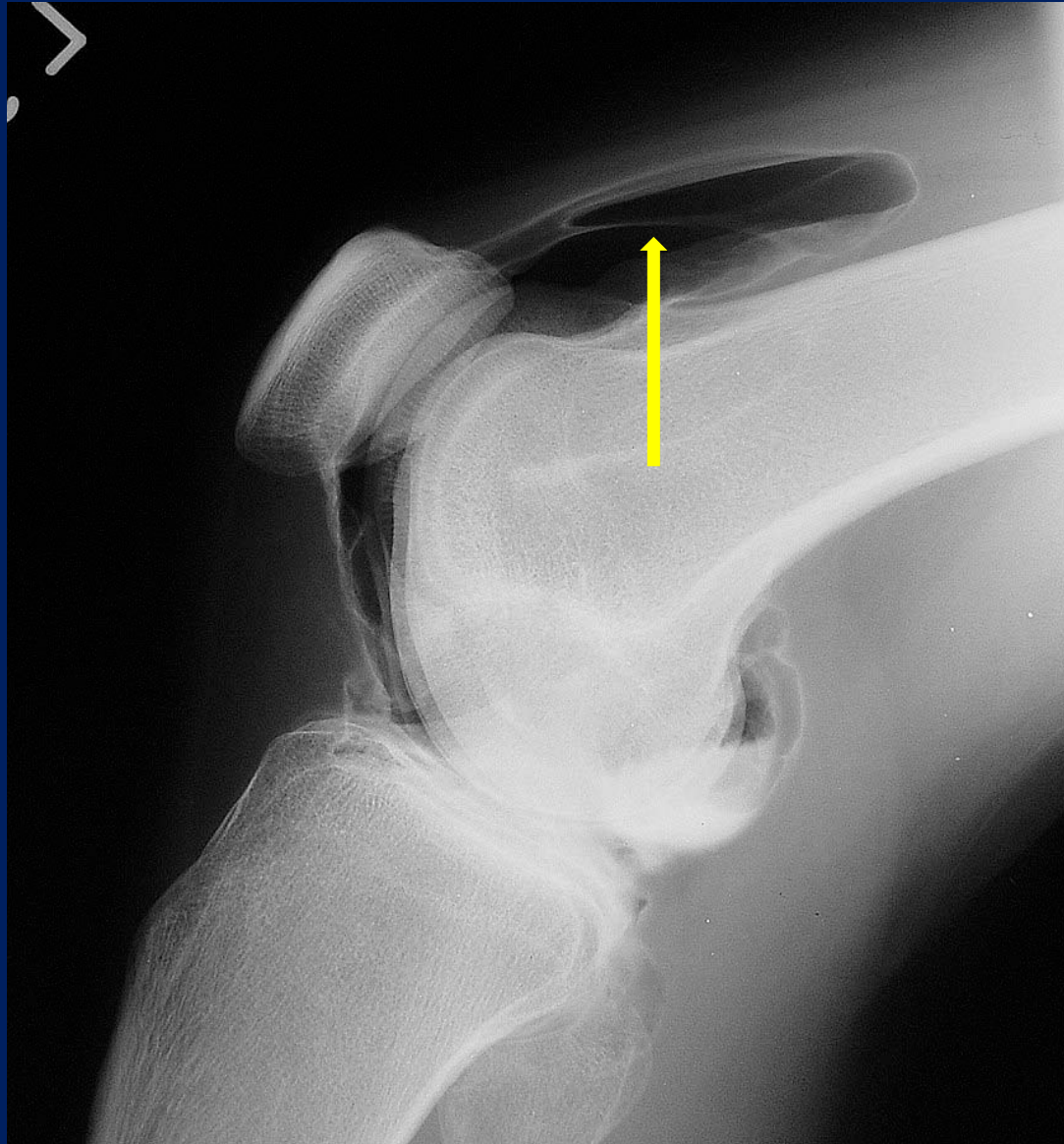
# Suprapatellar Plica

- Suprapatellar plica as seen during arthrography



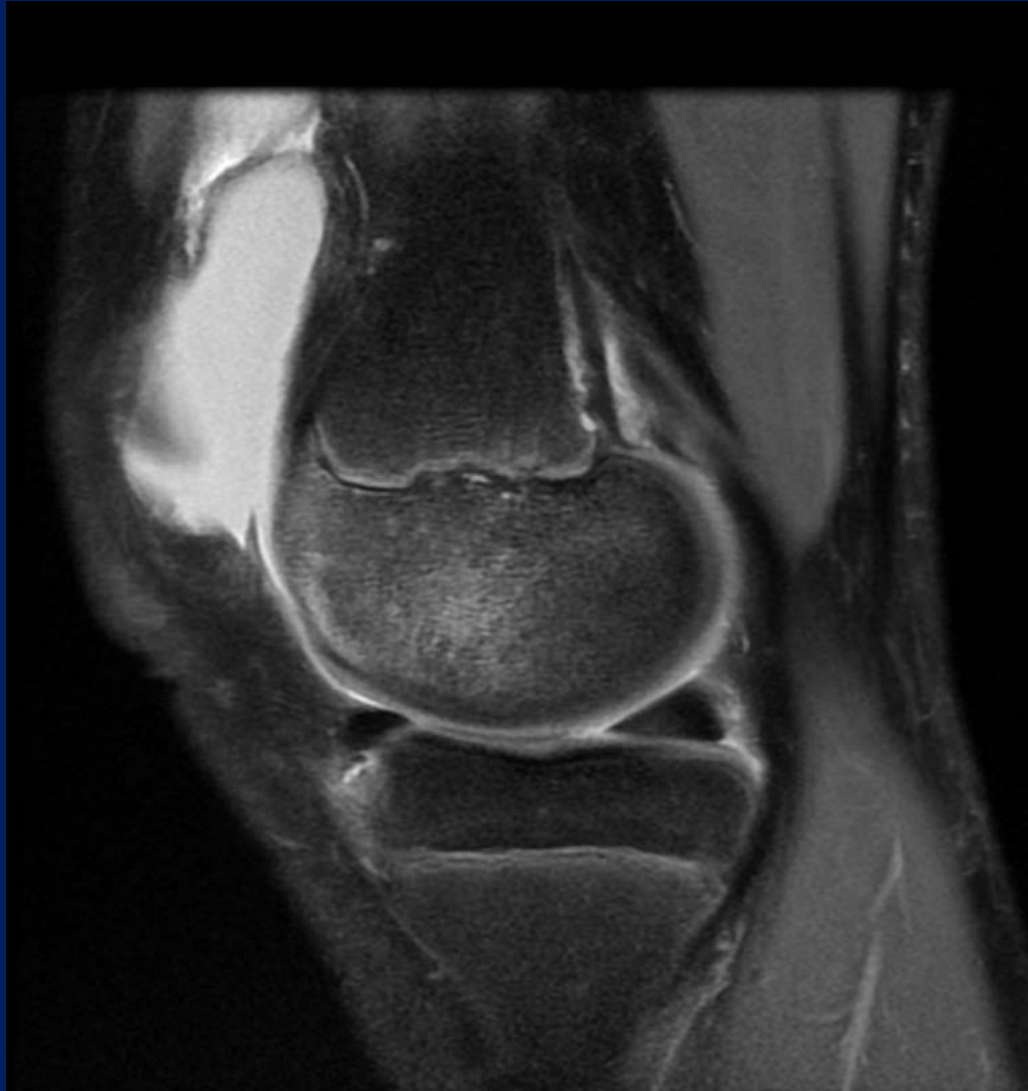**Figure 1.** Knee arthrography, lateral view: presence of a superior plica. Note the distance between the plica and the patellofemoral articular surfaces.

# Suprapatellar Plica



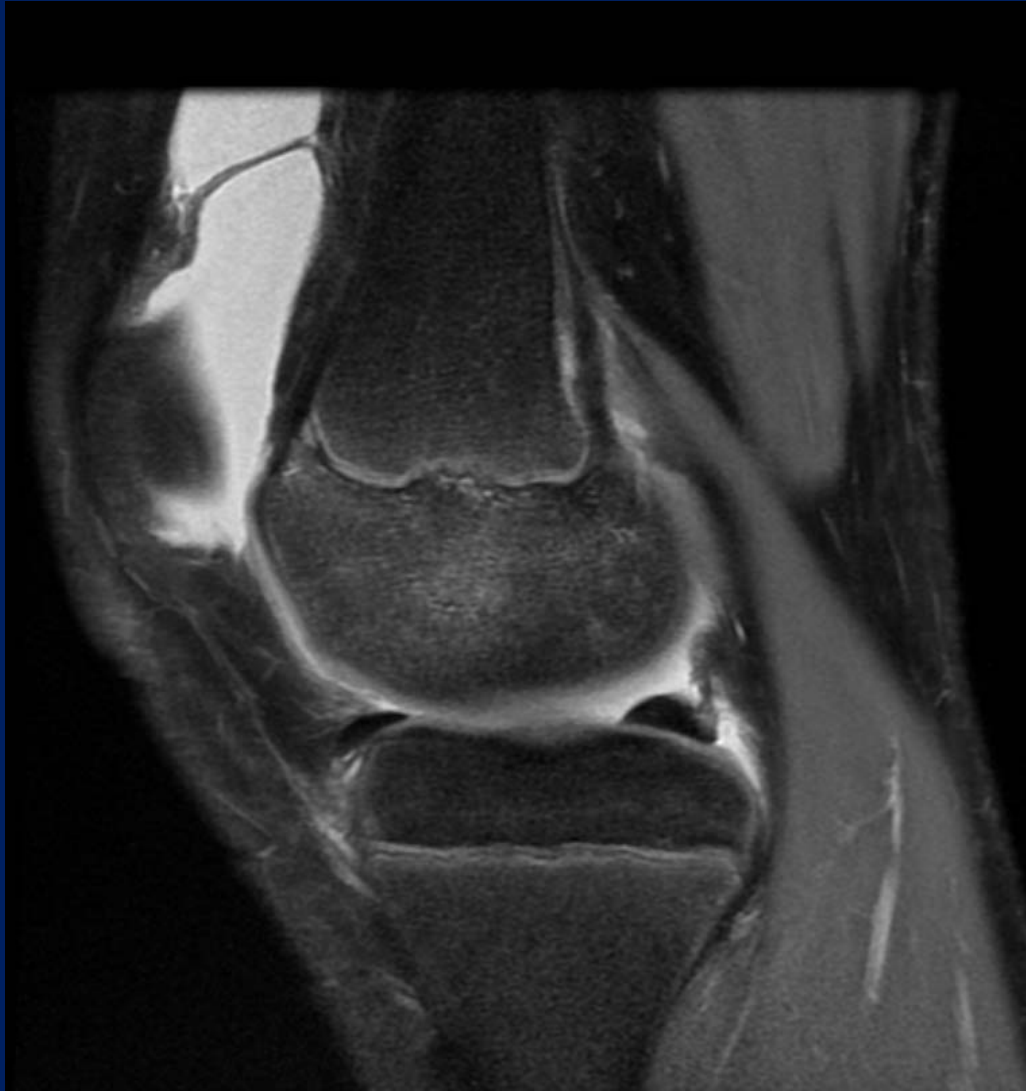Courtesy of Dr. D. Sartoris

# Suprapatellar Plica

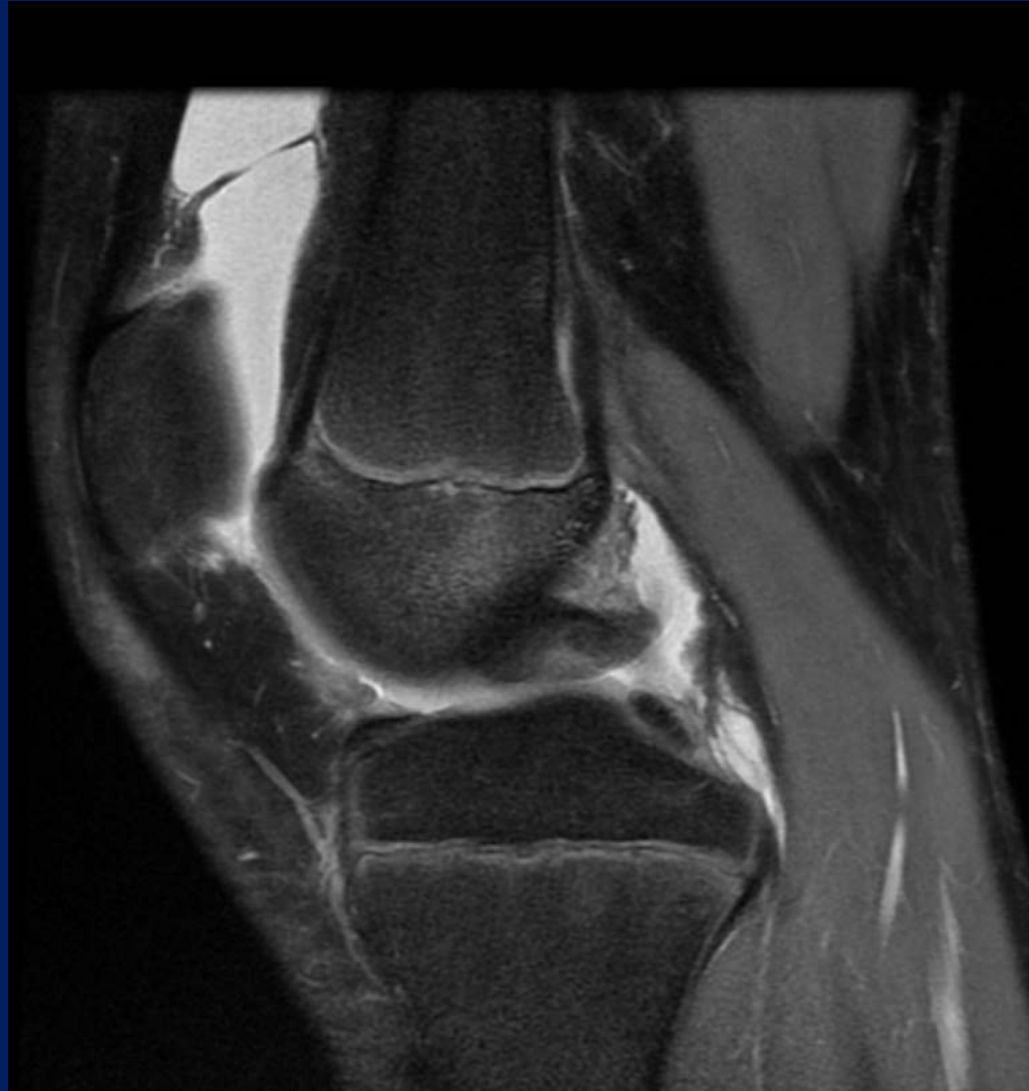



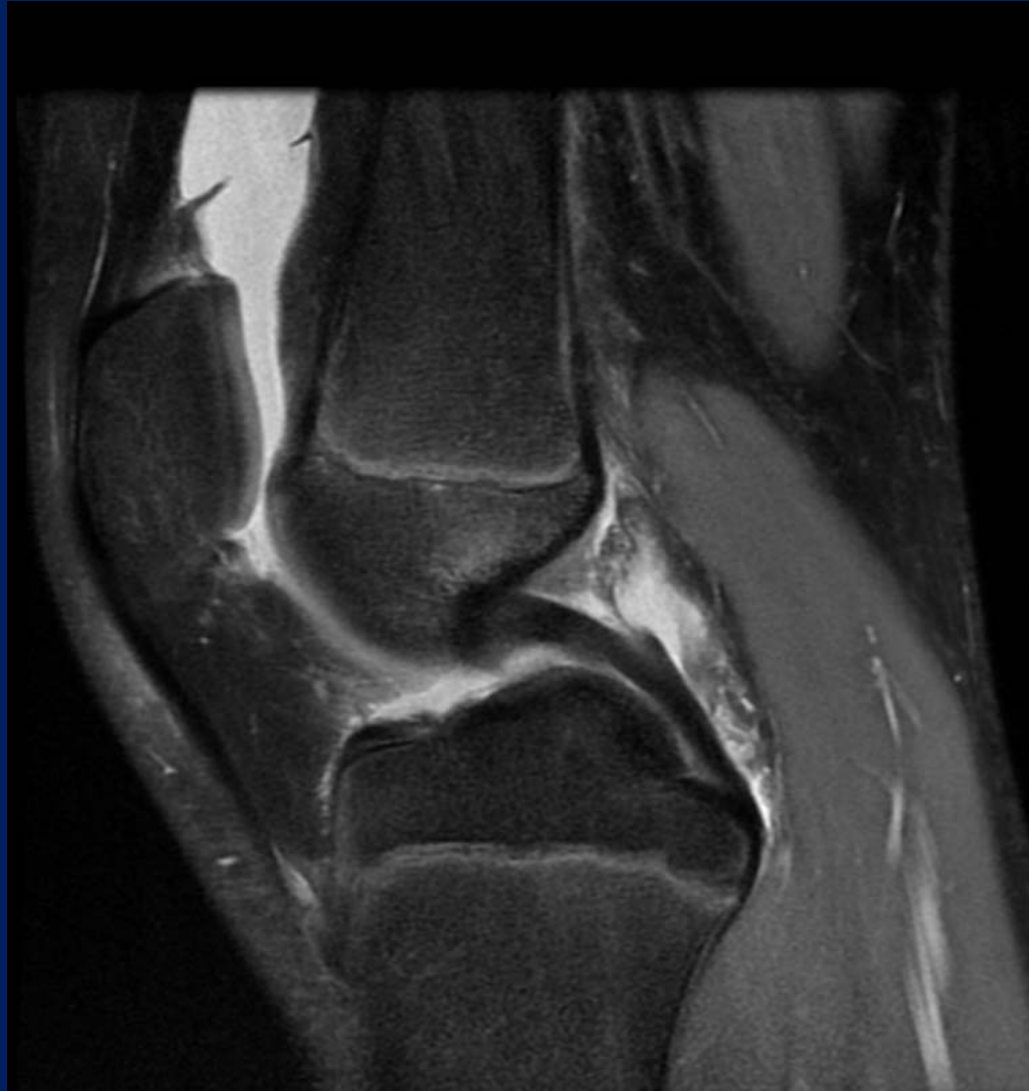# Suprapatellar Plica



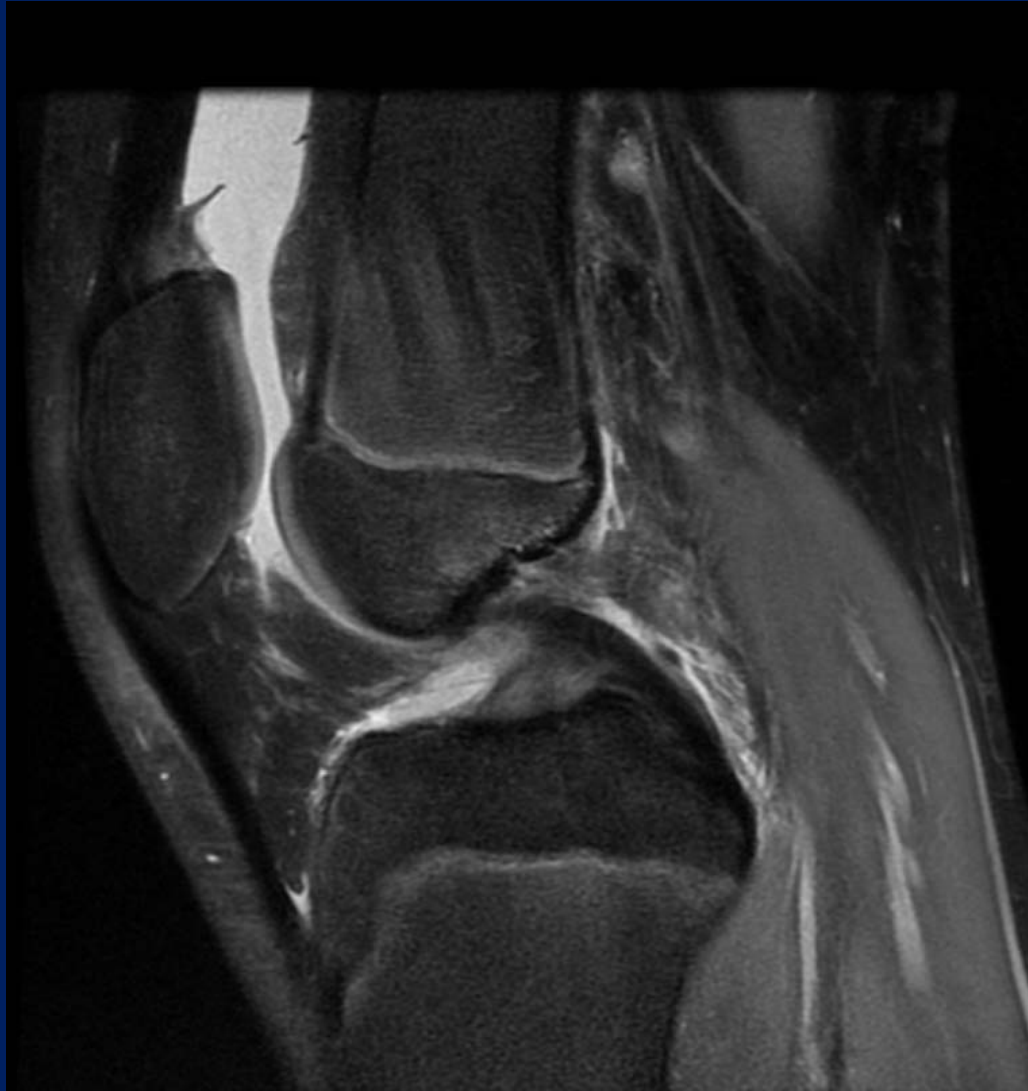# Suprapatellar Plica



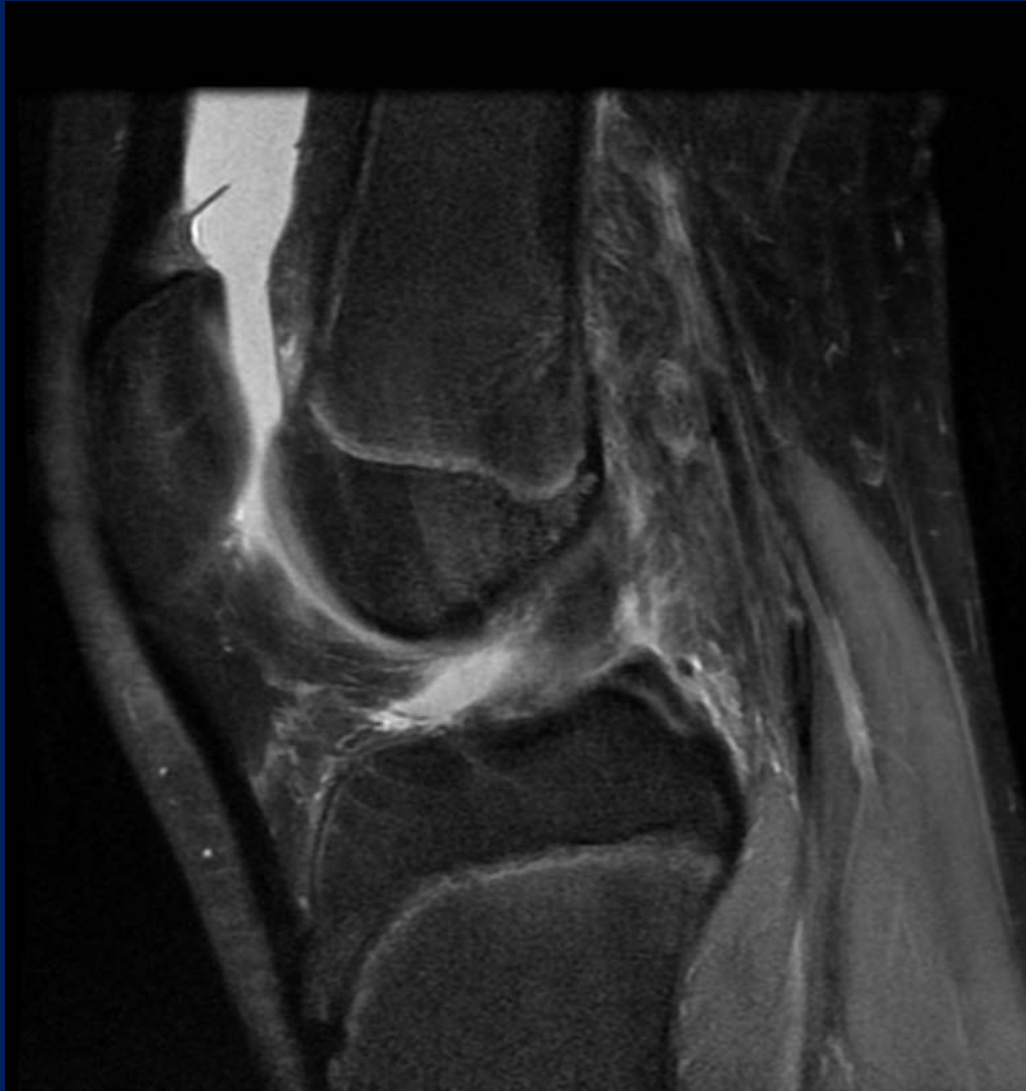# Suprapatellar Plica



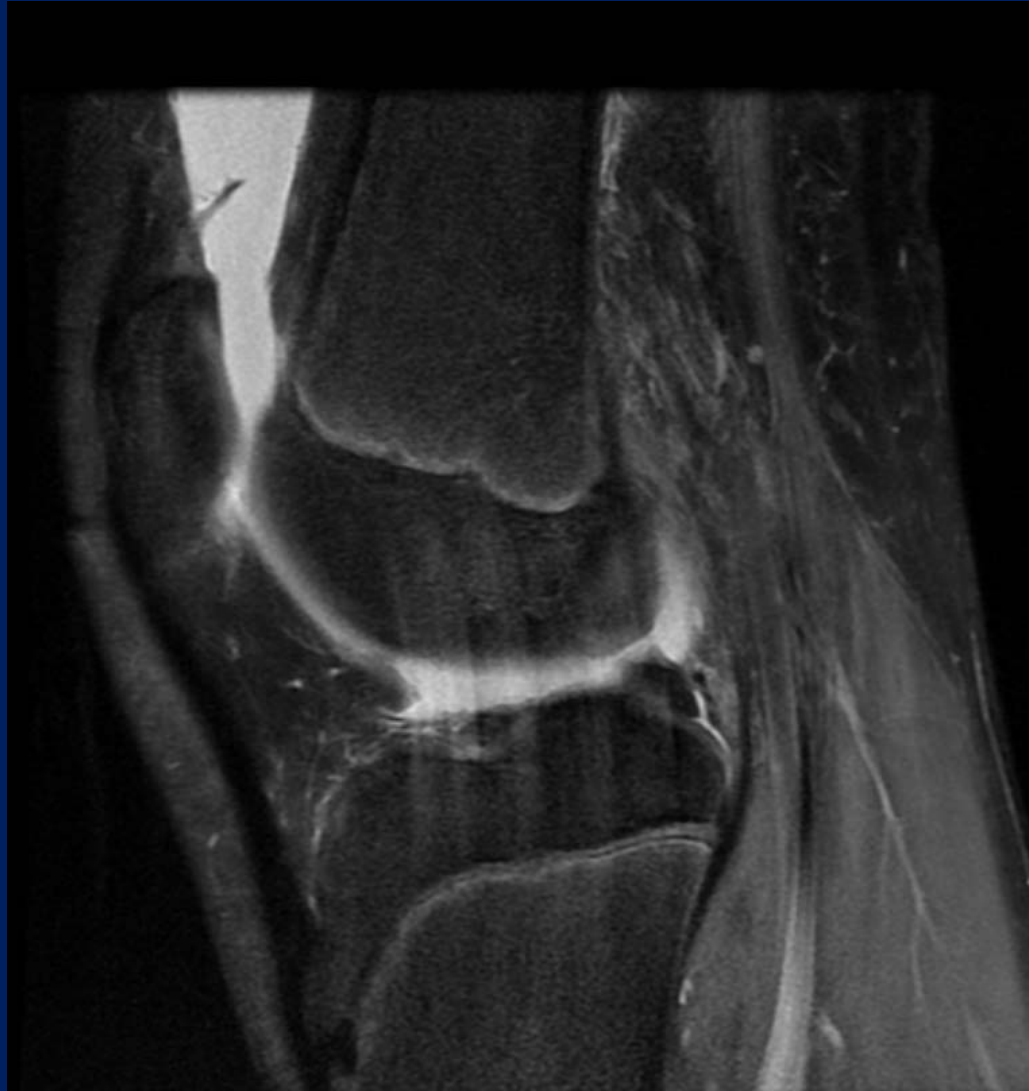# Suprapatellar Plica



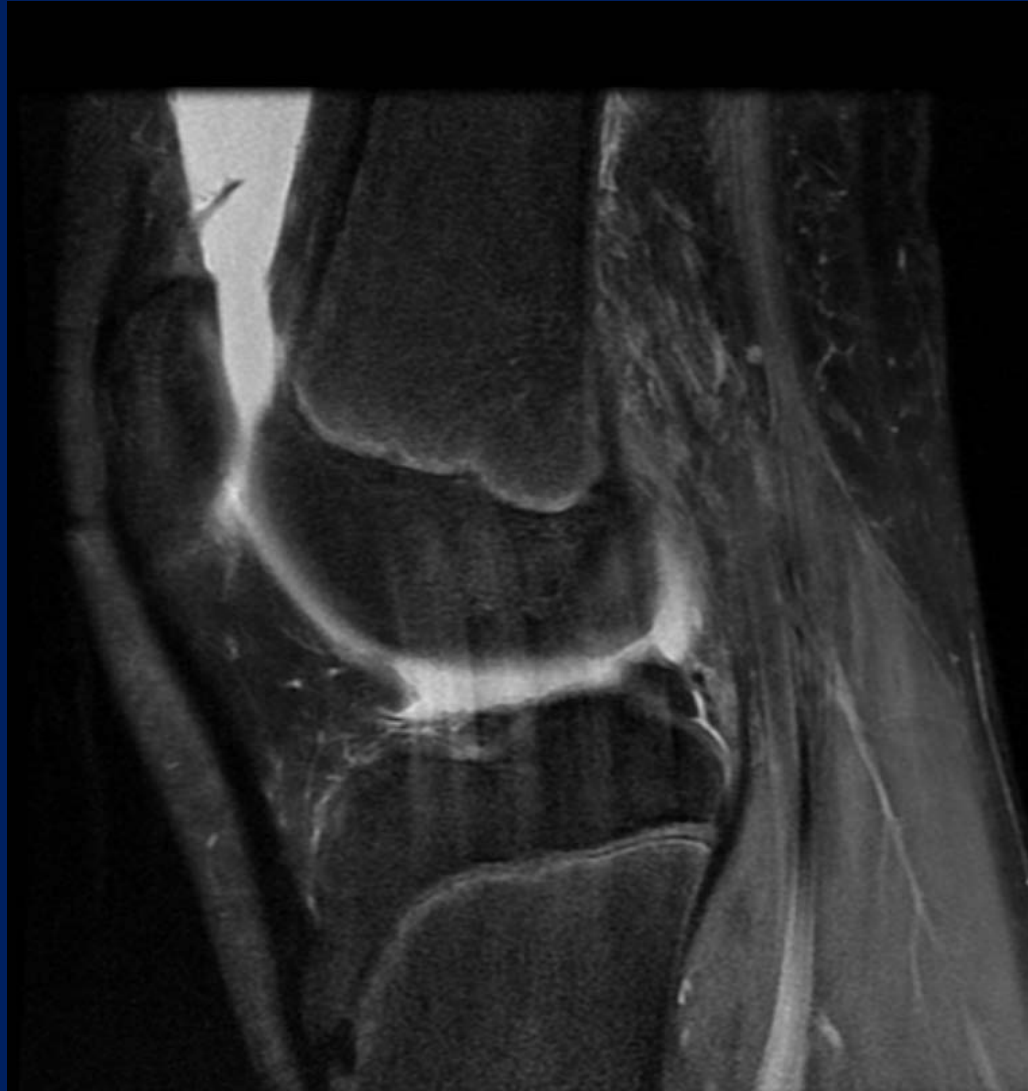# Suprapatellar Plica



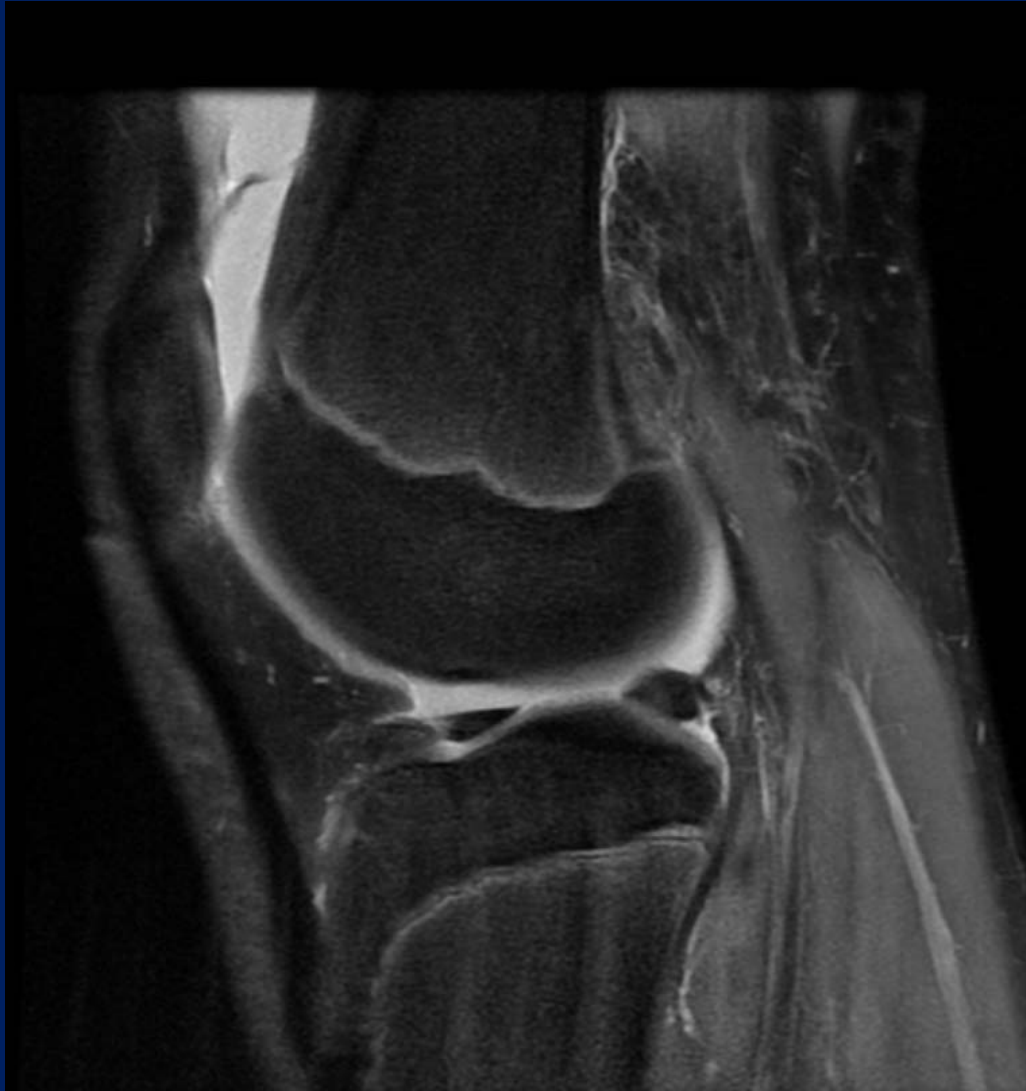# Suprapatellar Plica



# Suprapatellar Plica



# Suprapatellar Plica





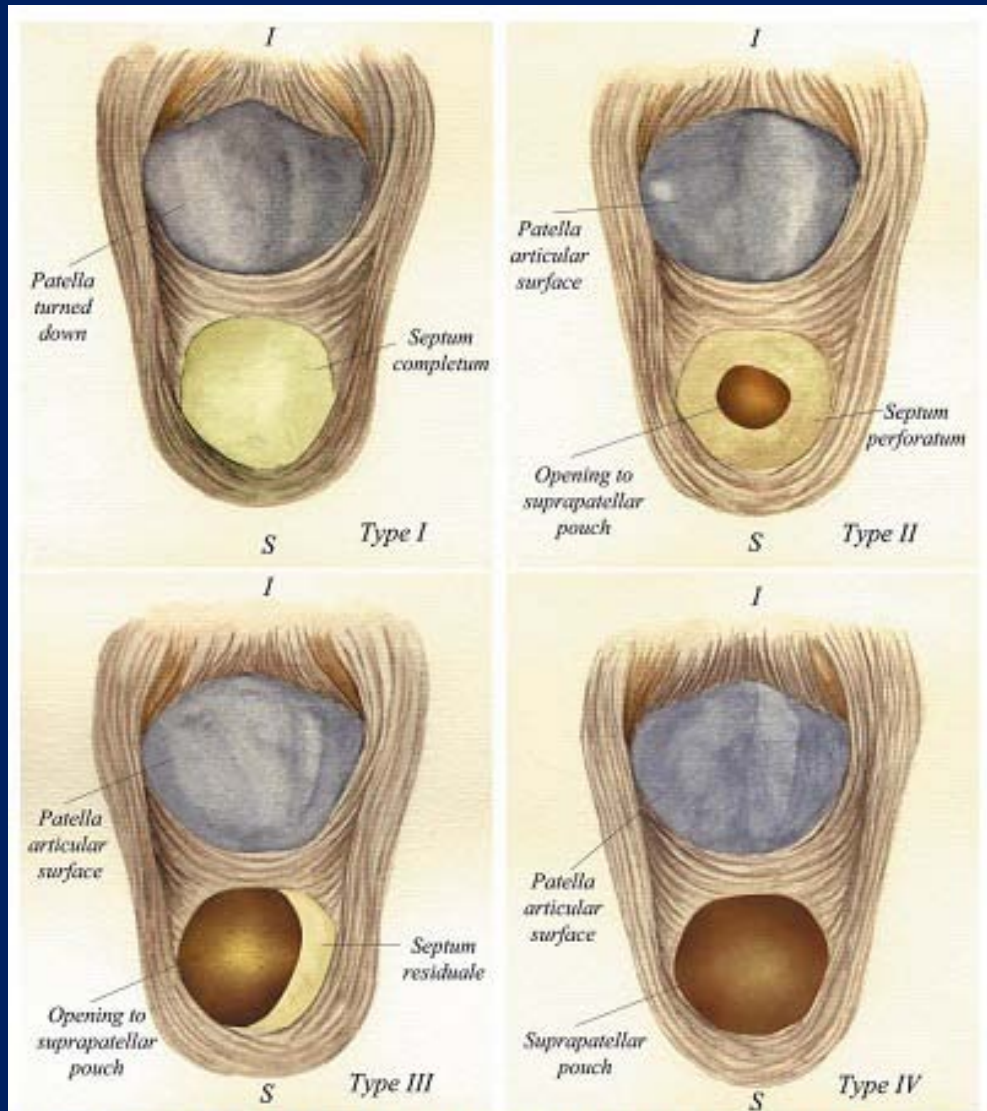
# Suprapatellar Plica

- Classification Systems:
  - **Zidorn Arthroscopic Classification System<sup>1</sup>**
    - Type I
      - *Septum completum*
      - Suprapatellar bursa and knee joint completely separated by septum
      - Incidence 16.2%<sup>20</sup>
    - Type II
      - *Septum perforatum*
      - One or more openings of varying size in the septum
      - Opening often called a “porta”
      - Incidence 29.5%<sup>20</sup>

# Suprapatellar Plica

- Classification Systems:
  - **Zidorn Arthroscopic Classification System**
    - Type III
      - *Septum residuale*
      - Residual fold remains, usually medially located
      - Incidence: 42.9%<sup>20</sup>
    - Type IV
      - *Septum extinctum*
      - Septum completely involuted
      - Incidence: 11.4%<sup>20</sup>

# Suprapatellar Plica



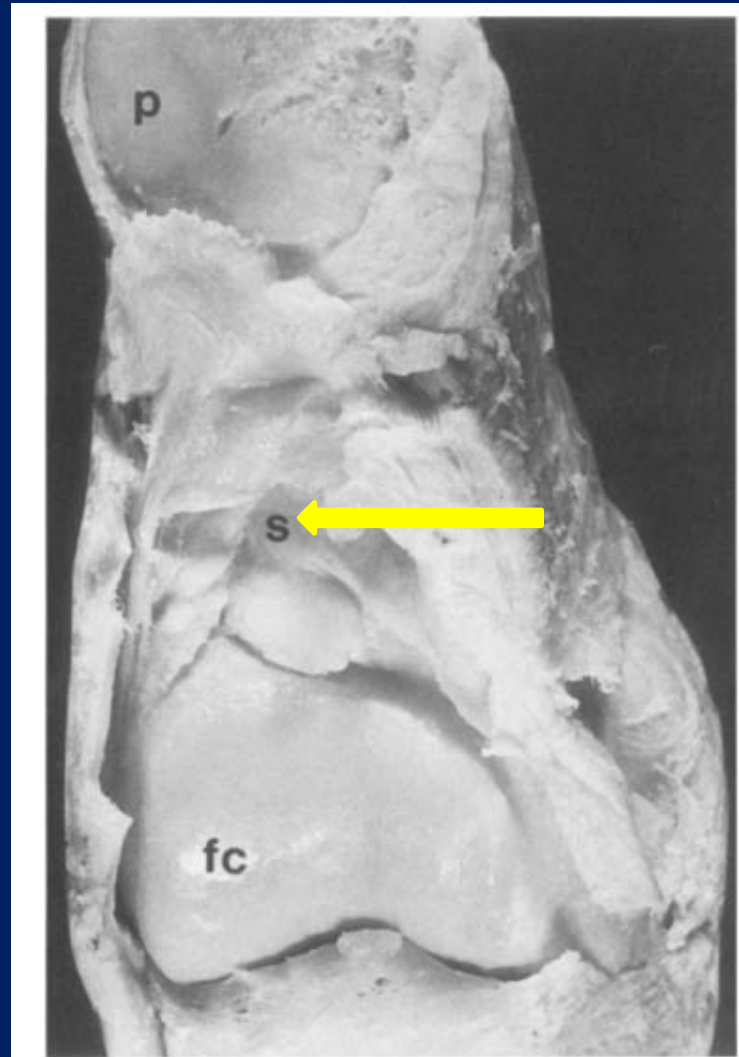
## Zidorn Classification of Suprapatellar Plica

**Figure 2.** Drawings illustrate the Zidorn classification scheme for suprapatellar septa: Type I (septum completum), in which the suprapatellar bursa and knee joint are completely separated by the septum; Type II (septum perforatum), in which there are one or more openings of varying size in the septum; Type III (septum residuale), in which there is a remaining fold, usually in a medial location; and Type IV (septum extinctum), in which the septum is completely involuted. *I* = inferior, *S* = superior.

Garcia-Valtuille R, Abascal F, Cerezal L, et al: Anatomy and MR Imaging Appearances of Synovial Plicae of the Knee. *Radiographics* 22: 775-784, 2002.

# Suprapatellar Plica

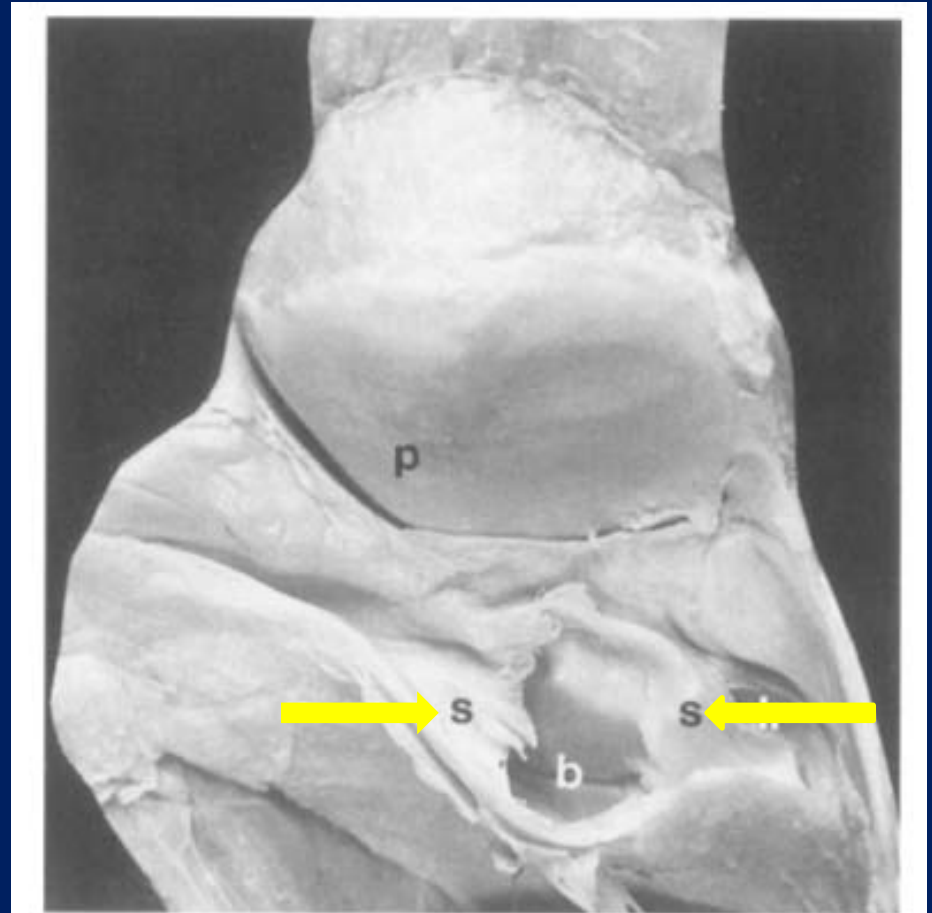
- Zidorn Type 1



**FIG. 3.** The suprapatellar bursa is separated from the knee joint cavity by a complete septum (s) and is not visible (p, patella; fc, femoral condyle).

# Suprapatellar Plica

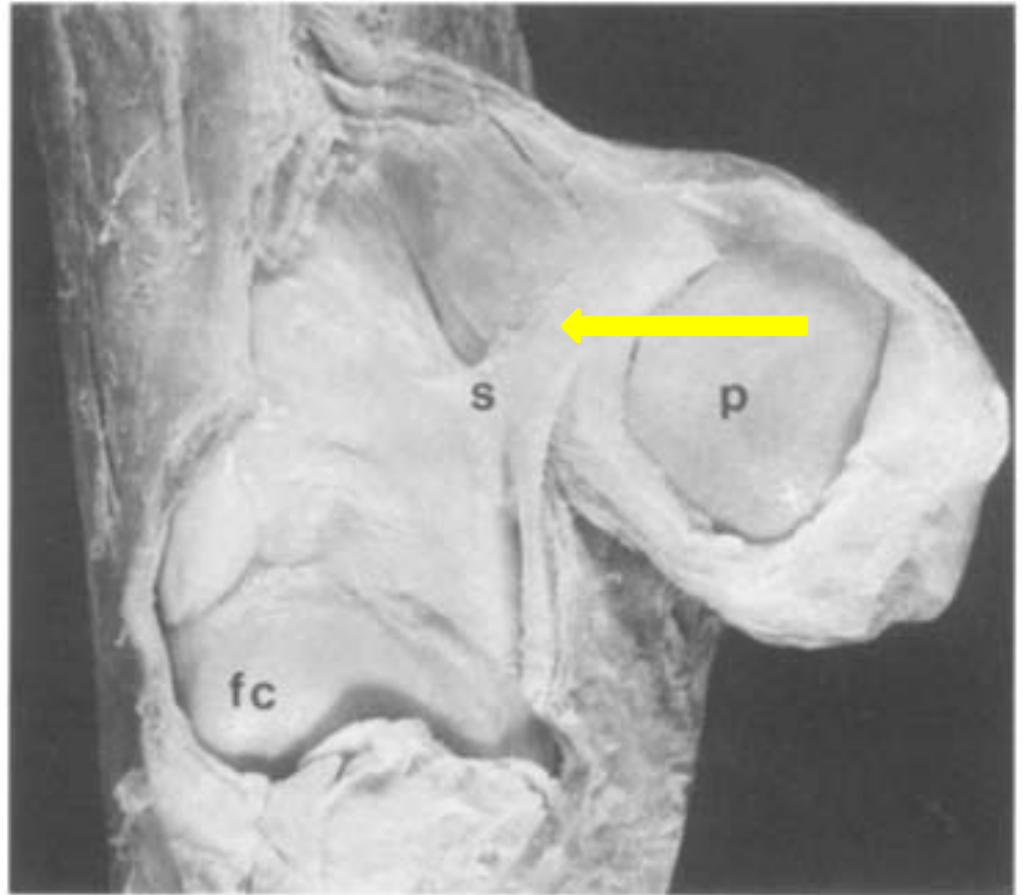
- Zidorn Type 2



**FIG. 4.** The knee joint cavity and the suprapatellar bursa (b) communicate via a central perforation of the suprapatellar septum (s), the so-called "porta." An additional opening on the lateral side leads into the lateral suprapatellar recess (lr).

# Suprapatellar Plica

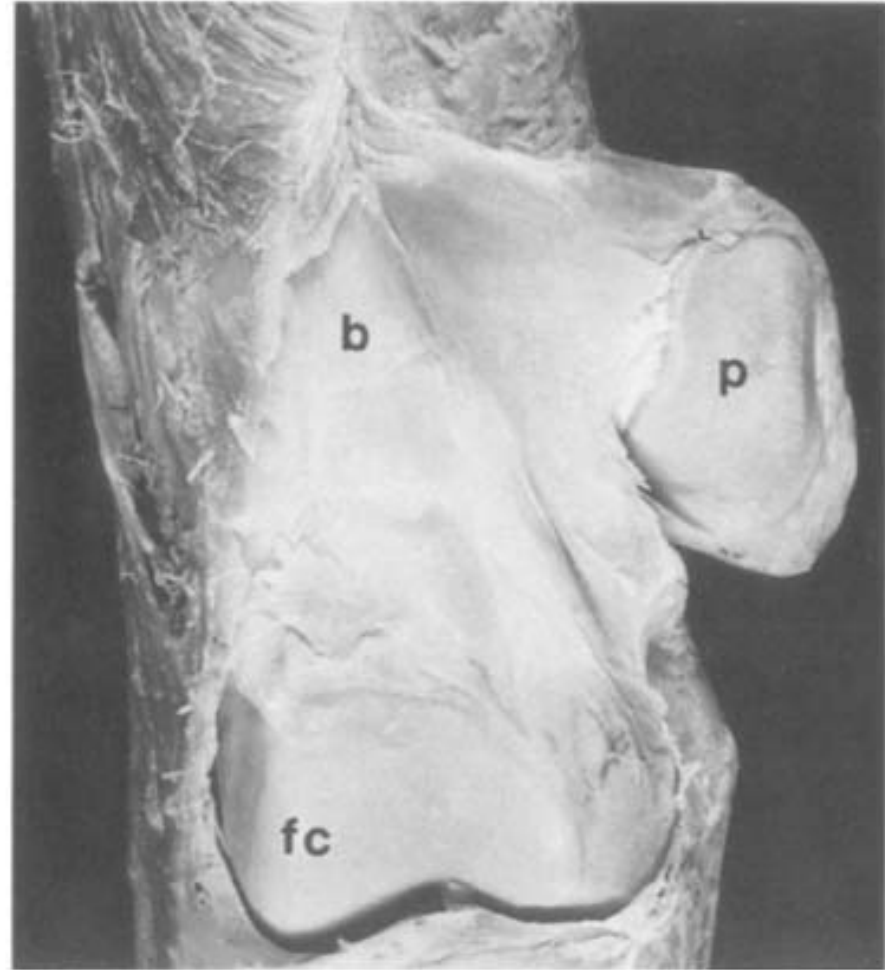
- Zidorn Type 3



**FIG. 5.** A right knee joint with a medial residual fold (s). This structure is the most common type of the suprapatellar septum and is also called "suprapatellar plica" (p, patella; fc, femoral condyle).

# Suprapatellar Plica

- Zidorn Type 4



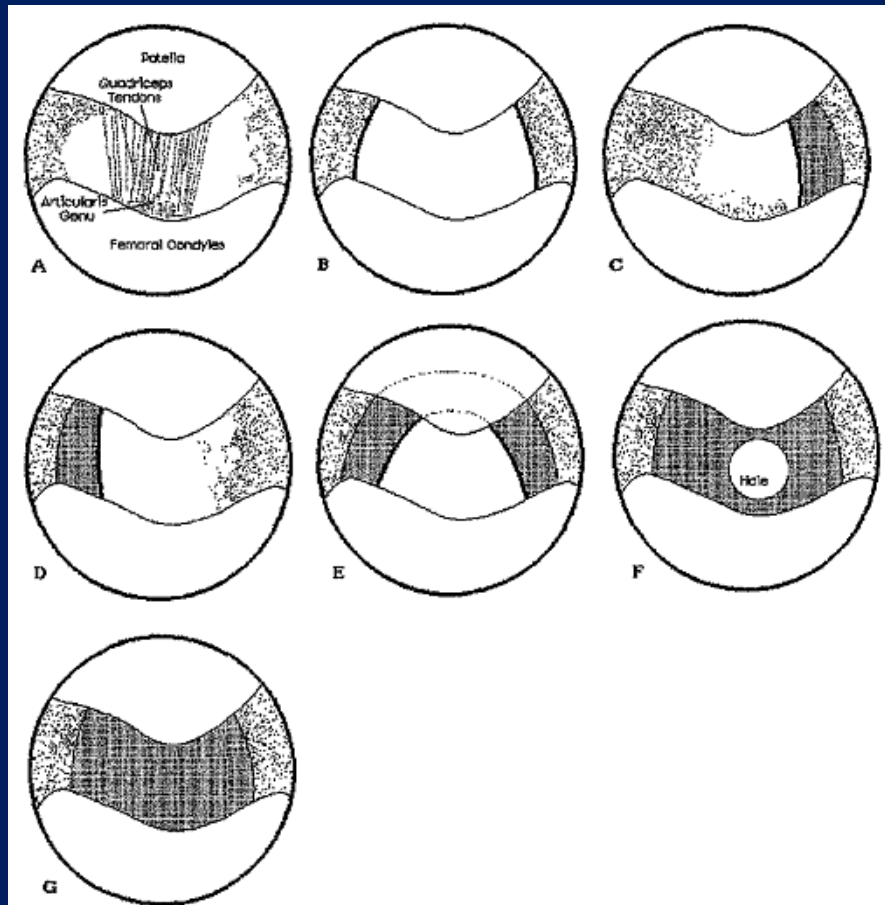
**FIG. 6.** A completely involuted suprapatellar septum. The border between the former suprapatellar bursa (b) and the knee joint is no longer visible (p, patella; fc, femoral condyle).

# Suprapatellar Plica

- Kim and Choe Arthroscopic Classification System<sup>9</sup>:
  - Absent
    - No sharp edged fold
  - Vestigial
    - Plica with less than 1 mm protrusion. Disappeared with external pressure
  - Medial
    - Plica lying on medial side of the suprapatellar pouch
  - Lateral (1.3% rarest)
    - Plica lying on lateral side of the suprapatellar pouch
  - Arch (28.5% - most common)
    - Plica present medially, laterally, and anteriorly but not over the anterior femur
  - Hole
    - Plica extending completely across the suprapatellar pouch but with a central defect
  - Complete (20.5% - 2<sup>nd</sup> most common)
    - Plica dividing the suprapatellar pouch into two separate compartments



# Suprapatellar plica



**FIG 1.** Illustrations for patterns of suprapatellar plica in the right knee. (A) absent; (B) vestigial; (C) medial; (D) lateral; (E) Arch; (F) hole; (G) complete septum. Each pattern may have one of various width (up to one third, between one and two thirds, or more than two thirds of the width of the suprapatellar pouch) with lateral cave, tunnel, or nothing.

# Infrapatellar Plica

# Infrapatellar Plica

- Synonyms in the literature<sup>2</sup>
  - Ligamentum mucosum
  - Inferior plica
  - Plica synovialis patellaris
  - Plica synovialis patellae
  - Infrapatellar fold
  - Infrapatellar septum

# Infrapatellar Plica

- Anatomy
  - Very commonly seen on arthroscopy; much less commonly seen on MR
  - Intercondylar notch
  - Anterior to the anterior cruciate ligament
    - May be separate, fenestrated or continuous with the anterior cruciate ligament
  - Thin proximally and attaches to the very anterior aspect of the intercondylar notch
  - It widens as it descends anteriorly and inferiorly through Hoffa's fat pad to attach to the inferoposterior aspect of the patella.
  - After attaching to the inferior aspect of Hoffa's fat pad it gives off two alar folds that extend laterally to cover the fat pad<sup>21</sup>

# Infrapatellar Plica

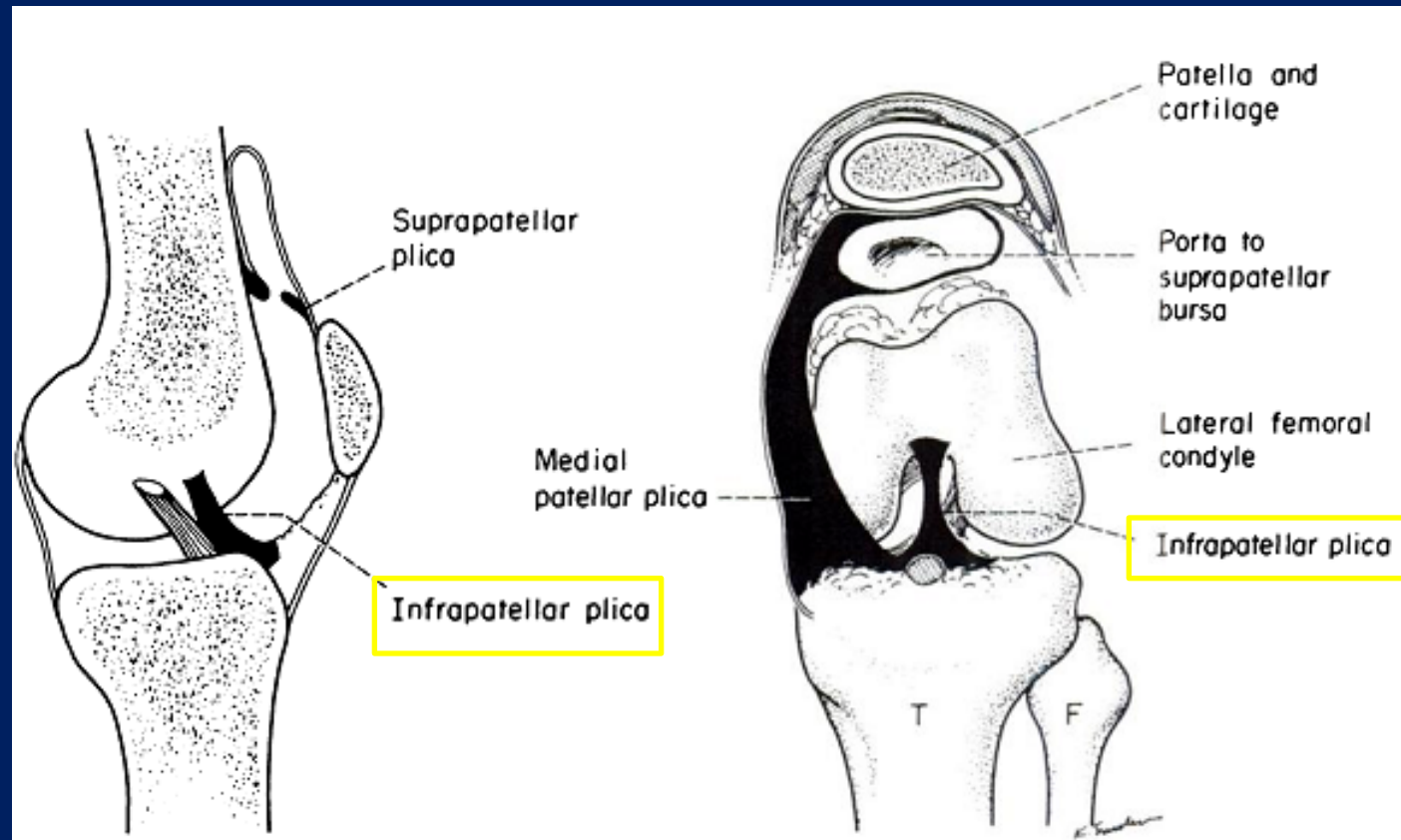
- Anatomy cont'd:
  - The plica then thins and runs through the Hoffa's fat pad and often attaches to the inferior aspect of the patella<sup>29</sup>
  - Fibrous septa within Hoffa's fat pad may connect the plica to the patellar tendon<sup>29</sup>
  - Purpose of infrapatellar plica:<sup>28</sup>
    - Prevents excessive anterior displacement of Hoffa's pad in the setting of a large joint effusion
    - Alar folds help to maintain the medial and lateral aspects of the Hoffa's fat pad in the presence of a large joint effusion
  - May be extremely thin and thread-like to very thick (as large as the ACL itself)
    - May be mistaken for the ACL in ACL-deficient knees

# Infrapatellar Plica

- Incidence
  - Most common plica seen at arthroscopy<sup>1</sup>
    - Seen in the vast majority of arthroscopies
    - Often must be cut to visualize the anterior cruciate ligament
  - Overall incidence at arthroscopy 86%<sup>5</sup>
    - Seen on nearly all the time

# Infrapatellar Plica

- Schematic diagram demonstrating the infrapatellar plica

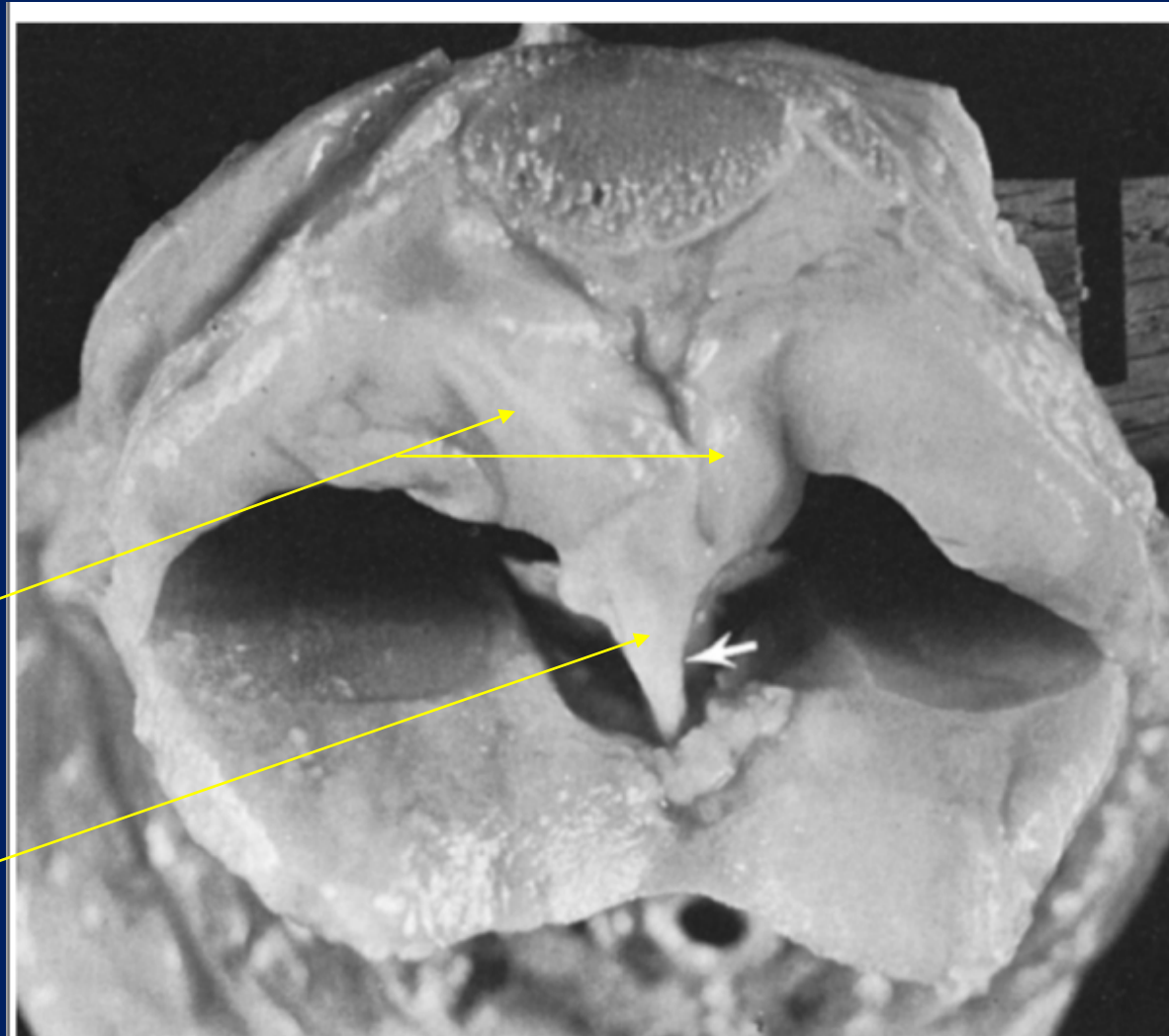


# Infrapatellar Plica

- Transverse section at level of intercondylar notch in a cadaver. Patella retracted anteriorly and superiorly
- Infrapatellar plica indicated by white arrow

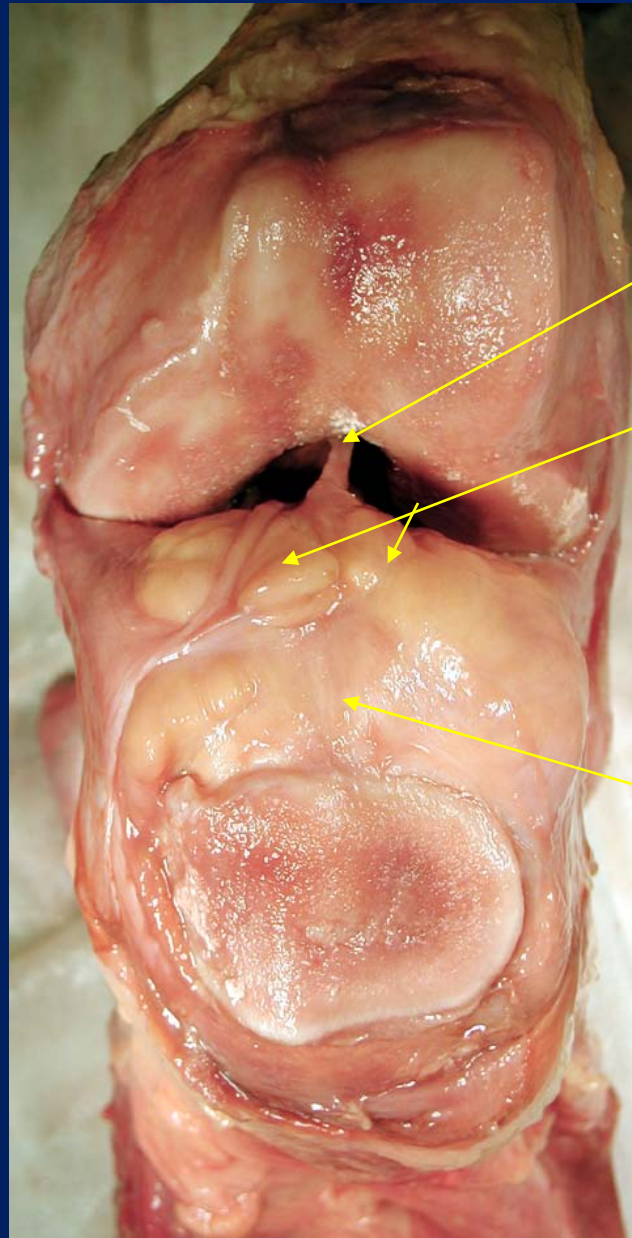
Medial and lateral alar folds of infrapatellar plica

Infrapatellar plica





# Infrapatellar Plica



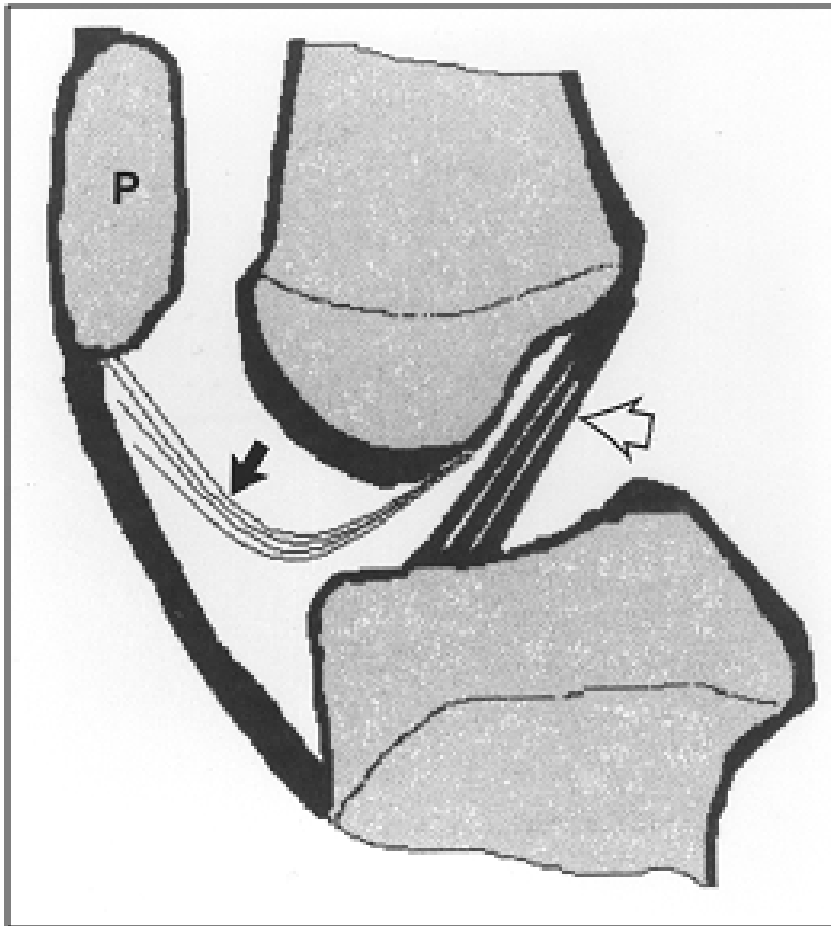
Infrapatellar plica

Alar folds

Infrapatellar plica extending  
toward inferior aspect of  
patella

Courtesy of Dr. T. Hughes

# Infrapatellar Plica



A

Fig. 1.—Normal infrapatellar plica.

A, Schematic drawing of knee in sagittal section through intercondylar notch shows infrapatellar plica (black arrow) extending from inferior pole of patella (P) or immediately adjacent fat, through Hoffa's fat pad, to intercondylar notch of femur anterior to anterior cruciate ligament (white arrow).

B, Sagittal fast spin-echo T2-weighted MR image (TR/TE, 4000/72) with fat suppression through intercondylar notch shows normal infrapatellar plica as thin, linear low-signal-intensity structure (black arrow) in Hoffa's fat with more prominent intercondylar component (straight white arrows) lying anterior to anterior cruciate ligament (curved white arrows), proximal attachment in intercondylar portion of femur, and distal visualized portion attaching to prominent transverse ligament.

C, Sagittal fast spin-echo T2-weighted MR image (4000/72) with fat suppression through intercondylar notch shows partially resorbed or less prominent intercondylar infrapatellar plica (arrows), with portion in Hoffa's fat as only visible component on MR image.

# Infrapatellar Plica

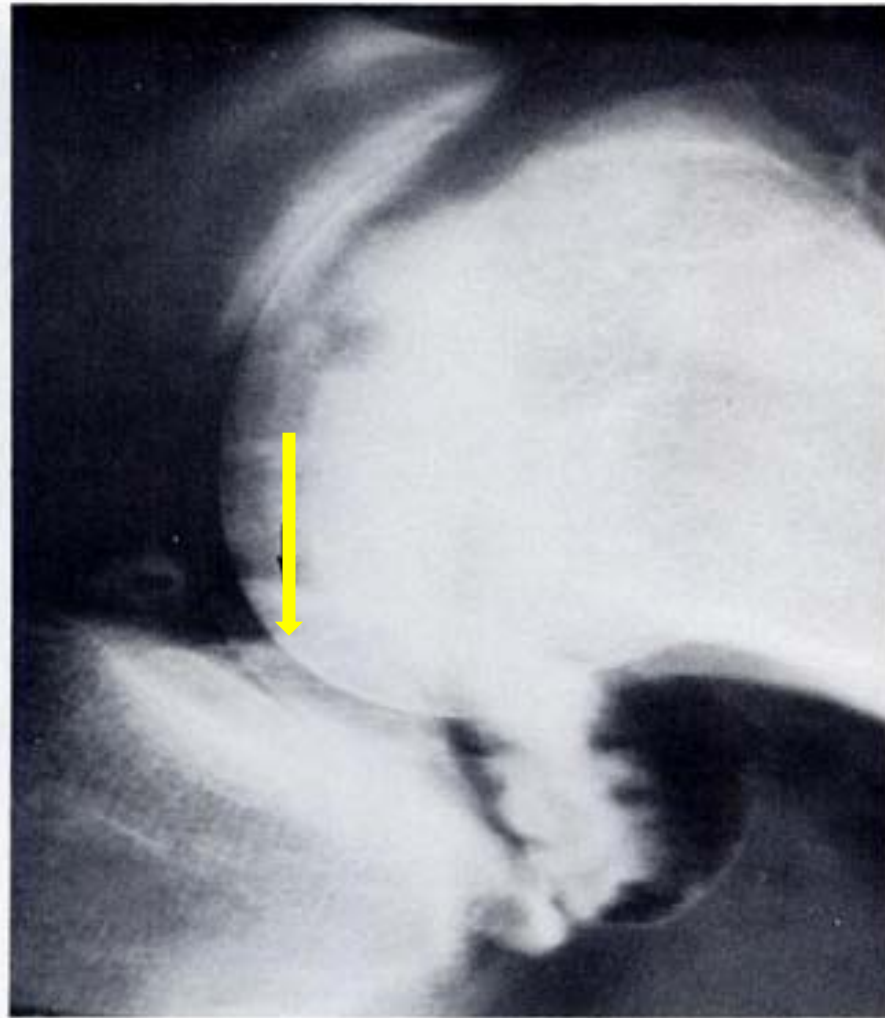
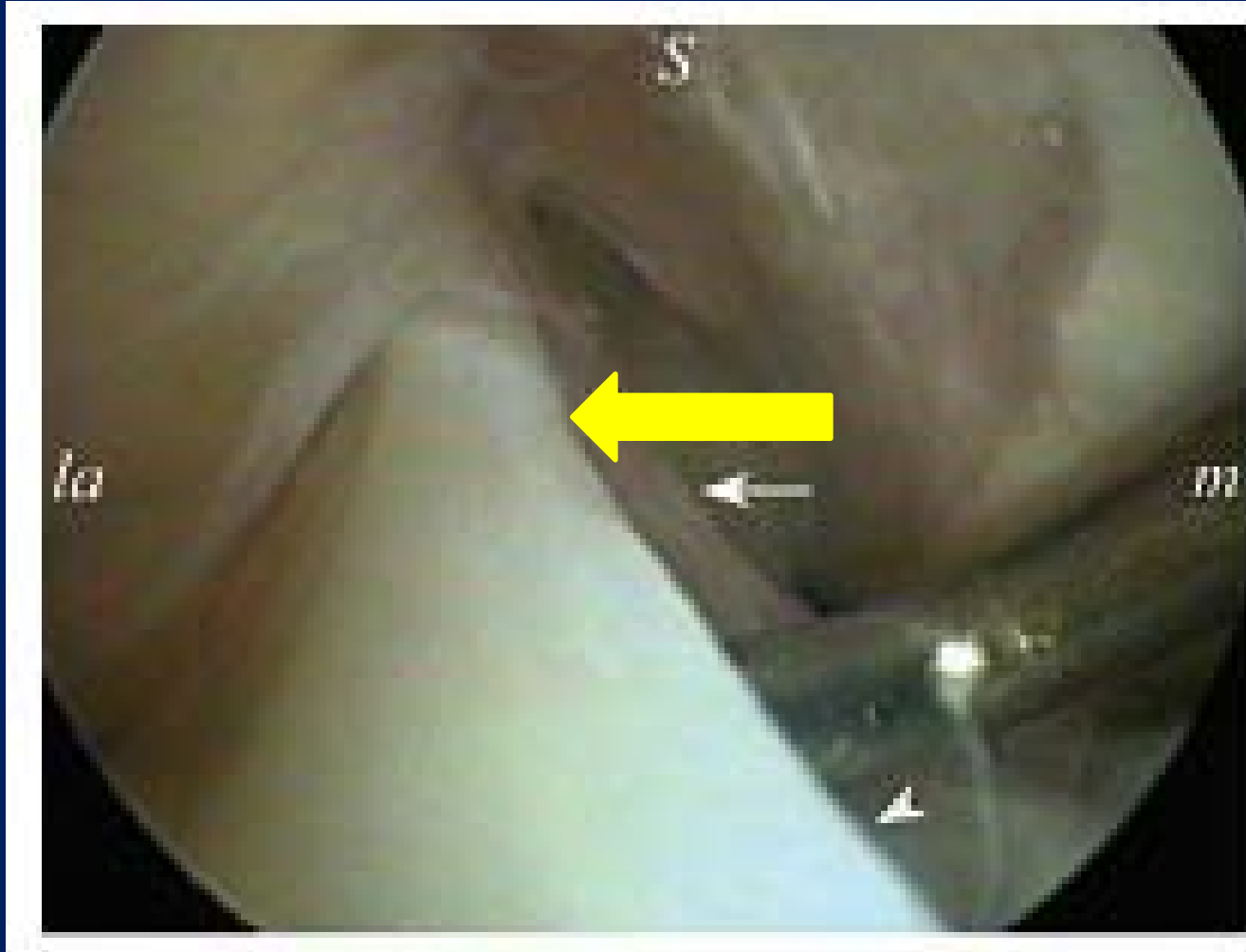

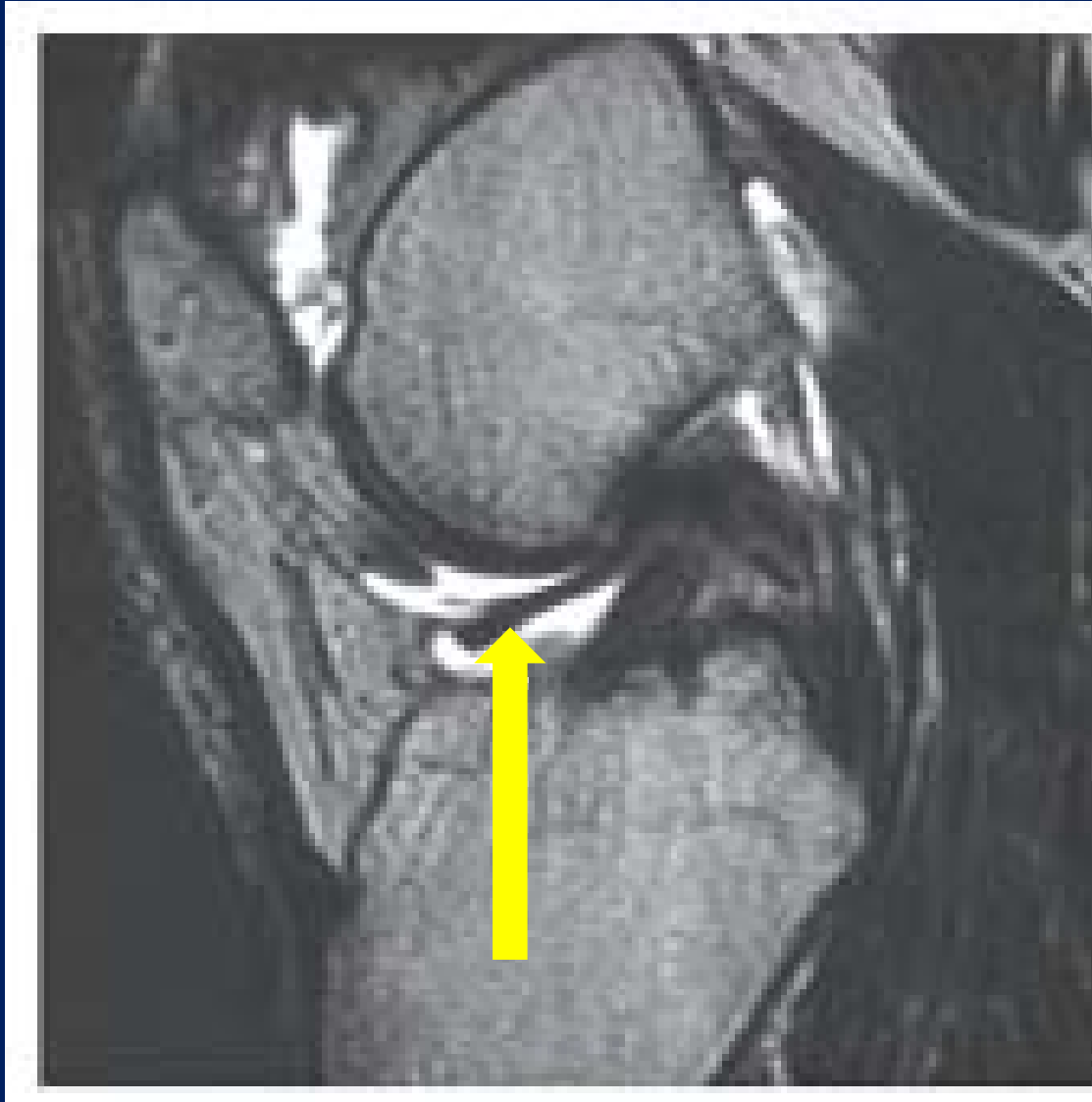
Fig. 6. Infrapatellar plica. Lateral view from a double contrast arthrogram depicts the plica in a patient with anterior cruciate disruption (arrow). (Reproduced with permission from Ref. 1.)

# Infrapatellar Plica

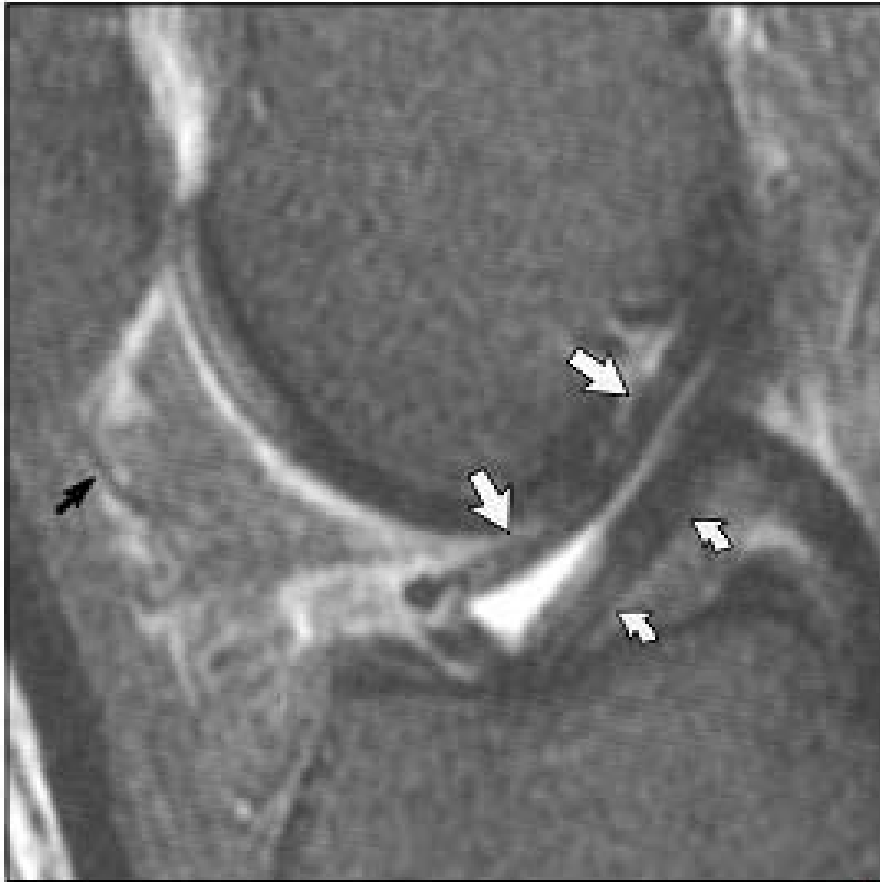- Infrapatellar plica (yellow arrow)
- ACL (white arrow)



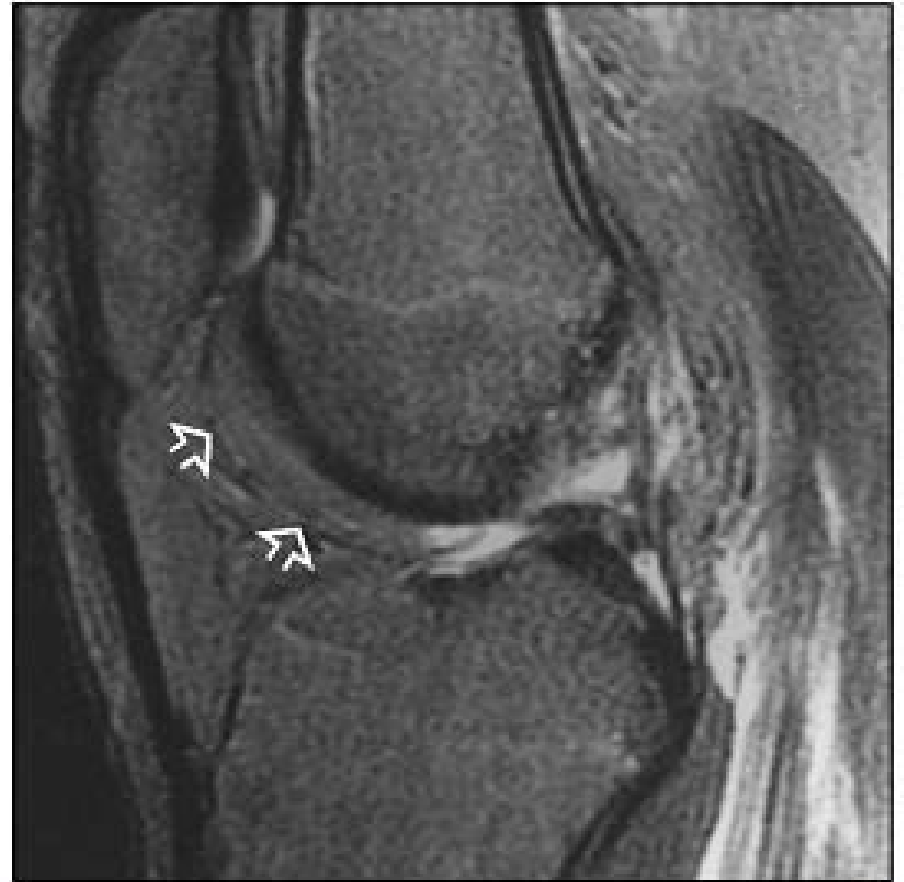# Infrapatellar Plica



# Infrapatellar Plica



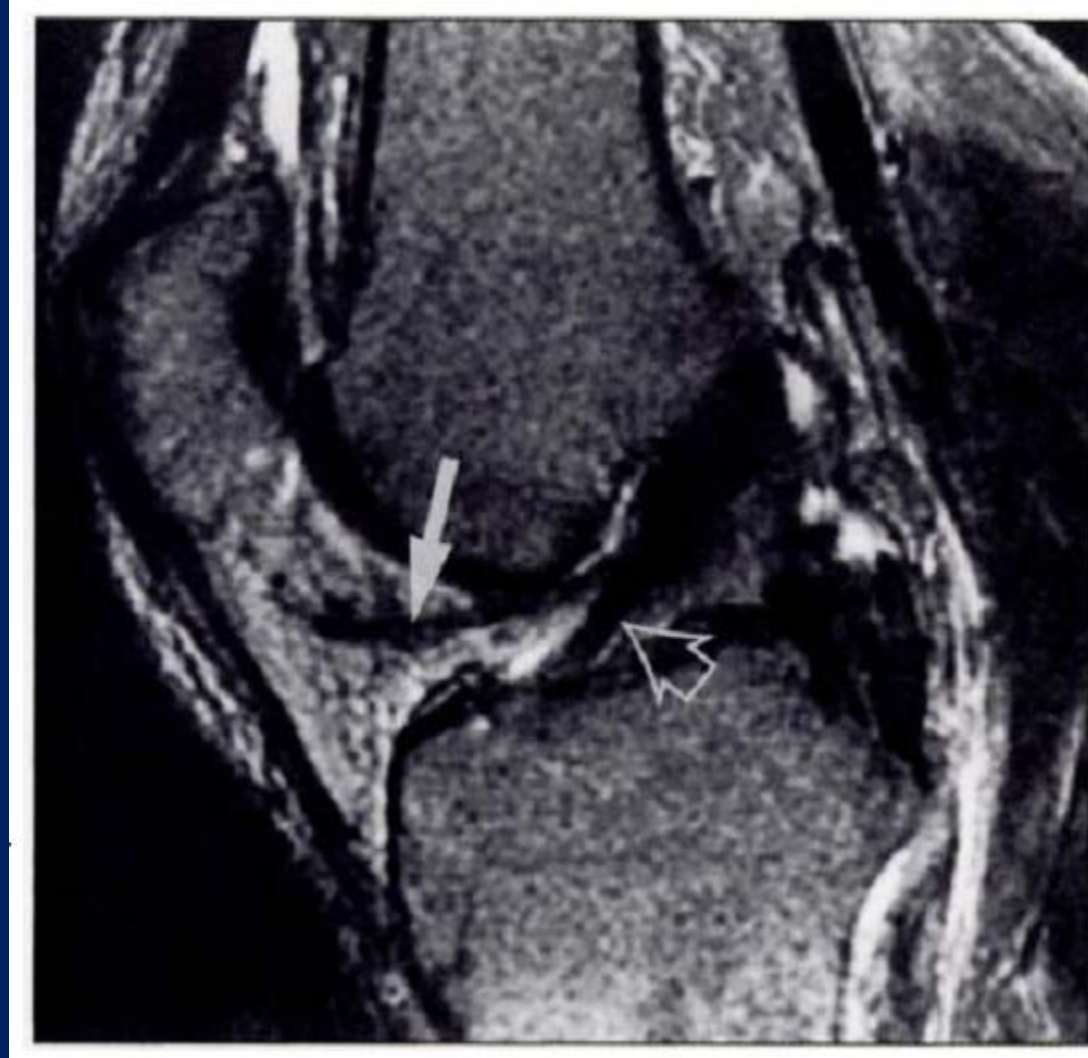
**B**



**C**

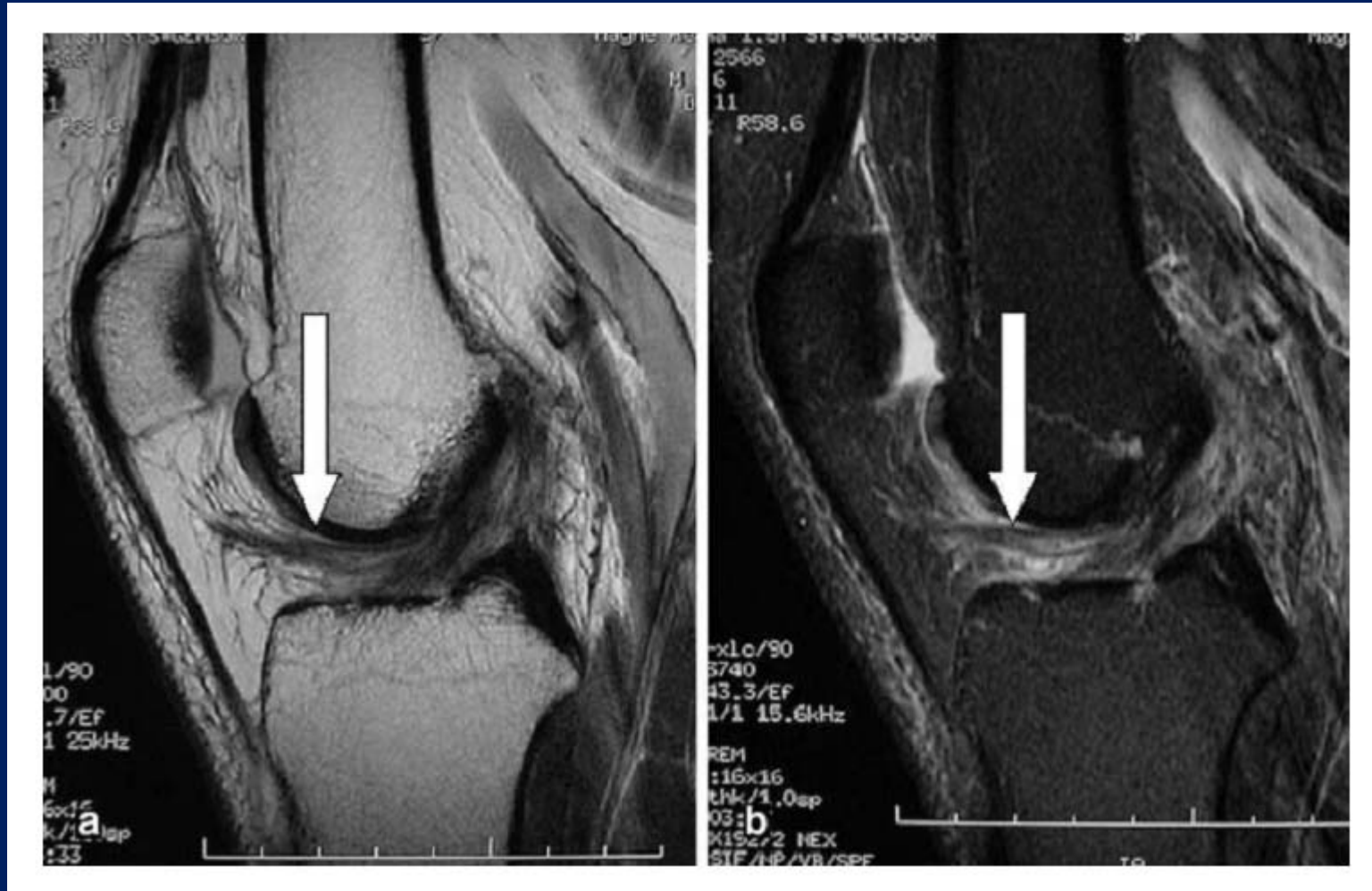# Infrapatellar Plica

- 40 year old male with surgically confirmed infrapatellar plica
- Plica courses from the intercondylar notch and attaches to the inferior pole of the patella and Hoffa's fat pad



# Infrapatellar Plica

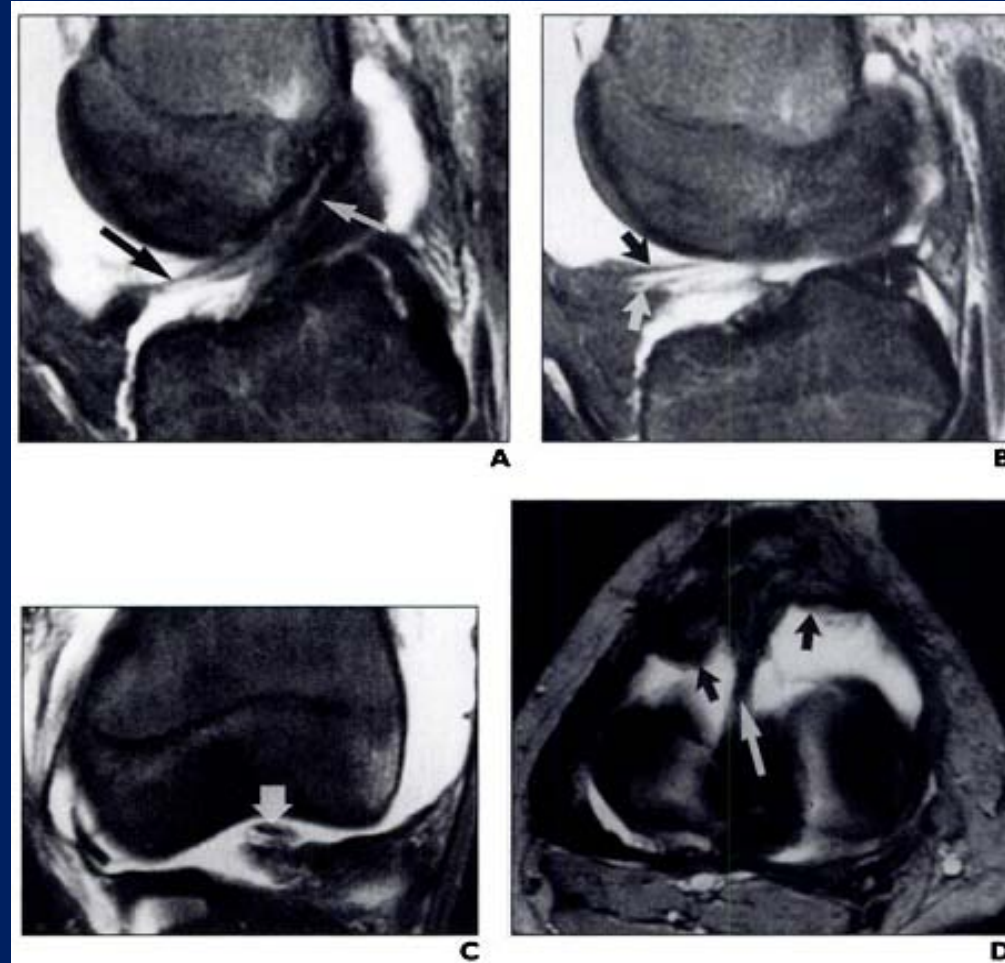
- Infrapatellar plica nicely demonstrating extension into the infrapatellar fat pad





# Infrapatellar Plica

- Infrapatellar plica seen in three orthogonal planes
- Alar folds of the infrapatellar plica extend medially and laterally and are responsible for maintaining the shape of the fat pad in the presence of an effusion<sup>21</sup>
- Infrapatellar plica seen in 0.4% of MR, markedly less than number reported at arthroscopy<sup>21</sup>



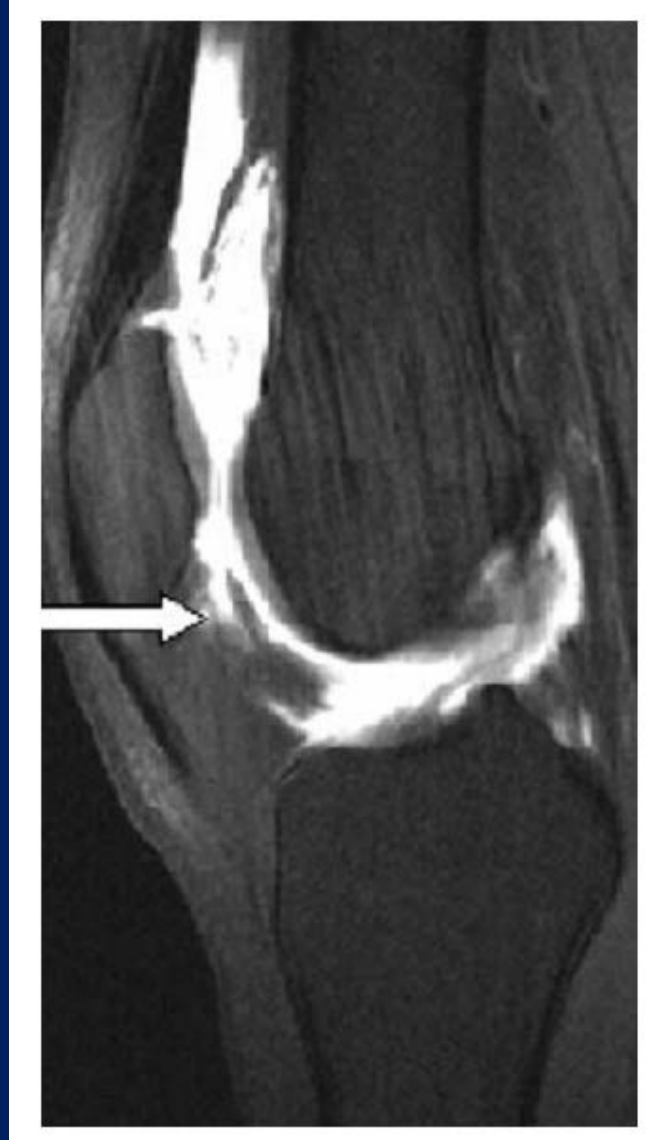**Fig. 4.**—15-year-old boy with large knee effusion after patellar dislocation.  
**A**, Sagittal T2-weighted fast spin-echo image with fat saturation shows infrapatellar plica (black arrow) as linear low-signal-intensity structure in intercondylar notch anterior to anterior cruciate ligament (white arrow).  
**B**, Sagittal T2-weighted fast spin-echo image with fat saturation in lateral slice next to **A** shows cleft of fluid in Hoffa's fat pad (white arrow) in which infrapatellar plica forms roof of cleft (black arrow).  
**C** and **D**, Coronal (**C**) T2-weighted fast spin-echo image with fat saturation and axial (**D**) gradient-recalled echo image show location of infrapatellar plica (white arrows). On axial image, note reflection of infrapatellar plica laterally over Hoffa's fat pad as alar folds (black arrows, **D**).

# Clefts of the Infrapatellar fat pad

- Two clefts are present within the infrapatellar fat pad that may mimic the infrapatellar plica and fill with fluid.
  - Horizontal cleft
  - Vertical cleft

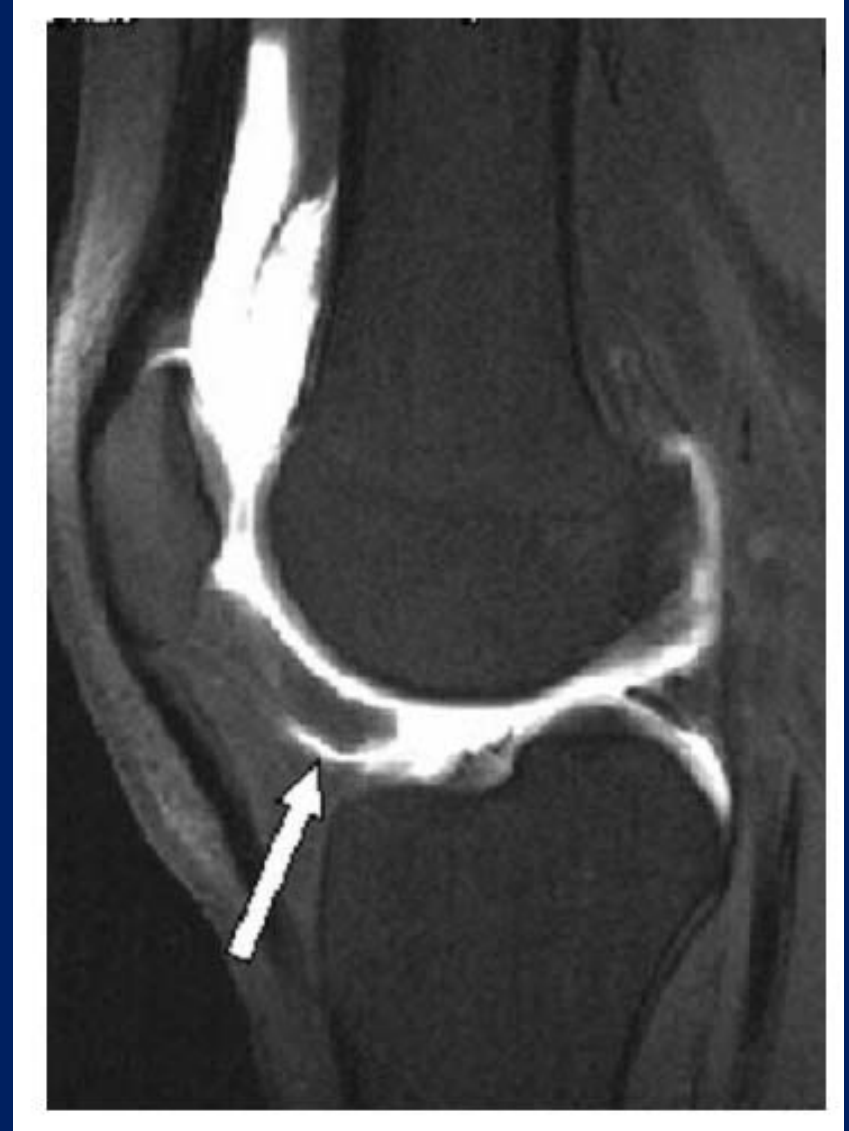# Clefts of the Infrapatellar fat pad

- Arthrogram demonstrating vertical cleft of infrapatellar fat pad



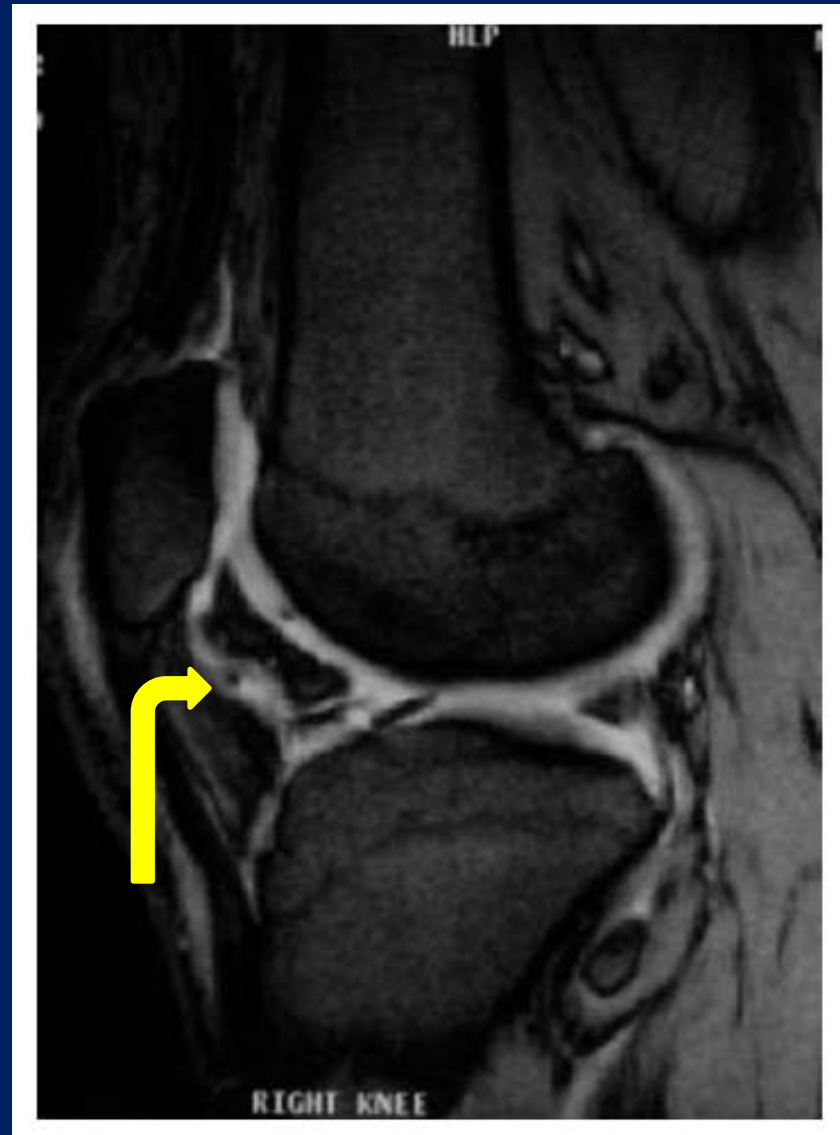
# Clefts of the Infrapatellar fat pad

- Arthrogram demonstrating Horizontal cleft of infrapatellar fat pad



# Clefts of the Infrapatellar fat pad

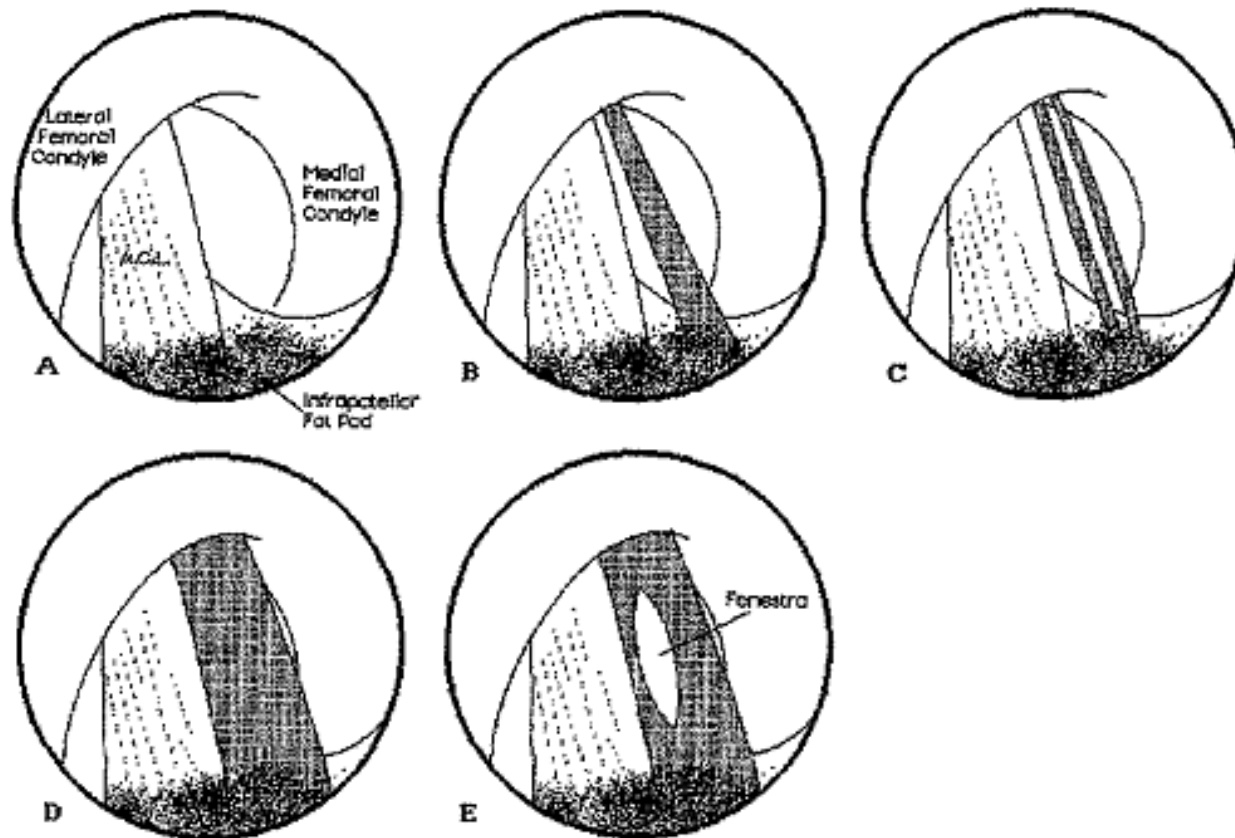
- Arthrogram demonstrating communication of the vertical and horizontal clefts in the infrapatellar fat pad



# Infrapatellar Plica

- Classification System:
  - Kim and Choe Arthroscopic Classification System<sup>9</sup>
    - Absent
      - No synovial fold present between the femoral condyles
    - Separated
      - Complete synovial fold separate from the anterior cruciate ligament
    - Split
      - Synovial fold separate from the anterior cruciate ligament but divided into two or more cords
    - Vertical Septum
      - Complete synovial fold that is attached to the ACL and divides the joint into separate medial and lateral compartments
    - Fenestrated
      - Vertical septum that has a hole/defect

# Infrapatellar Plica



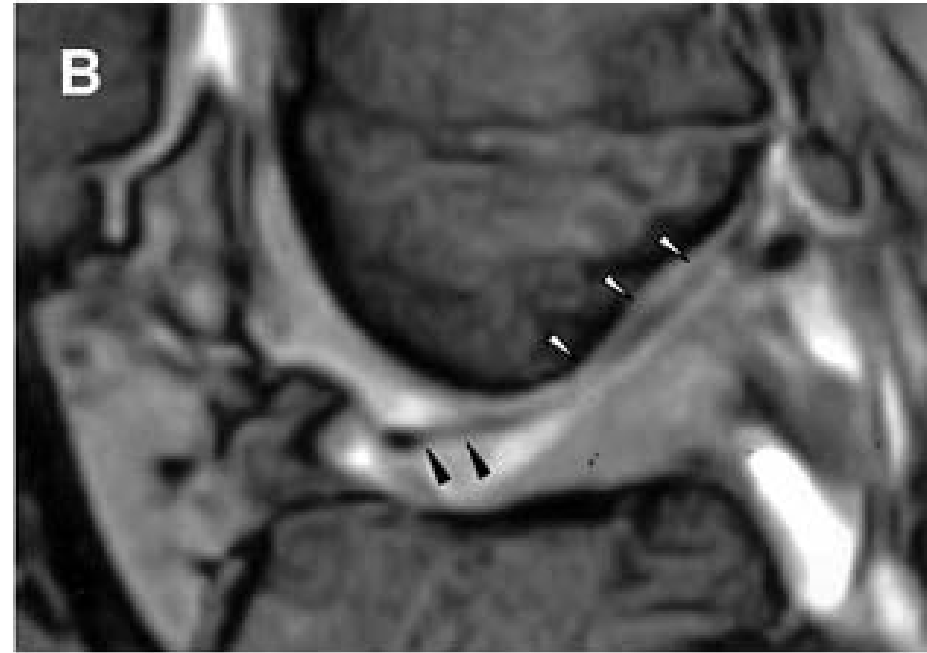
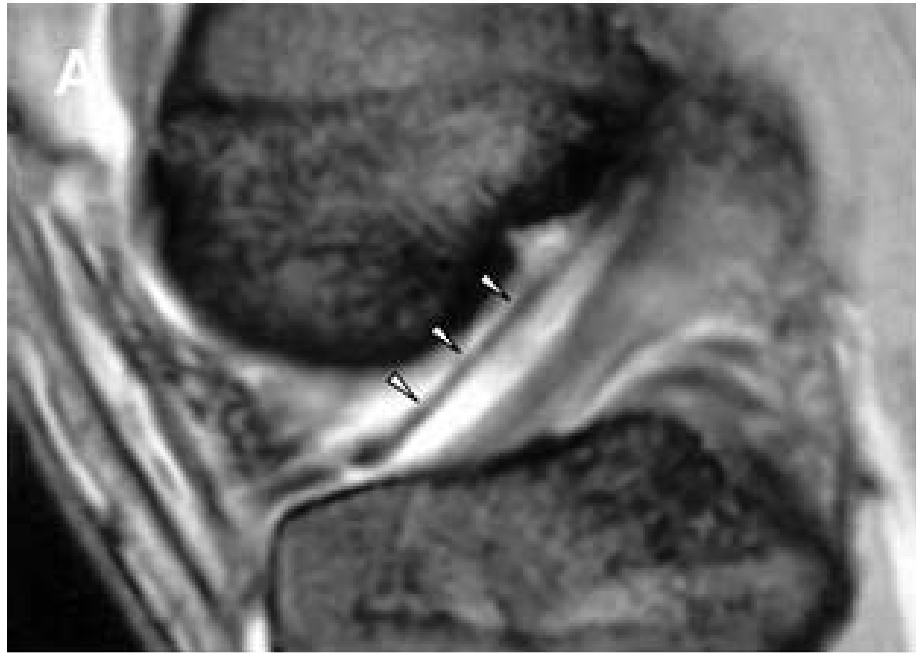
**FIG 9.** Illustrations for patterns of infrapatellar plica in the right knee. (A) absent; (B) separate; (C) split; (D) vertical septum; (E) fenestra. Separate pattern may have one of various thickness such as slender, medium, or thick.

# Anteromedial Meniscomfemoral Ligament

- The **main differential diagnosis of the infrapatellar plica**
  - Can look nearly identical to the infrapatellar plica
- Incidence estimated between 1.2% to 15%<sup>22</sup>
- Proximal attachment<sup>22</sup>:
  - Posterolateral wall of the intercondylar fossa immediately anterior to the ACL
- Distal attachment<sup>22</sup>:
  - Anterior horn of the medial meniscus +/- adjacent tibia
- Unlike the infrapatellar plica, the AMMFL does not curve back upward toward the patella

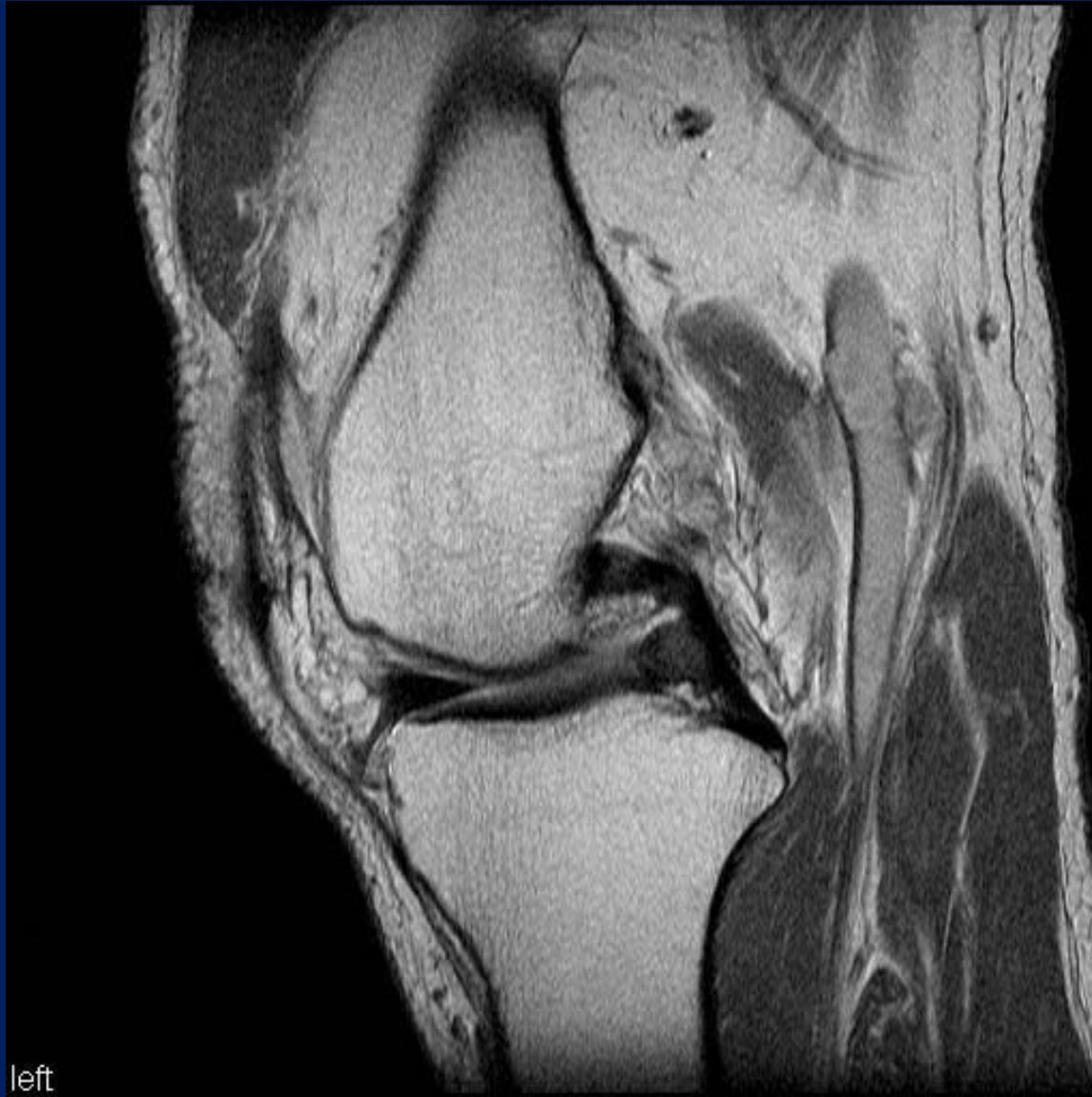

# Anteromedial Meniscomfemoral Ligament



Soejima T, Murakami H, Tanaka N et al: Anteromedial meniscomfemoral ligament. *Arthroscopy* 19: 90-95, 2003.

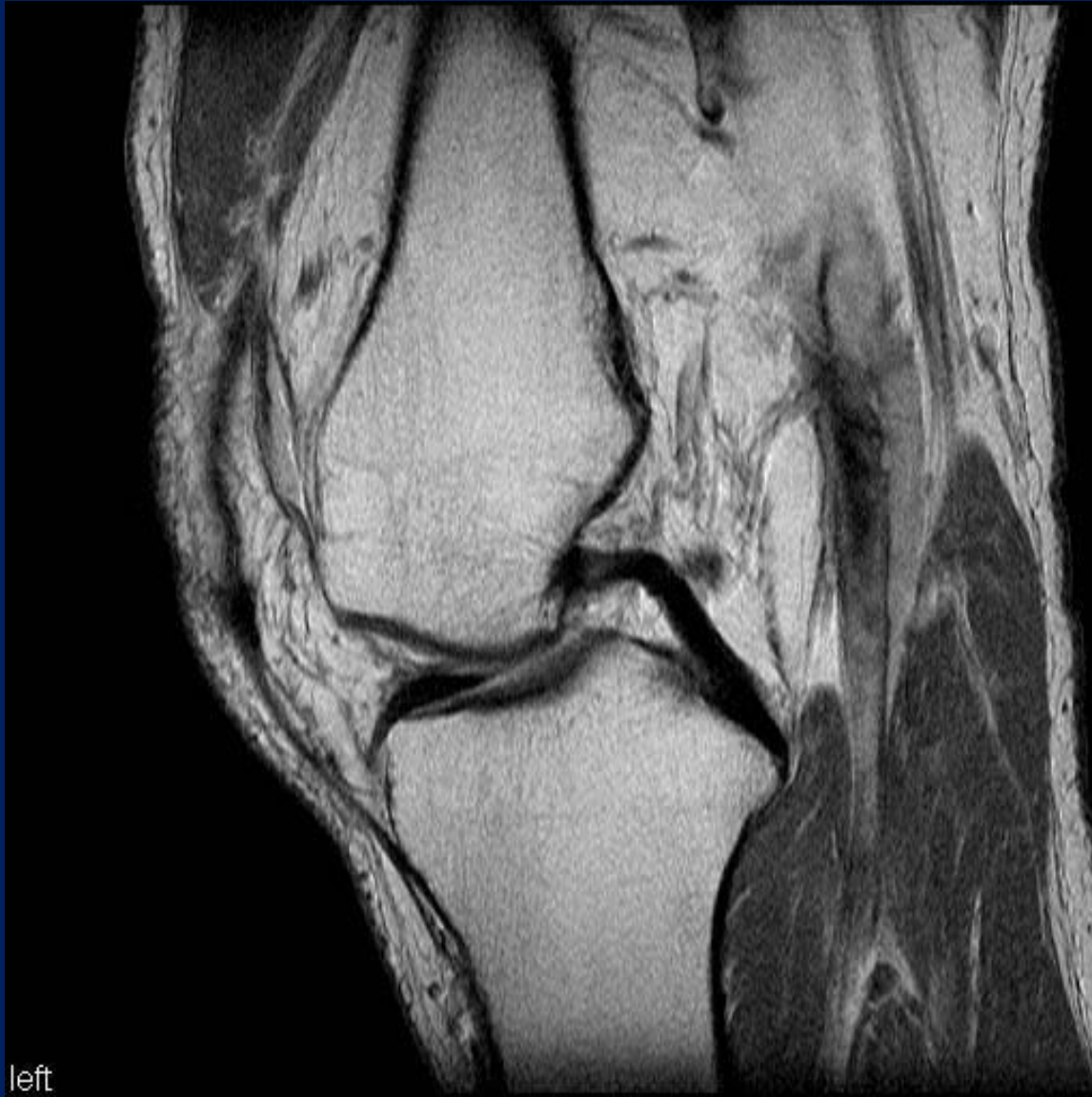# Anteromedial Meniscomfemoral Ligament



left

Images courtesy  
Of Dr. T. Hughes

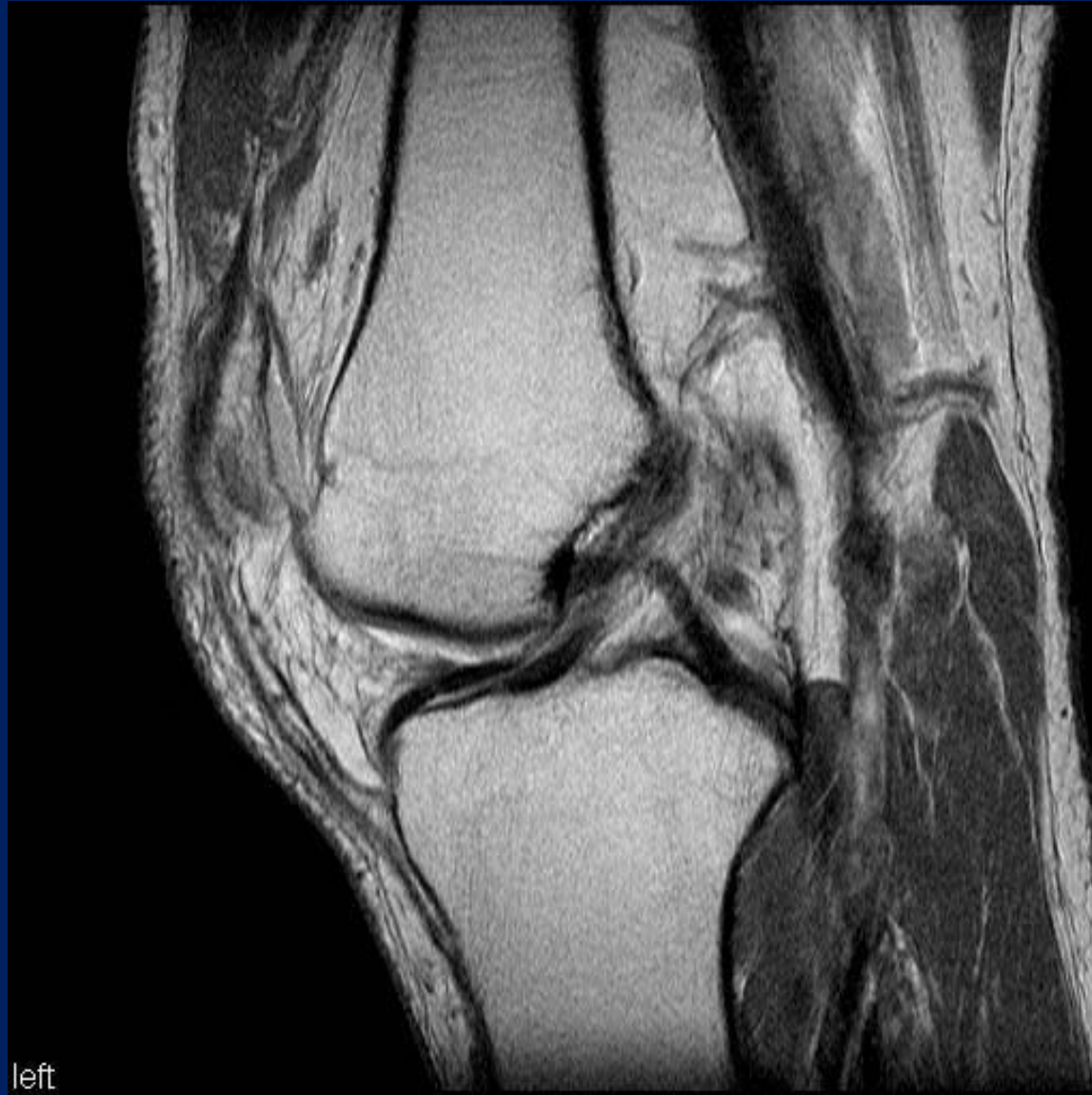# Anteromedial Meniscomfemoral Ligament



left

Images courtesy  
Of Dr. T. Hughes

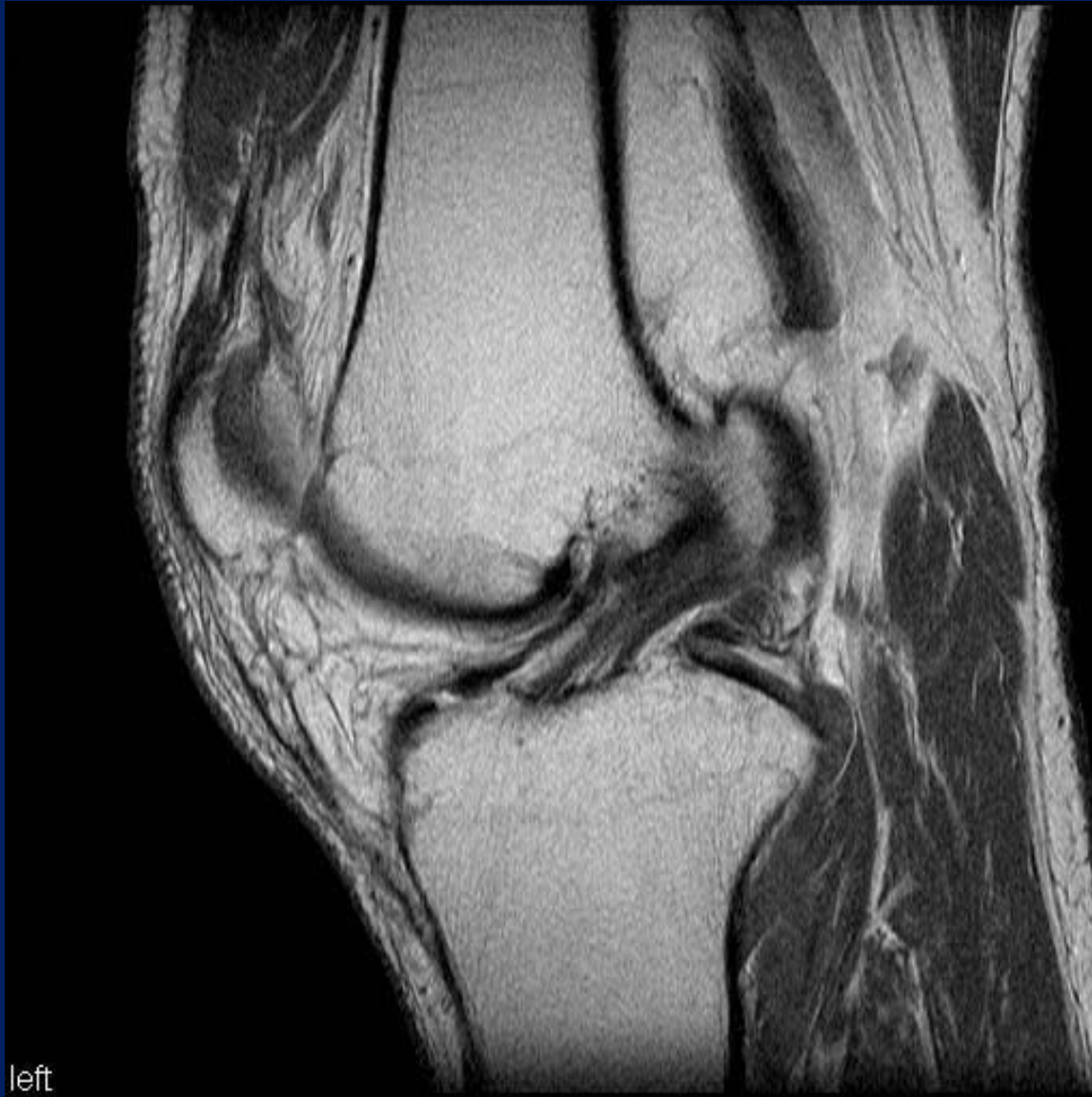
# Anteromedial Meniscomfemoral Ligament



left

Images courtesy  
Of Dr. T. Hughes

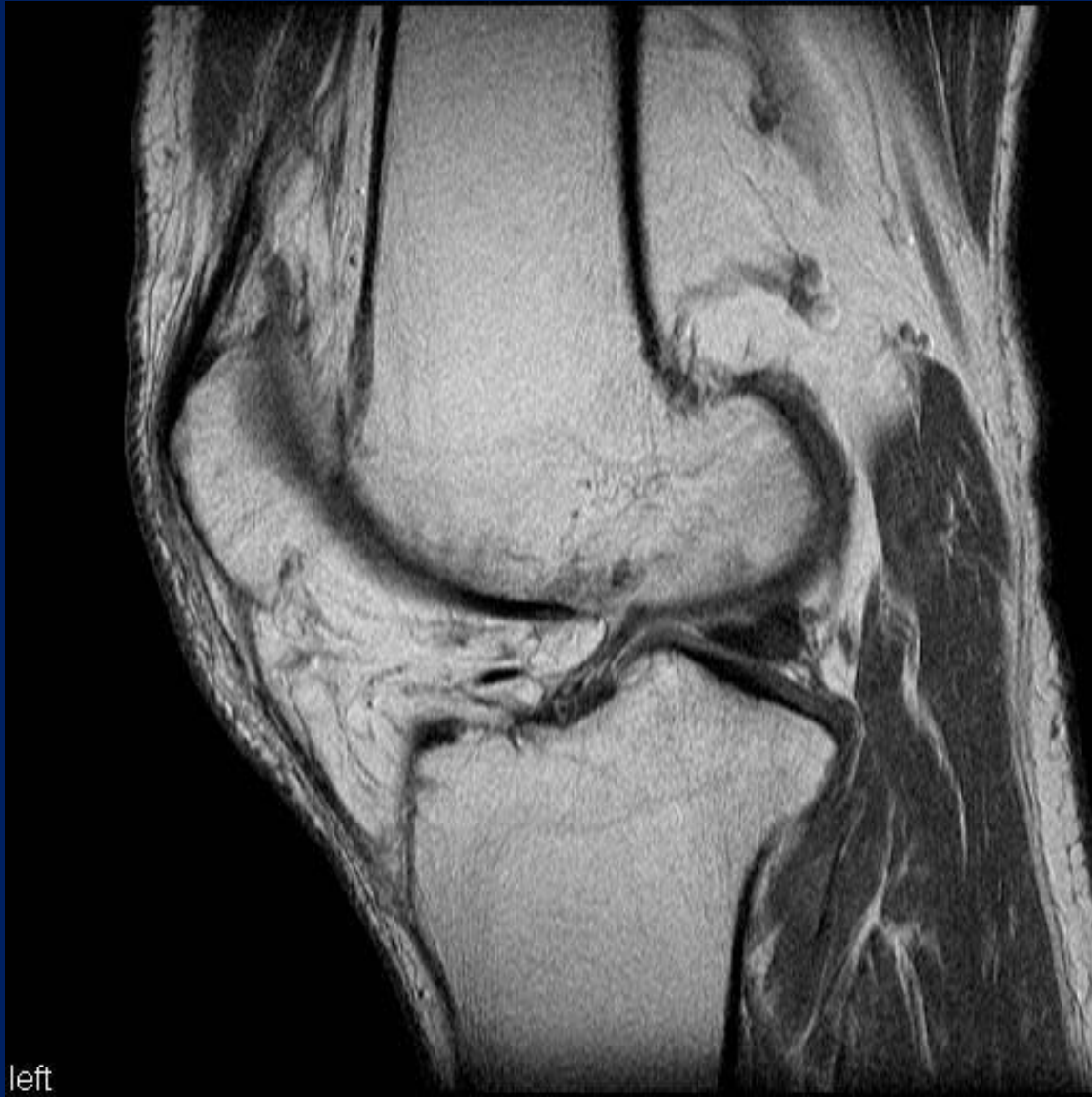
# Anteromedial Meniscomfemoral Ligament



left

Images courtesy  
Of Dr. T. Hughes

# Anteromedial Meniscomfemoral Ligament



left

Images courtesy  
Of Dr. T. Hughes

# Anteromedial Meniscomfemoral Ligament

- Significance of AMMFL is speculated:
  - If there is a tibial attachment:
    - Mobility of meniscus is normal
    - However, AMMFL may cause anterior knee pain by impinging against the femoral condyle
  - If there is no tibial attachment:
    - Abnormal mobility of the anterior horn of the medial meniscus
    - May result in premature rupture or degeneration of the anterior horn of the medial meniscus
    - Abnormal meniscal mobility may result in abnormal hoop stresses that may lead to degeneration of other portions of the medial meniscus as well

Medial patellar plica



# Medial patellar plica

- Synonyms in the literature<sup>2</sup>
  - Medial plica
  - Plica synovialis patellaris/mediopatellaris
  - Shelf, Synovial shelf, Medial shelf
  - Medial intra-articular band
  - lino's band
  - Synovial chorda
  - Medial pleat
  - Intra-articular medial band, ledge, wedge, cleat
  - Alar ligament
  - Plica alaris elongata
  - Semilunar fold
  - Mediopatellar pseudo-meniscus
  - Patellar meniscus
  - AND MORE!!!

# Medial patellar plica

- Anatomy
  - Originates from the medial wall of the knee joint, runs obliquely downward, and attaches to the synovium covering the infrapatellar fat pad
  - Superiorly may attach to the suprapatellar plica
  - Free border may extend over the medial facet of the trochlea or under the medial facet of the patella

# Medial patellar plica

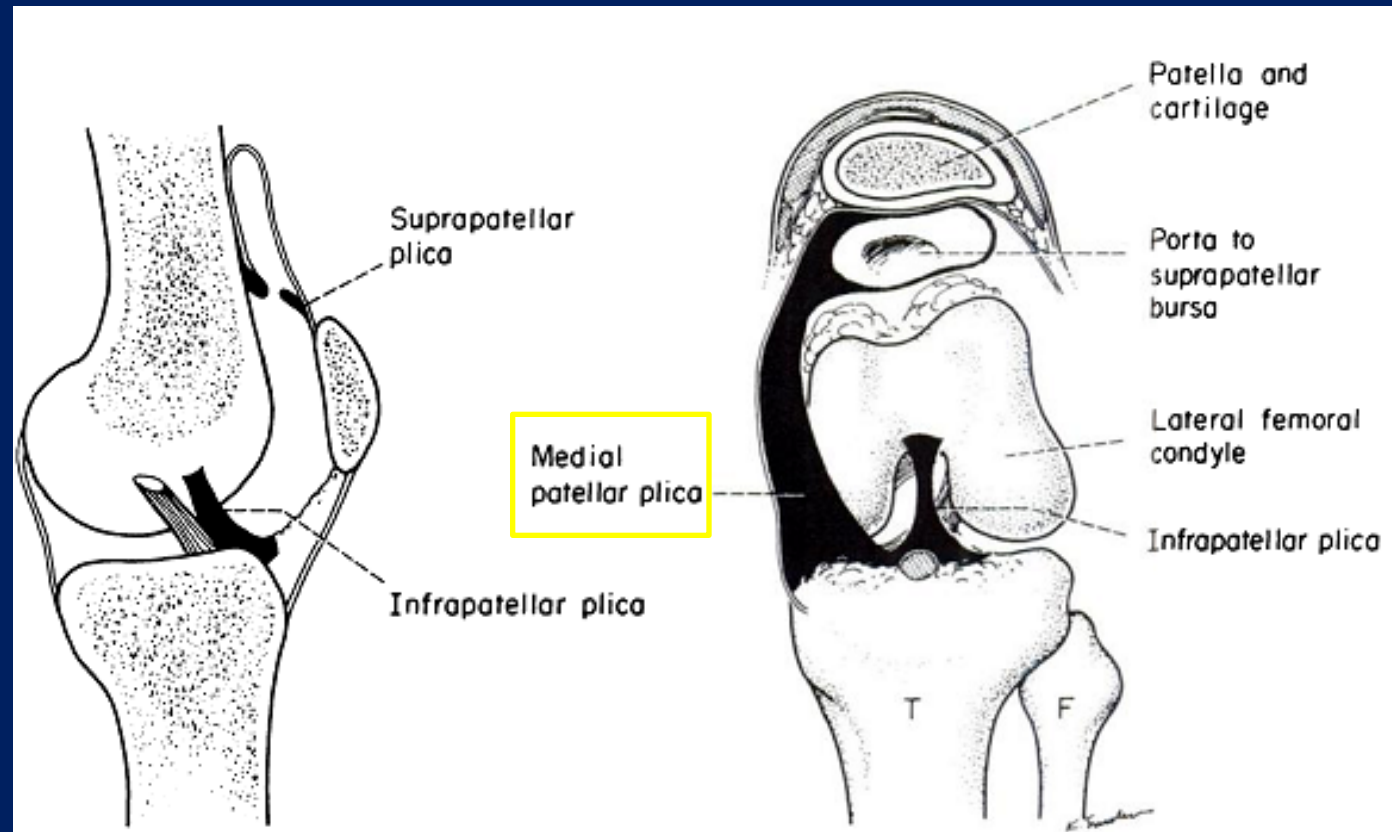
- Incidence:
  - Third most common plica
  - Arthroscopic incidence ranges from 55-72%<sup>5</sup>

# Medial patellar plica

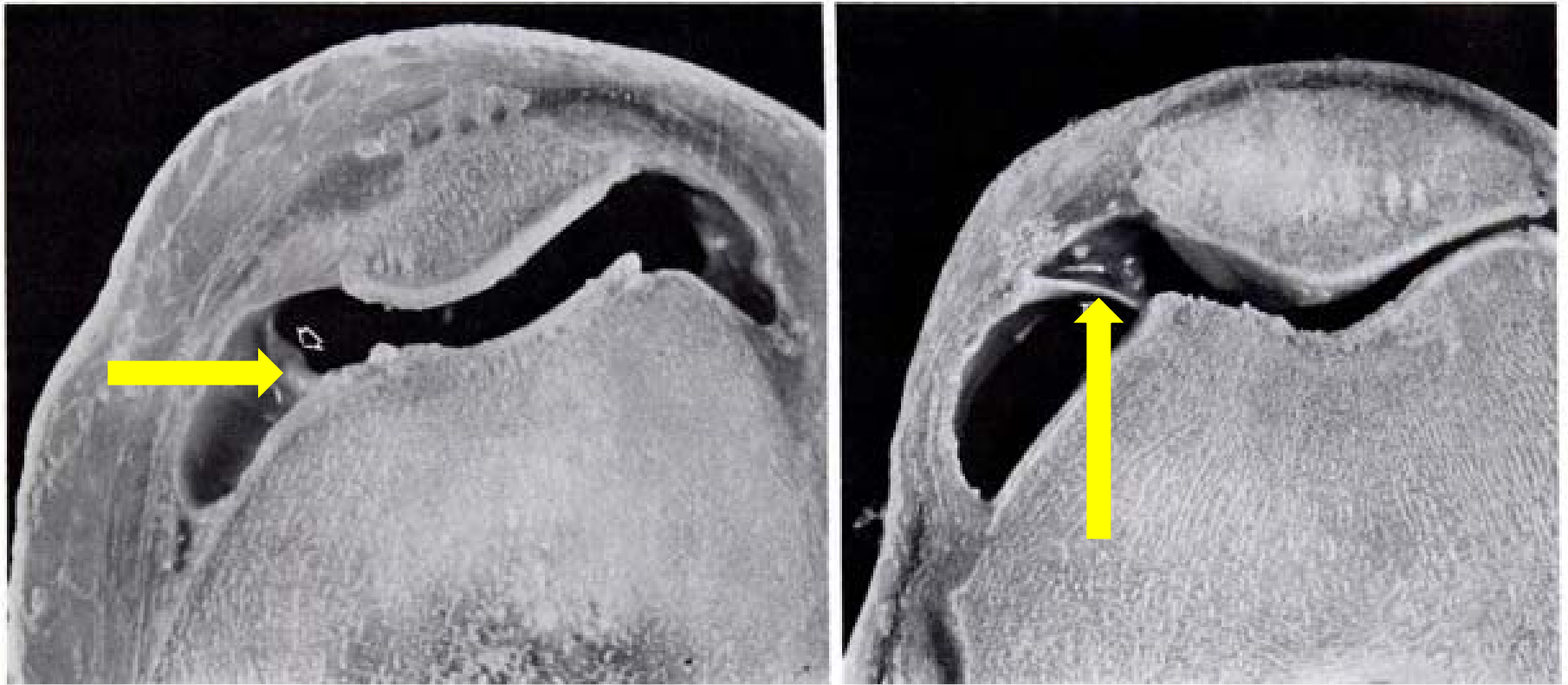
- Five structures present within the medial gutter<sup>11</sup>:
  - Superomedial plica
    - Portion of the suprapatellar plica
    - Transverse orientation and lies well above the patella
  - Alar fold or ligament/Plica Alaris Elongata
    - Longitudinal fold of synovium just medial to the patella
    - Simply folding of the medial retinaculum when relaxed
    - Inconstant, wide, and extremely soft
    - Triangular shape in cross-section
    - Usually not seen on arthroscopy but seen commonly on MR imaging
  - Medial patellar plica
    - Located one fingerbreadth from the patella and alar fold
    - Thinner than alar fold
  - Anteromedial fringe of synovium
    - Covers the anterior horn of the medial meniscus
  - Transverse arcuate folds
    - Folds of synovium located at the bottom of the medial gutter

# Medial patellar plica

- Schematic diagram demonstrating the medial patellar plica

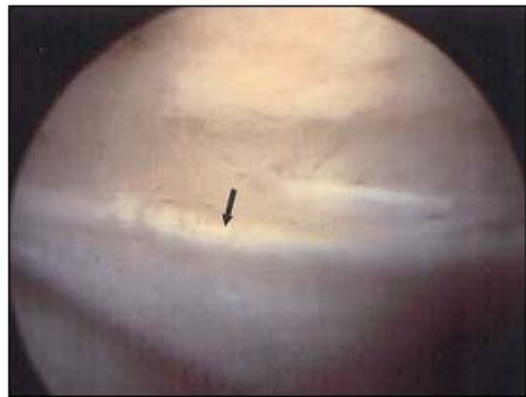

# Medial patellar plica

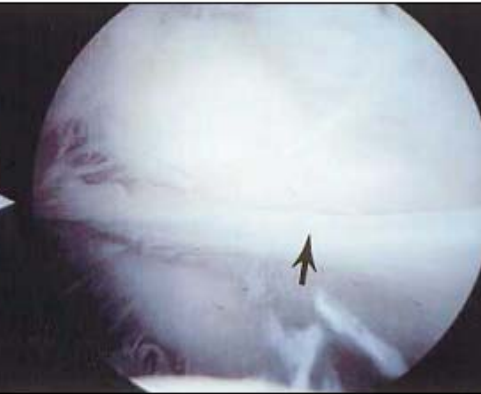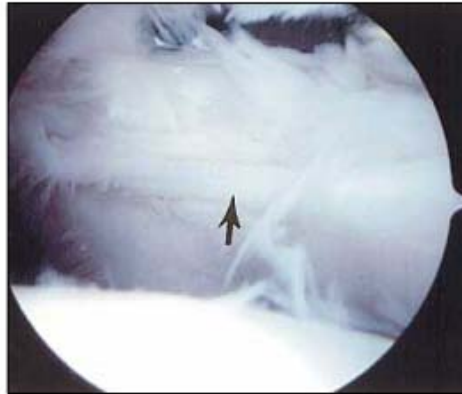


**Fig. 4a and b.** Medial patellar plica. Transverse section through the knee joint at the level of the patella in two different cadavers demonstrates the medial patellar plica (arrow).

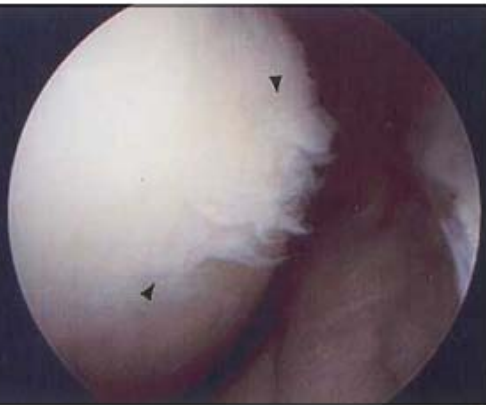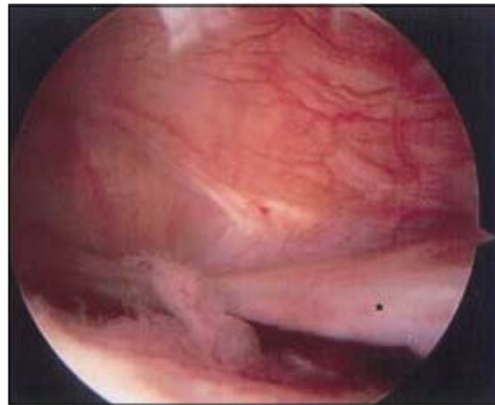# Medial patellar plica



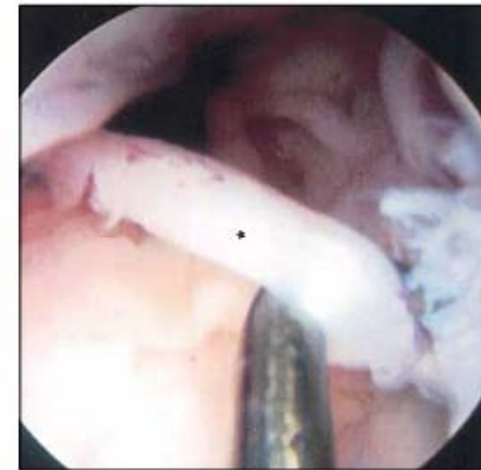
A



B



C



D

Fig. 8.—Arthroscopic images depicting Sakakibara's four types of medial plica.

A, Type A (arrow) is thin elevation of synovium under medial retinaculum. Patient is 40-year-old man with chondromalacia.

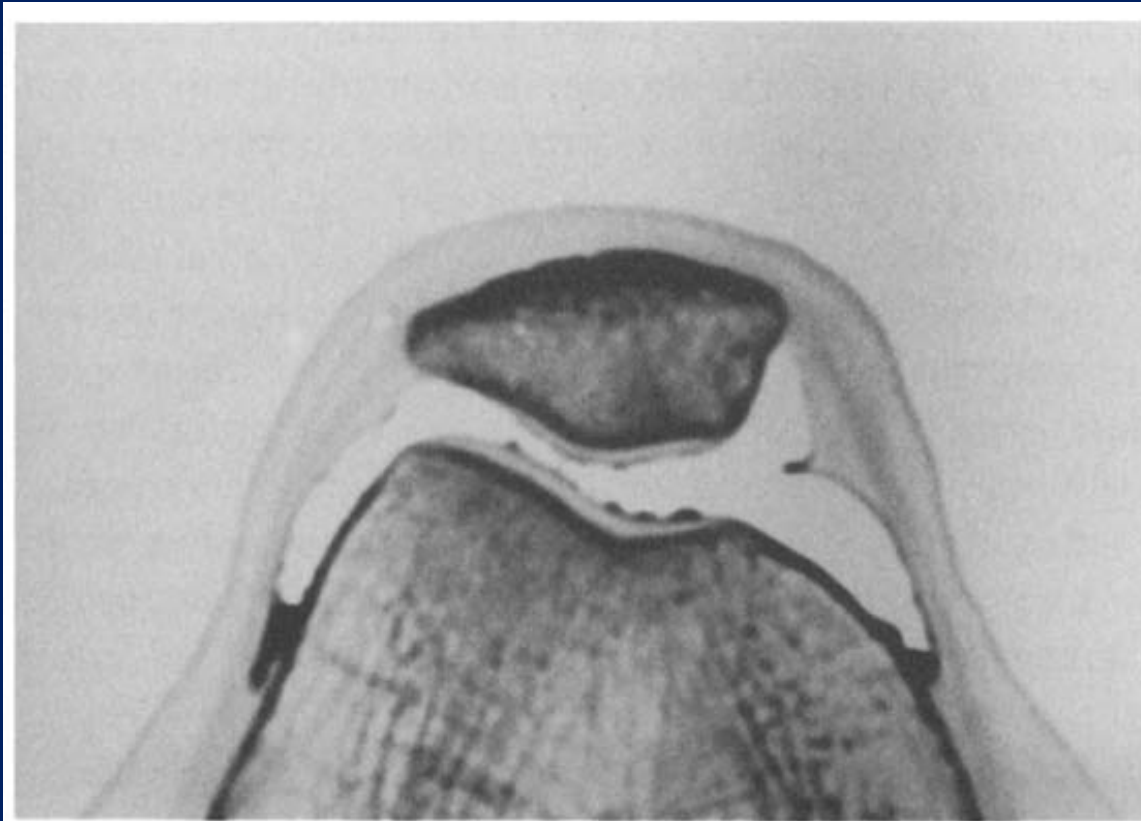
B, 69-year-old man with osteoarthritis. Type B is narrow pleat (arrows) that does not impinge on medial condyle. Uninflamed ridge is seen amid synovial hypertrophy in patient with osteoarthritis.

C, 58-year-old man with medial meniscus tear. Type C is larger structure (asterisk) that partially covers medial femoral condyle. Note inflammation of plica and frayed cartilage of adjacent medial femoral condyle (arrowheads).

D, Type D is fenestrated type C or bandlike plica (asterisk). Note generalized synovial hypertrophy. Data about patient were not recorded.

# Medial patellar plica

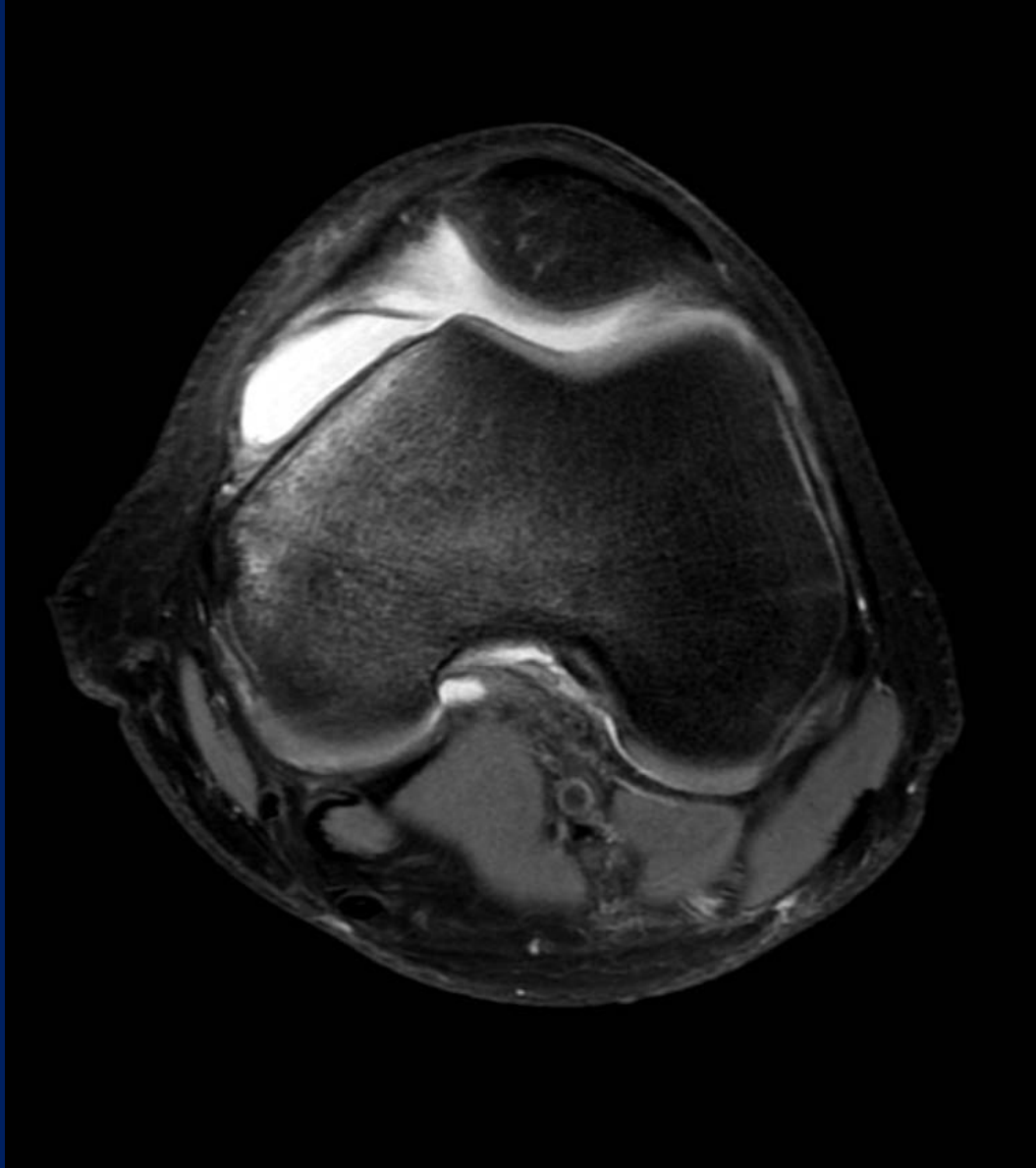
- Double contrast CT-arthrogram demonstrating medial patellar plica



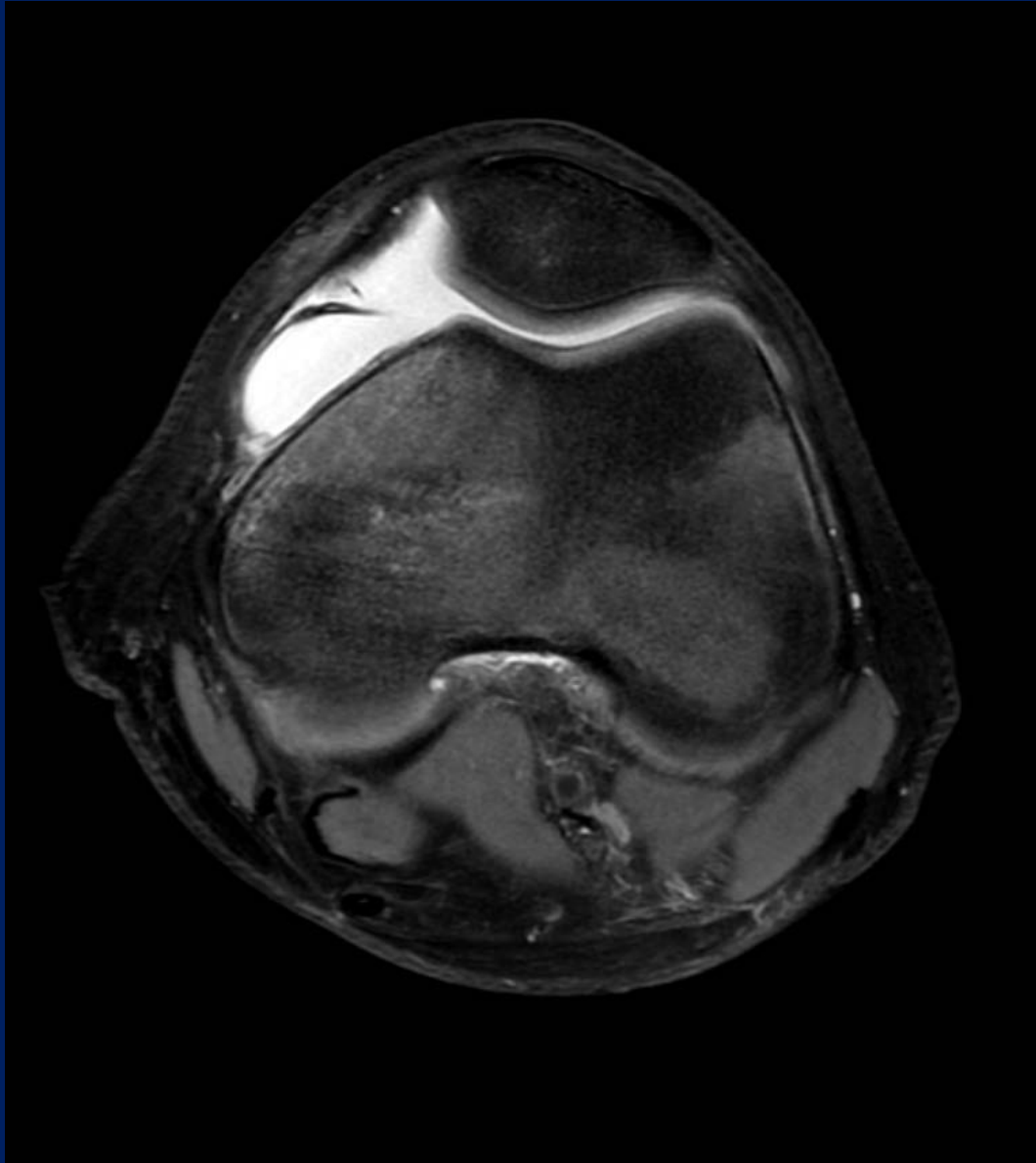
**Figure 6.** CT scan with double-contrast arthrogram: presence of a narrow medial plica (right knee).



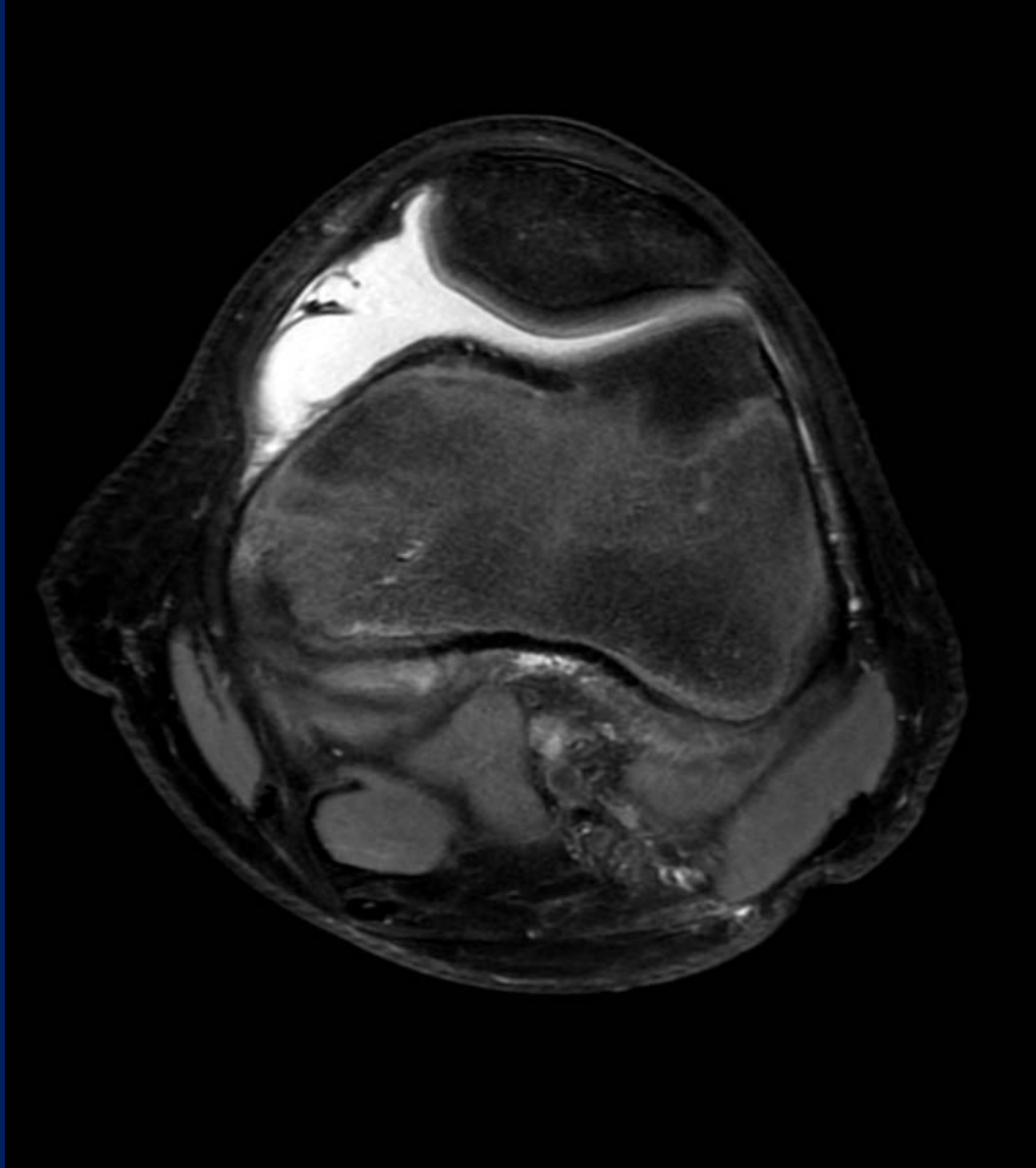
# Medial patellar plica



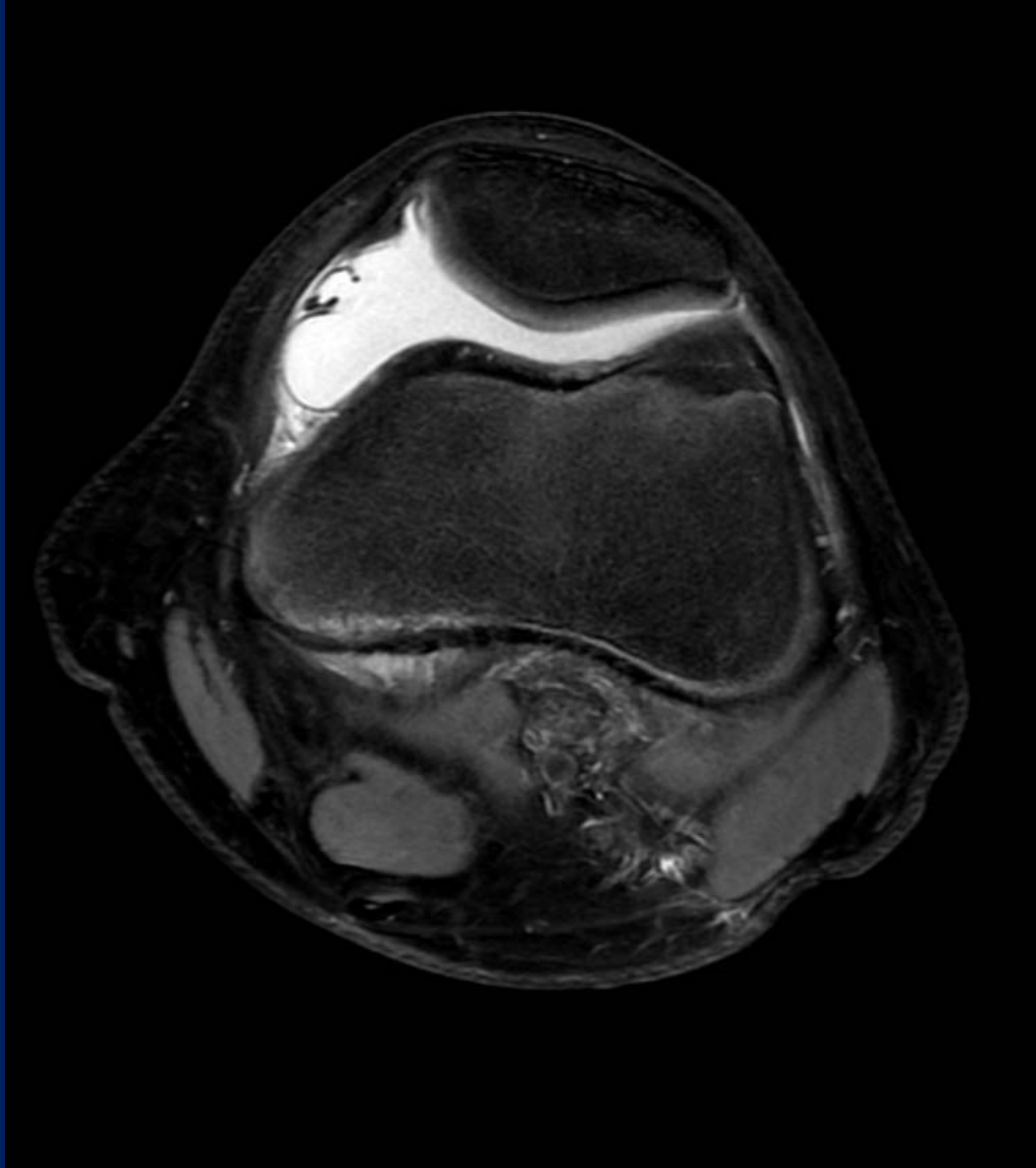
# Medial patellar plica



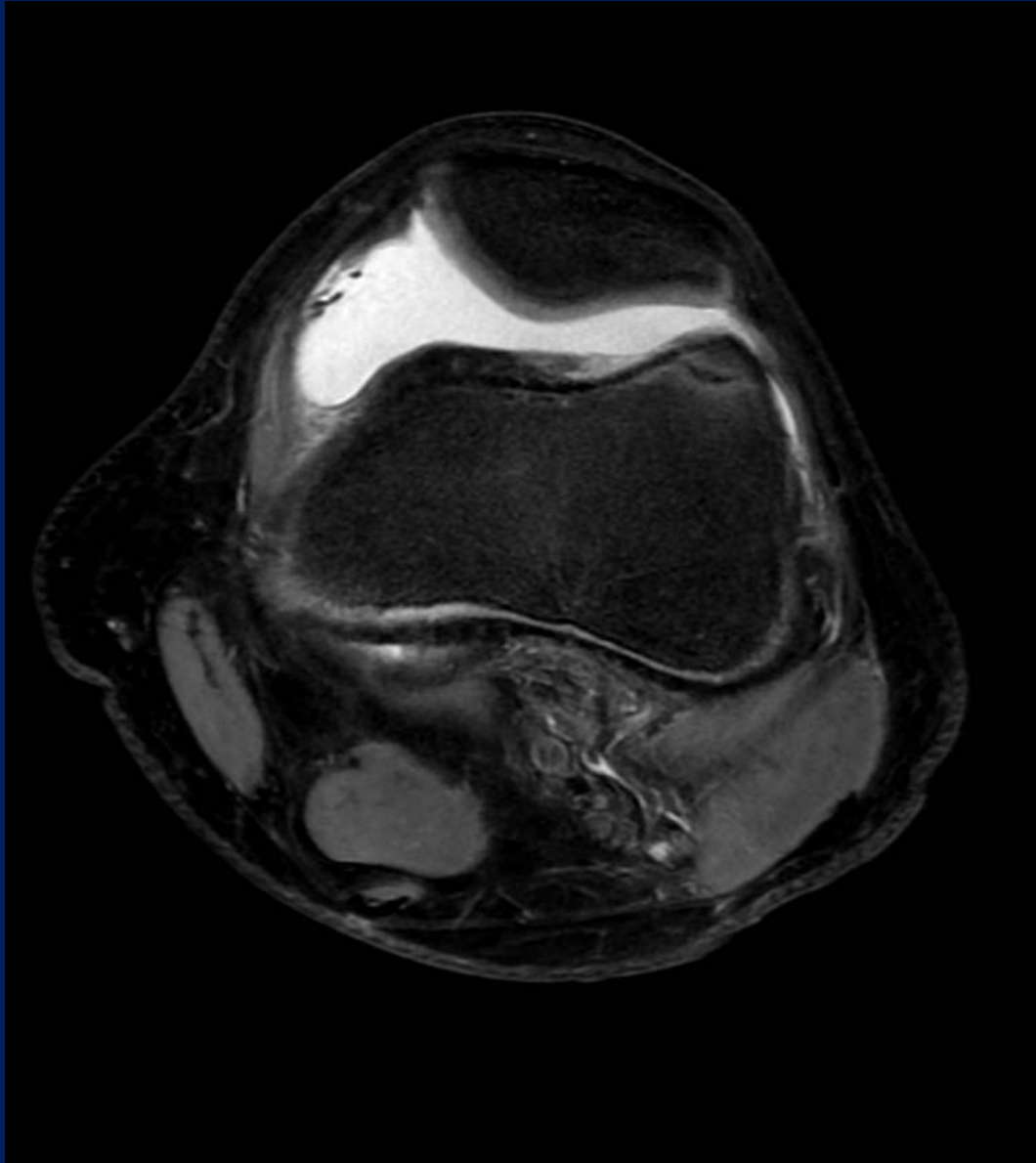
# Medial patellar plica



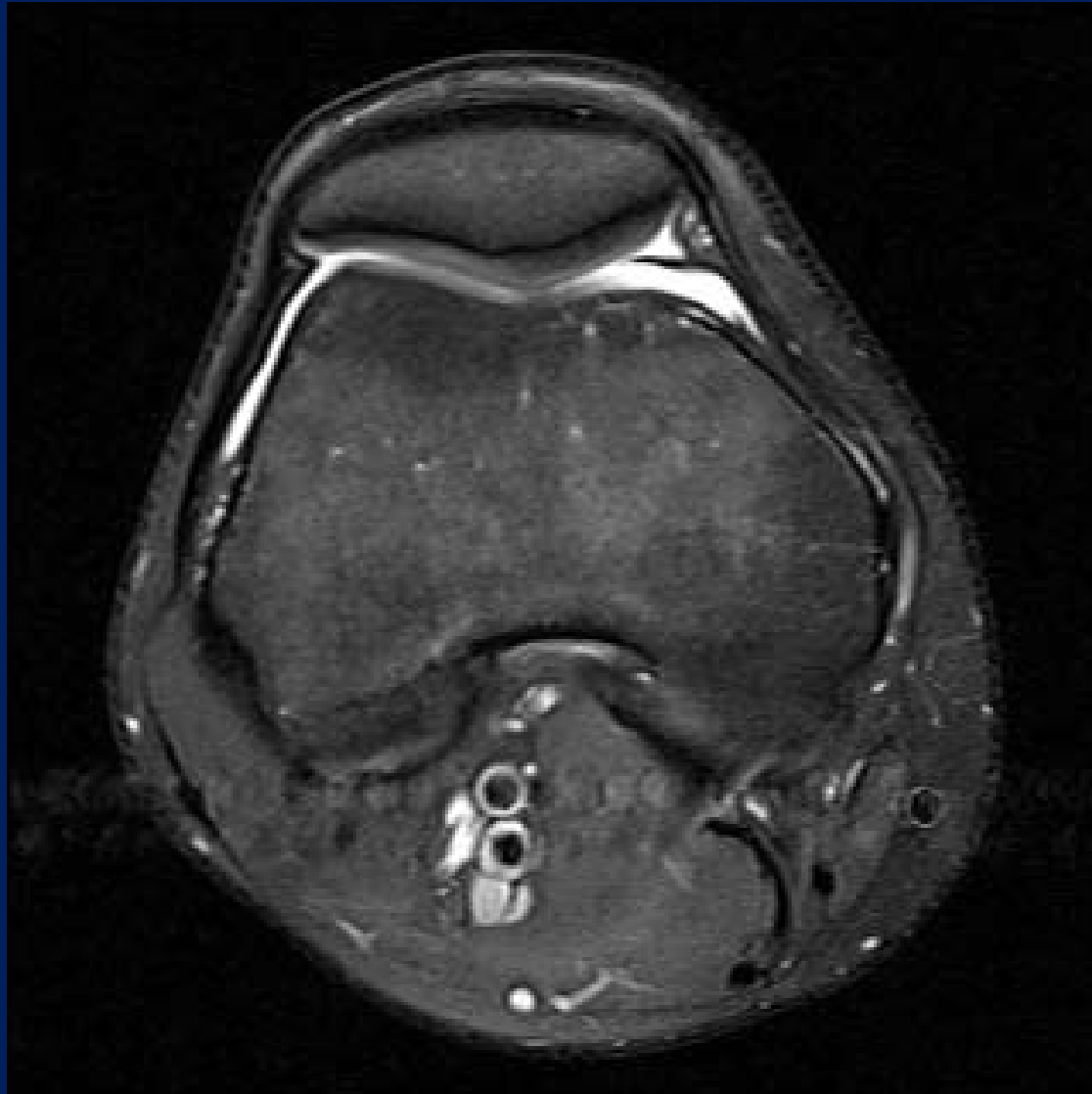
# Medial patellar plica



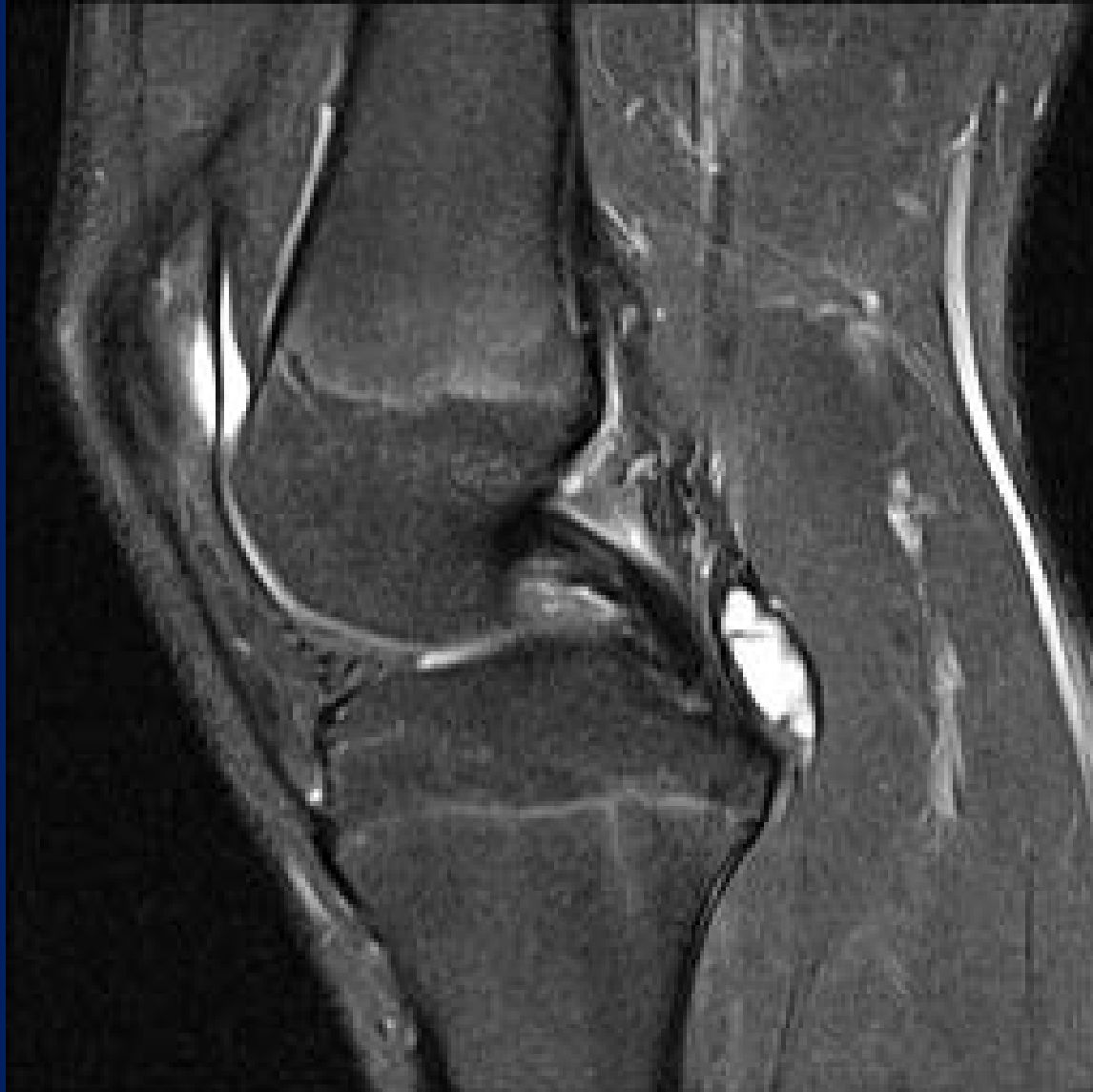# Medial patellar plica



# Medial patellar plica



# Medial patellar plica

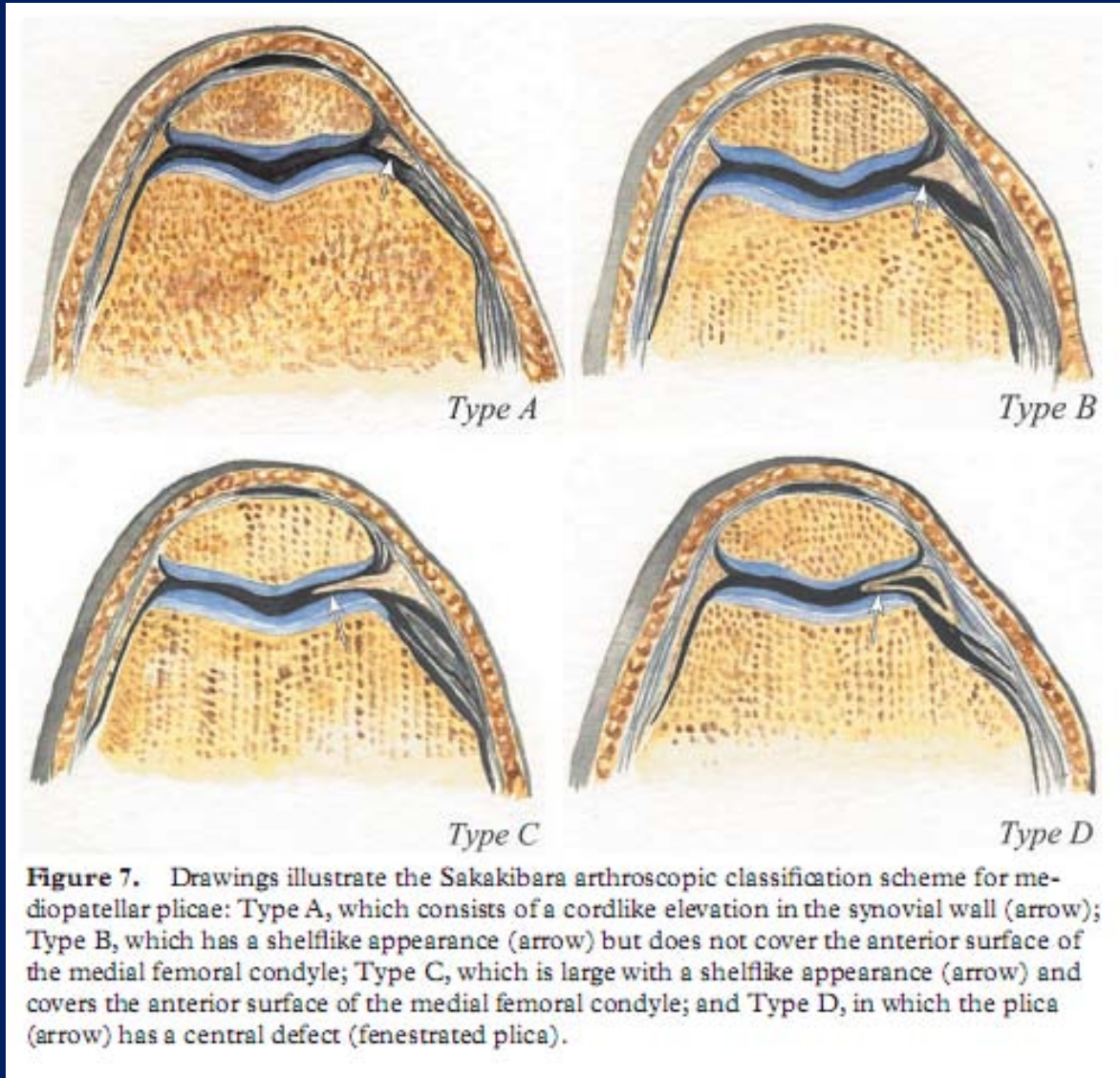


# Medial patellar plica

- Classification System:
  - Sakakibara arthroscopic classification scheme<sup>1</sup>
    - Type A
      - Cord-like elevation of the synovial wall
    - Type B
      - Shelf-like elevation of the synovial wall but does not cover the medial femoral condyle
    - Type C
      - Large and shelf-like elevation that covers the medial femoral condyle
    - Type D
      - Plica with central defect (fenestrated plica)

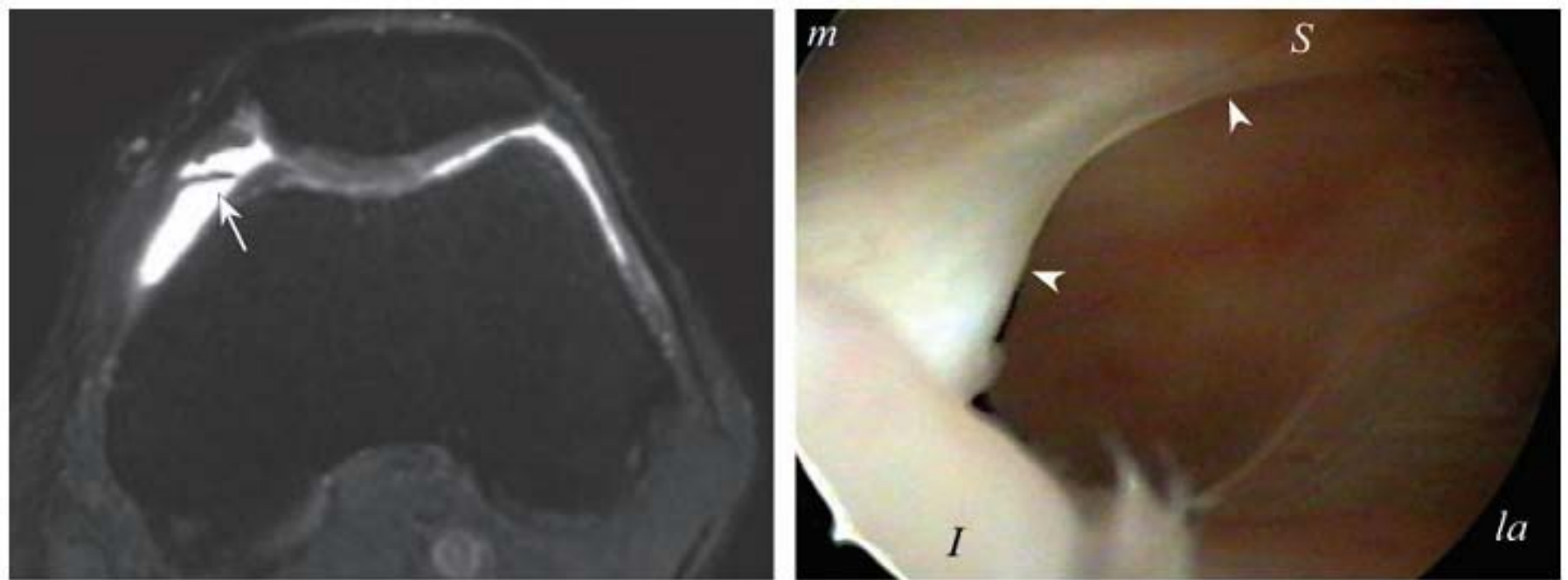


# Medial patellar plica



# Medial patellar plica

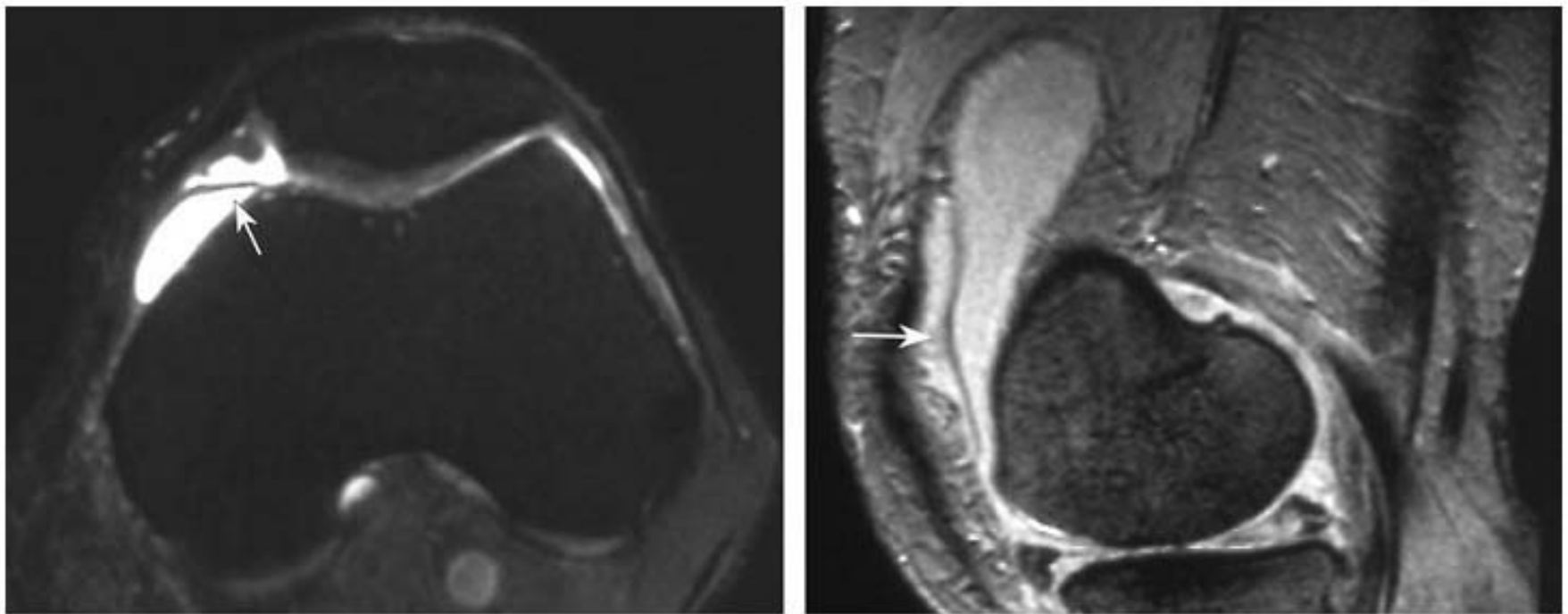
- MRI of Sakakibara Type A



**a.** **b.**  
**Figure 8.** Asymptomatic medial plica (Sakakibara type A). **(a)** Axial fat-saturated spin-echo proton density-weighted MR image of the knee (3,000/50) demonstrates a cordlike elevation in the medial synovial wall (arrow). **(b)** Arthroscopic image shows a thin band (mediopatellar plica) in the medial wall of the knee (arrowheads). *I* = inferior, *la* = lateral, *m* = medial, *S* = superior.

# Medial patellar plica

- MRI of Sakakibara Type B



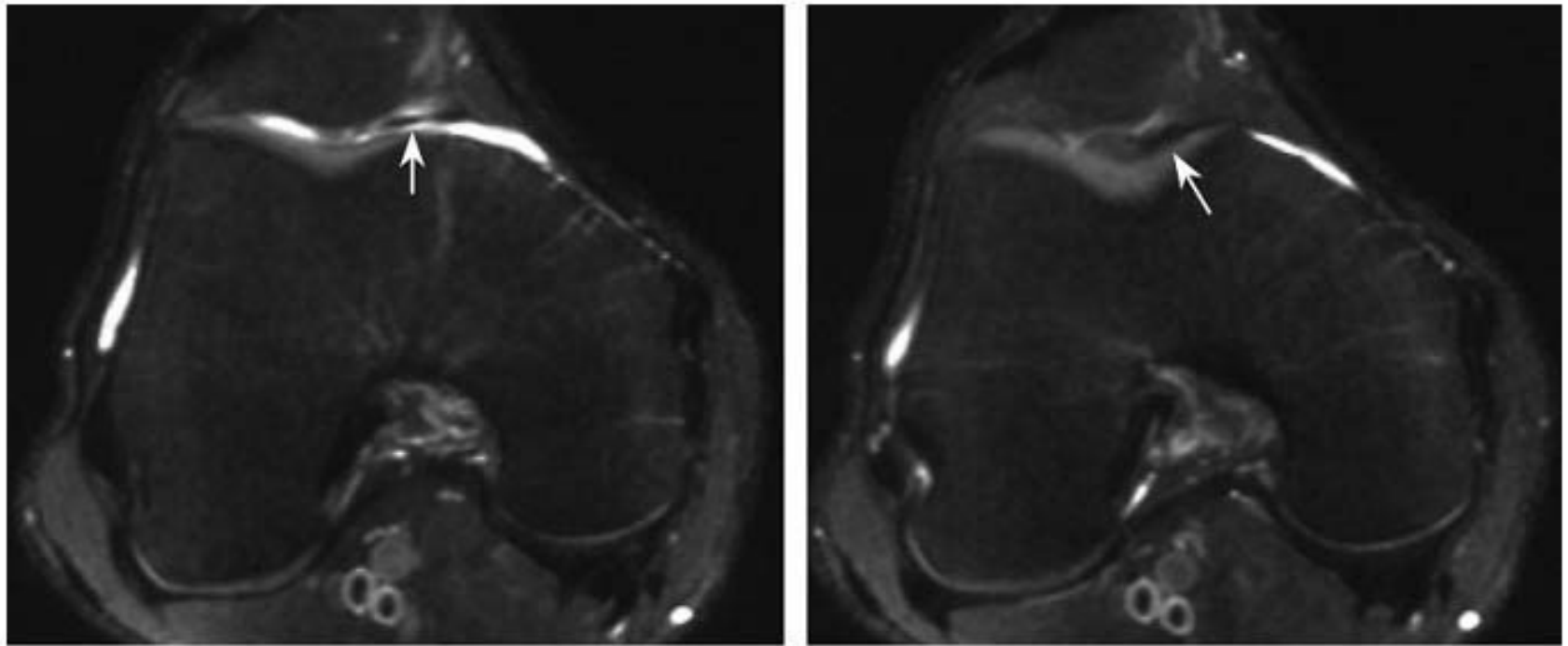
**a.**

**b.**

**Figure 9.** Medial plica (Sakakibara type B). Axial fat-saturated spin-echo proton density-weighted (3,000/50) (a) and sagittal three-dimensional gradient-echo (523/20, 35° flip angle) (b) MR images demonstrate a thin, hypointense line (arrow) that originates at the medial wall of the knee joint.

# Medial patellar plica

- MRI of Sakakibara Type C



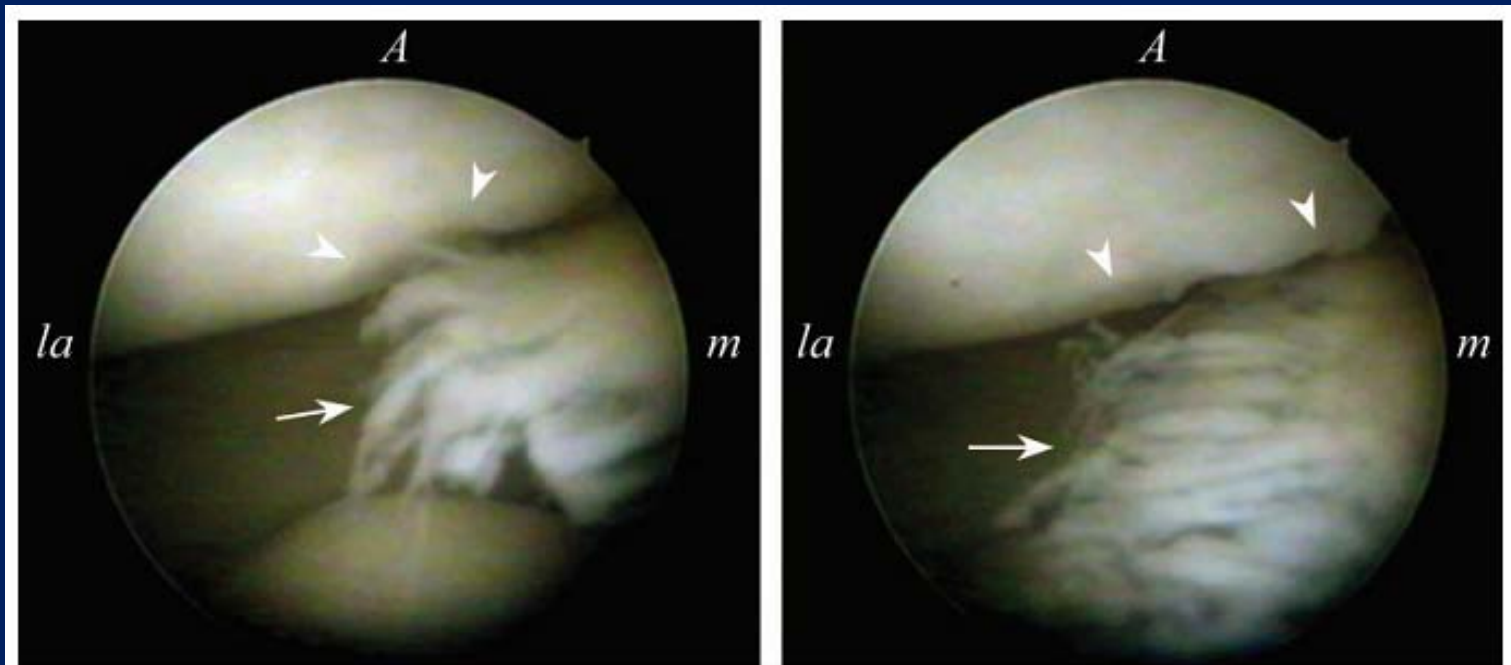
a.

b.

**Figure 10.** Symptomatic medial plica (Sakakibara type C) in a professional bicyclist. Axial fat-saturated spin-echo proton density-weighted MR images (3,000/50) obtained at different levels demonstrate a hypointense band (arrow) that covers the anterior surface of the medial femoral condyle.

# Medial patellar plica

- Arthroscopy of Sakakibara Type C with patellar erosive changes



a.

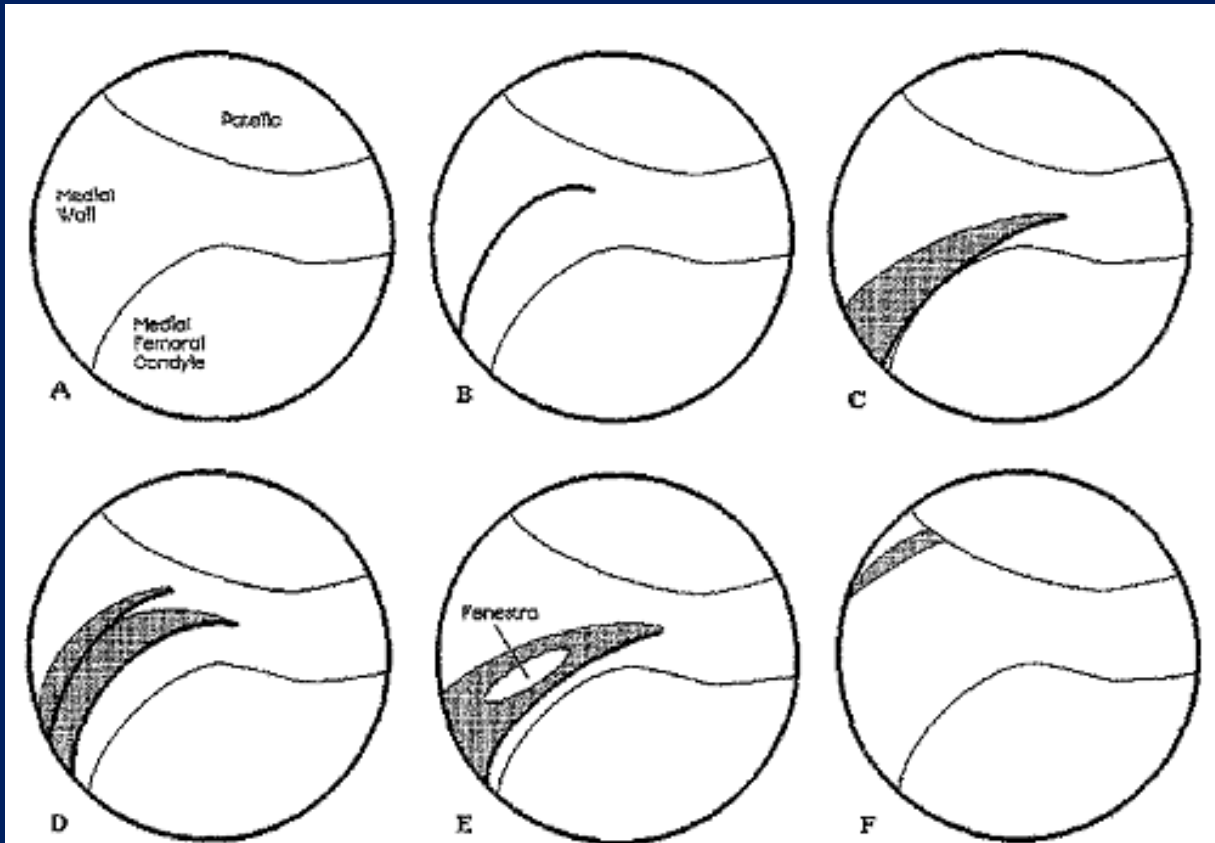
b.

**Figure 11.** Symptomatic mediopatellar plica (Sakakibara type C). Arthroscopic images demonstrate a mediopatellar plica (arrow) with patellar erosive changes (arrowheads). *A* = anterior, *la* = lateral, *m* = medial.

# Medial patellar plica

- Kim and Choe Arthroscopic Classification System<sup>9</sup>:
  - Absent
    - No synovial shelf on the medial wall
  - Vestigial
    - Less than 1 mm of synovial elevation that disappears with external pressure
  - Shelf
    - A complete fold with sharp free margin
  - Reduplicated
    - Two or more shelves running parallel to the knee. They may be differing sizes.
  - Fenestra
    - The shelf contains a central defect
  - High-riding
    - A shelf-like structure running anterior to the posterior part of the patella, in a position where it could not touch the femur

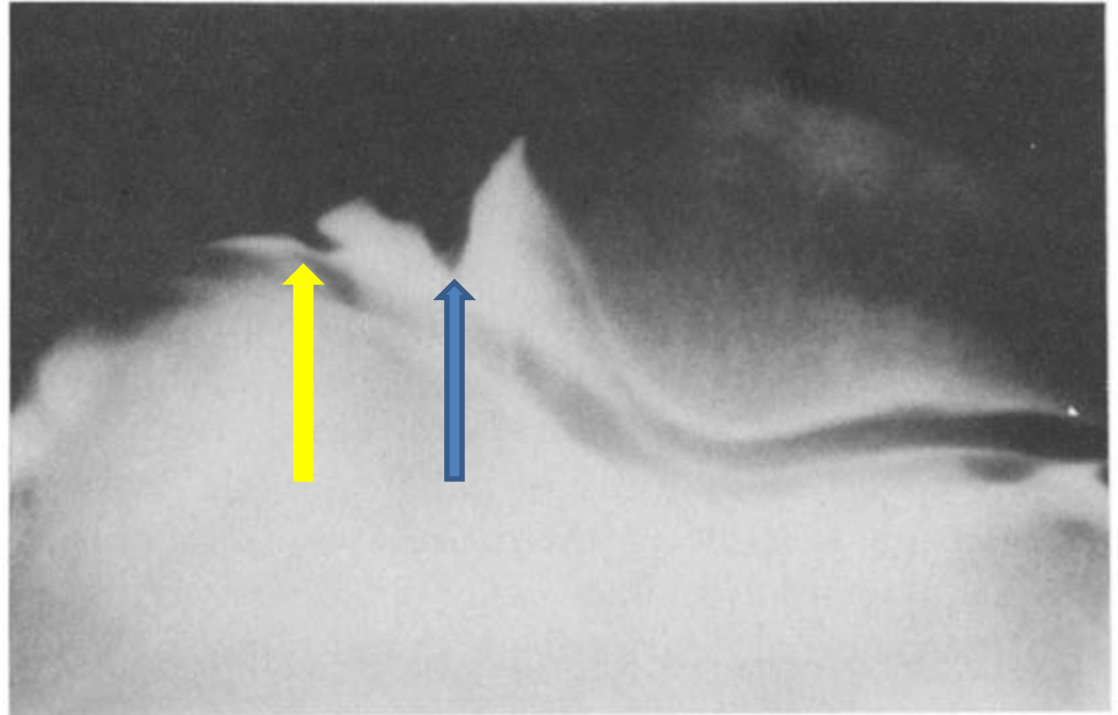
# Medial patellar plica



**FIG 5.** Illustrations for patterns of mediopatellar plica in the right knee. (A) absent; (B) vestigial; (C) shelf; (D) reduplicated; (E) fenestra; (F) high-riding. Each pattern may have one of various width such as narrow non-touch, medium touch, and wide covering.

# Medial patellar plica

- Arthrogram demonstrating both the alar fold (blue arrow) and medial patellar plica (yellow arrow)

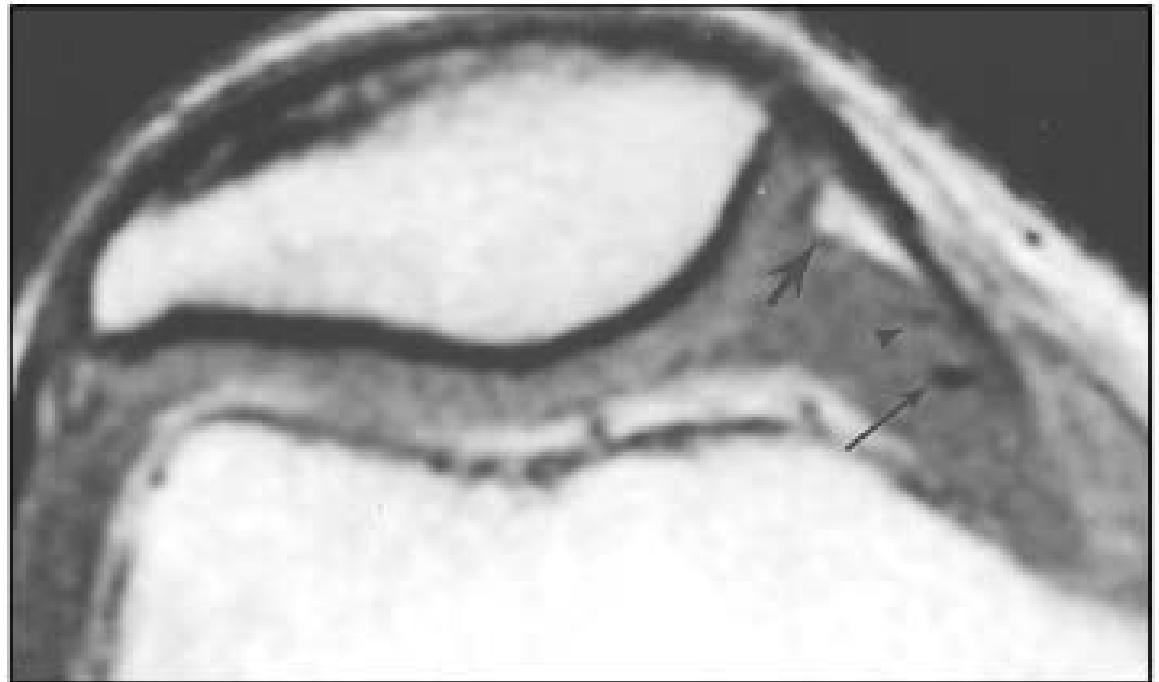


**Figure 3.** Knee arthrography, skyline view: medial plica with Morris' alar fold. The plica is more medial and thinner than the alar fold which is triangular. Its width would classify it as Type B (right knee).

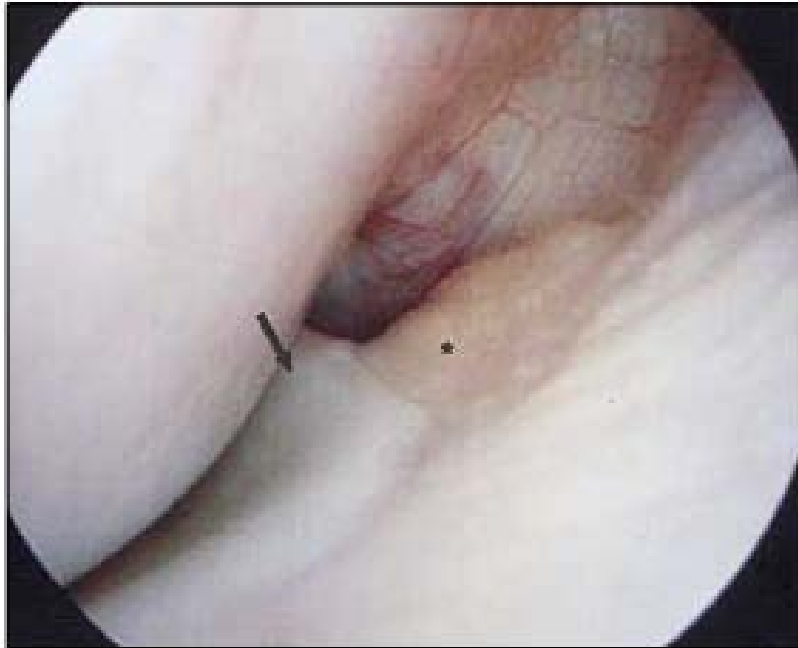

# Medial patellar plica

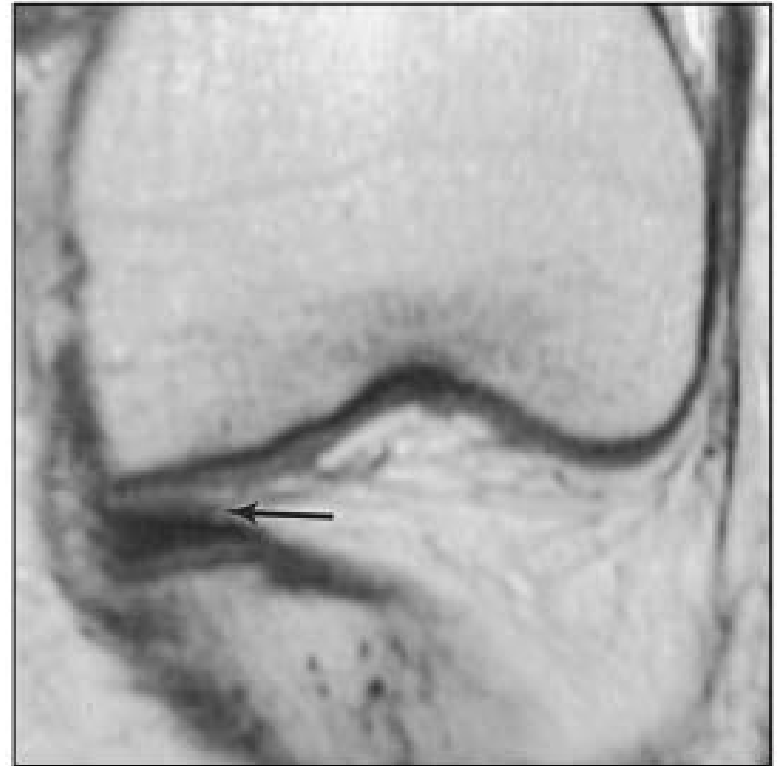Fig. 9.—39-year-old man. Relatively T1-weighted MR image (TR/TE, 1000/16) reveals alar fold (*thick arrow*) anterior to medial plica (*thin arrow*). Alar fold may not be seen at arthroscopy but is usually found on axial MR images. Thin minor synovial fold is noted just anterior to medial plica (*arrowhead*). Alar fold may also be found lateral to patella, which is typically closer to patella than is medial fold.



# Medial patellar plica



C



D

C, Arthroscopic image of small anteromedial fringe (*asterisk*) that abuts medial meniscus (*arrow*).  
D, Coronal T1-weighted MR image (TR/TE, 433/15) reveals soft tissue between medial meniscus and cartilage of medial femoral condyle (*arrow*).

Lateral patellar plica

# Lateral patellar plica

- Anatomy:
  - The equivalent of the medial patellar plica except on the lateral side (mirror image of the medial plica)<sup>2</sup>
  - Longitudinal, very thin, and located 1-2 cm lateral to the patella<sup>2</sup>

# Lateral patellar plica

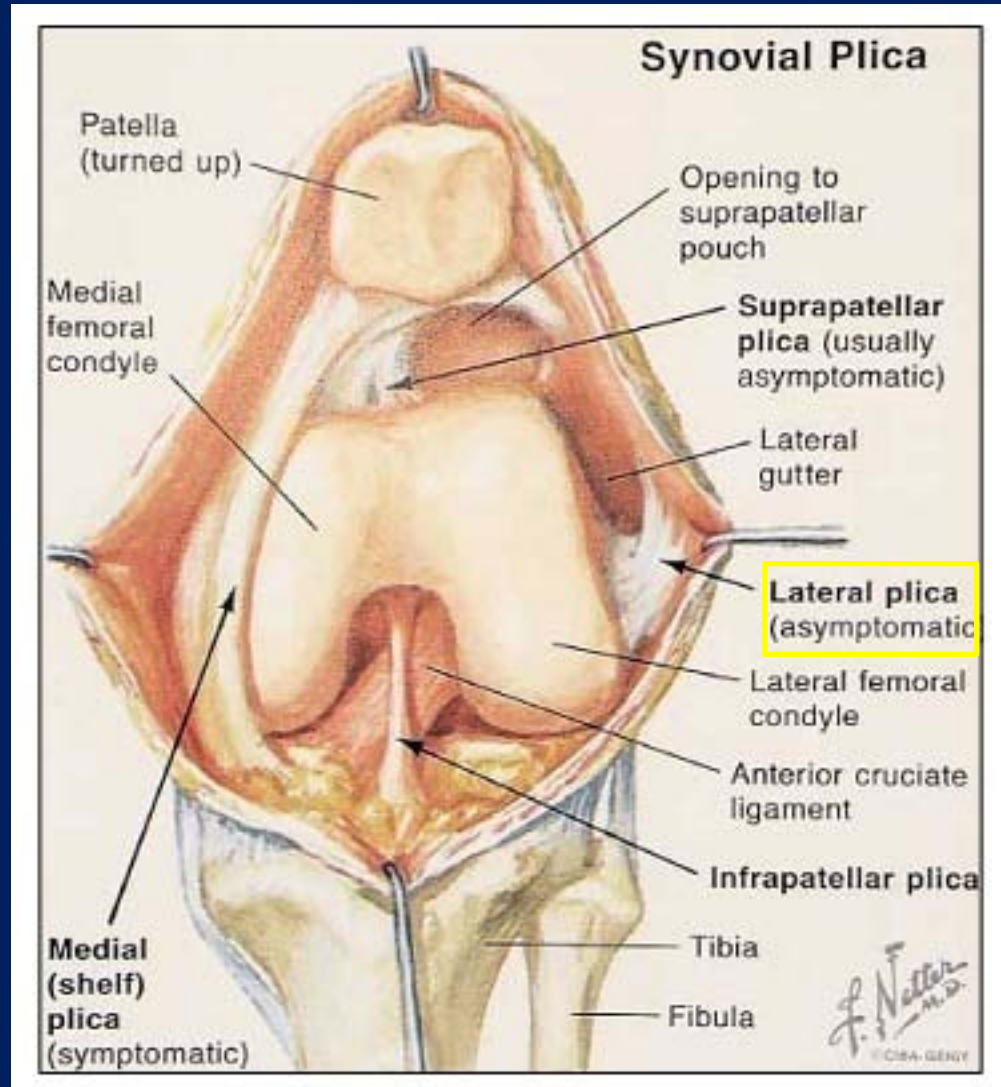
- Incidence:
  - By far the rarest plica
  - Arthroscopic studies indicate an incidence of 0.7 – 1.0%<sup>2,5</sup>
    - Commonly used arthroscopic approaches may miss this plica so the incidence may be underestimated (requires medial approach)
  - Ogata and Uthoff noted one in a 9-week embryo

# Lateral patellar plica

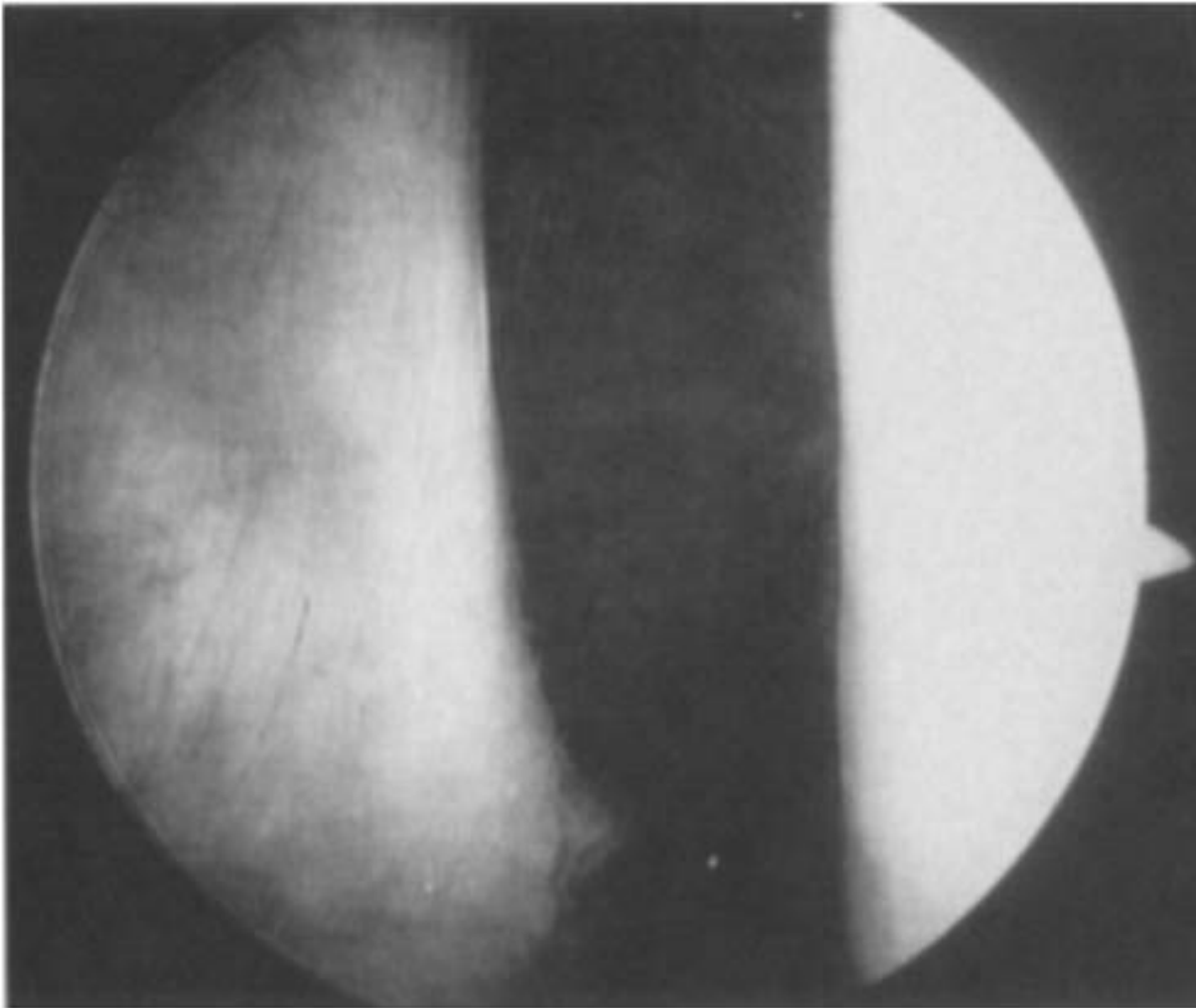
- Four structures of the lateral gutter:
  - Superolateral plica
    - Lateral portion of the suprapatellar plica
    - Transverse orientation and lies well above the patella
  - Alar fold or ligament/Plica Alaris Elongata
    - Longitudinal fold of synovium just lateral to the patella
    - Simply folding of the lateral retinaculum when relaxed
    - Inconstant, wide, and extremely soft
    - Triangular shape in cross-section
    - Usually not seen on arthroscopy but seen commonly on MR imaging
  - Lateral patellar plica
    - Located one fingerbreadth from the patella and alar fold
    - Thinner than alar fold
  - Transverse arcuate folds
    - Folds of synovium located at the bottom of the lateral gutter

# Lateral patellar plica

- Schematic diagram demonstrating the synovial plicae
- Note the location of the lateral plica



# Lateral patellar plica



**FIG 14.** A shelf pattern of lateral patellar plica.



# Lateral patellar plica

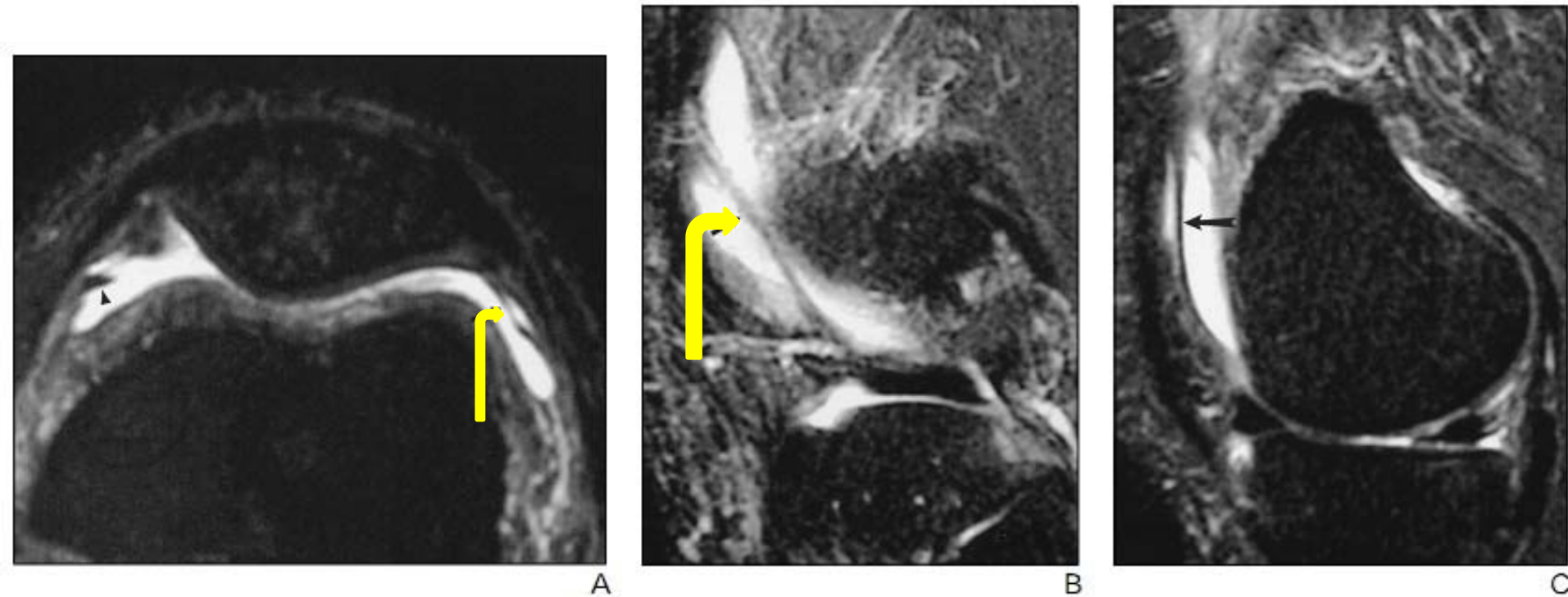


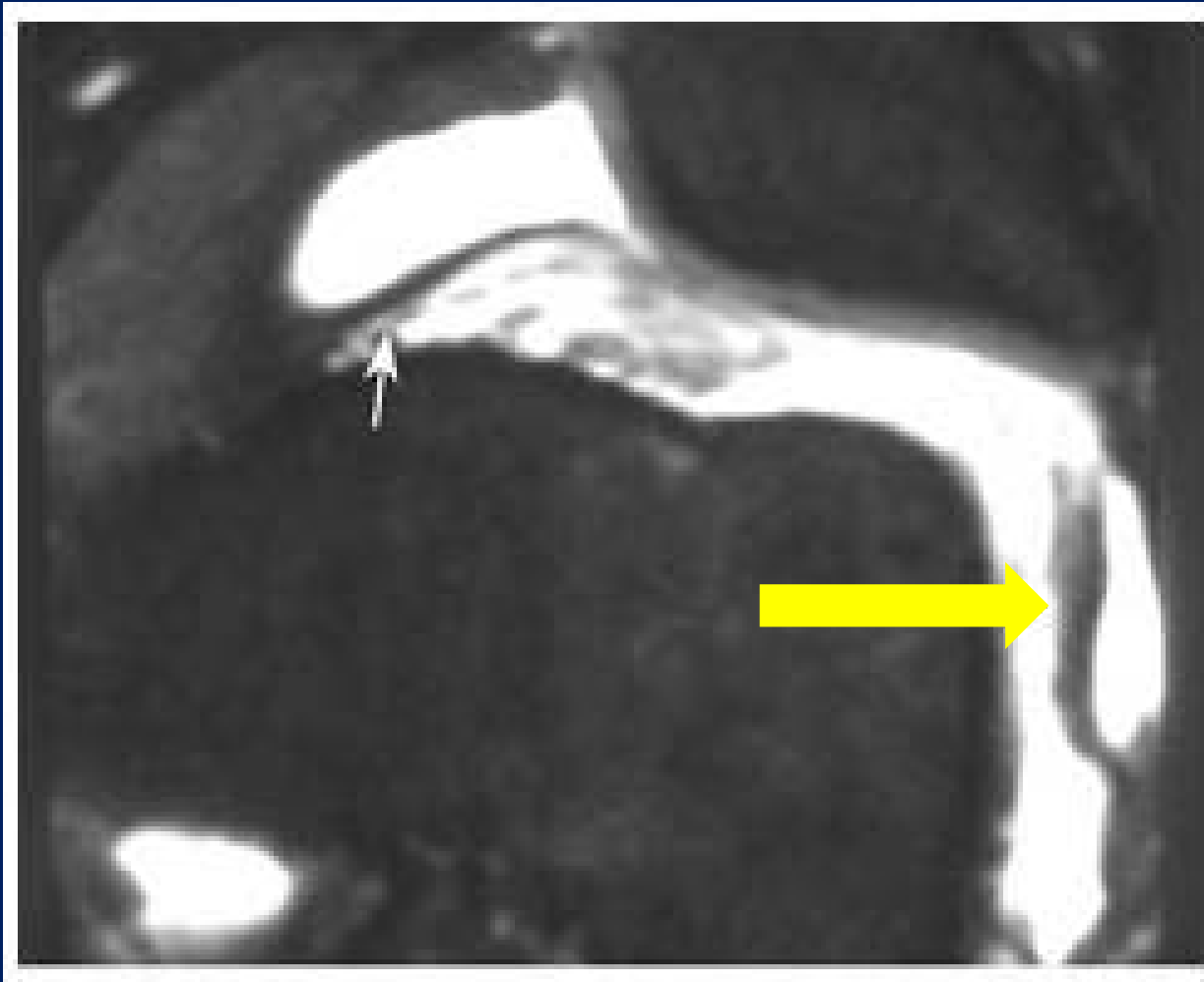
Fig. 10.—40-year-old man with rare lateral plica.

A, Axial short tau Inversion recovery (STIR) image (TR/effective TE, 3950/ 36) reveals bandlike low signal intensity in lateral joint at level of patella (*arrow*). Note prominent medial plica (*arrowhead*).

B, Sagittal STIR Image (4466/39) shows oblique-coronal orientation of lateral plica (*arrow*). Compare with transversely oriented, more posterior arcuate fold in Fig. 11. Lateral plicae may limit arthroscopic visualization of lateral gutter.

C, Sagittal STIR Image (4466/39) of medial joint reveals coronal orientation of medial plica (*arrow*).

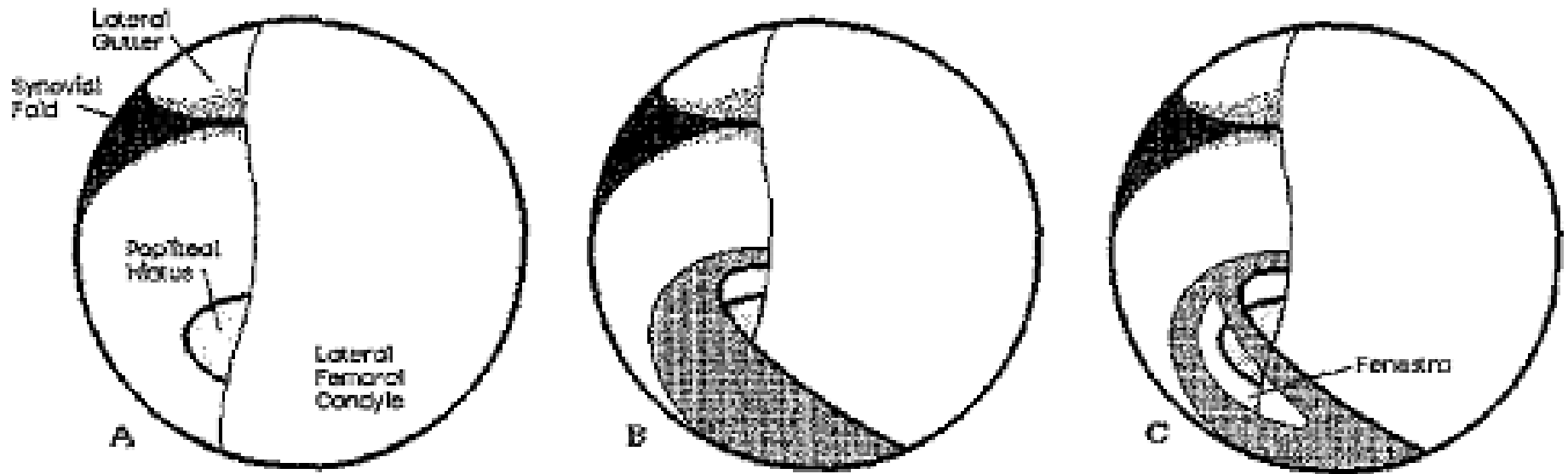
# Lateral patellar plica



# Lateral patellar plica

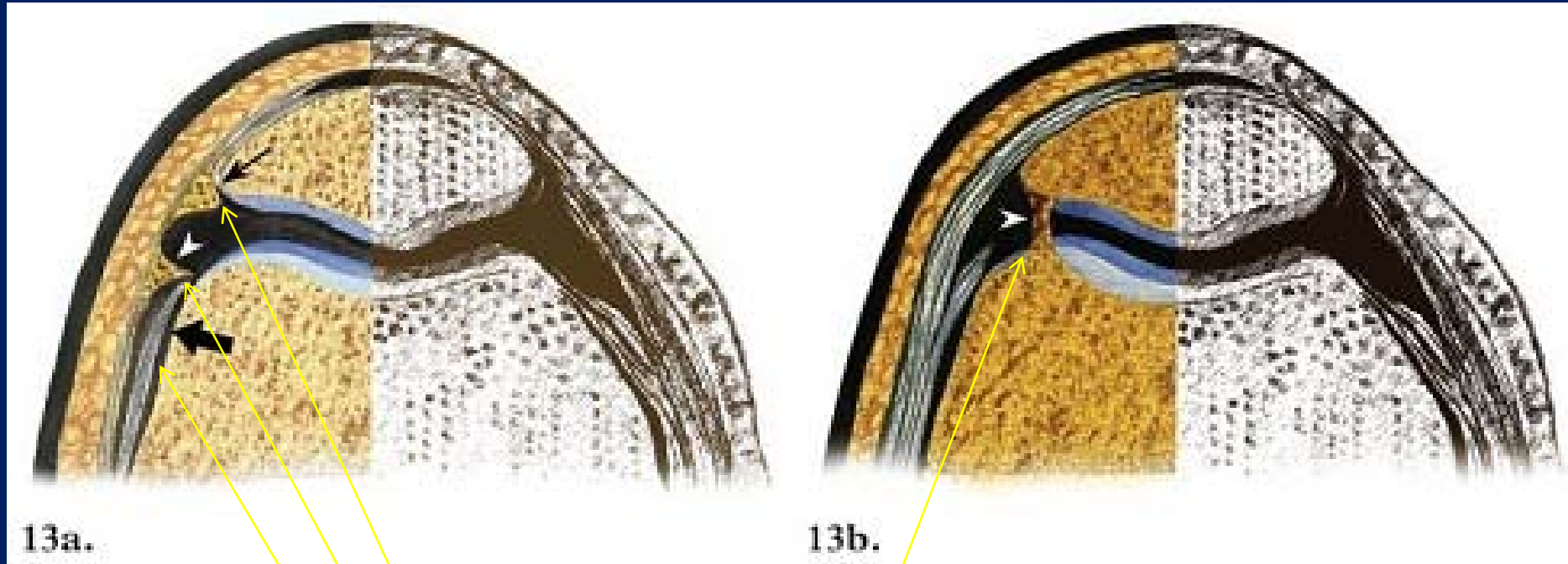
- Kim and Choe Arthroscopic Classification System<sup>9</sup>:
  - Absent
    - No plica present
  - Shelf
    - Complete shelf present with sharp free edge
  - Fenestra
    - Shelf with central defect

# Lateral patellar plica



**FIG 13.** Illustrations for patterns of lateral patellar plica in the right knee. (A) Absent; (B) shelf; (C) fenestra.

# Lateral patellar plica



- Superolateral plica
- Alar fold
- Lateral patellar plica
- Transverse arcuate folds

# Transverse Arcuate Fold

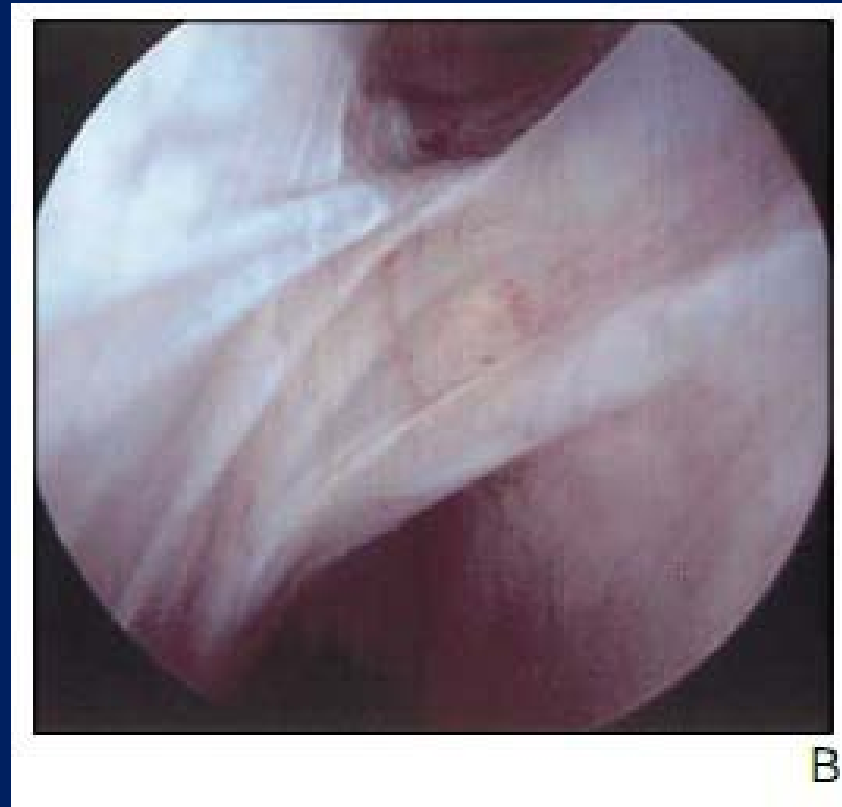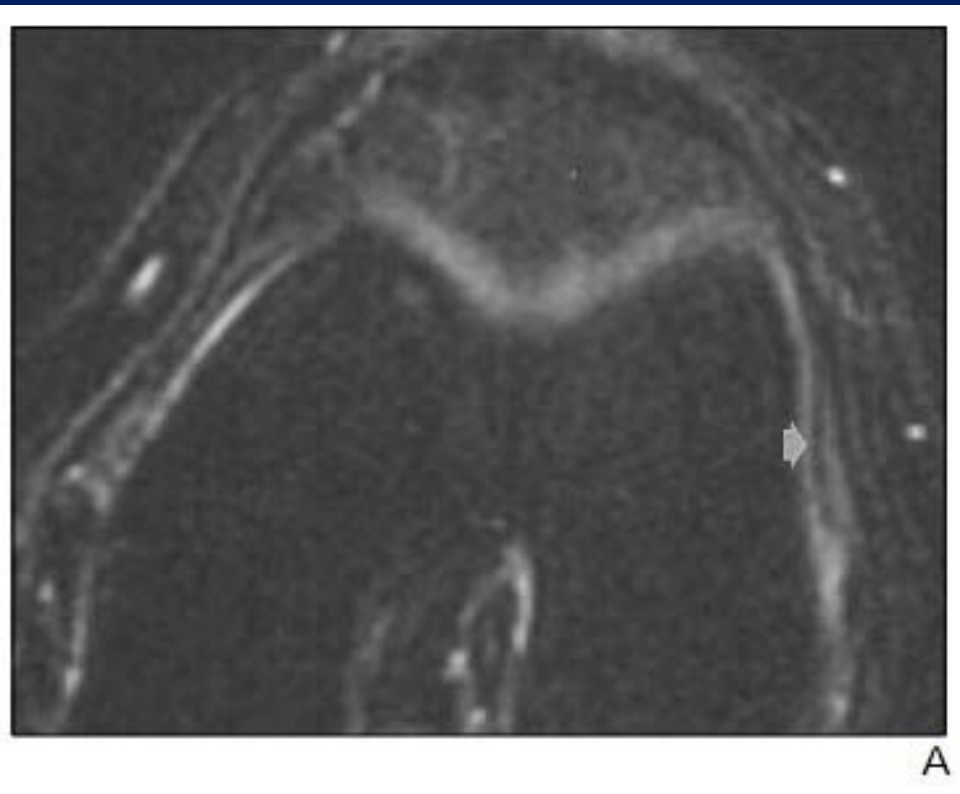


Fig. 11.—34-year-old woman with transverse arcuate fold.

A, Axial fat-suppressed T2-weighted MR image (TR/effective TE, 5500/84) obtained at level of intercondylar notch reveals curvilinear band in lateral gutter (*arrow*). Transverse arcuate fold is more sagittally oriented on axial plane, whereas true lateral plica is more anterior and has oblique coronal orientation (see Fig. 10).

B, Arthroscopic image of lateral transverse arcuate fold.

# Plicae are Normal Structures

- Plicae are common and **normal** synovial folds<sup>1</sup>
  - Only 10% of knees did not have a plica in one anatomic study<sup>1</sup>
  - 11% of knees had all three major plicae: suprapatellar, infrapatellar and medial plicae<sup>1</sup>
- The presence of a plica does not indicate a pathologic condition<sup>1</sup>
- Commonly seen on imaging and at arthroscopy

# Plicae are Normal Structures

- Proposed physiologic purposes of plicae<sup>8</sup>:
  - Limit friction
  - Increase the area covered by the synovial membrane
  - May help spread synovial fluid over the articular surfaces of the knee aiding in joint lubrication



# When good plica go bad: “Plica Syndromes”

- Plica can lead to clinical symptoms that can mimic internal derangements of the knee<sup>13</sup>
  - “Plica Syndromes”
- Two general mechanisms cause plica syndromes:
  - Inflammatory process or trauma can thicken and stiffen a plica
    - Normal elastic tissues replaced by fibrous elements
    - Plica becomes inelastic and tight resulting in:
      - Mechanical synovitis
      - Softening and erosion of adjacent articular cartilage
  - Complete failure of resorption leaving a complete septum and compartmentalization a joint
    - Suprapatellar and infrapatellar plica

# Pathologic Plica: Suprapatellar Plica

# Plica Syndrome: Suprapatellar Plica

- How does the suprapatellar plica cause symptoms?
  - Joint Compartmentalization
    - By far the most common cause of symptoms
    - Suprapatellar plica with a small porta may close and function as a complete plica if it pathologically thickens
  - Impingement on medial femoral condyle with possible adjacent cartilage damage

# Plica Syndrome: Suprapatellar Plica

- Joint Compartmentalization
  - 1996 Trout et al.<sup>13</sup>
    - Report on five patients with abnormal suprapatellar plica that led to compartmentalization of the suprapatellar pouch
    - Led to distension of the suprapatellar pouch and manifested as a soft-tissue mass clinically

# Plica Syndrome: Suprapatellar Plica

- 2009 Ehlinger M et al.<sup>14</sup>
  - Present case of 17 yo male with complete suprapatellar plica that presented with a **suprapatellar mass**

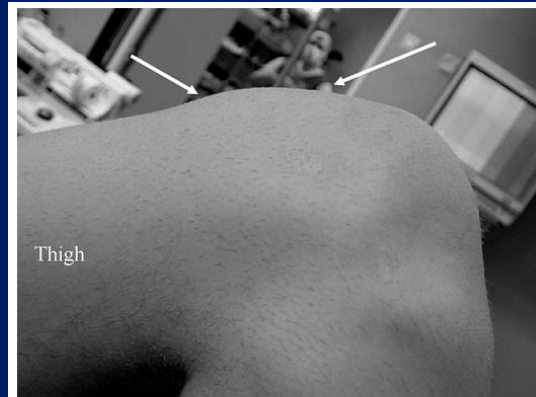


Figure 1 Preoperative macroscopic view of suprapatellar septum.

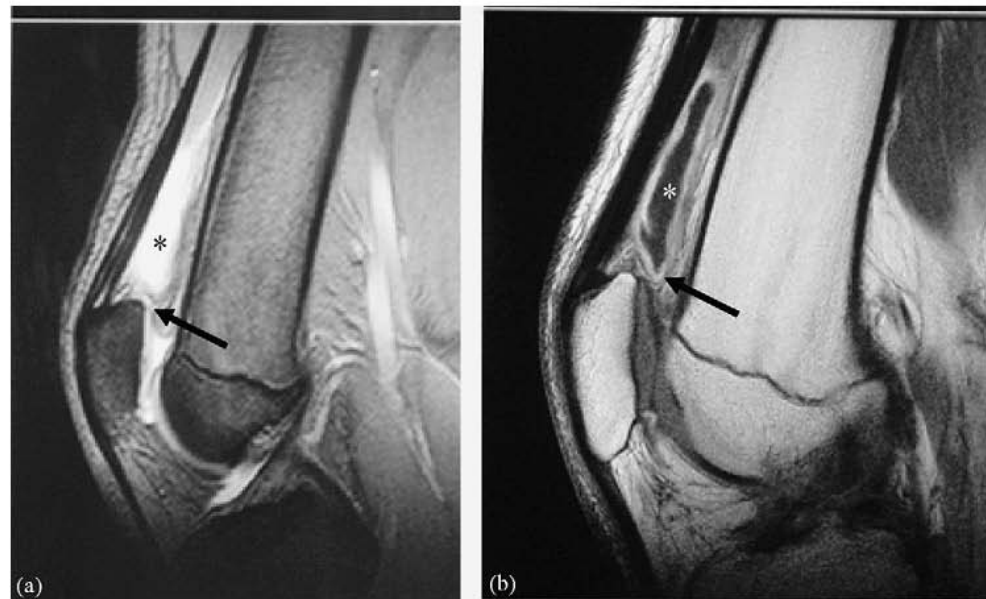
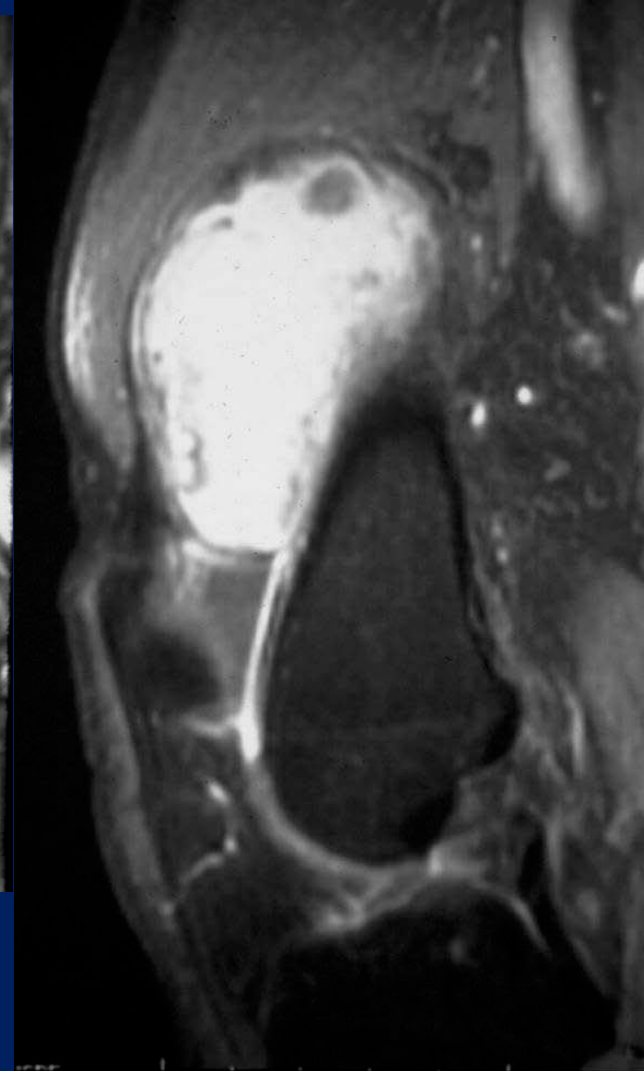
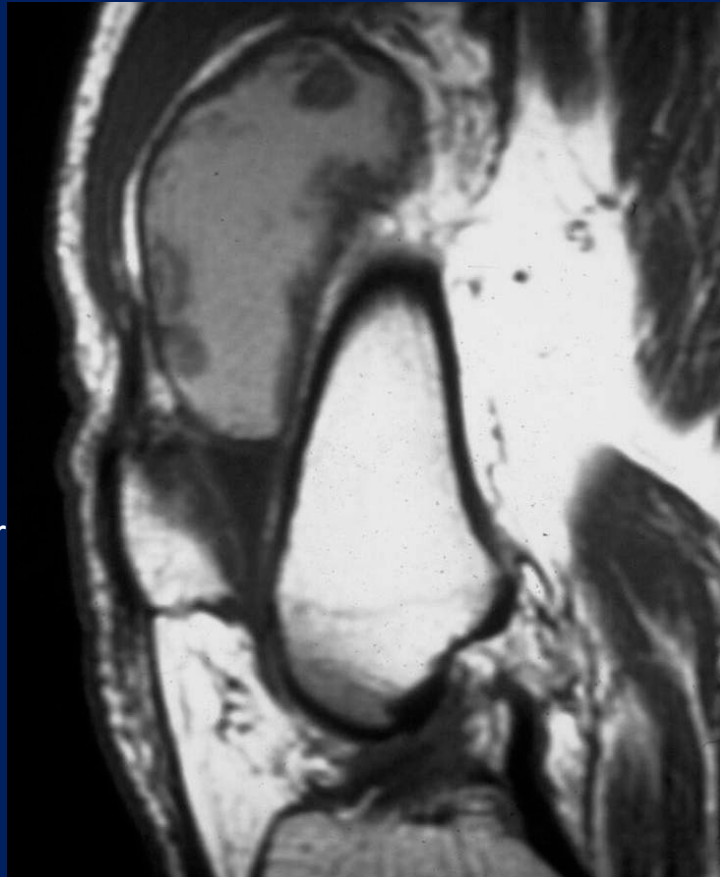


Figure 2 MR imaging. The suprapatellar plica (arrow) separates the sub-quadricipital bursa (asterisk) from the knee joint. a: fat-suppressed T2-weighted sagittal view. High-signal-intensity sub-quadricipital bursa; b: T1-weighted sagittal view after injection of contrast material. Low-signal-intensity bursa. Its wall is slightly thickened and contrasts thus revealing a synovitis.

# Pathologic plicae: Suprapatellar Plica

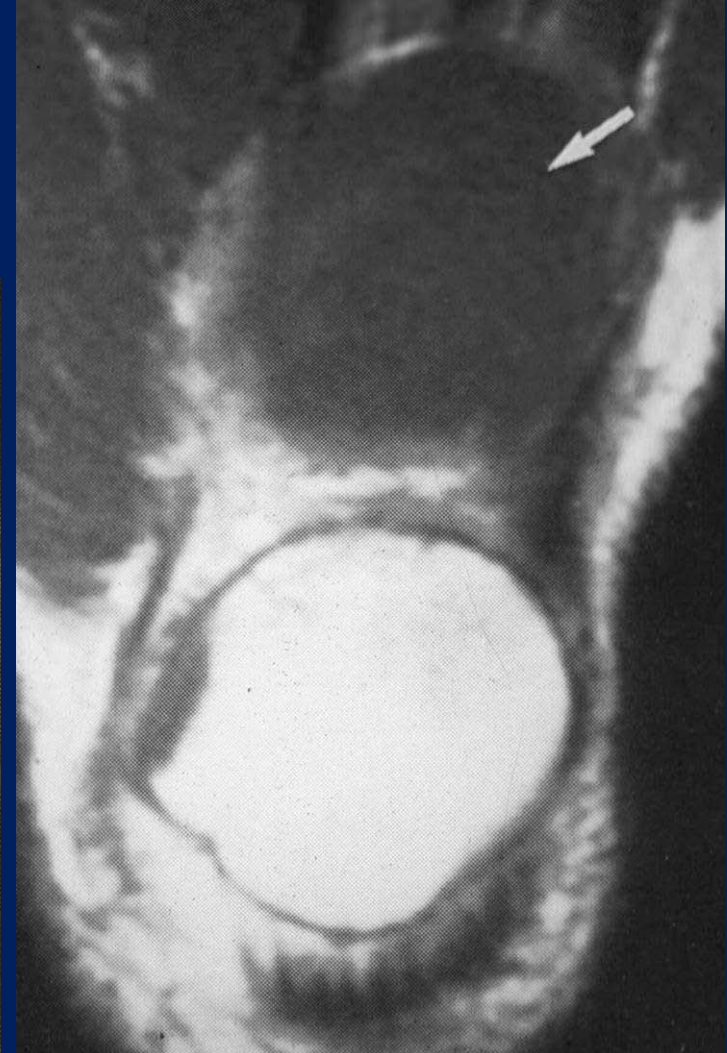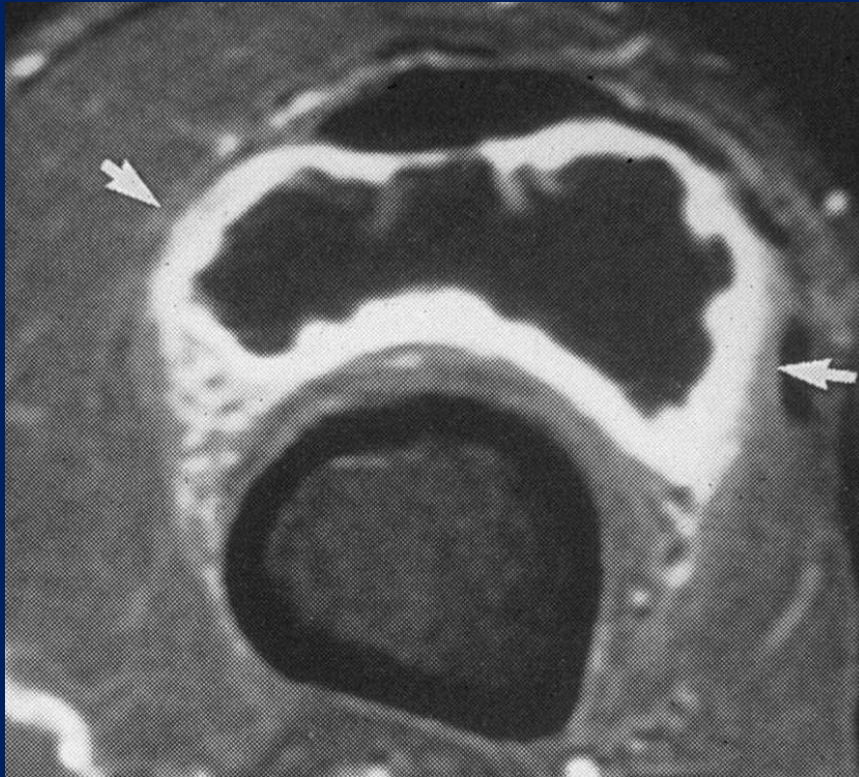- Compartmentalization of the joint by the suprapatellar plica
- Note the synovitis that may be confined to either the suprapatellar pouch or knee joint



Images courtesy of Dr. D. Resnick

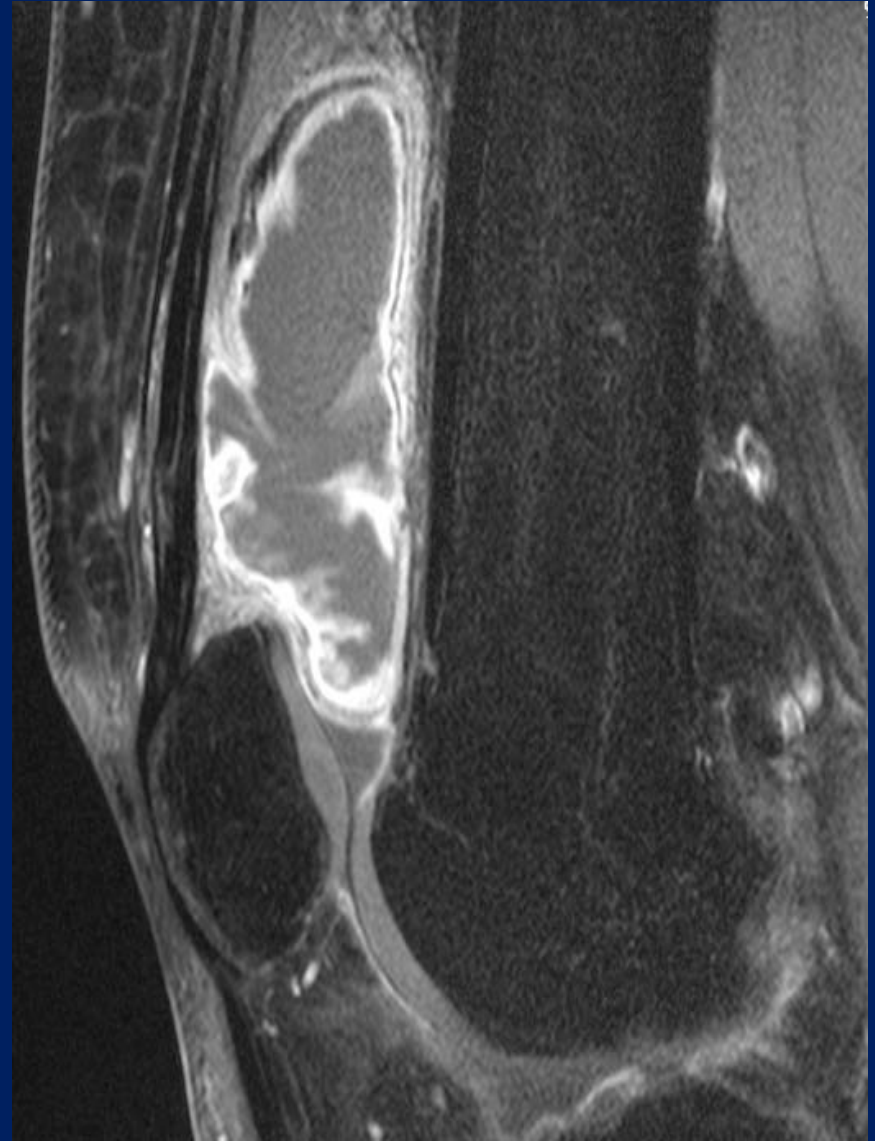
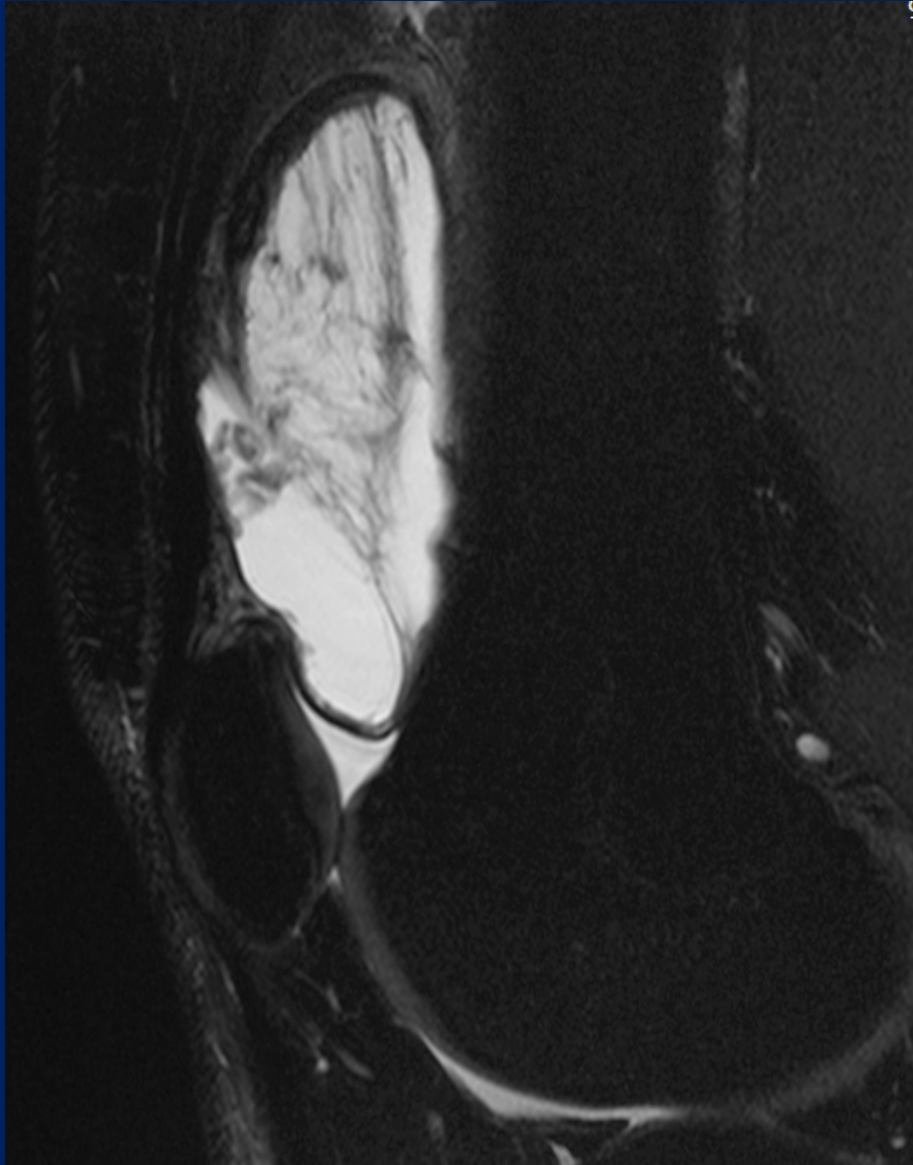
# Plica Syndrome: Suprapatellar Plica

- Another example of joint compartmentalization by a complete suprapatellar plica



Images courtesy of Dr. D. Resnick

# Plica Syndrome: Suprapatellar Plica

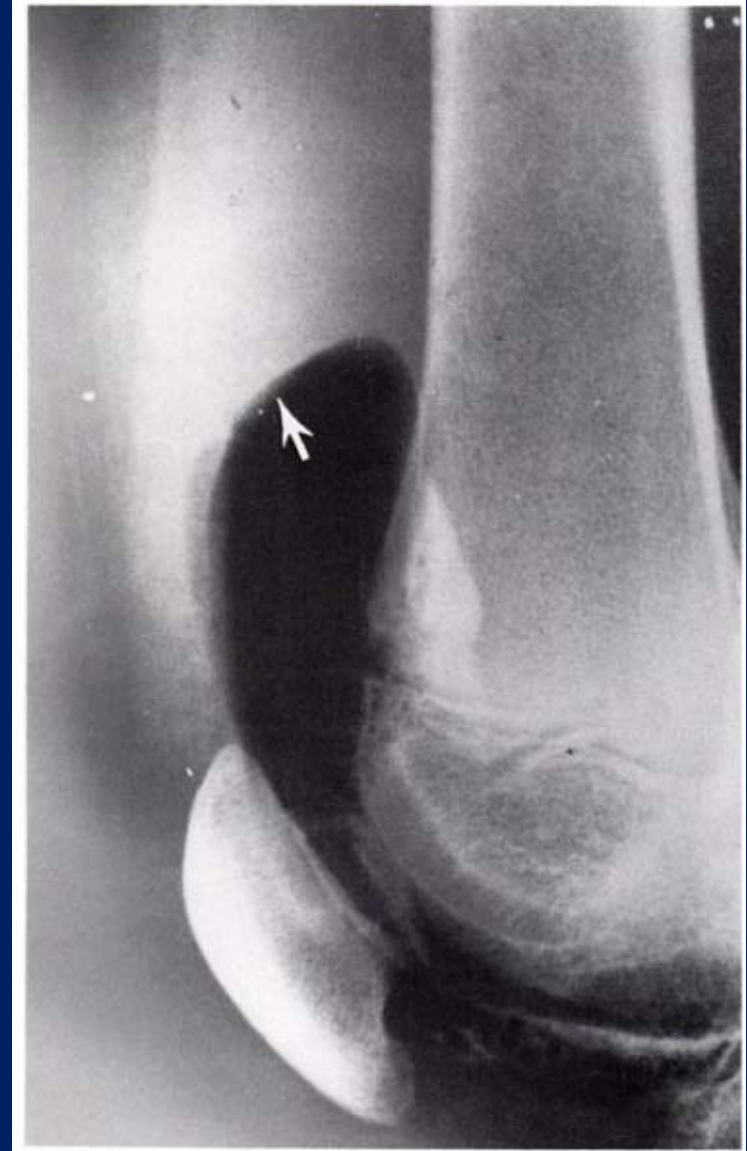

Images courtesy of Dr. M. Pathria



# Pathologic plicae: Suprapatellar Plica

- Double contrast arthrogram demonstrating a complete suprapatellar plica and compartmentalization of the knee joint



# Plica Syndrome: Suprapatellar Plica

- Suprapatellar plica resulting in partition of a **lipohemarthrosis**

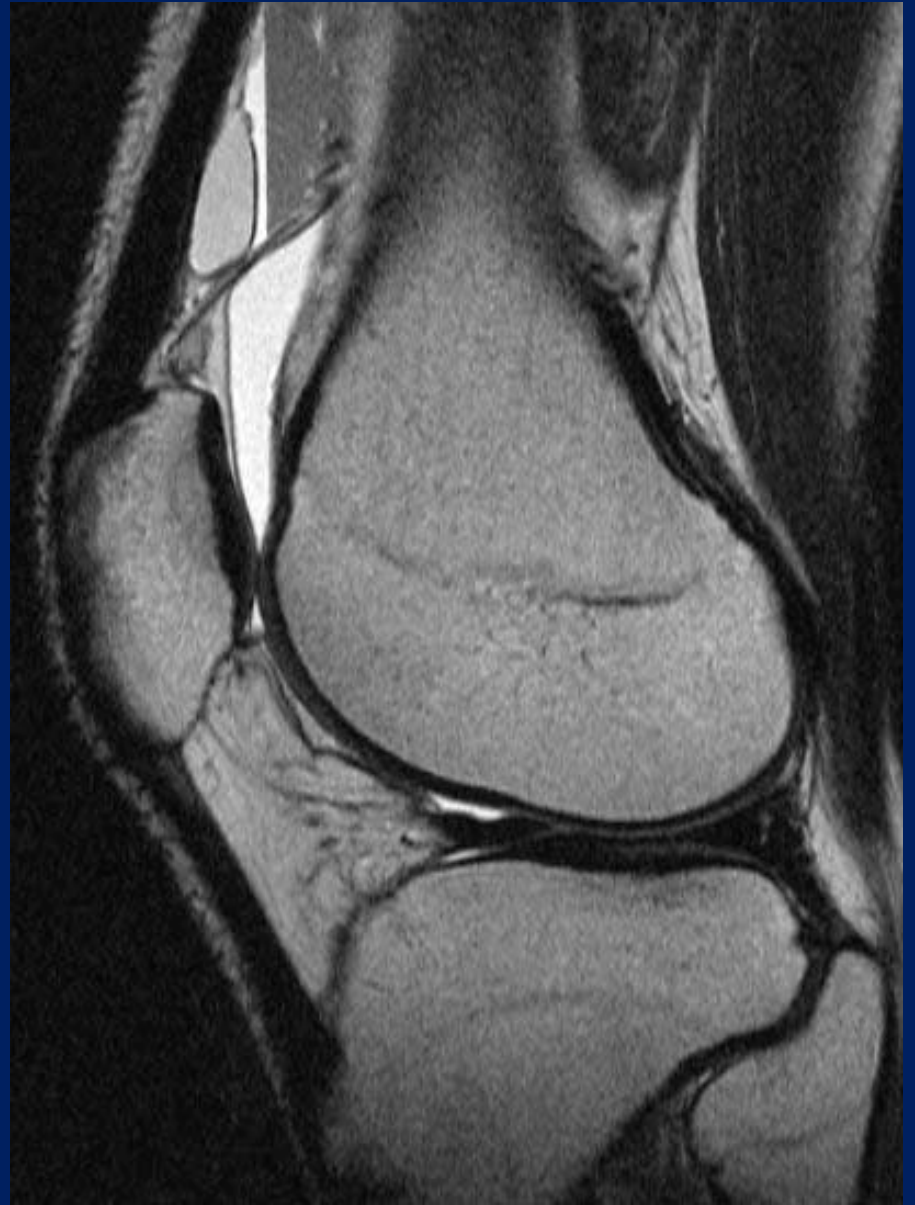
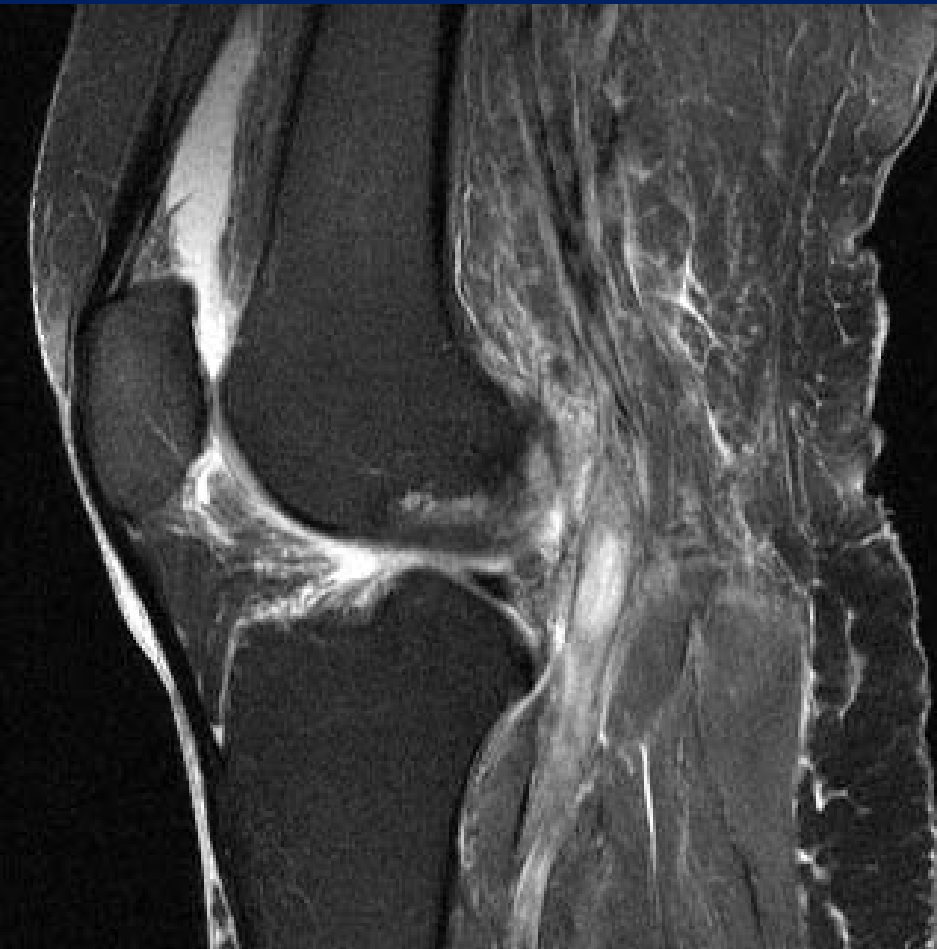
Image courtesy of Dr. T. Hughes

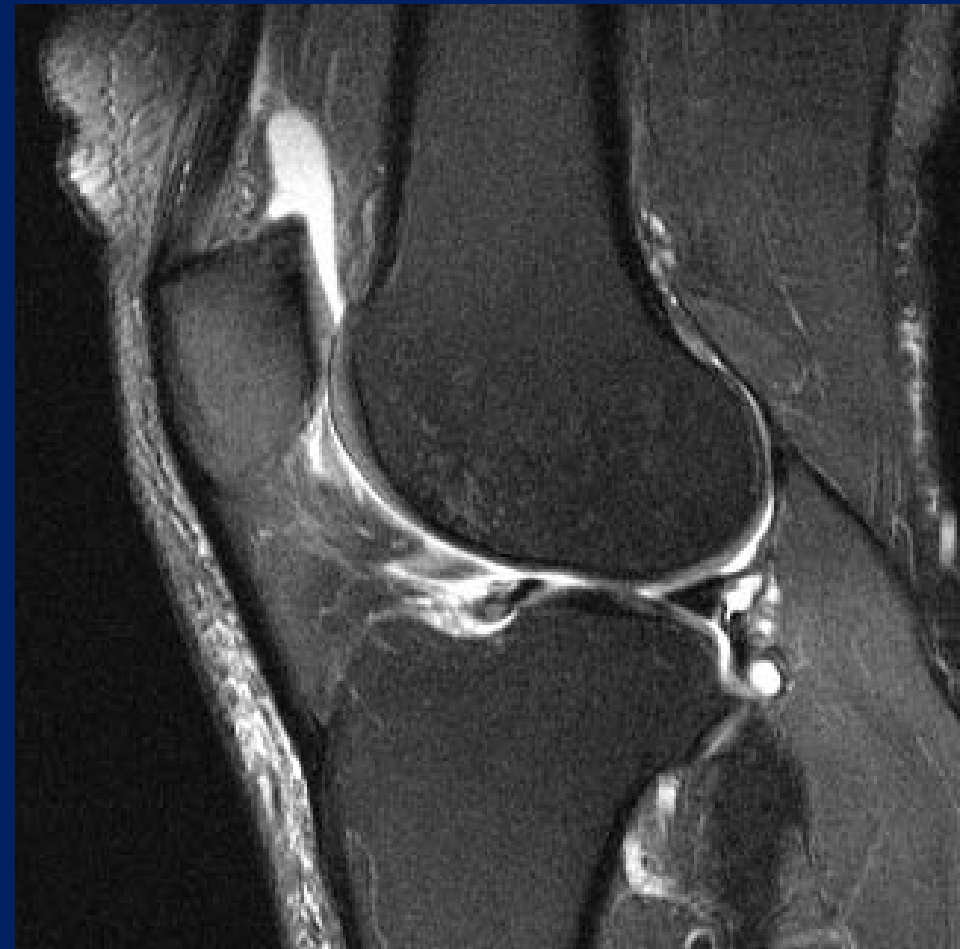# Pathologic plicae: Suprapatellar Plica

- Documentation of a complete suprapatellar plica is very important
  - Will change surgical approach
  - Cases of osteocartilaginous bodies in a separate suprapatellar bursa that could not be located after infrapatellar incision<sup>8</sup>
  - Diffuse synovial processes (ex. PVNS) may only affect the sequestered suprapatellar pouch<sup>8</sup>
  - Acute suppurative bursitis – rupture of the plica may unnecessarily contaminate the joint<sup>8</sup>

# Pathologic plicae: Suprapatellar Plica



Incomplete Suprapatellar Plica

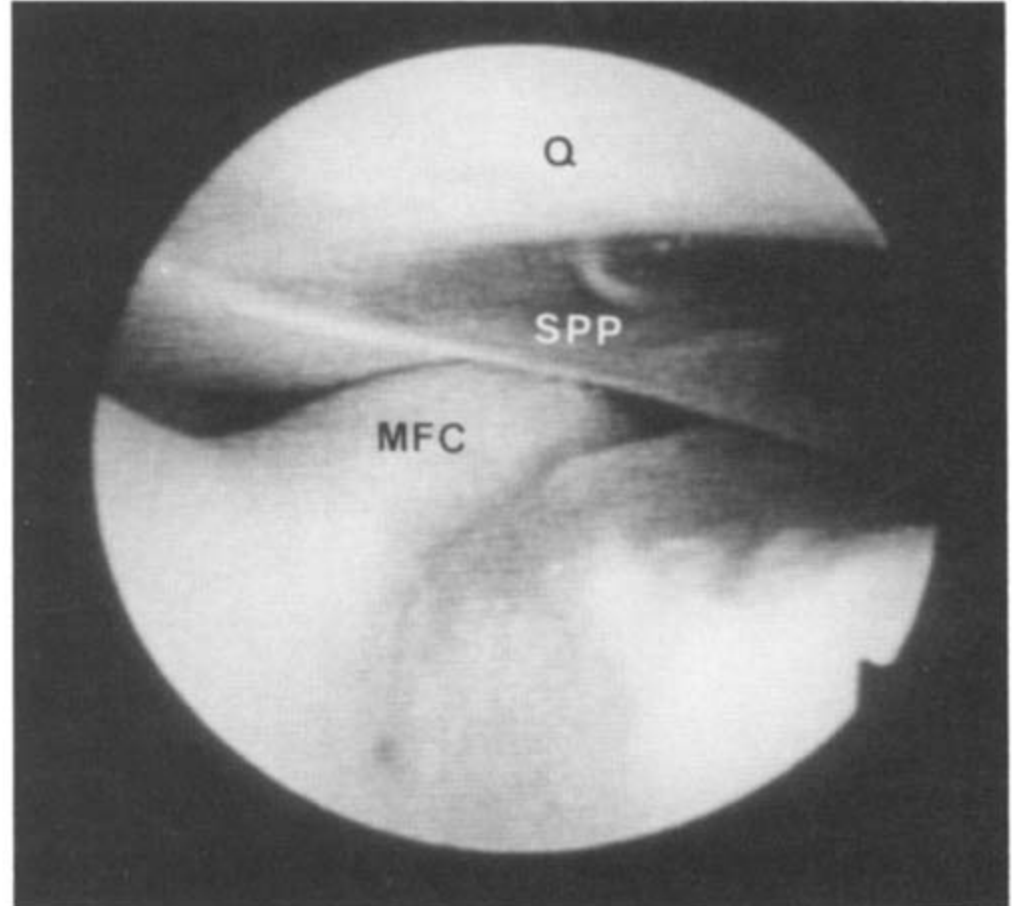


Complete Suprapatellar Plica

Note: Reduced size and blunting of the suprapatellar bursa

# Plica Syndrome: Suprapatellar Plica

- Impingement and cartilage damage
- 1991 Strover et al.<sup>12</sup>:
  - Demonstrated impingement of suprapatellar plicae on the medial femoral condyle when the knee is flexed at arthroscopy
  - Speculated possibility of damage to the articular surfaces of the patella and trochlea



**FIG. 3.** Arthroscopic view of the impingement of the suprapatellar plica on the medial femoral condyle using a 70° arthroscope through the lateral suprapatellar portal. Q, quadriceps; SPP, suprapatellar plica; MFC, medial femoral condyle.

# Plica Syndrome: Suprapatellar Plica

2004 Adachi et al.<sup>15</sup>

- Report case of 27-year-old professional baseball pitcher with complete-type suprapatellar plica and **anterior knee pain**
- Complete suprapatellar plica may be a source of anterior knee pain
- Arthroscopy showed damage to cartilage on lateral patellar facet
- Experienced complete symptom relief after plica resection

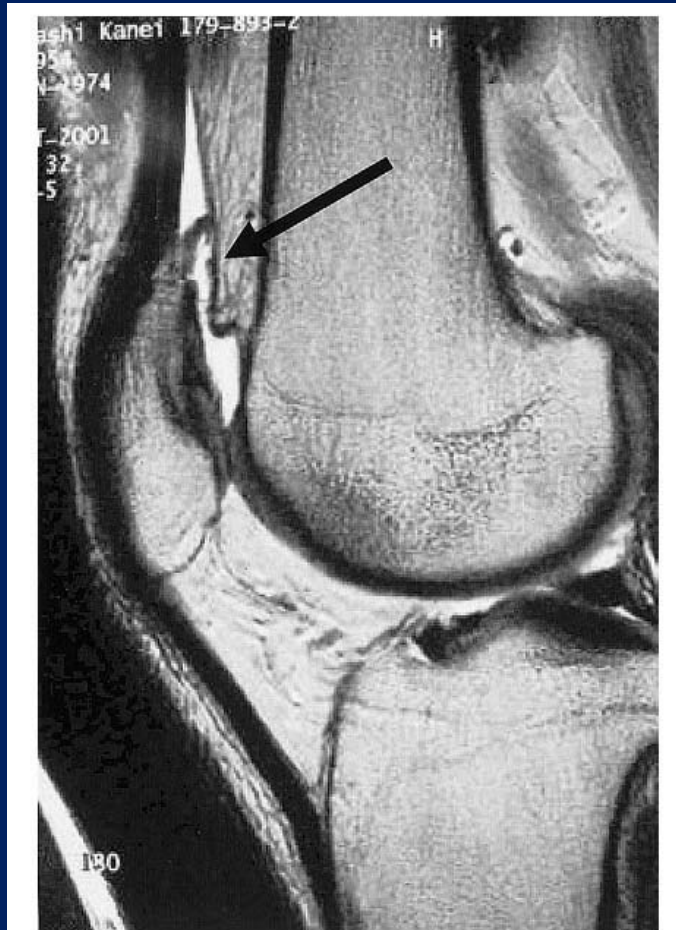

FIGURE 3. Preoperative sagittal MRI (T2-weighted image, TR/TE 3500/96) shows the suprapatellar plica (arrow).

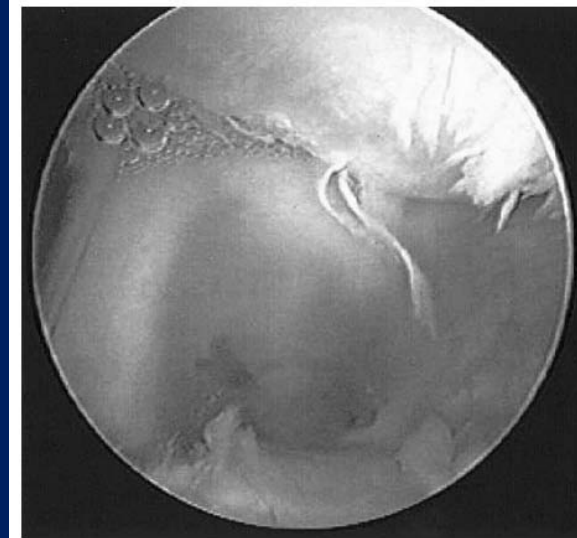

FIGURE 6. Arthroscopic view showing the complete type of the suprapatellar plica.

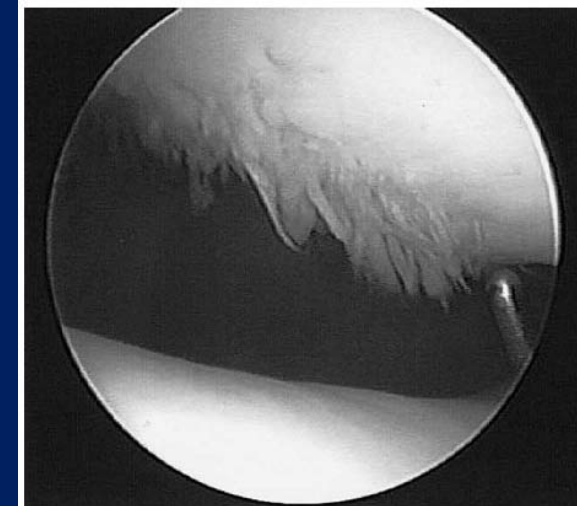


FIGURE 5. Arthroscopic view showing the cartilaginous damage on the lateral facet of the patella.

# Plica Syndrome: Infrapatellar Plica

# Plica Syndrome: Infrapatellar plica

- Very rarely a cause of symptoms
- Etiologies of Infrapatellar Plica Syndrome:
  - May become thick and fibrotic resulting in **impingement** in the intercondylar notch
  - Can rupture and mimic an ACL tear and result in a **hemarthrosis**
  - May form a complete septum and result in **compartmentalization** of the medial and lateral knee compartments
    - Similar compartmentalization of the joint has been seen in hereditary onycho-osteochondrodysplasia (nail-patella syndrome)
  - Can limit mobility of the arthroscope and make arthroscopy more difficult

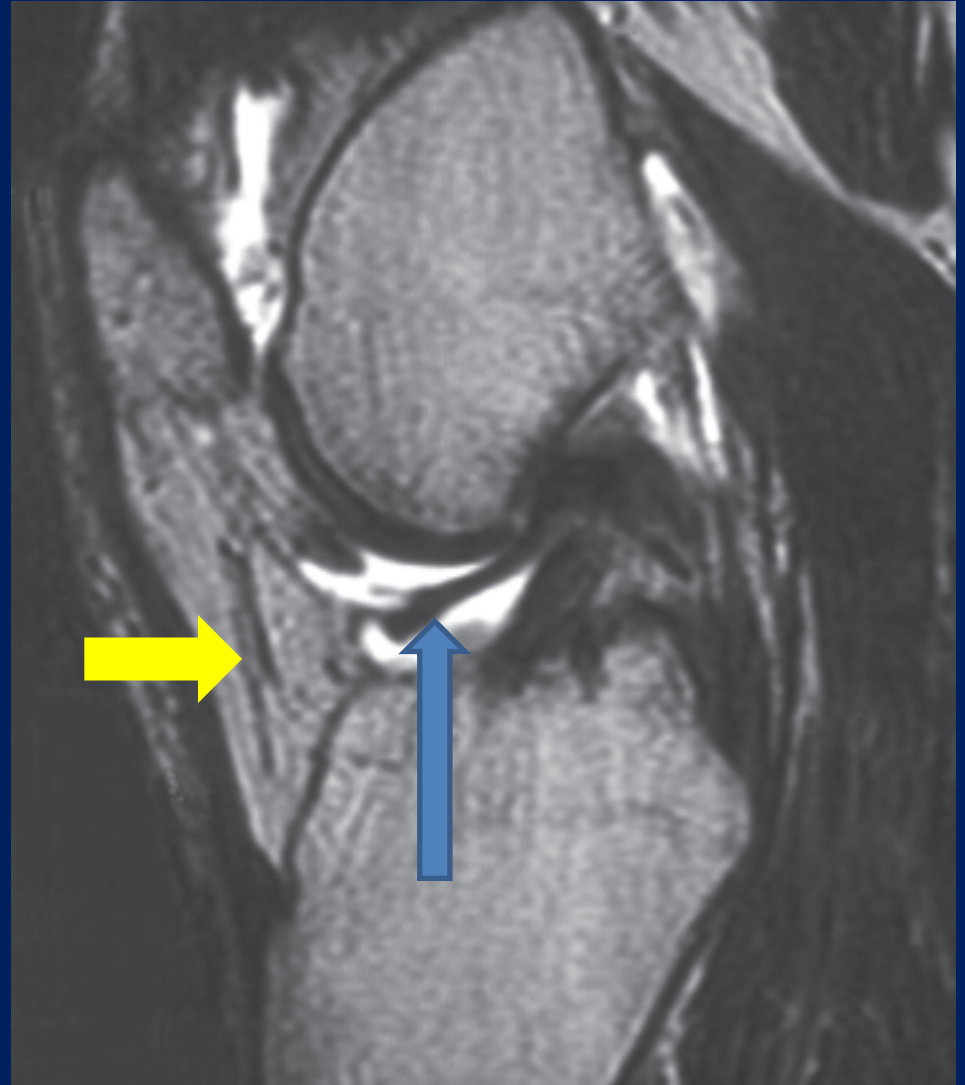


# Plica Syndrome: Infrapatellar plica

- 1996 Kim and Choe<sup>16</sup>
  - Two cases of flexion contractures of the knees where a vertical septum type infrapatellar plica was demonstrated
  - Plica were thickened, fibrotic, and lost their normal elasticity
  - Resection of the plica resulted in complete symptom resolution

# Plica Syndrome: Infrapatellar plica

- Thickened infrapatellar plica (blue arrow)
- Strands of tissue (yellow arrow) may extend from the thickened plica to the patellar tendon and result in tethering of the patellar ligament



# Plica Syndrome: Infrapatellar plica

- Ruptured infrapatellar plica may result in a **post-traumatic hemarthrosis**
- 1995 Kohn et al.<sup>18</sup>
  - Anatomic and clinical study in the orthopedic literature
  - Describes torn infrapatellar plica as only abnormality in 3/57 patients with posttraumatic hemarthrosis and a clinically stable joint

# Plica Syndrome: Infrapatellar plica

- 2003 Cothran et al.<sup>17</sup>
  - Often we see increased signal along the course of the infrapatellar plica
  - **Abnormal increased signal** along the infrapatellar plicae at MR imaging may indicate direct trauma to the plica or inflammation related to Hoffa's disease
  - Isolated injury to plica is uncommon and therefore they recommend exclusion of other causes of internal derangements prior to attributing symptoms to an injured plica
  - Most of the examples cited in the article were diagnosed retrospectively
- **Caution** is warranted in diagnosing infrapatellar plica pathology<sup>8</sup>:
  - Abnormal signal along the course of the plica is frequent
    - There are normal recesses in Hoffa's fat pad that may collect fluid

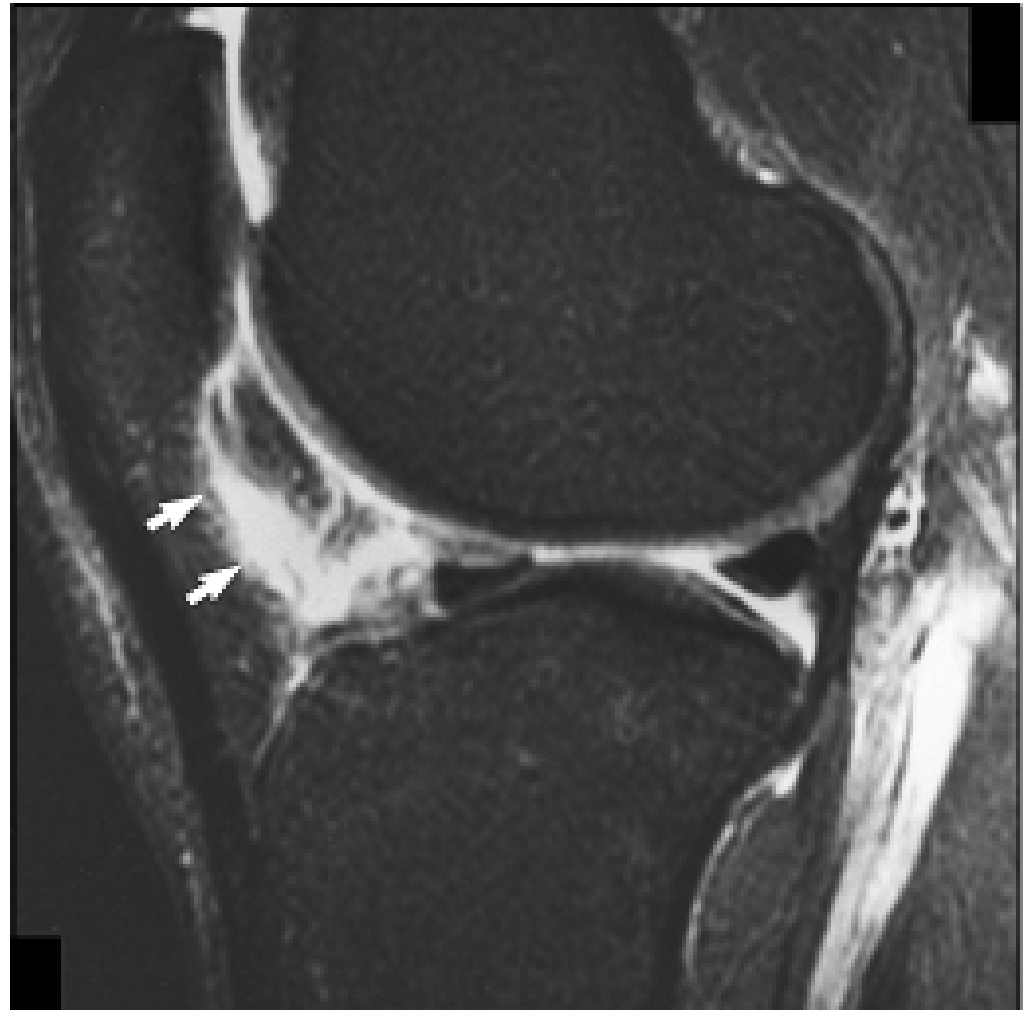
# Plica Syndrome: Infrapatellar plica

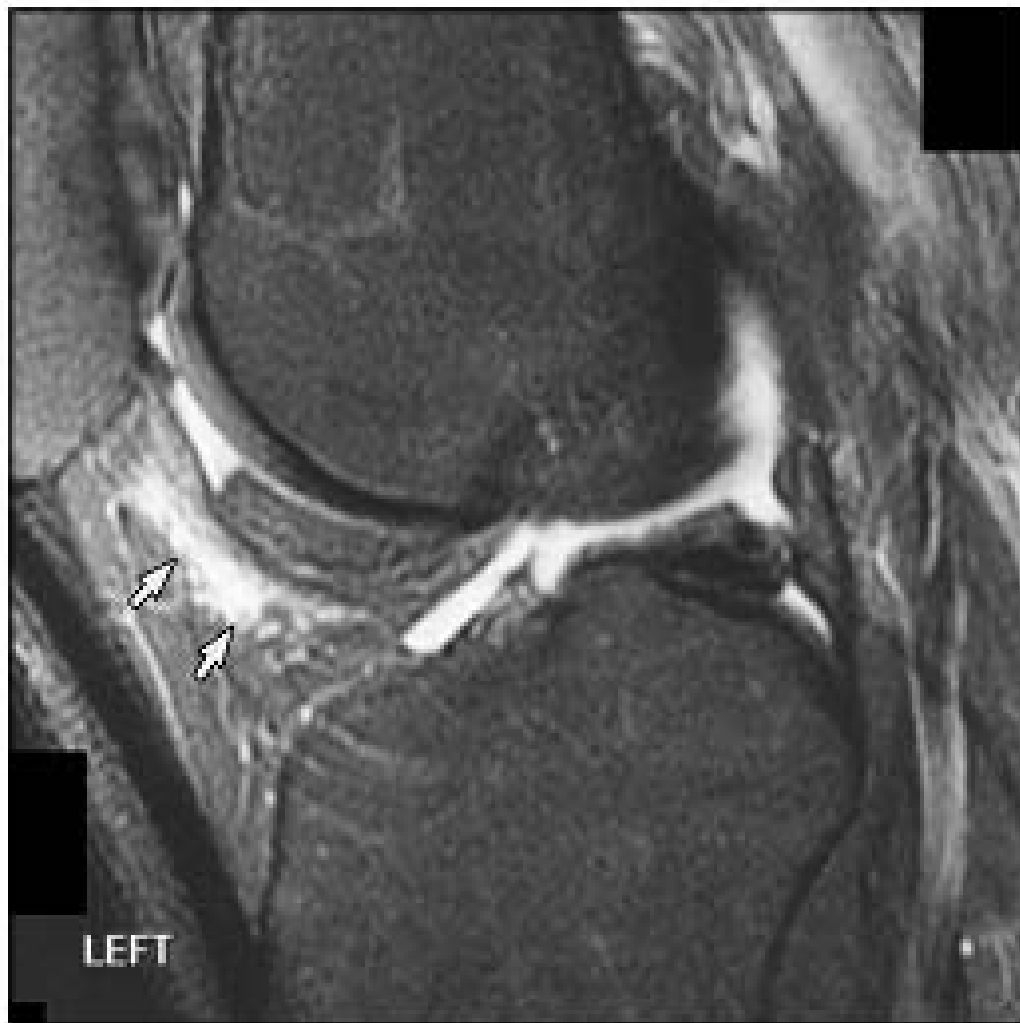

Fig. 4.—22-year-old male collegiate basketball player with bilateral anterior knee pain. Sagittal fast spin-echo T2-weighted MR image (TR/TE, 4000/73) with fat suppression through left intercondylar notch shows curvilinear high signal intensity along course of infrapatellar plica (arrows). Knee was otherwise normal.

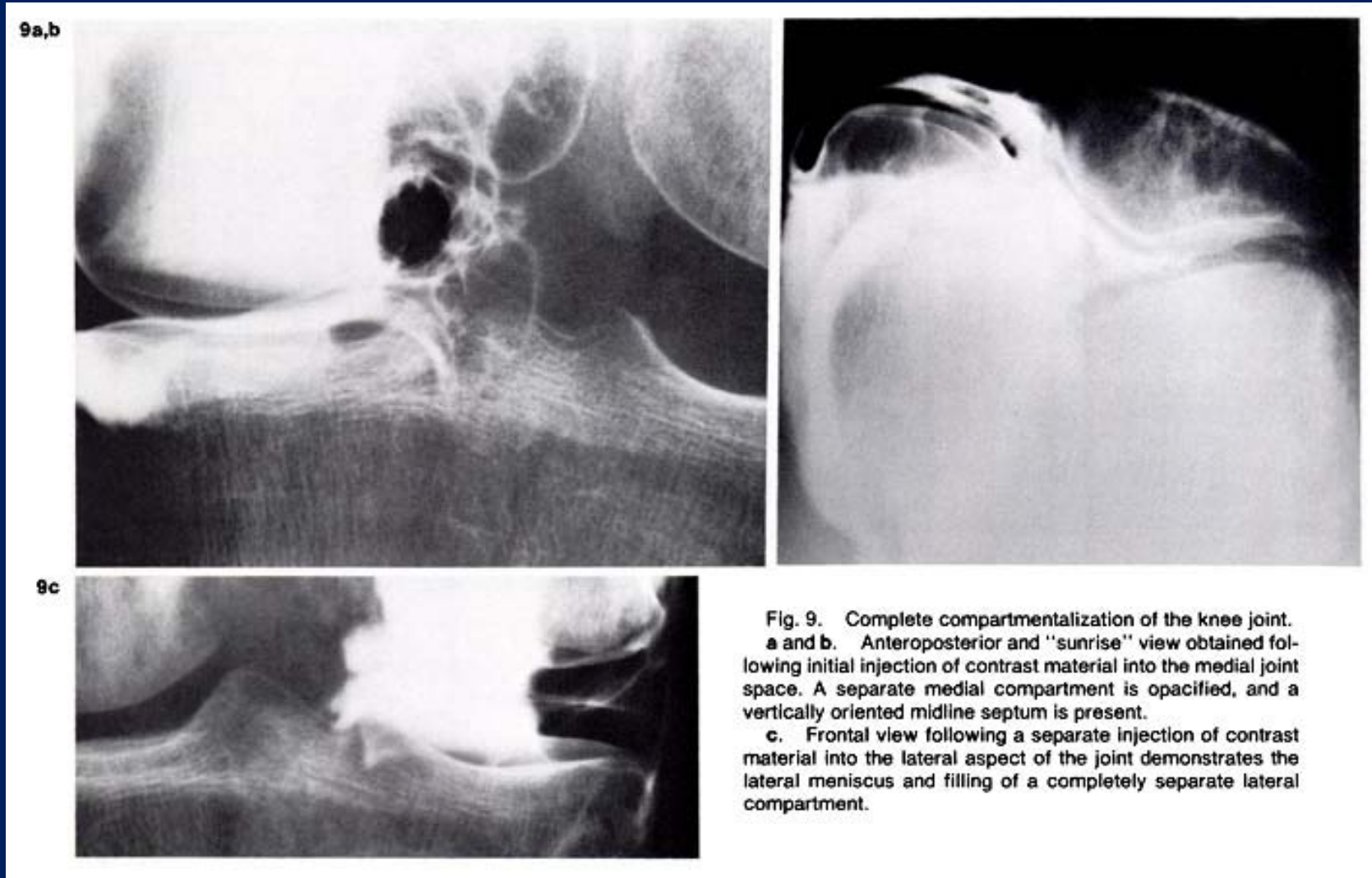
# Plica Syndrome: Infrapatellar plica

**Fig. 3.**—38-year-old woman with skiing injury. Sagittal fast spin-echo T2-weighted MR image (TR/TE, 4000/87) with fat suppression through knee 6 months after injury shows fluid signal along course of infrapatellar plica (arrows) interpreted as torn anterior cruciate ligament with associated rupture of infrapatellar plica. At arthroscopy 2 months later (not shown), scar tissue was found in expected position of infrapatellar plica, suggesting that plica had been injured.



# Plica Syndrome: Infrapatellar plica

- Infrapatellar Plica: Joint Compartmentalization



# Plica Syndrome: Medial patellar plica

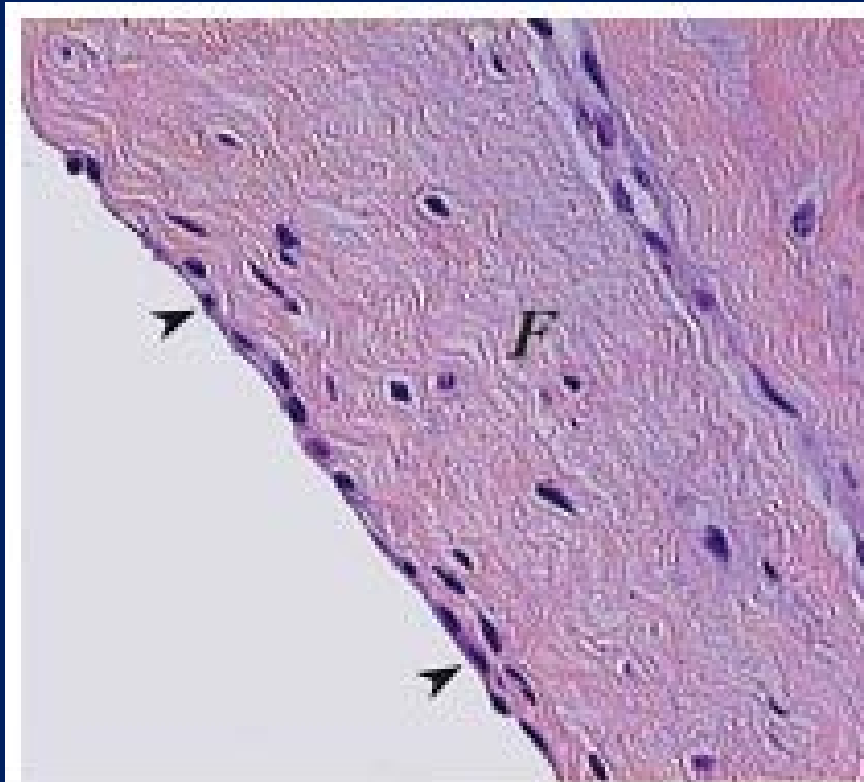


# Plica Syndrome: Medial patellar plica

- The plica most commonly associated with symptoms
- The medial patellar plica is normally a thin and elastic structure<sup>18</sup>
- Why does the plica result in anterior knee pain?
  - Somewhat controversial
  - Direct trauma or repetitive indirect trauma may provoke inflammation of the plica<sup>19</sup>
    - Inflamed plica becomes thick and loses its elasticity
  - Thick plica exerts **mechanical pressure** on the medial femoral condyle or medial articular surface of the patella may result in pain<sup>23</sup>
  - Thickened plica may **damage the cartilage** of the medial patellar facet or the medial aspect of the femoral trochlea

# Plica Syndrome: Medial patellar plica

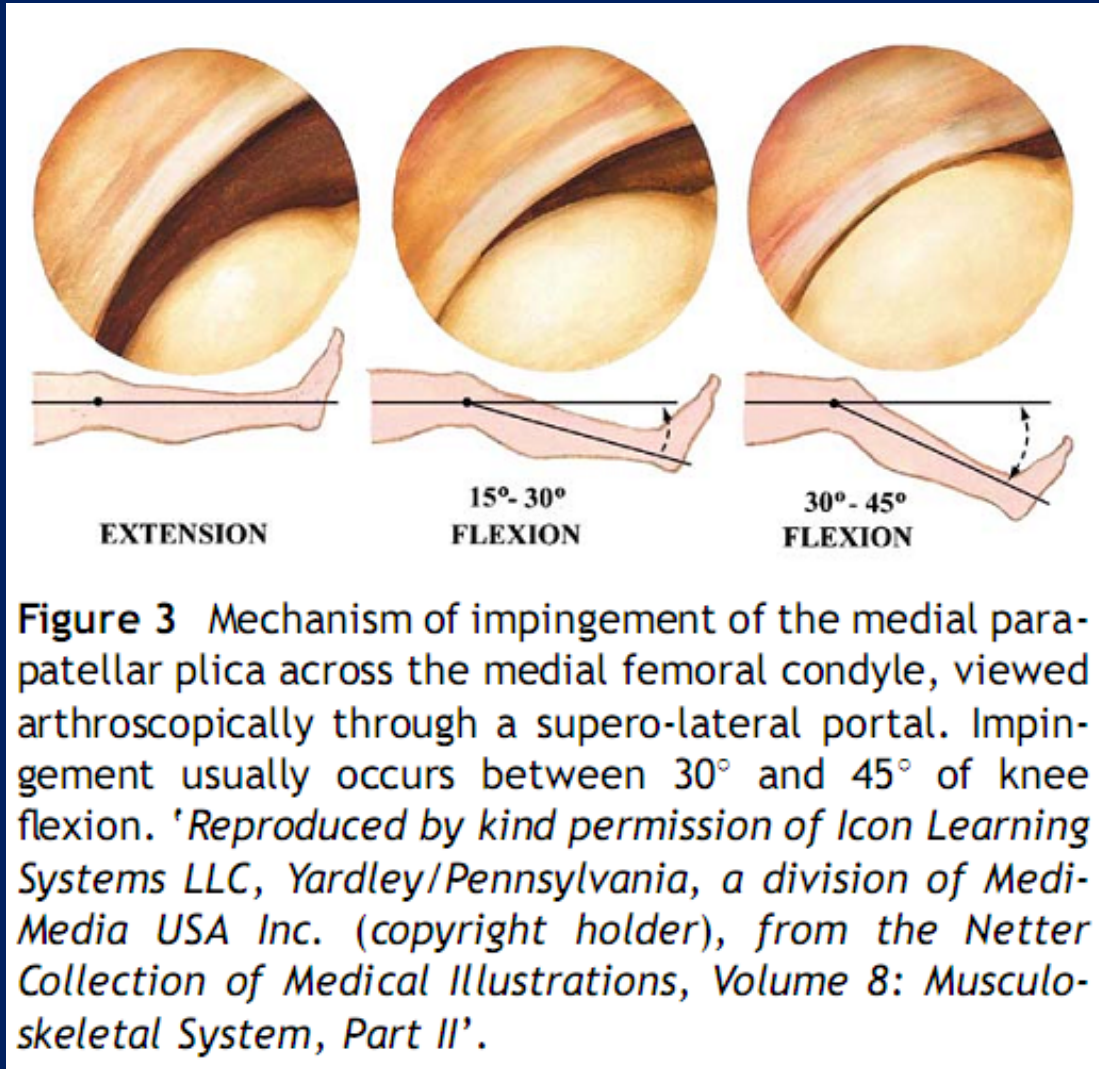
- Histology of inflamed medial patellar plica



**Figure 14.** Mediopatellar plica. Photomicrograph (original magnification,  $\times 40$ ; hematoxylin-eosin stain) of a symptomatic synovial plica demonstrates a fibrotic band (*F*) covered with slightly inflamed synovium (arrowheads).

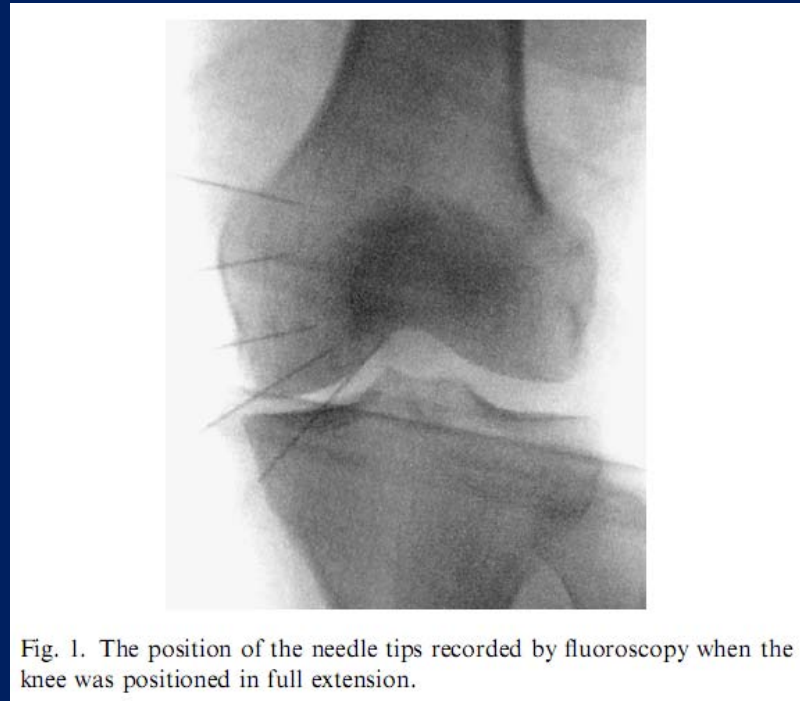
# Plica Syndrome: Medial patellar plica

- Impingement of medial patellar plica with knee flexion



# Plica Syndrome: Medial patellar plica

- Lyu (2007) located the inner margins of the plica using needle under arthroscopy and observed the movement of the plica under fluoroscopy<sup>29</sup>
- All types of plica slide medially when the knee moved from flexion to extension<sup>29</sup>



# Plica Syndrome: Medial patellar plica

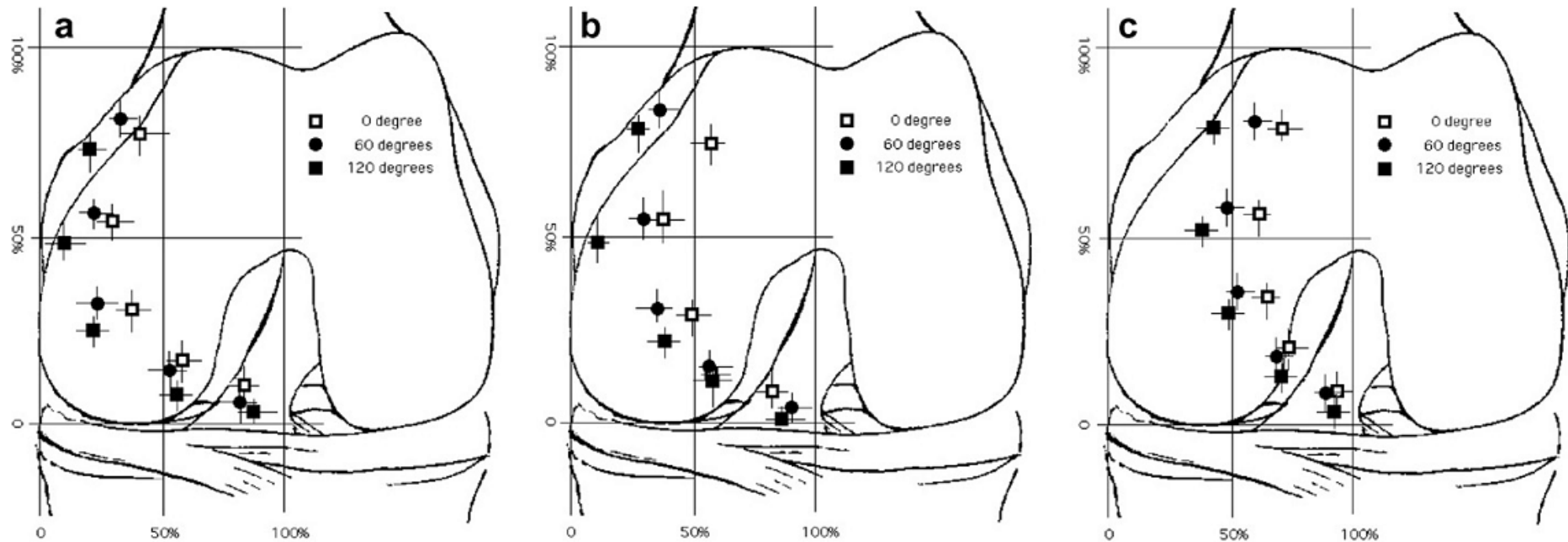
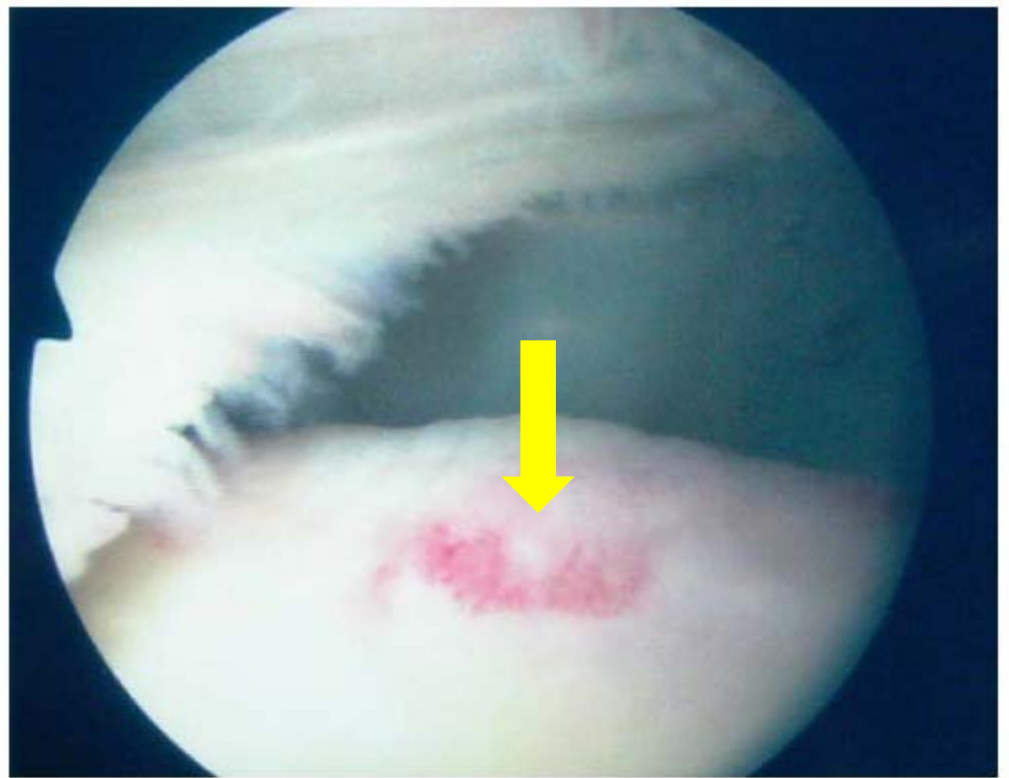


Fig. 2. The topographic change of the margins of three different types of medial plica during knee motion. (a) The topographic change of the margin of type A (non-overriding type) medial plica during knee motion. (b) The topographic change of the margin of type B (overriding type) medial plica during knee motion. (c) The topographic change of the margin of type C (covering type) medial plica during knee motion.

# Plica Syndrome: Medial patellar plica

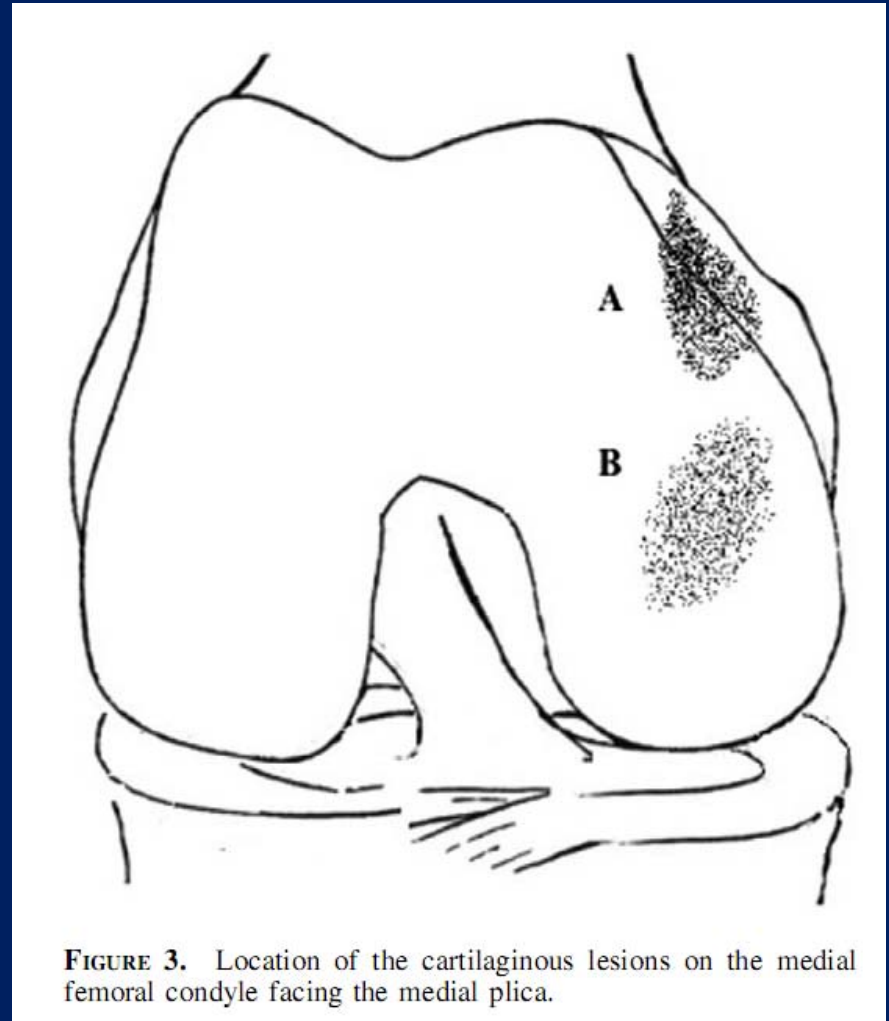
- Medial femoral condyle articular cartilage inflammation with adjacent medial patellar plica



**Figure 5** Arthroscopic view from the supero-lateral portal in a left knee at full extension. Localised inflammatory changes of articular cartilage on the medial femoral condyle caused by plica impingement can be seen.

# Plica Syndrome: Medial patellar plica

- Typical locations of cartilage lesions on the medial femoral condyle



**FIGURE 3.** Location of the cartilaginous lesions on the medial femoral condyle facing the medial plica.

# Plica Syndrome: Medial patellar plica

- 2004 Farkas et al.<sup>23</sup>
  - The criteria for a “symptomatic plica” is not uniform and often the diagnosis is only made after removal of the plica causes a reduction in the patient’s symptoms
  - Even plica that are not in direct contact with the articular surface may be a source of pain
  - Discovered a significantly **increased number of neuroelements** in symptomatic plica compared to asymptomatic plica
    - The more neuroelements the greater the pain sensitivity of the structure
  - Found that the number of neuroelements was significantly higher in patients that had previous trauma
    - Trauma may induce neuroelement formation and “sensitize” the plica



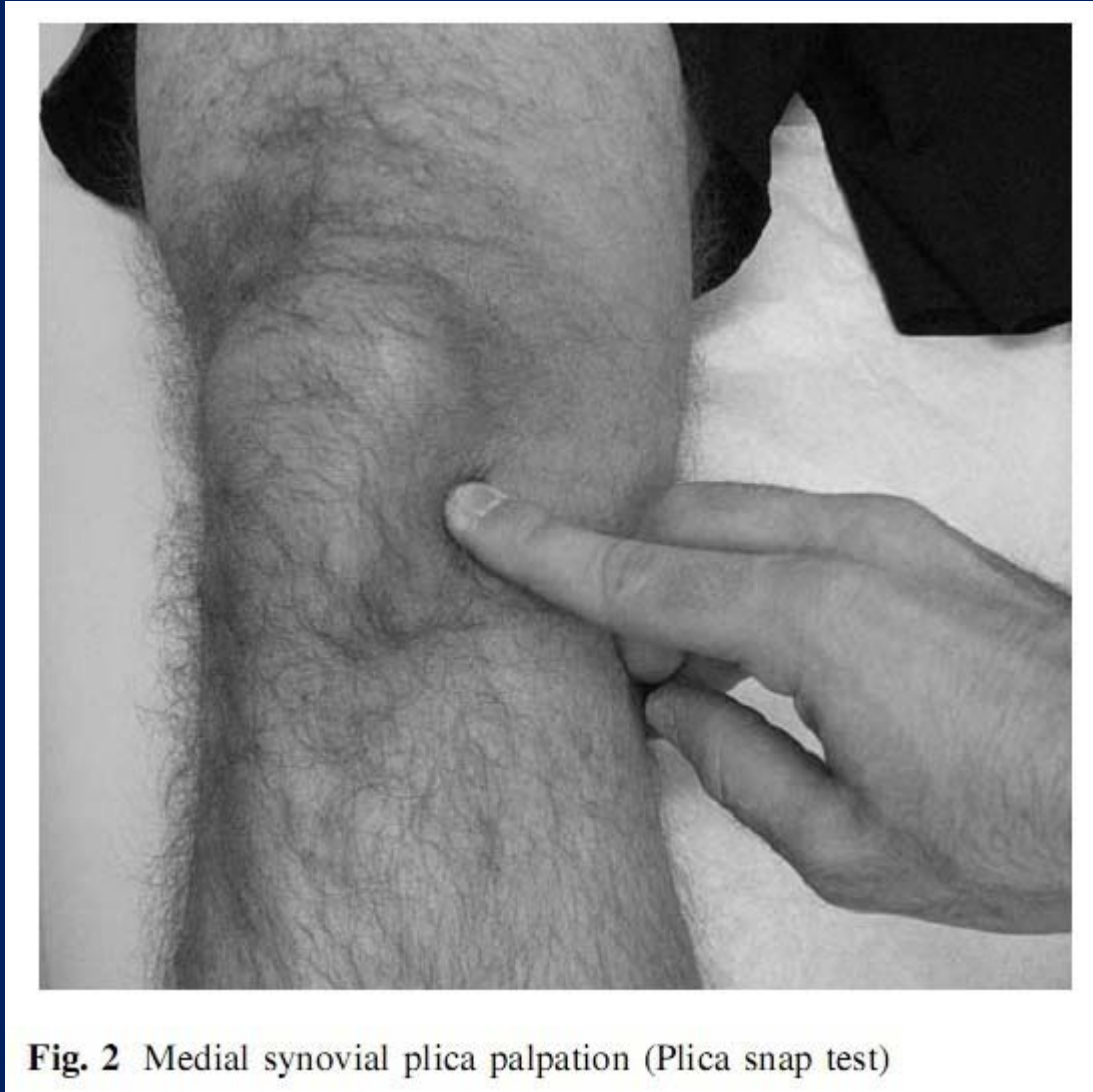
# Plica Syndrome: Medial patellar plica

- Clinical history of medial plica syndrome<sup>18</sup>:
  - Usually teenagers to young adults
  - Dull, achy, pain that increases with activity
    - Worse when going up or down stairs, squatting or bending, rising from chair after sitting
  - Pain localizes to proximomedial aspect of the knee
  - Some will give history of recent trauma
  - 50% give history of repetitive strenuous activity
  - Plica may catch and product a “pseudo-locking” event
  - Symptoms mimic a torn medial meniscus, arthritis, OCD, or other internal derangement

# Plica Syndrome: Medial patellar plica

- Diagnosis:
  - Physical examination<sup>18</sup>:
    - Palpation between medial border of patella and adductor tubercle reproduces patients symptoms
      - Plica is rolled under the examiner's fingers
      - Ribbon-like fold is palpated
    - Many other provocative tests have been developed

# Plica Syndrome: Medial patellar plica



**Fig. 2** Medial synovial plica palpation (Plica snap test)

# Plica Syndrome: Medial patellar plica

- Diagnosis:
  - Imaging:
    - The main purpose of imaging is to rule out other sources of pathology not to diagnose plica syndrome<sup>18</sup>
    - Radiographs of the knee are obtained to rule out osseous sources of pain (OCD, OA, fractures, etc.)<sup>18</sup>

# Plica Syndrome: Medial patellar plica

- Diagnosis:
  - Imaging
    - MRI
      - MR findings are non-specific<sup>18</sup>
      - No correlation between MR findings and arthroscopic classification systems<sup>19</sup>
      - No correlation between MR findings and probability of resection at time of arthroscopy<sup>19</sup>
      - No significant correlation between preoperative MR imaging and arthroscopic findings<sup>19</sup>

# Plica Syndrome: Medial patellar plica

- Diagnosis:
  - Imaging:
    - MRI
      - A normal MR does not rule out the presence of a medial plica<sup>19</sup>
        - » Sensitivity lower if minimal joint fluid is present
      - Most authors agree that wider plica are more often symptomatic and demonstrate pathologic changes at histology<sup>1</sup>
        - » Most asymptomatic plica are 1-2 mm in thickness
        - » Most symptomatic plica are over 2 mm and may even reach 1 cm in size
        - » However, no absolute thickness can distinguish them<sup>8</sup>
      - MR may show chondral abnormalities on the medial patellar facet or medial femoral condyle associated with the plica
      - MR is excellent at ruling out other internal derangements that may cause the patient's symptoms

# Plica Syndrome: Medial patellar plica

- Medial patellar plica with associated abnormal medial patellar facet cartilage

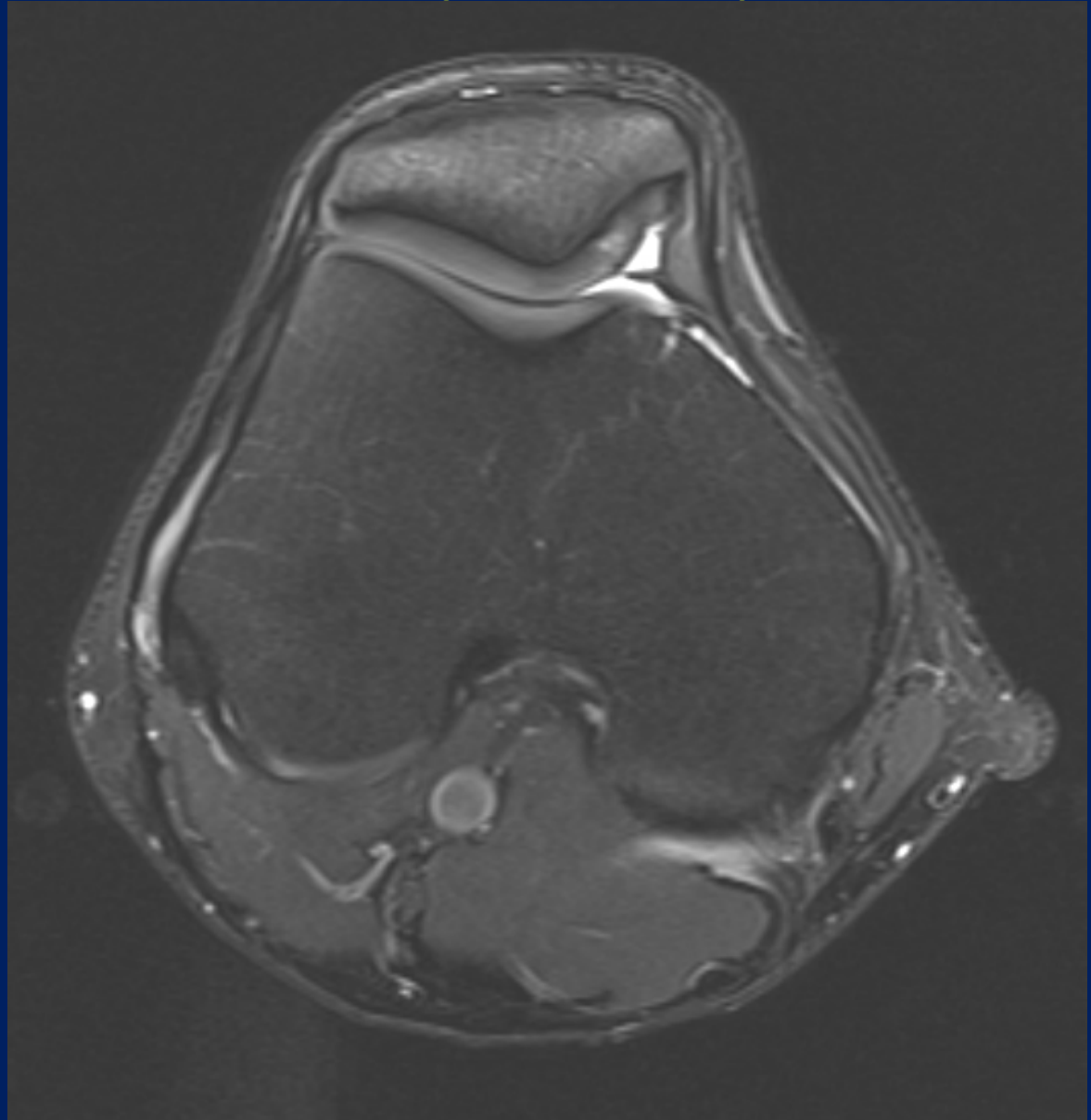
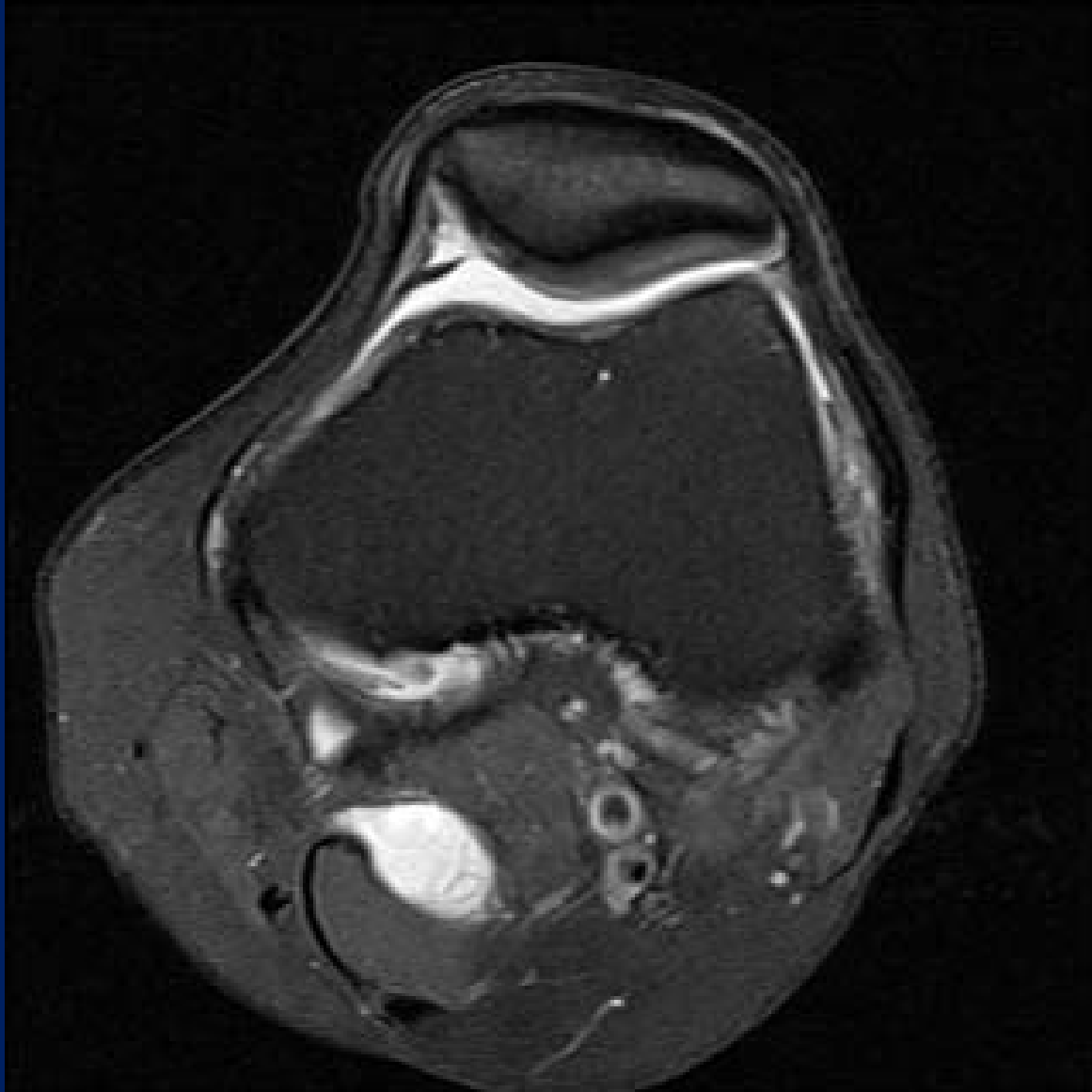


Image courtesy of Dr. T. Hughes

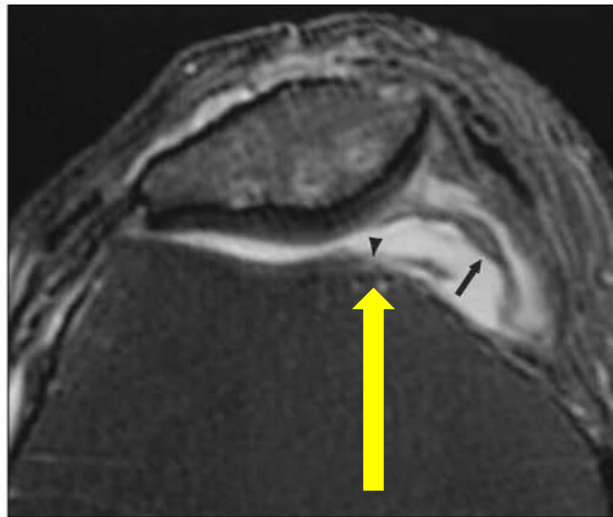
# Plica Syndrome: Medial patellar plica



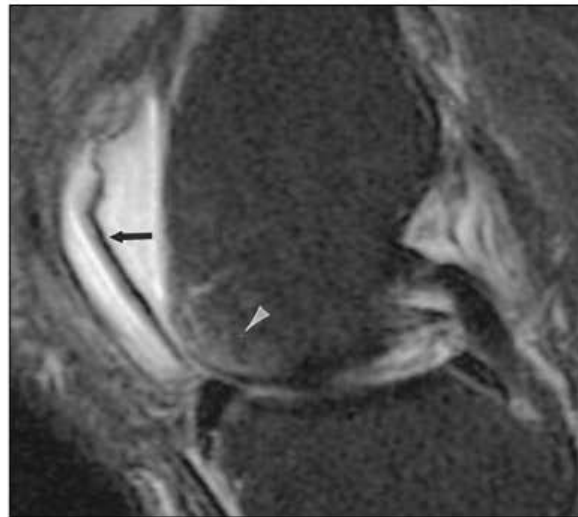


# Plica Syndrome: Medial patellar plica

- Medial patellar plica demonstrating abnormal cartilage of the medial femoral trochlea



A



B

Fig. 13.—Middle-aged man with knee pain. A, Axial fat-suppressed T2-weighted MR image of cord-like medial plica adjacent to medial facet of patella (*arrow*). Cartilage irregularity and signal changes in adjacent subchondral trochlea are present (*arrowhead*). B, Sagittal fat-suppressed T2-weighted MR image of cord-like medial plica (*arrow*). Note signal changes in adjacent subchondral medial femoral condyle (*arrowhead*). Figure 8D is corresponding arthroscopic image.

# Plica Syndrome: Medial patellar plica

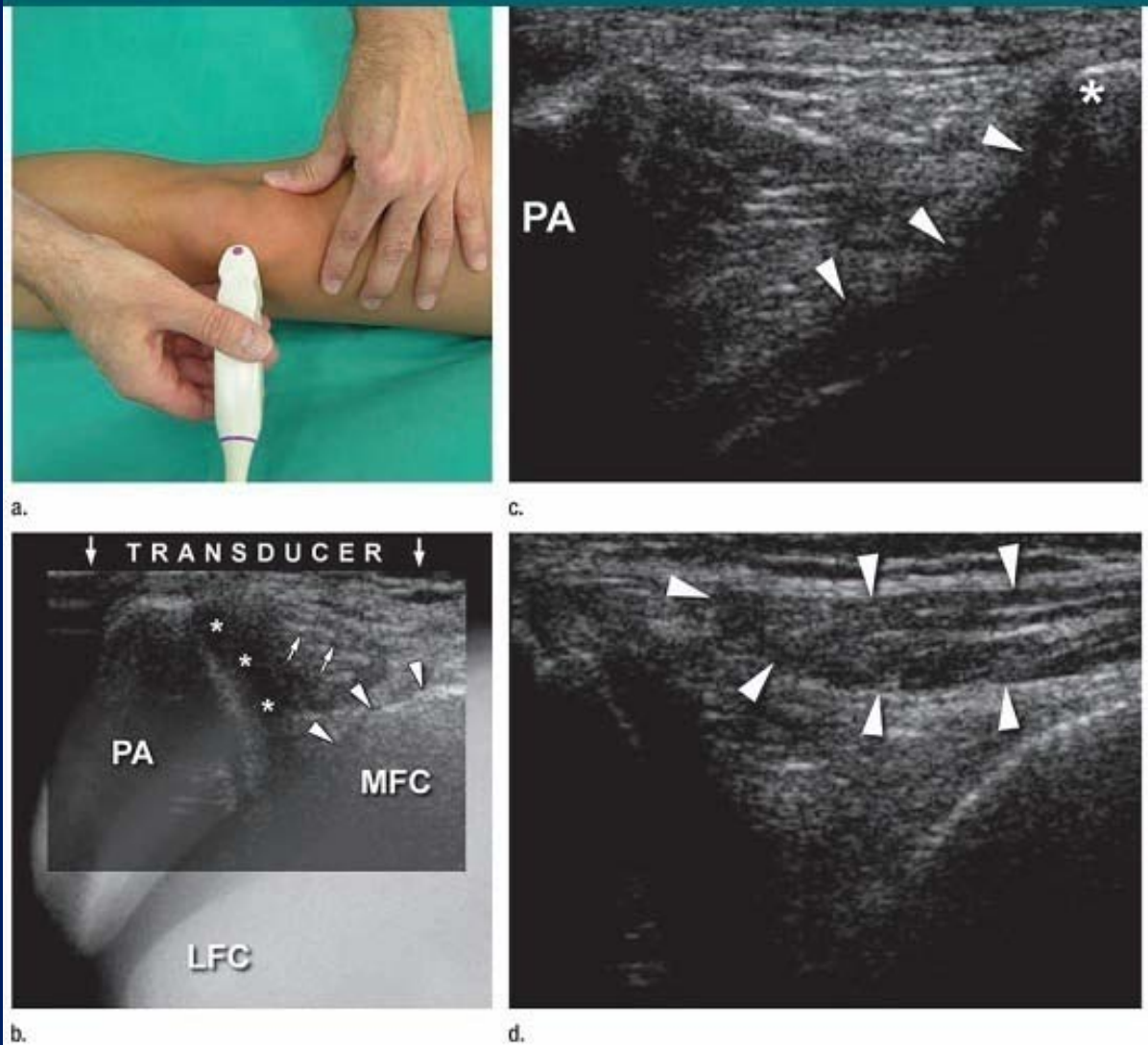
- Diagnosis
  - Dynamic Sonography<sup>27</sup>
    - Paczesny and Kruczynski Radiology 2009
    - Feasibility study of dynamic sonography for diagnosis of medial plica syndrome of the knee
    - Arthroscopy used as gold standard
    - Three sonographic criteria:
      - Continuous echo sliding over the medial femoral condyle during medial and lateral movement of the patella
      - Entry of the echo under the patella during medial movement of the patella
      - Pain or discomfort during dynamic sonography

# Plica Syndrome: Medial patellar plica

- Diagnosis
  - Dynamic Sonography<sup>27</sup>
    - If all three criteria met:
      - Diagnostic accuracy 88%
      - Sensitivity 90%
      - Specificity 83%

# Plica Syndrome: Medial patellar plica

- Transducer position
- Patella displaced toward transducer



Transducer too distal

Normal study superimposed over radiograph

Transducer too proximal

# Plica Syndrome: Medial patellar plica

Figure 2

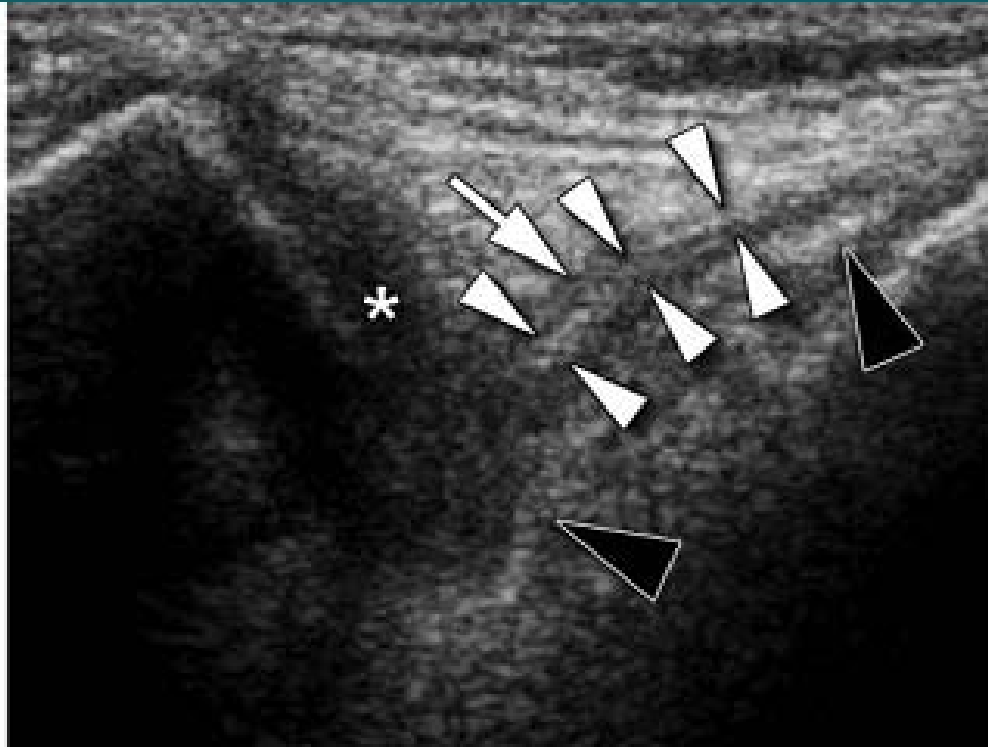


Figure 2: Sonogram of symptomatic right knee in 15-year-old female subject. Medial plica echo was defined as hyperechoic longitudinal zone (white arrowheads) sliding over anterior surface of medial femoral condyle (black arrowheads) toward hypoechoic patellar cartilage echo (\*) during dynamic examination. Thin hypoechoic border (arrow) of plica echo was seen. Dynamic sonographic test is shown in Movie 1 (<http://radiology.rsna.org/cgi/content/full/251/2081652/DC1>).

# Plica Syndrome: Medial patellar plica

- Treatment:
  - Initial treatments are non-operative<sup>18</sup>
    - Very good chance of improvement
    - Physical therapy
    - Quadriceps strengthening
    - Concurrent hamstring stretching
  - If improvement is slow or case is severe<sup>18</sup>
    - Intra-articular corticosteroid injection performed
  - If this fails → arthroscopic surgery
    - Complete resection is preferred over division<sup>18</sup>
      - Divided plica may grow back and symptoms may recur
    - Results are excellent in relieving pain especially in young adults<sup>19</sup>

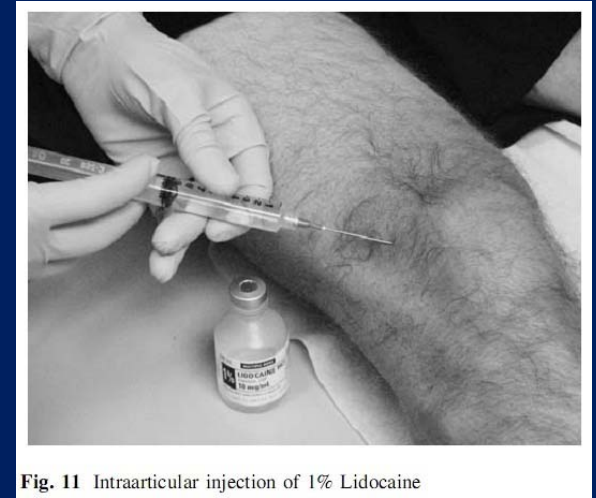
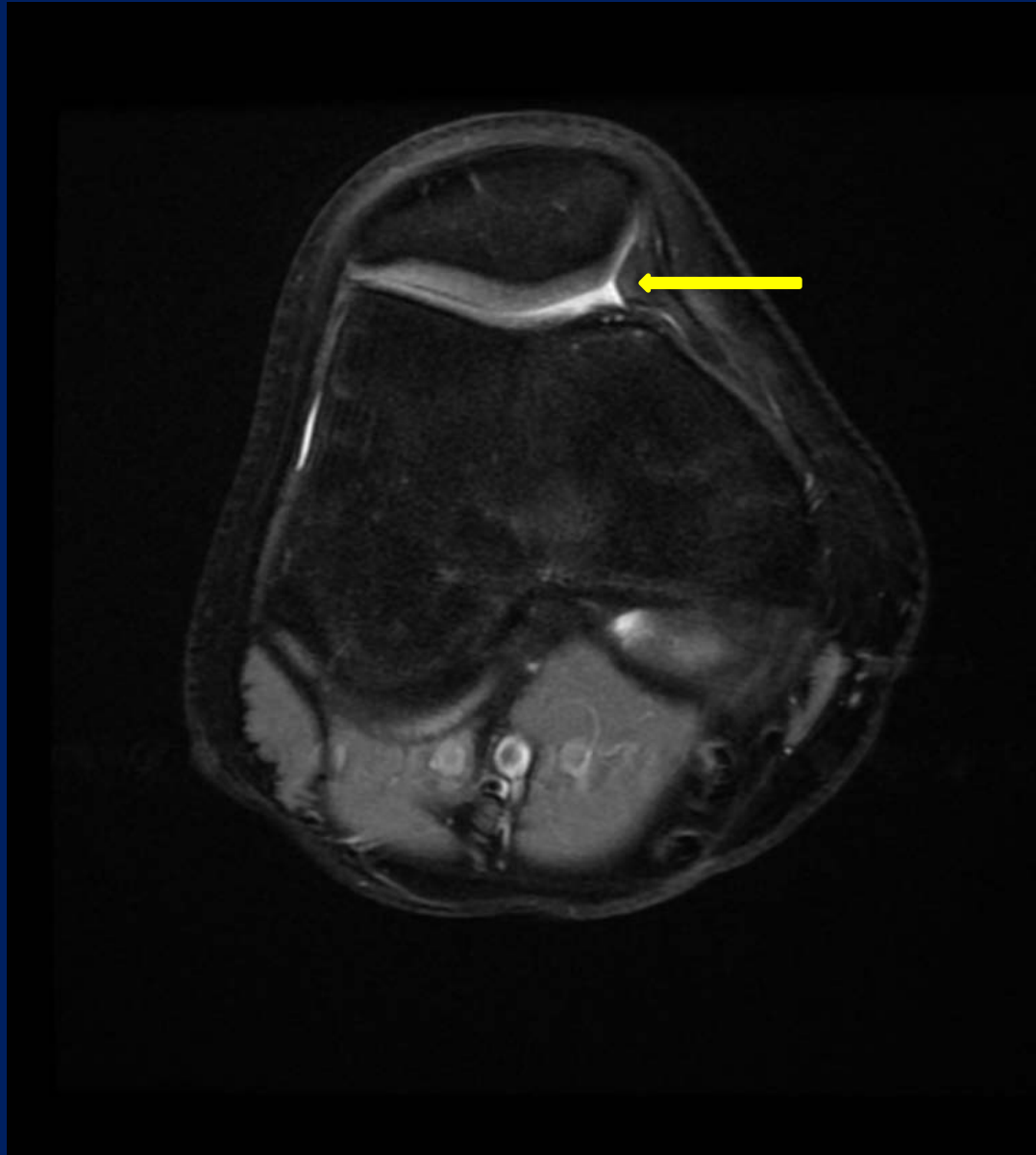
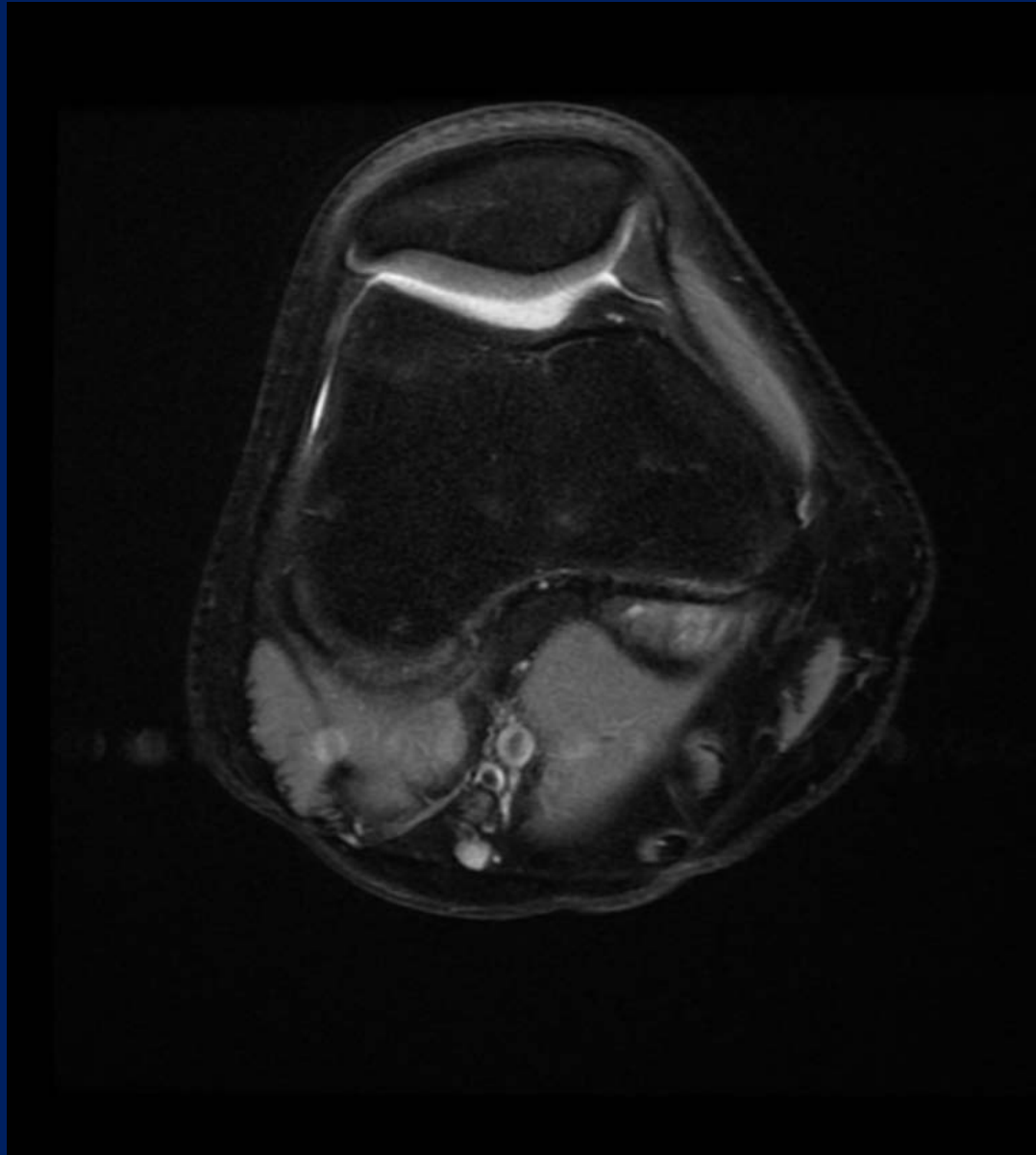


Fig. 11 Intraarticular injection of 1% Lidocaine

# Medial Plica Resection



# Medial Plica Resection





# Plica Syndrome: Medial patellar plica

- Bucket handle tear of the medial patellar plica

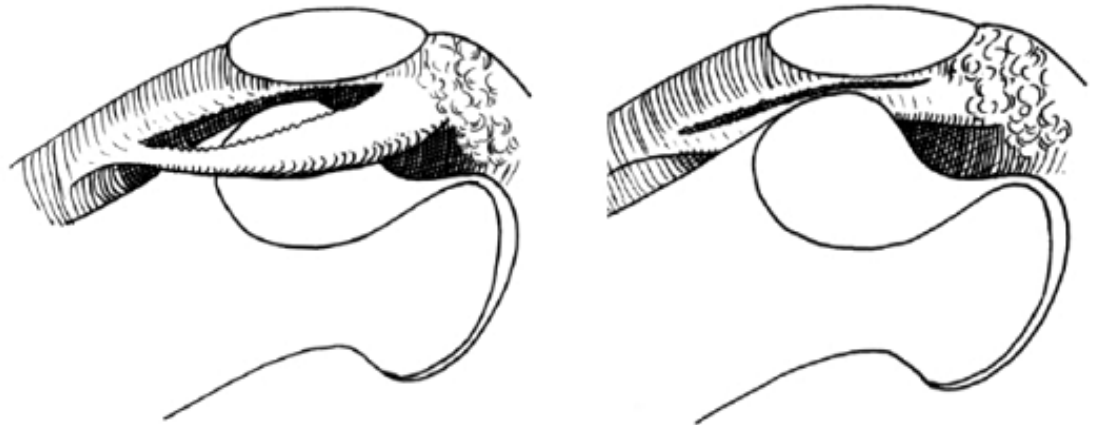
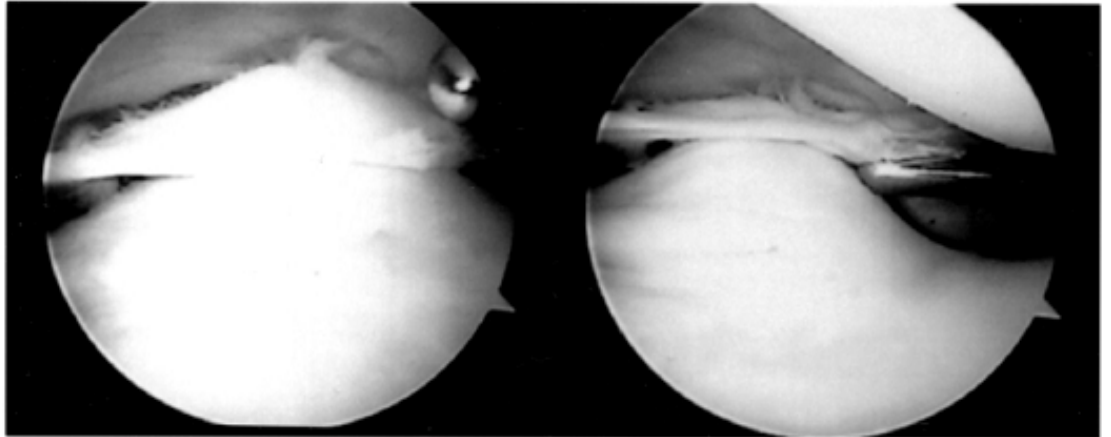


Fig. 1. Arthroscopic views from a superolateral portal show the torn medial plica caught in the trochlea on the left, and reduced on the right.

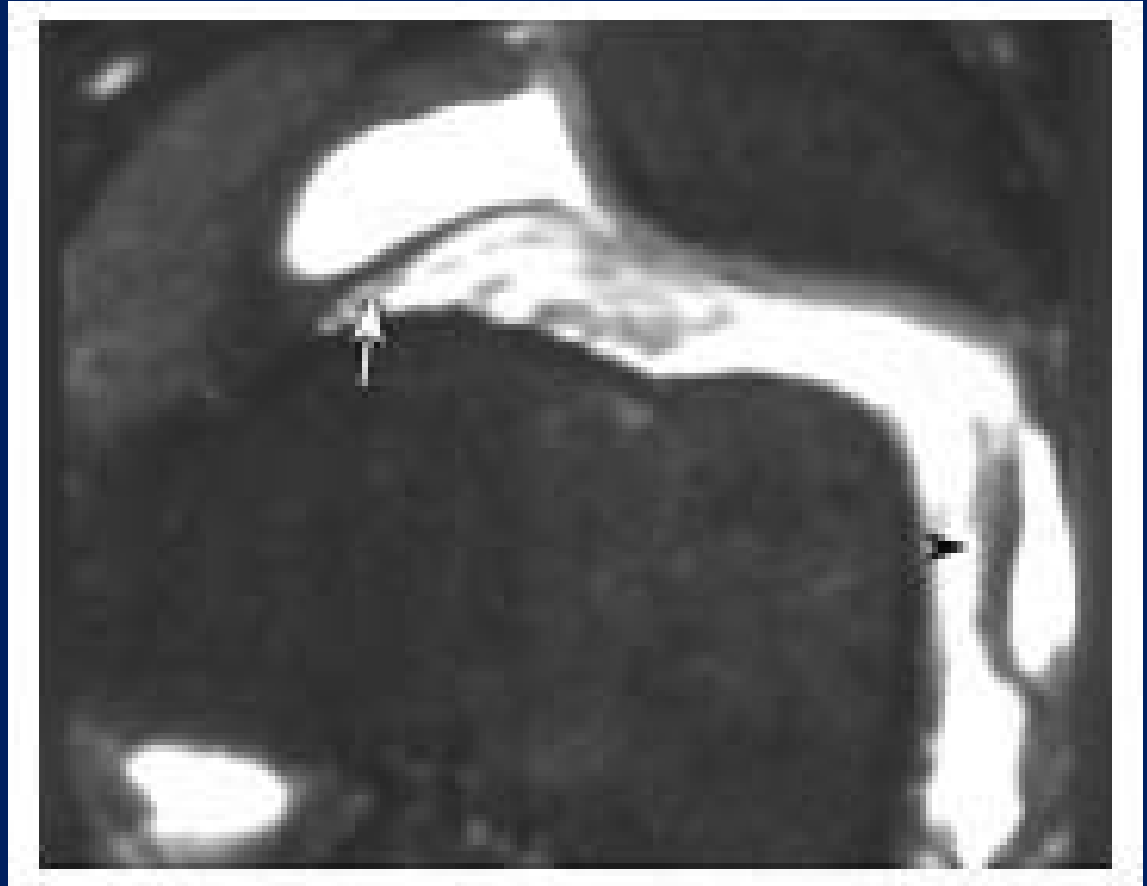
# Plica Syndrome: Lateral patellar plica

# Plica Syndrome: Lateral patellar plica

- Essentially same entity as medial plica syndrome except occurring on the lateral side of the knee
- Etiology, clinical presentation, and physical examination identical
- Role of imaging is the same
- Entity is rarer due to much reduced prevalence of the lateral plica

# Plica Syndrome: Lateral patellar plica

- Symptomatic lateral plica (arrowhead)
- Symptomatic medial plica present as well (arrow)



# In Review

- The suprapatellar and infrapatellar plicae are remnants of the septa that form during knee development
- The medial patellar and lateral patellar plica are formed from residual mesenchymal tissue
  - The medial plica is much more common than the lateral plica because of lateralization of the patella in the embryo

# In Review

- Many arthroscopic classifications for the plicae exist.
  - Imaging has not been shown to reliably classify plica
- Plicae are **normal structures** and their presence alone does not indicate a pathologic condition

# In Review

- Plica syndromes occur for two main reasons:
  - Inflammatory processes or trauma may thicken and stiffen a plica
    - May result in adjacent chondral injuries
    - Plica itself may become a source of pain
    - May mimic internal derangement of the knee
  - Failure of resorption of plica can lead to joint compartmentalization
    - Suprapatellar and infrapatellar plica
- Imaging cannot reliably diagnose medial patellar plica syndrome

# In Review

- It is important for radiologists to:
  - State if a plica is demonstrated on imaging
  - Give the thickness and length of the plica
  - Document any associated chondral abnormalities
  - Document the presence of a complete plica
    - Suprapatellar or infrapatellar plica
  - **Rule out other mimics of plica syndromes**
    - Meniscal tears, chondral injuries etc.



# References

- 1. Garcia-Valtuille R, Abascal F, Cerezal L, et al: Anatomy and MR Imaging Appearances of Synovial Plicae of the Knee. *Radiographics* 22: 775-784, 2002.
- 2. Dupont J: Synovial plicae of the knee: Controversies and Review. *Clin Sports Med* 16: 87-122, 1997.
- 3. Schindler O: Synovial plicae of the knee. *Current Orthopedics* 18: 210-219, 2004.
- 4. Dorfmann H, Orengo P, Amarenco G, et al: Pathologie des replis synoviaux du genou: interet de l'arthroscopie. *Rev Rhum* 49: 67-73, 1982.
- 5. Kent M, Khanduja V: Synovial plicae around the knee. *The Knee* 17: 97-102. 2010.
- 6. Ogata S, Uthoff H: The development of synovial plicae in human knee joints: An embryologic study. *Arthroscopy* 6: 315-321, 1990.
- 7. Deutsch A, Resnick D, Dalinka M, et al: Synovial plicae of the knee. *Radiology* 141: 627-634, 1981.

# References

- 8. Resnick D, Heung SK, Pretterklieber ML: Internal Derangements of Joints, 2<sup>nd</sup> Edition, Volume 2. Saunders Elsevier 2007. Pg. 1582-1586.
- 9. Kim S, Choe W: Arthroscopic Findings of the Synovial Plicae of the Knee. *Arthroscopy* 13: 33-41, 1997.
- 10. Boles CA, Martin DF: Synovial plicae in the knee: pictorial essay. *AJR* 177: 221-227, 2001.
- 11. Dupont J: Synovial plicae of the knee. *The Knee* 1: 5-19, 1994.
- 12. Strover AE, Rouholamin E, Guirguis N et al: An arthroscopic technique of demonstrating the pathomechanics of the suprapatellar plica. *Arthroscopy* 7:308-310, 1991.
- 13. Trout TE, Bock H, Resnick D: Suprapatellar plicae of the knee presenting as a soft-tissue mass report of five patients. *Clinical imaging* 20:55-59, 1996.
- 14. Ehlinger M, Moser T, Adam P et al: Complete suprapatellar plica presenting like a tumor. *Orthopaedics & Traumatology: Surgery & Research* 95:447-250, 2009.

# References

- 15. Adachi N, Ochi M, Uchio Y: The complete type of suprapatellar plica in a professional baseball pitcher: consideration of a cause of anterior knee pain. *Arthroscopy* 20: 987-991, 2004.
- 16. Kim S, Choe, W: Pathological infrapatellar plica: A report of two cases and literature review. *Arthroscopy* 12: 236-239, 1996.
- 17. Cothran RL, McGuire PM, Helms CA et al: MR imaging of infrapatellar plica injury. *AJR* 180: 1443-1447, 2003.
- 18. Griffith CJ, LaPrade RF: Medial plica irritation: diagnosis and treatment. *Curr Rev Musculoskelet Med* 1: 53-60, 2008.
- 19. Weckstrom M, Niva MH, Lamminen A et al: Arthroscopic resection of medial plica in the knee in young adults. *The Knee*: 17: 103-107, 2010.
- 20. Zidorn T: Classification of the suprapatellar septum considering ontogenetic development. *Arthroscopy* 8: 459-464, 1991.
- 21. Kosarek FJ and Helms CA: The MR appearance of the infrapatellar plica. *AJR* 172: 481-484, 1999.

# References

- 22. Soejima T, Murakami H, Tanaka N et al: Anteromedial menisconfemoral ligament. *Arthroscopy* 19: 90-95, 2003.
- 23. Farkas C, Hargitai Z, Gaspar L et al: Histological changes in the symptomatic mediopatellar plica. *The Knee* 11: 103-108, 2004.
- 24. Lyu S: Relationship of medial plica and medial femoral condyle during flexion. *Clinical Biomechanics* 22: 1013-1016, 2007.
- 25. Lyu S and Chia-Chen H: Medial plicae and degeneration of the medial femoral condyle. *Arthroscopy* 22: 17-26, 2006.
- 26. White SH: Bucket handle tear of medial plica. *The Knee* 9: 253-254, 2002.
- 27. Paczesny L and Kruczynski L: Medial plica syndrome of the knee: Diagnosis with Dynamic Sonography. *Radiology* 251: 439-446, 2009.
- 28. Gallagher J, Tierney P, Murray P et al: The infrapatellar fat pad: anatomy and clinical considerations. *Knee Surg Sports Traumatol Arthrosc* 13: 268-272.

# References

- 29. Saddik D, McNally EG, Richardson M: MRI of Hoffa's fat pad. *Skeletal Radiology* 33: 433-444, 2004.
- 30. Patel SJ, Kaplan PA, Dussault RG, Kahler, DM: Anatomy and clinical significance of the horizontal cleft in the infrapatellar fat pad of the knee: MR imaging. *AJR* 170: 1551-1555, 1998.