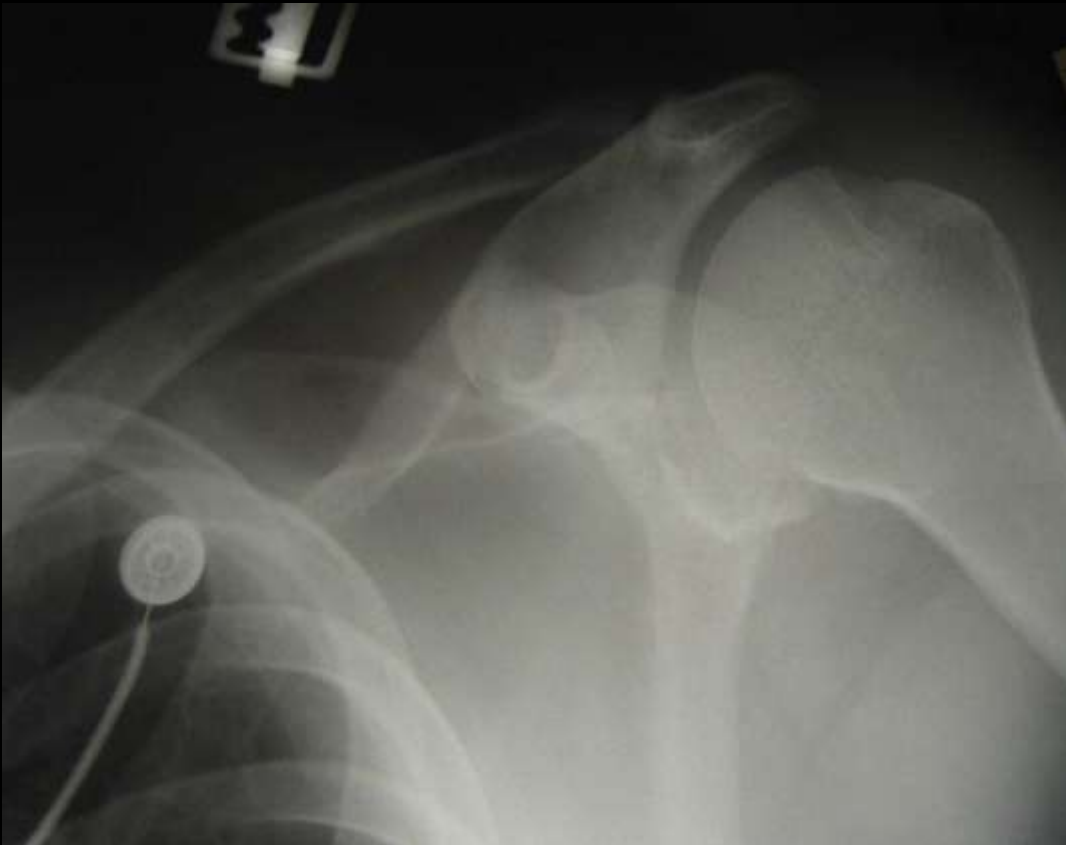
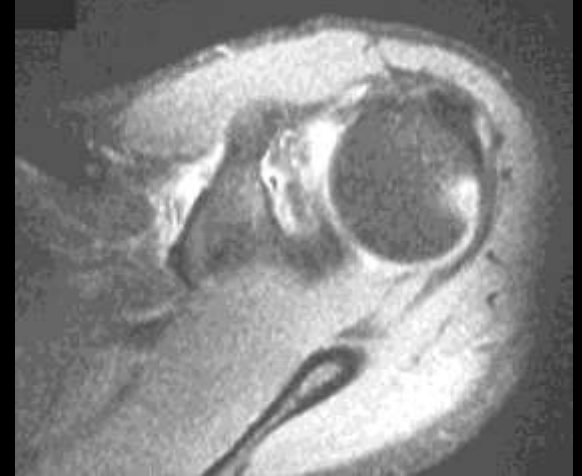
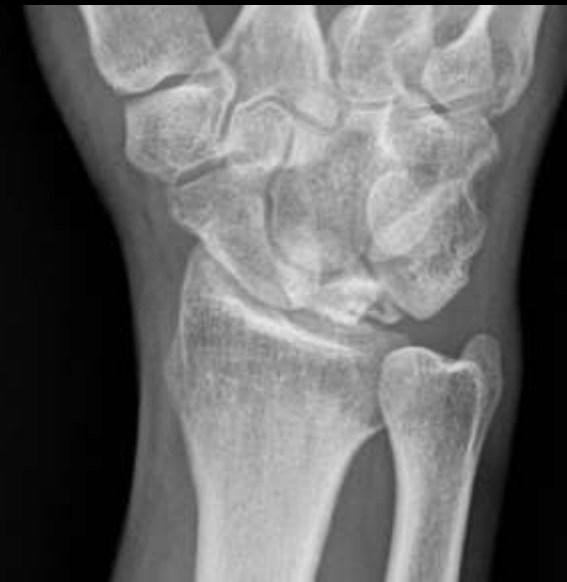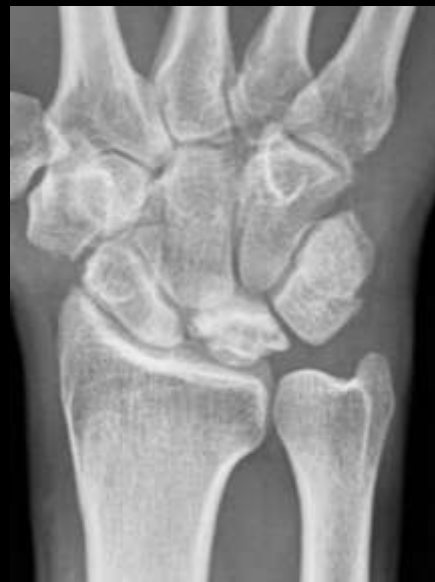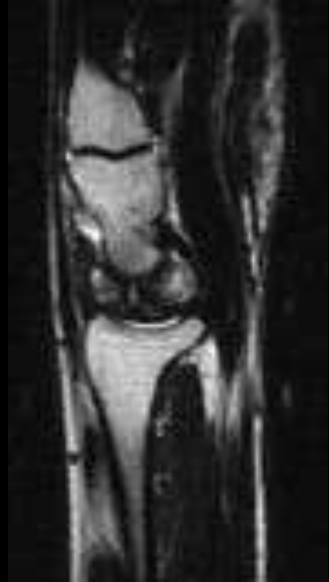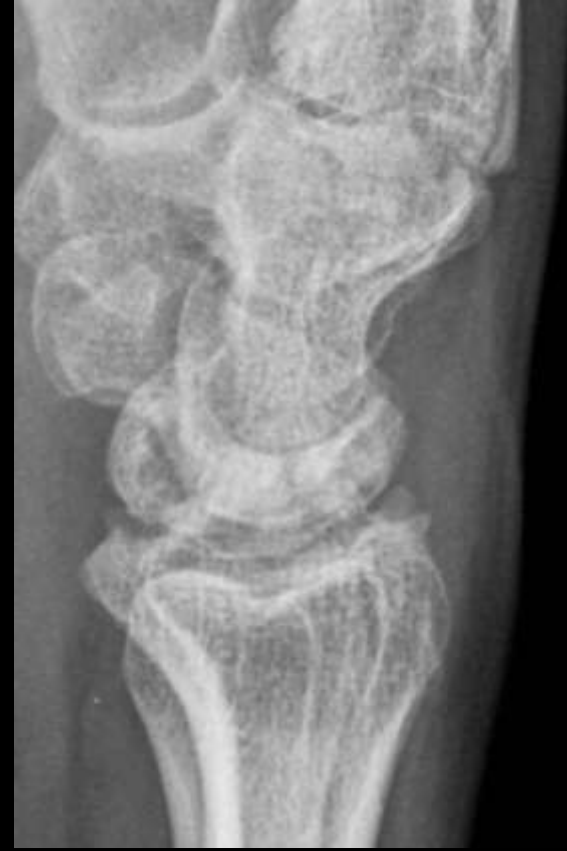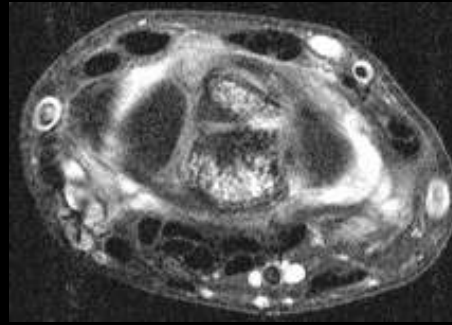


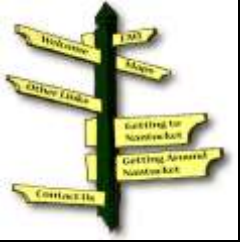Hatchet deformity Hill Sachs Anterior Dislocation



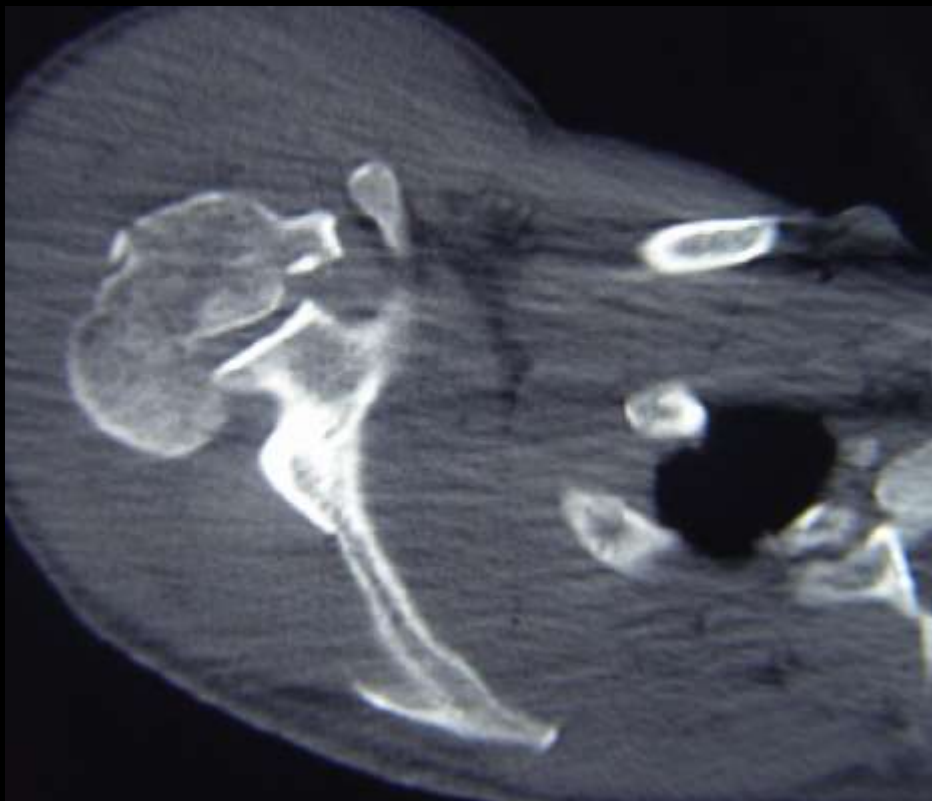


Broken canoe sign Kienbochs



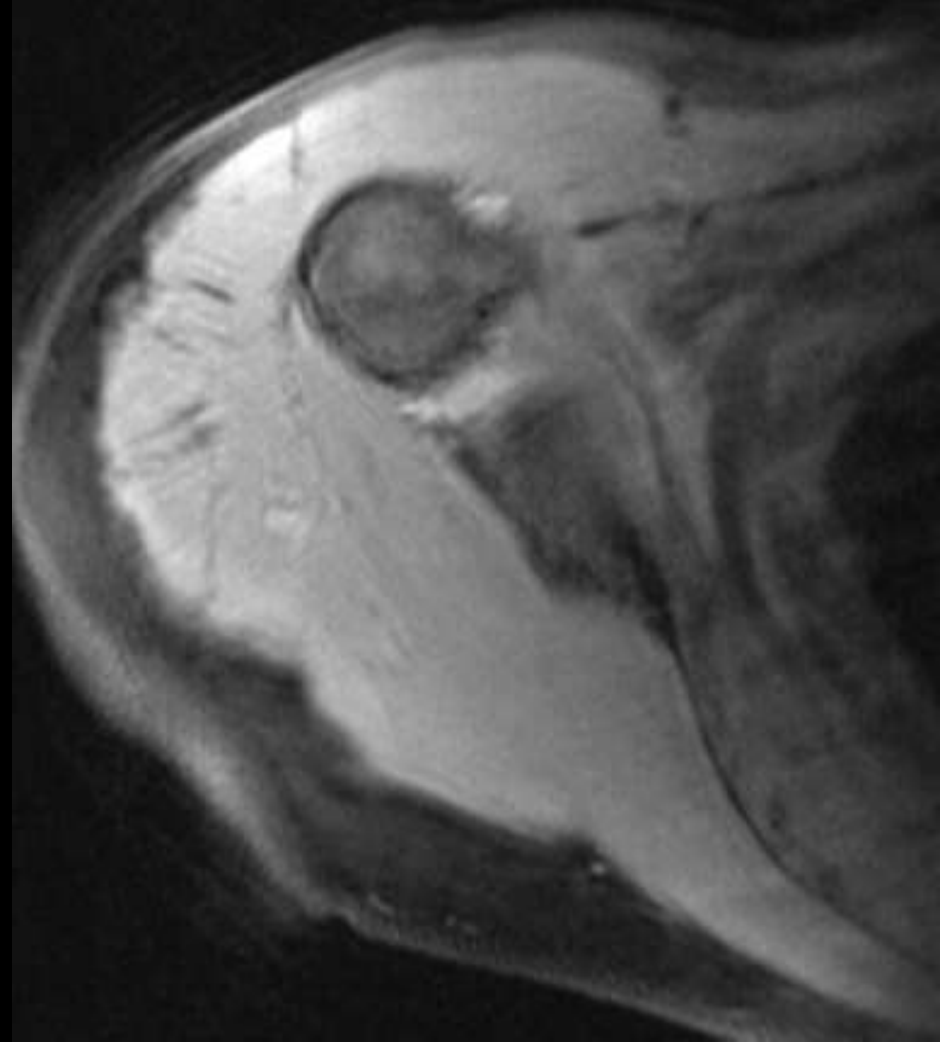
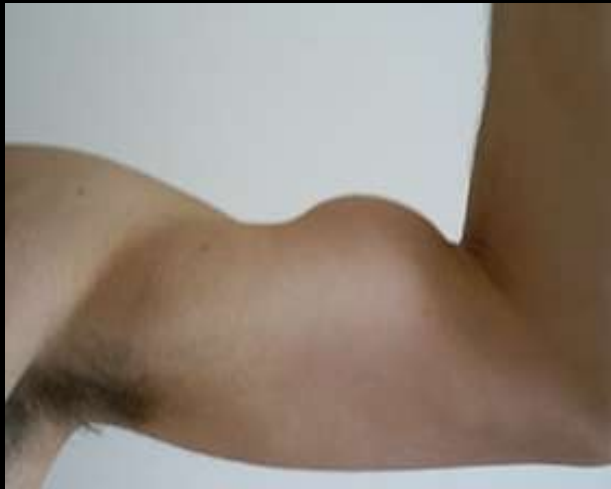

Trough Fracture Posterior Dislocation



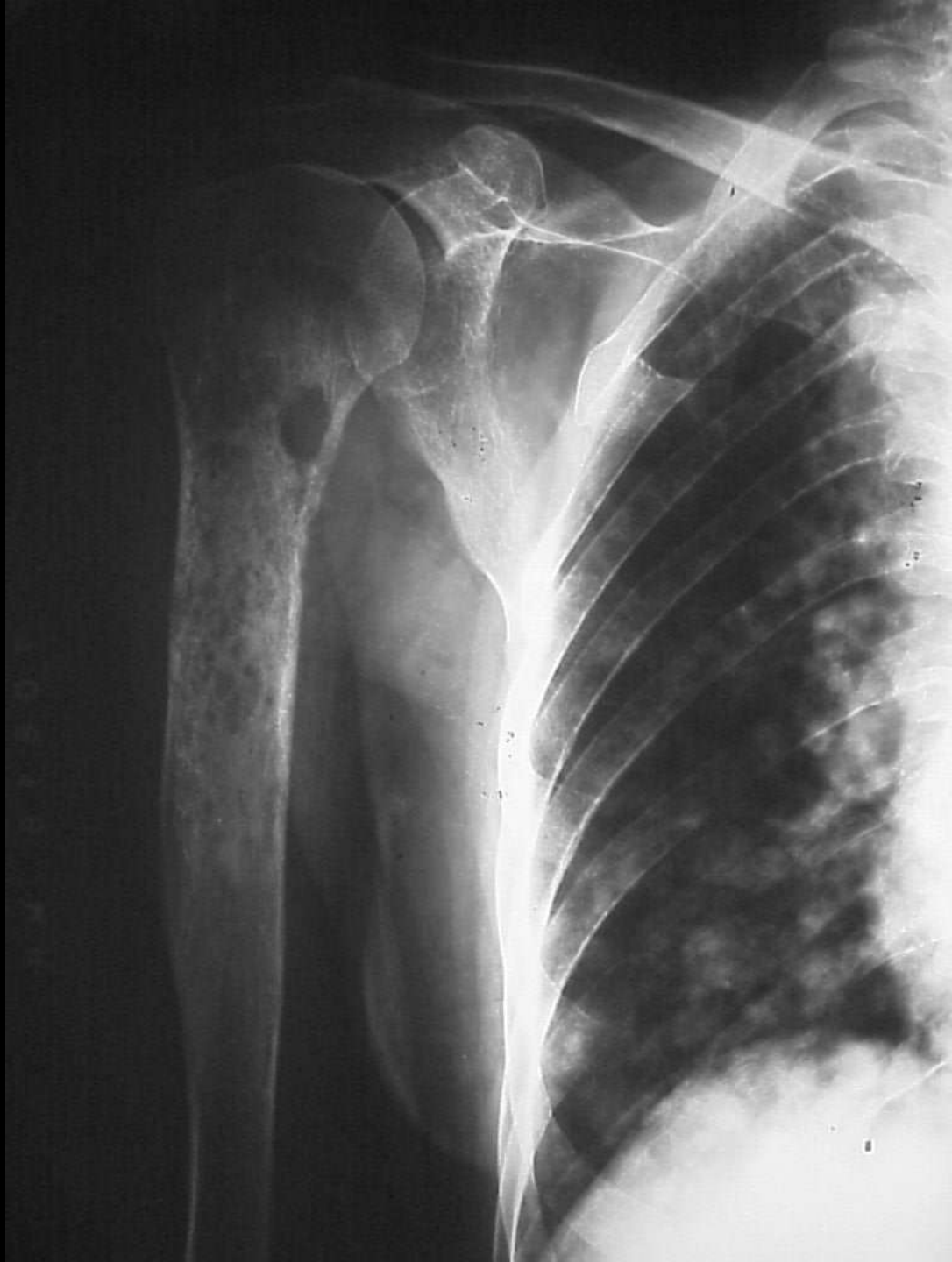

Popeye sign Torn long head of biceps



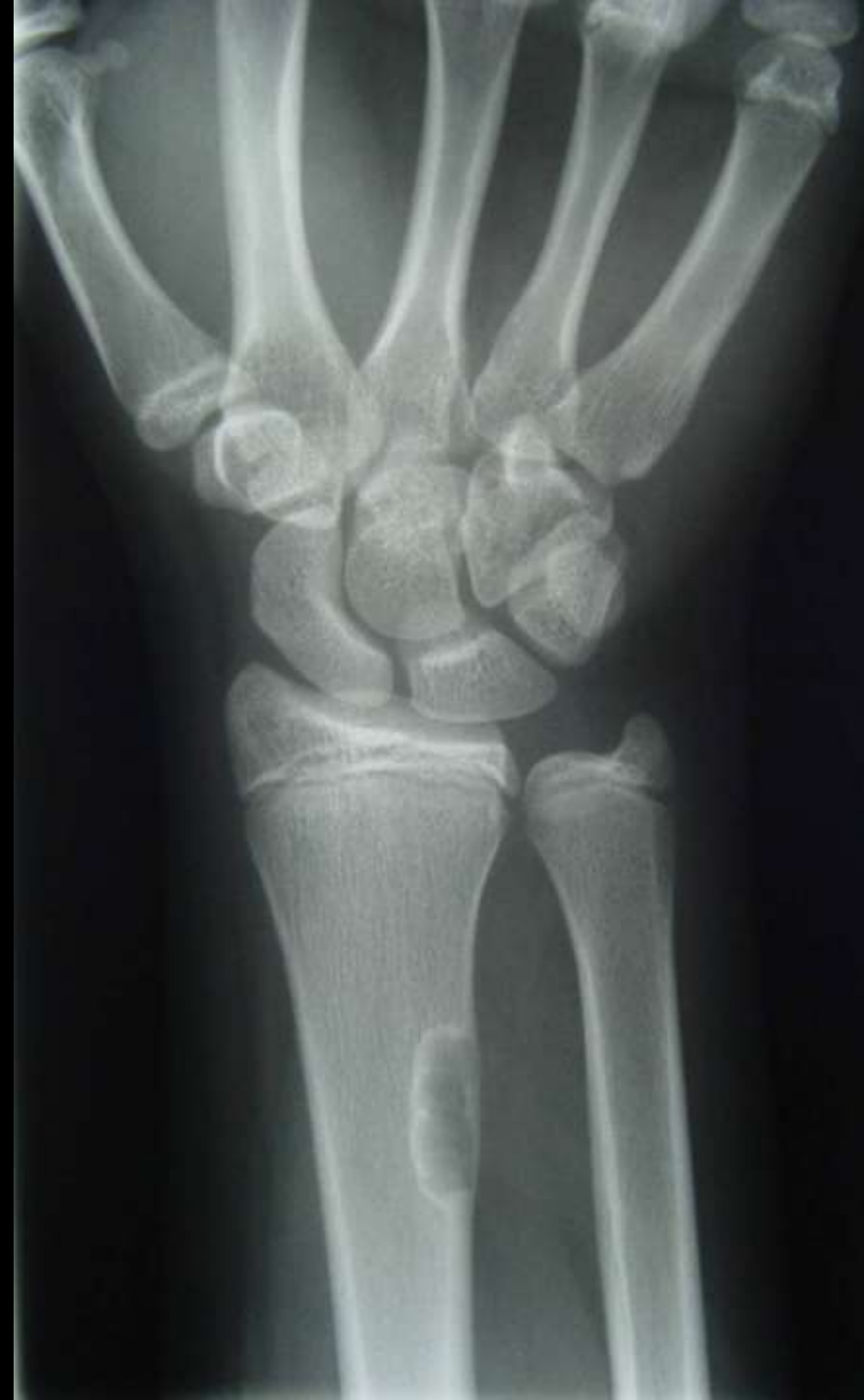
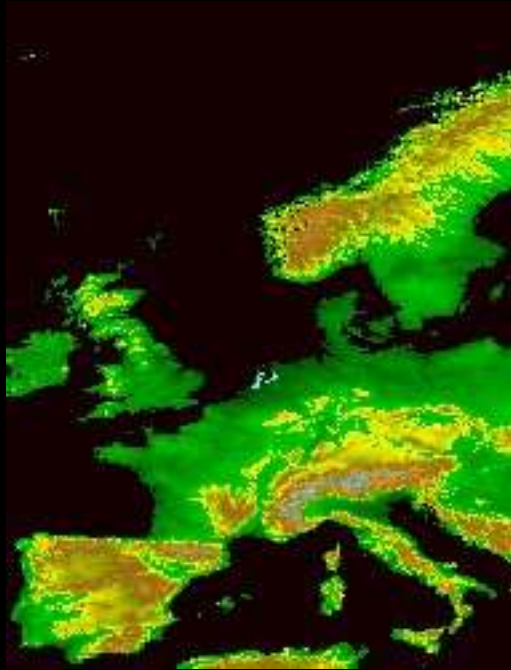
Moth eaten
Intermediate aggressive
Mets





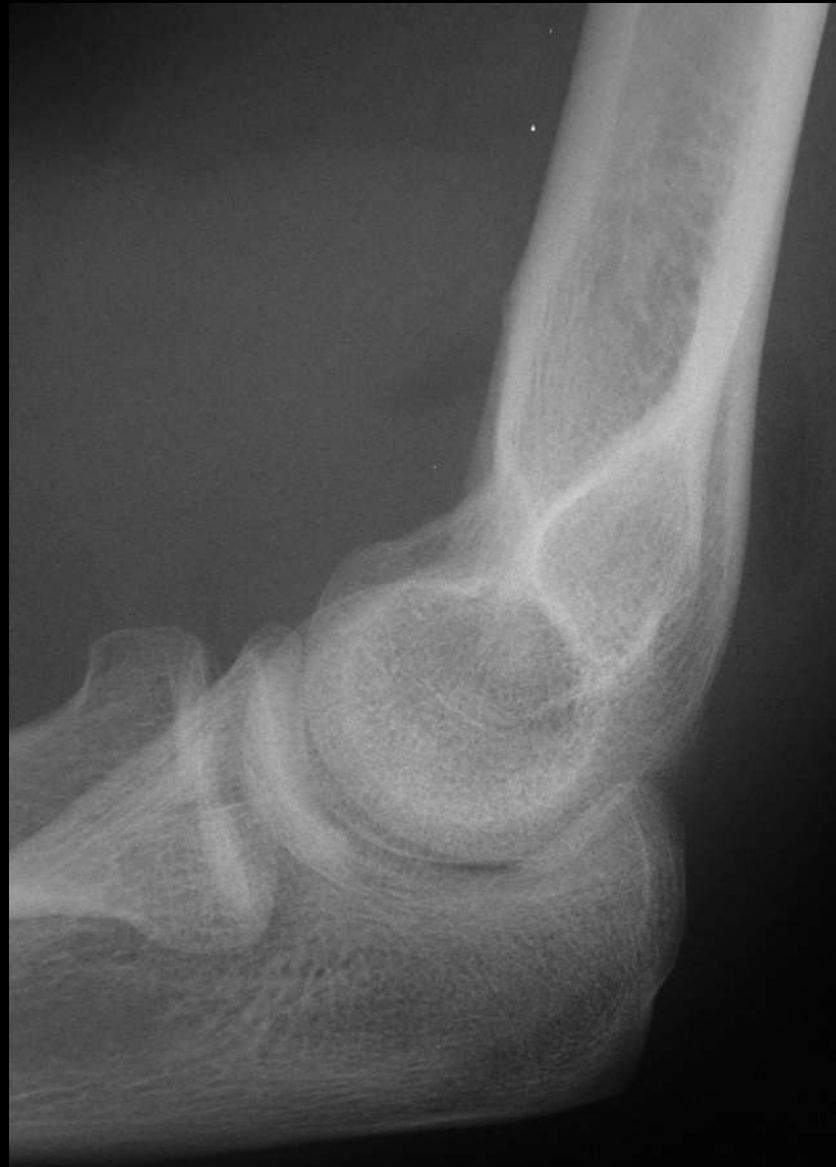Geographic Benign





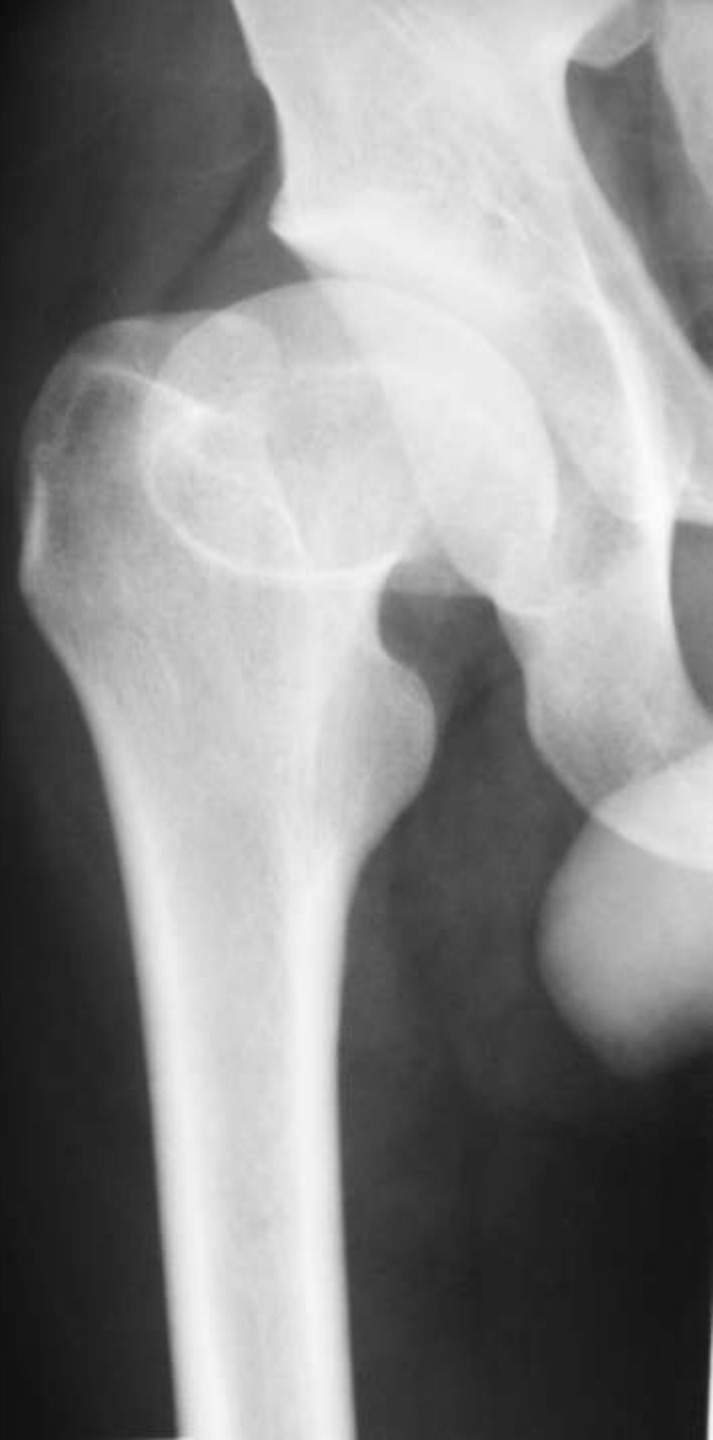Sail sign

Elbow effusion



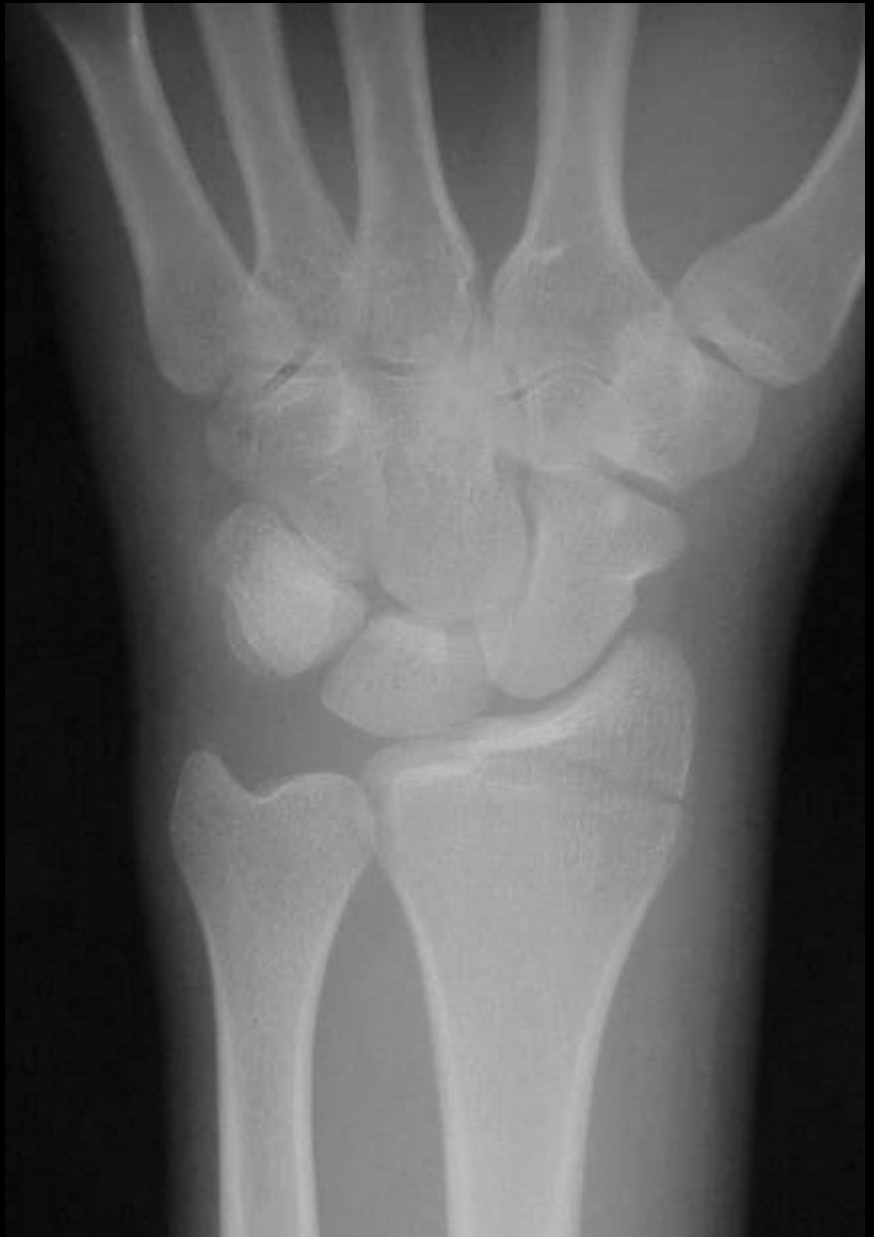

Sagging rope sign Legg Calve Perthes





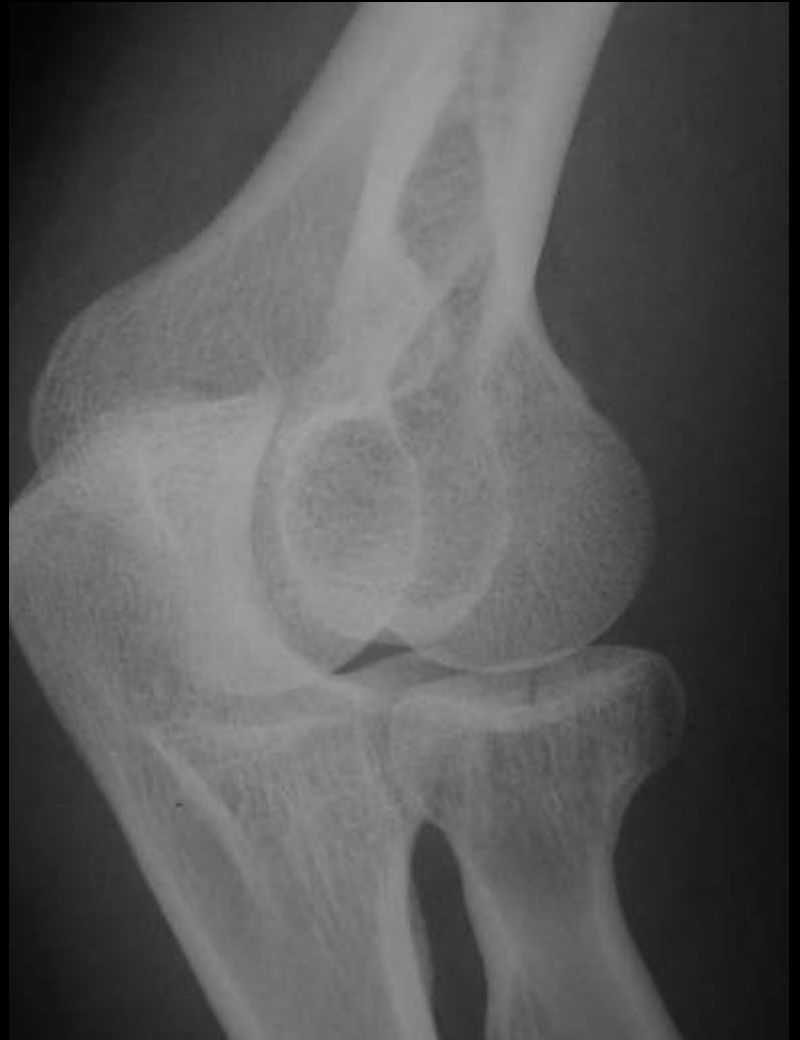Chauffeur fracture Radial styloid fracture

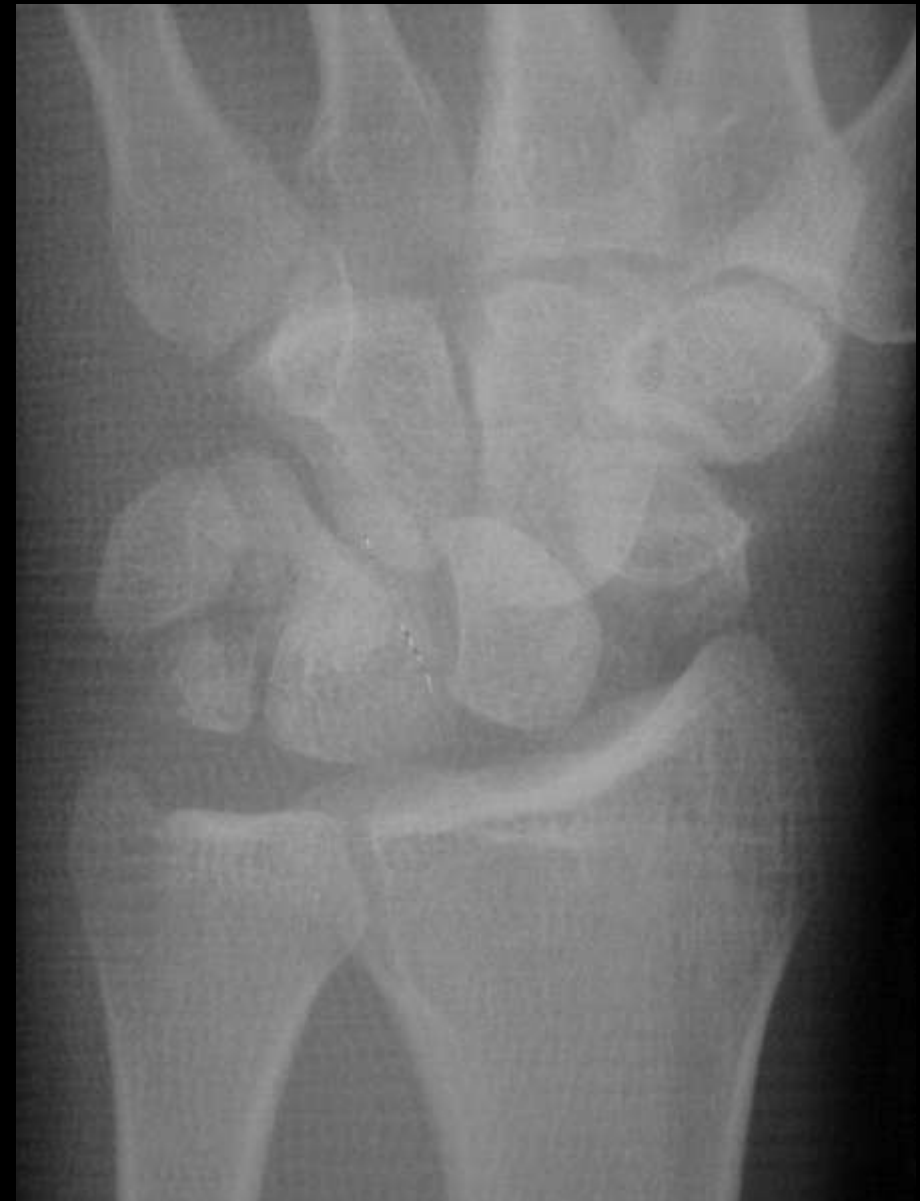
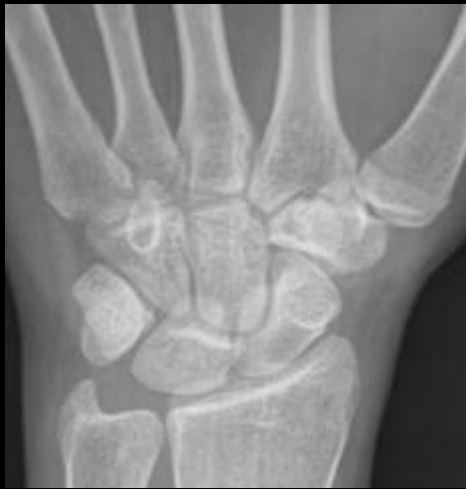


Chisel Fracture

Radial head fracture





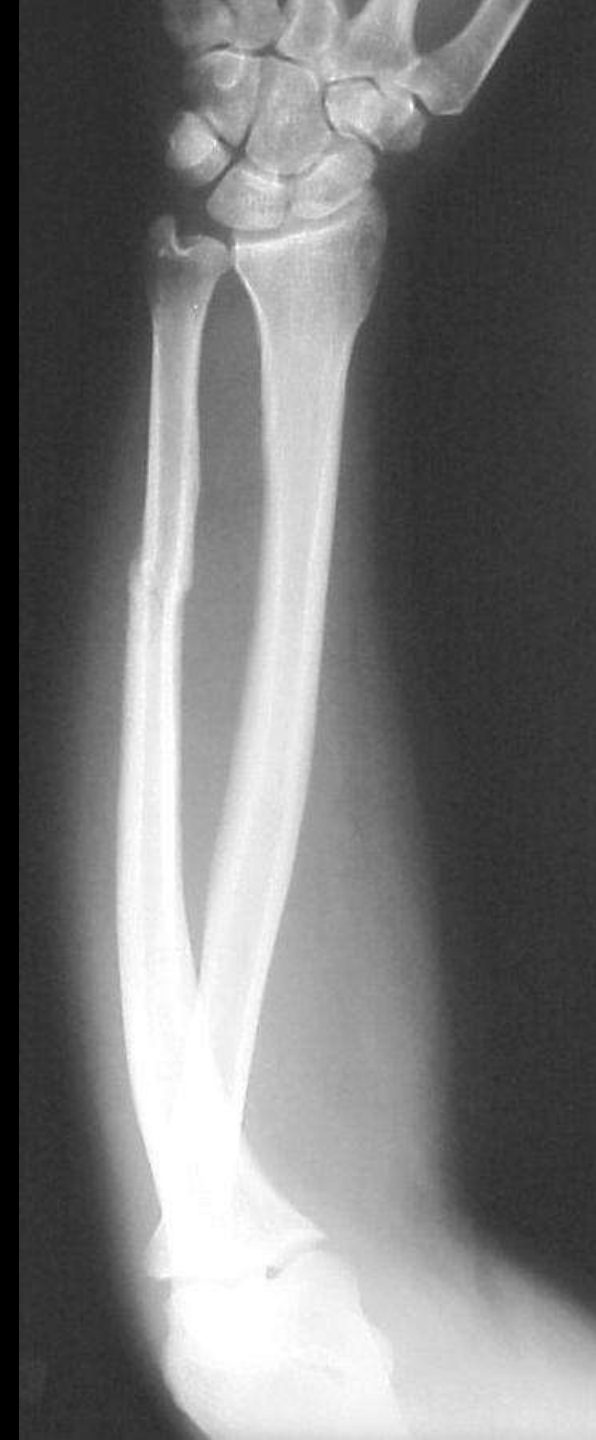Pie shaped lunate
Lunate subluxation





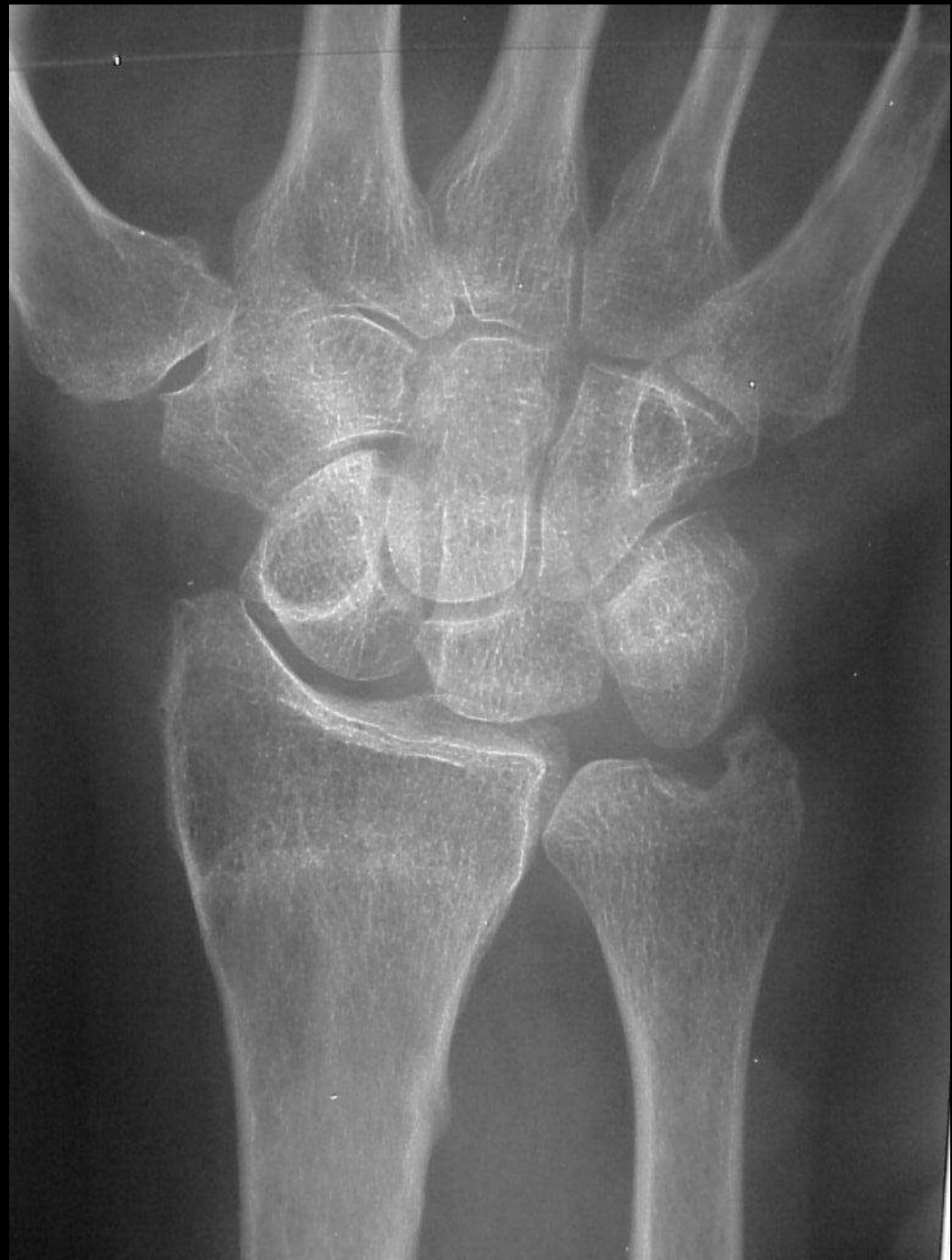Nightstick fracture

Direct trauma





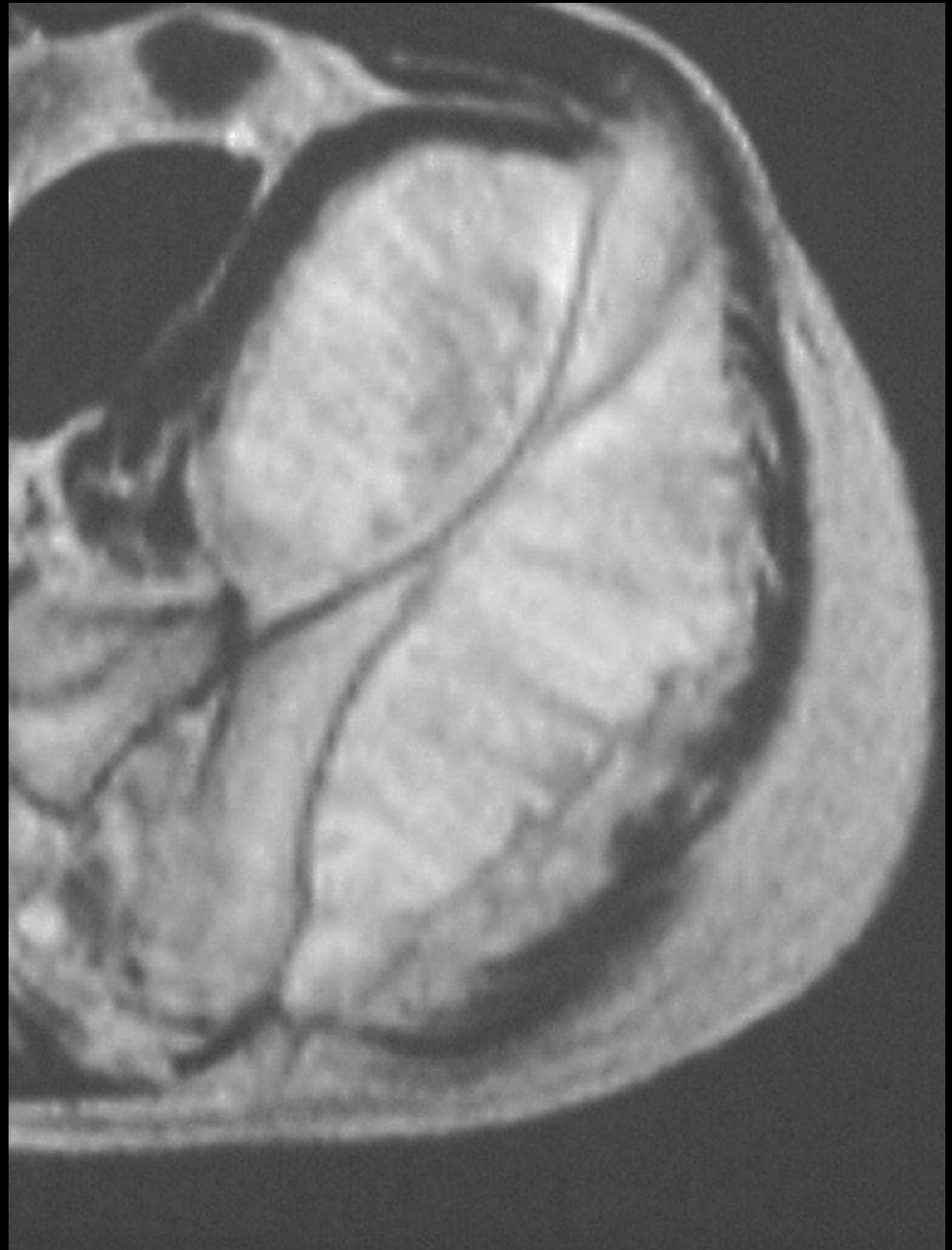Signet ring Scaphoid
Scaphoid seen near end on
Fx of waist
DISI





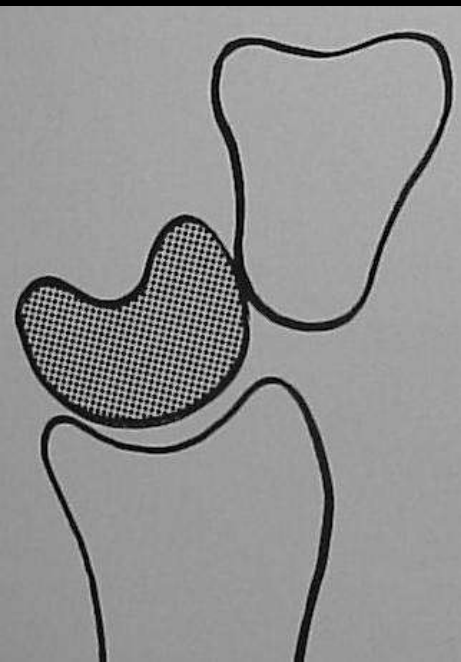
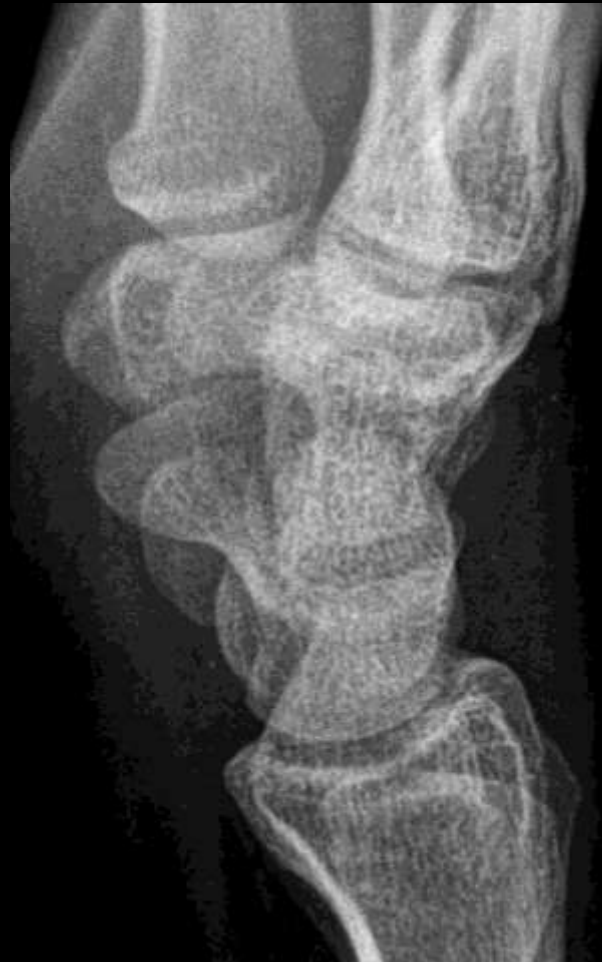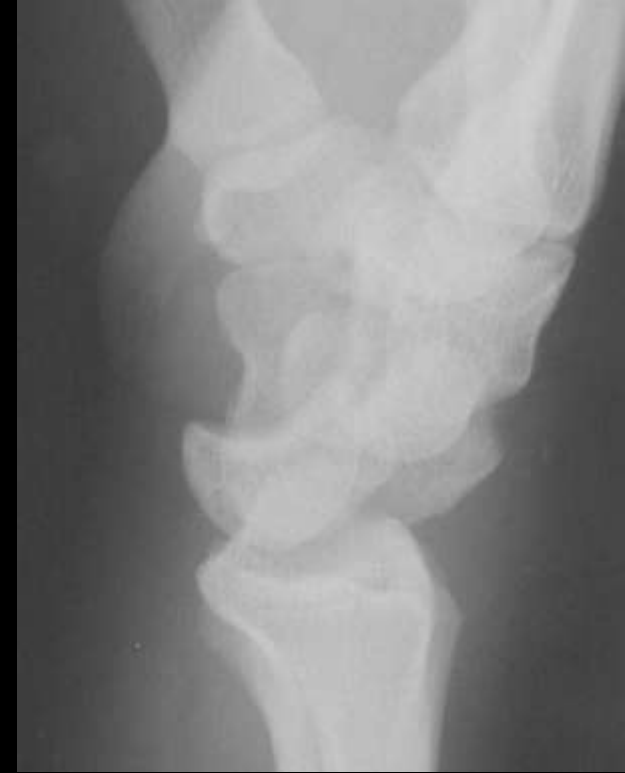Sunburst

Osteosarcoma





Spilt tea sign Perilunate dislocation

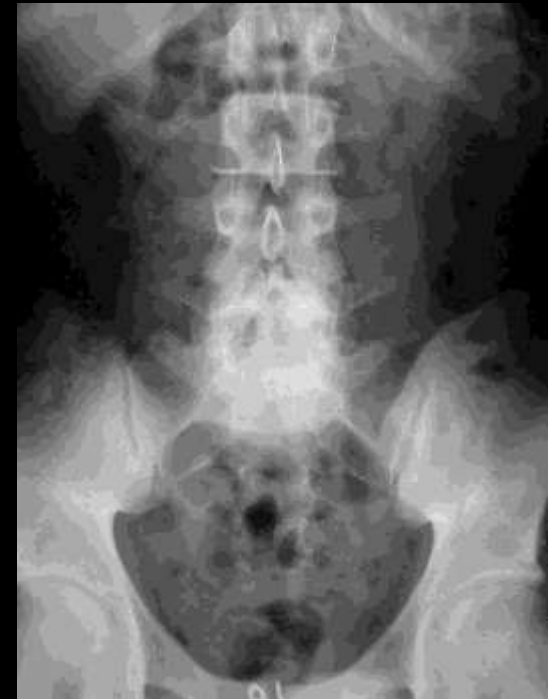
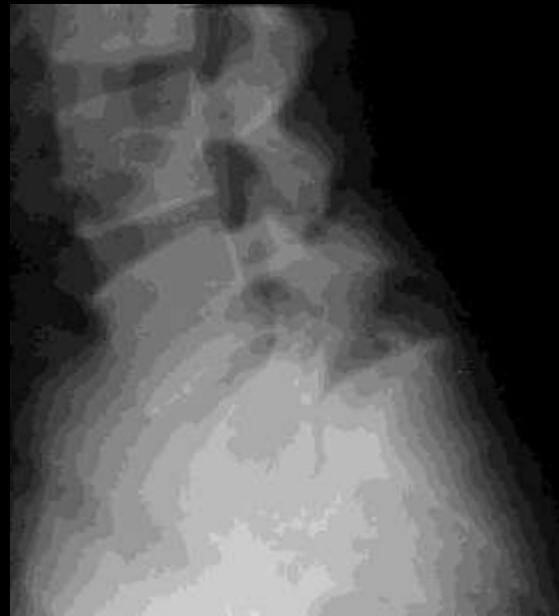
Spilt tea



Inverted Napoleon hat sign

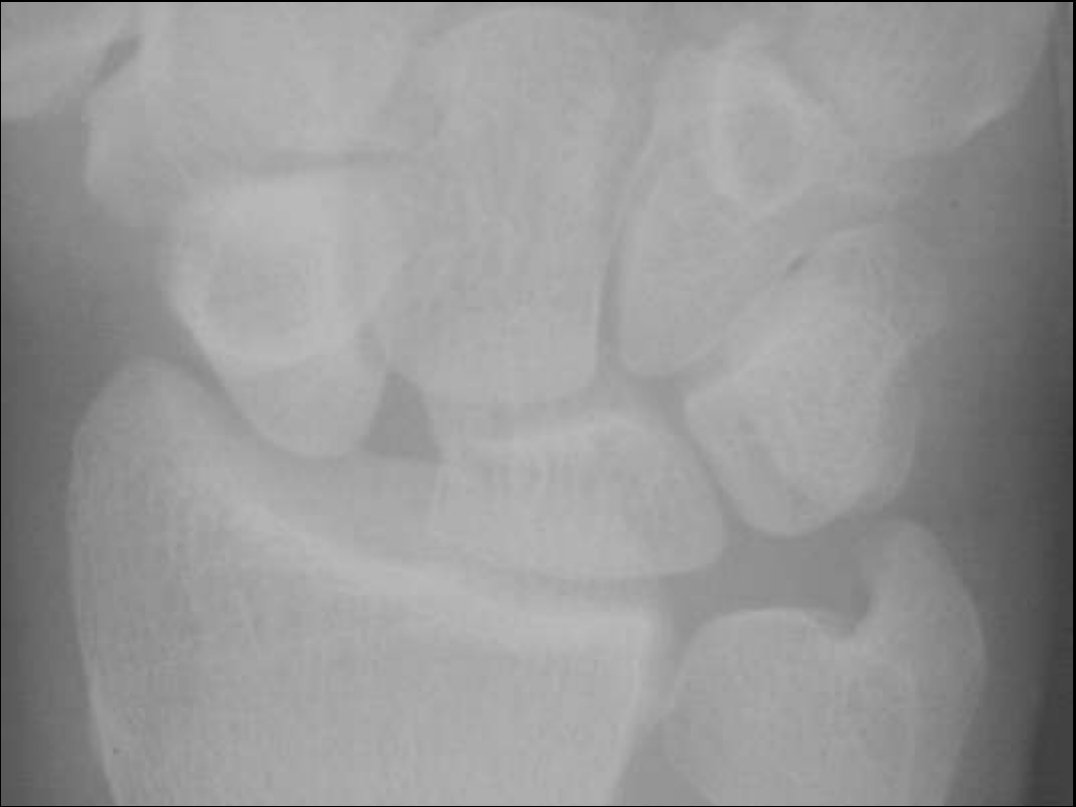
Spondylolisthesis





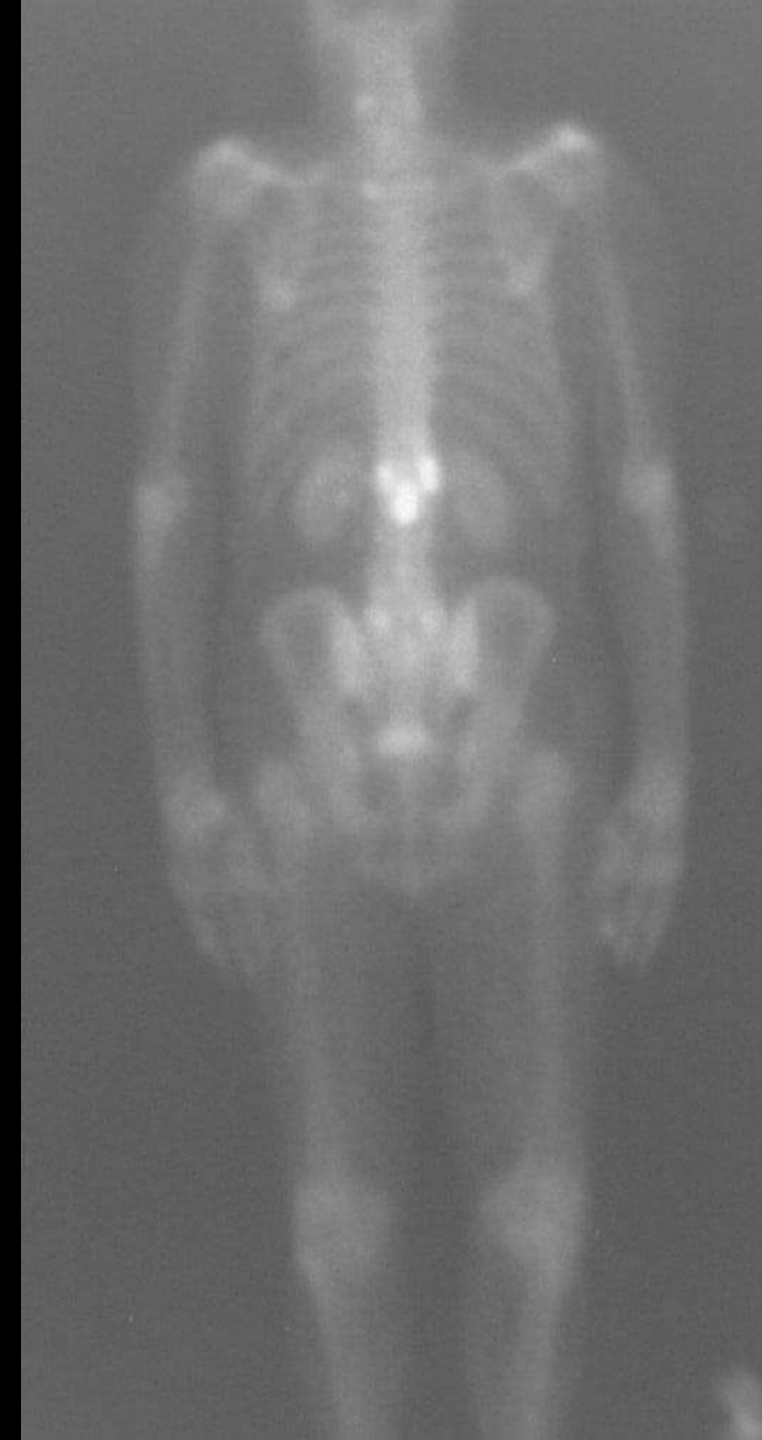
Terry Thomas sign

Scapholunate ligament
disruption



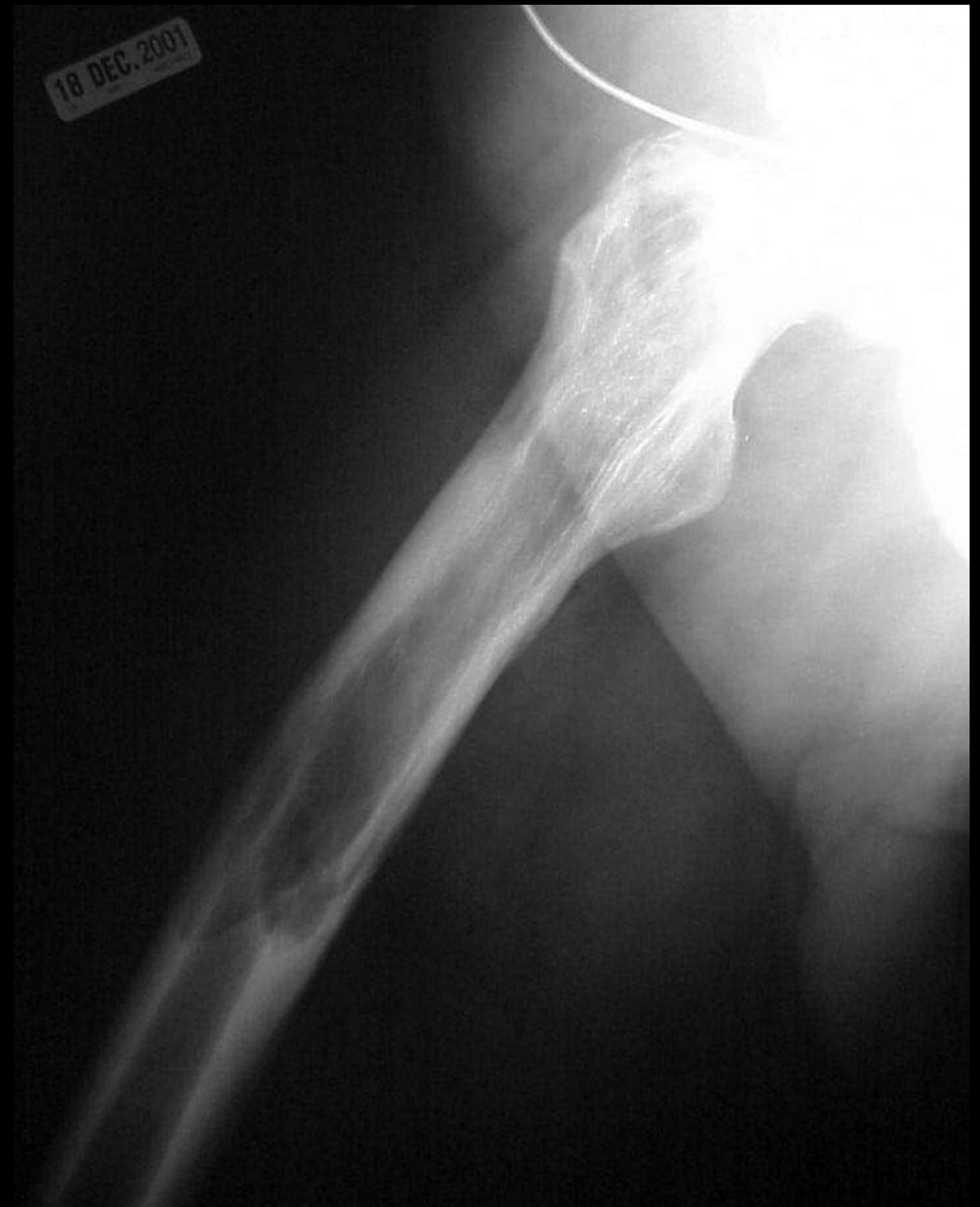

Mickey Mouse sign
Pagets disease of spine with NM





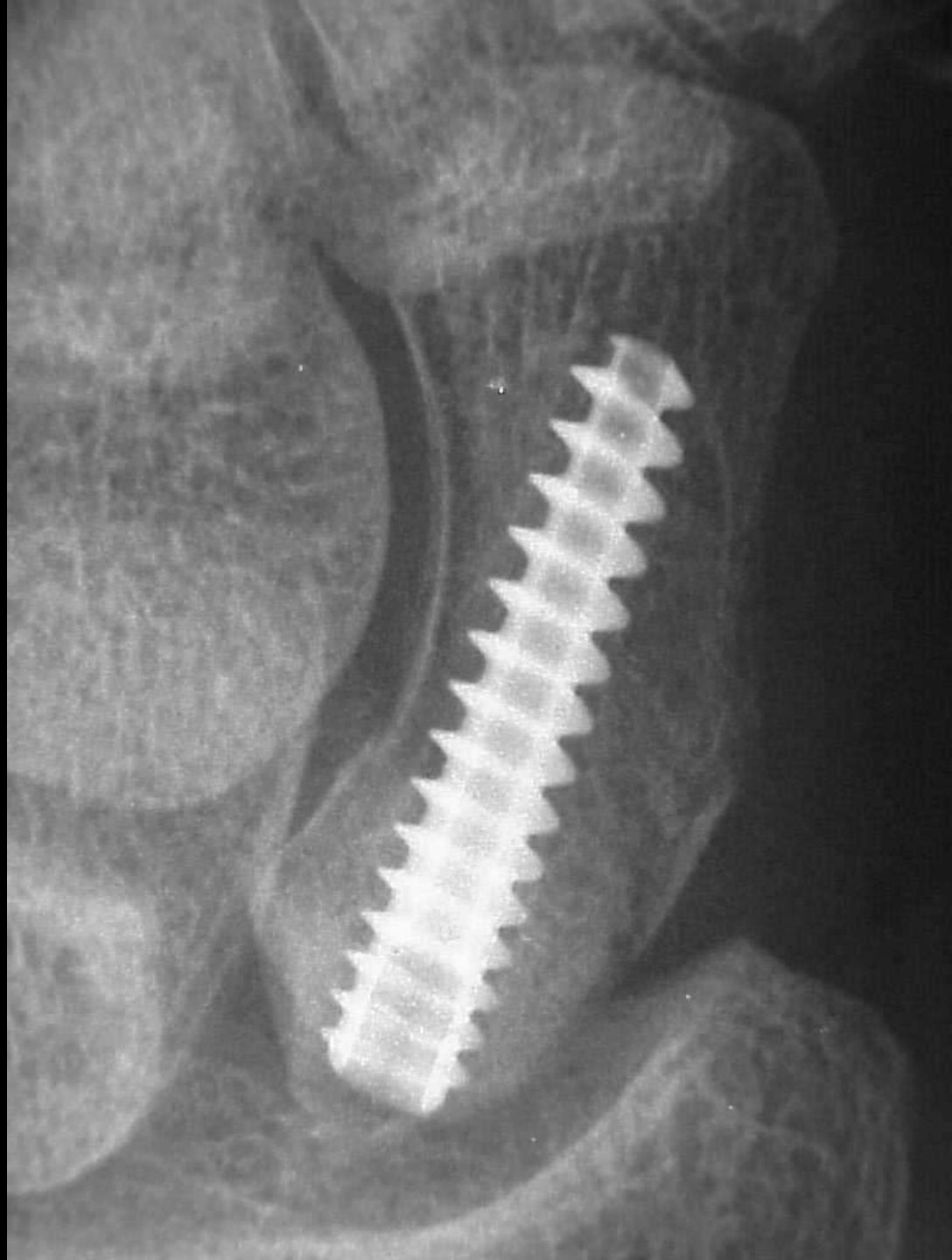
Blade of grass Pagets





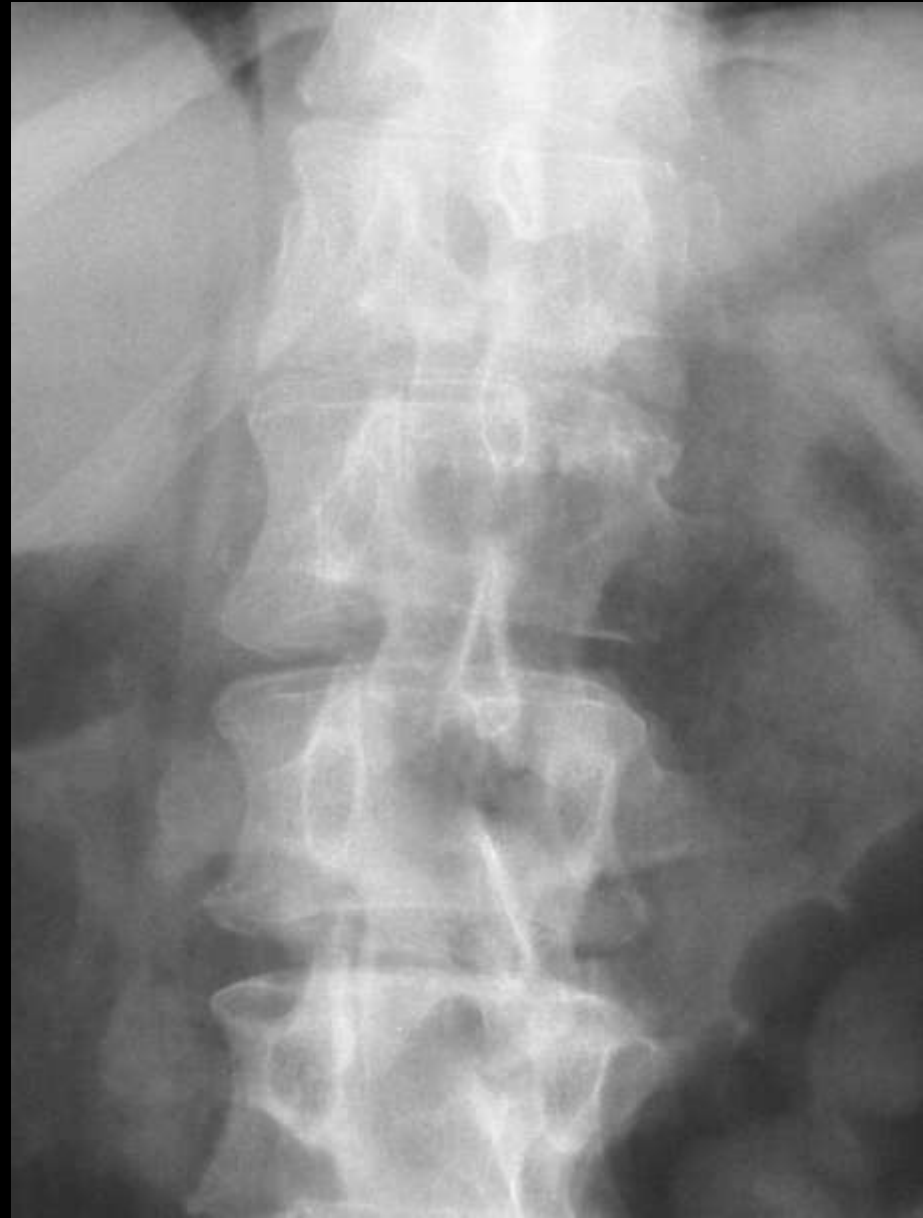Happy Hawkin's sign

Lunate subluxation



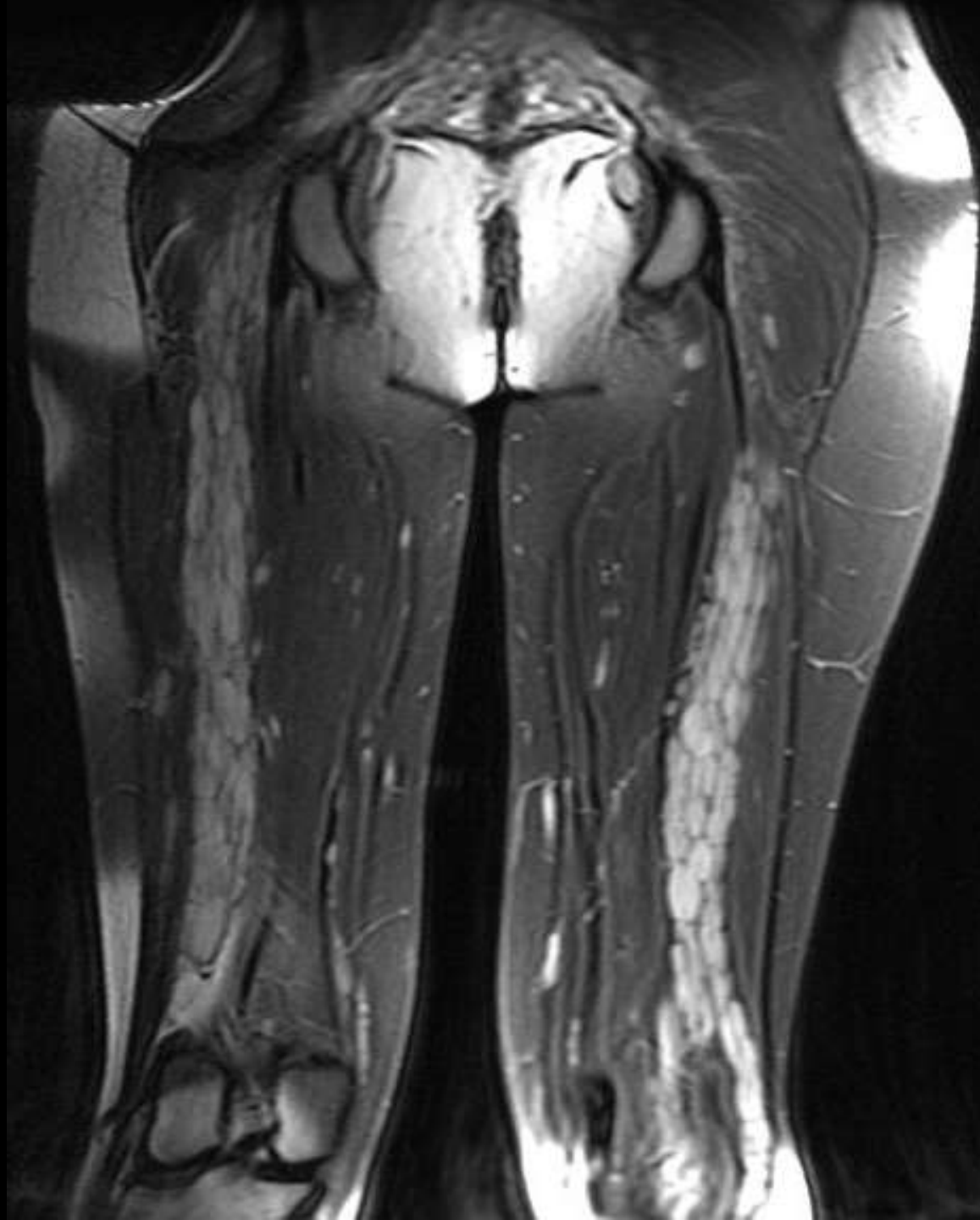

Winking Owl Pedicle metastasis



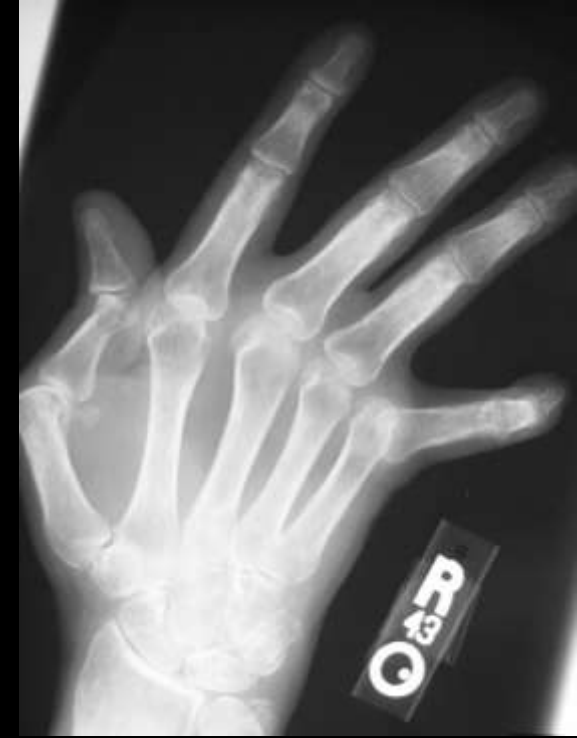
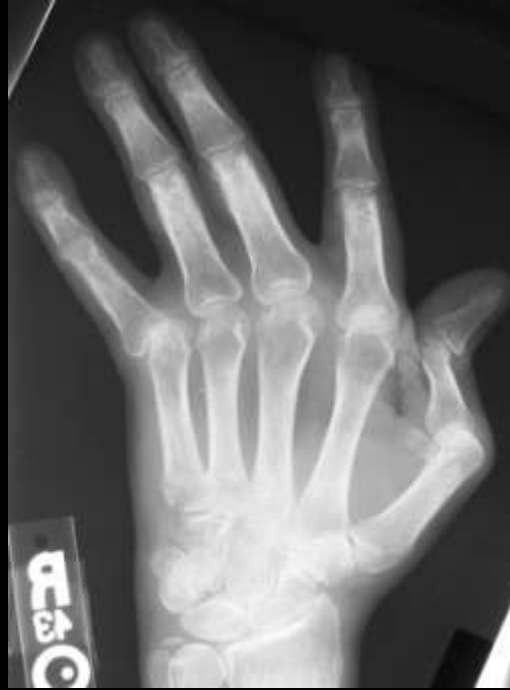
Bag of worms NF1





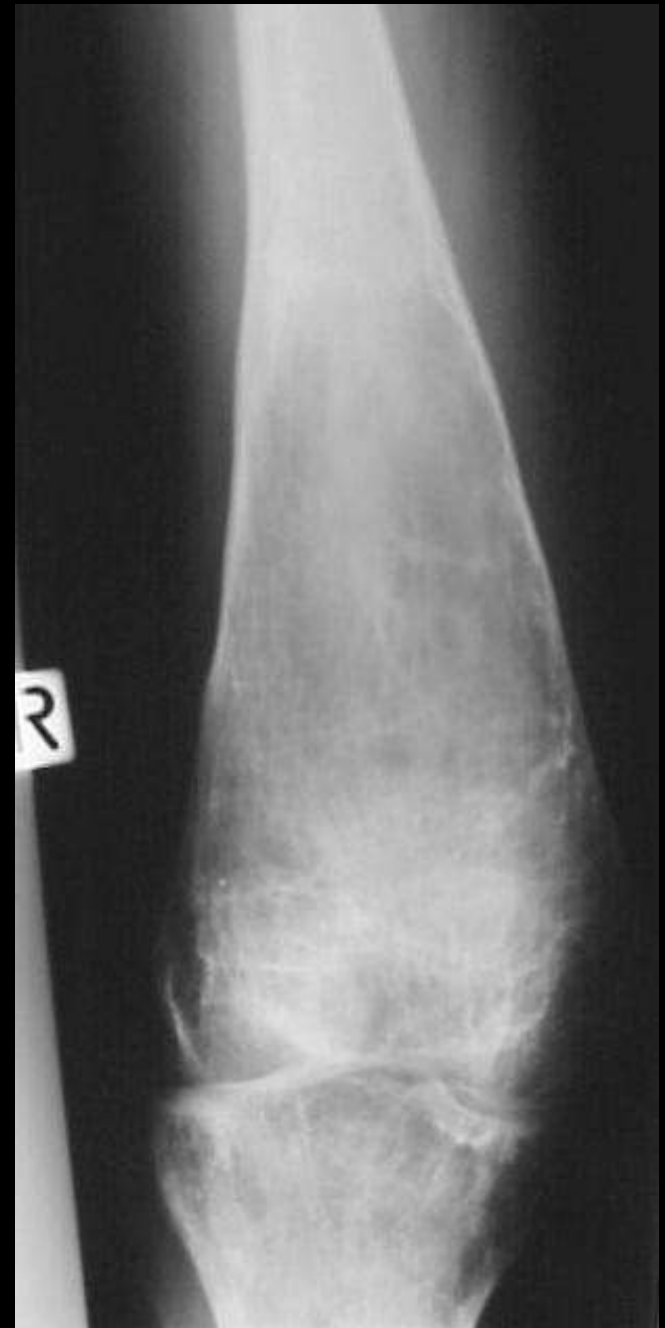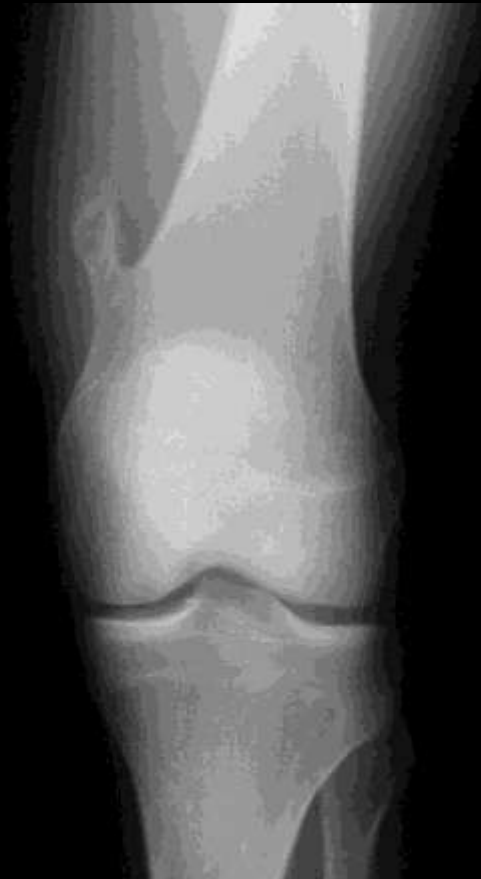Accordian hand
RhA
SLE
MCRH





Erlenmyer flask

Gaucher's
Osteopetrosis
Thalasaemia



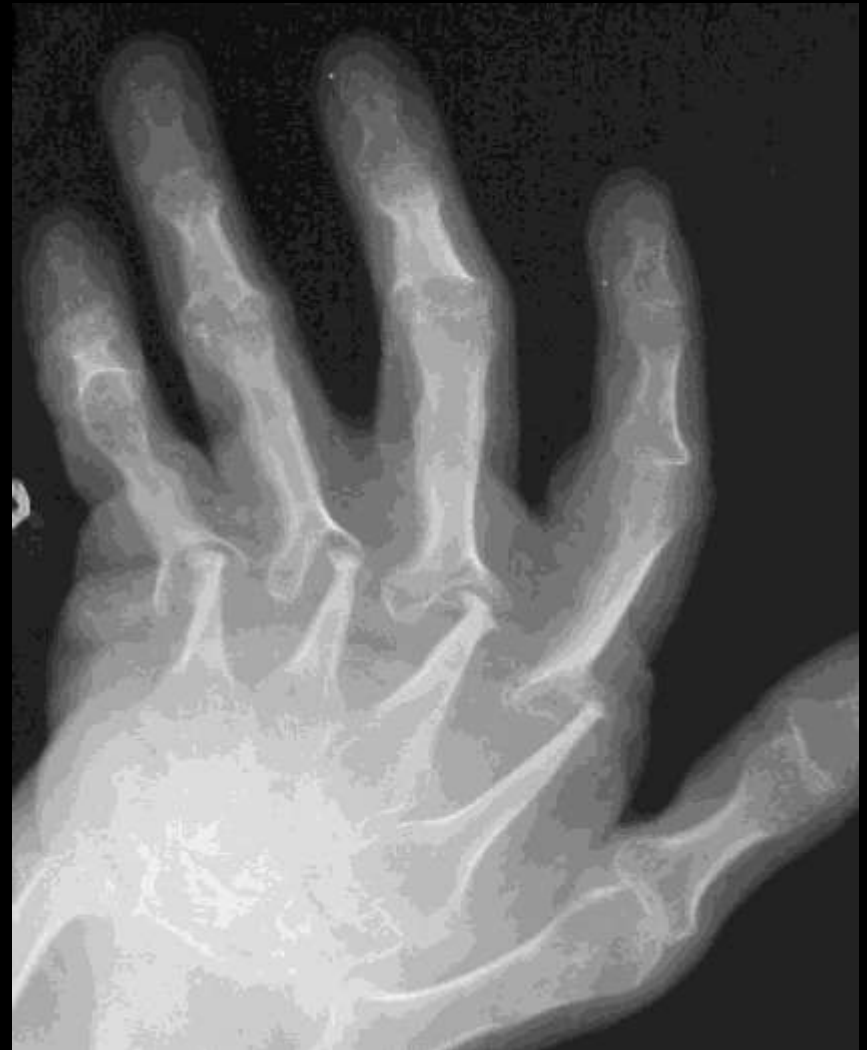

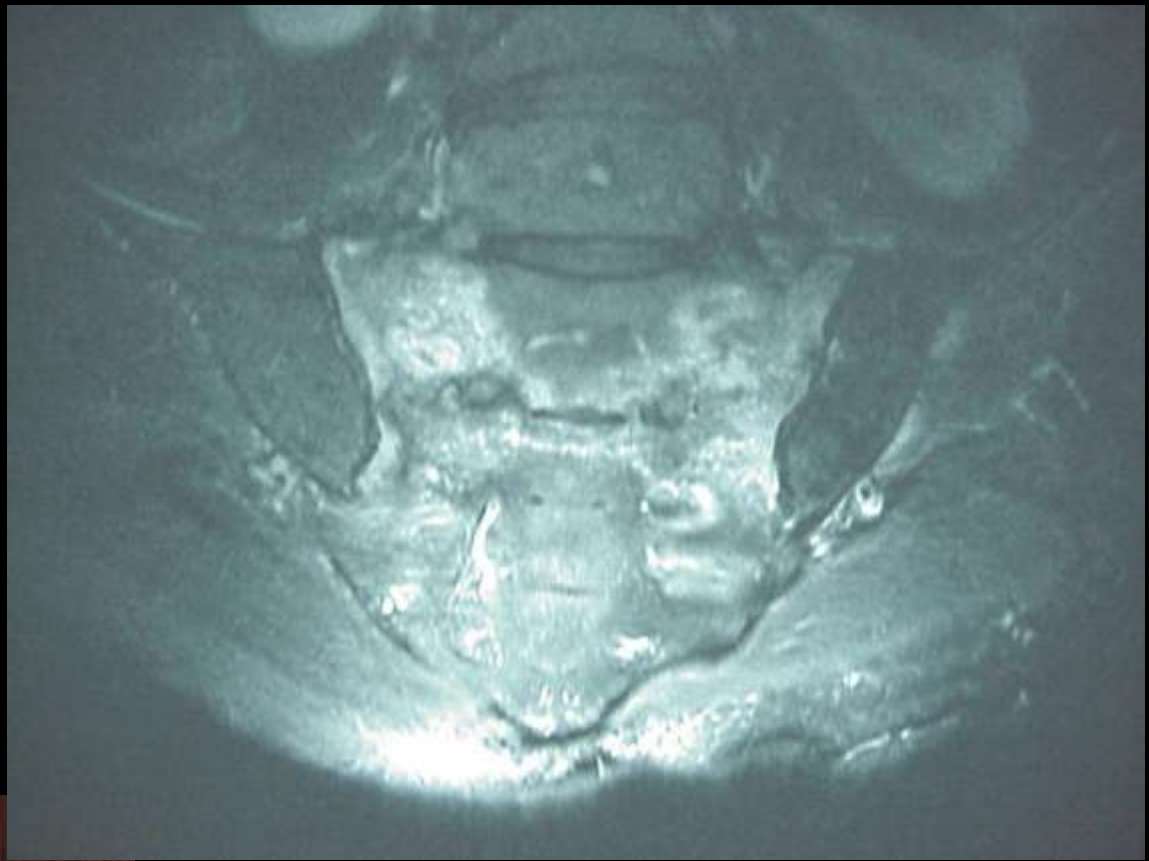Pencil in cup deformity

Psoriasis

Gout

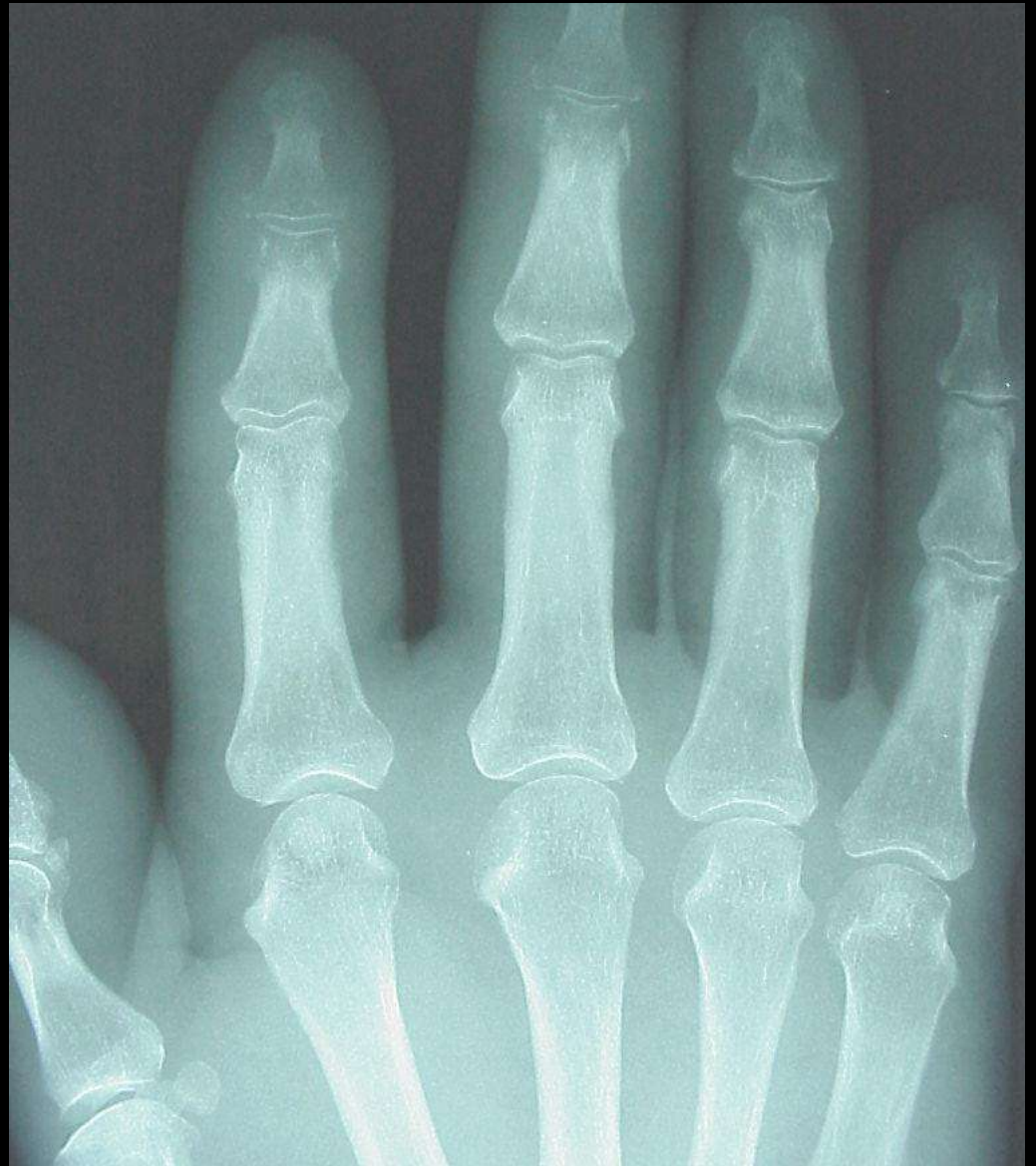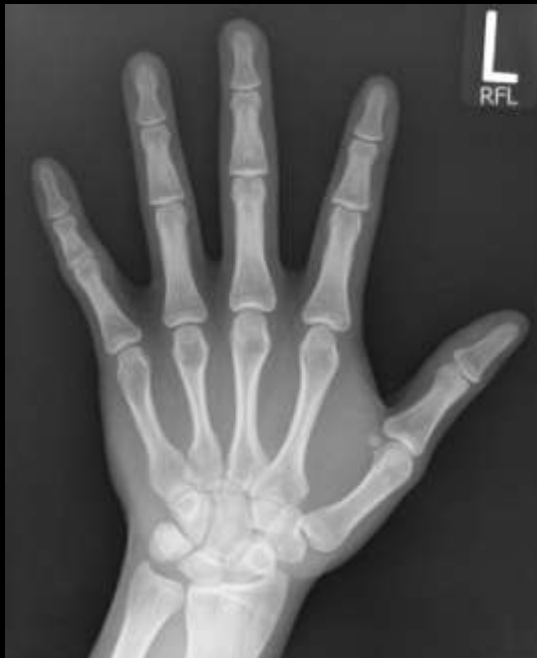RhA



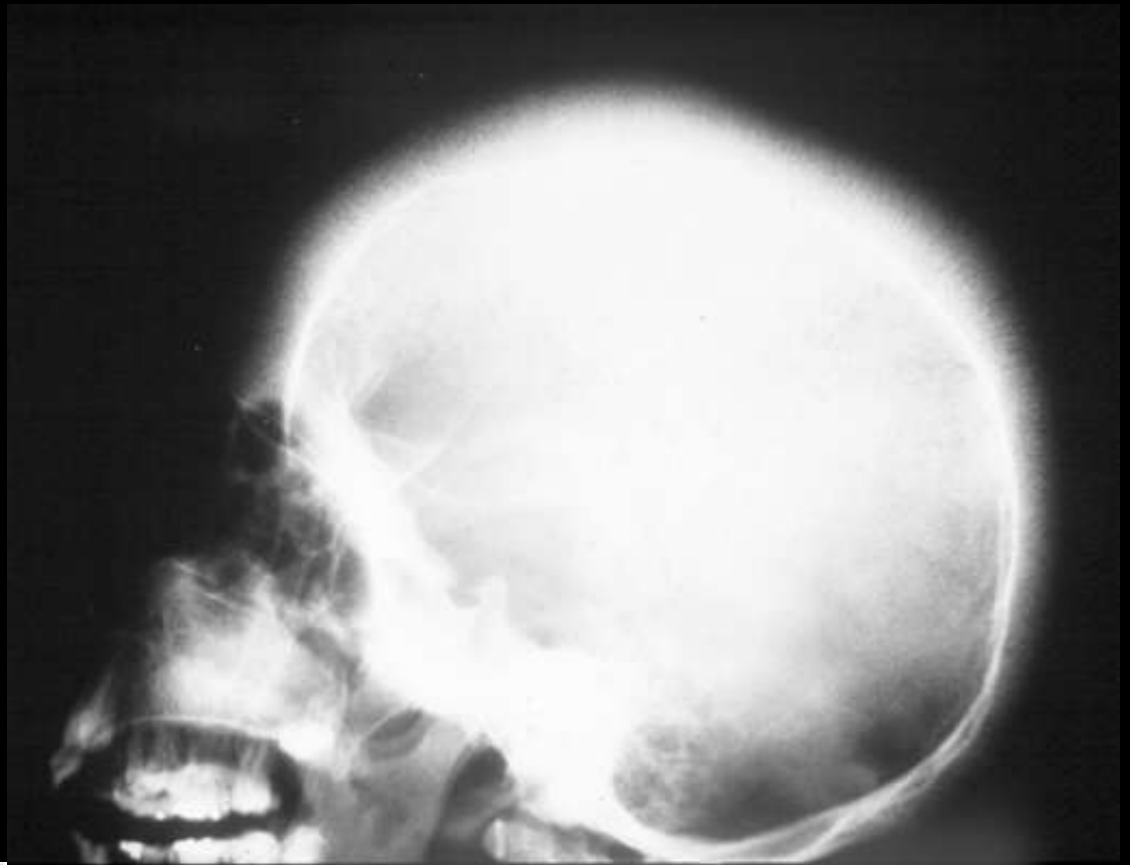


Honda sign

Sacral insufficiency fracture



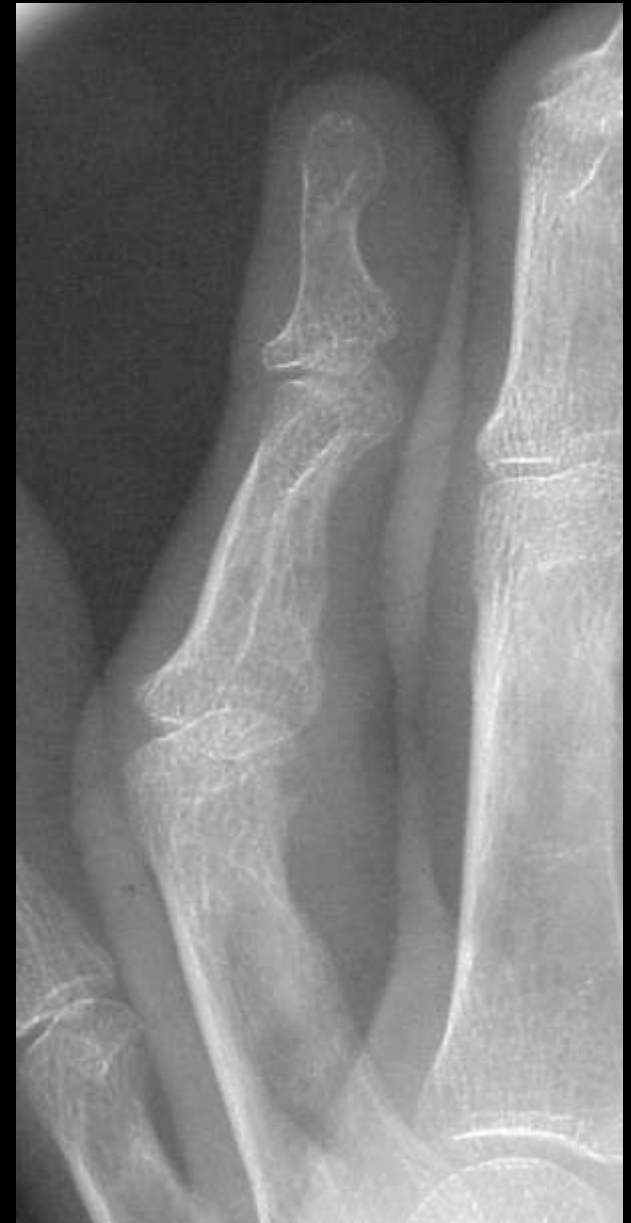Sausage digit
Psoriasis



Hair on end
Thalassemia



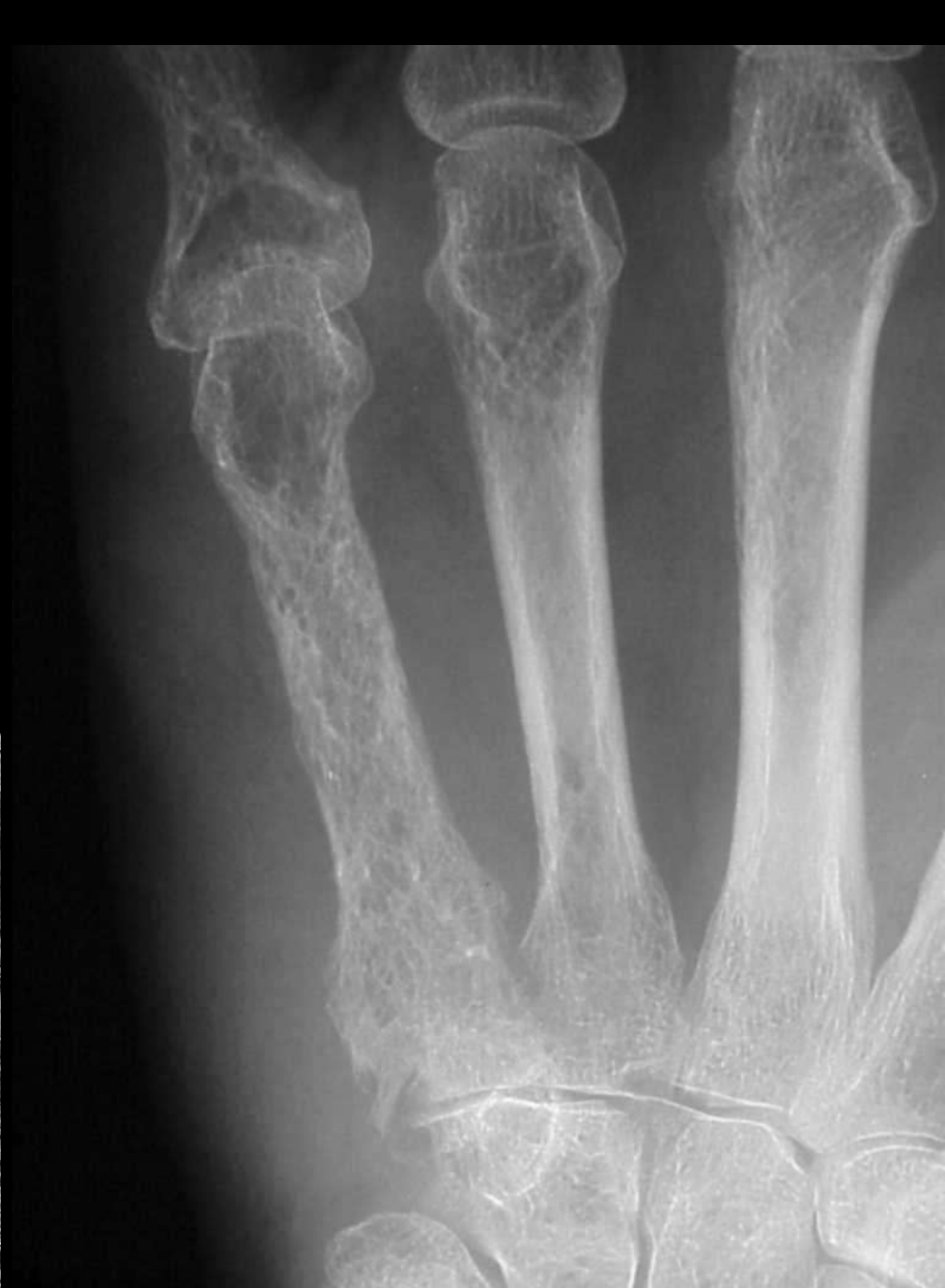Boutonniere deformity





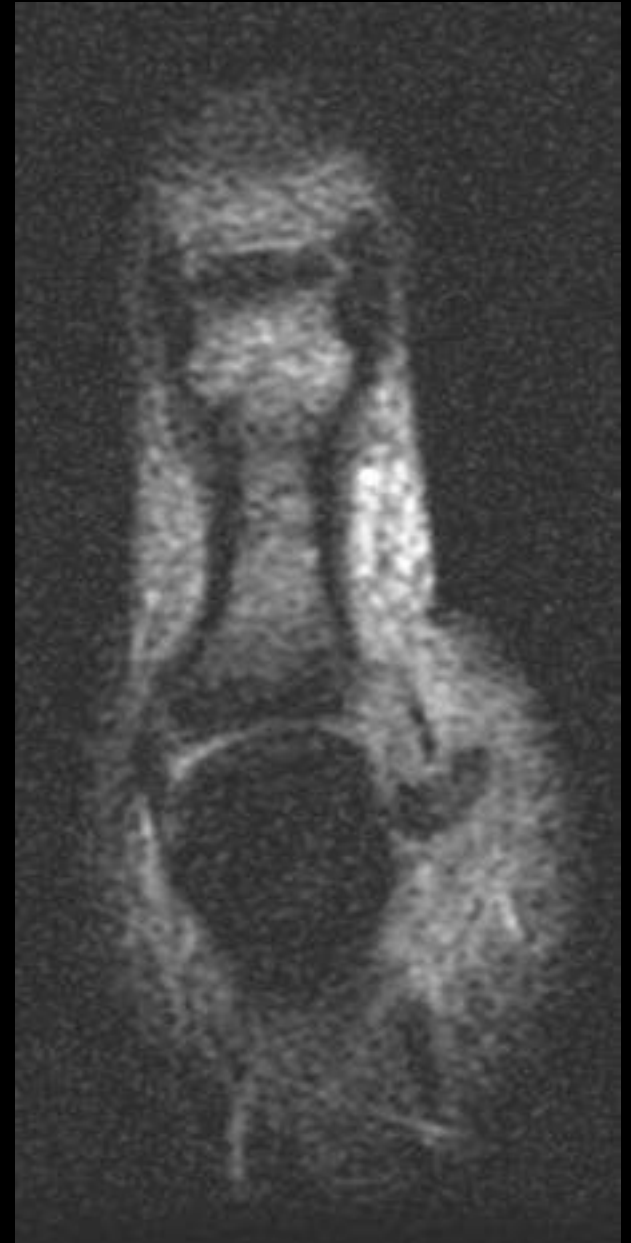
Lace like

Sarcoidosis



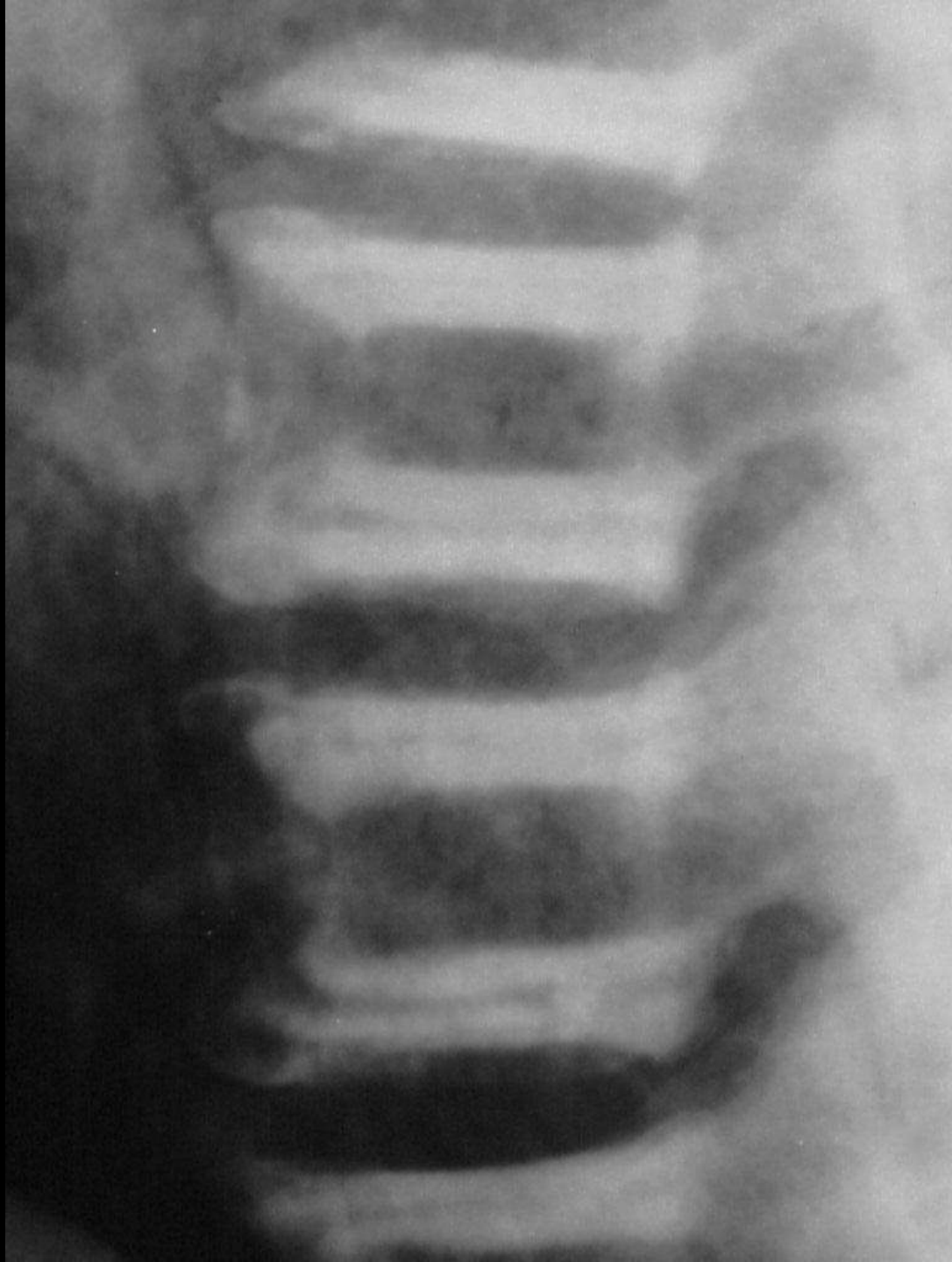


Yo Yo on a string Stenners lesion





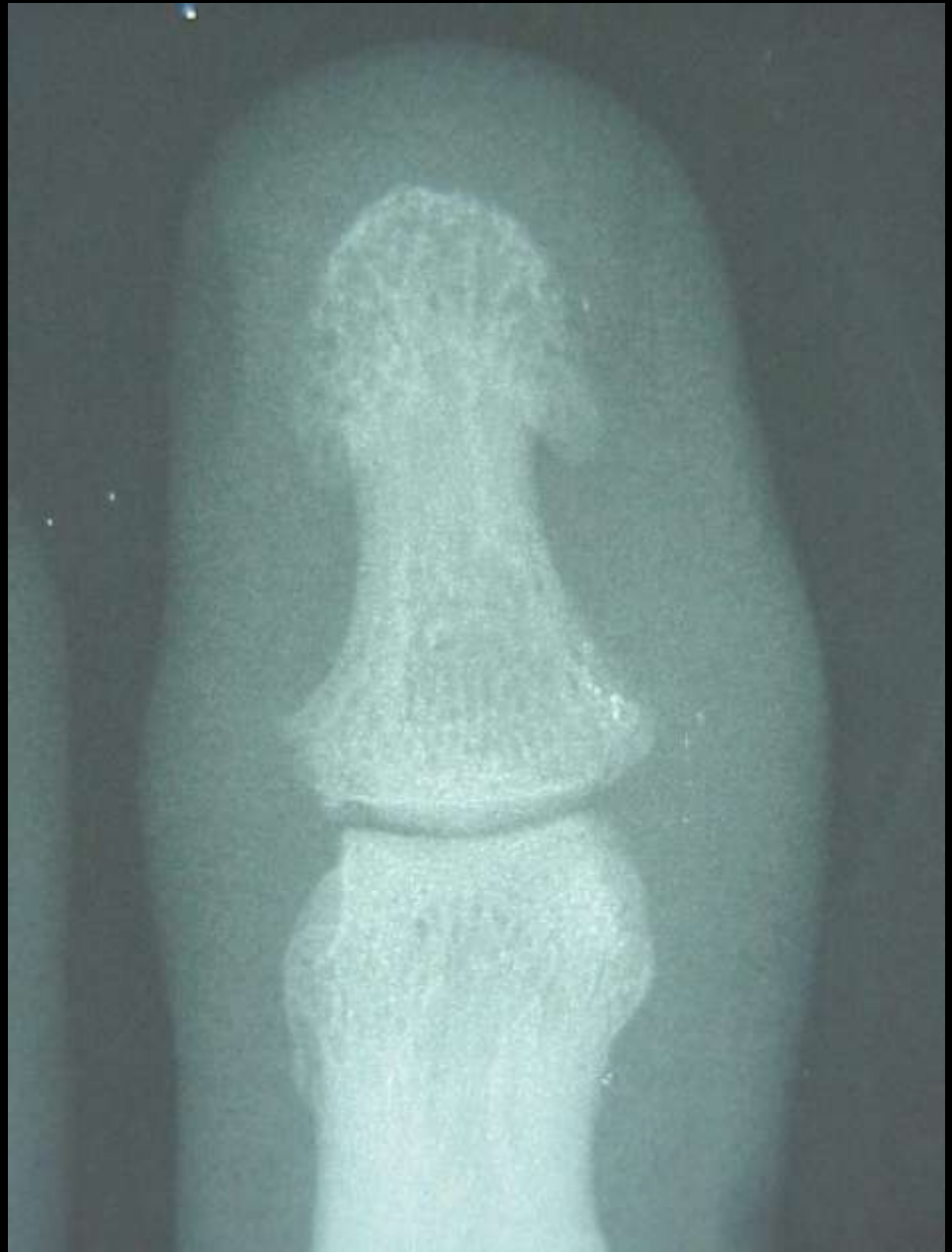Sandwich vertebrae Osteopetrosis





Whiskering

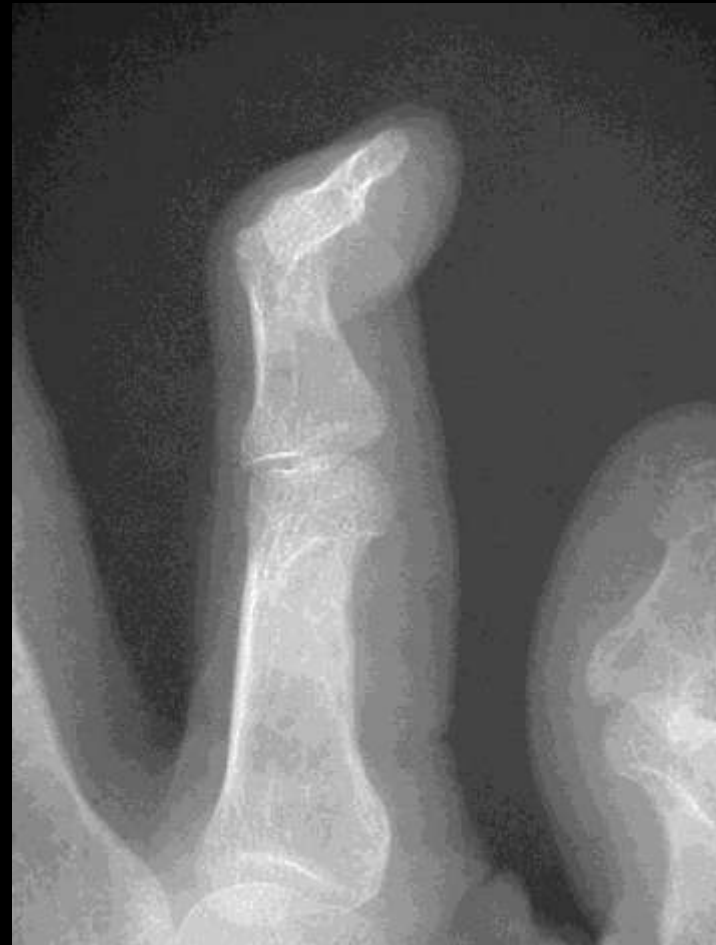Psoriasis
Reiter's





Swan neck deformity

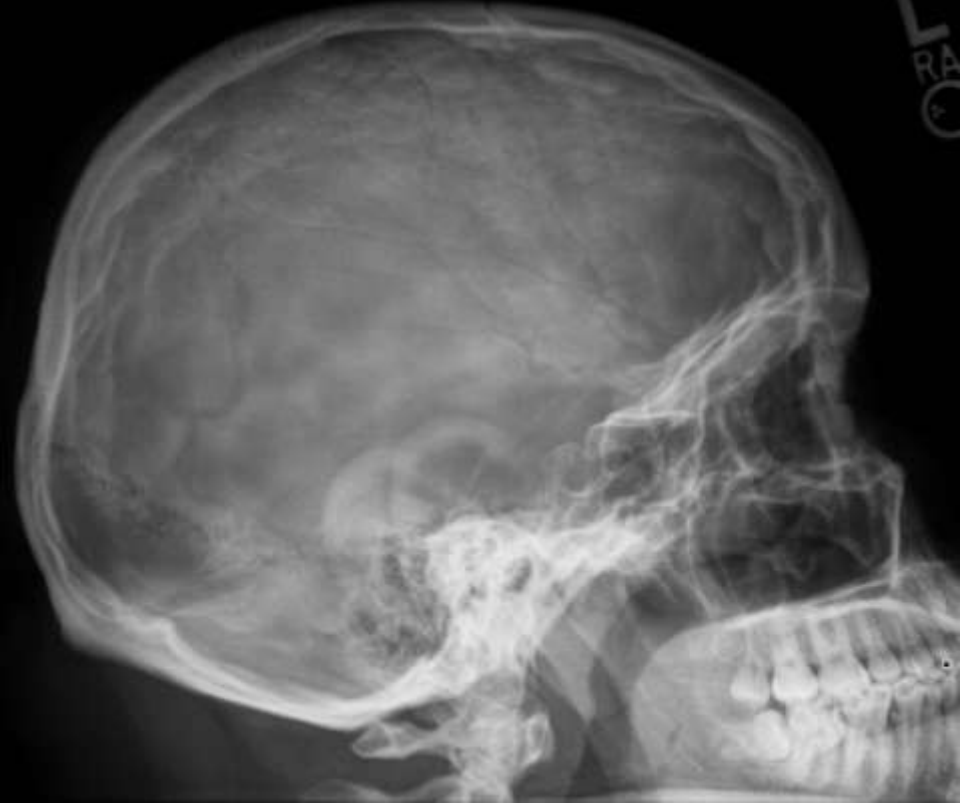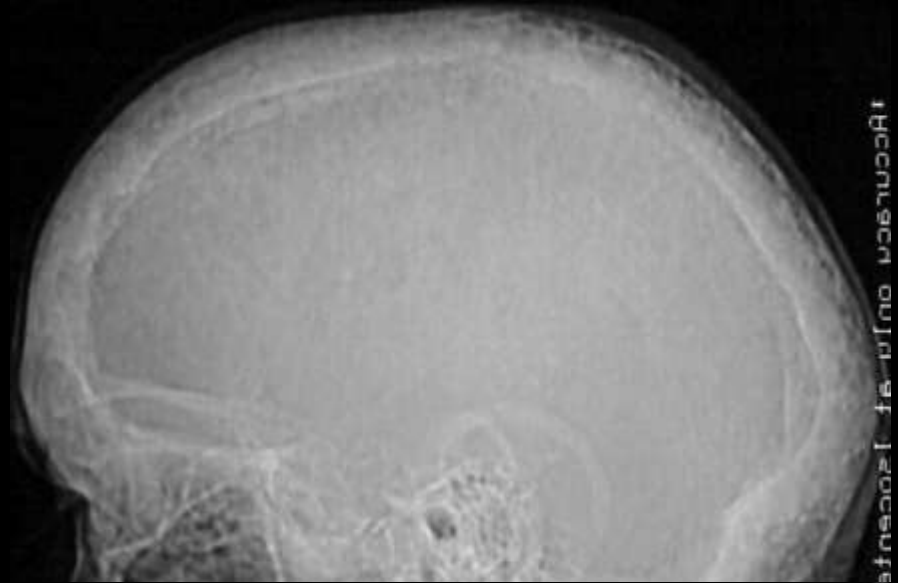
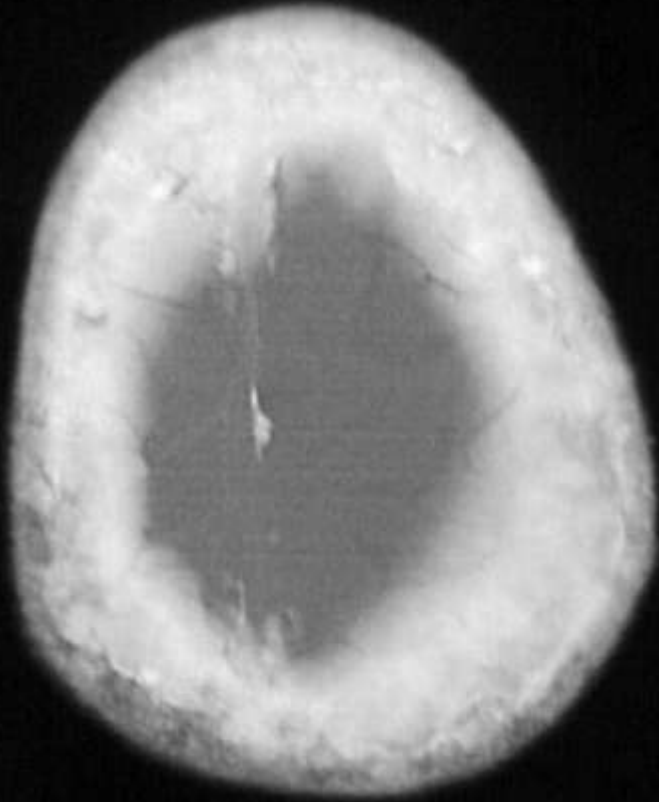
Rheumatoid arthritis





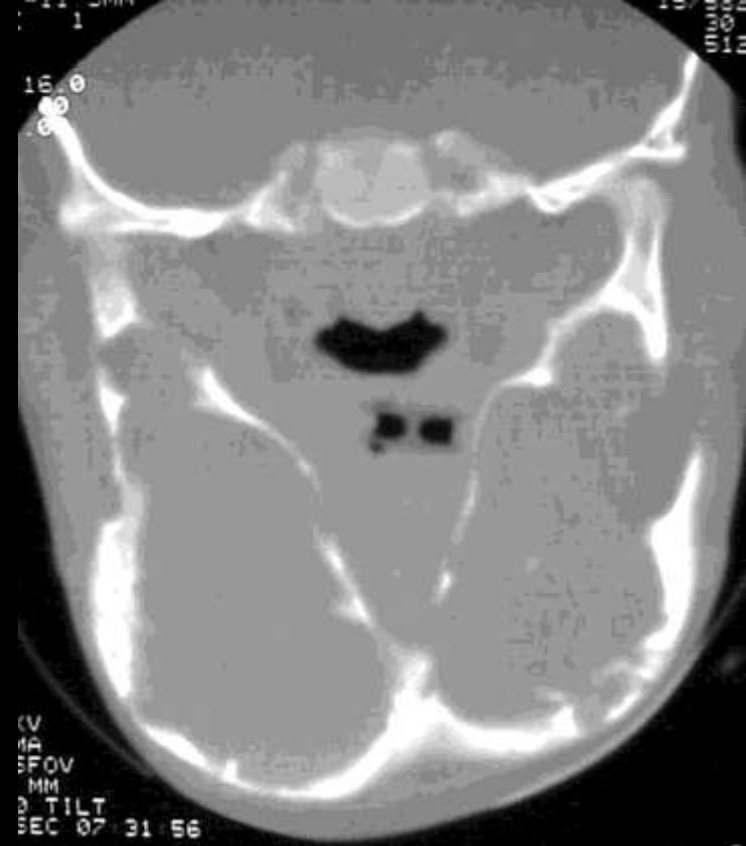
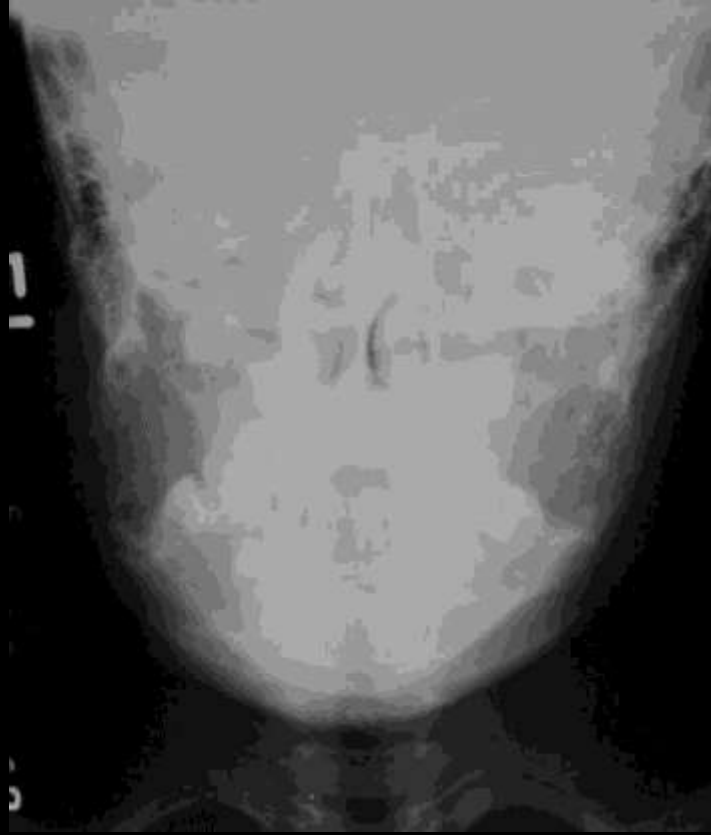
Cotton wool sign

Pagets



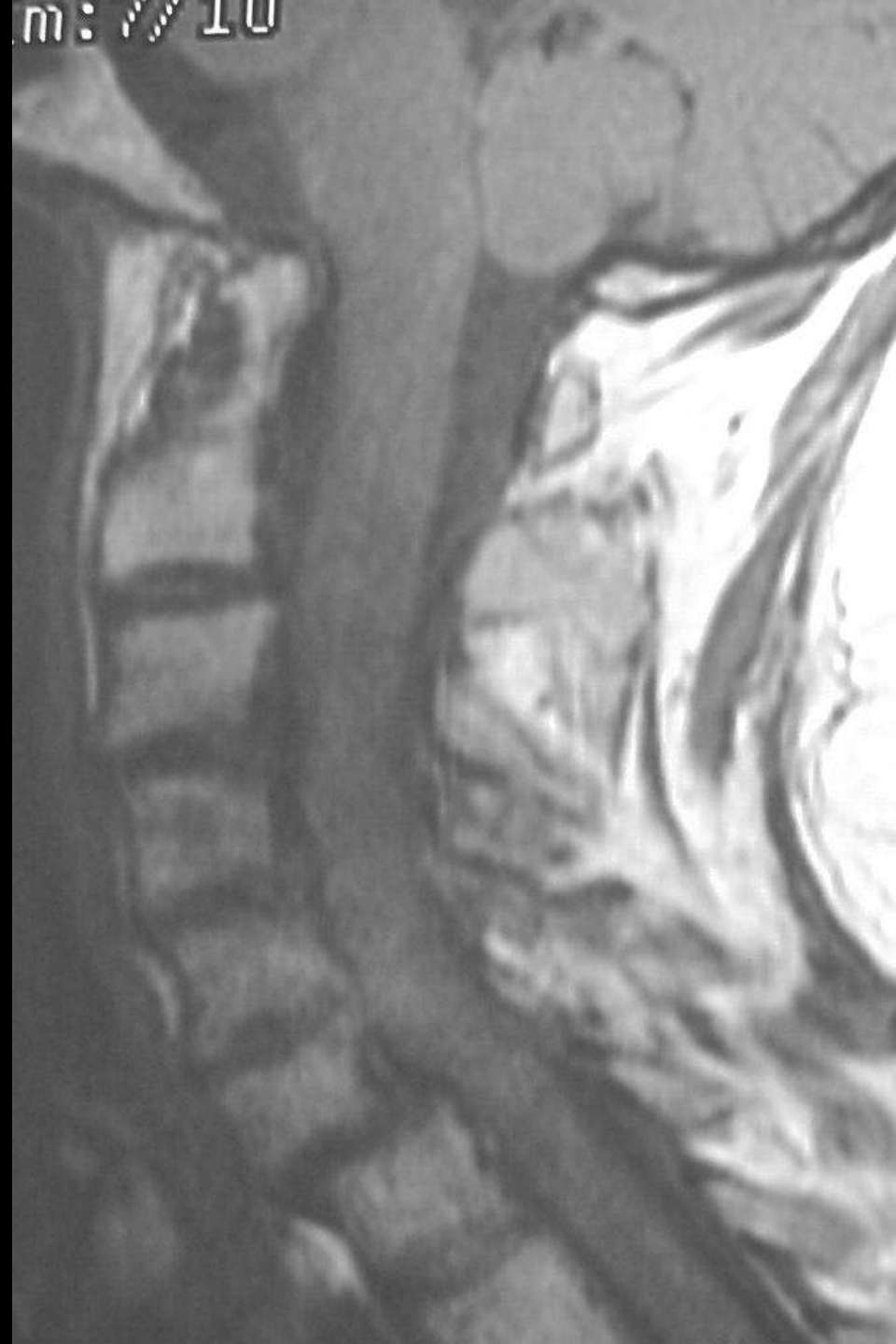afnrcnscu onfr fa 1200000000

RA
C



Cherubism
Fibrous dysplasia





Stepladder spine

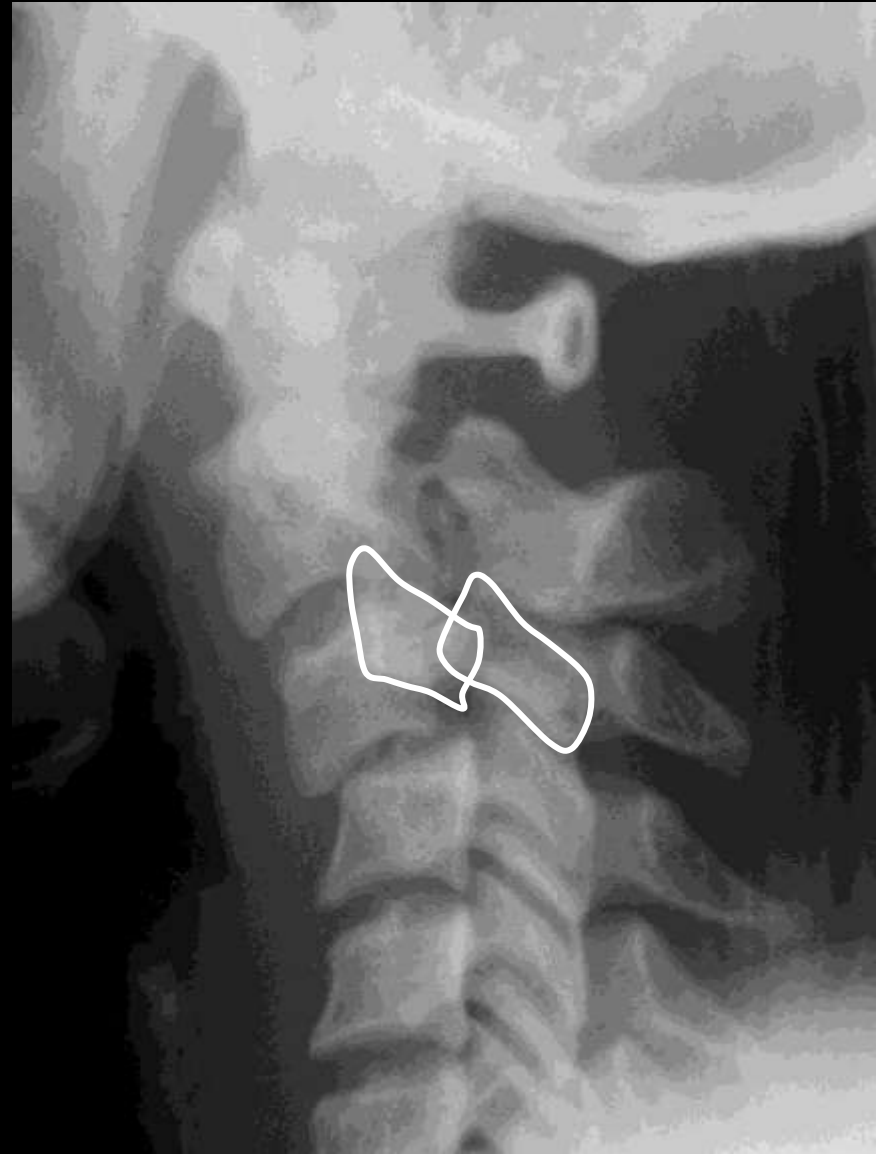

RhA of Cx spine

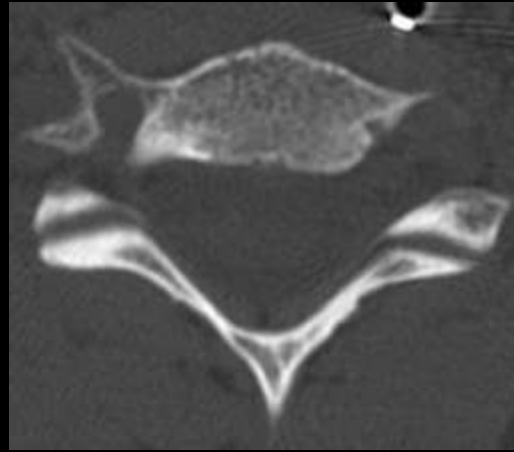




Bow tie sign

Unilateral cervical facet dislocation

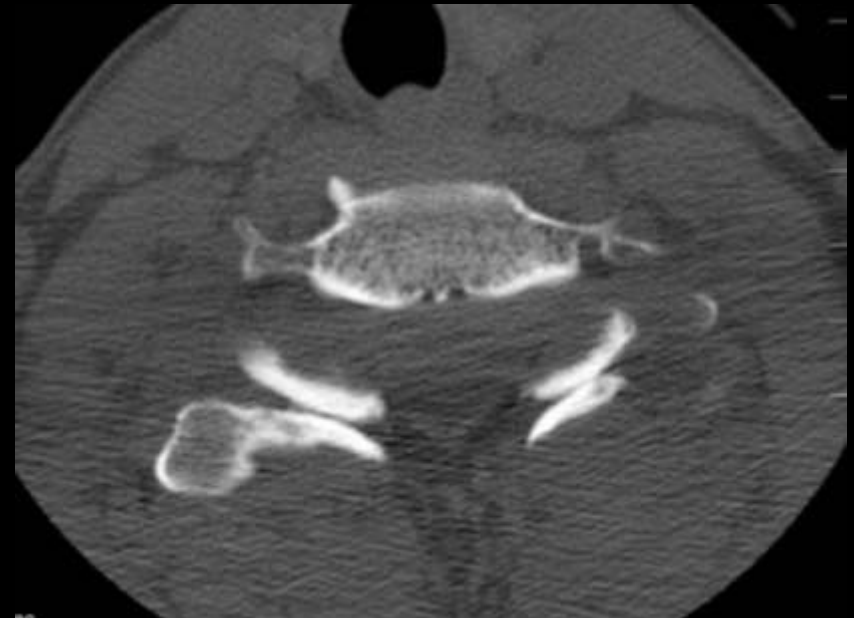
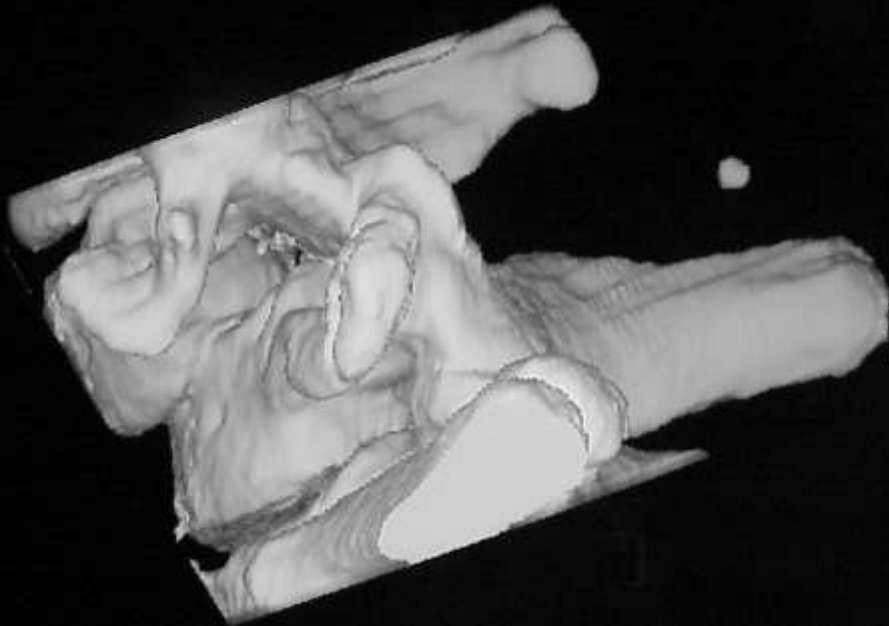




Burger sign

Normal facet alignment

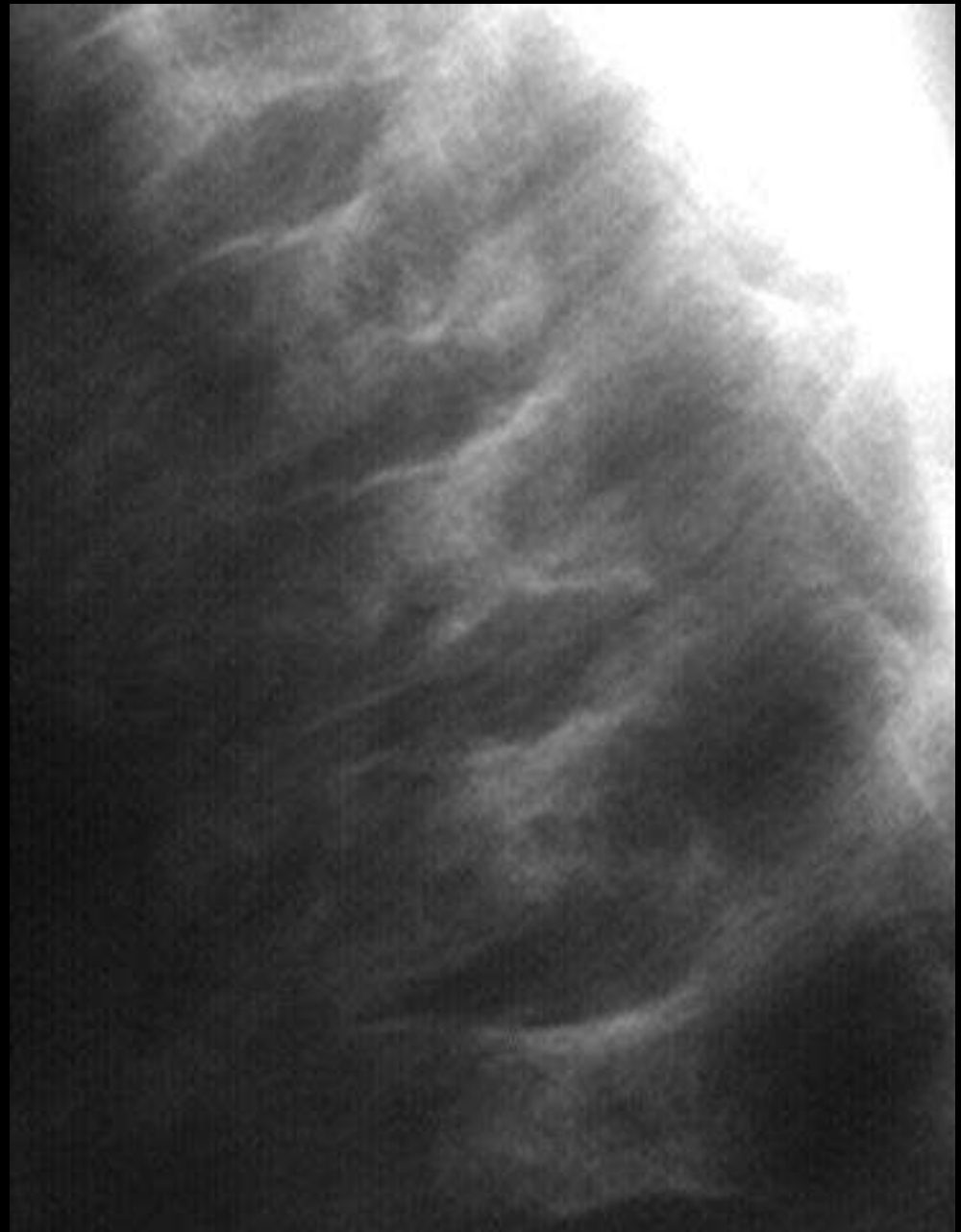Lost with facet dislocation





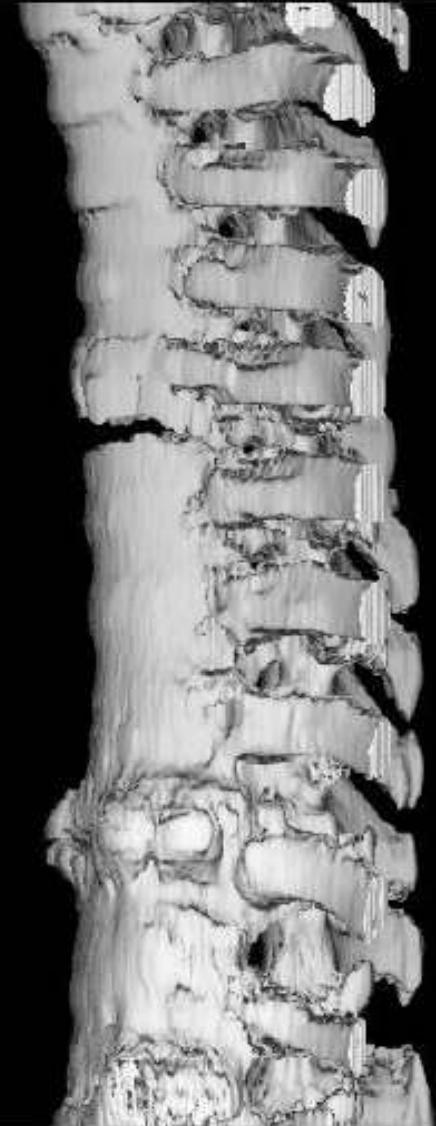
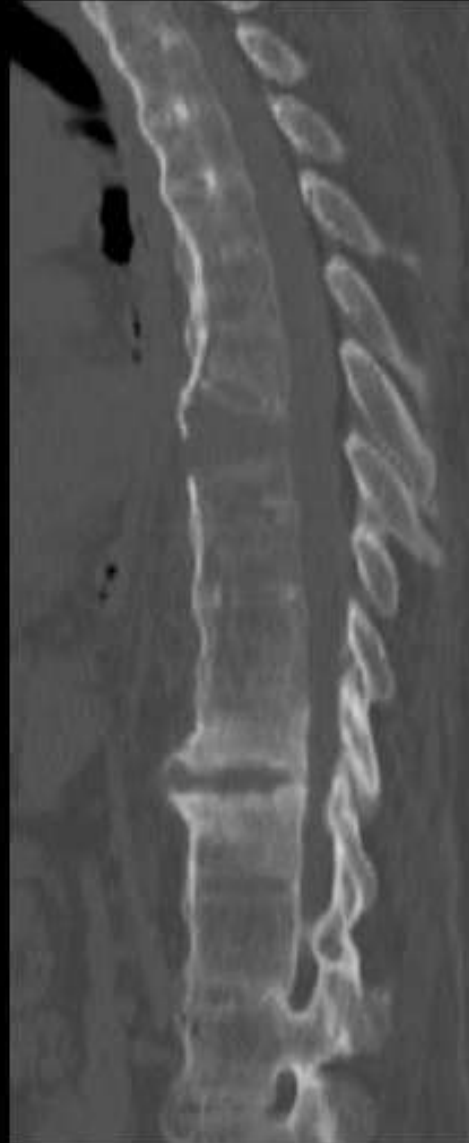
H shaped vertebrae

Sickle cell disease



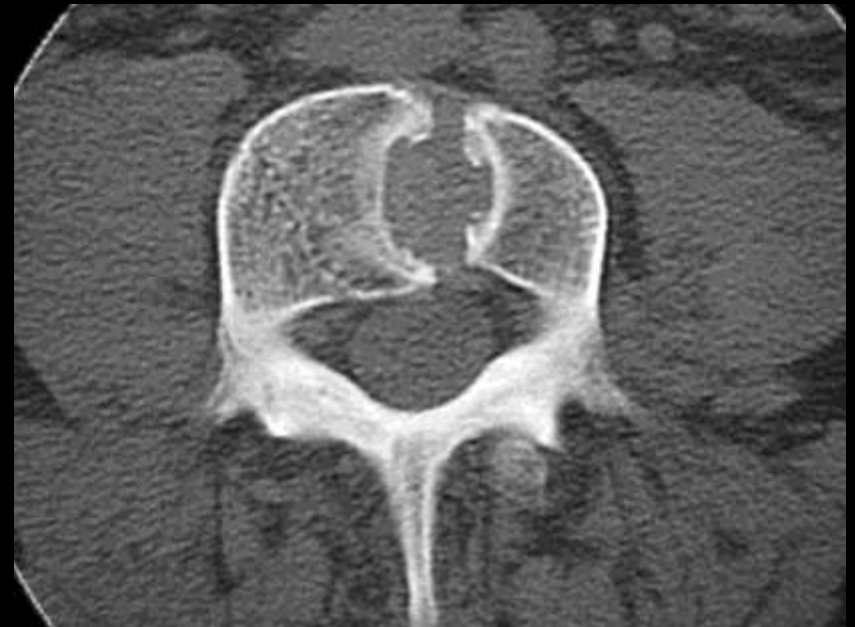

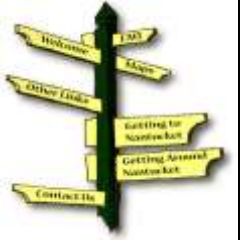Chalk stick fracture Ankylosing Spondylitis





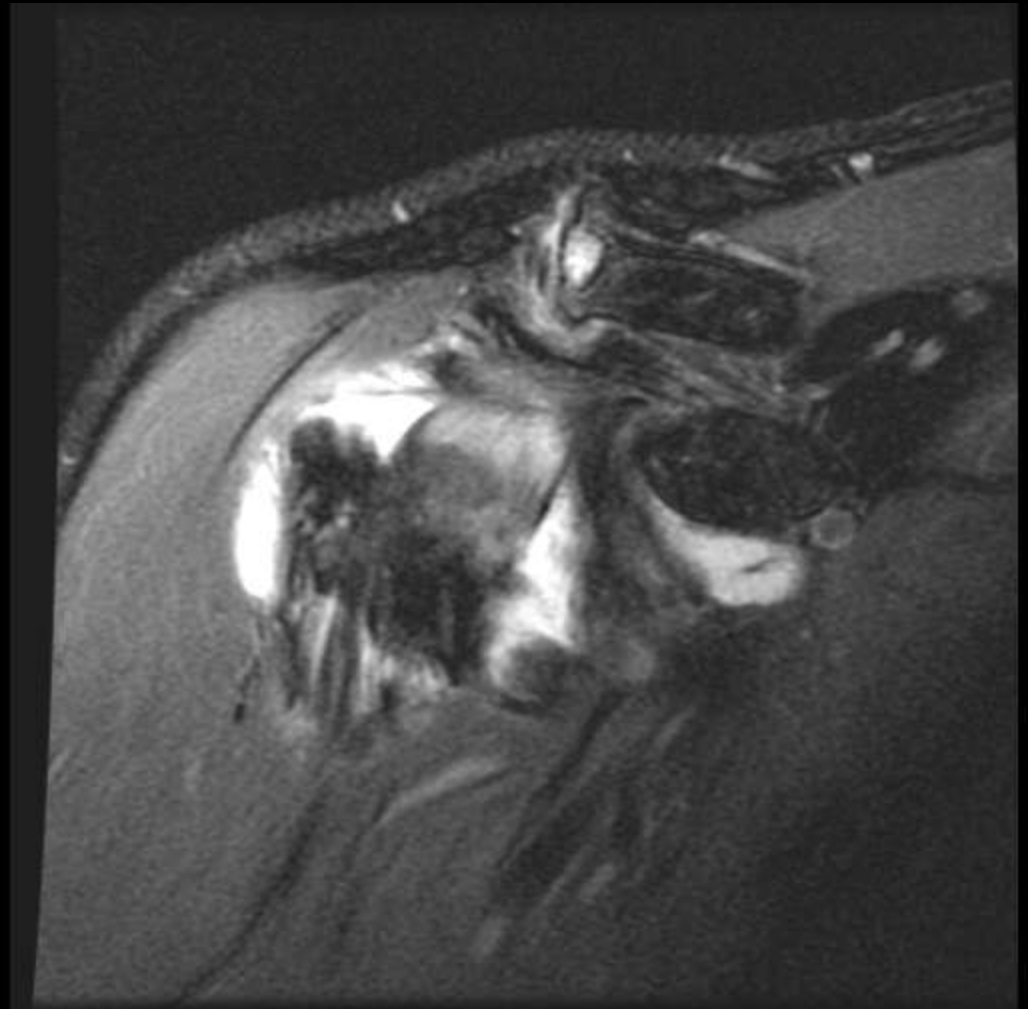
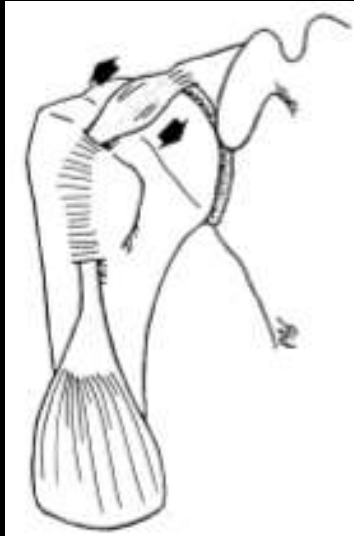Butterfly vertebrae Congenital segmentation anomaly





Hourglass sign

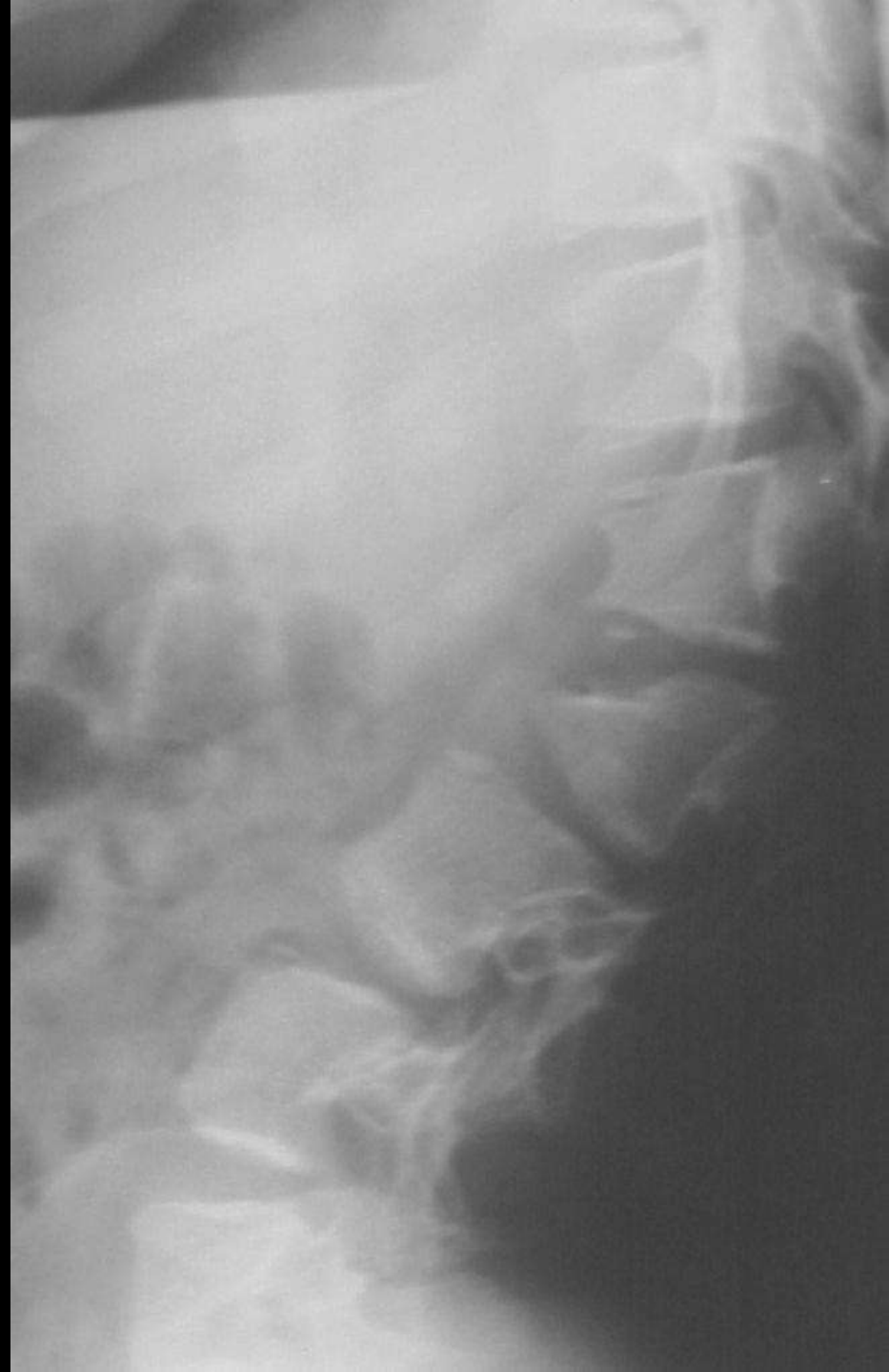Tapered biceps in bicipital groove





Bullet shaped vertebrae

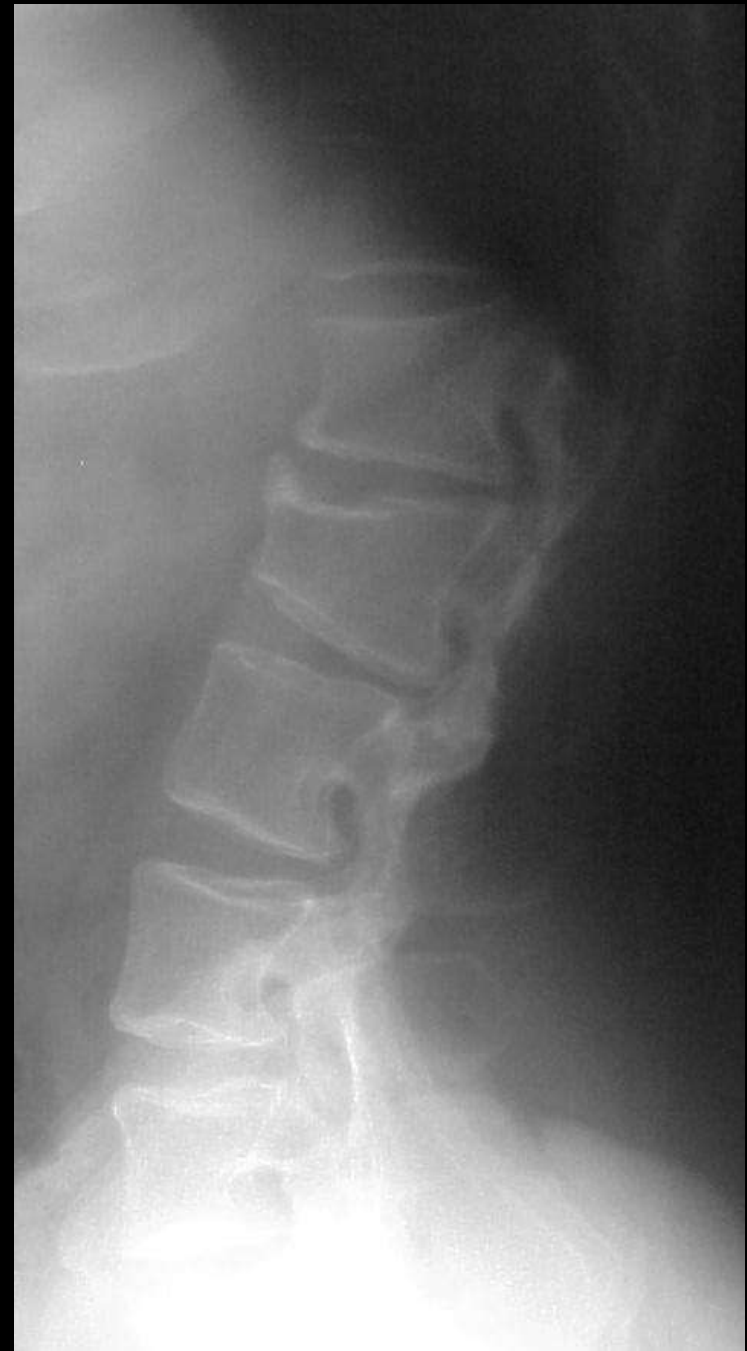Achondroplasia
Hurler's syndrome





Vertebral Scallop

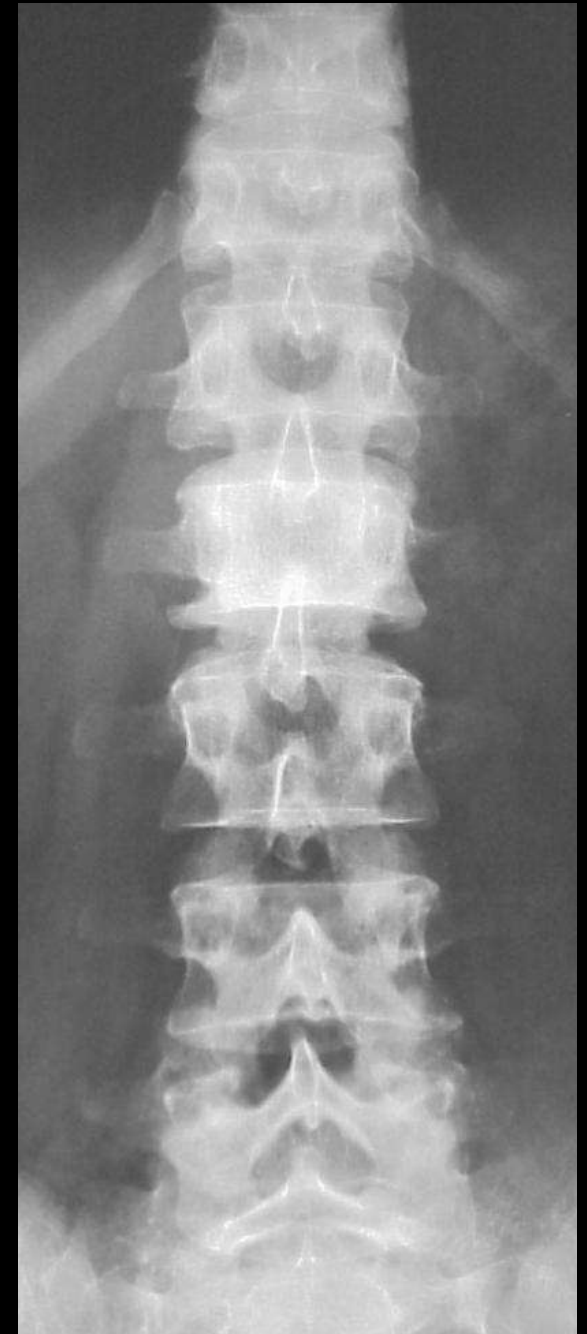Achondroplasia
Neurofibromatosis

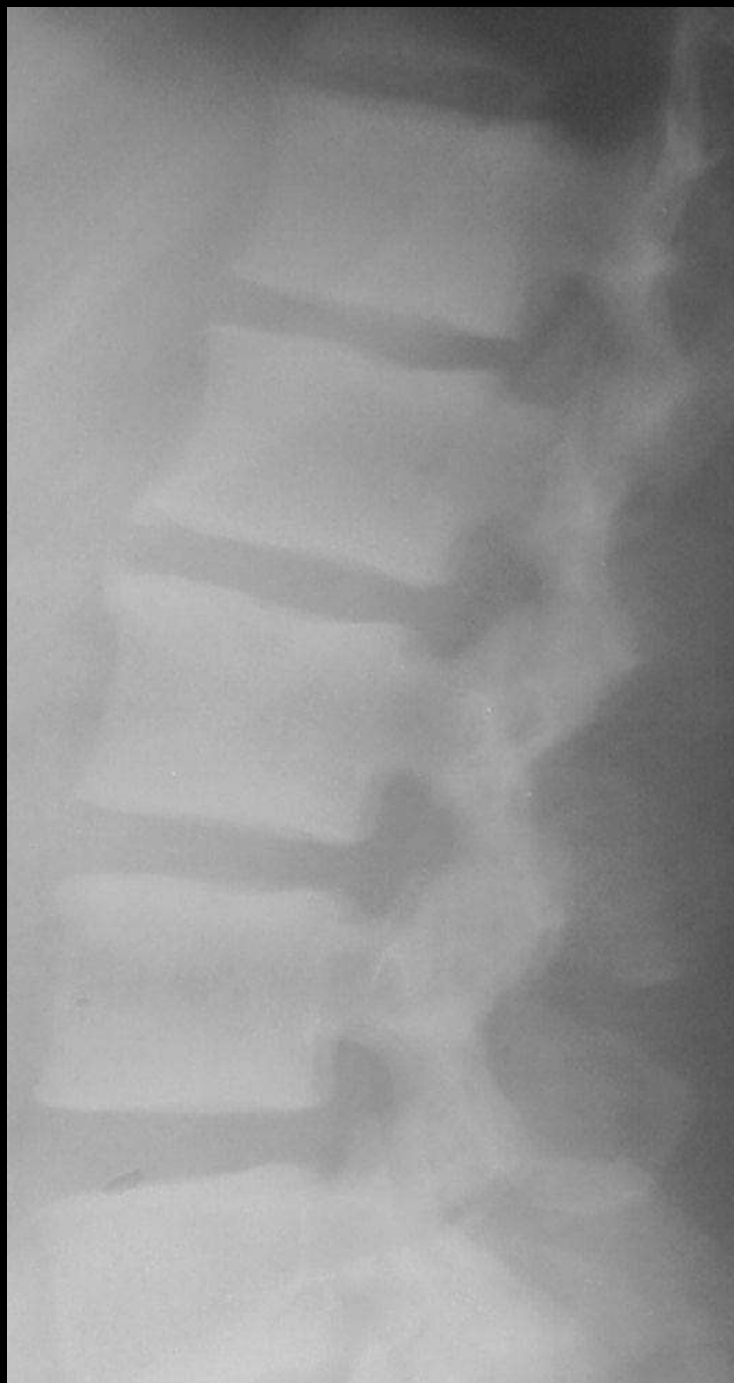



Ivory vertebrae

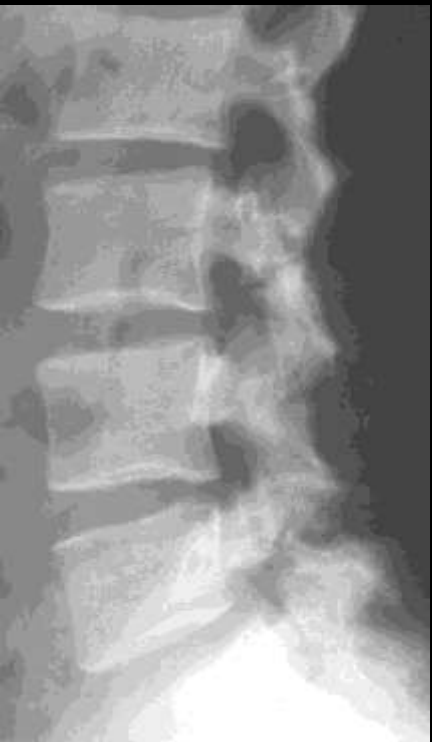Hodgkin's
Mets
Osteosarcoma

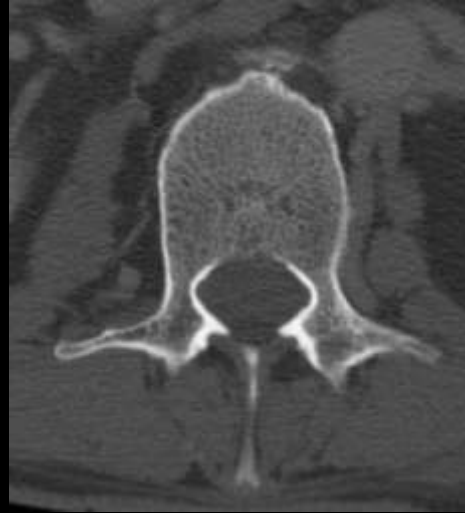




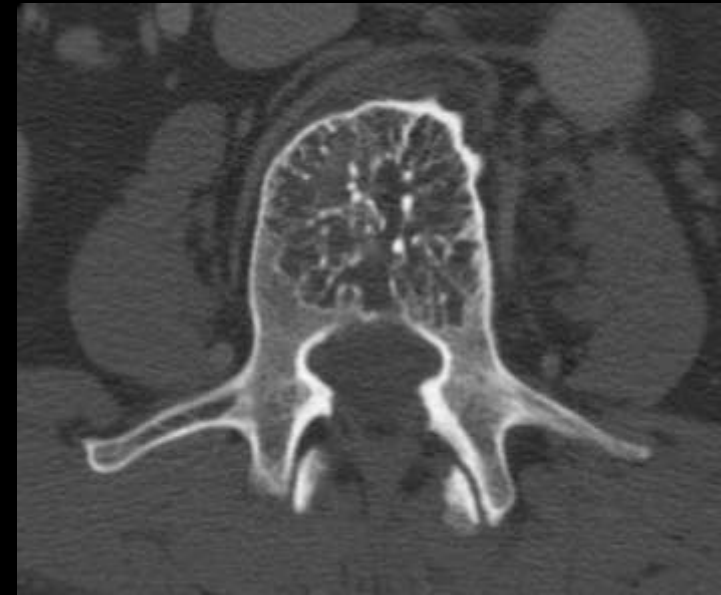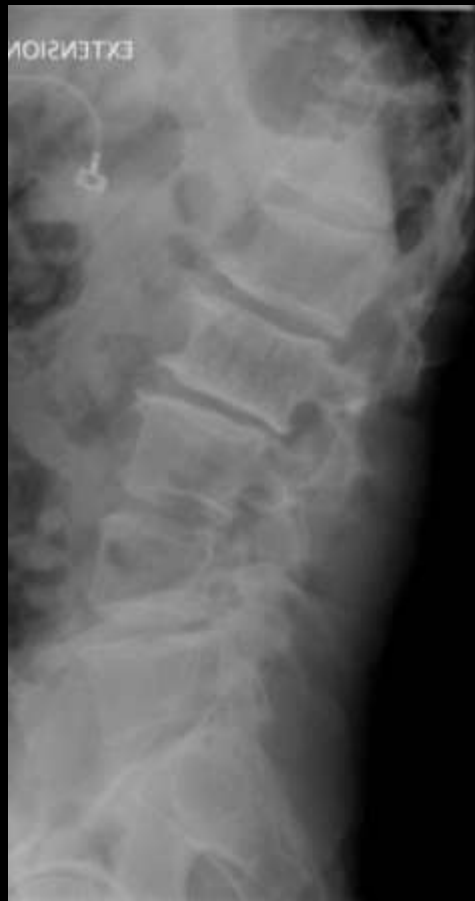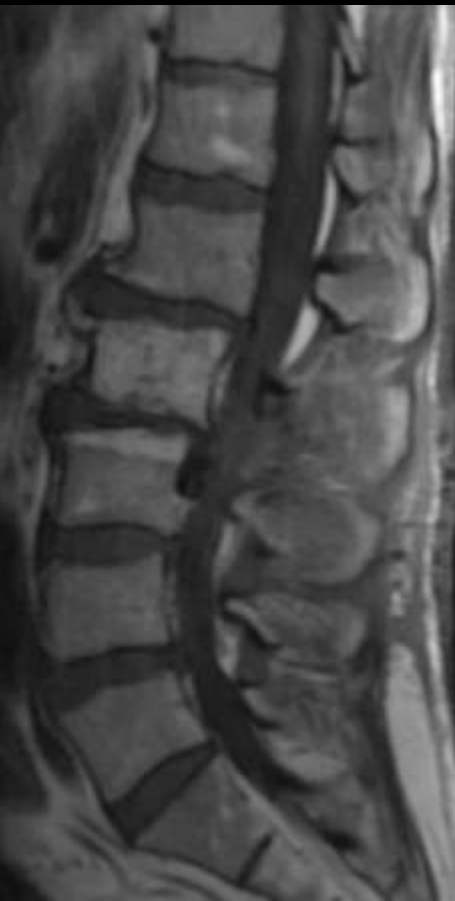Rugger jersey spine

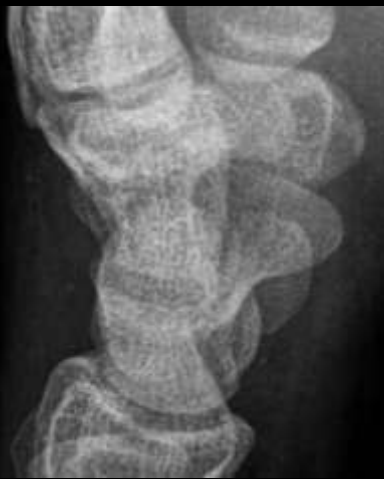Renal
Osteodystrophy



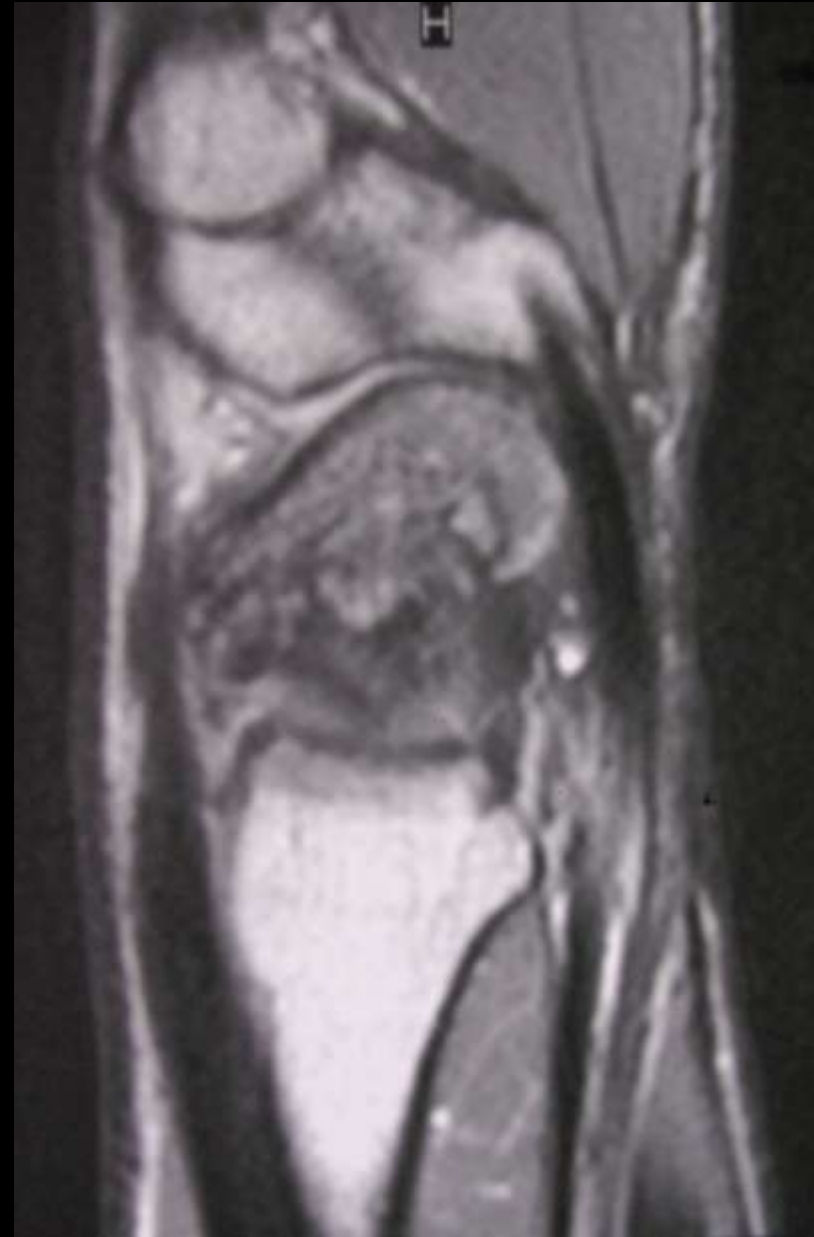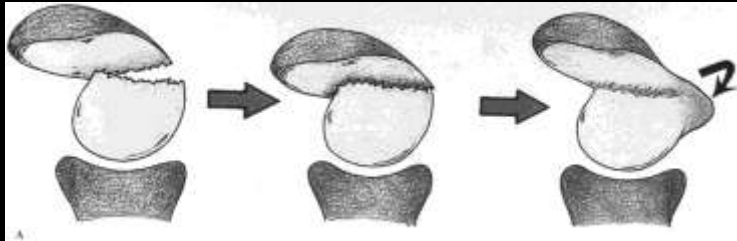


Polkadot Sign
Hemangioma





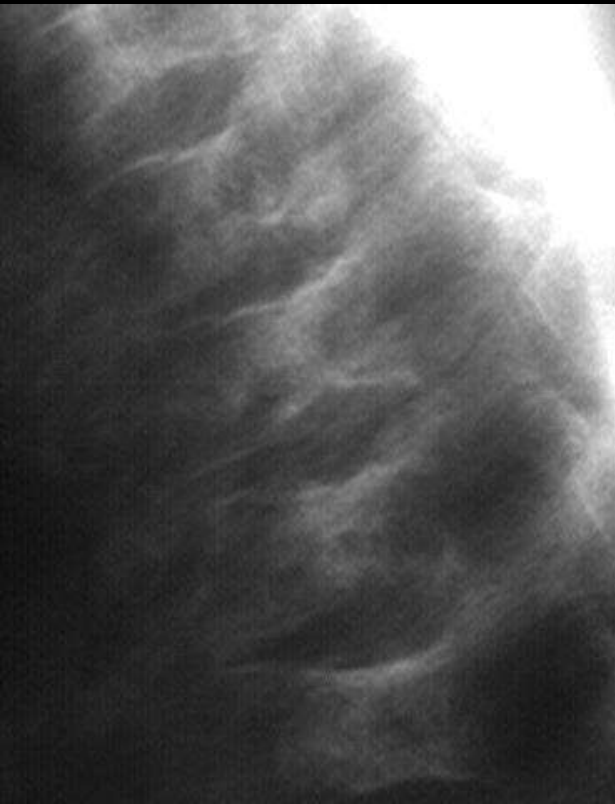
Hunchback deformity Scaphoid malunion

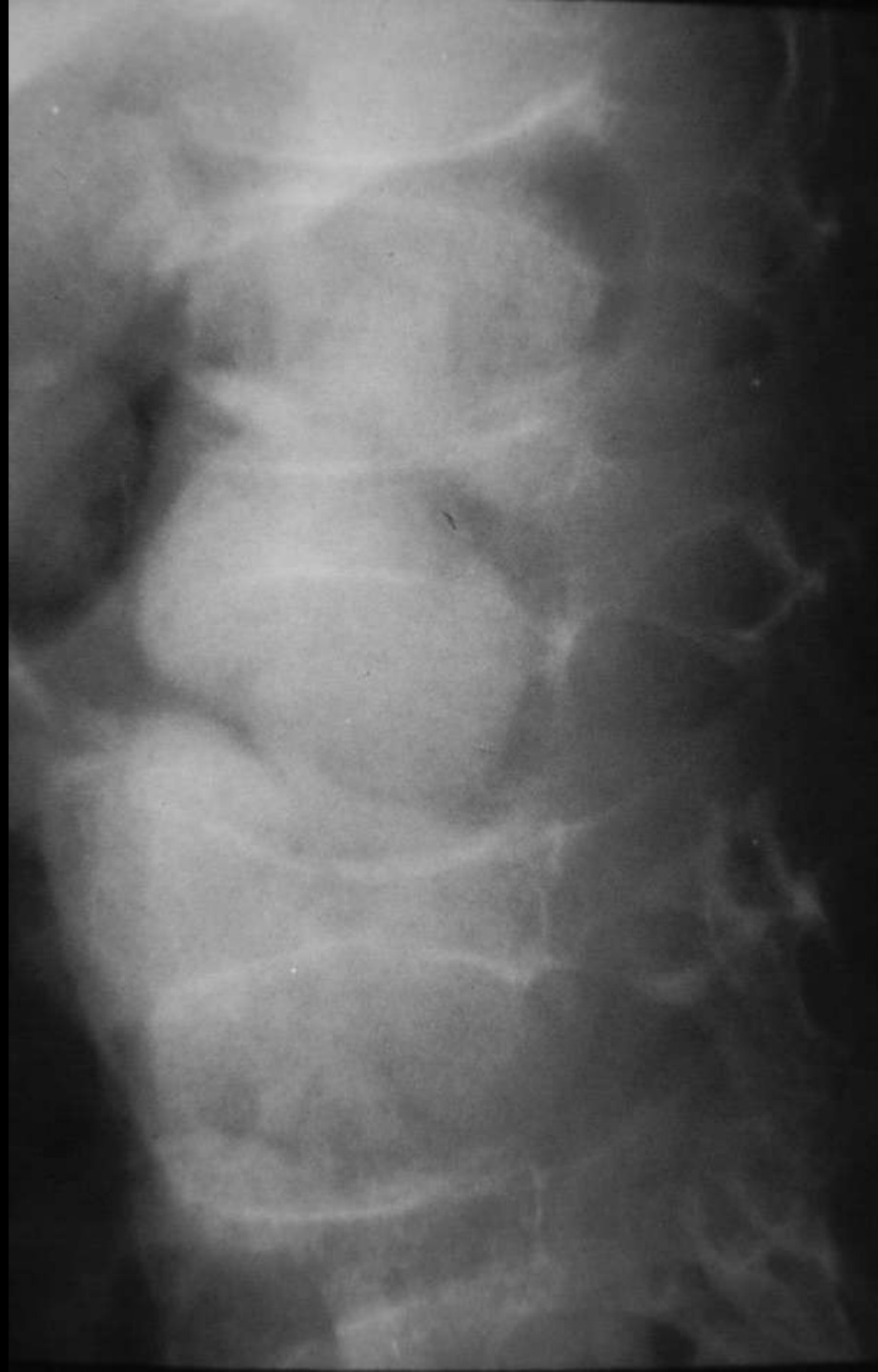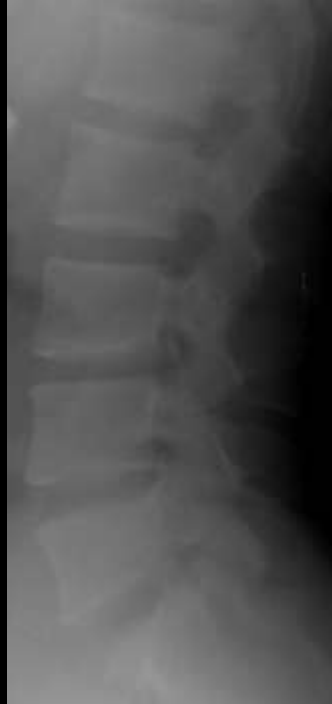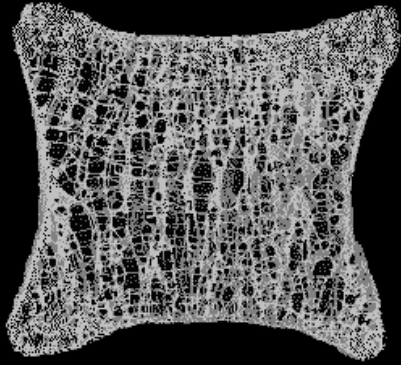




Lincoln log deformity


Sickle cell end plate infarctions





Codfish vertebrae

Osteoporosis



THE CODFISH

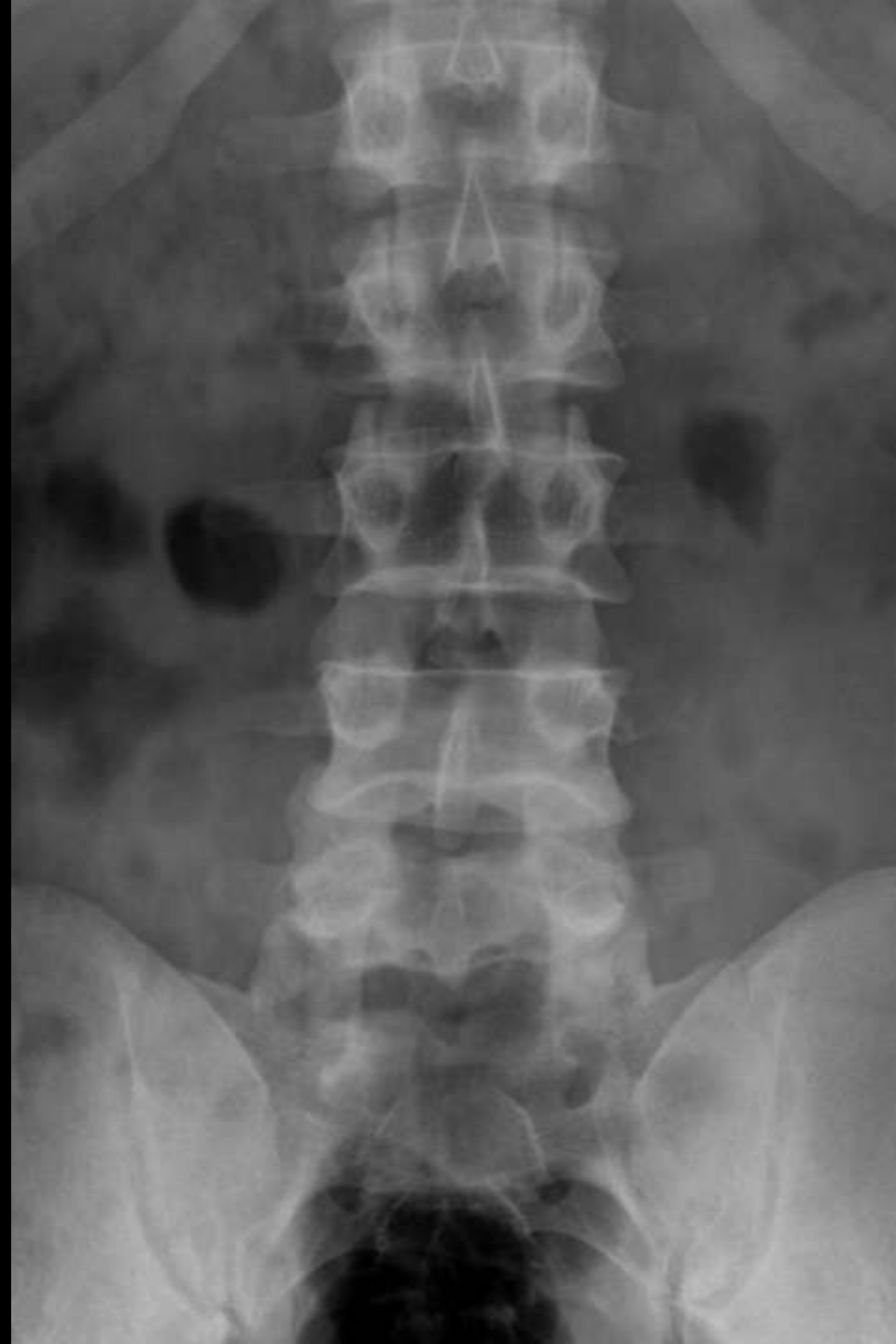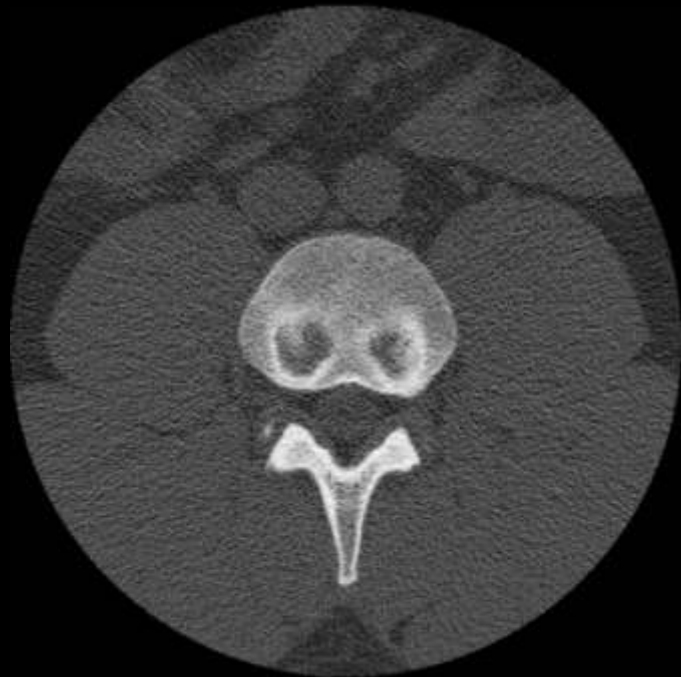Gadus morhua, L. (p. 201)

Illustration by G. S. Davis, from the book 'The Fishes of the United States' (Washington, D.C.: U.S. Government Printing Office, 1907), p. 201.



Cupid's bow sign Normal vertebrae

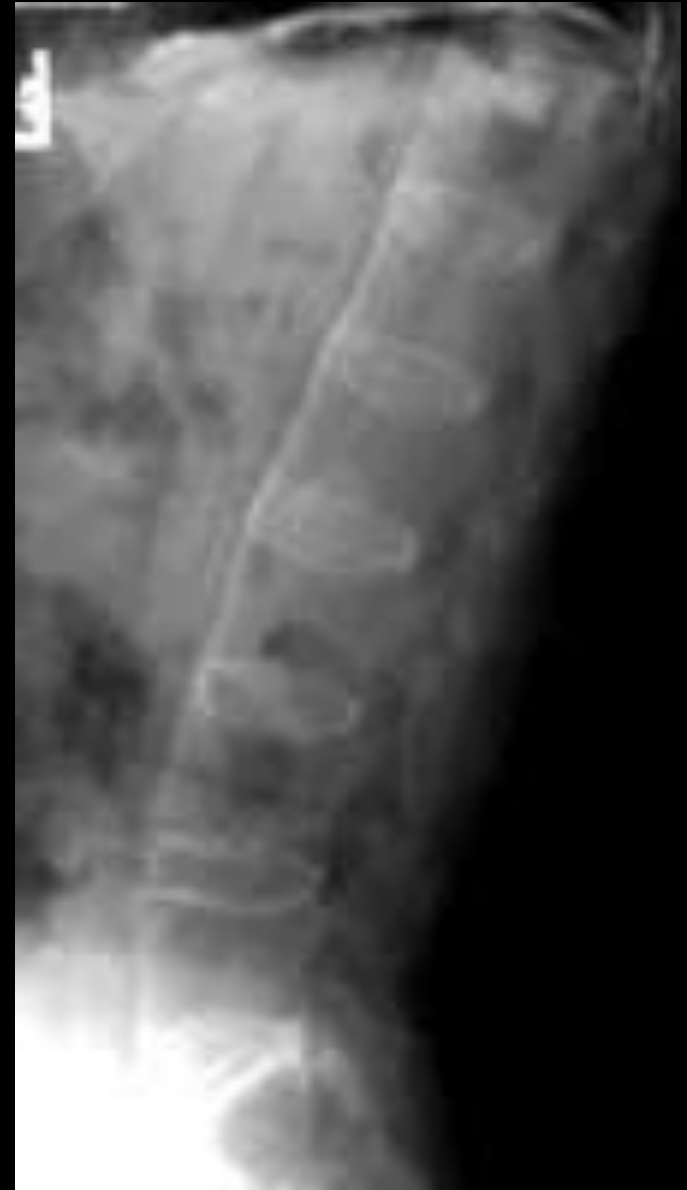93





Bamboo spine

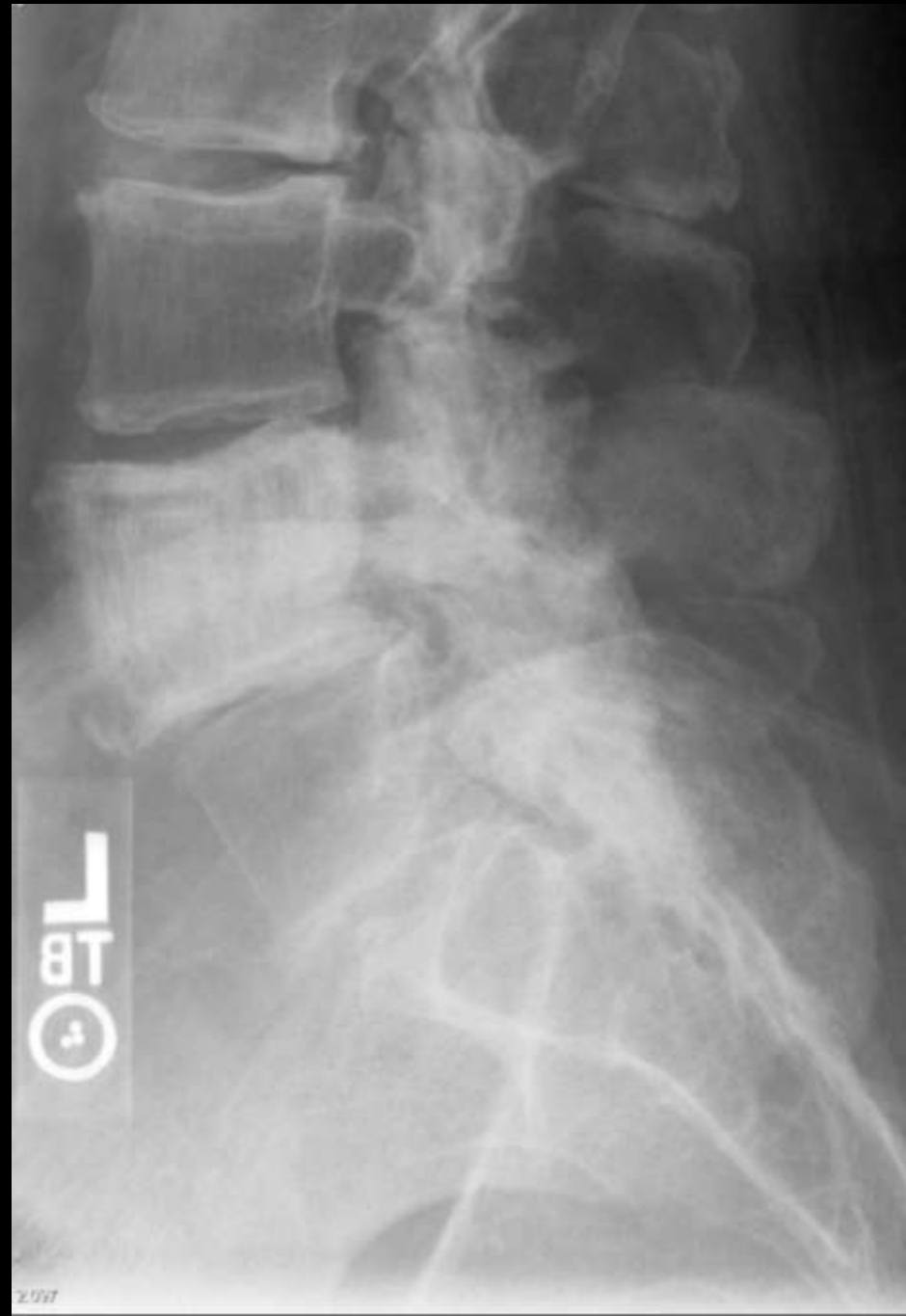Ankylosing spondylitis





Picture frame

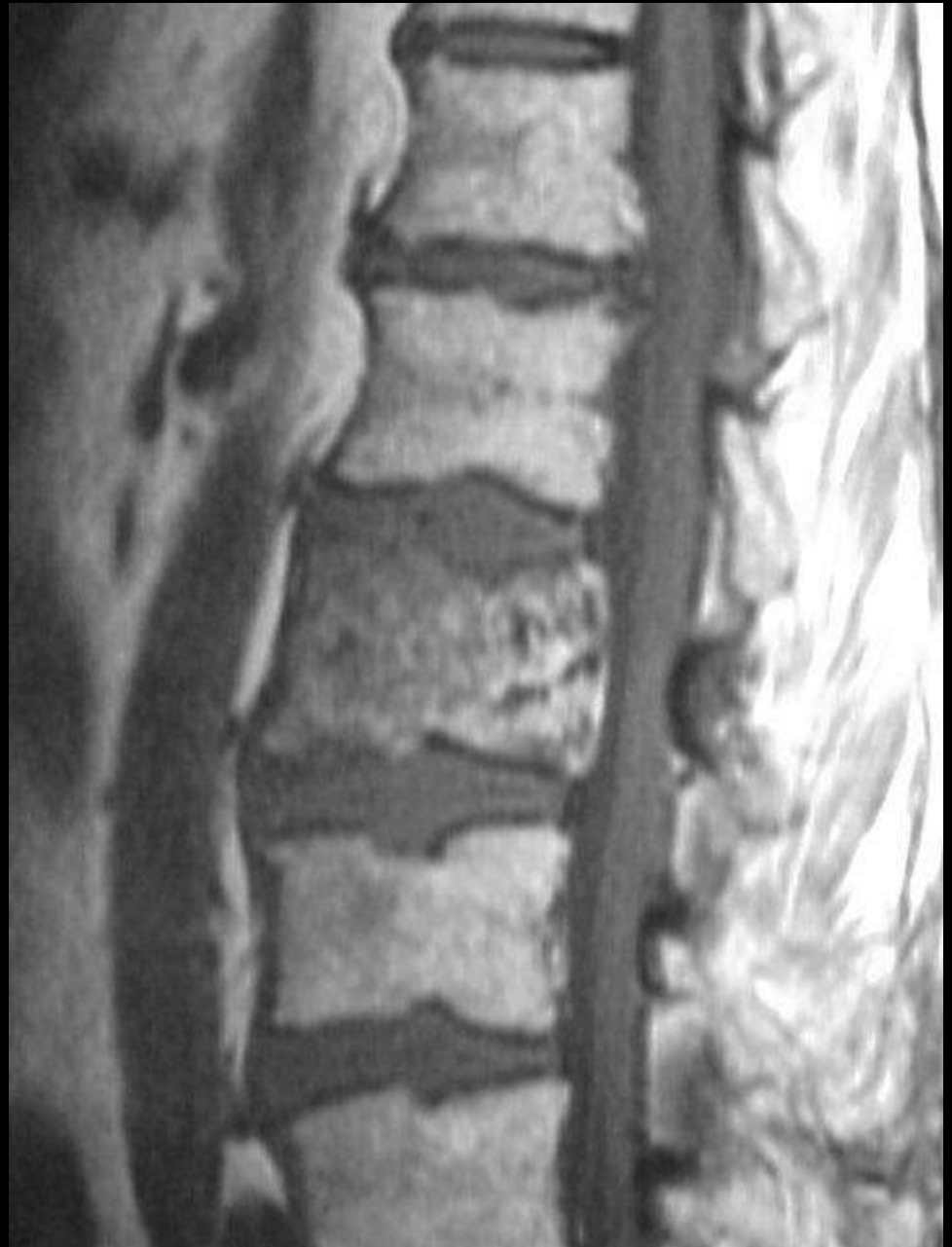Paget's spine

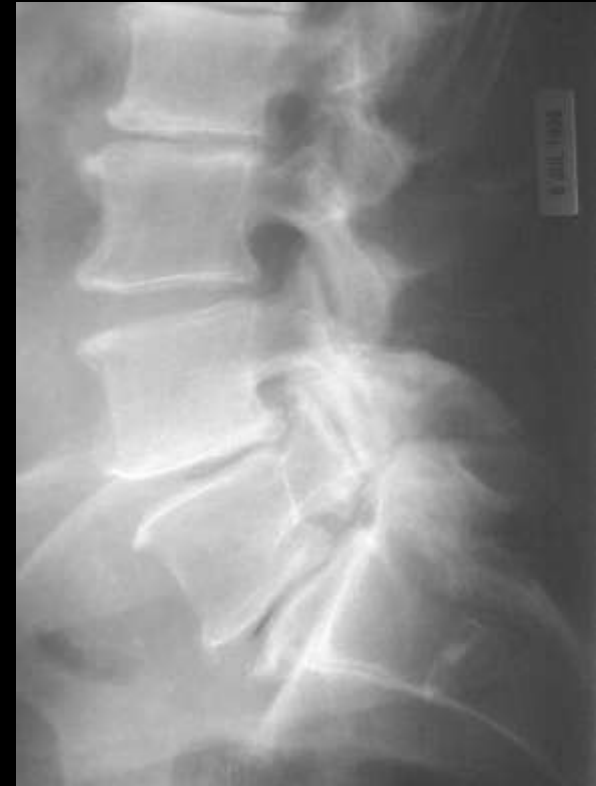
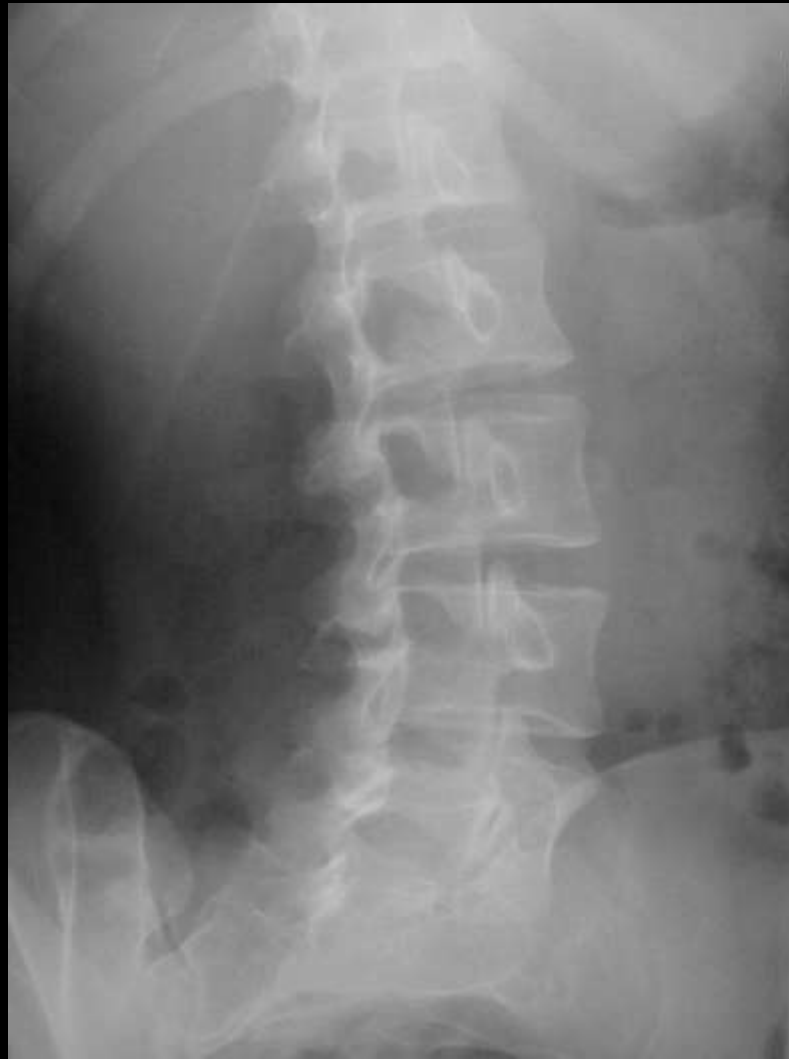
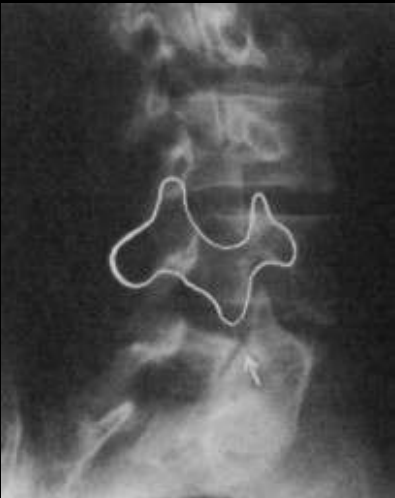

Picture frame

Paget's spine



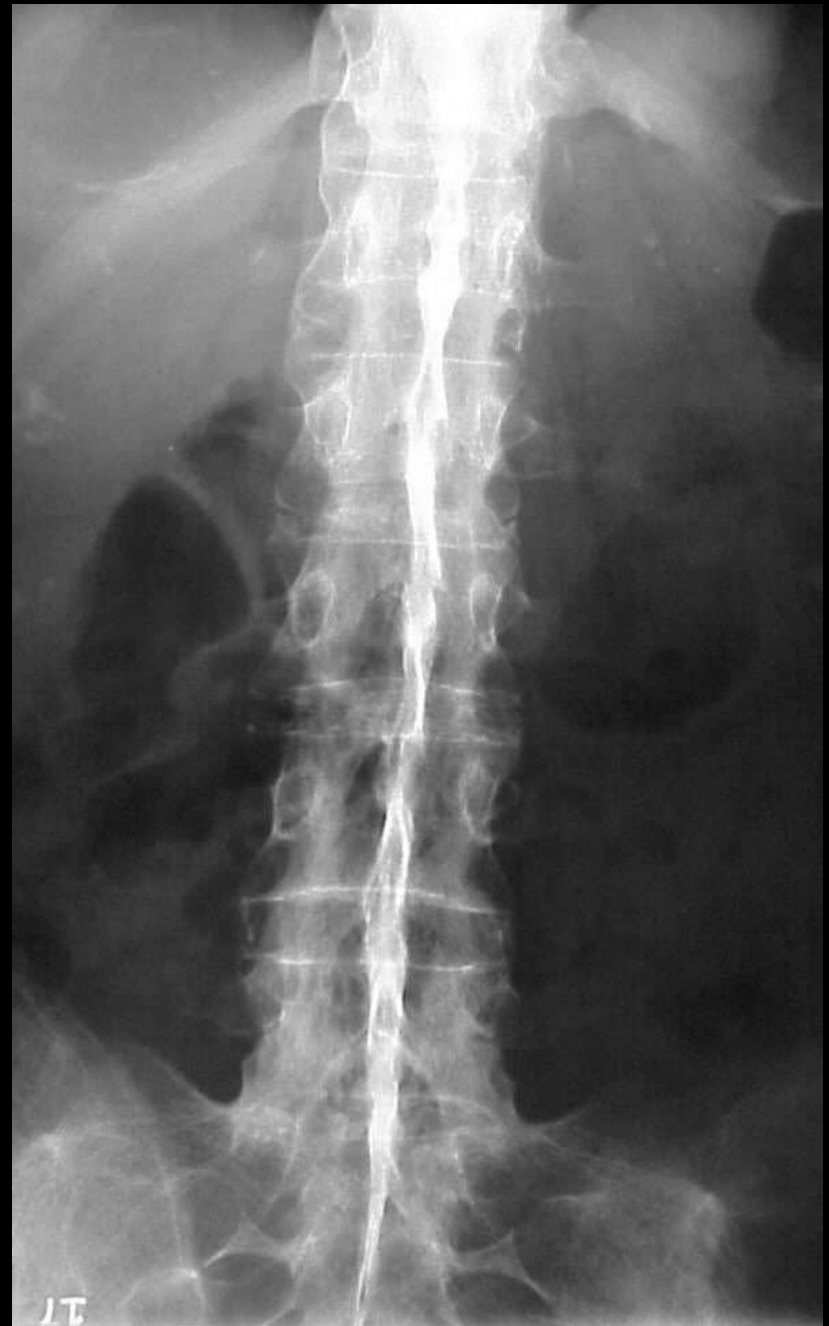

Scotty dog
Pars defects



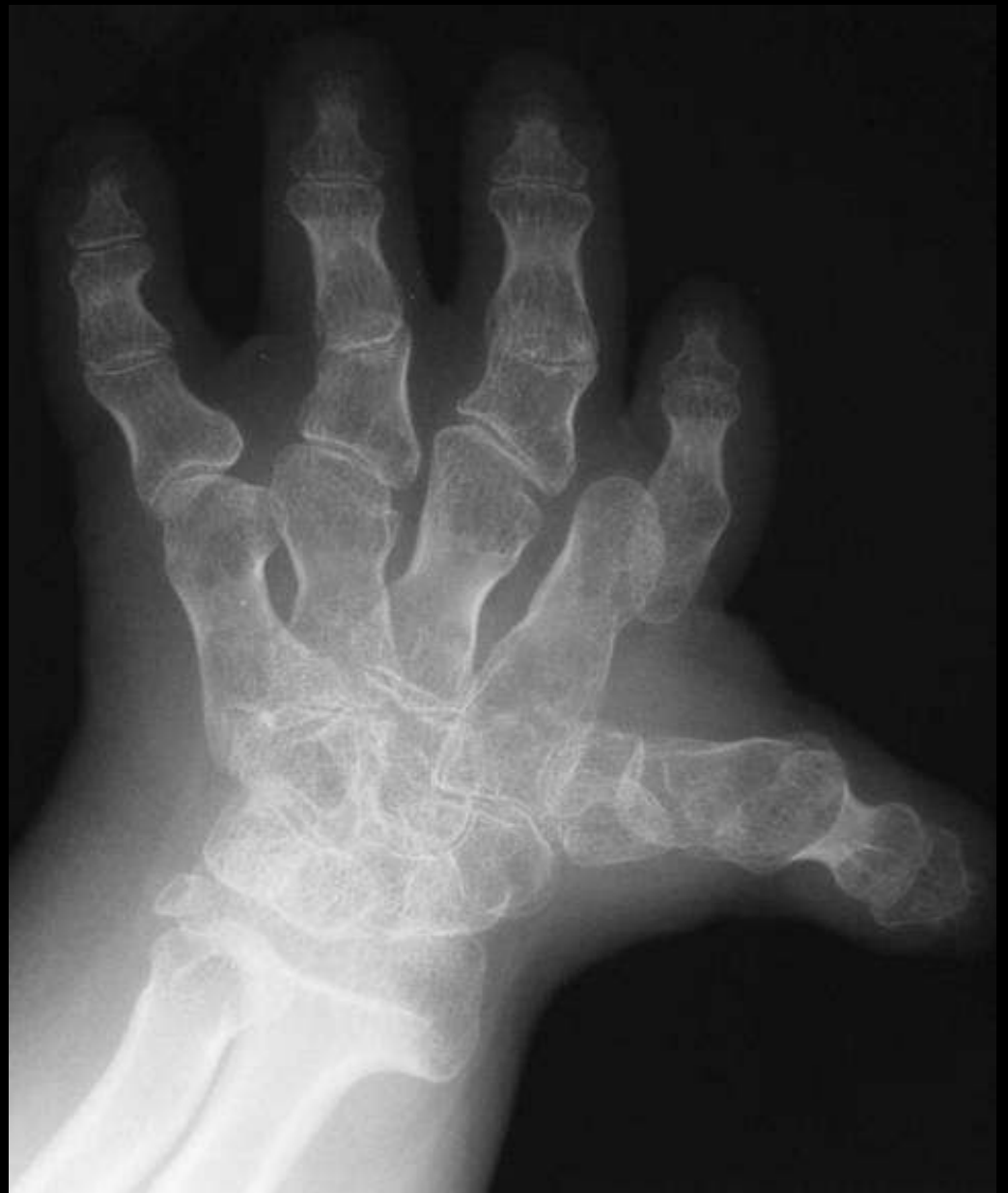Dagger sign

Ankylosing spondylitis



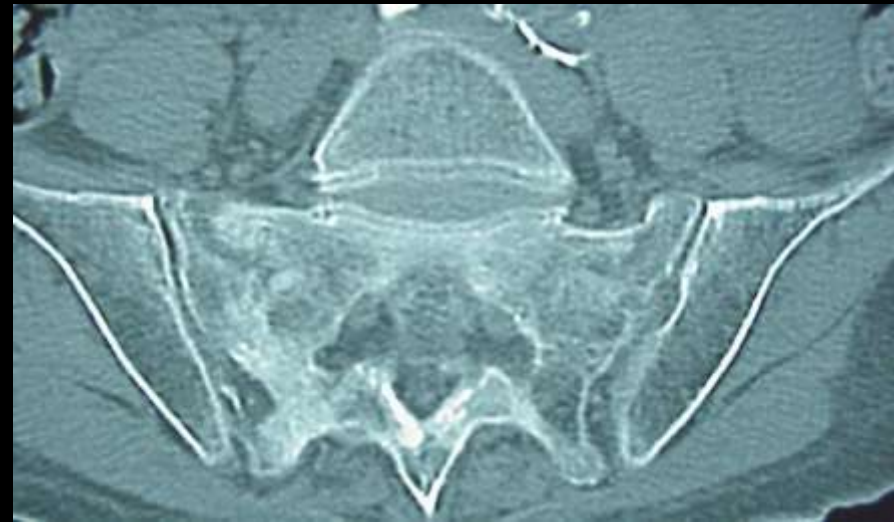
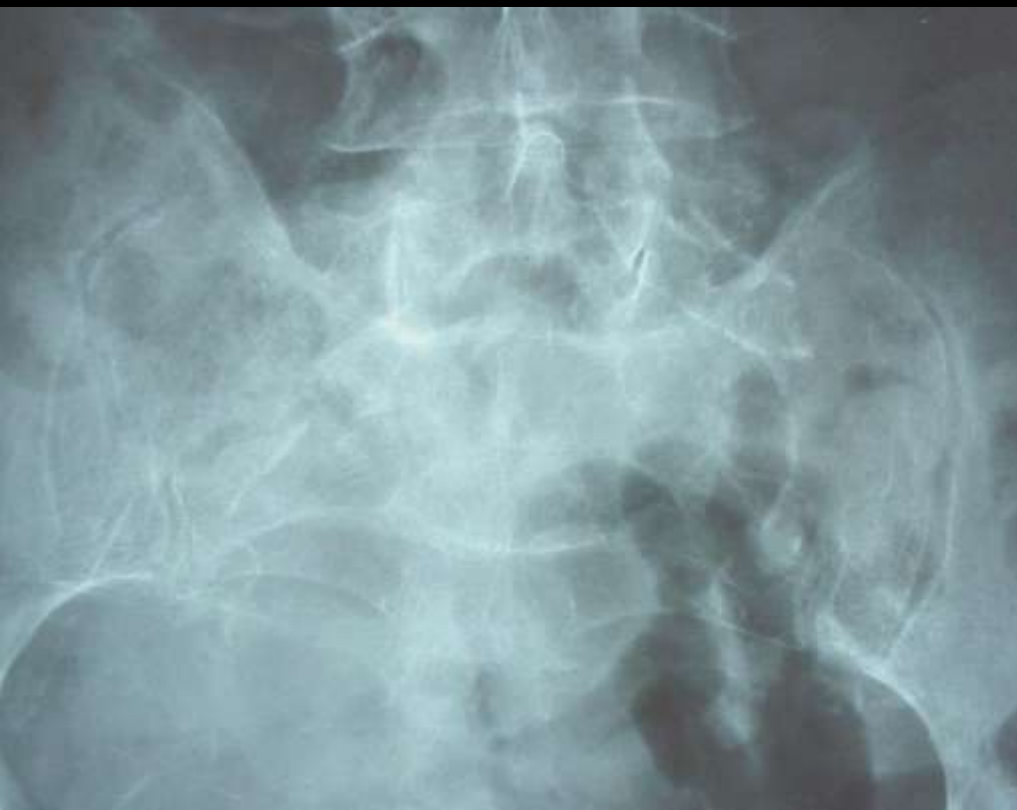
Hitchhiker thumb Diastrophic dwarfism



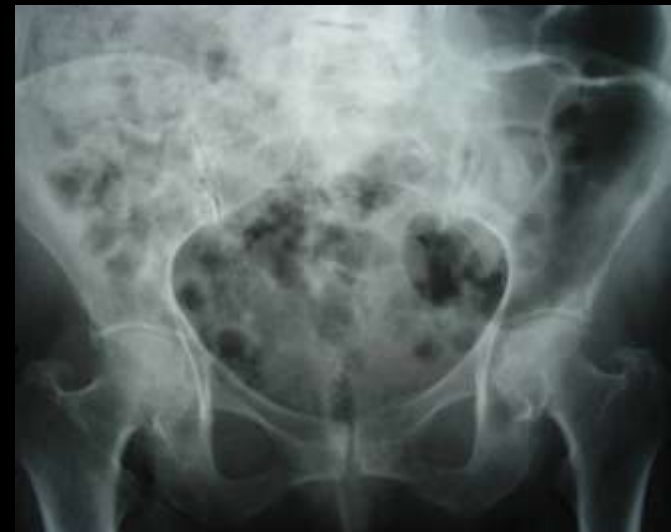
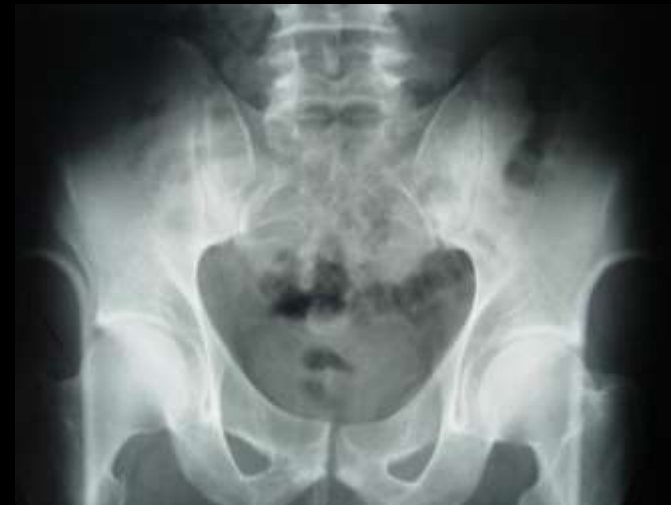
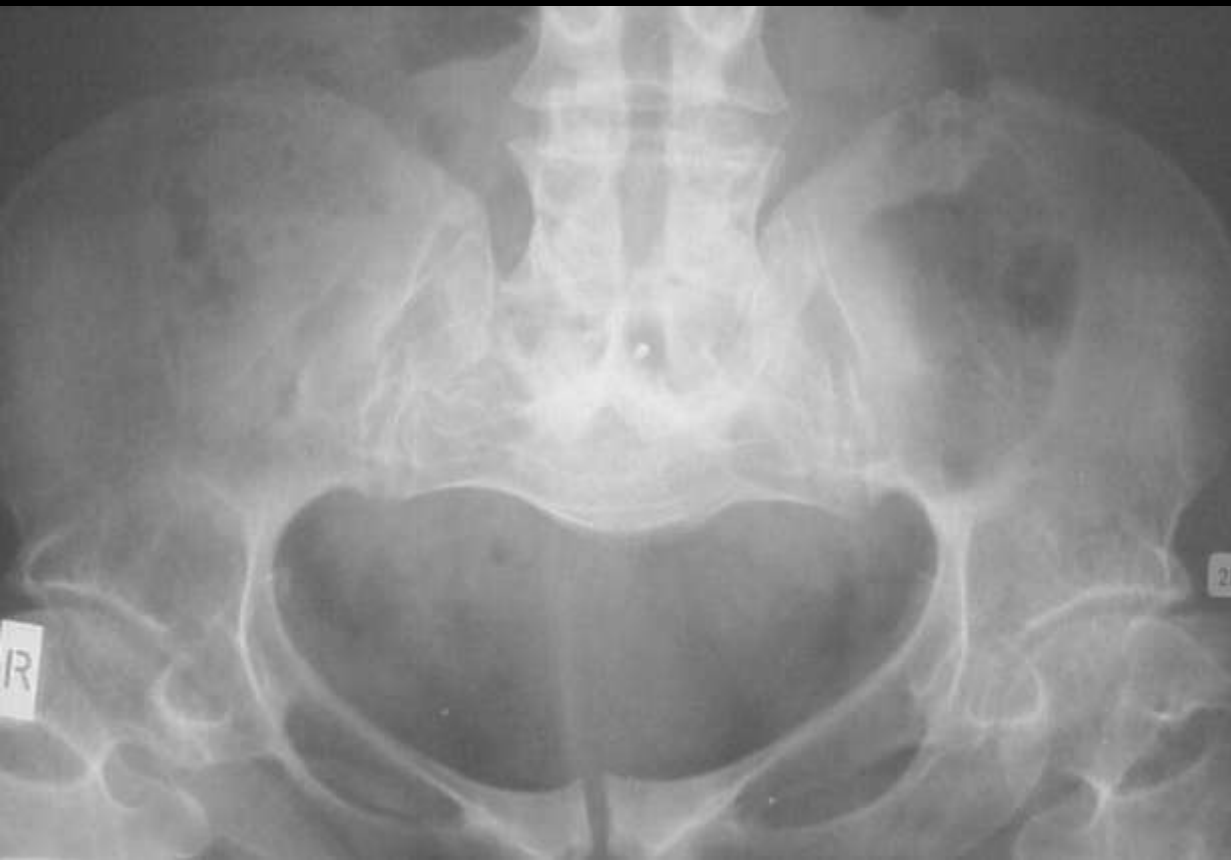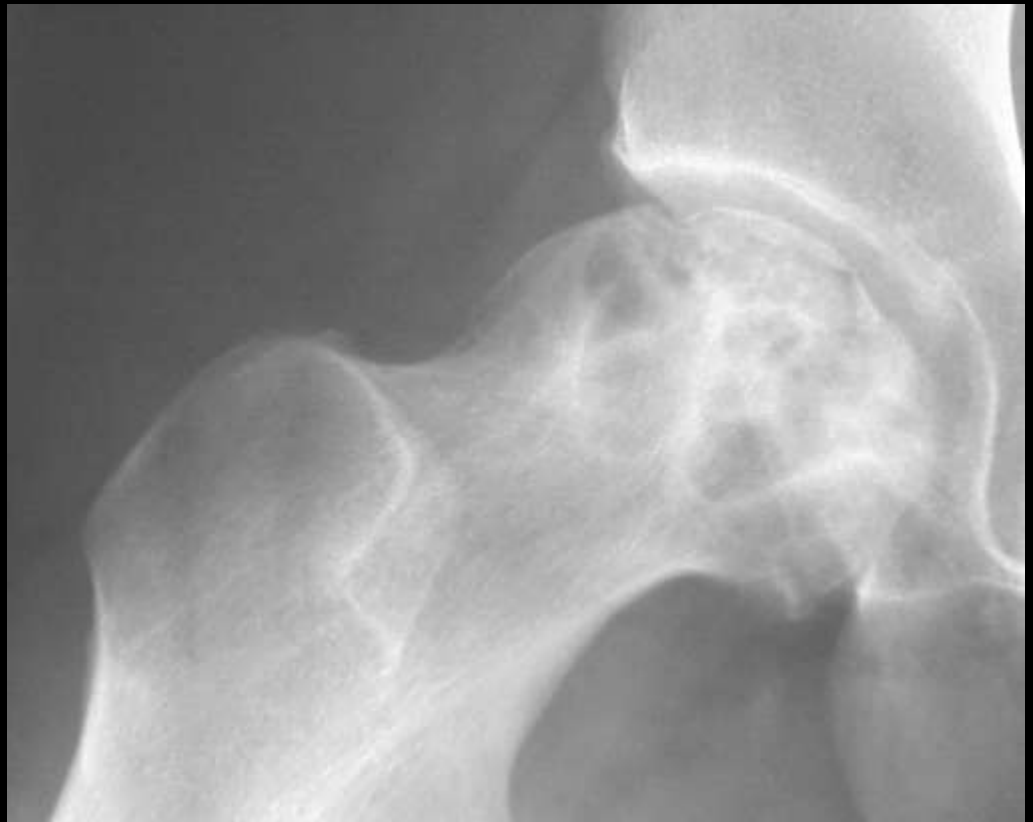Butterfly sacral Fx Insufficiency Fx





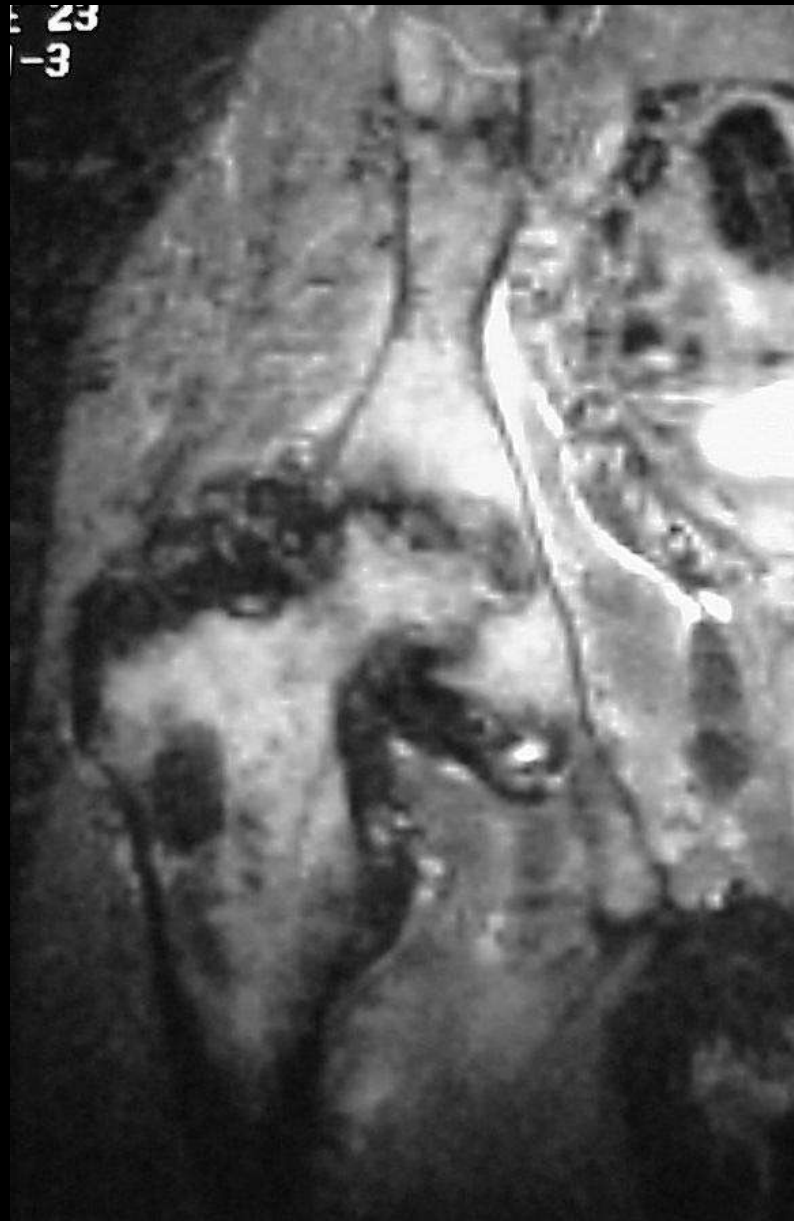Champagne pelvis Achondroplasia





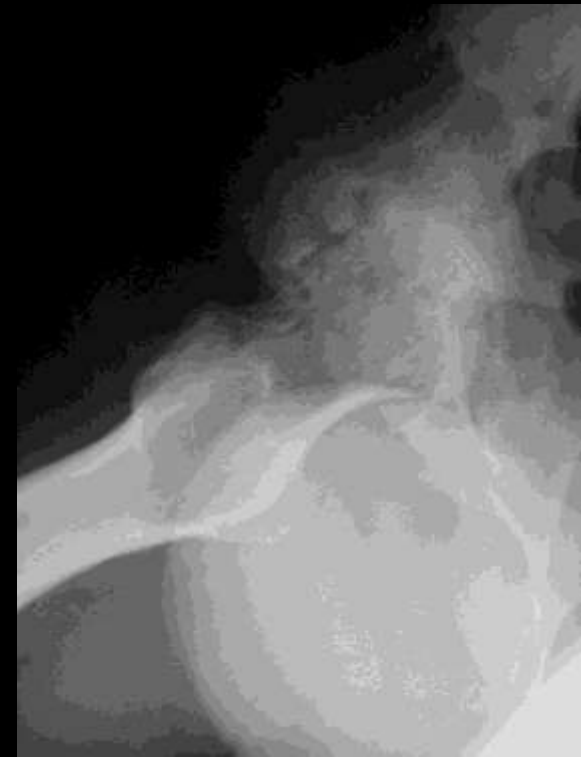Grade III AVN hip
Crescent sign

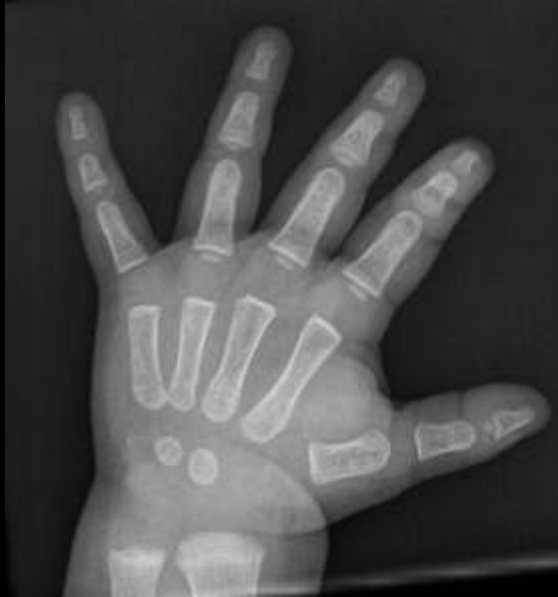



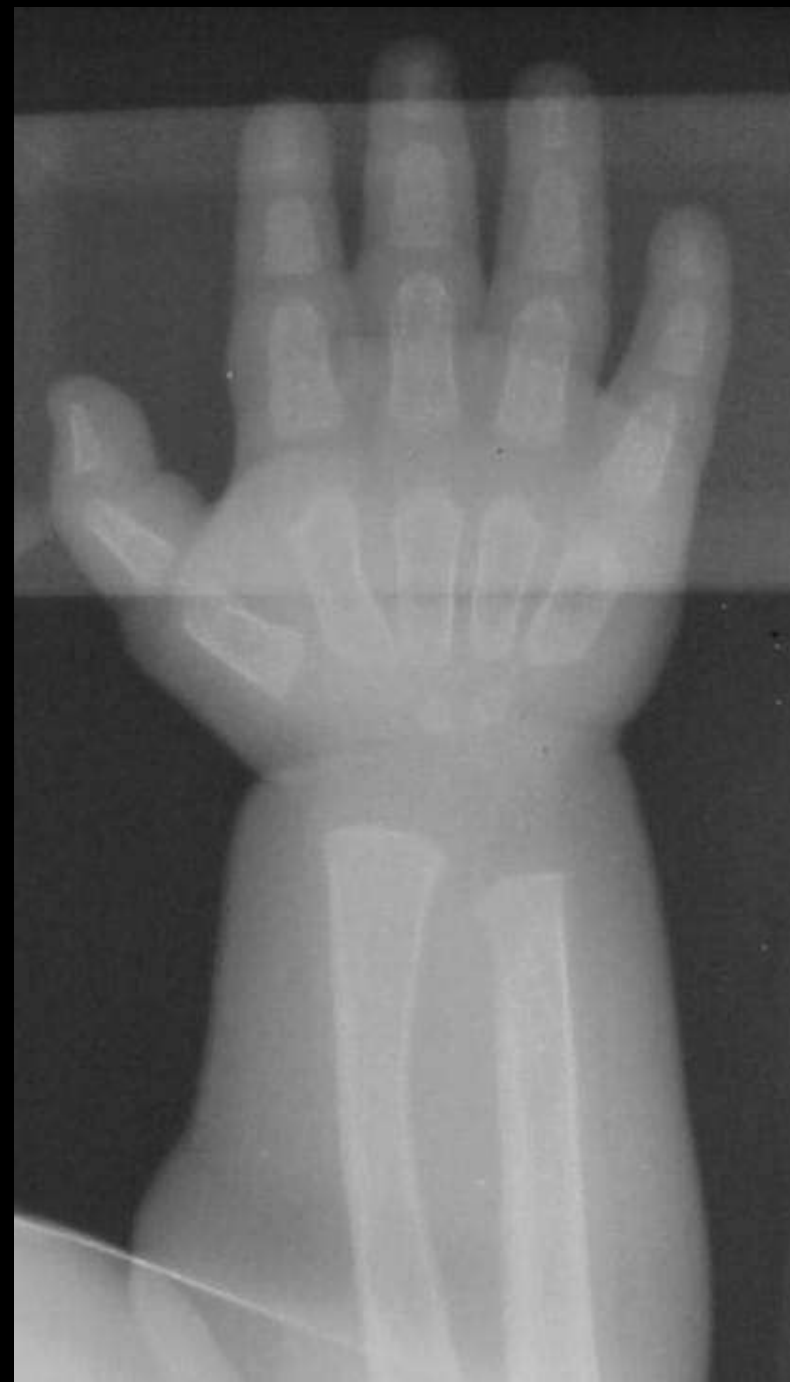Apple core sign

PVNS





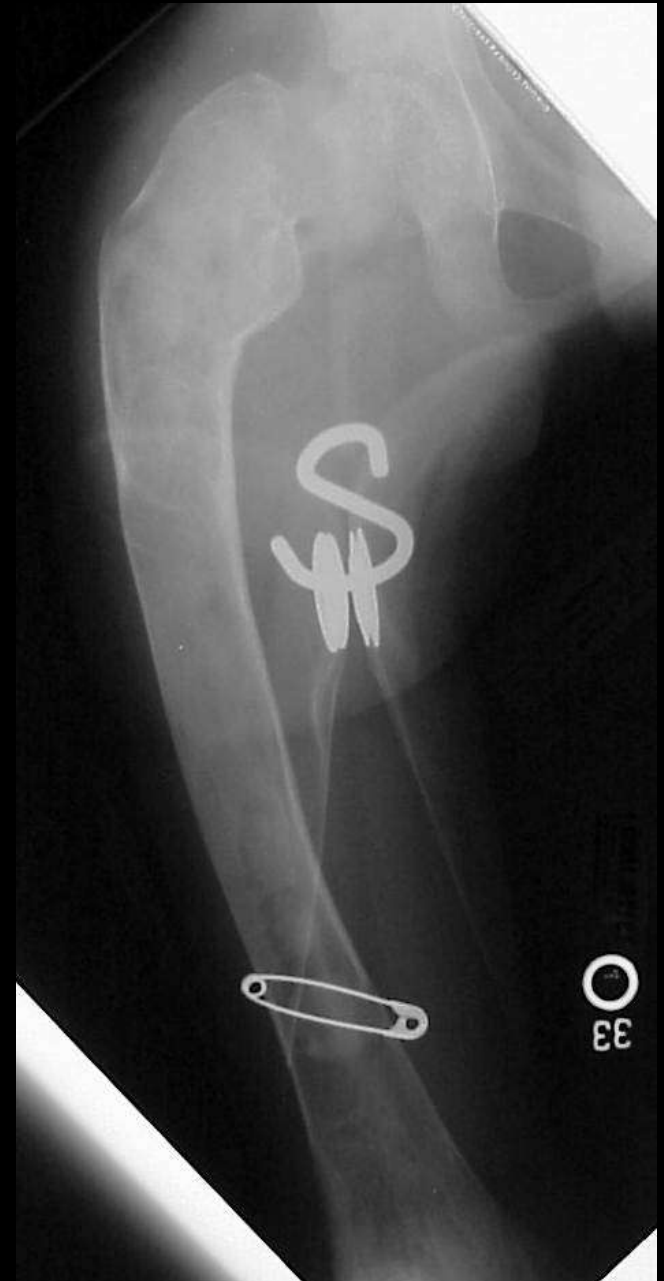Bullet shaped metacarpal
Dysostosis multiplex





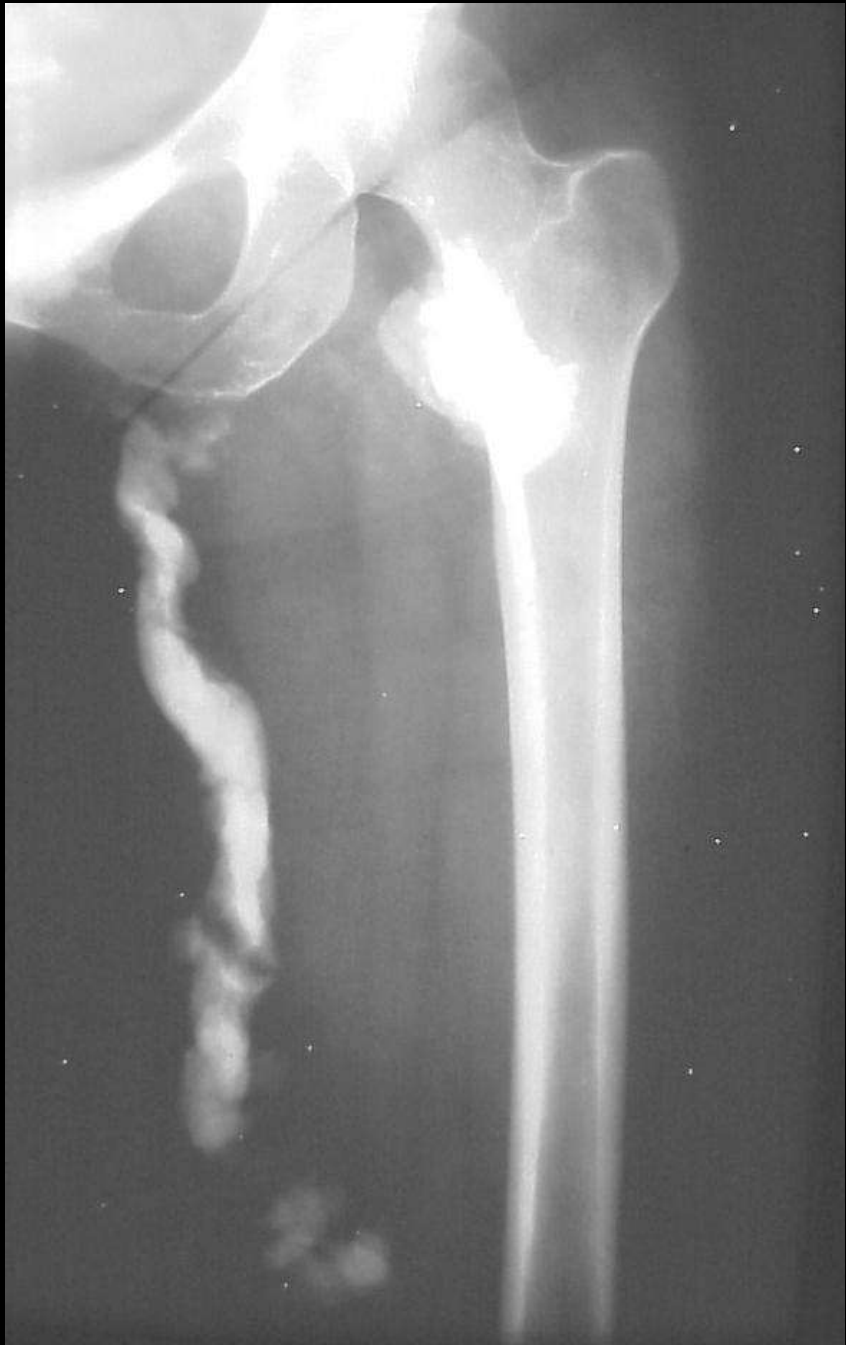Shepherds Crook deformity

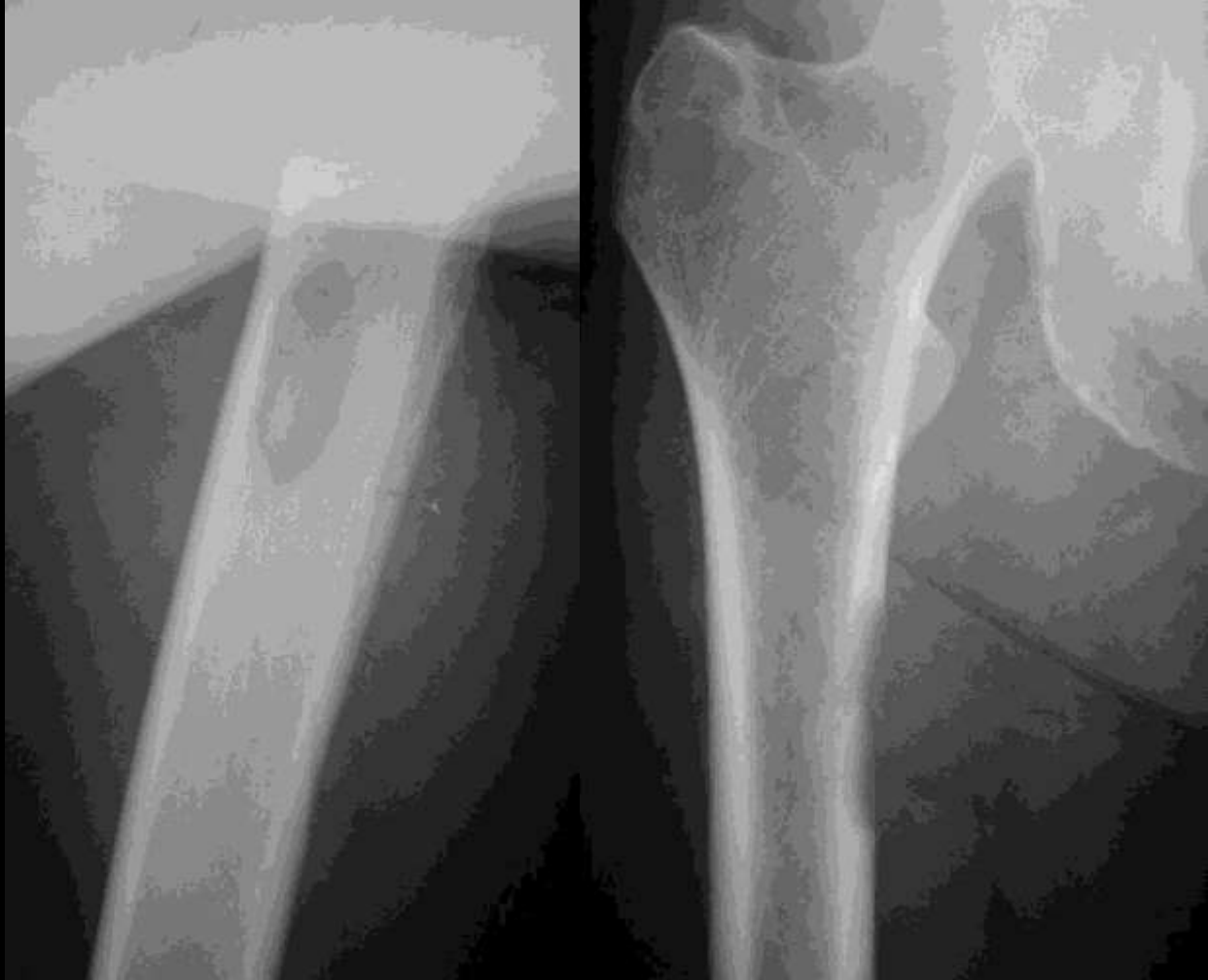Fibrous dysplasia





Dripping candle wax
Melorrrheostosis





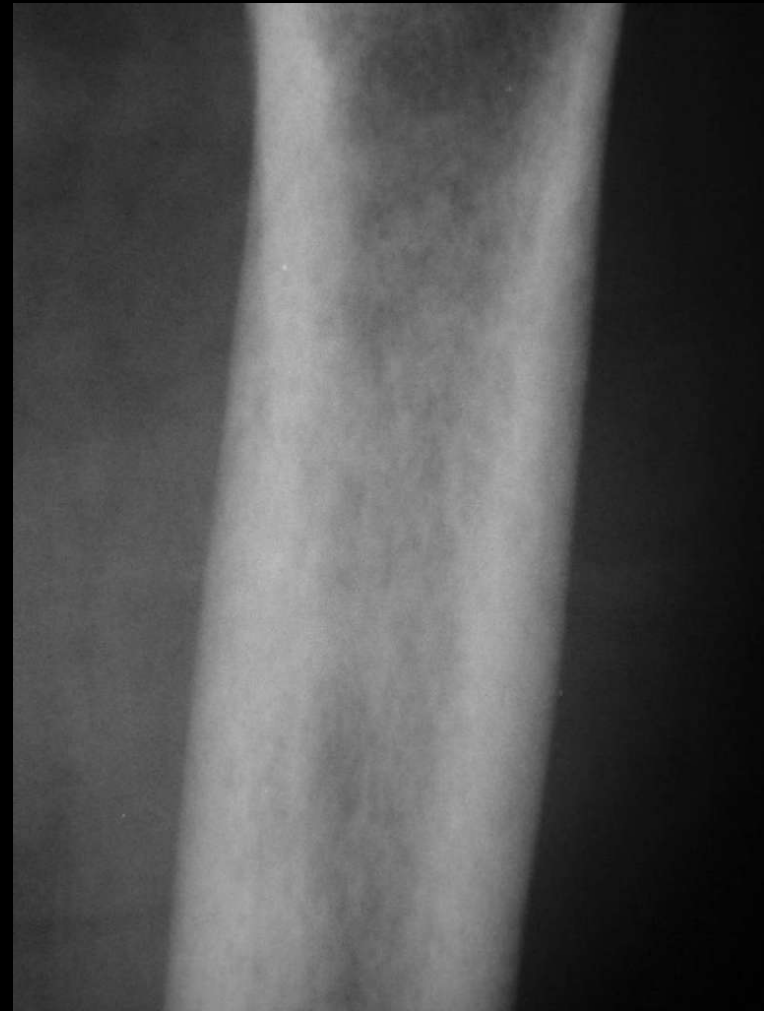
Cookie bite lesion
Cortical mets
Lung or adeno



Rotting Fence Post

Rubella

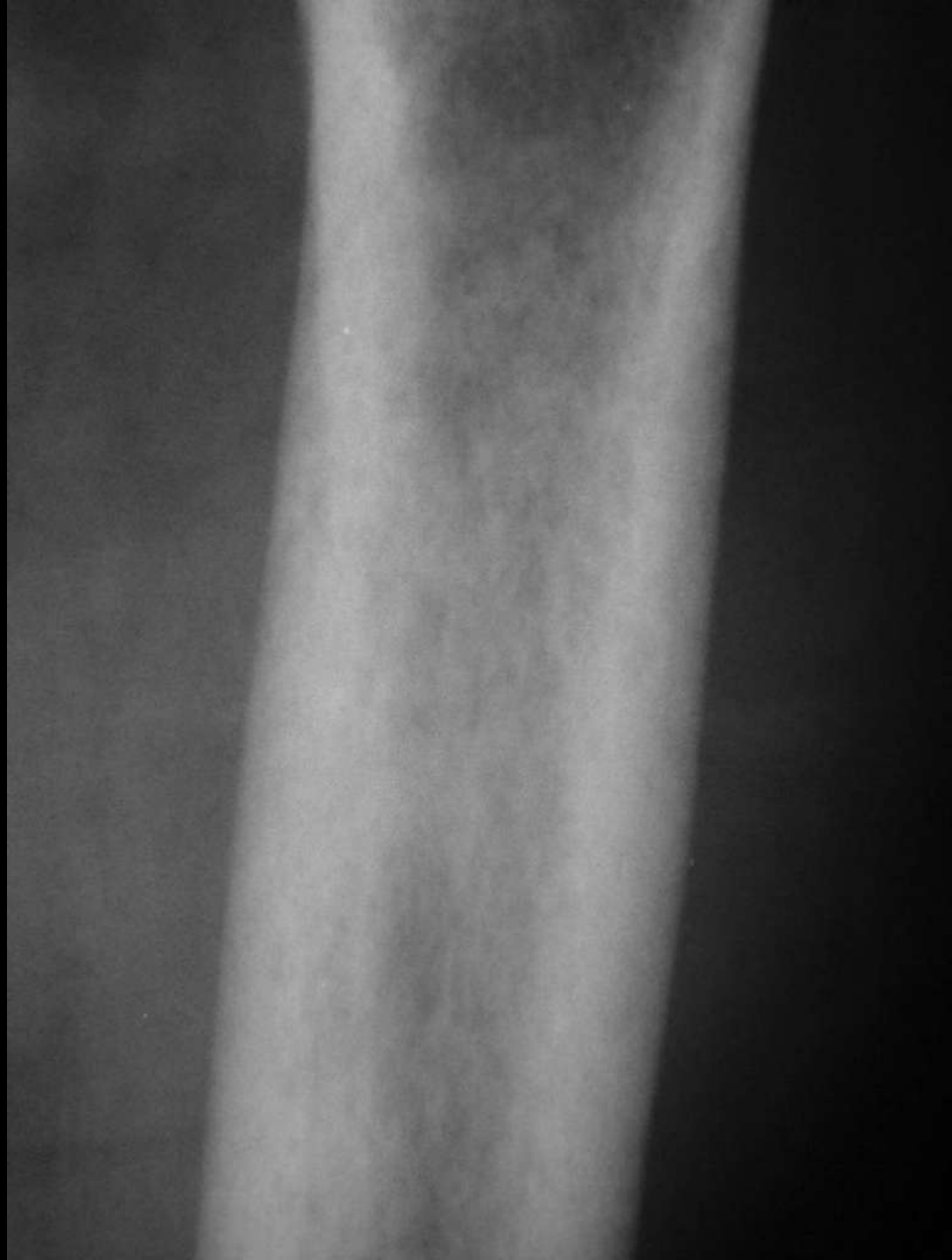HPT

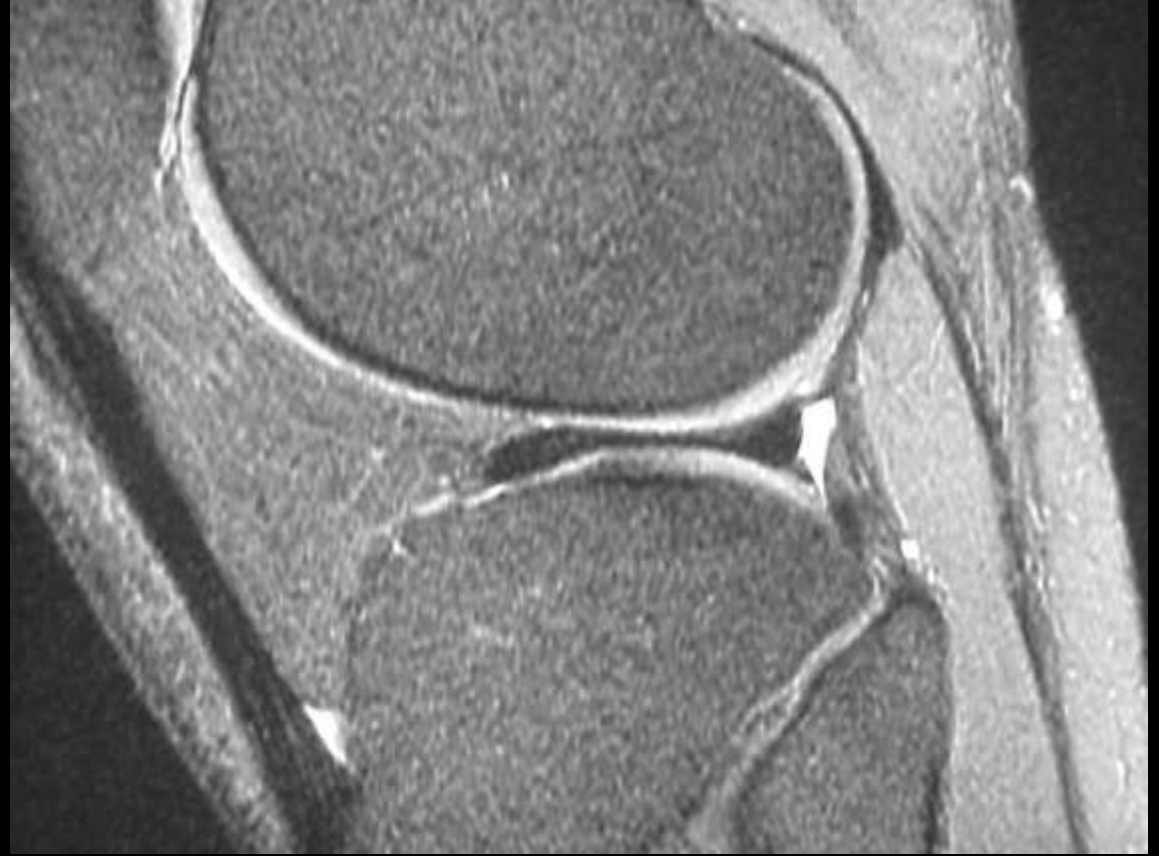



Celery stalk sign

Congenital Rubella

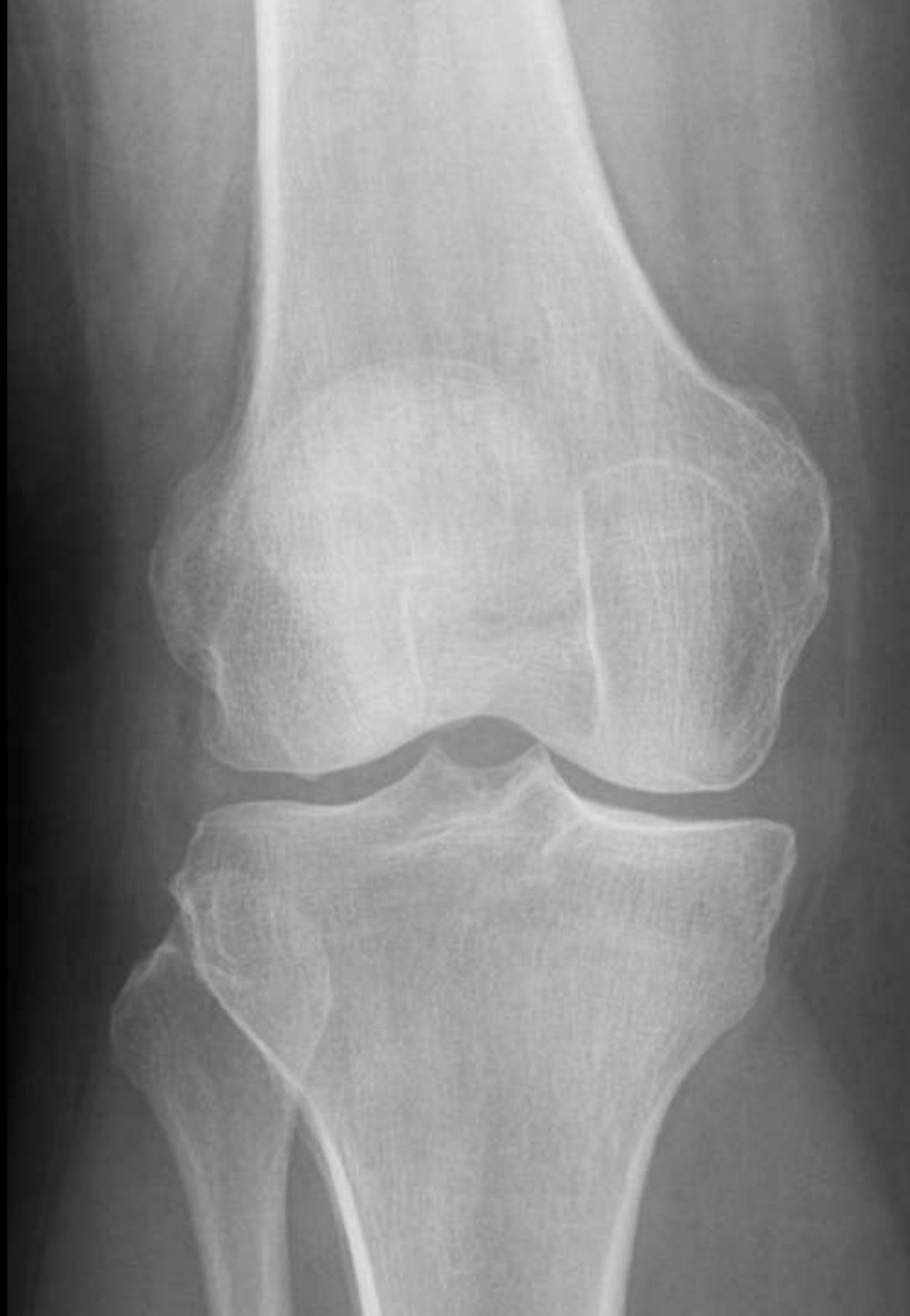


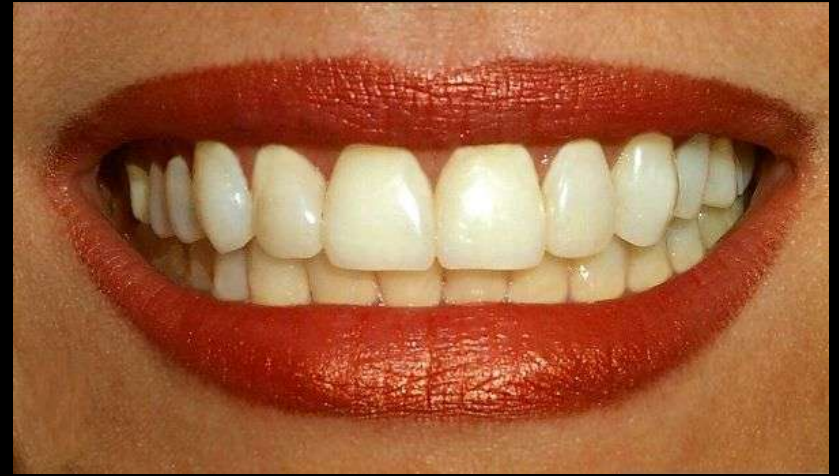
Bow tie sign of
Discoid meniscus

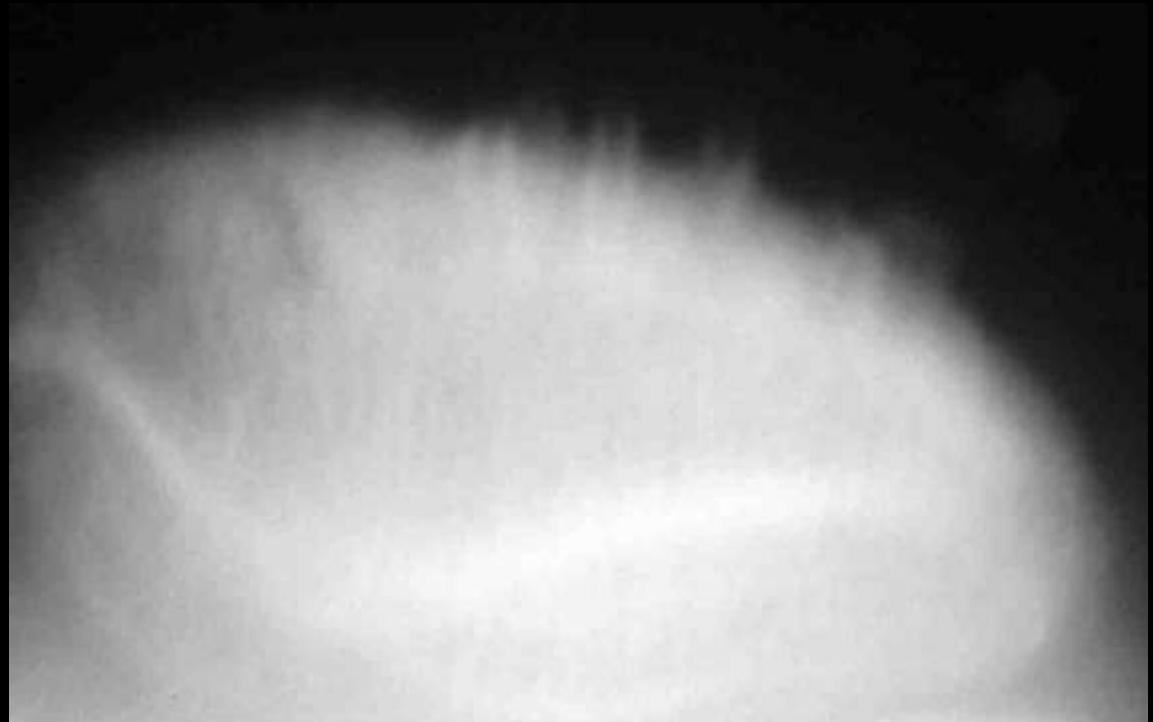


Button osteophyte Osteoarthritis



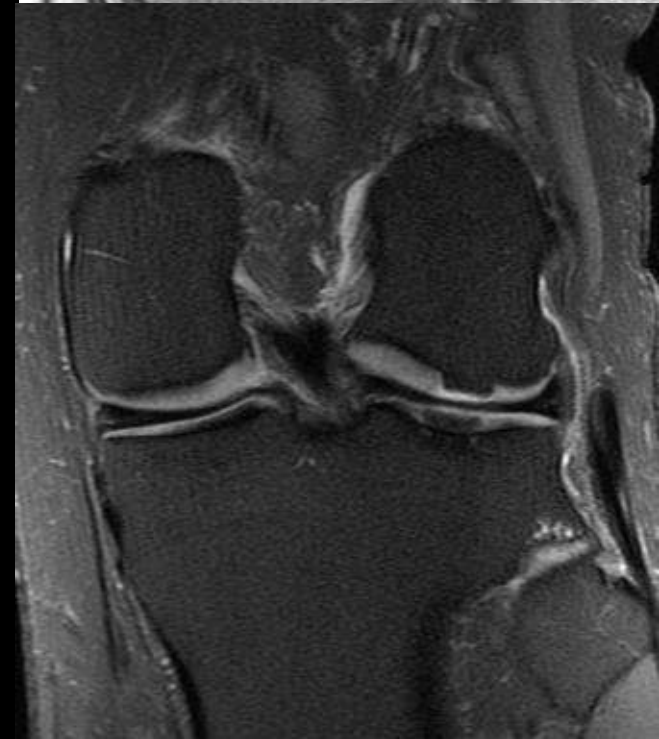
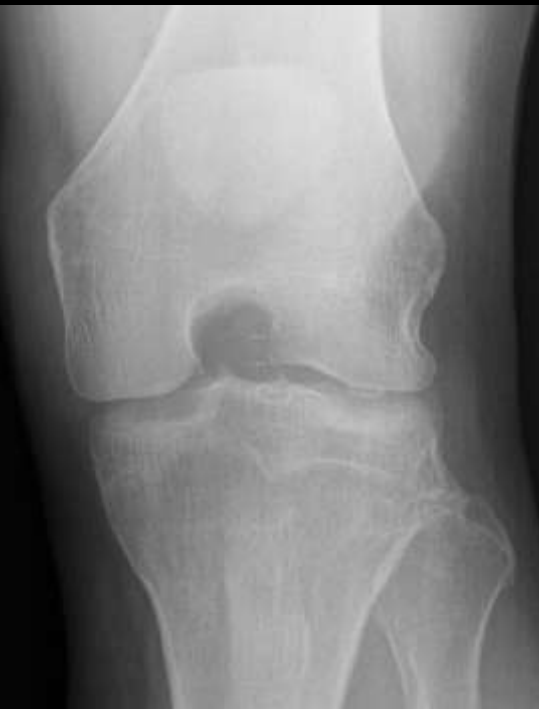
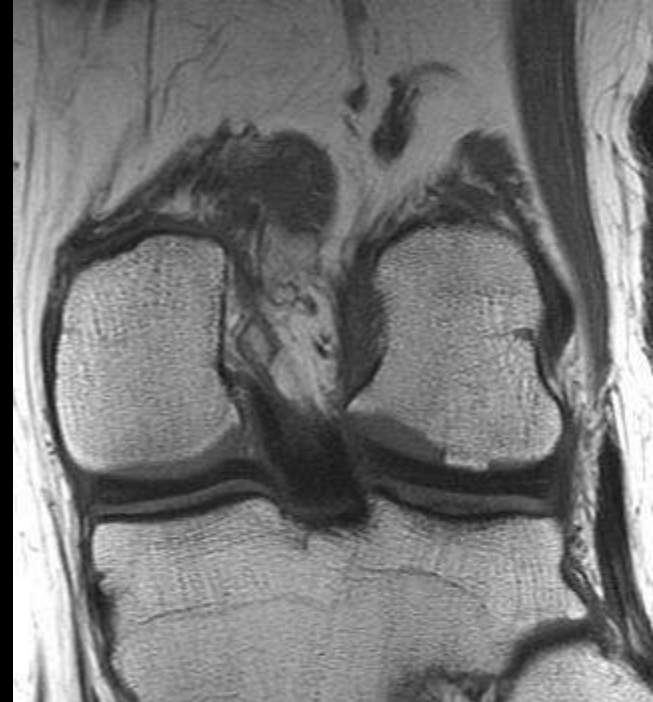
Patella Teeth
Degenerative enthesopathy



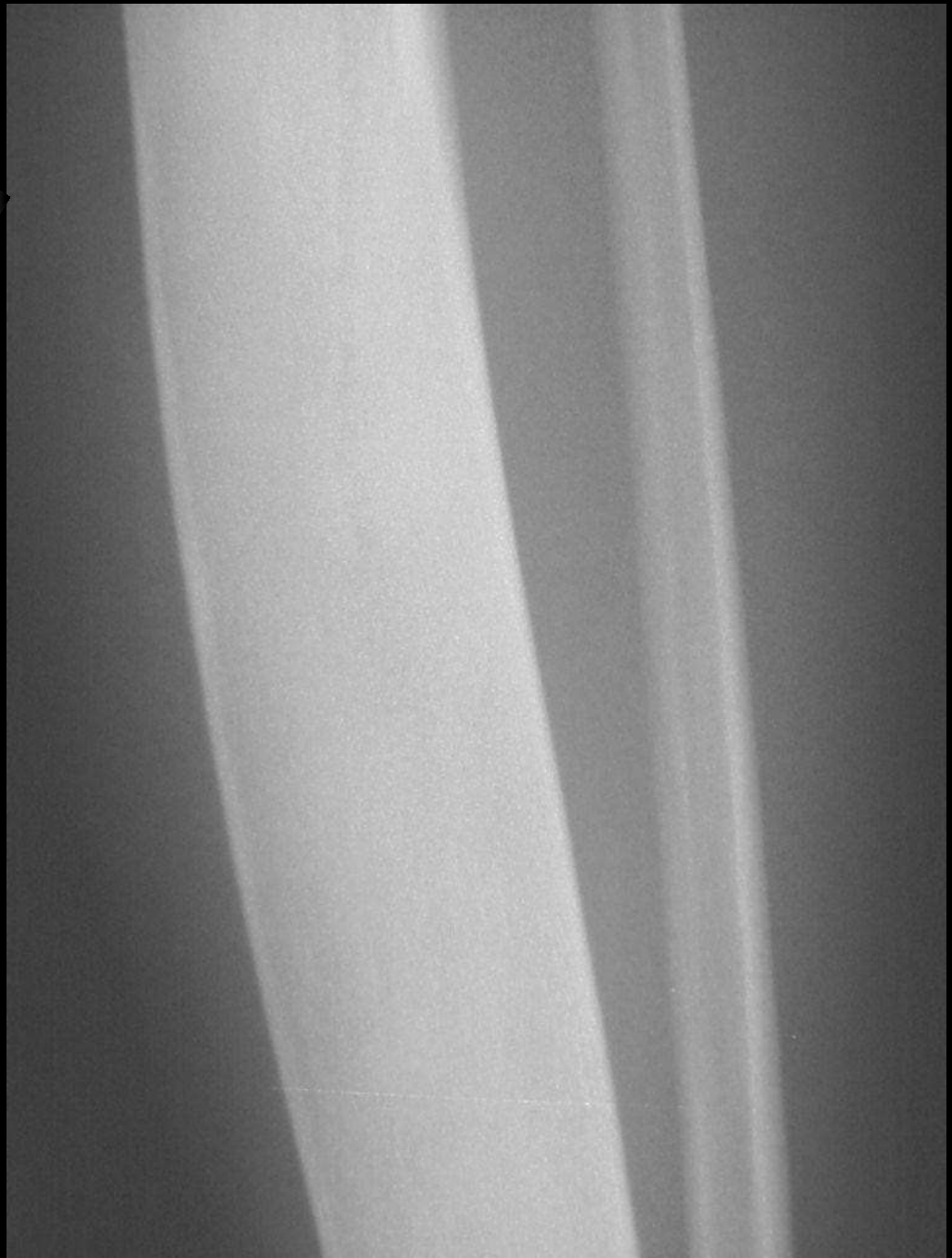

Curtain osteophyte Osteoarthritis



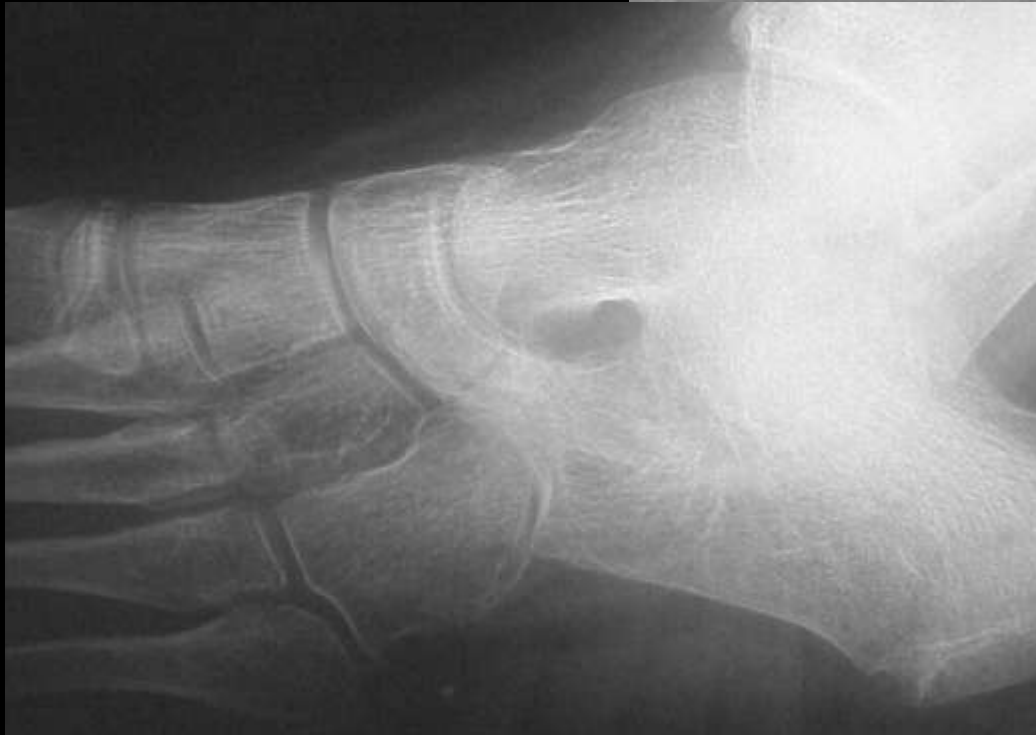
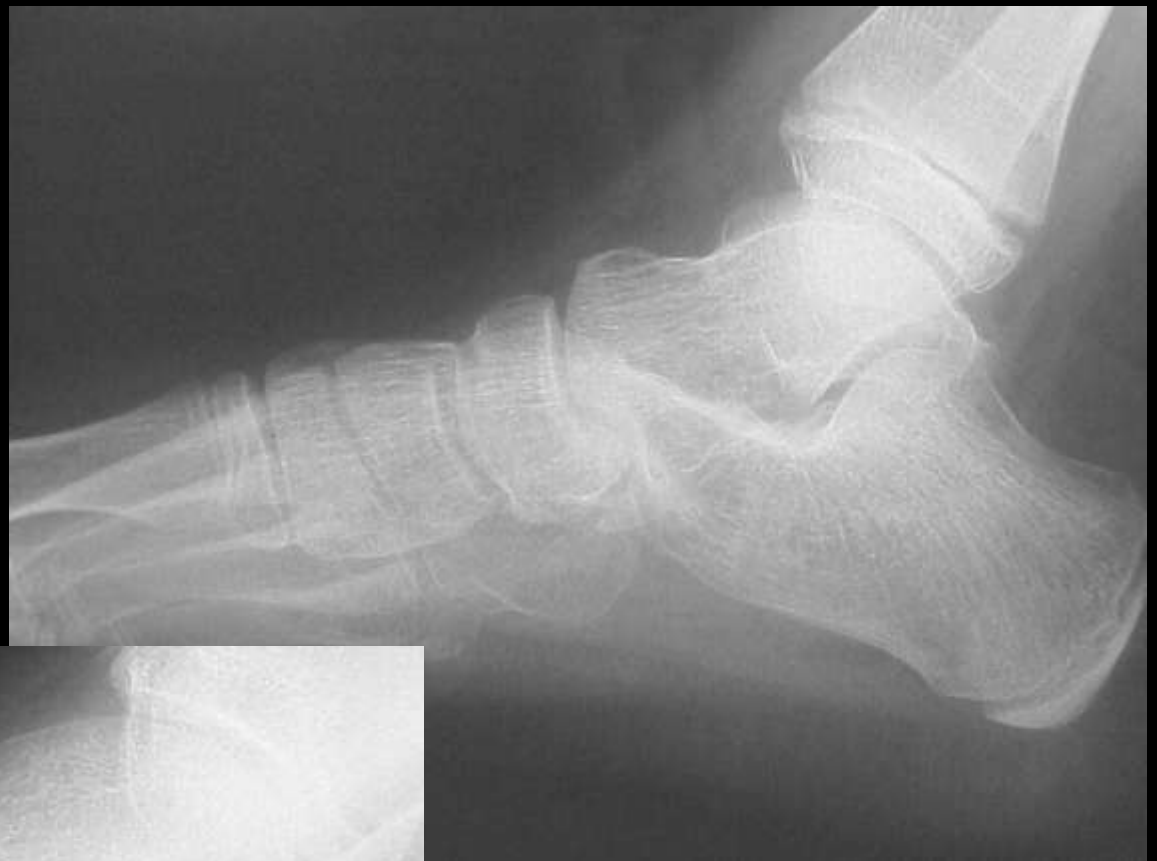
Ground glass
Fibrous dysplasia



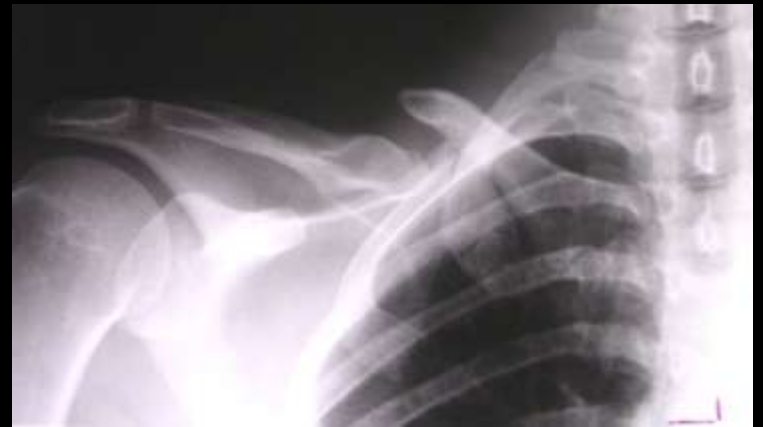
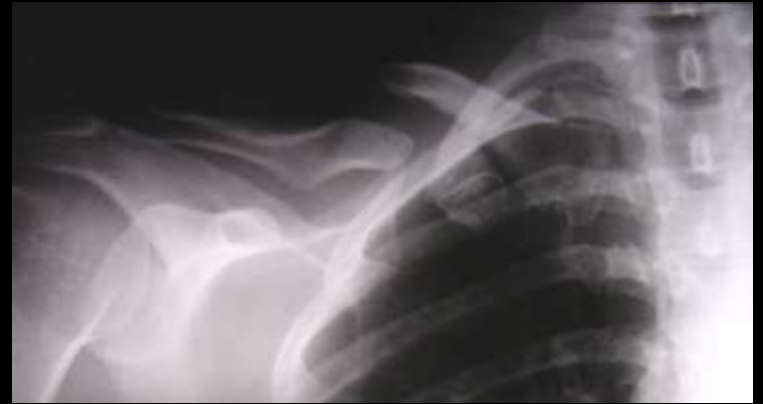
Anteater sign
Calcaneonavicular
coalition



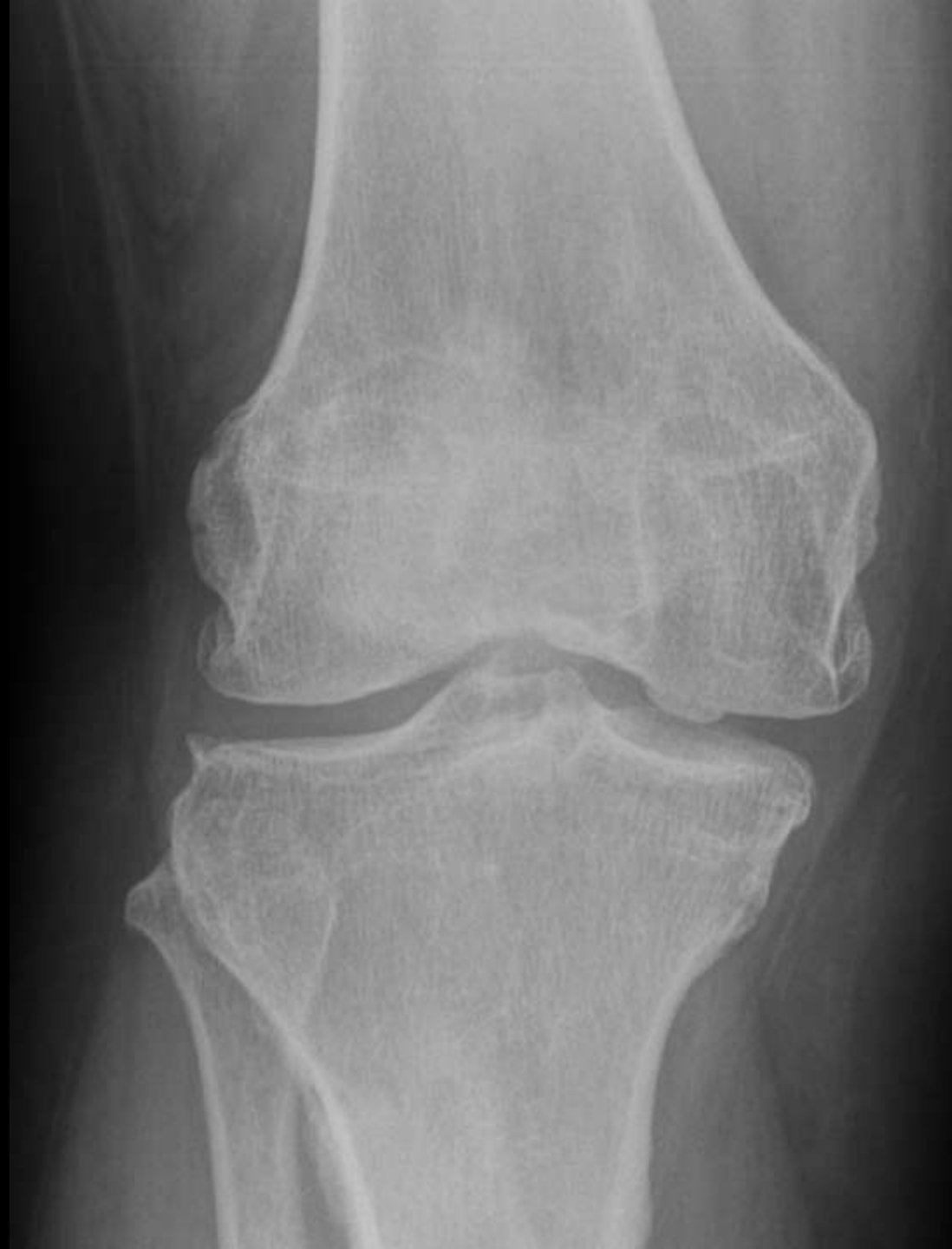

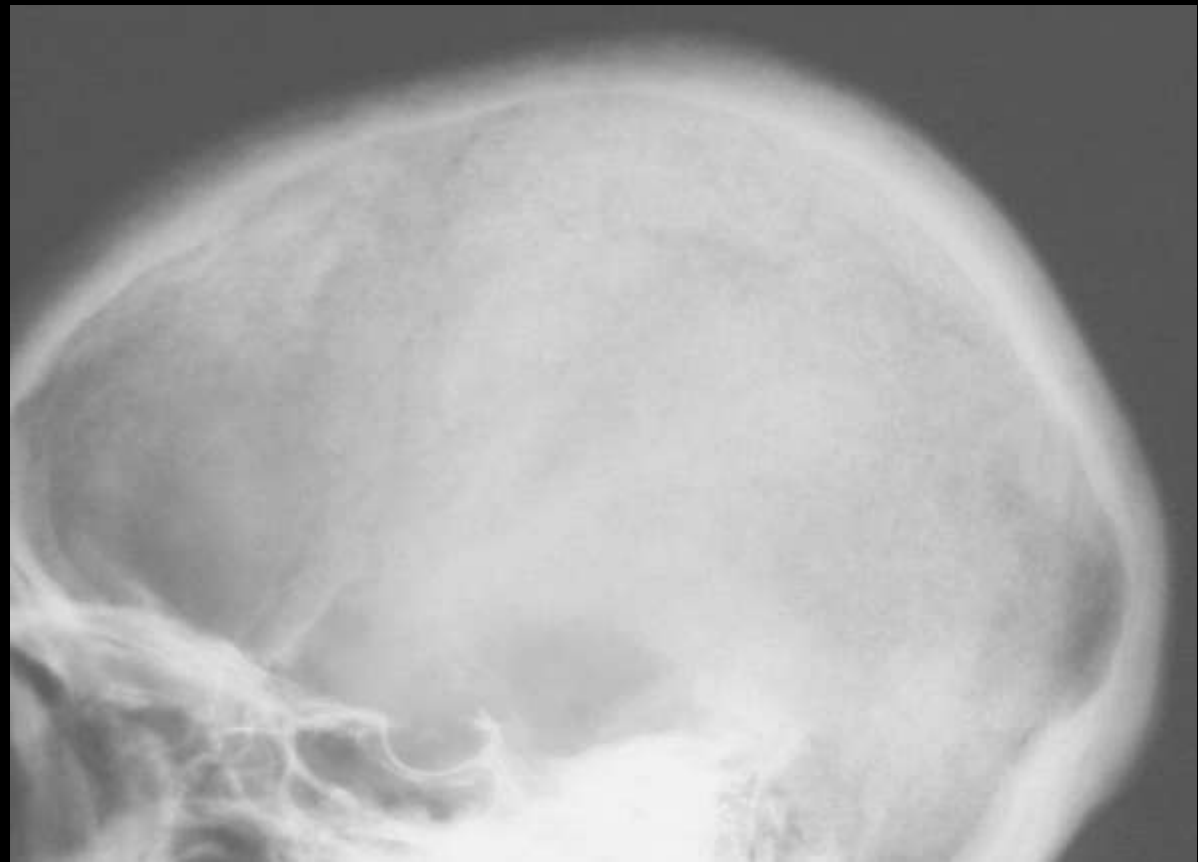
Bayonet deformity Clavicle fracture





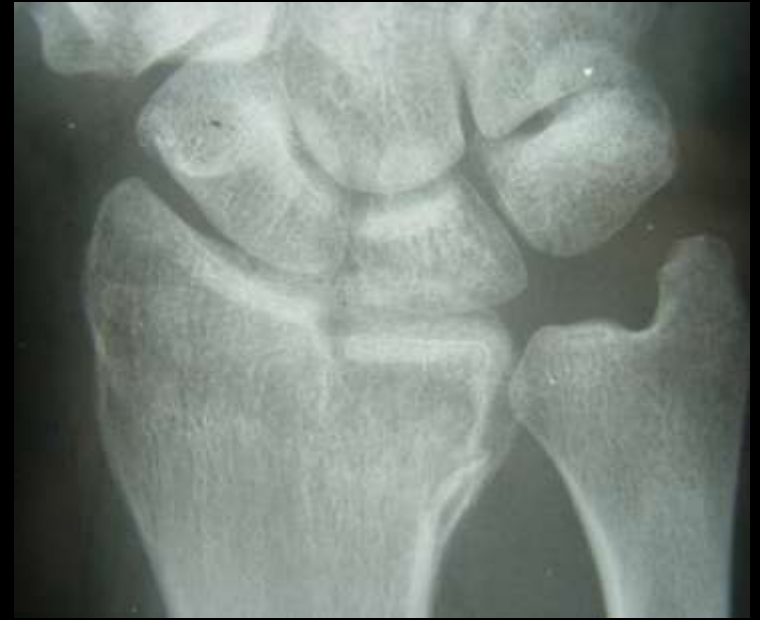Button Osteophyte Osteoarthritis



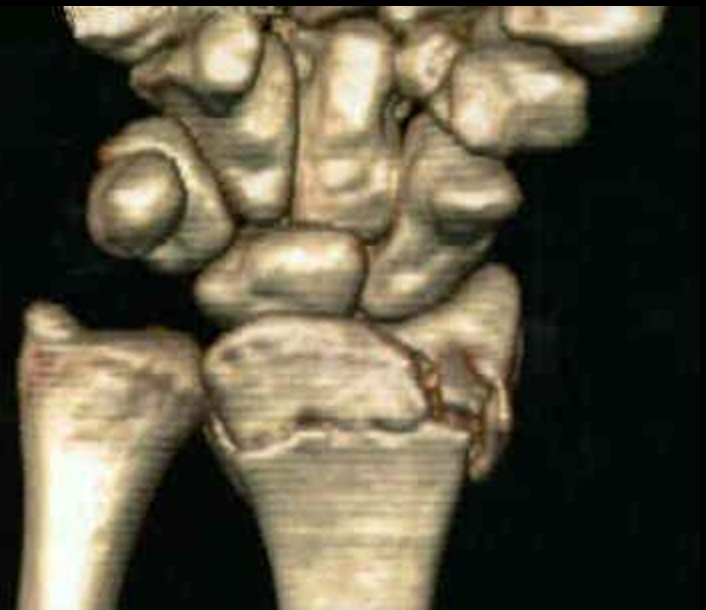

Salt and Pepper skull

Hyperparathyroidism



Die punch fracture
Lunate into radius







Paintbrush metaphysis Rickets





Bell Clapper

Muscle tear in hematoma





Stepladder wrist CPPD arthropathy





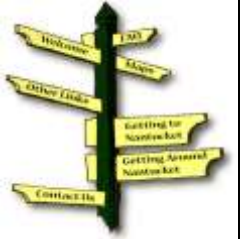Hook oosteophytes Hemachromatosis





Mickey Mouse sign Psoriasis





FBI sign Lipohemarthrosis



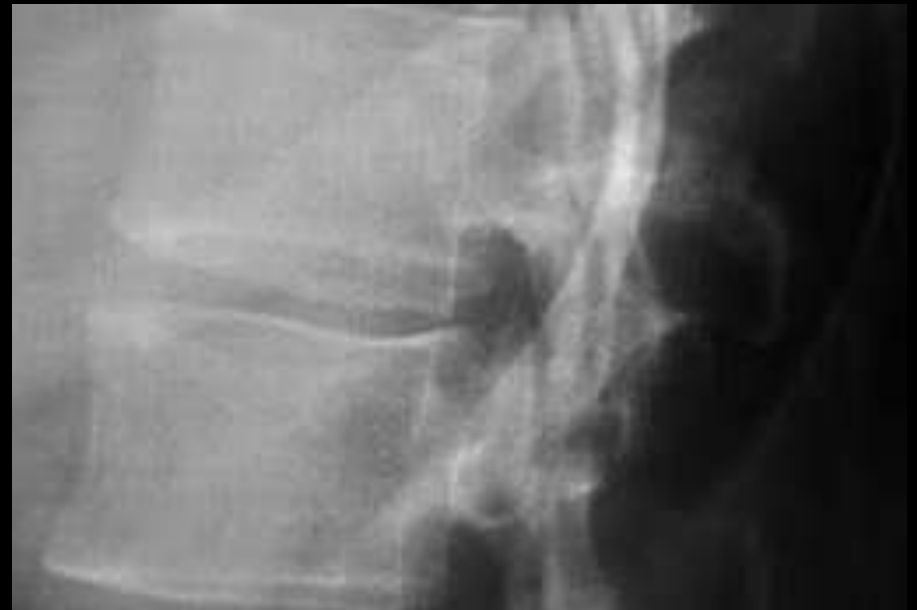

Trolley (tram) tract sign Ankylosing Spondylitis





Shiny corner sign Ankylosing spondylitis





Elephant foot Hypertrophic non-union

