

Rotator Cuff Anatomy

Dr. XXXXX

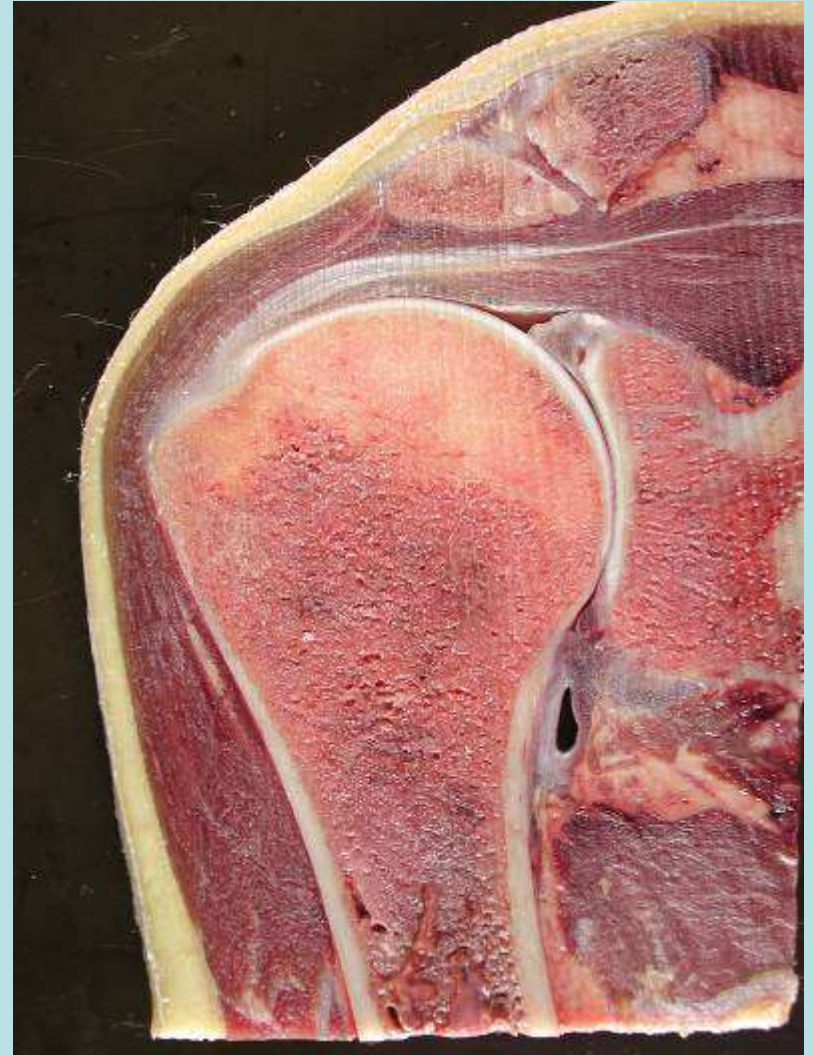Hospital XXXXX

Date XXXXX



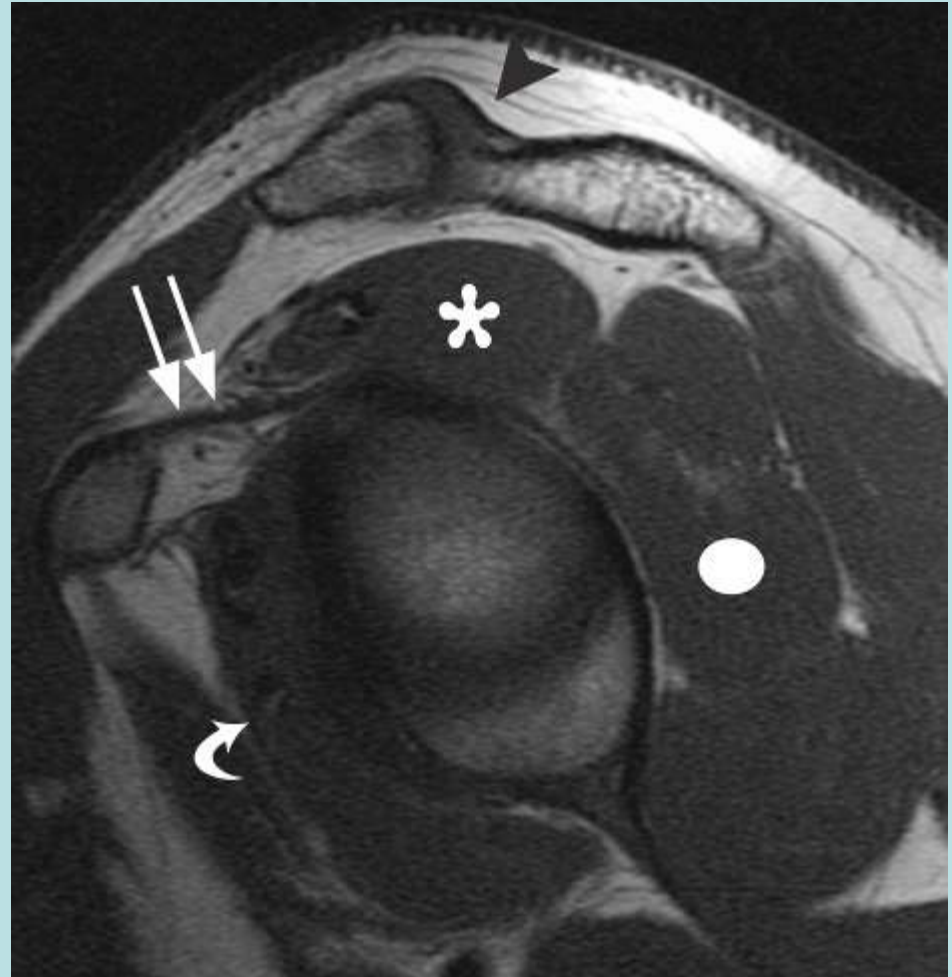
Rotator Cuff

- Muscles/Tendons
- Individual Tendon Components
- Supraspinatus Anomalies
- Anterior Fibers of Supraspinatus
- Infraspinatus
- Greater Tuberosity Anatomy
- Bare Area of GT
- Interdigitation Artifact
- 4-5 Histologic Layers
- Cable Crescent Component
- Teres Minor
- Subscapularis
- Rotator Intervals



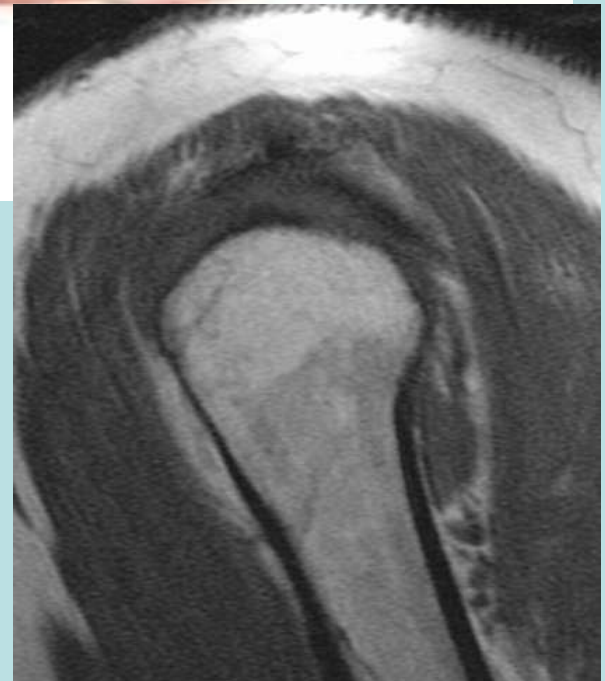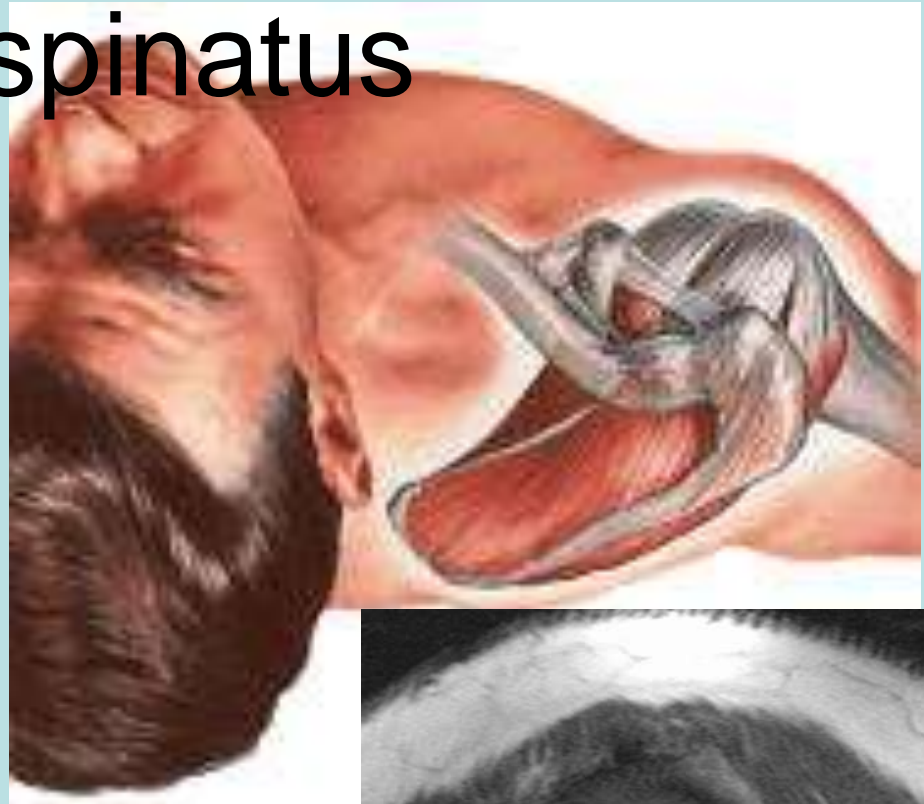
Rotator Cuff Muscles

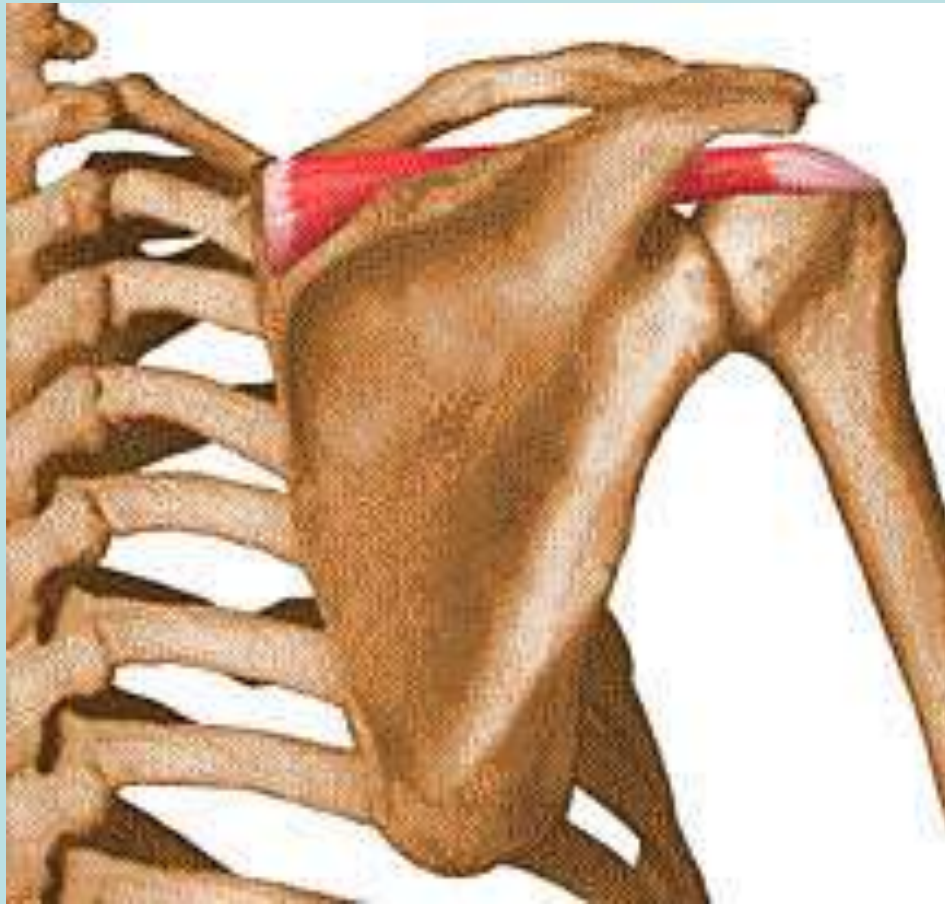- Supraspinatus
- Infraspinatus
- Teres Minor
- Subscapularis



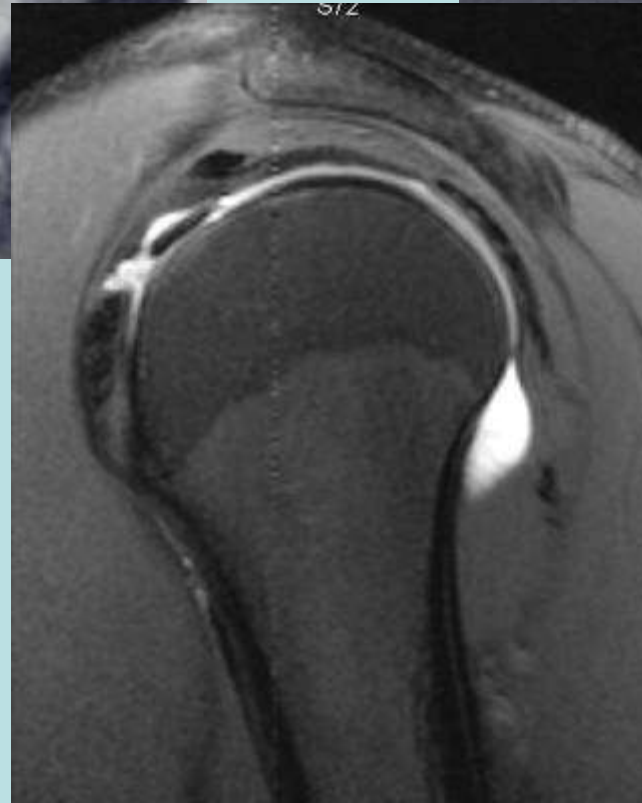
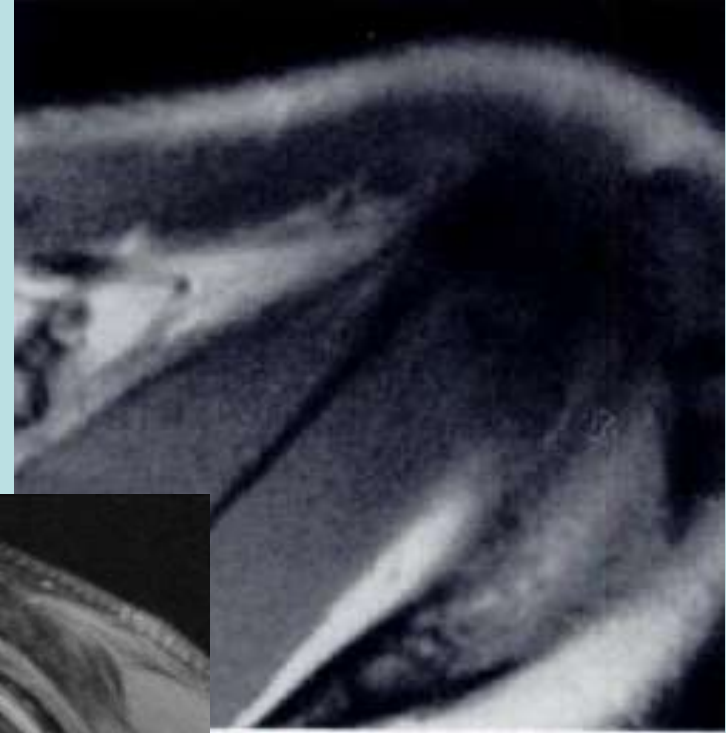
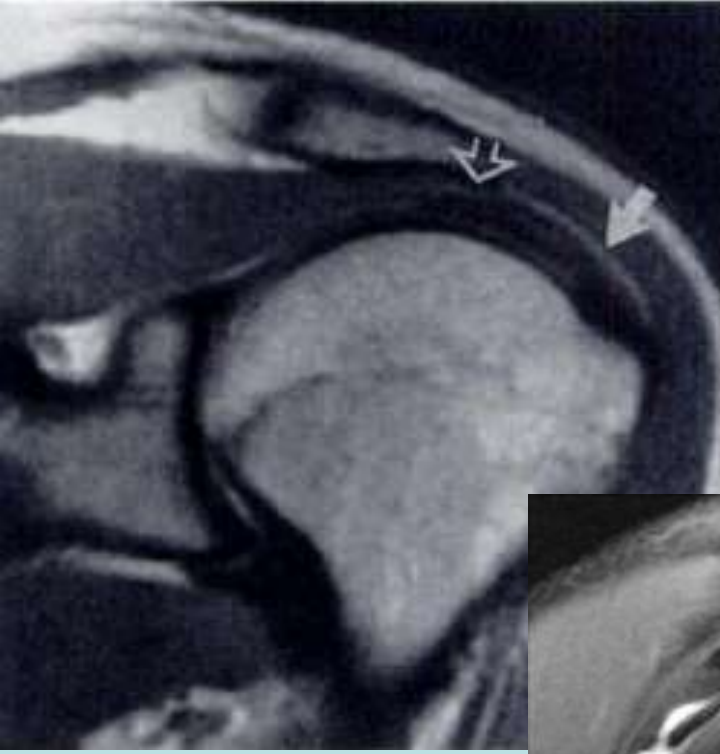
Supraspinatus

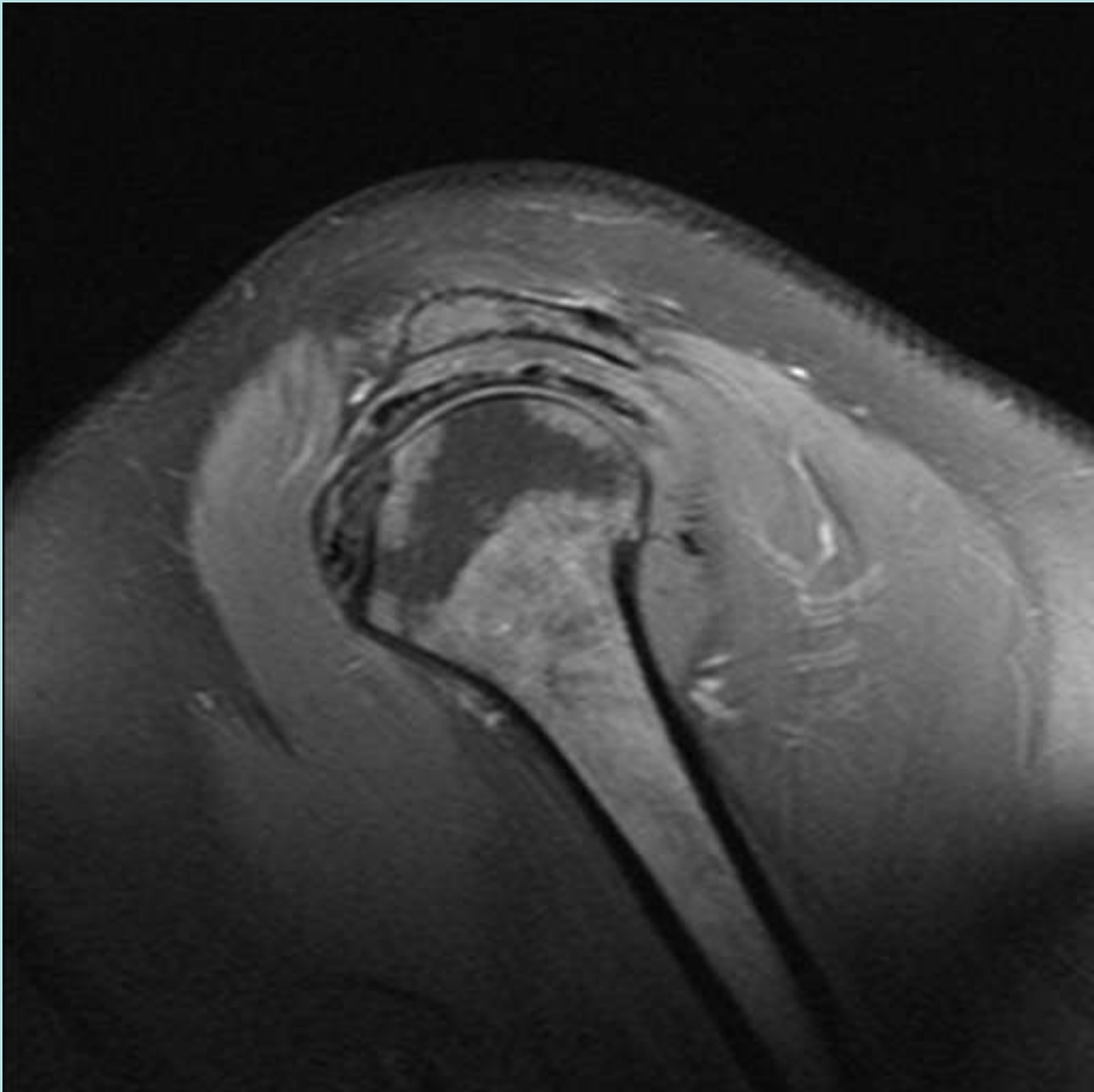
- Muscular origin
Supraspinatus Fossa
- Inserts on Greater
Tuberosity
- Innervation from
Suprascapular Nerve
- Triple Blood Supply
- Two and Perhaps
three main tendinous
components

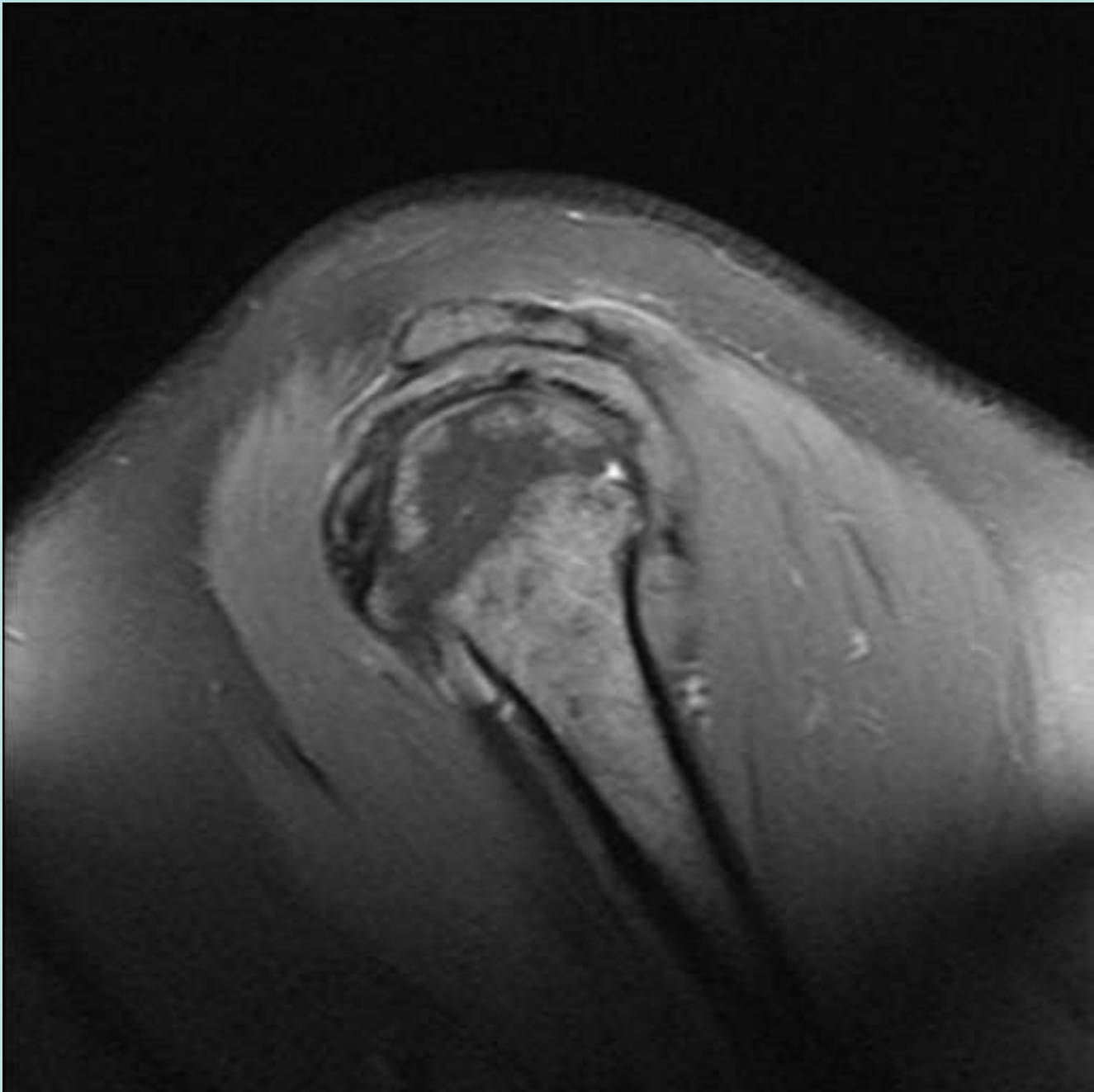


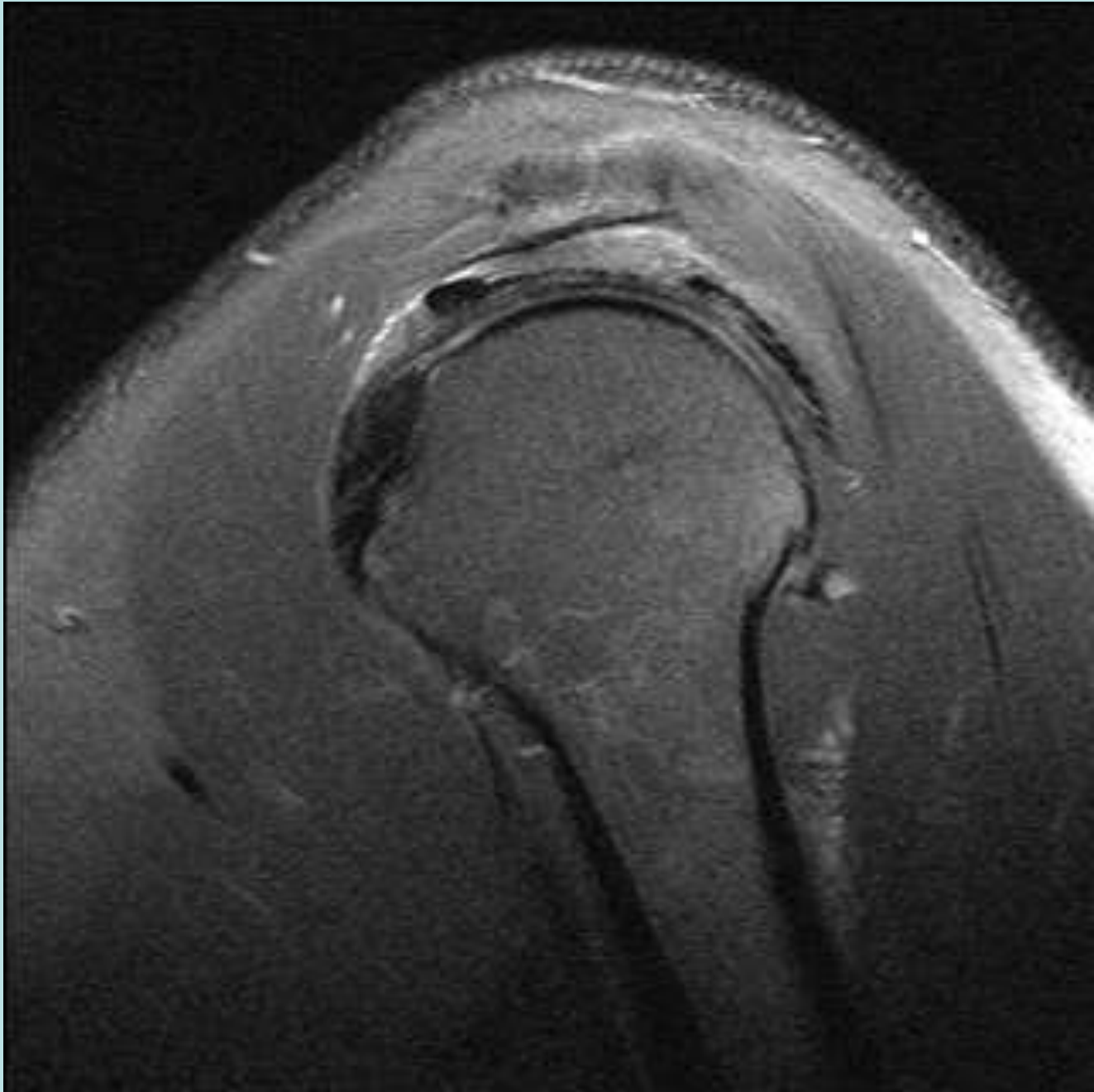


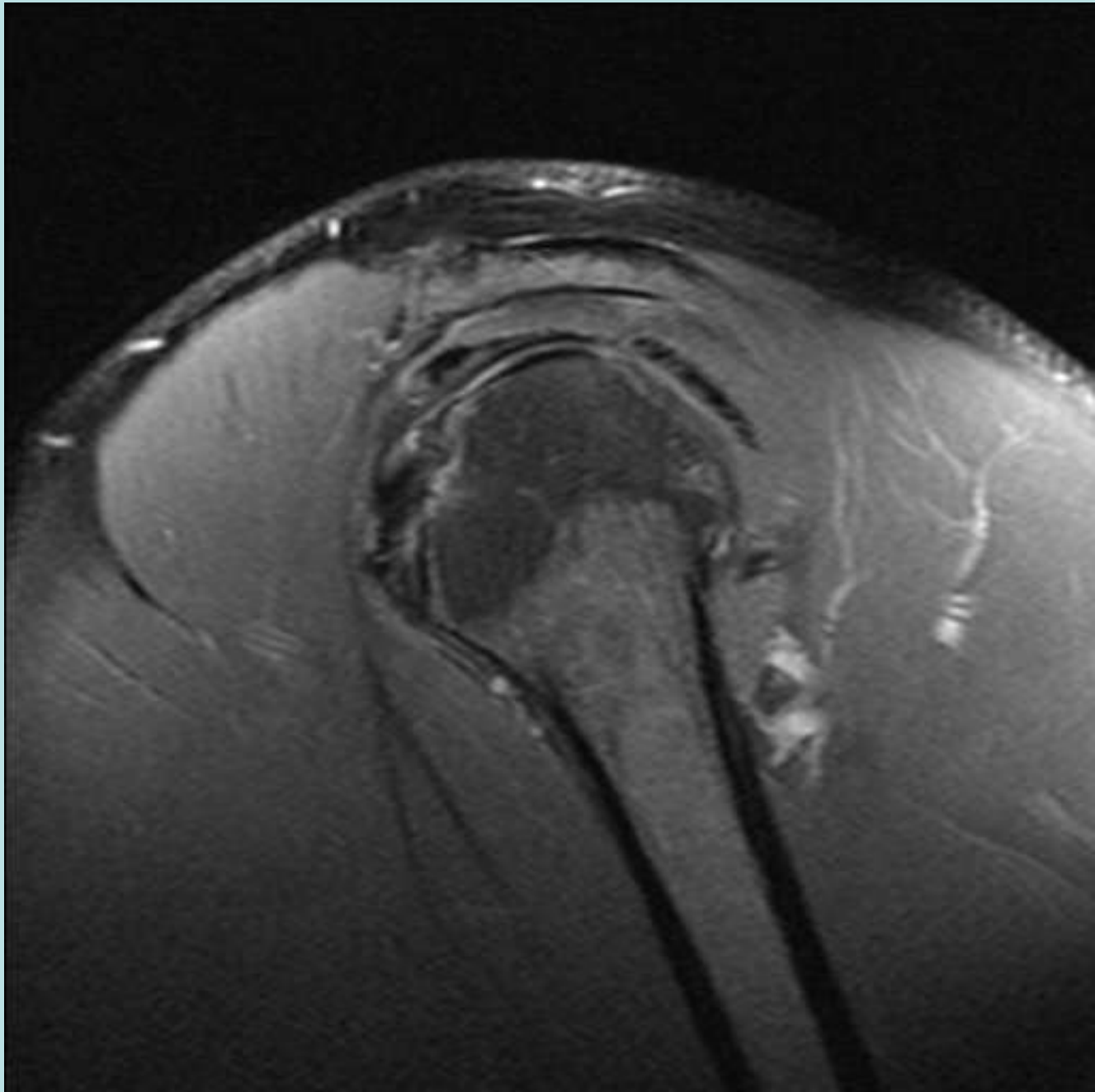
Supraspinatus

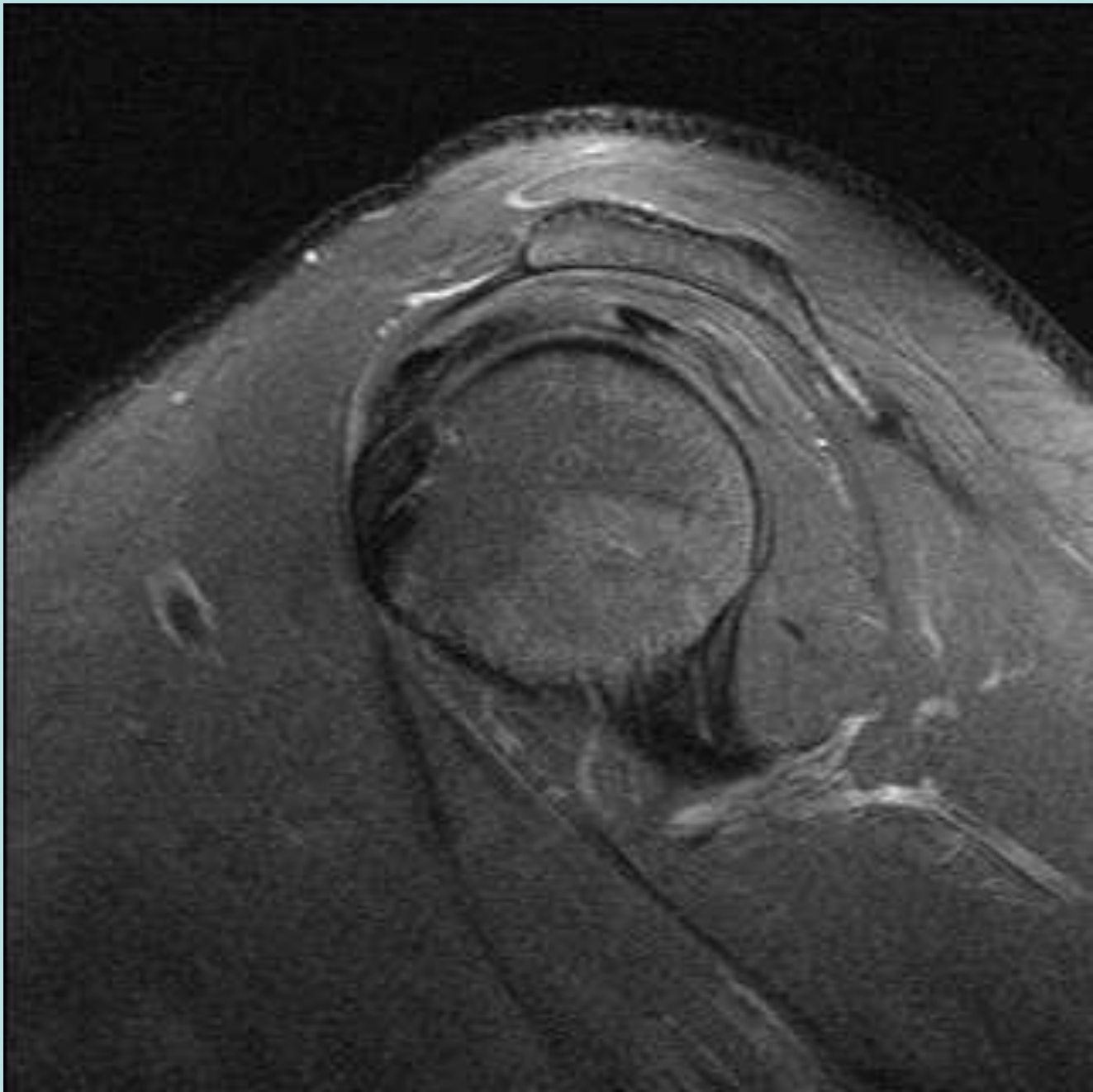


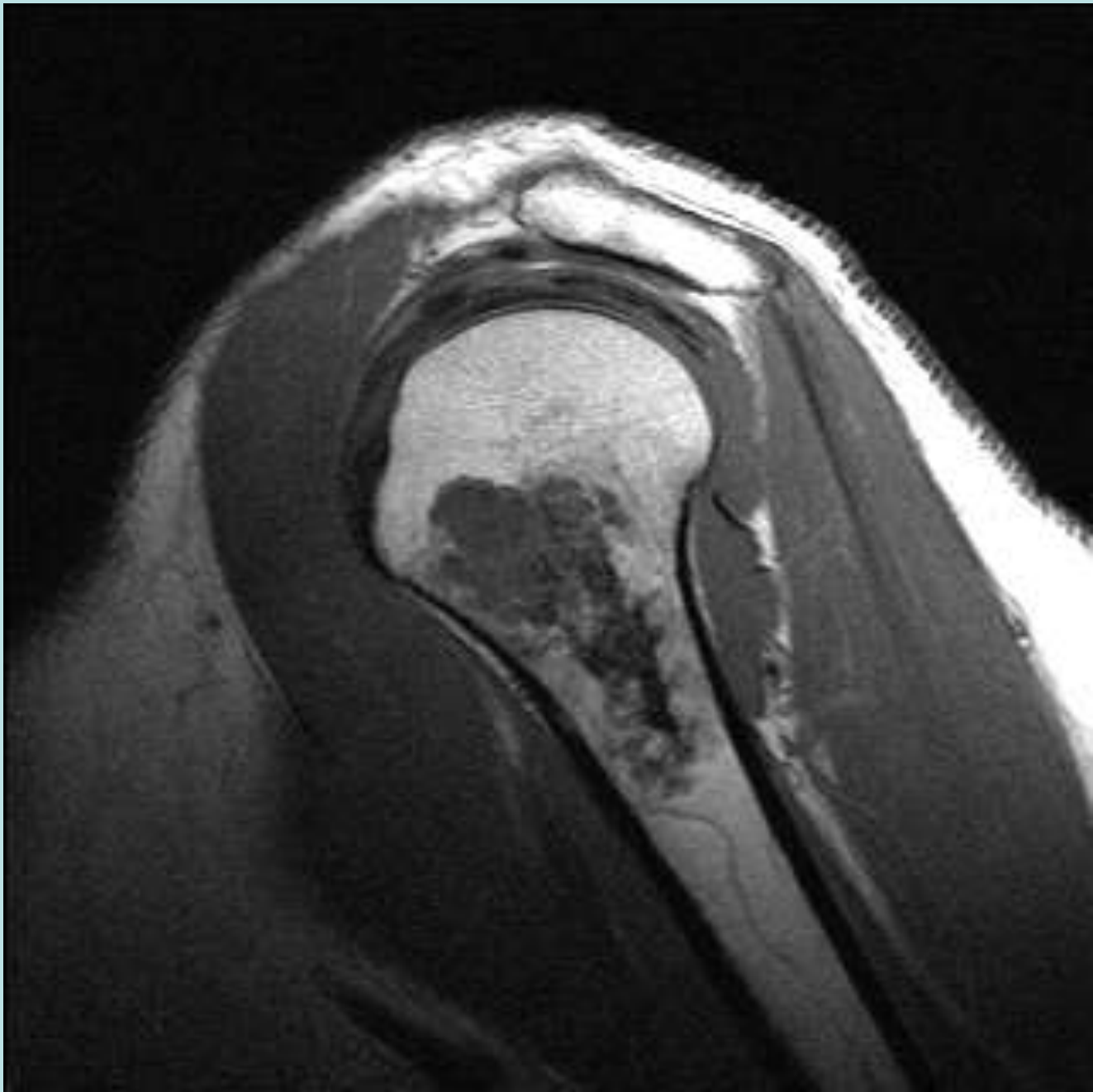


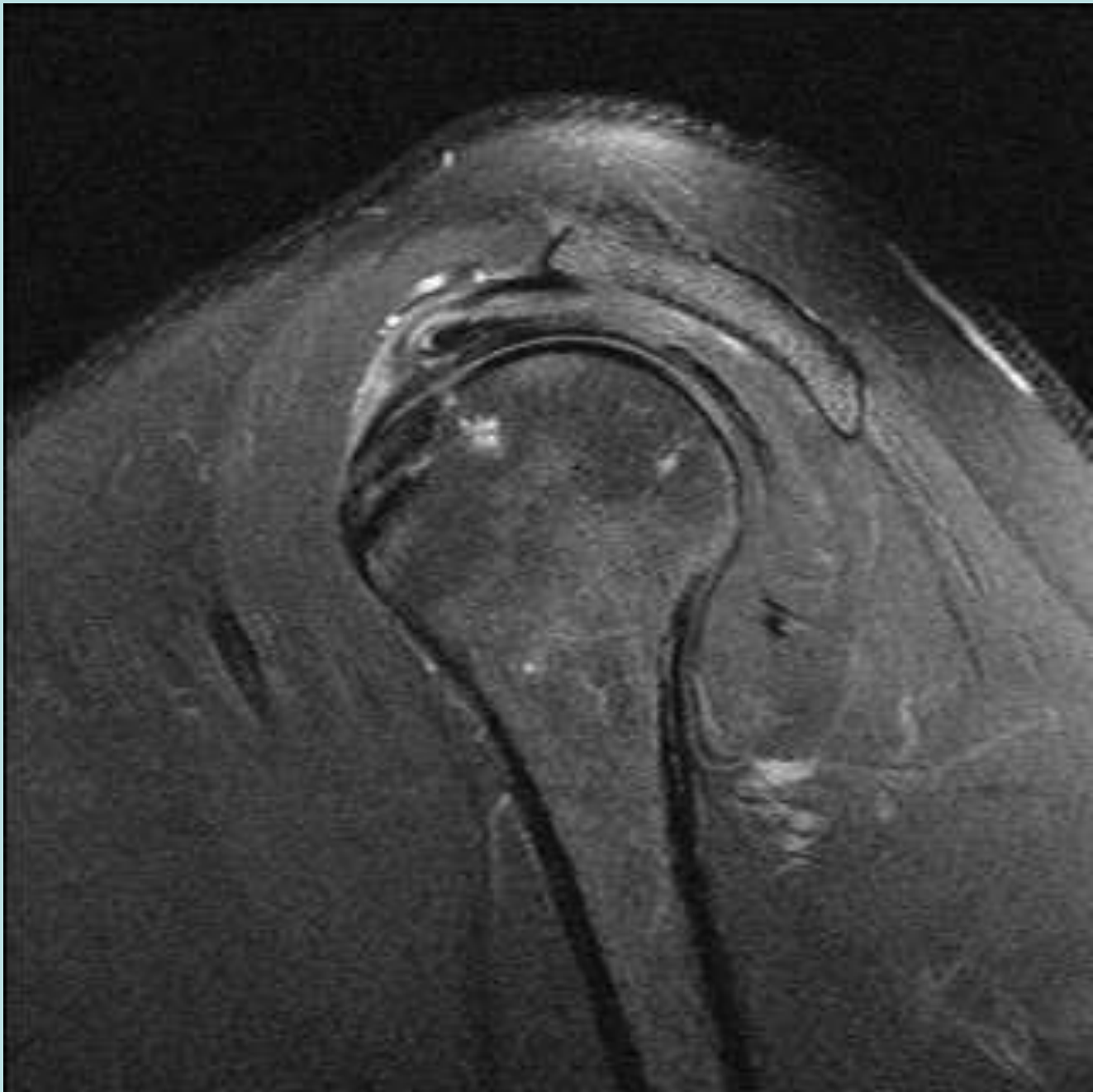










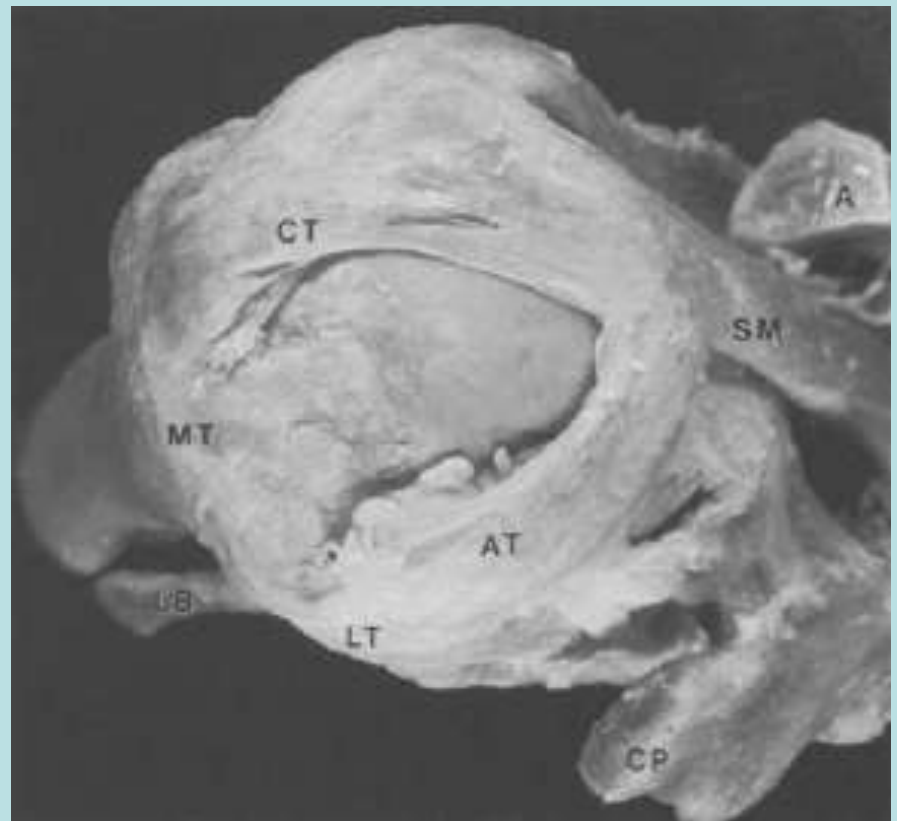
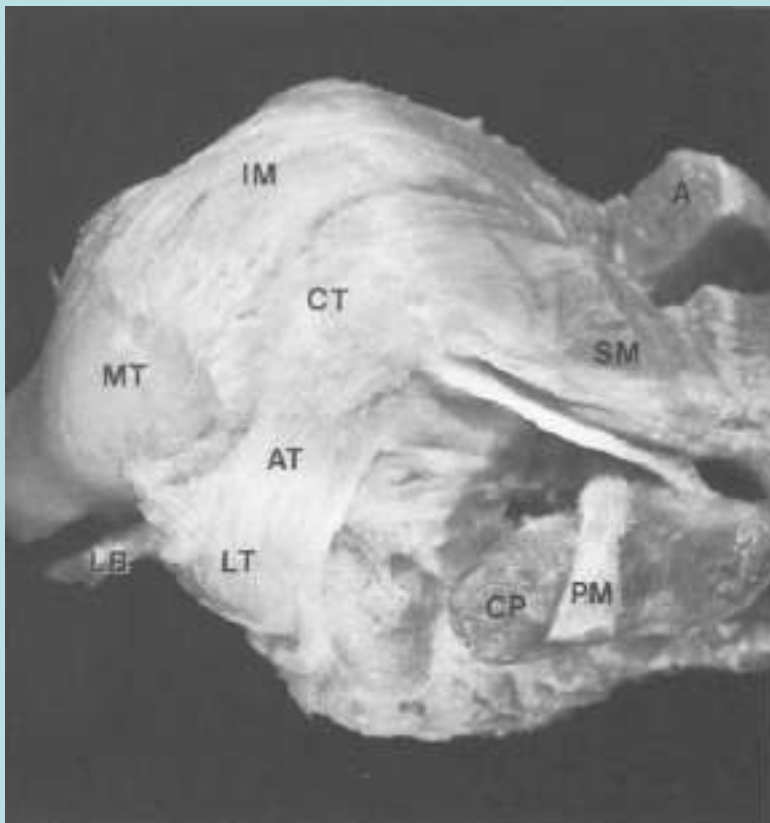


Supraspinatus Anomalies

- Separate Muscular origins from the Supraspinatus fossa, anterior component intramuscular tendon and posterior component lateral tendon
- Accessory Slip extends to Lesser Tuberosity
- ????

Accessory Anterior Slip of Supra

- 10/37 cadaveric specimens, 1 with FT RCT



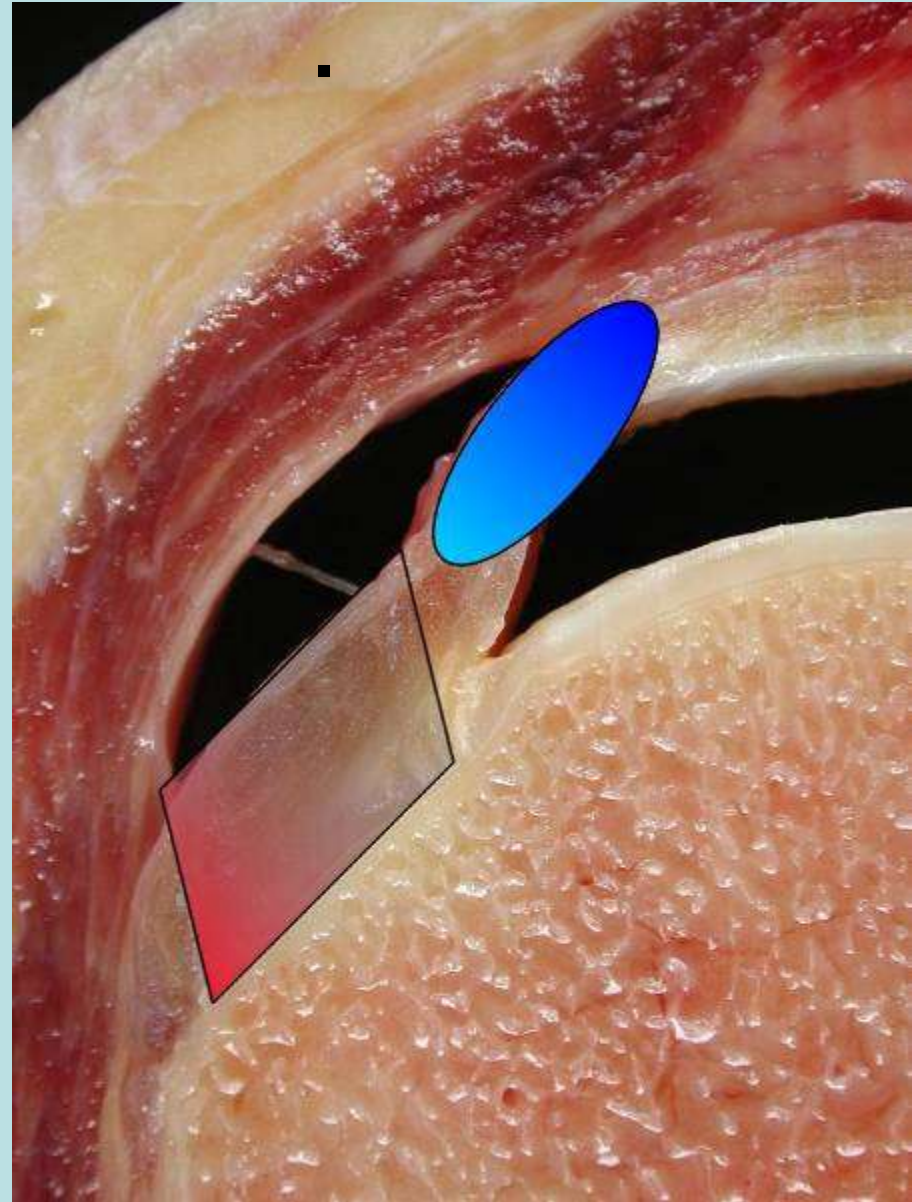
A note on the anatomy of the supraspinatus muscle

I. Kolts

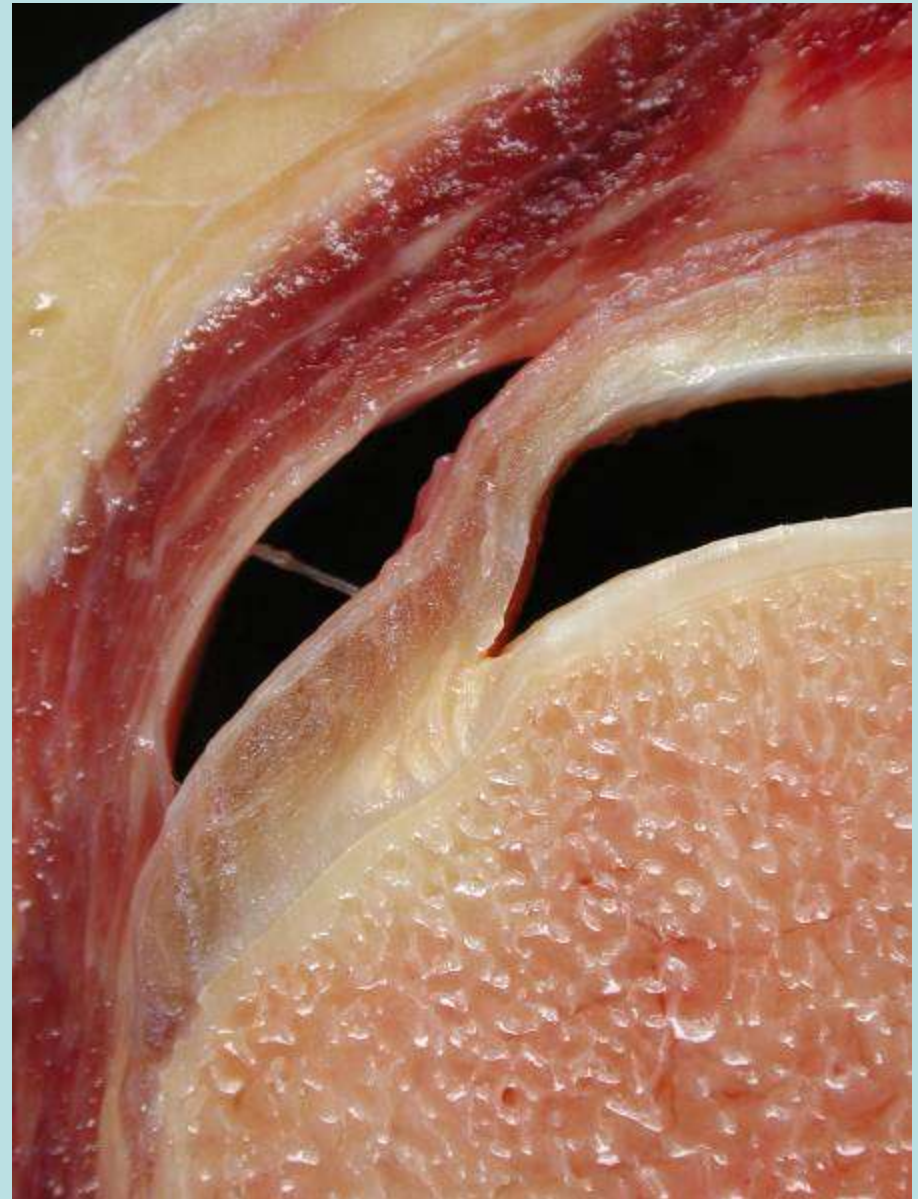
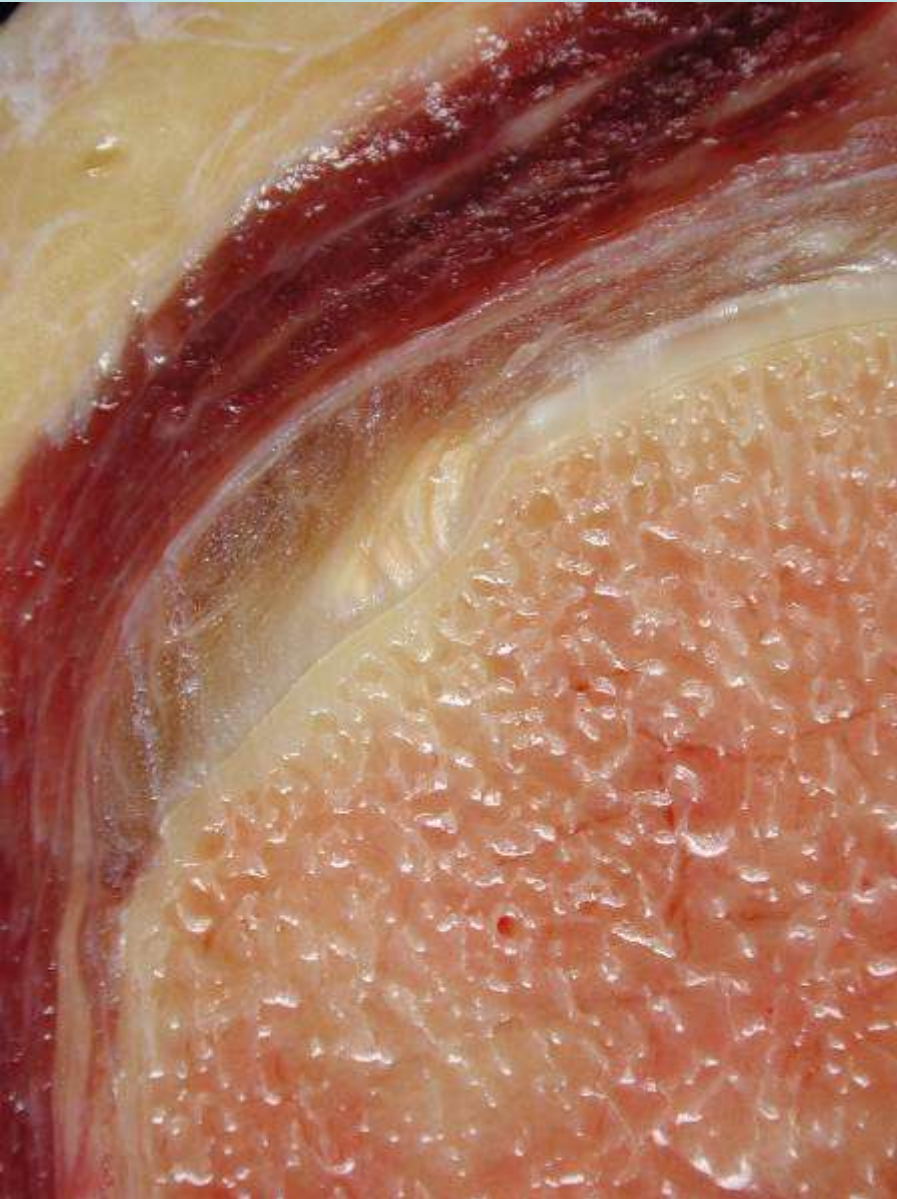Arch Orthop Trauma Surg (1992) 111:247-249

Zonal Anatomy of Supraspinatus Tendon

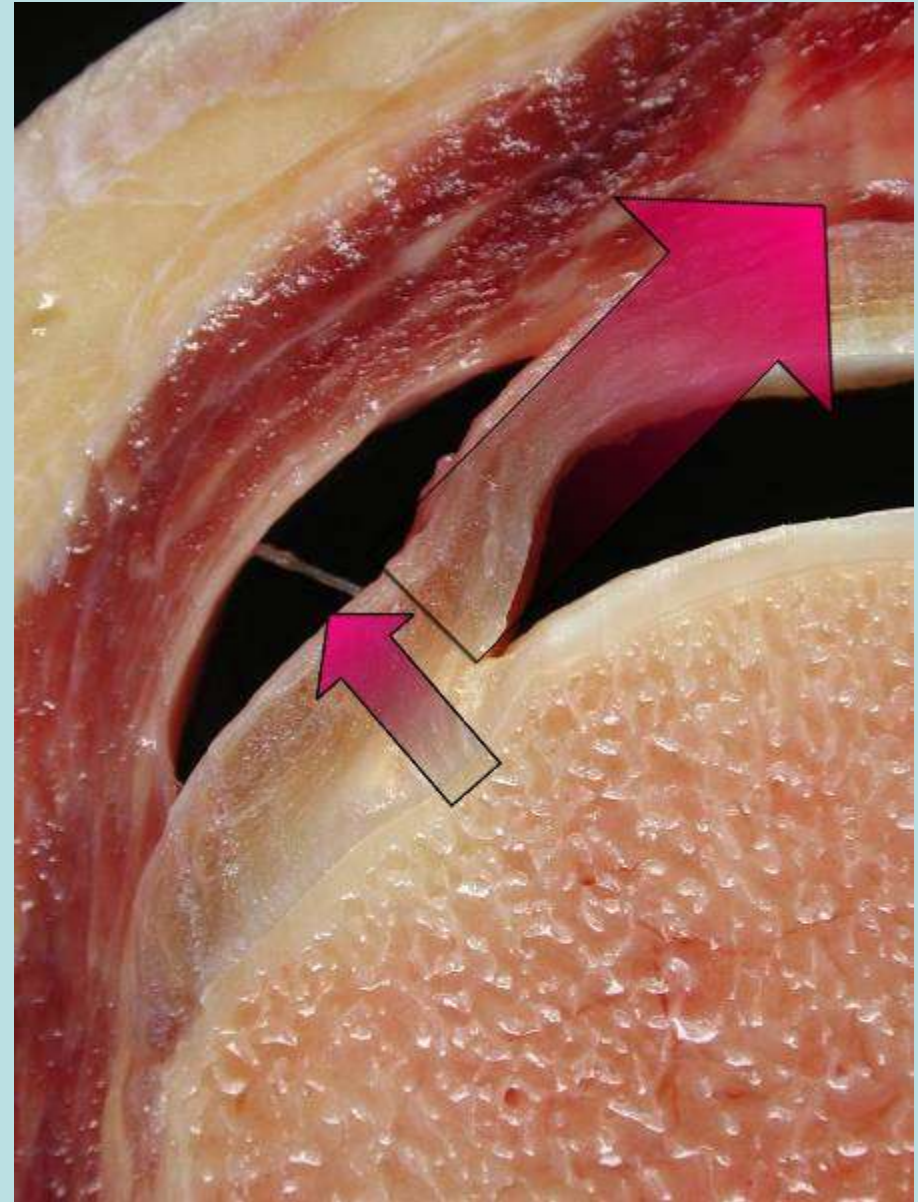
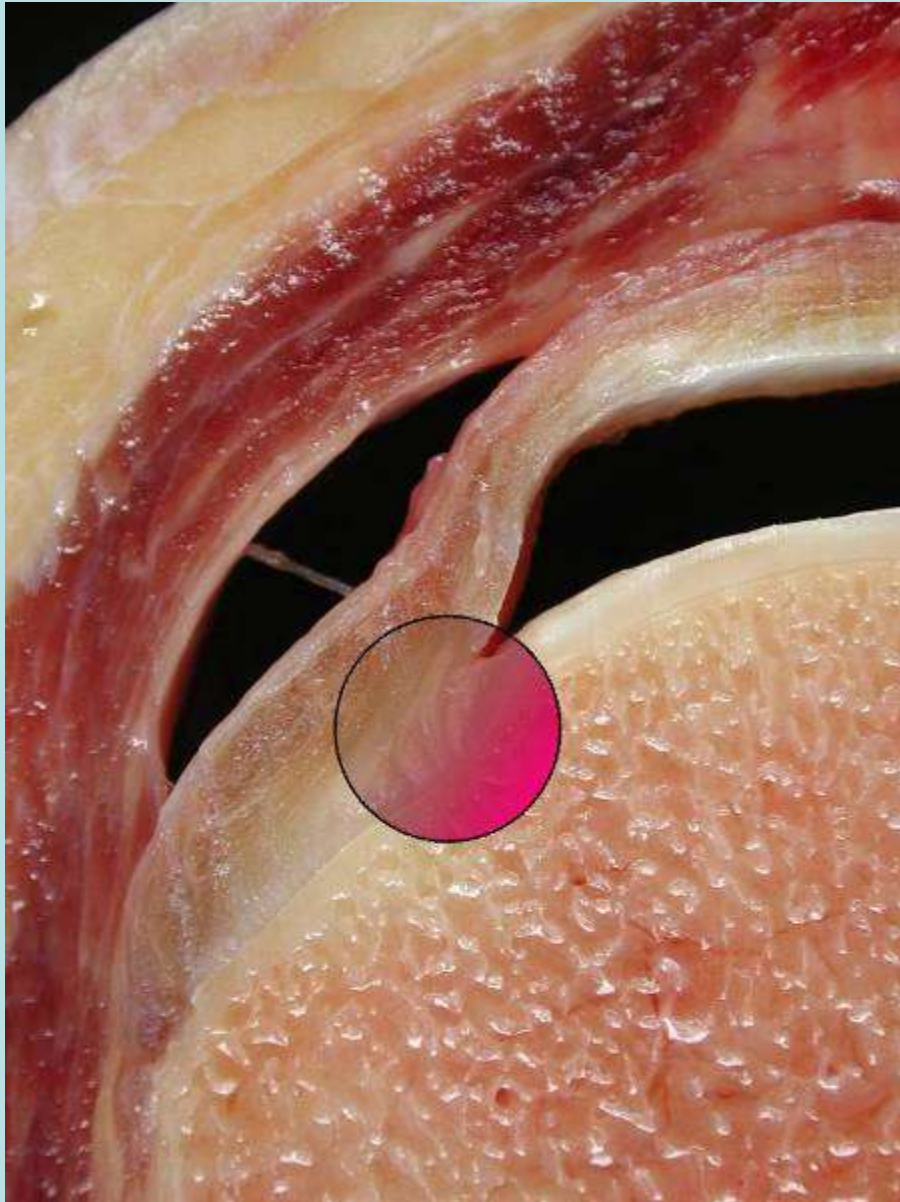
- Insertional fibers-
Rim Rent Tears
- Critical Zone-
Hypovascular
- Intramuscular/Mus-
culotendinous



Anterior Insertional Fibers

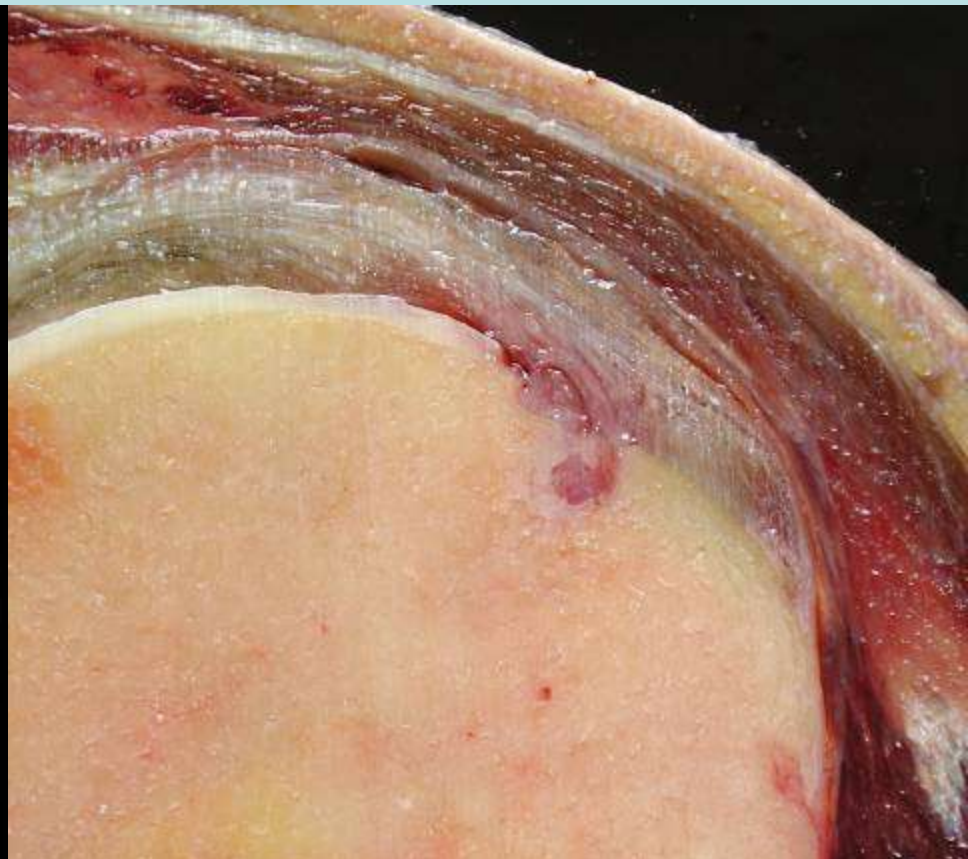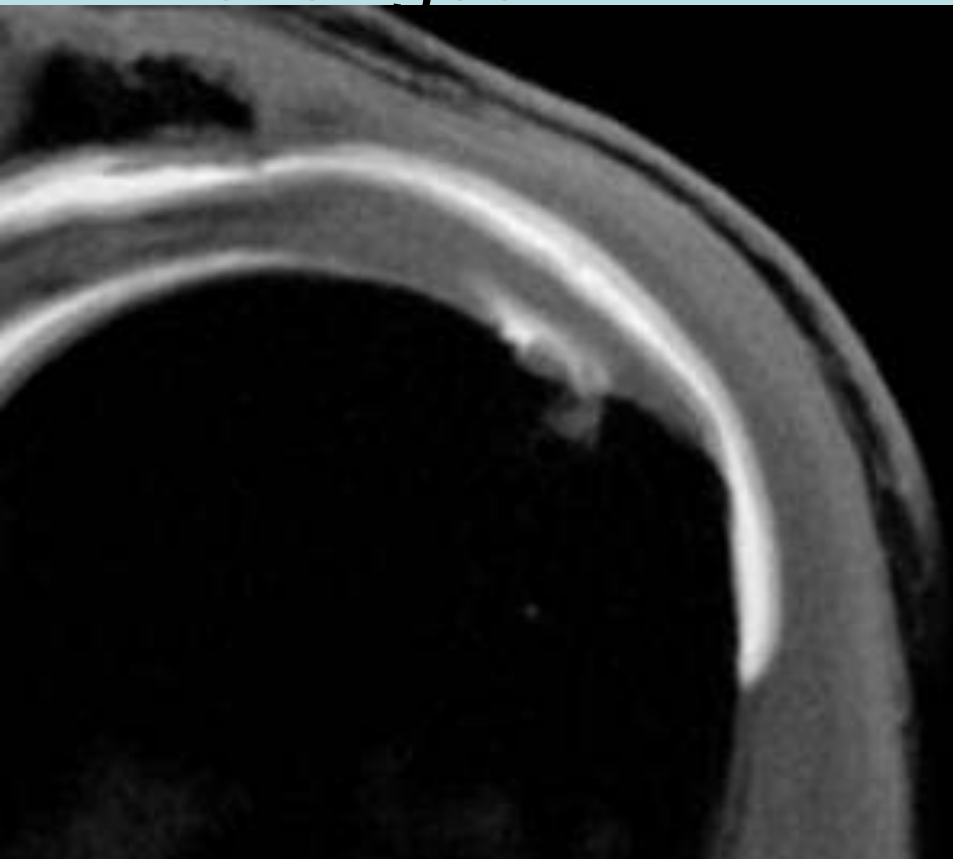


Anterior Insertional Fibers/Rim Rent

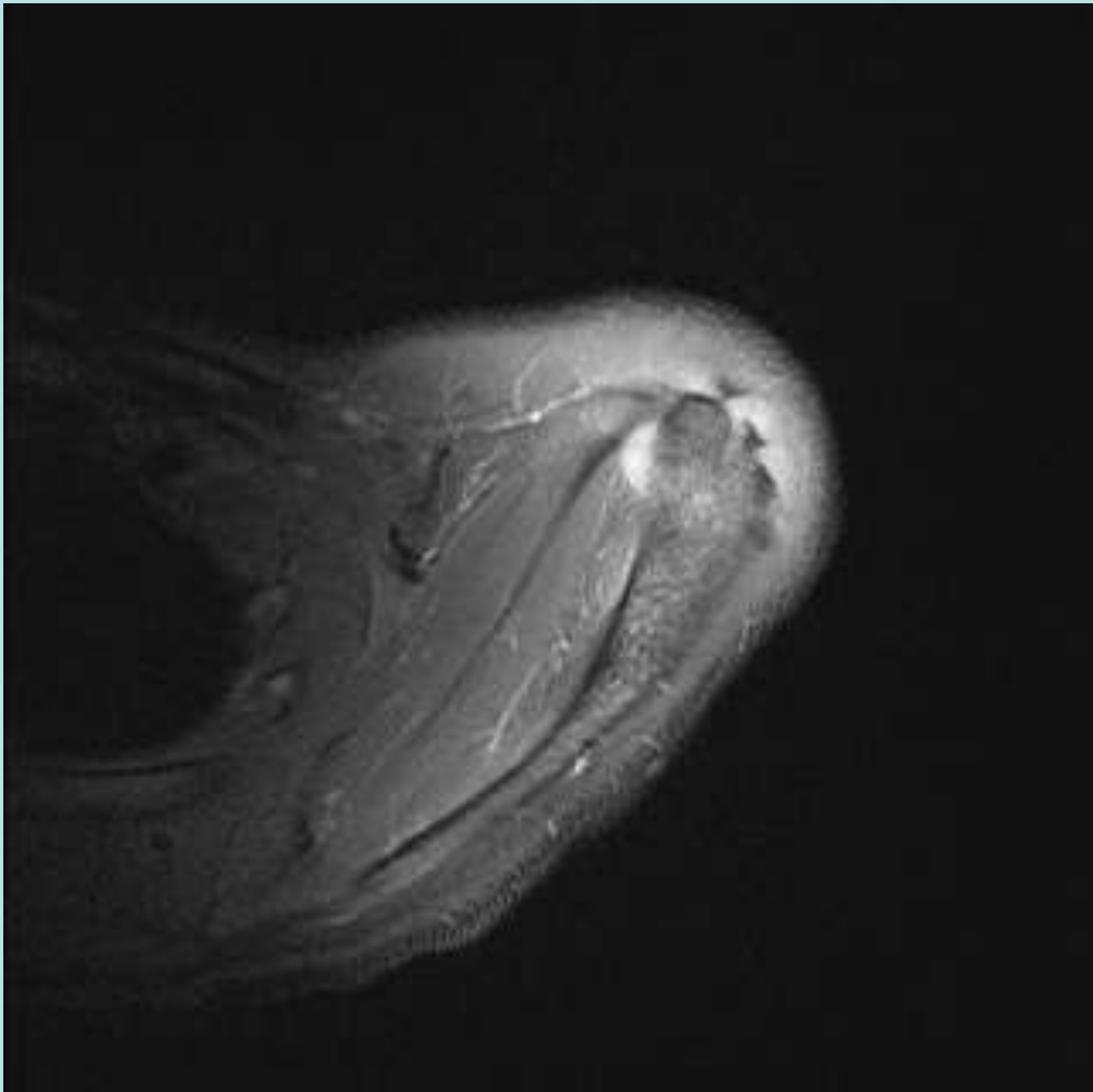


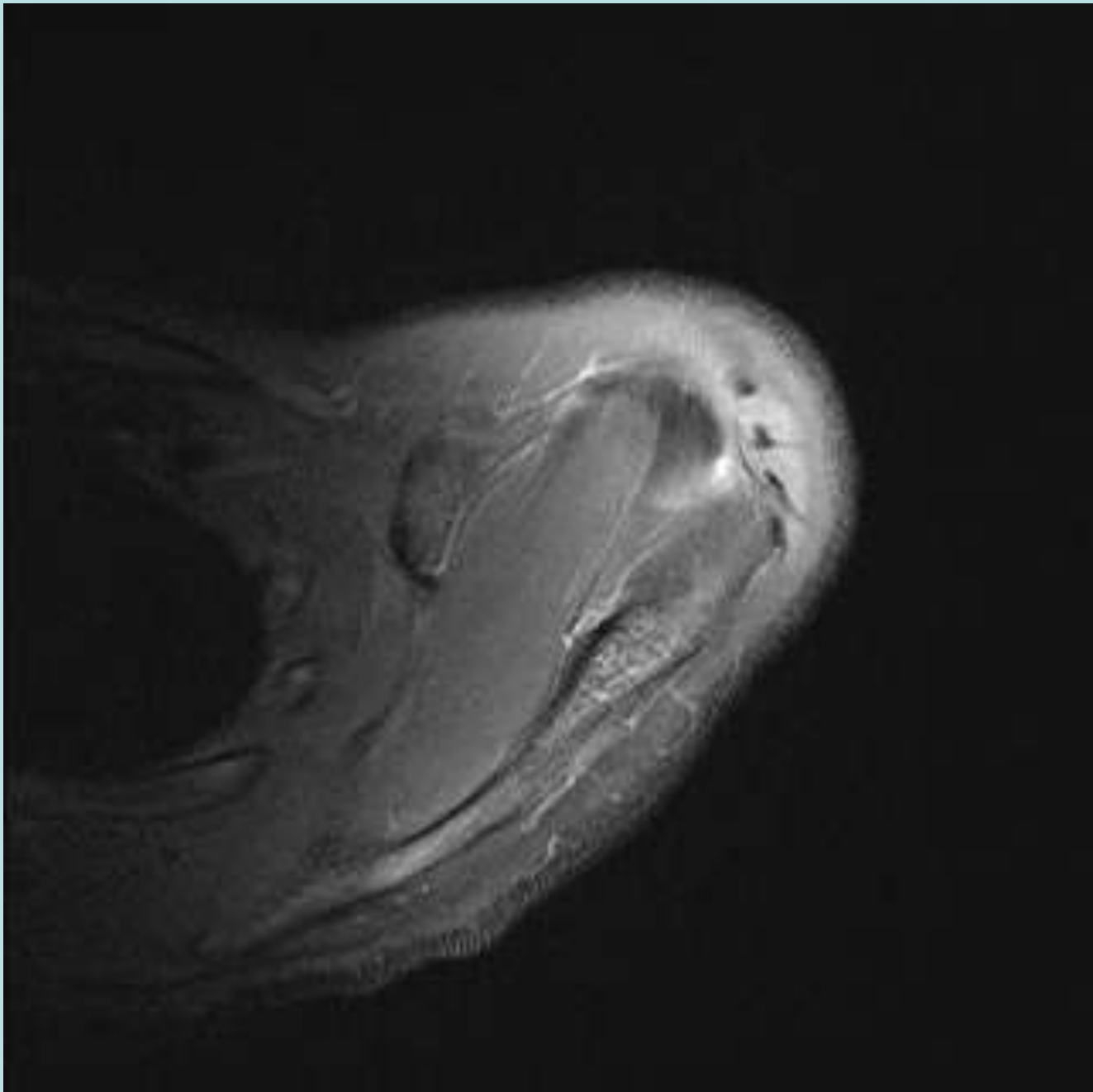
Rim Rent Tears

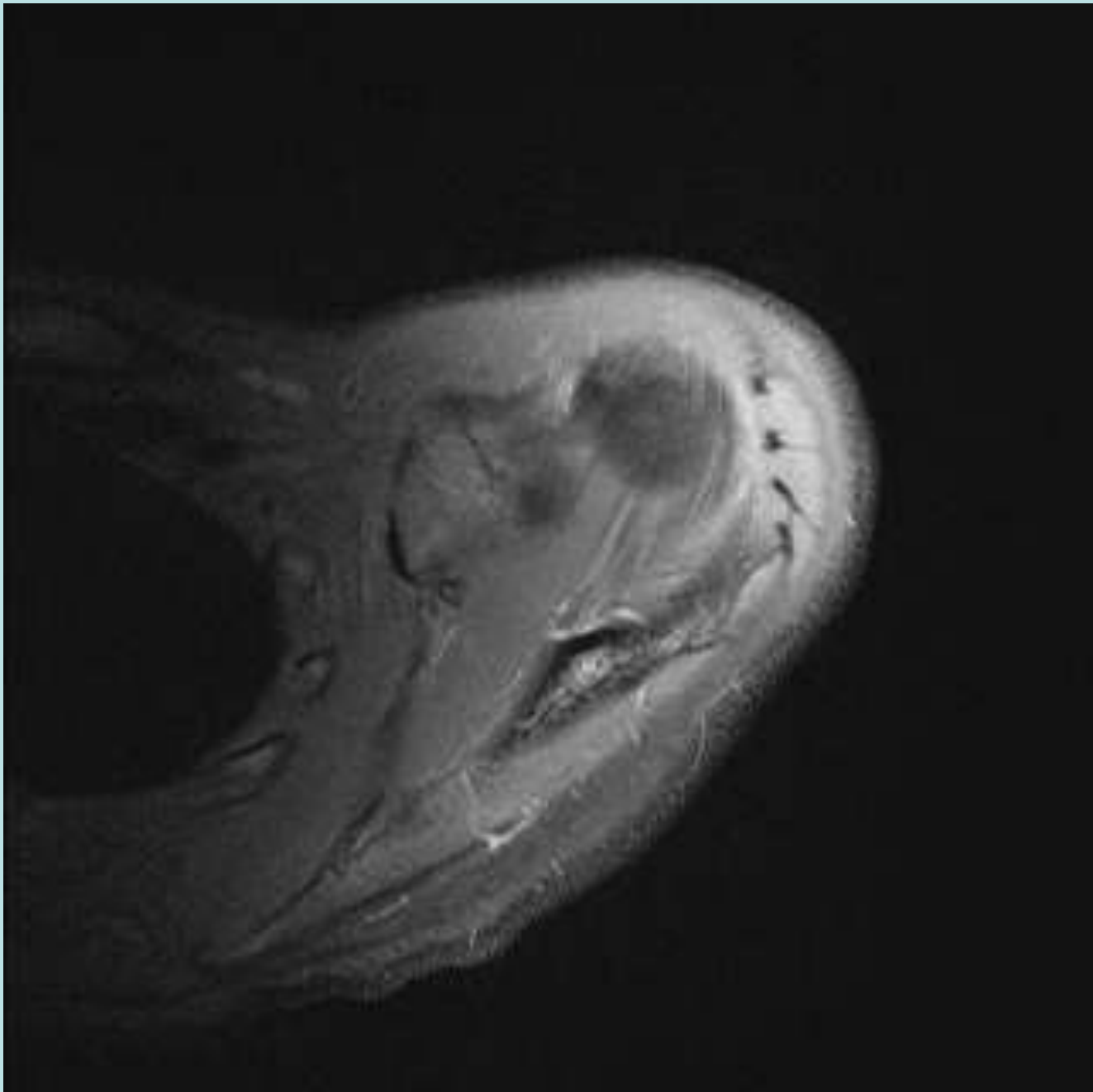
- Younger Patients anterior insertional SS tears, frequently with adjacent bone changes

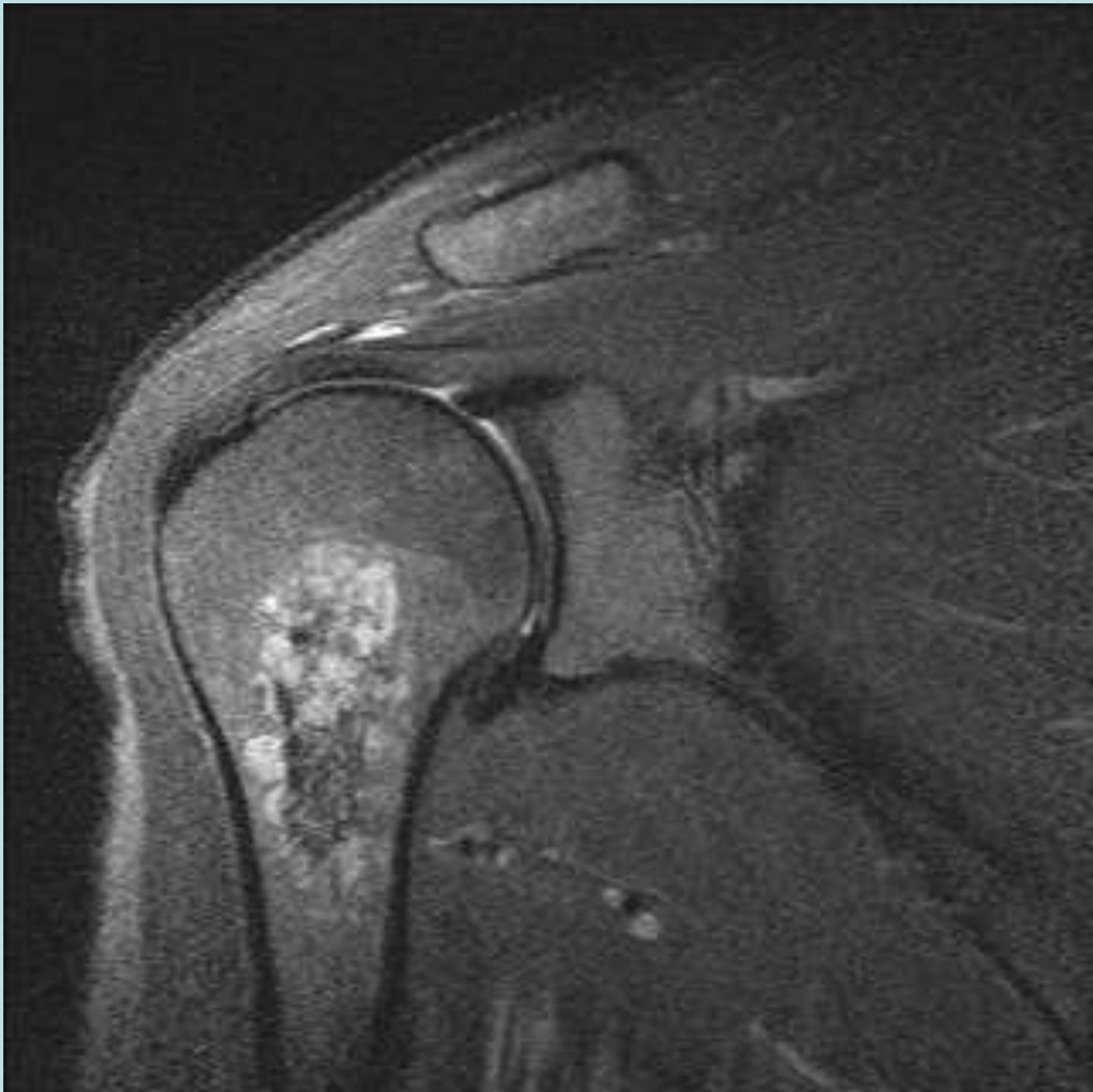

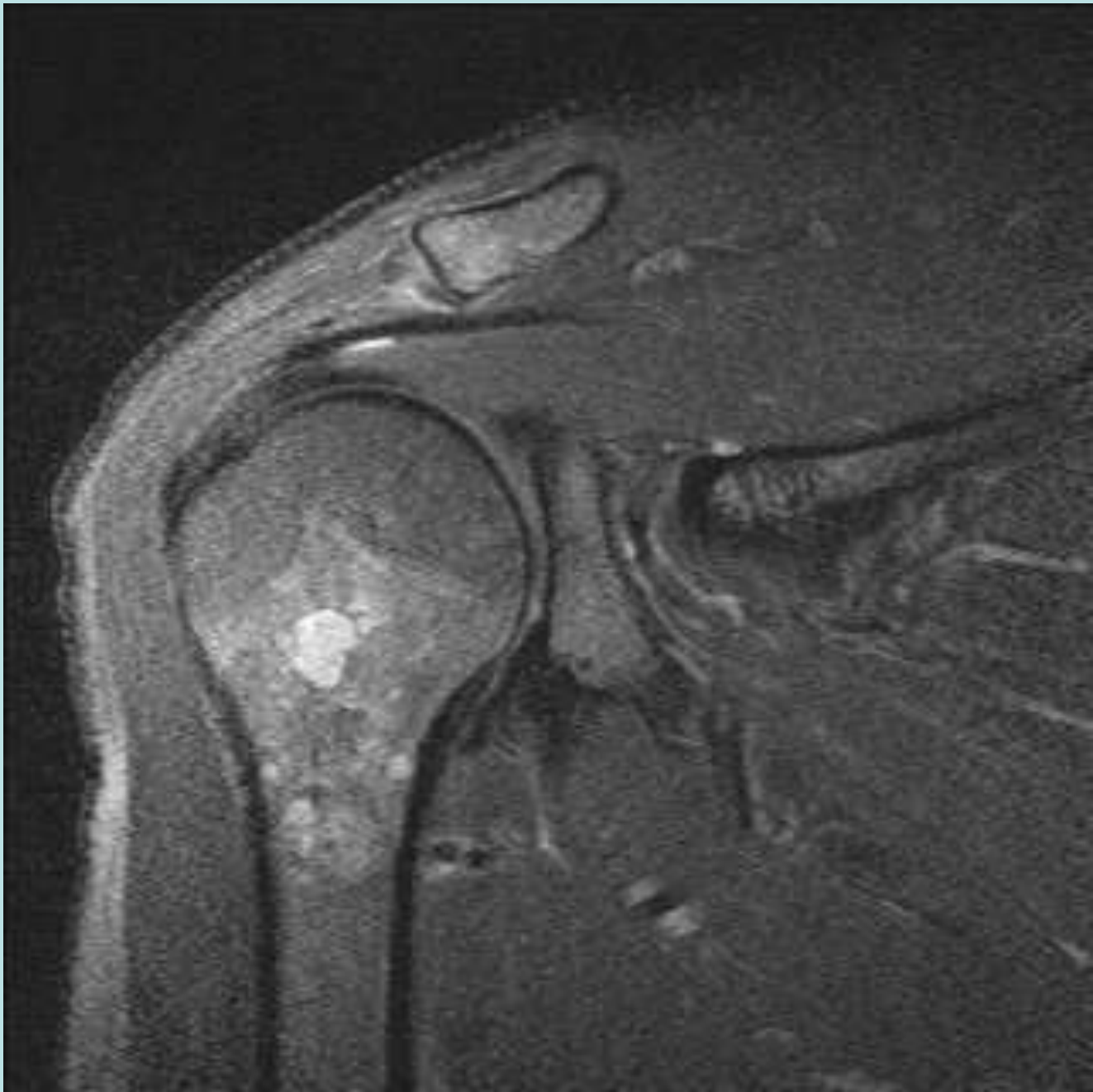Anomalous Supraspinatus Tendon 1

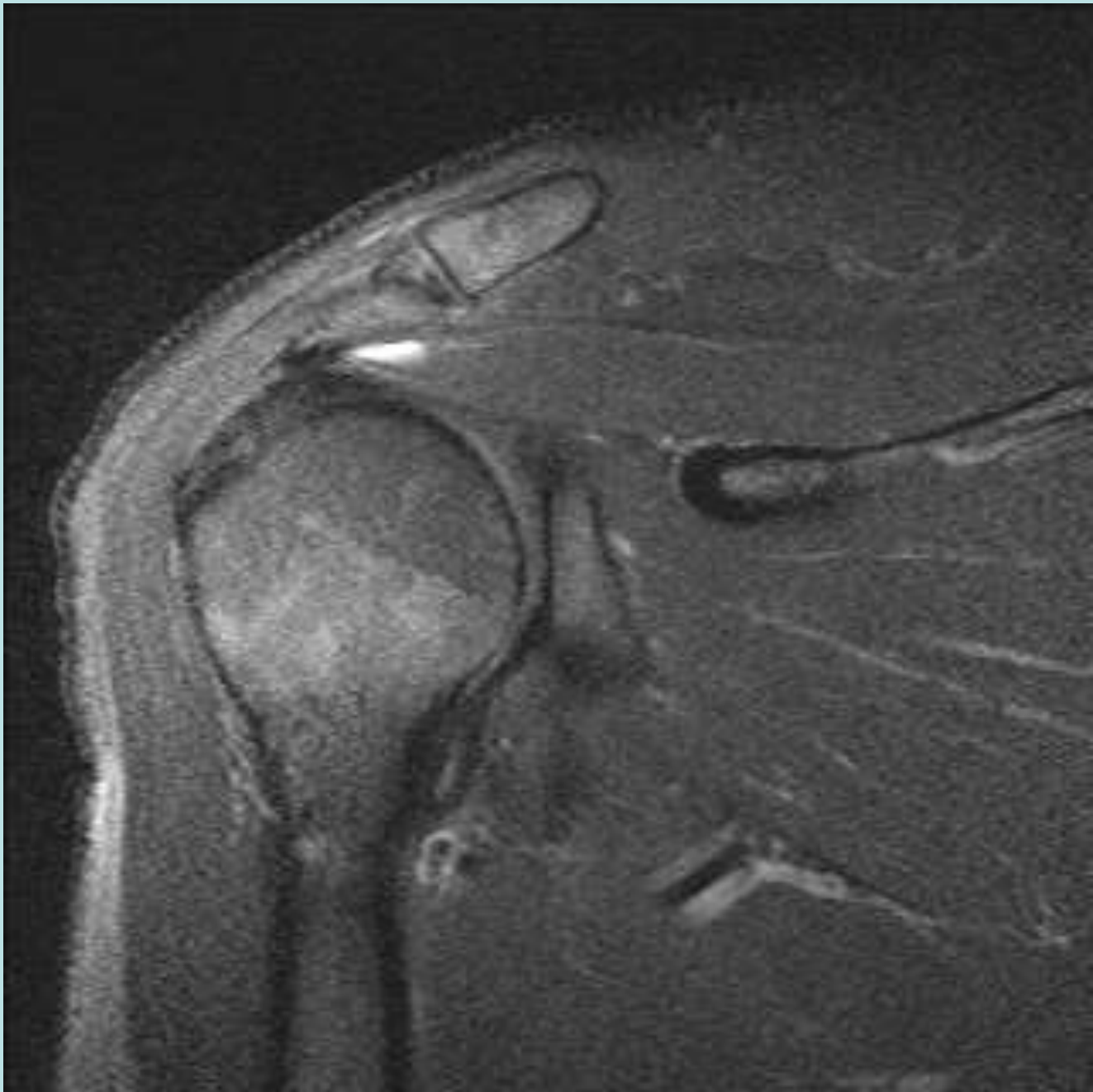


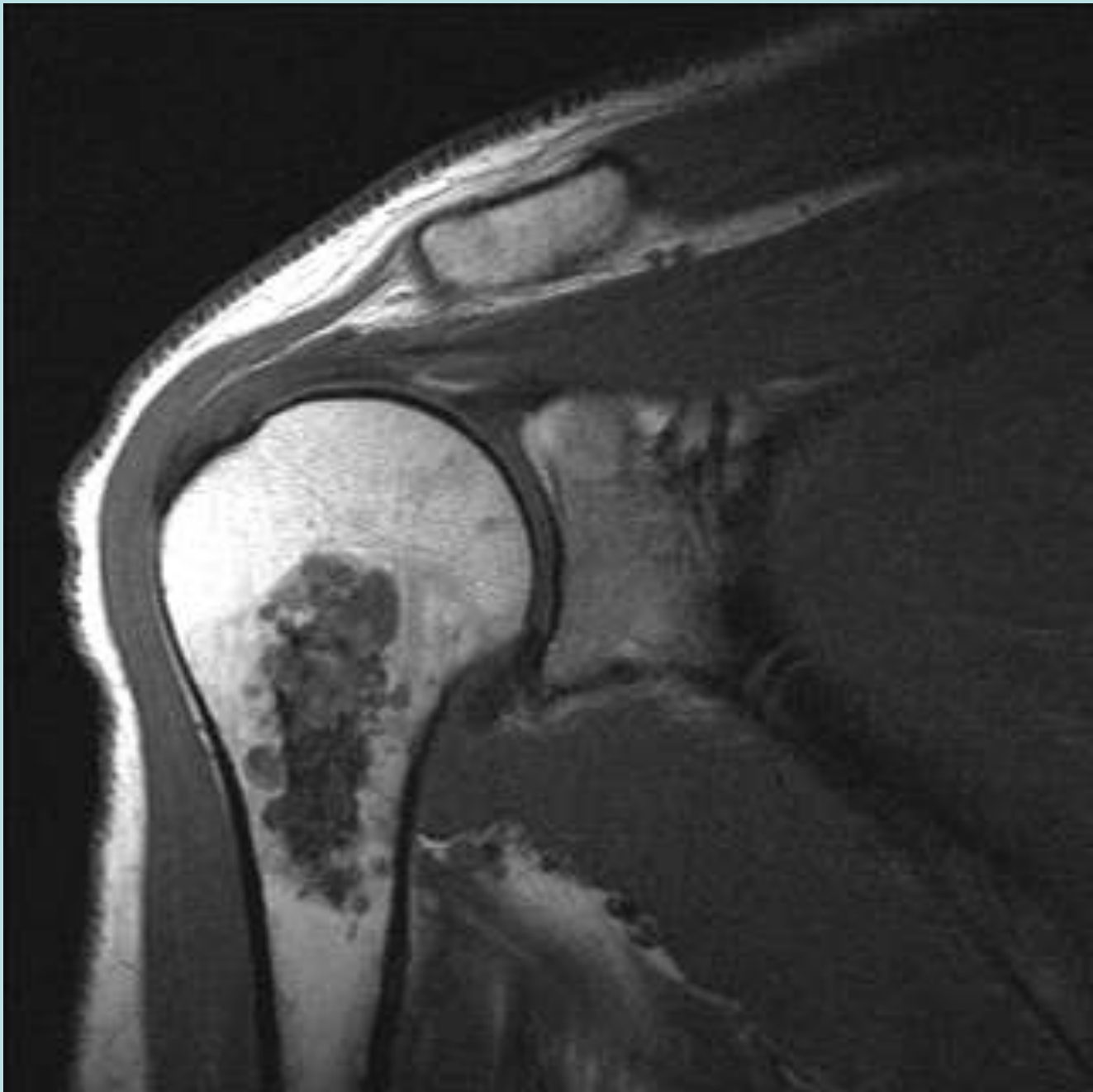


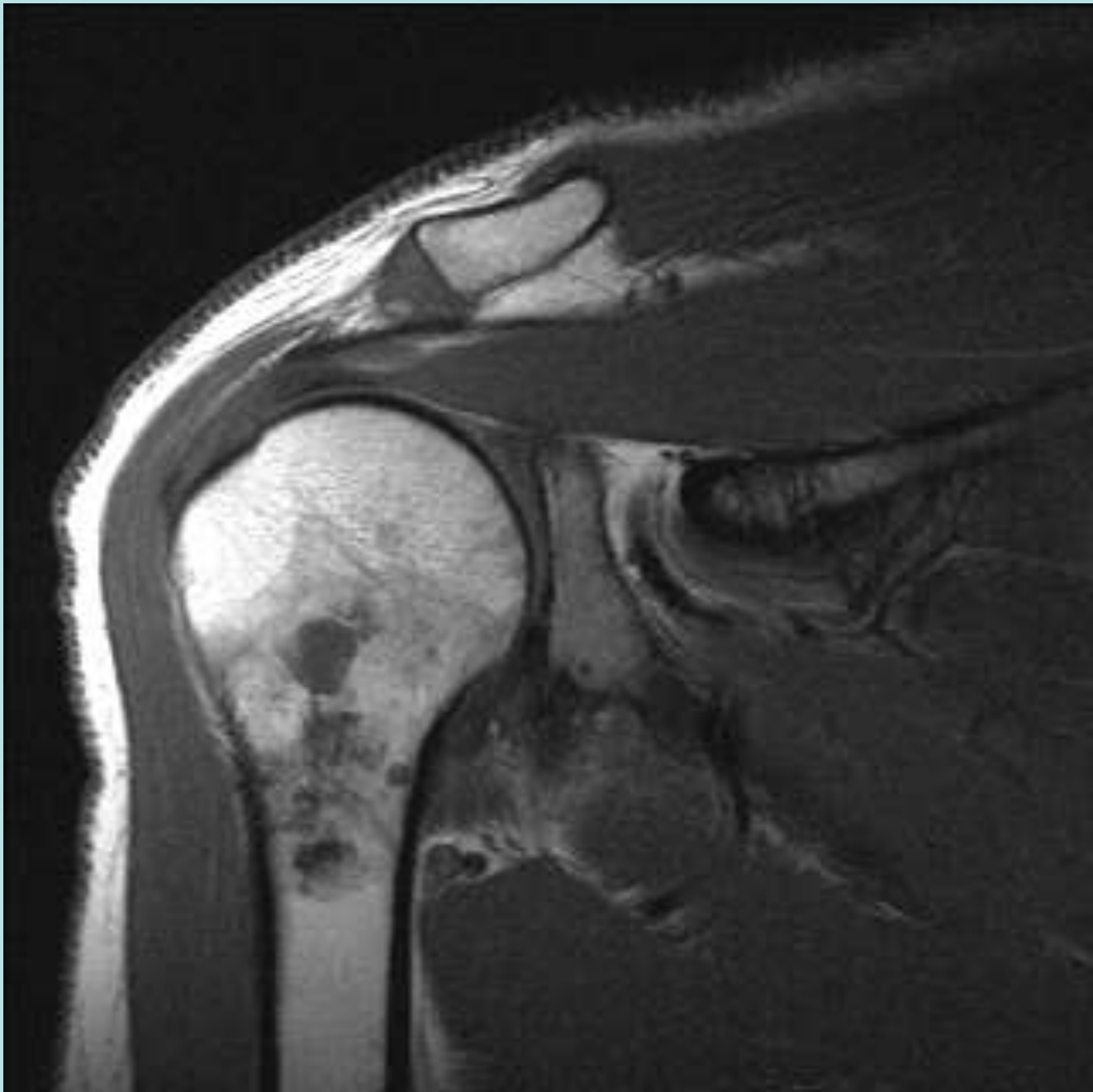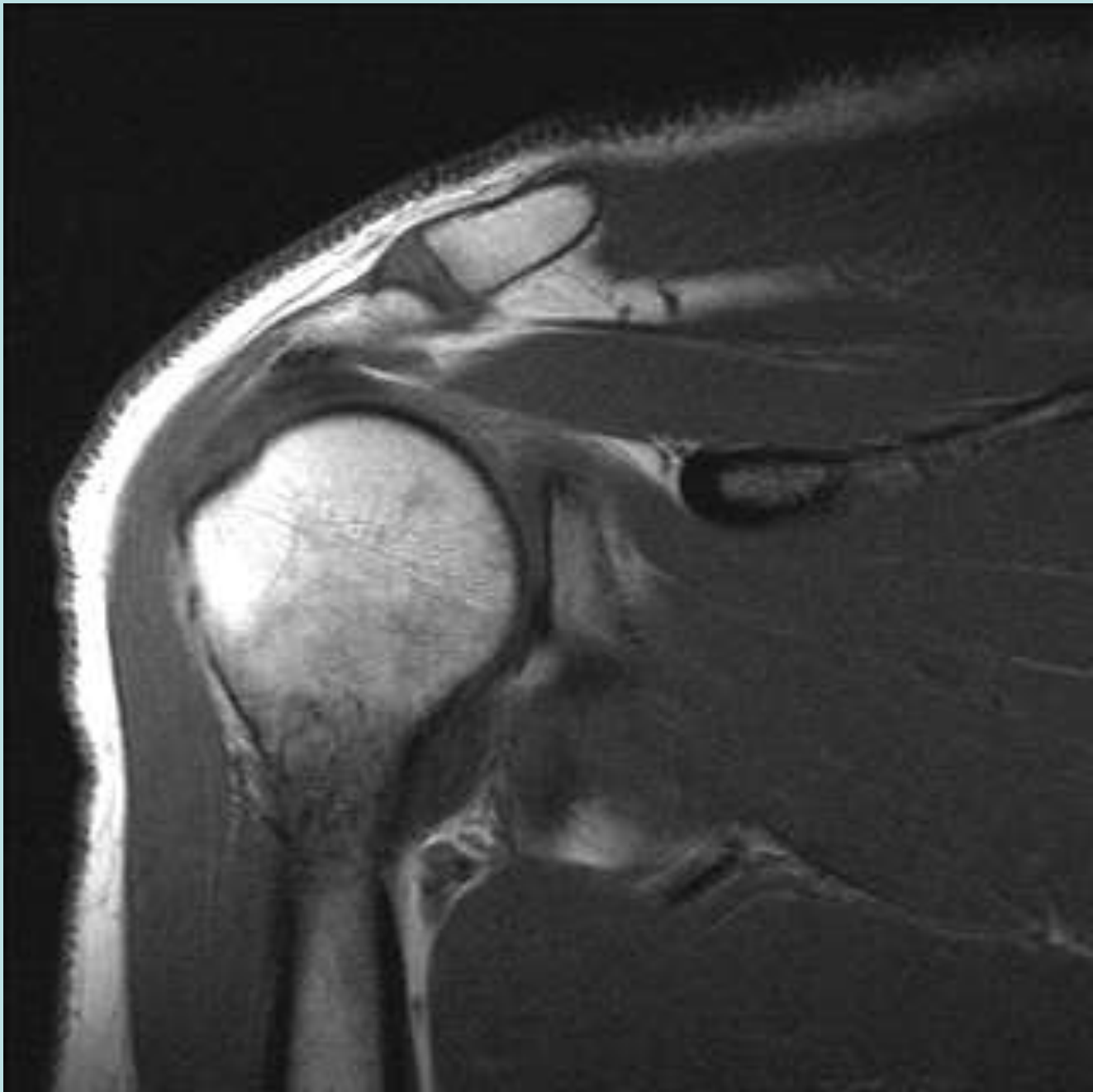




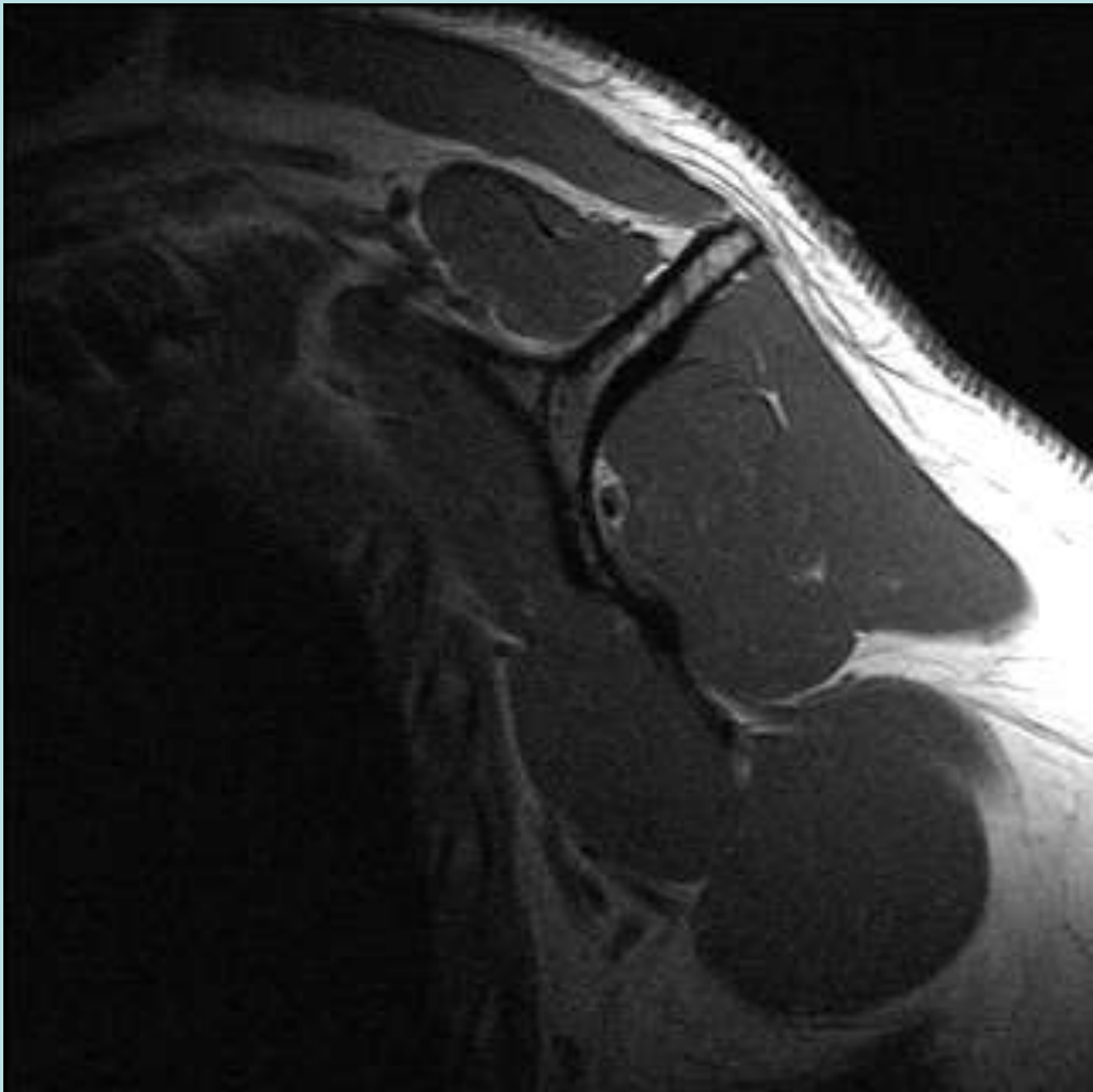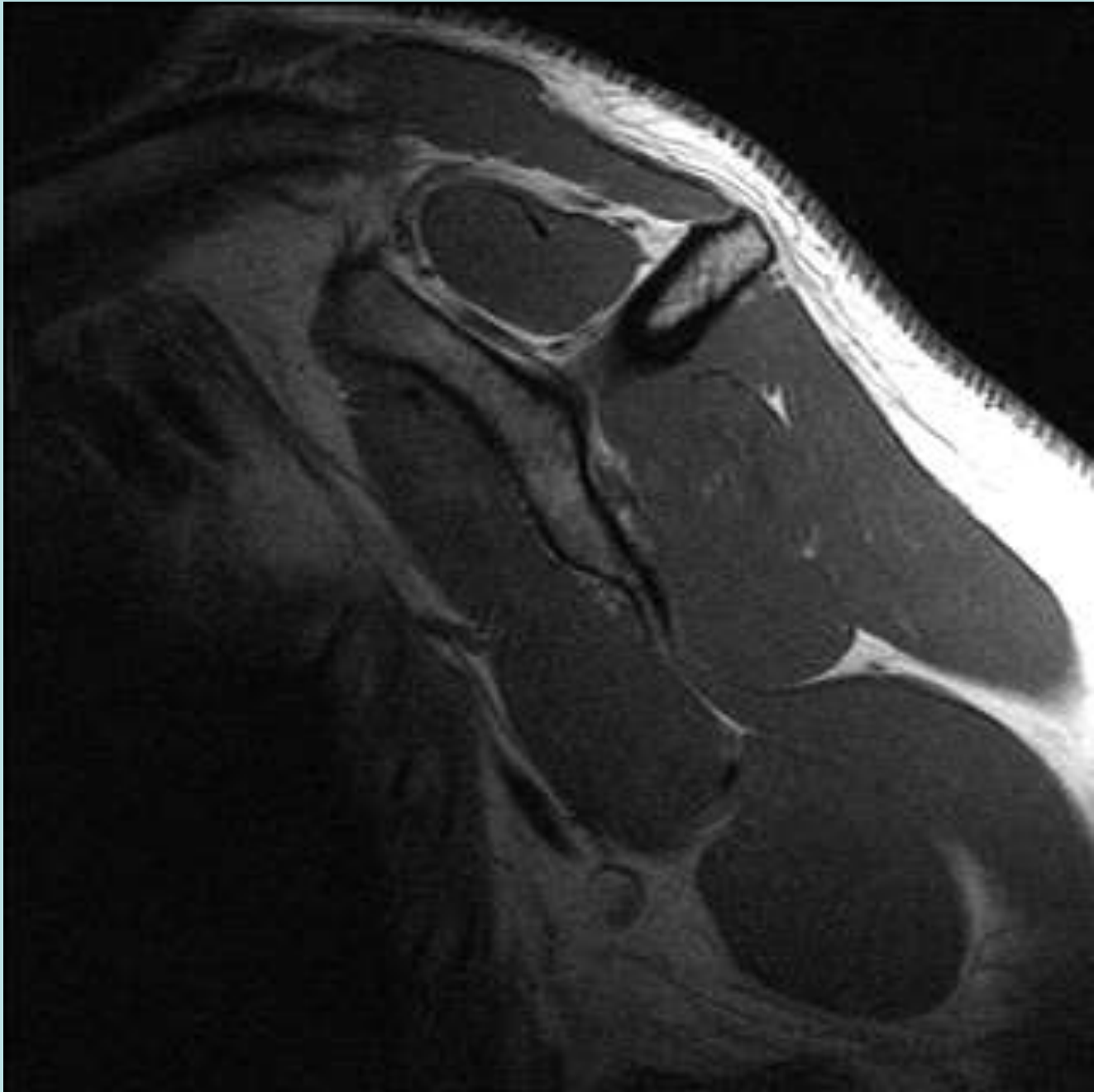


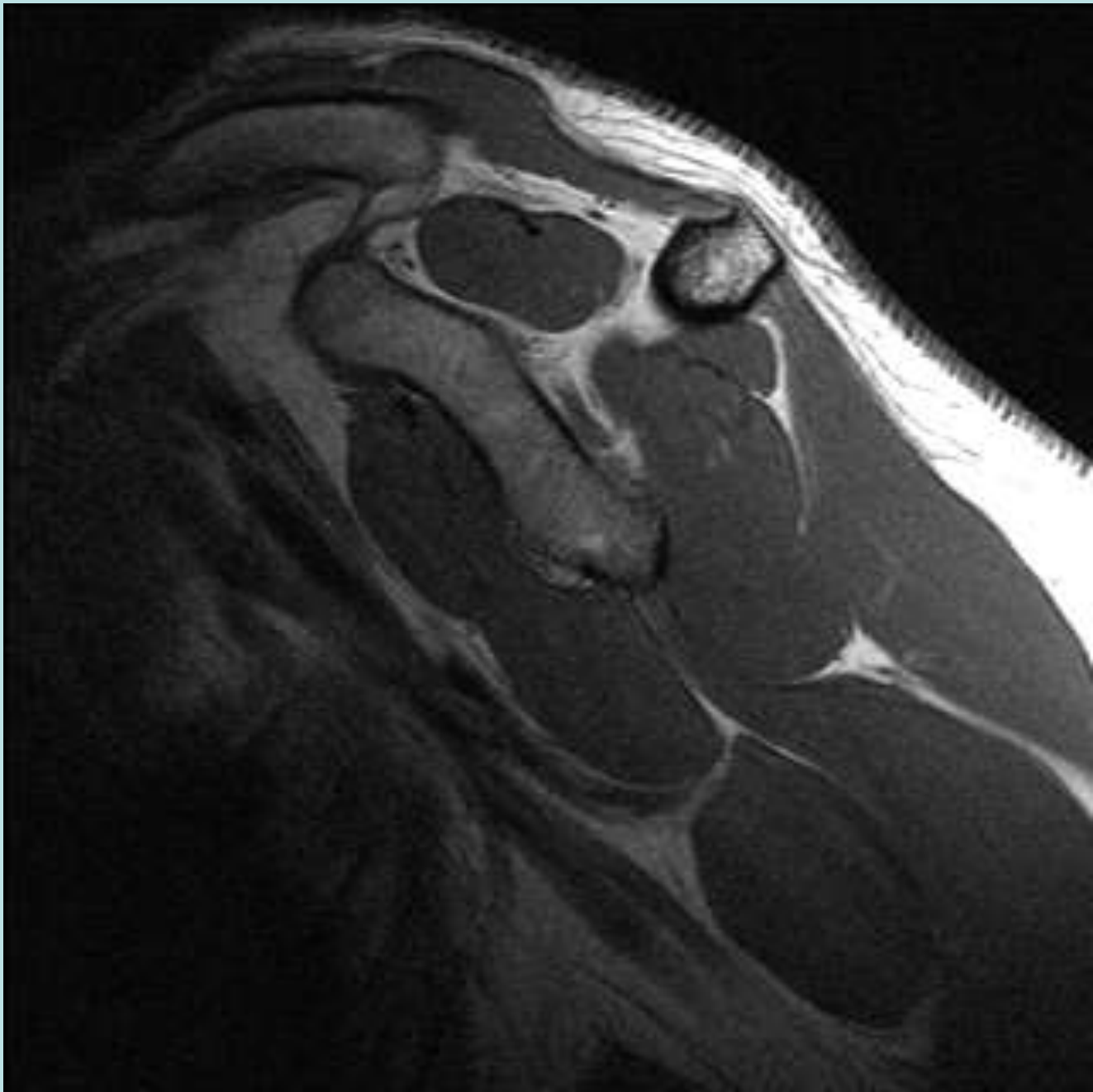


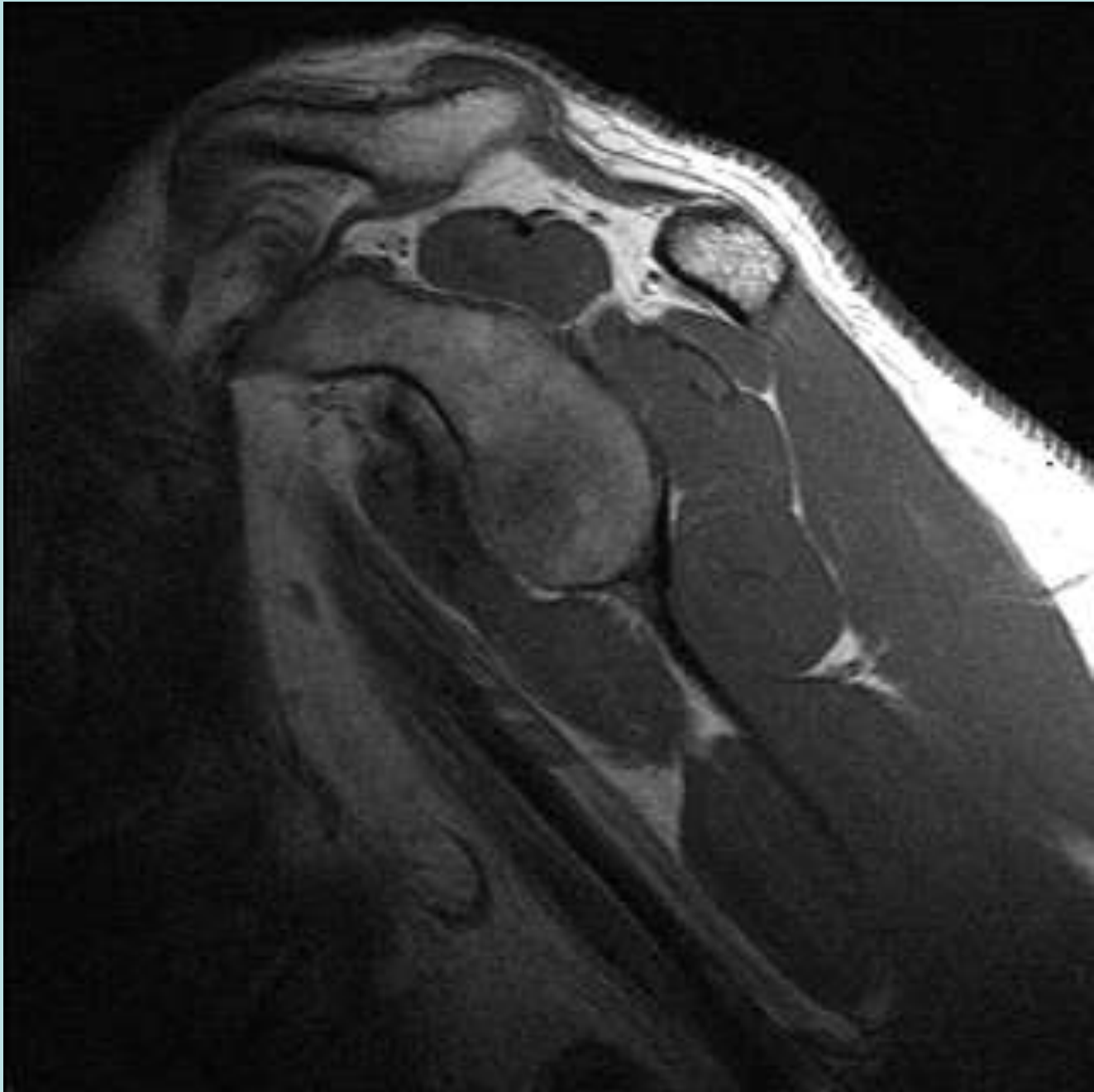


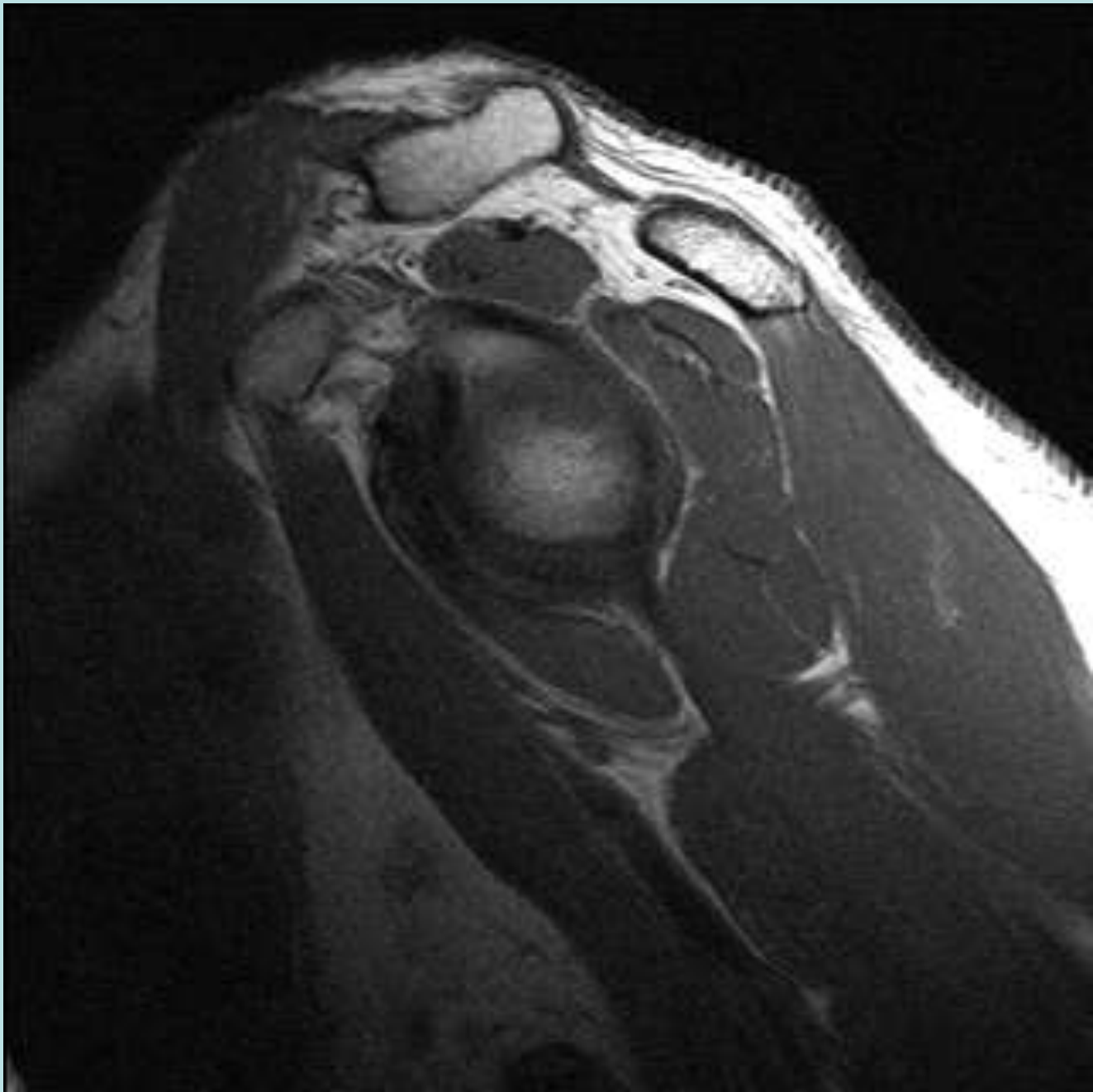


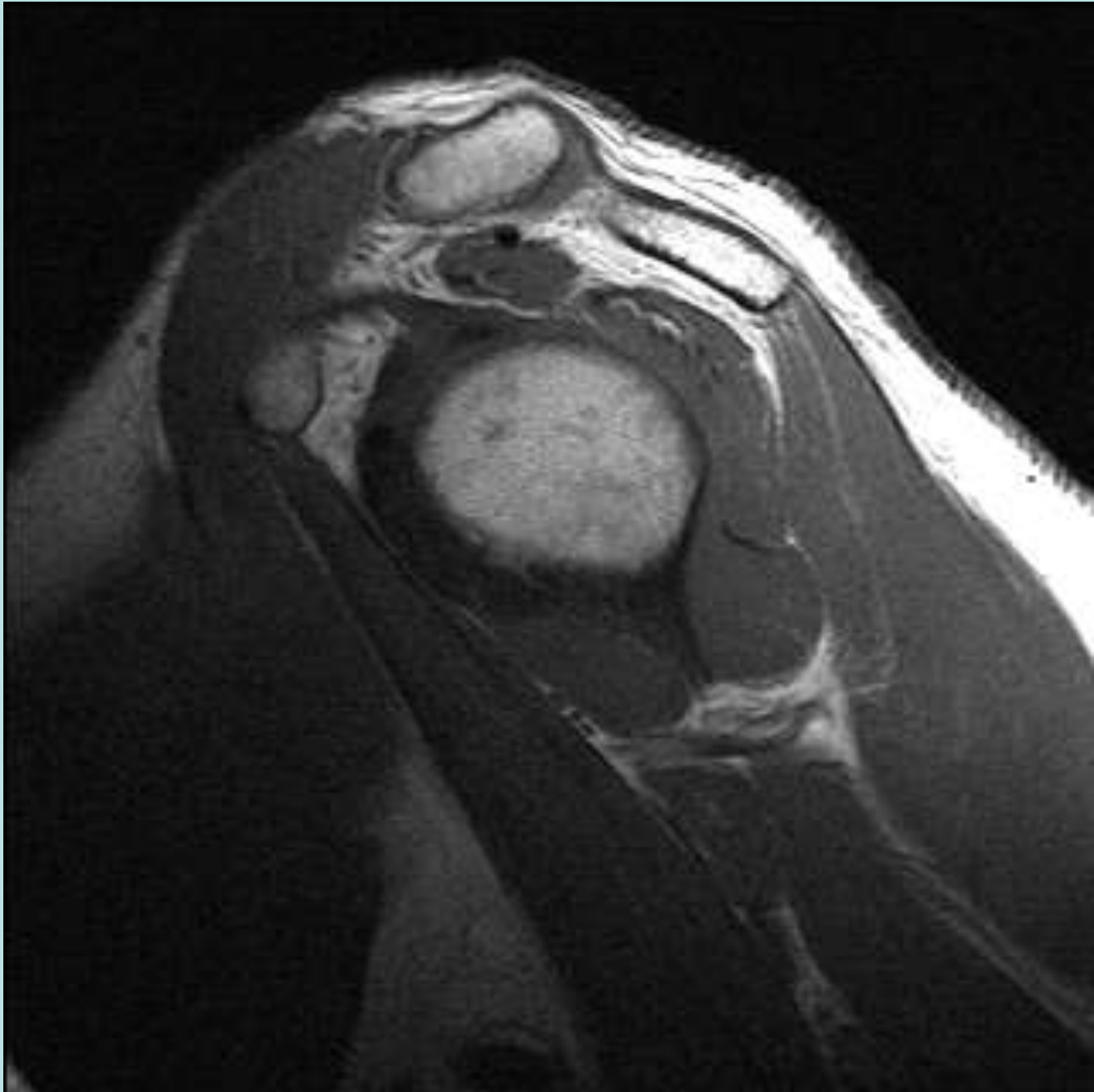


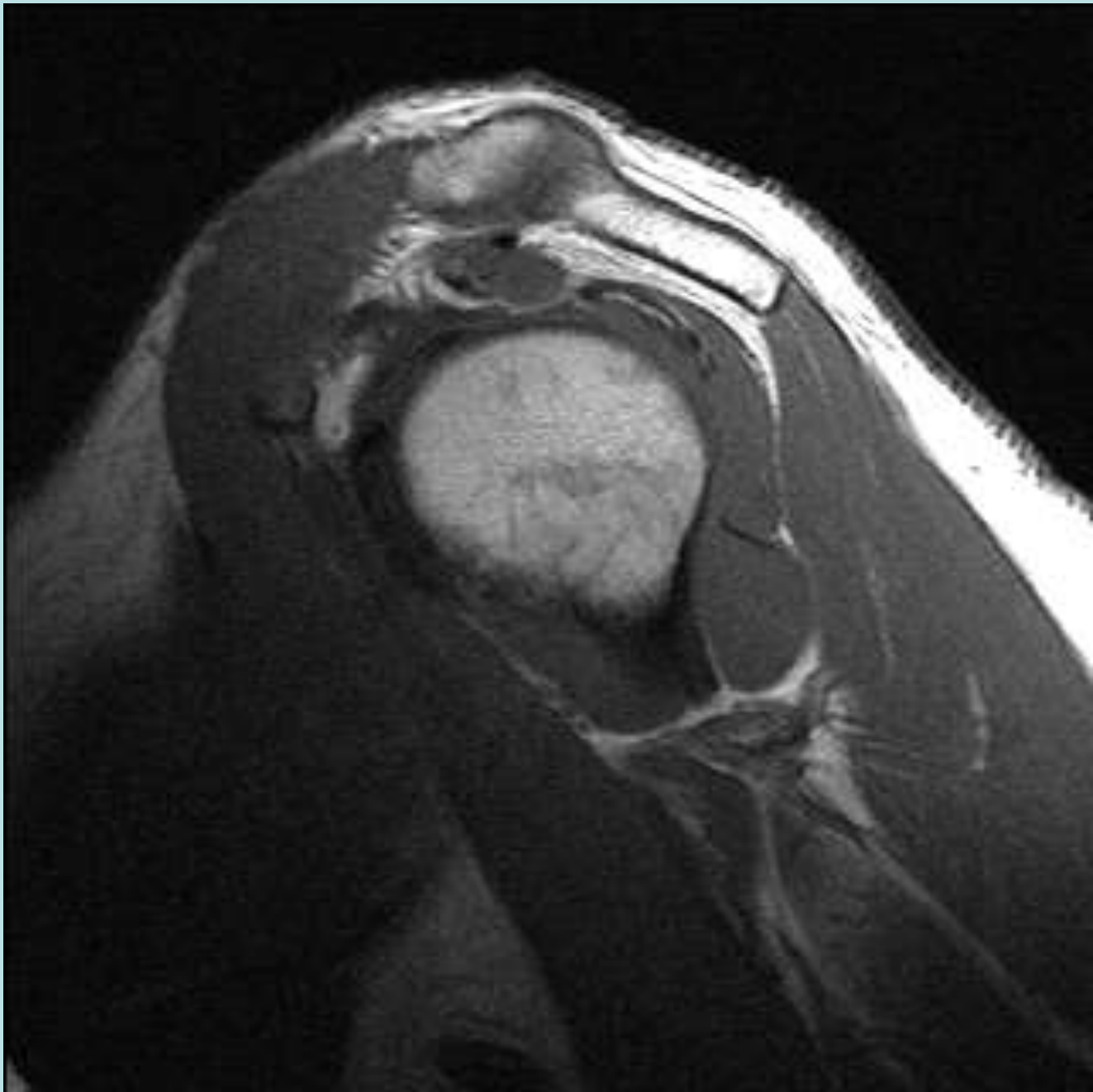


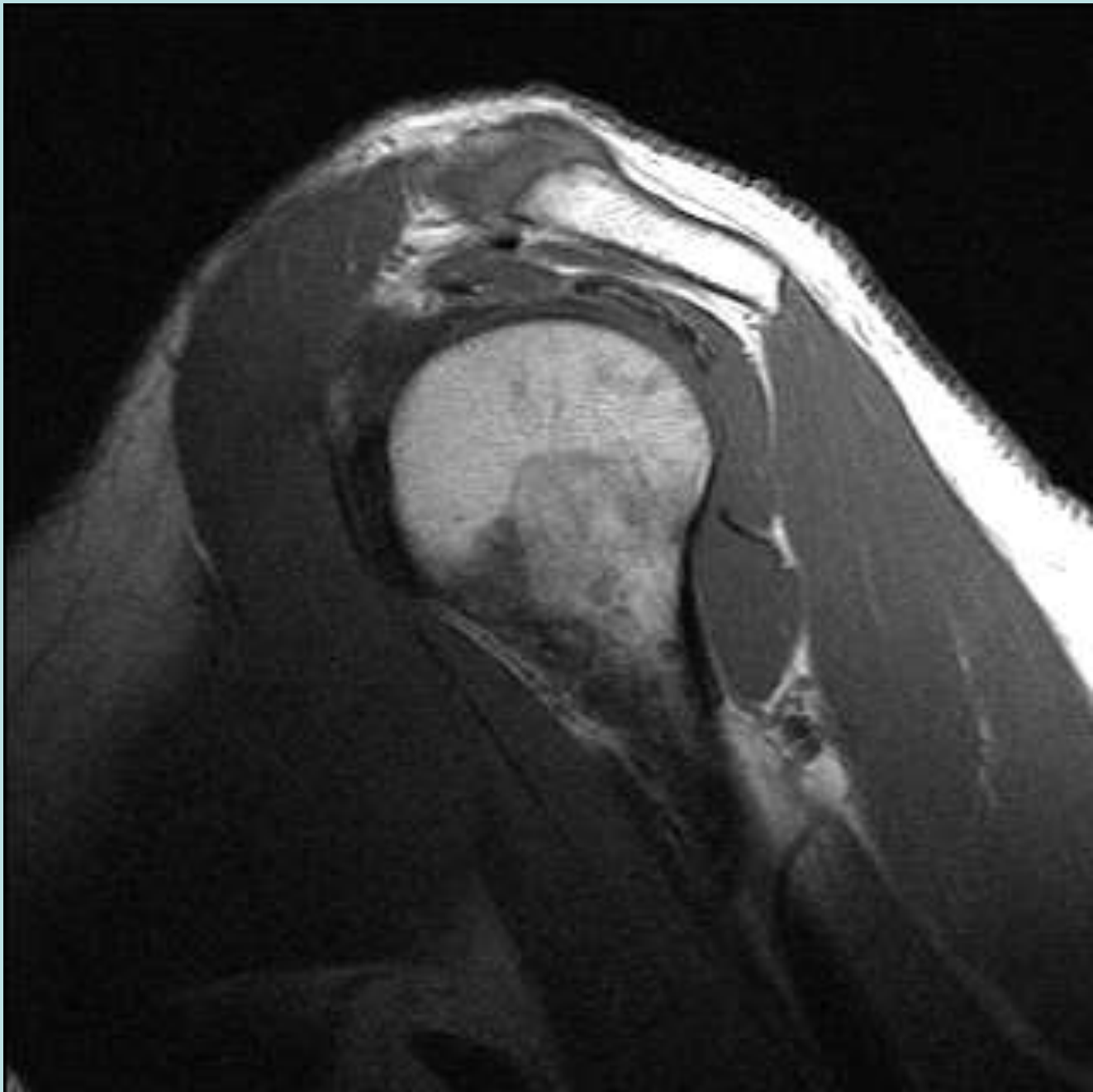


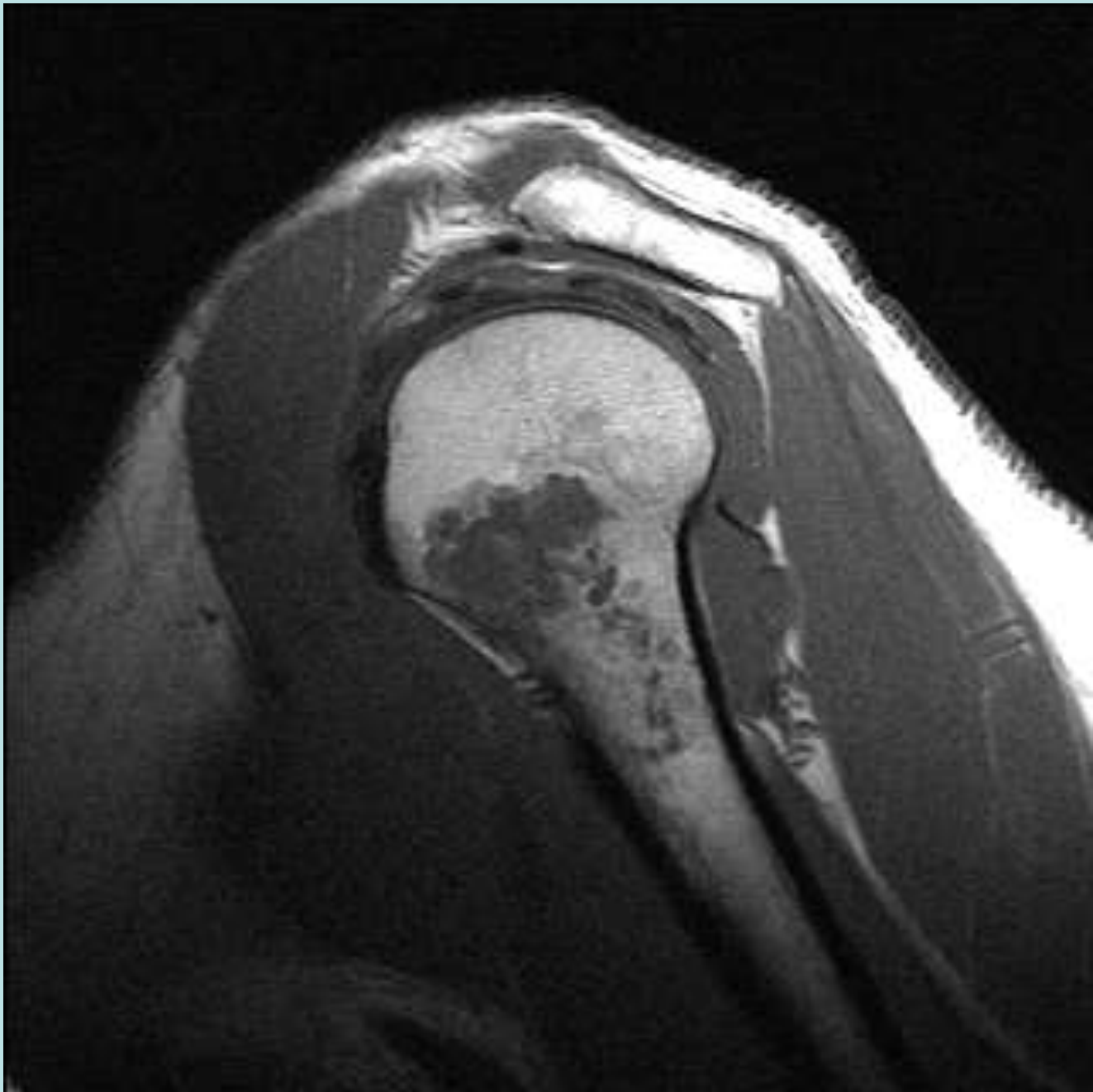


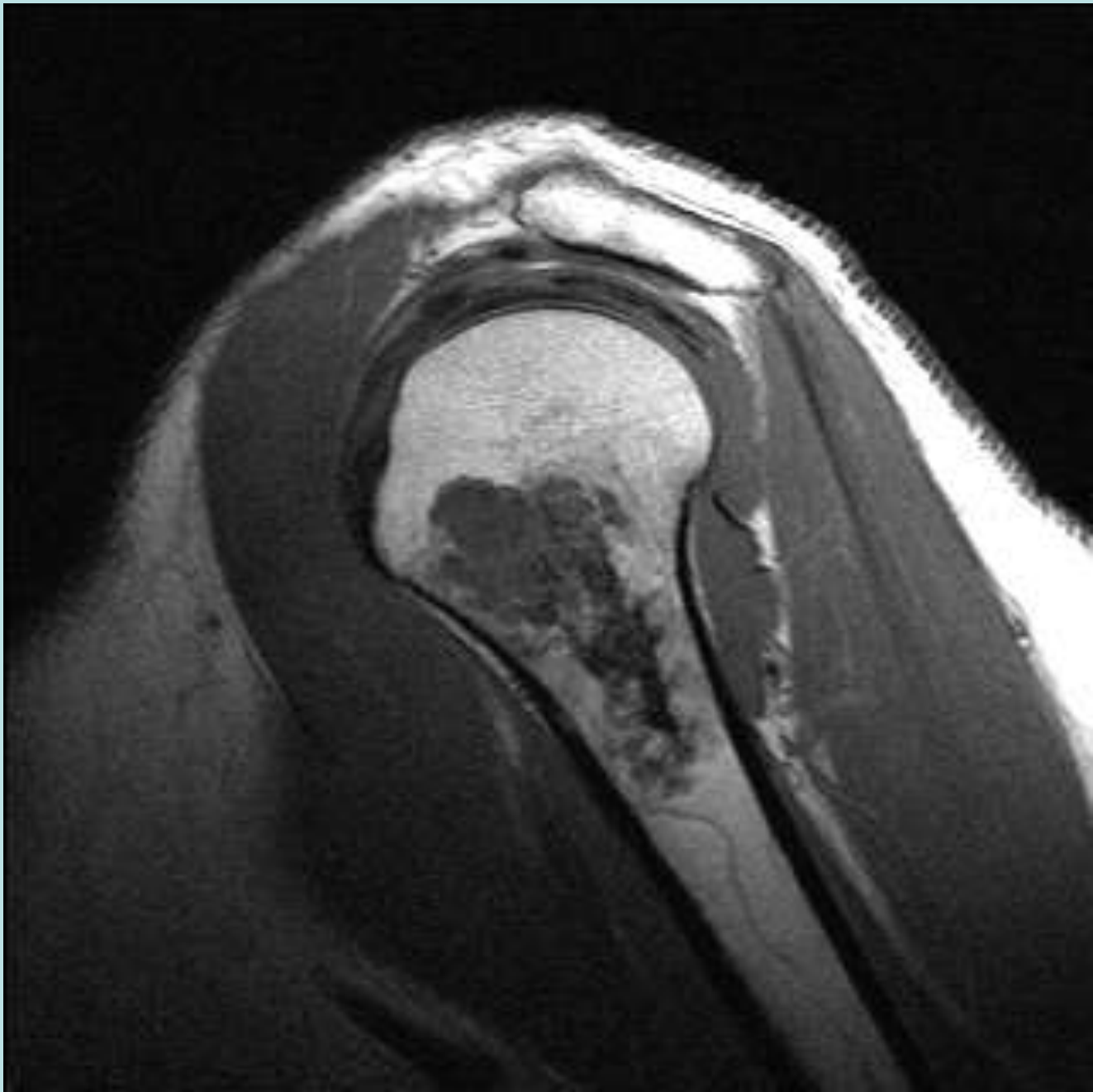


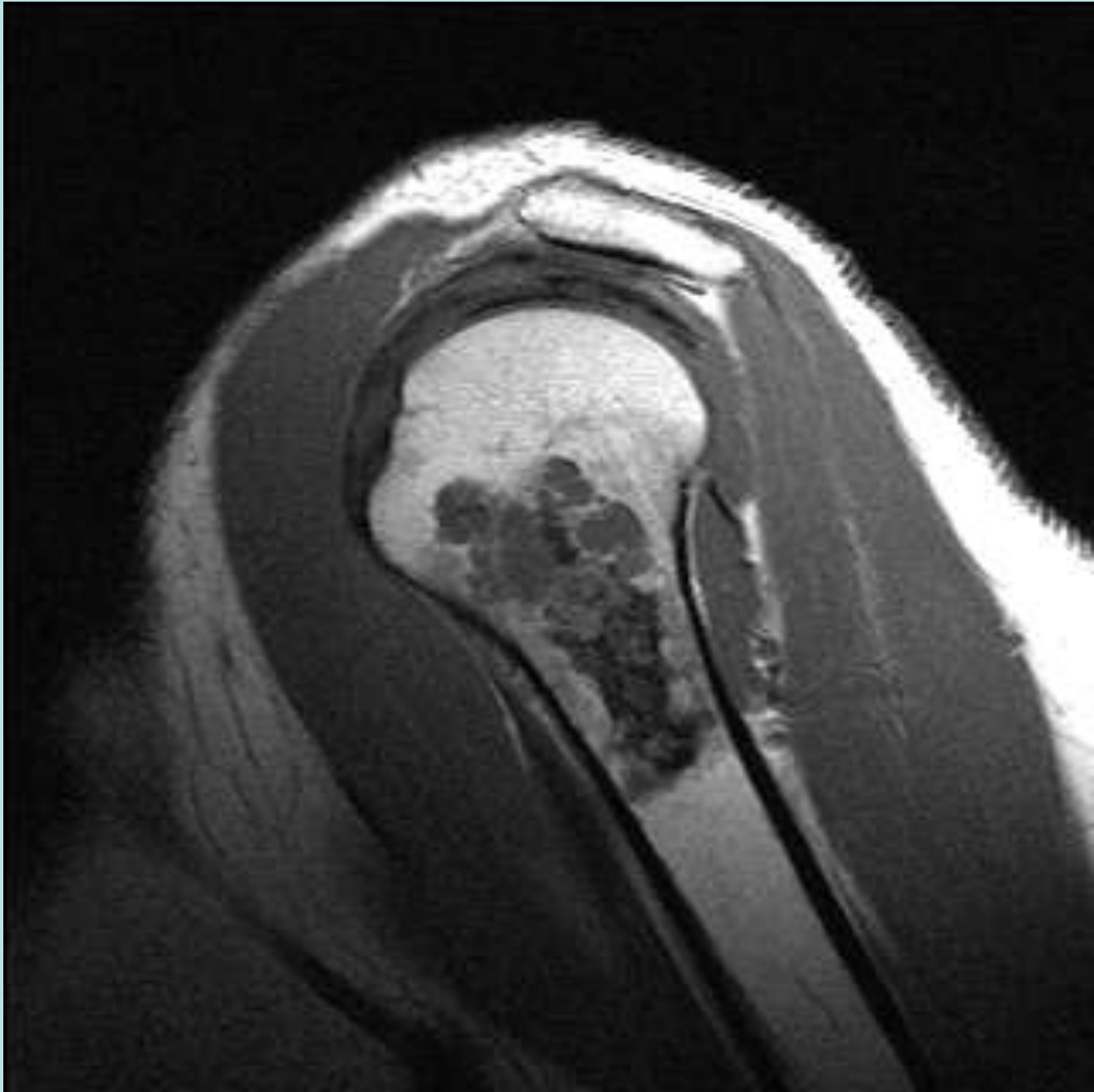


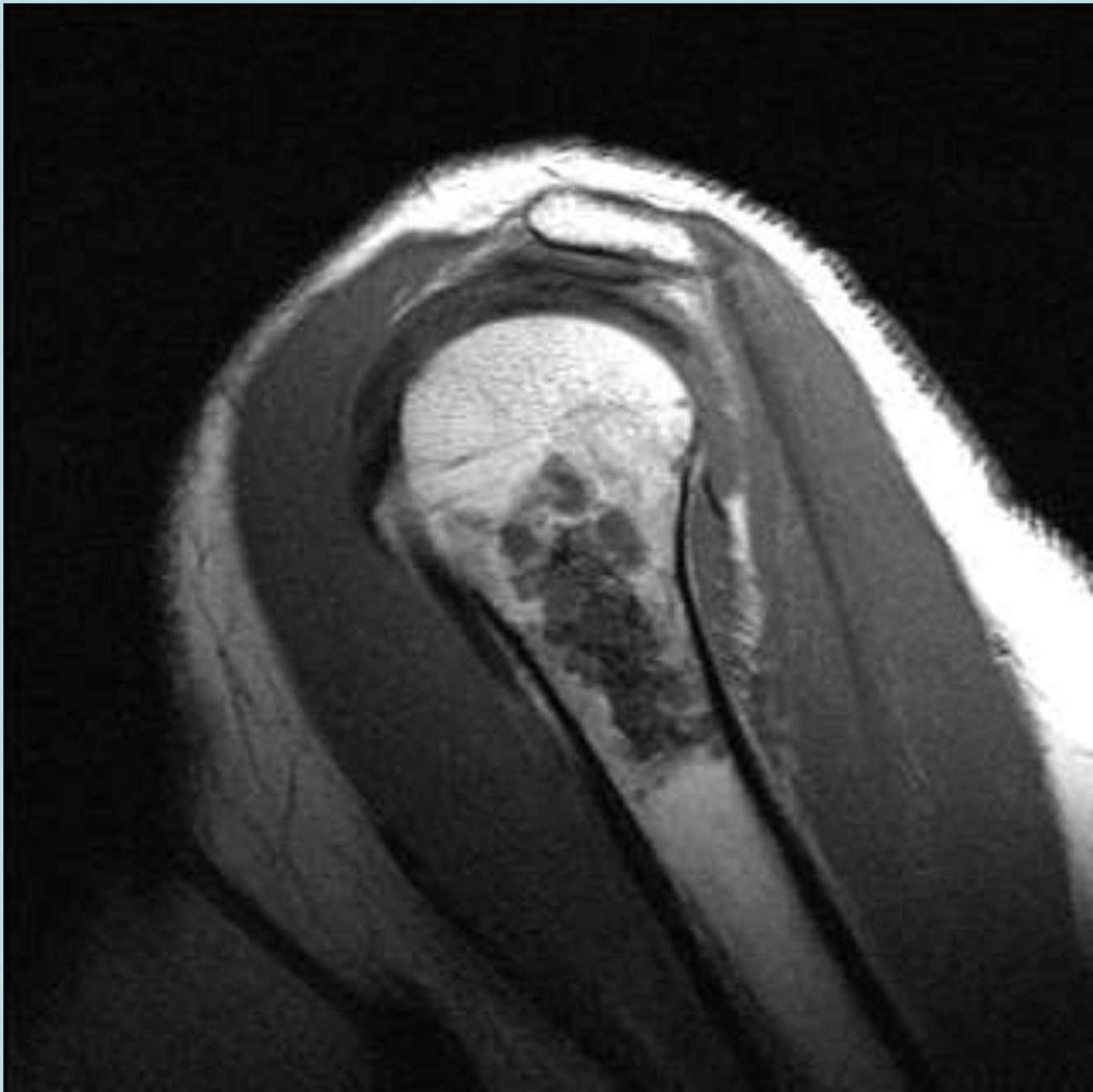


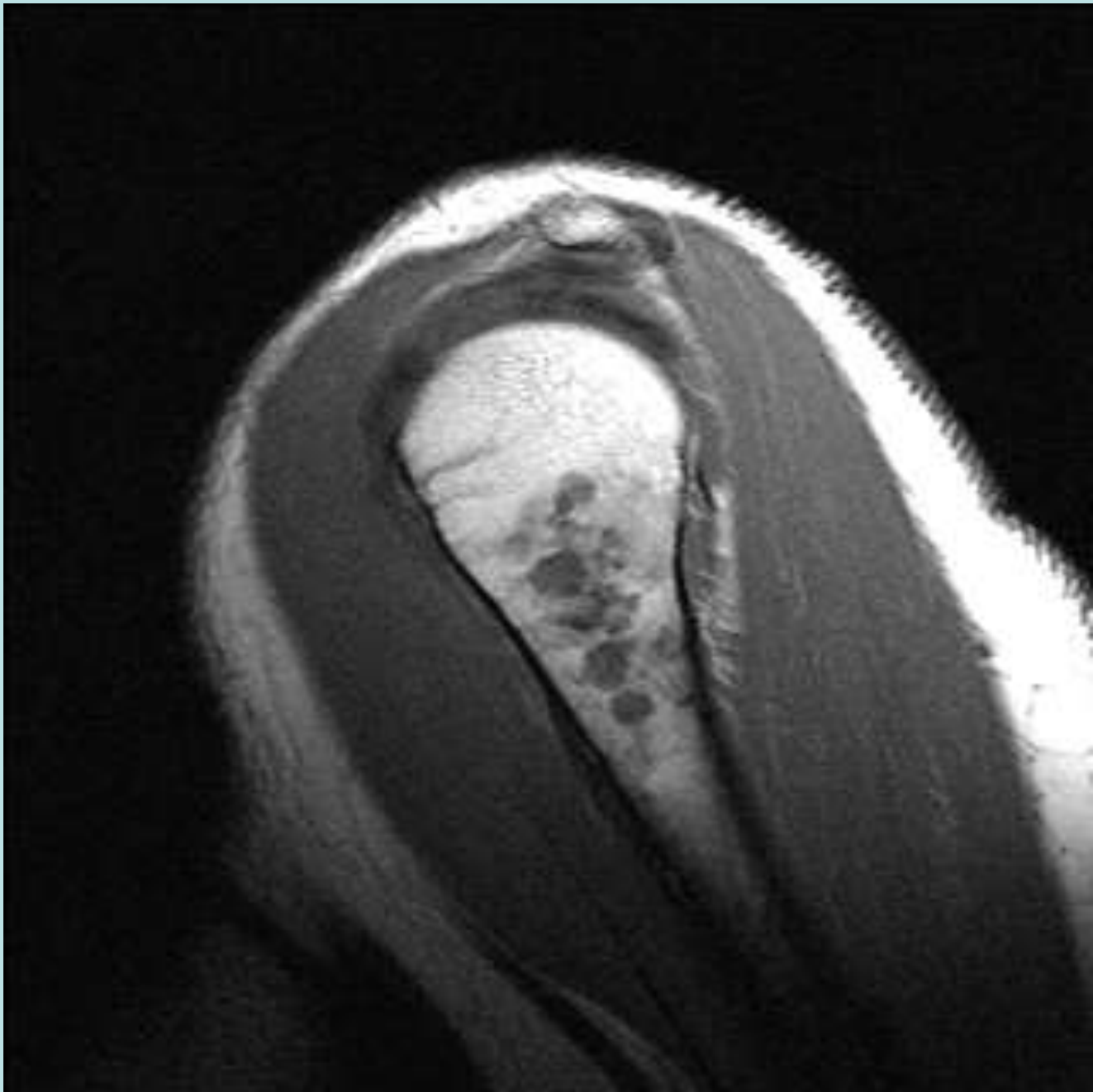


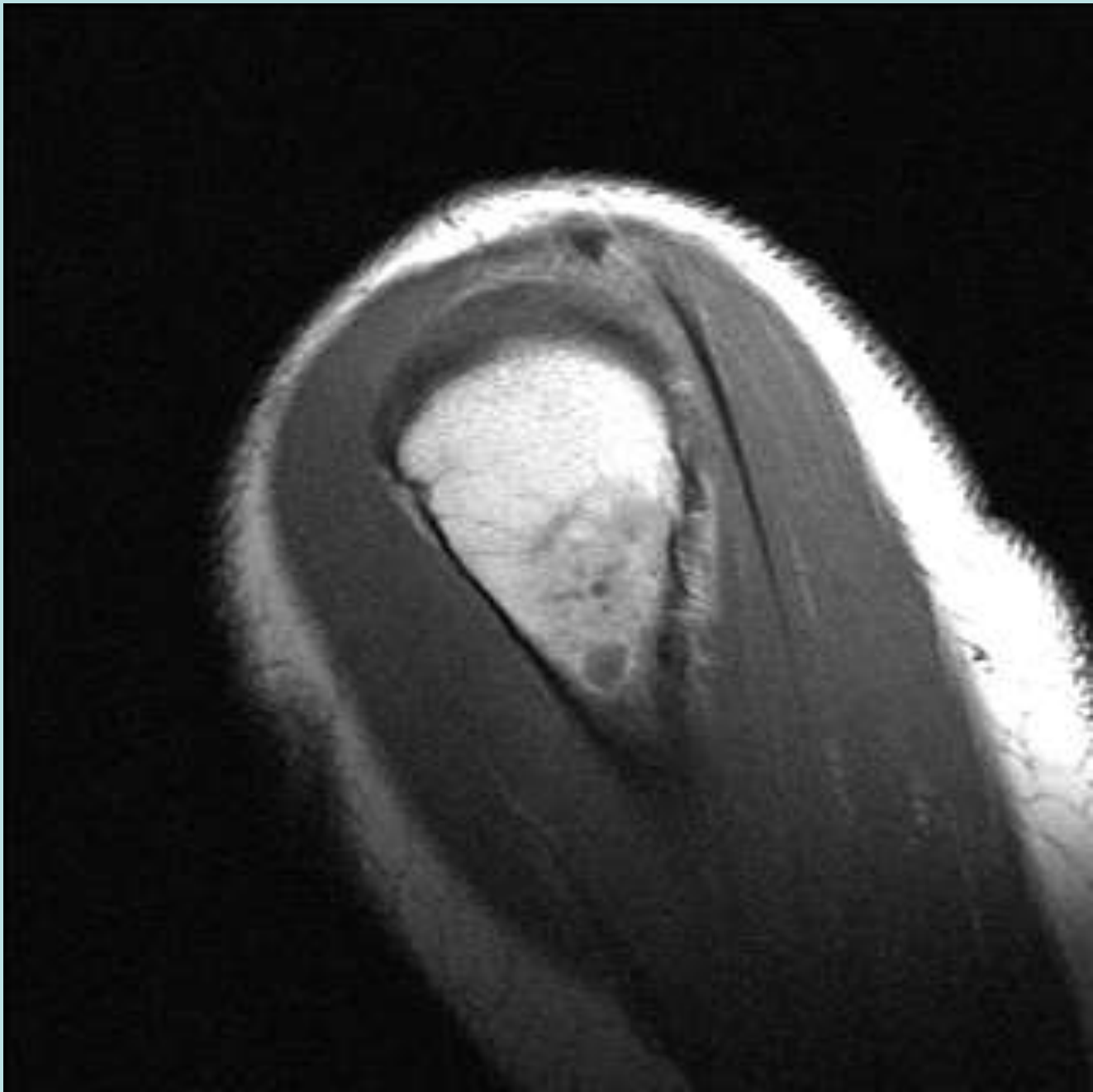


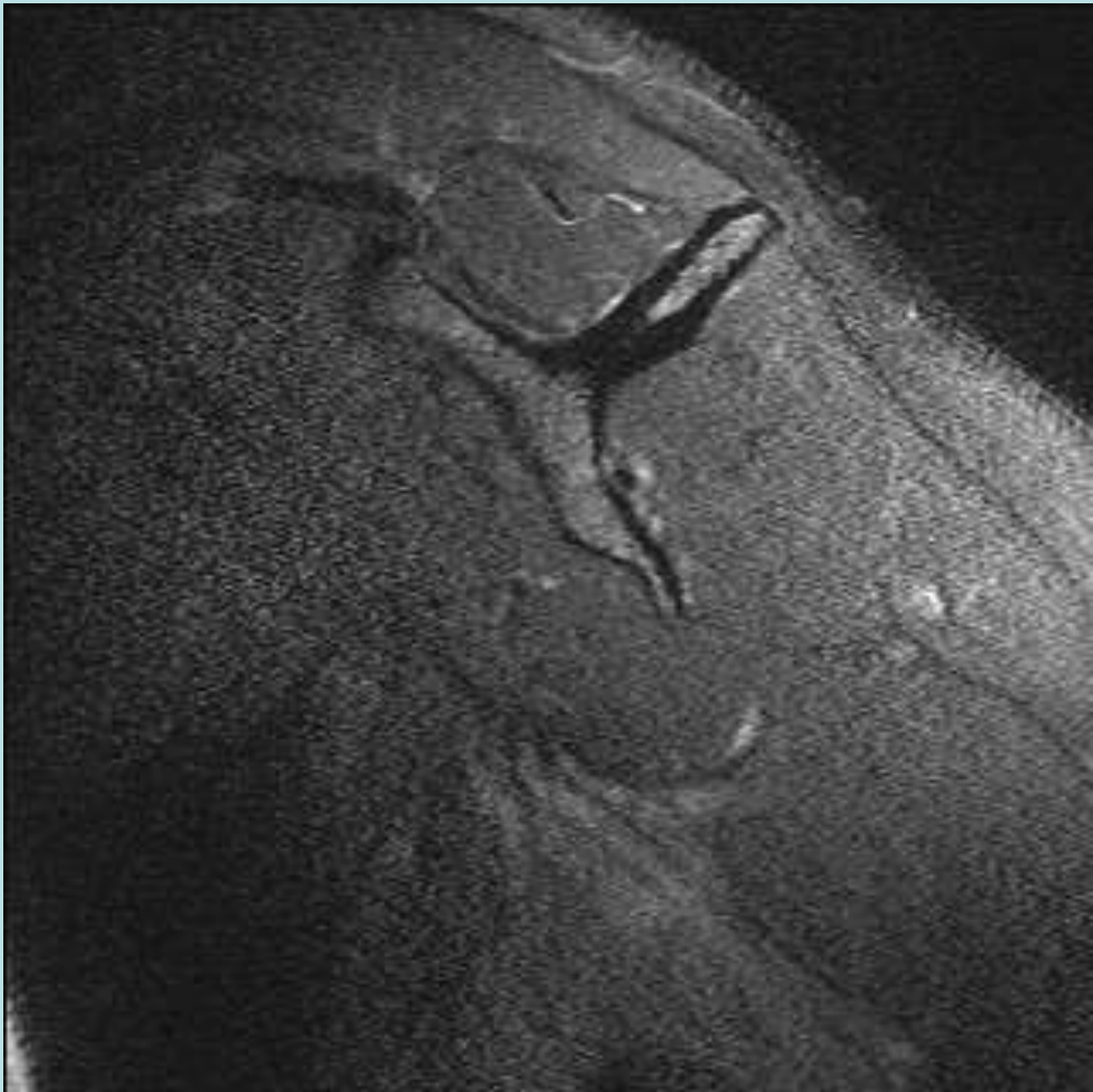


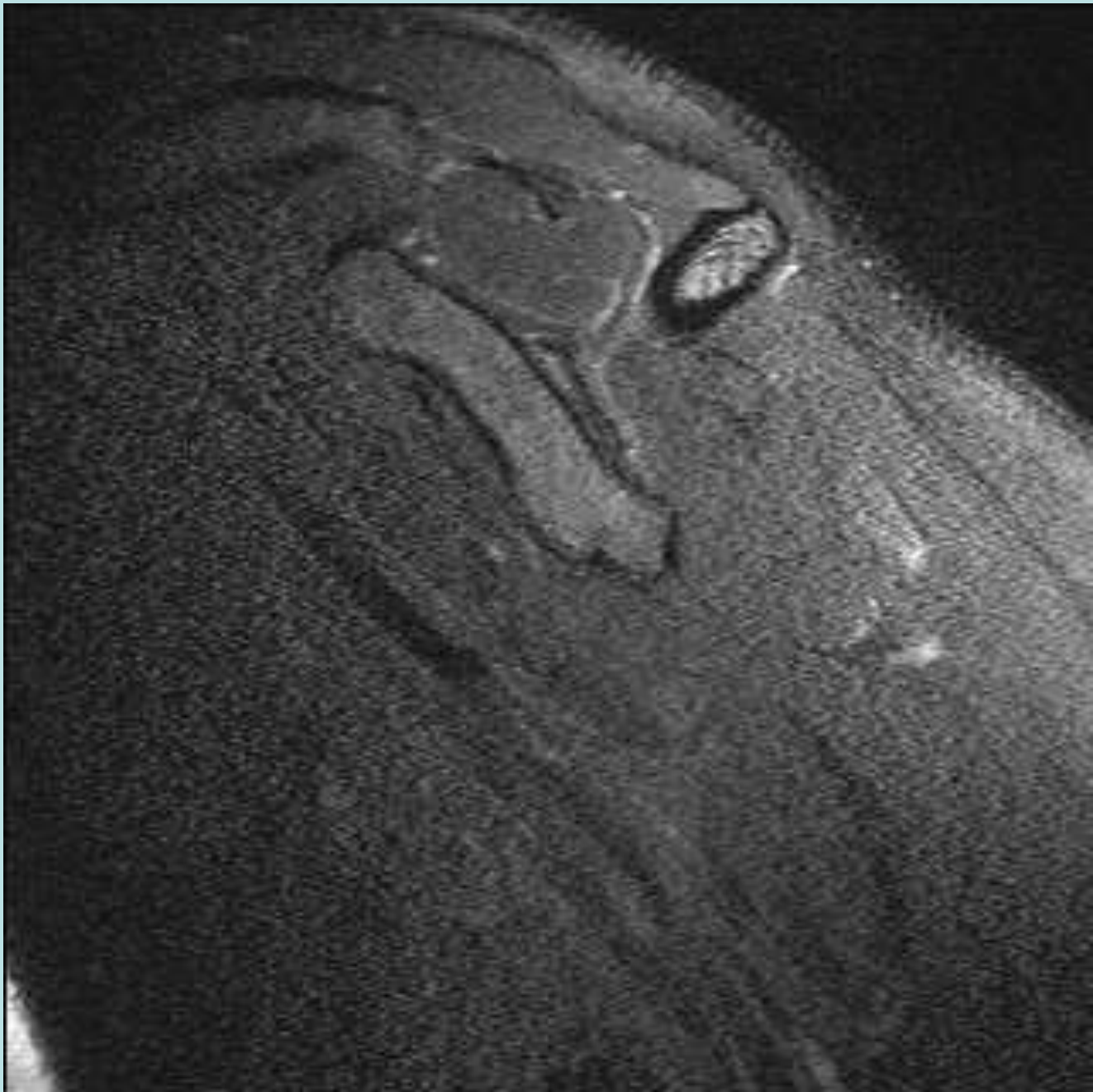


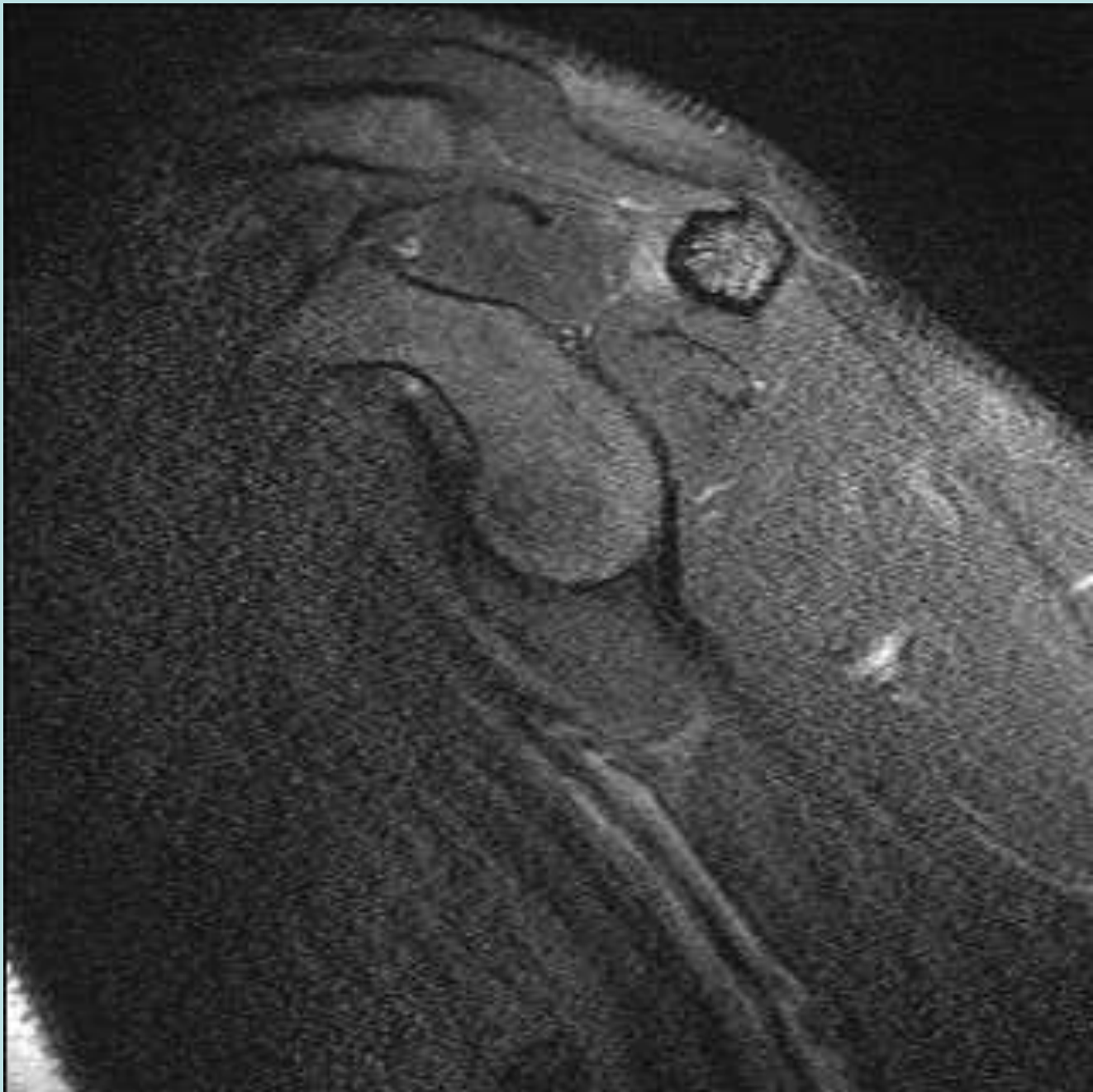


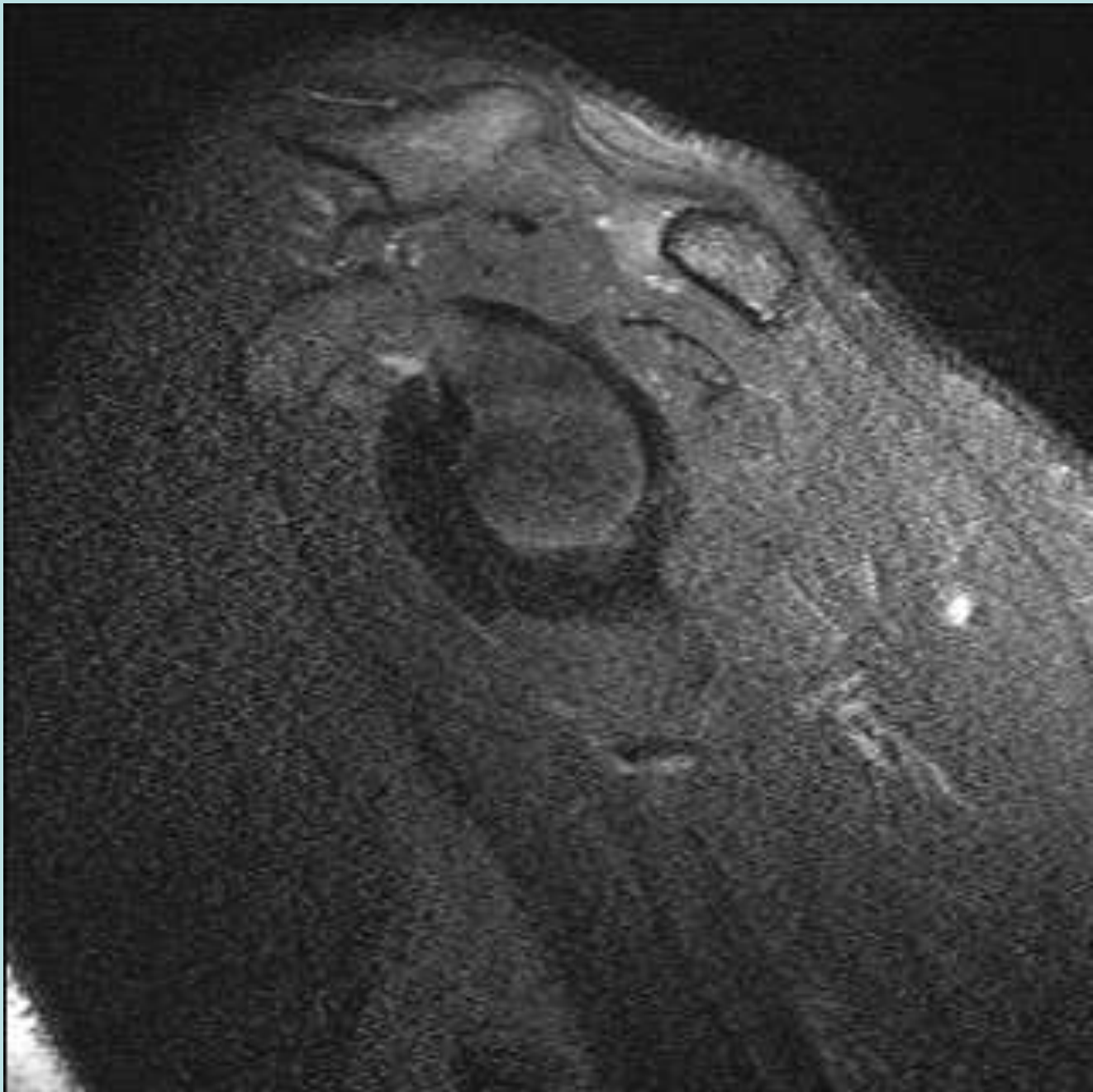


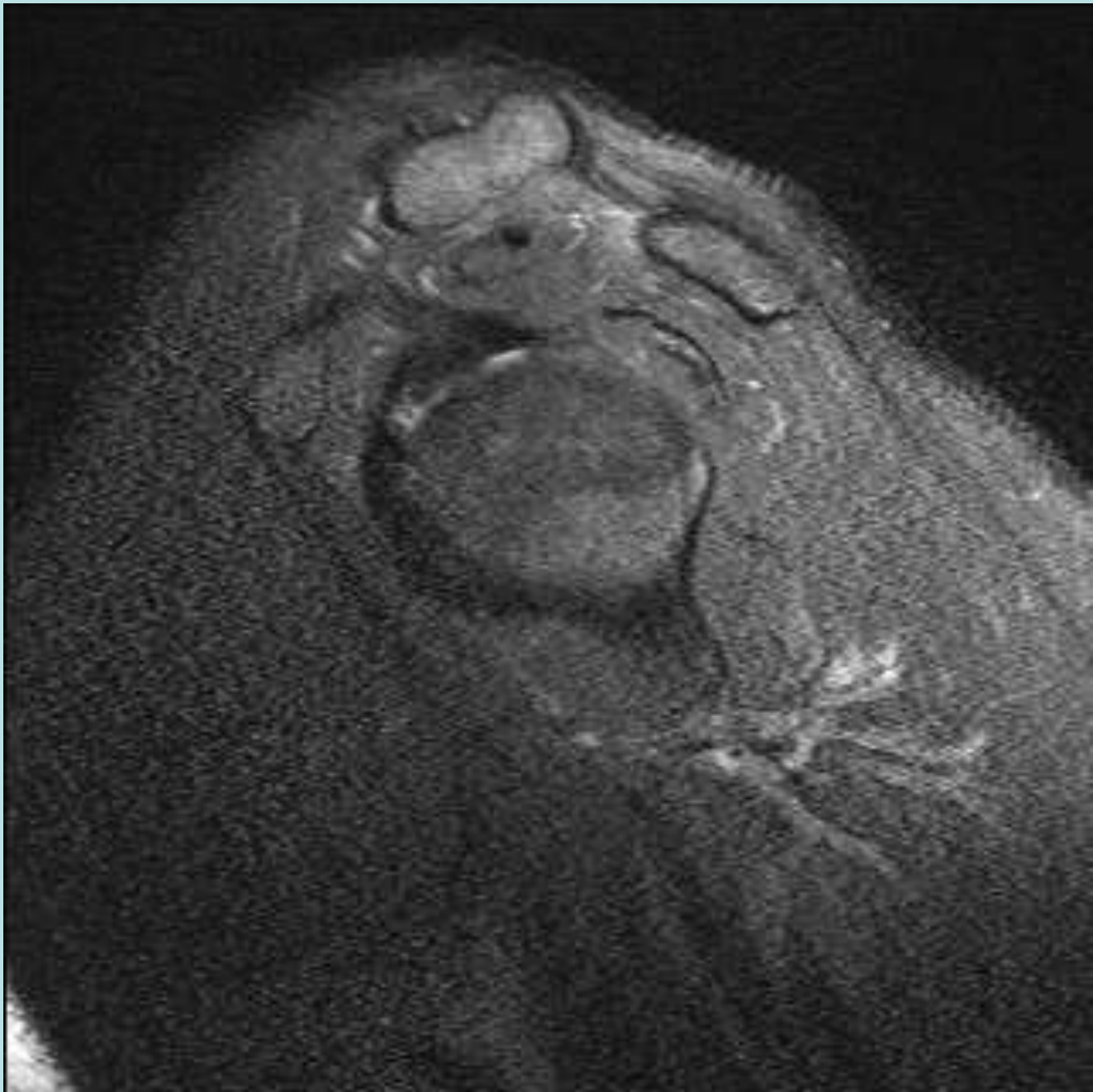


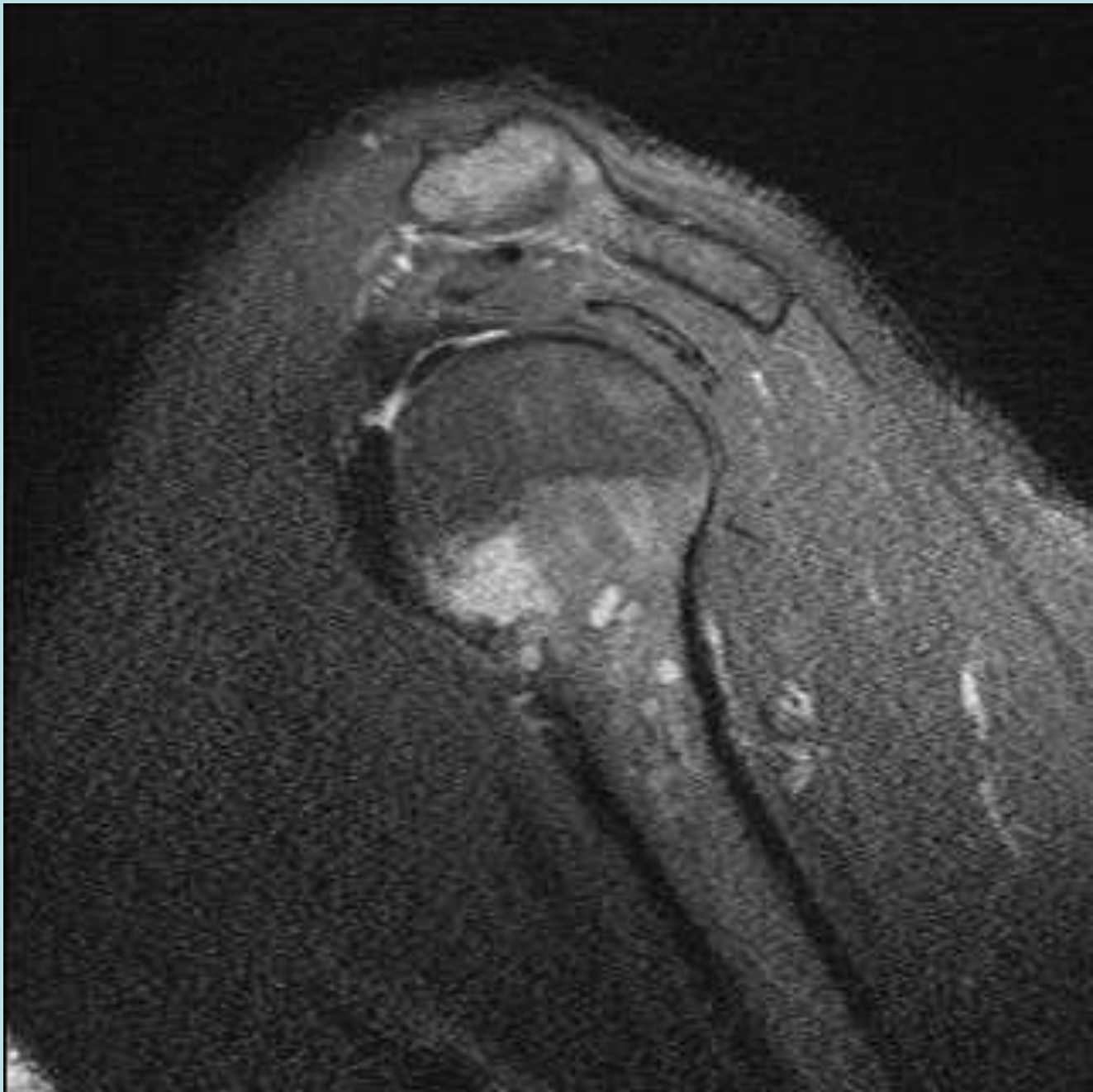


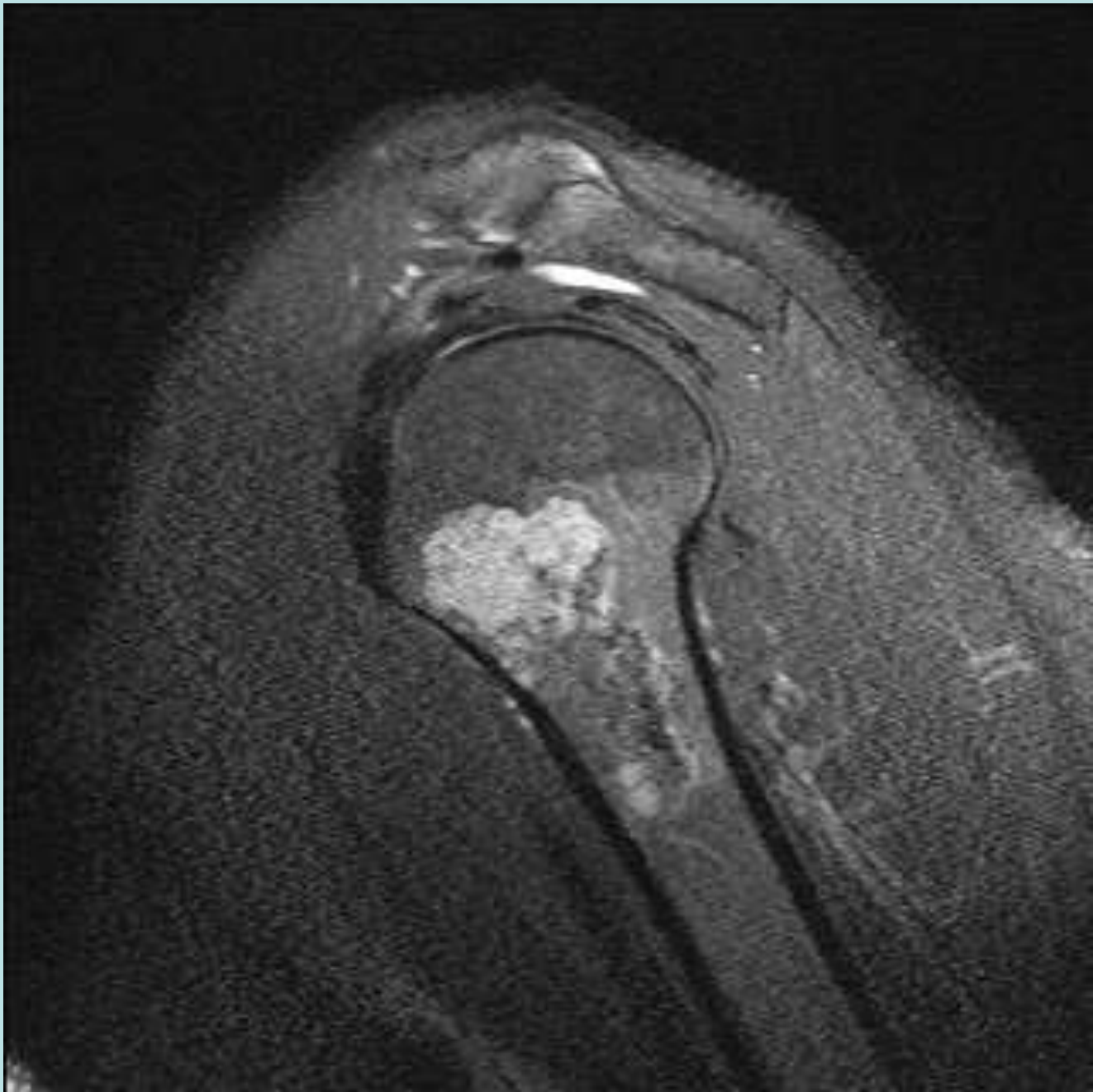


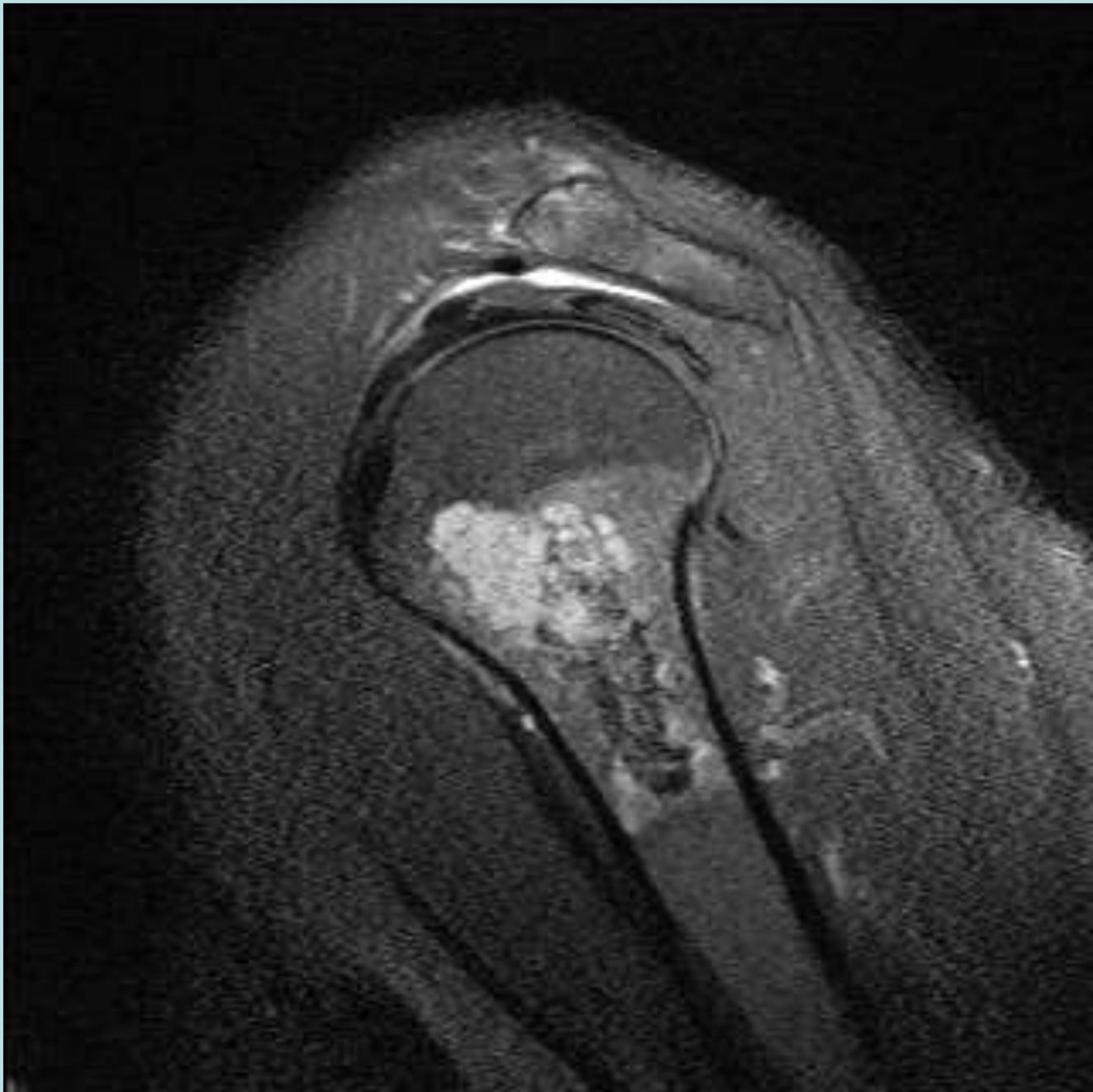


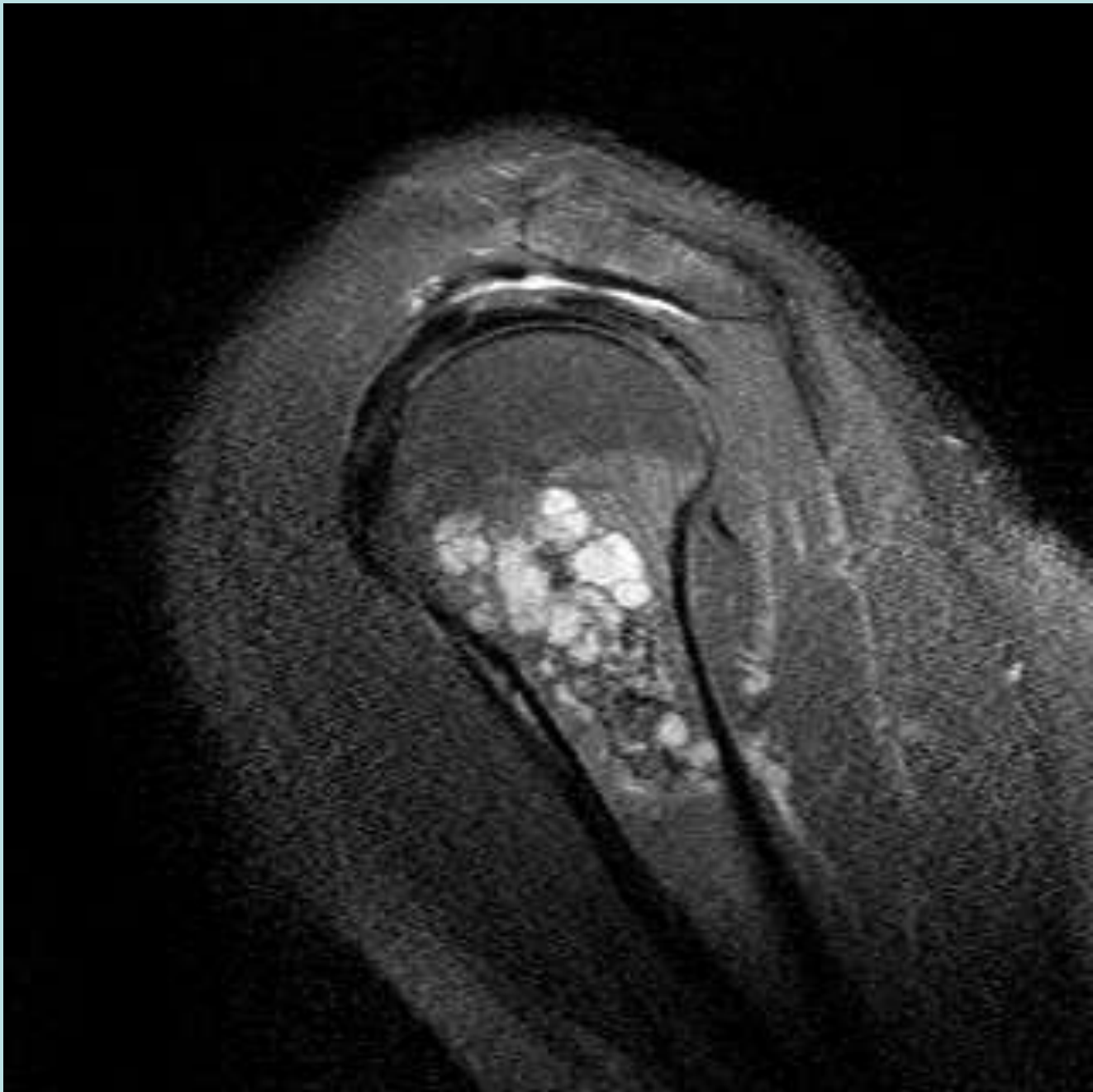


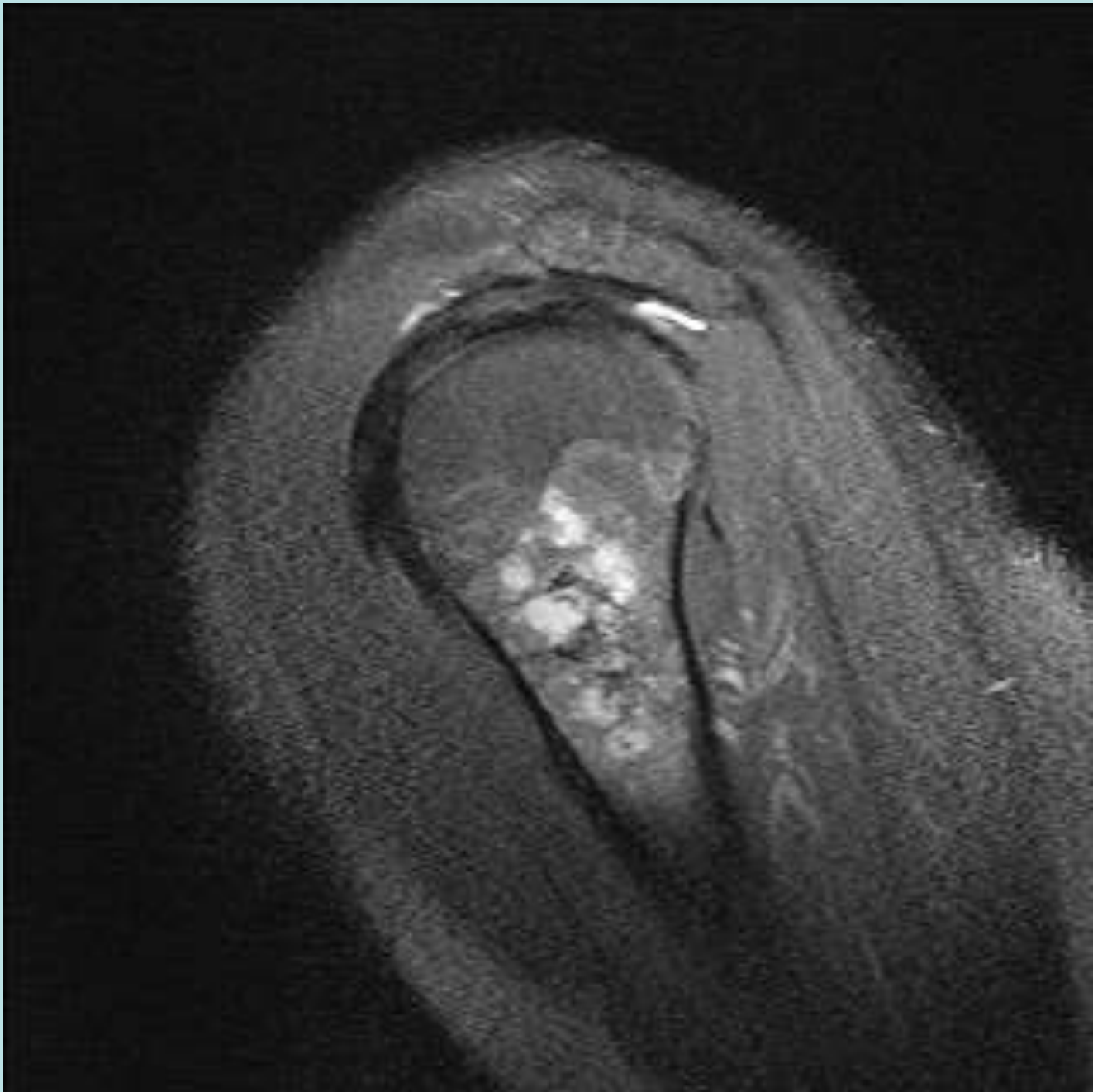


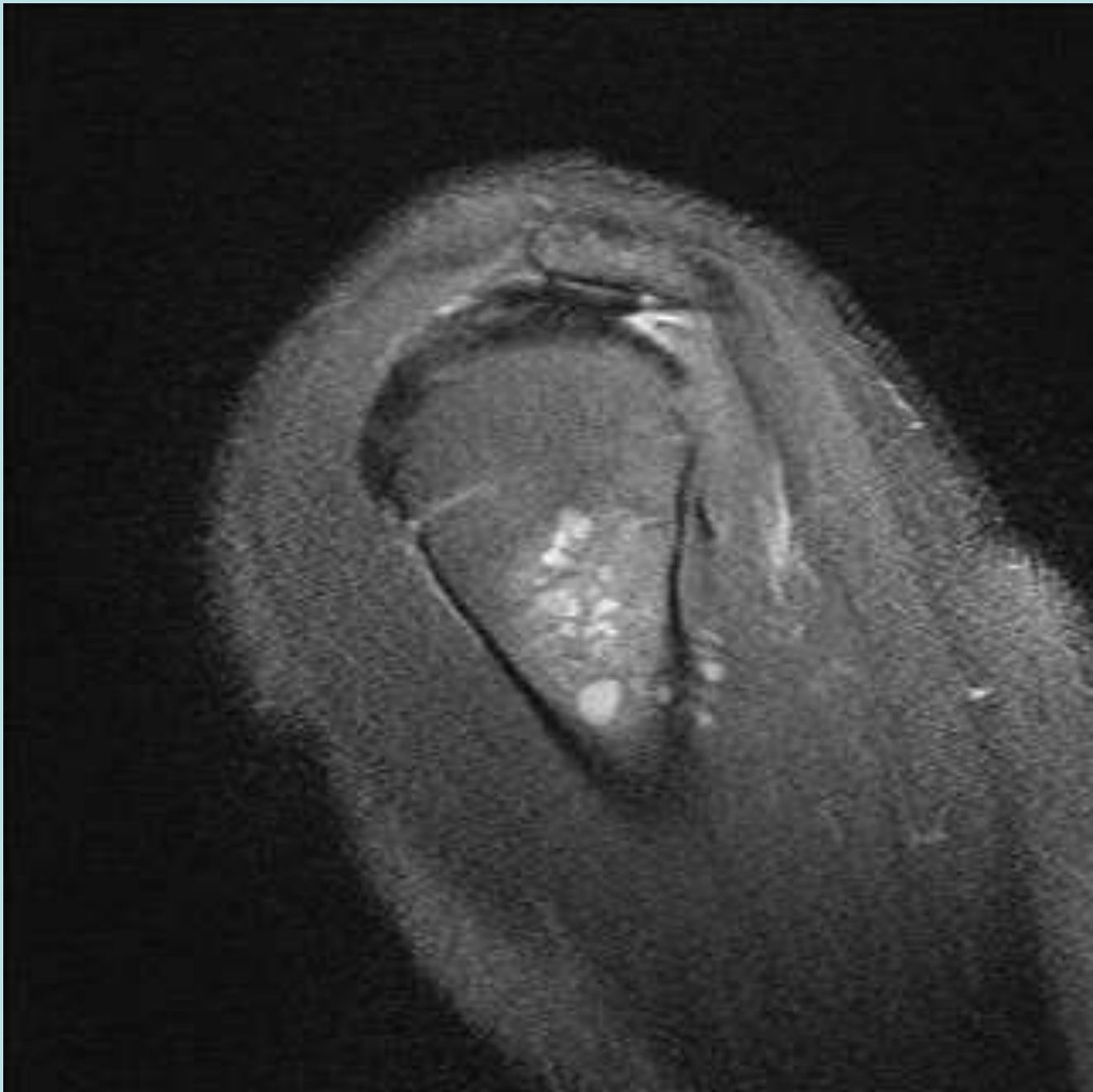


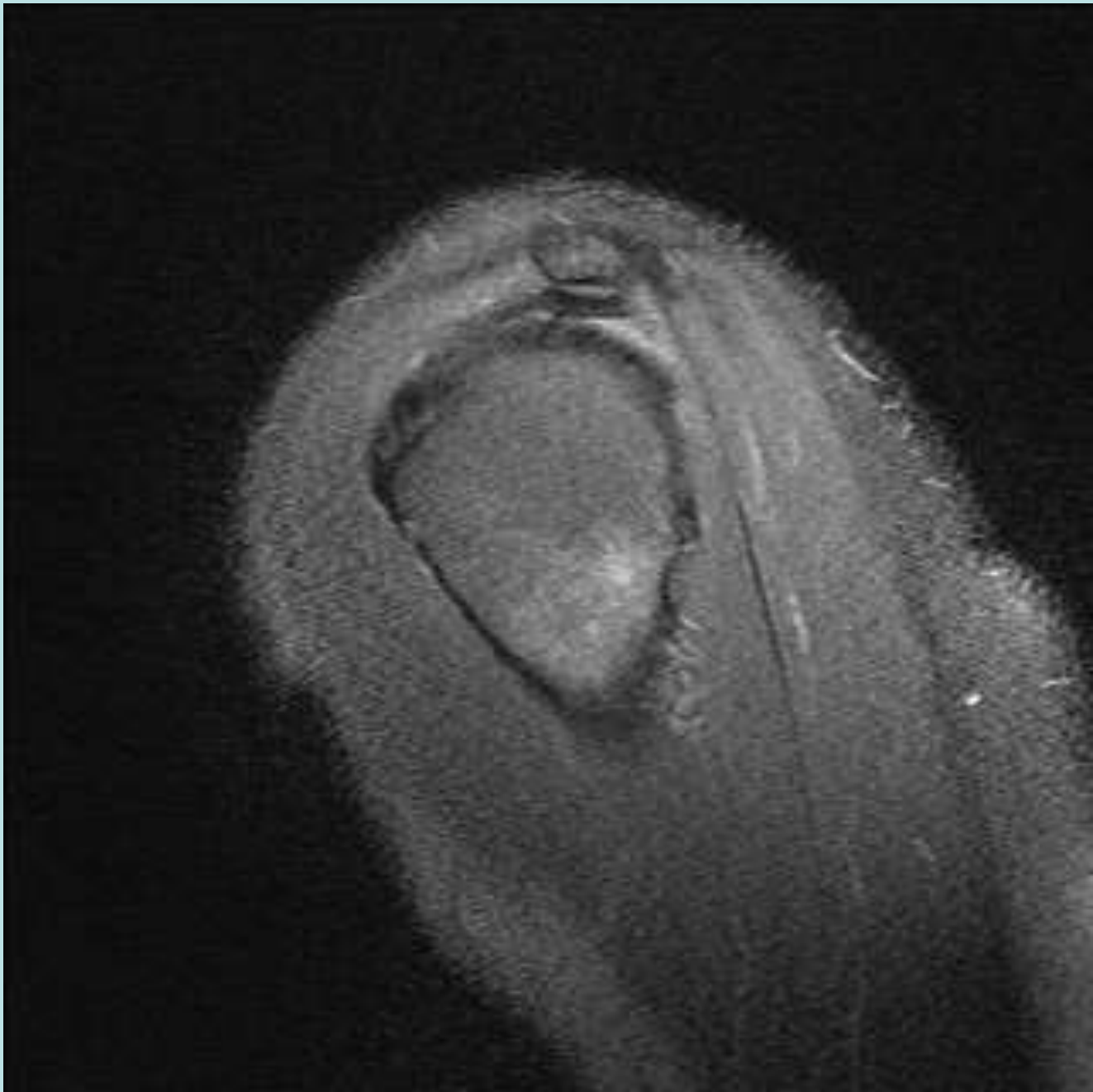


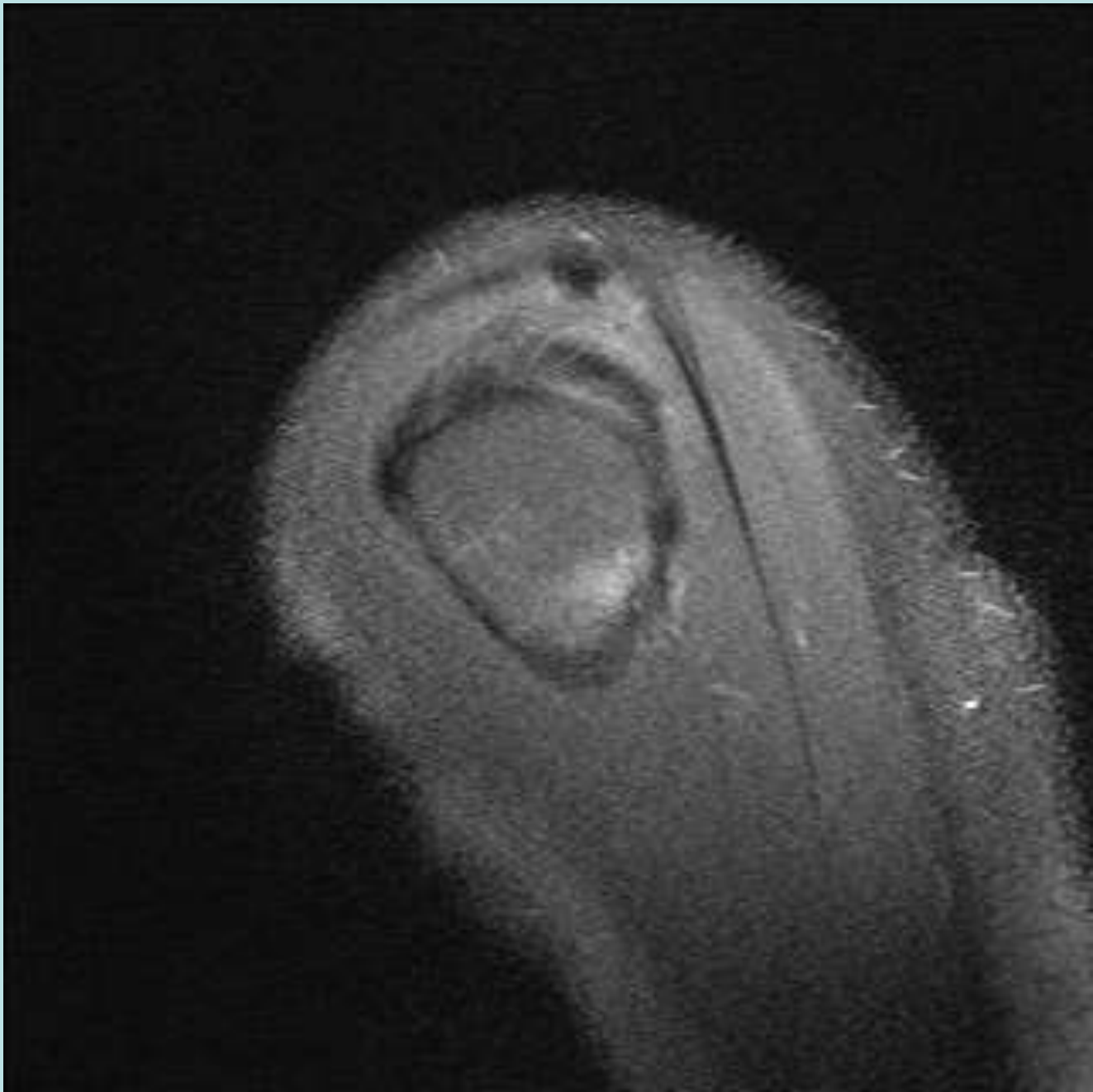


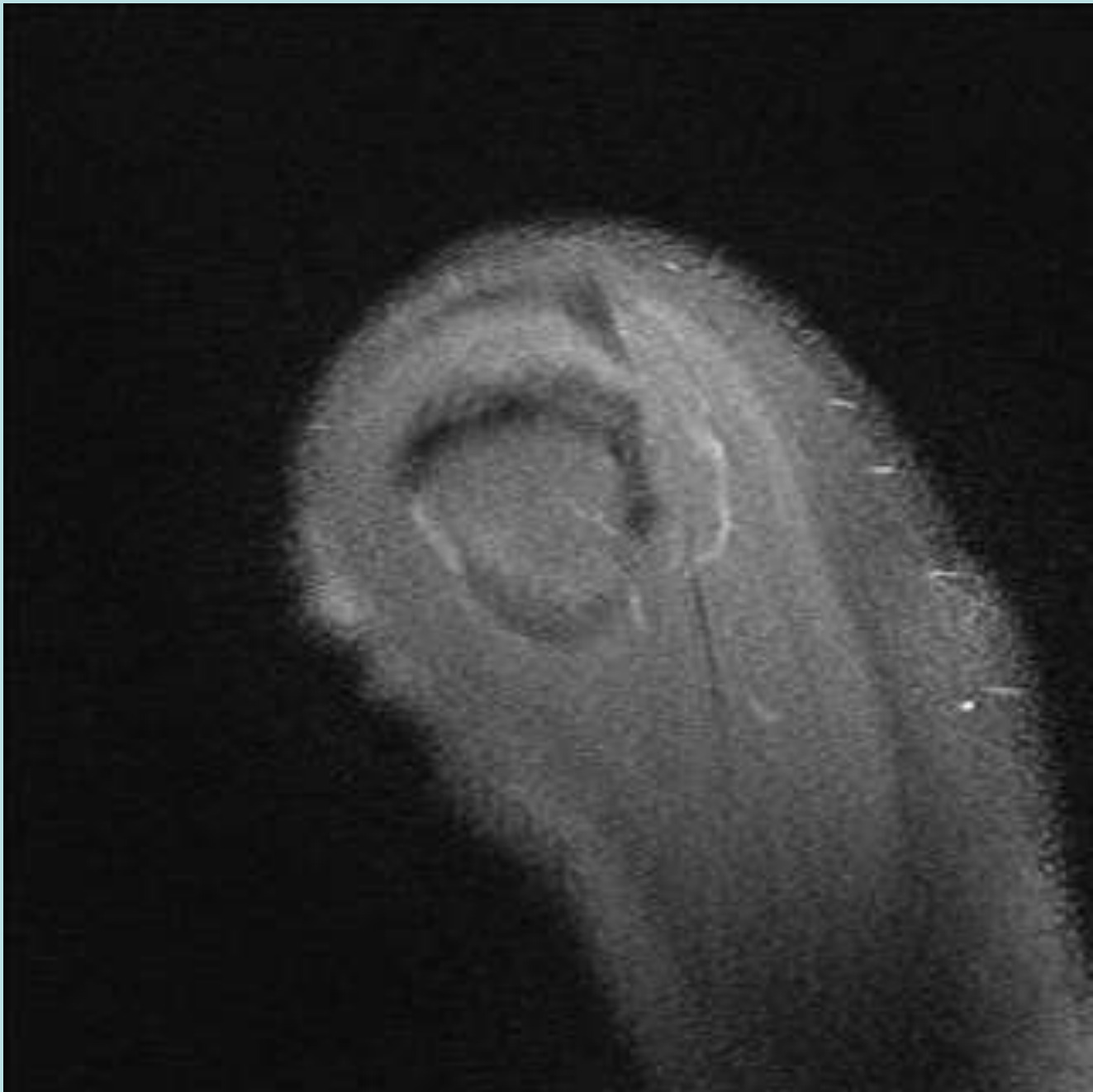




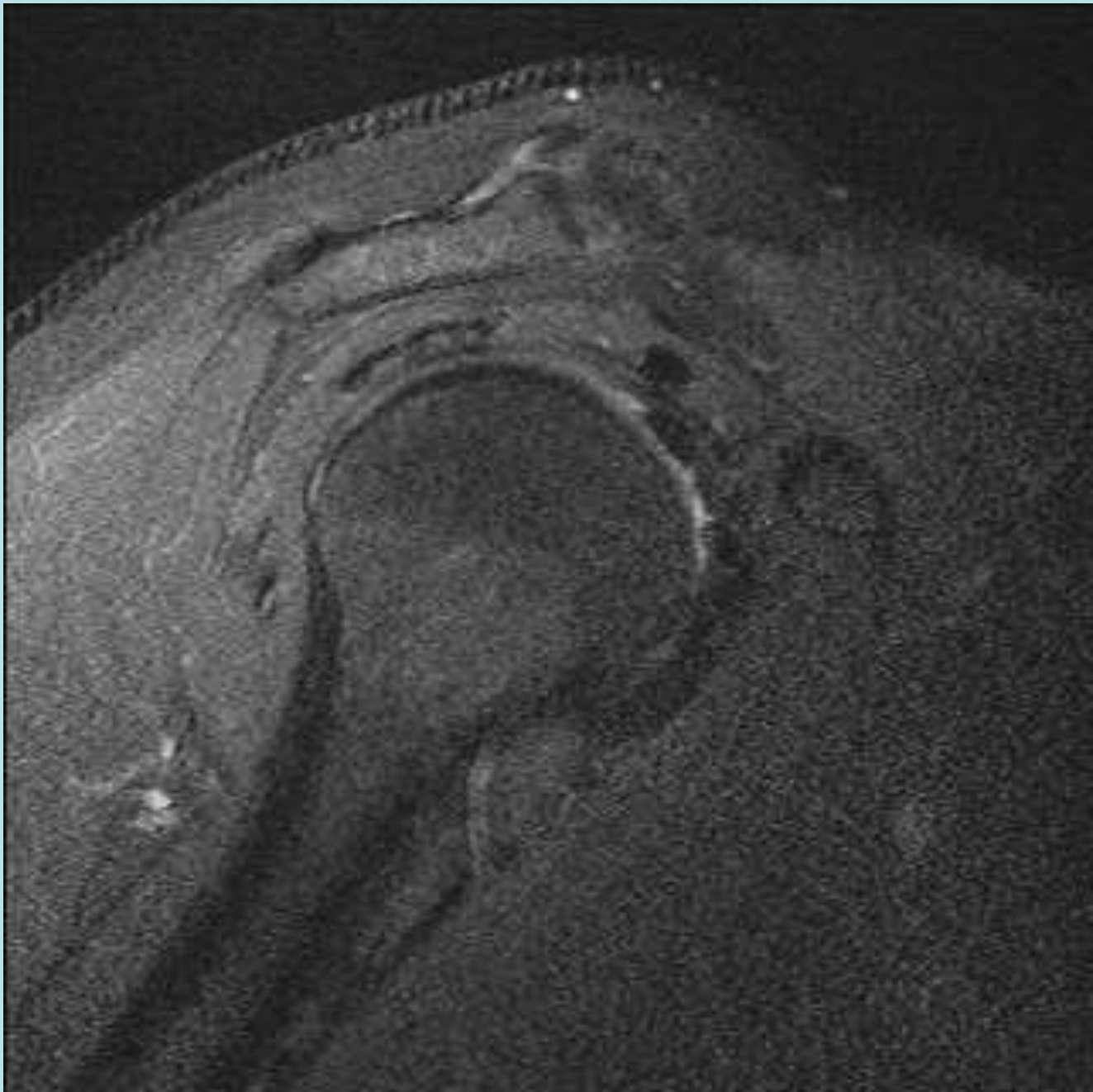


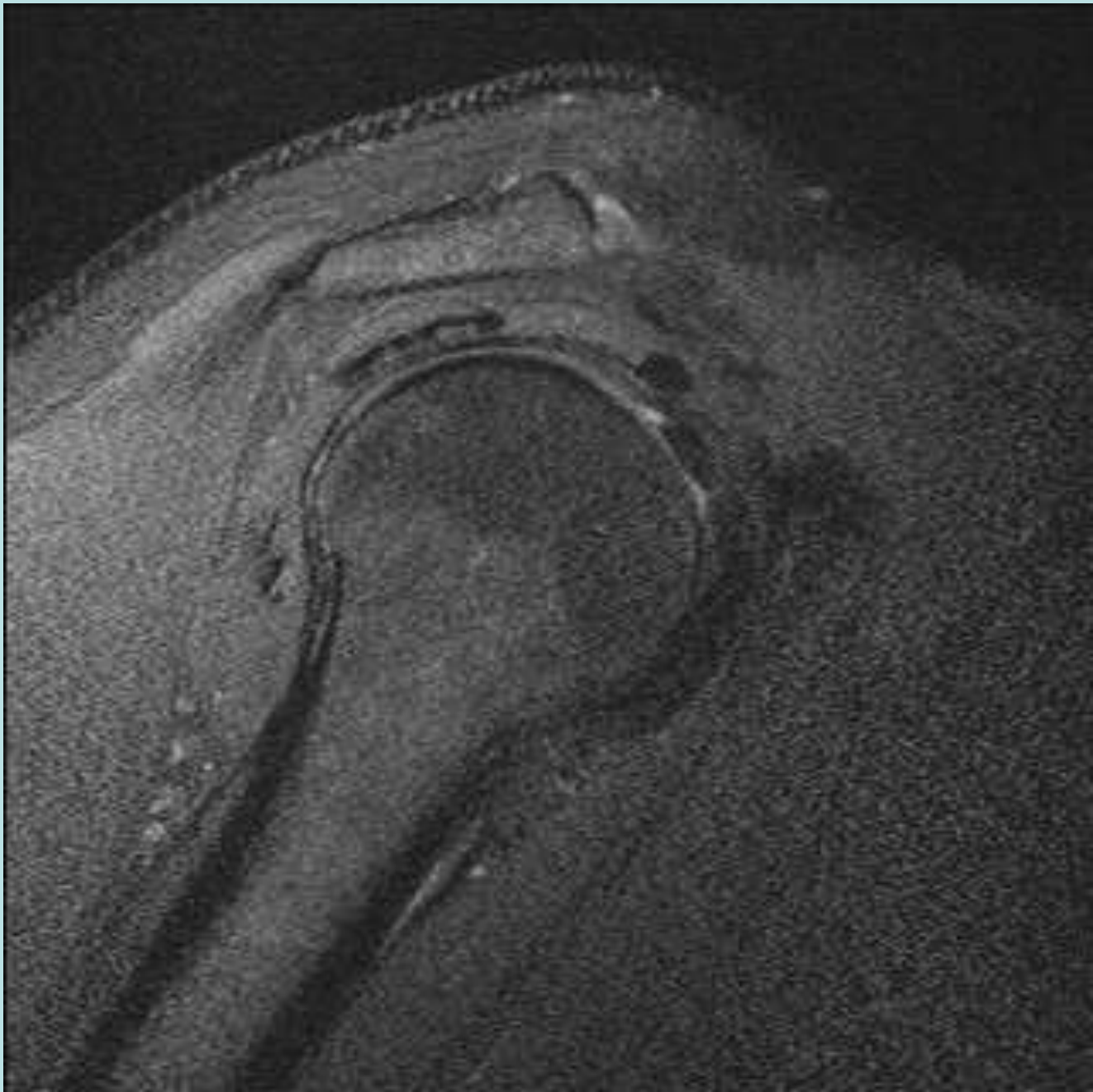


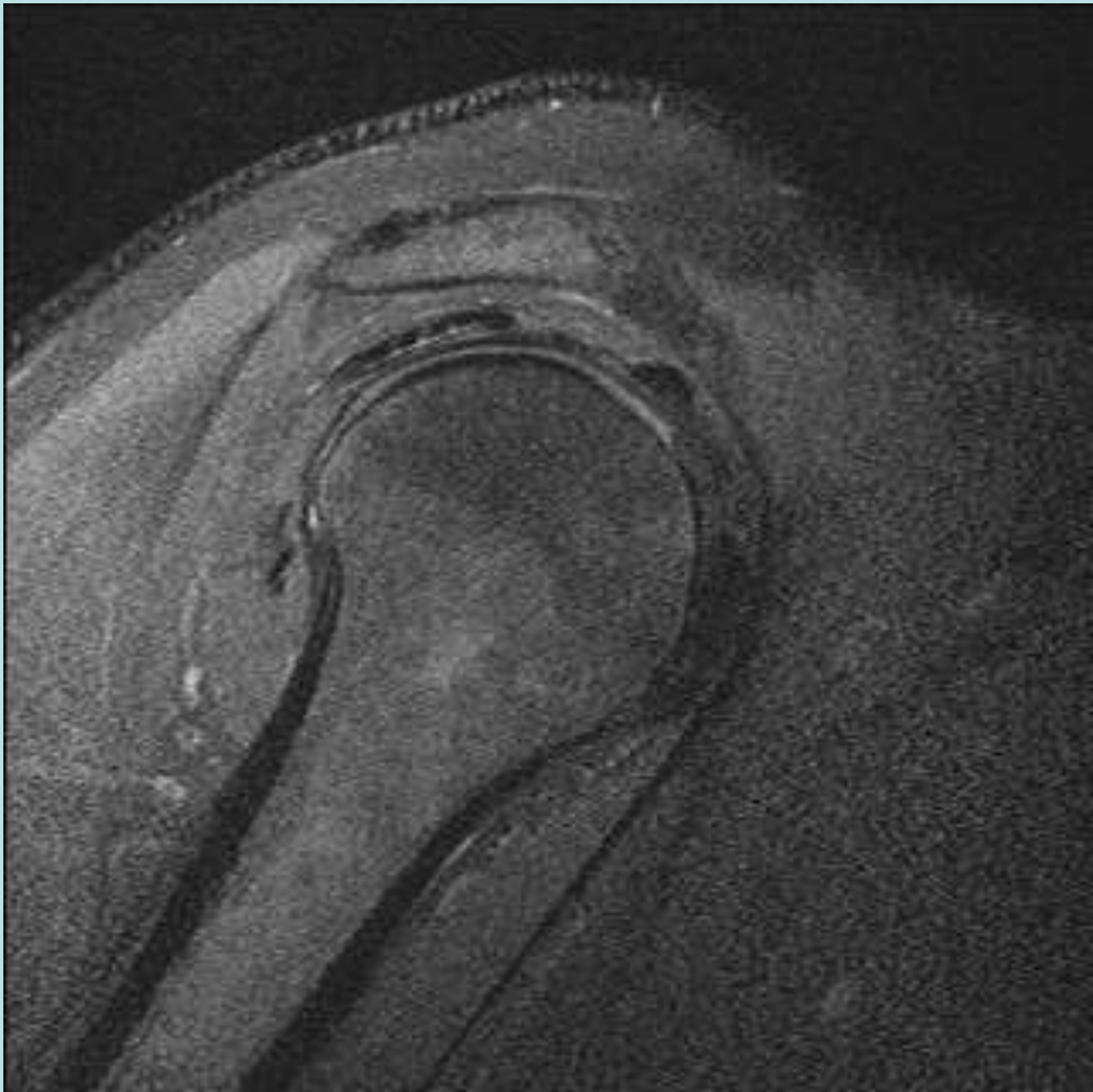


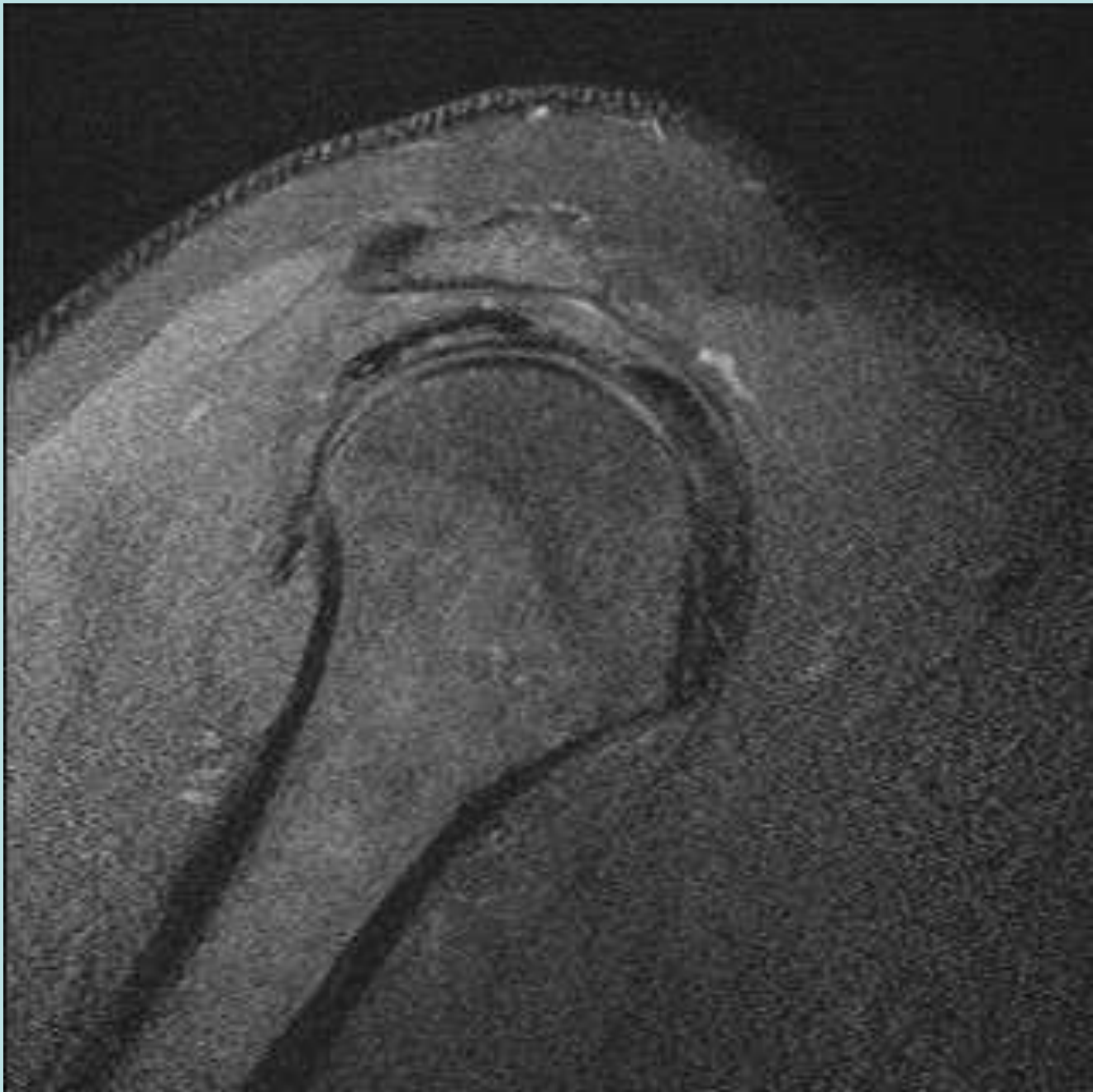


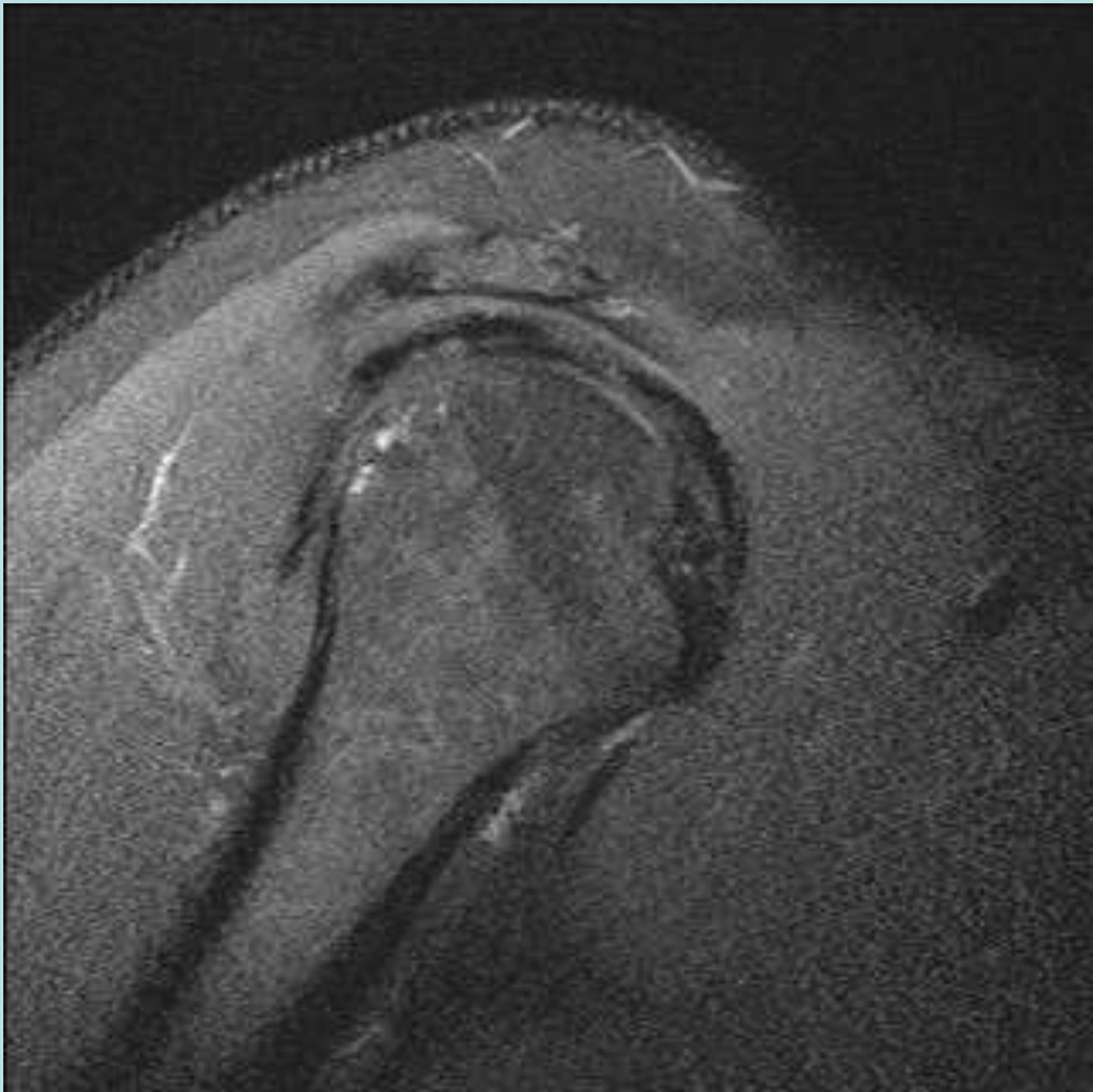
Anomalous Supraspinatus with Prominent RI Slip

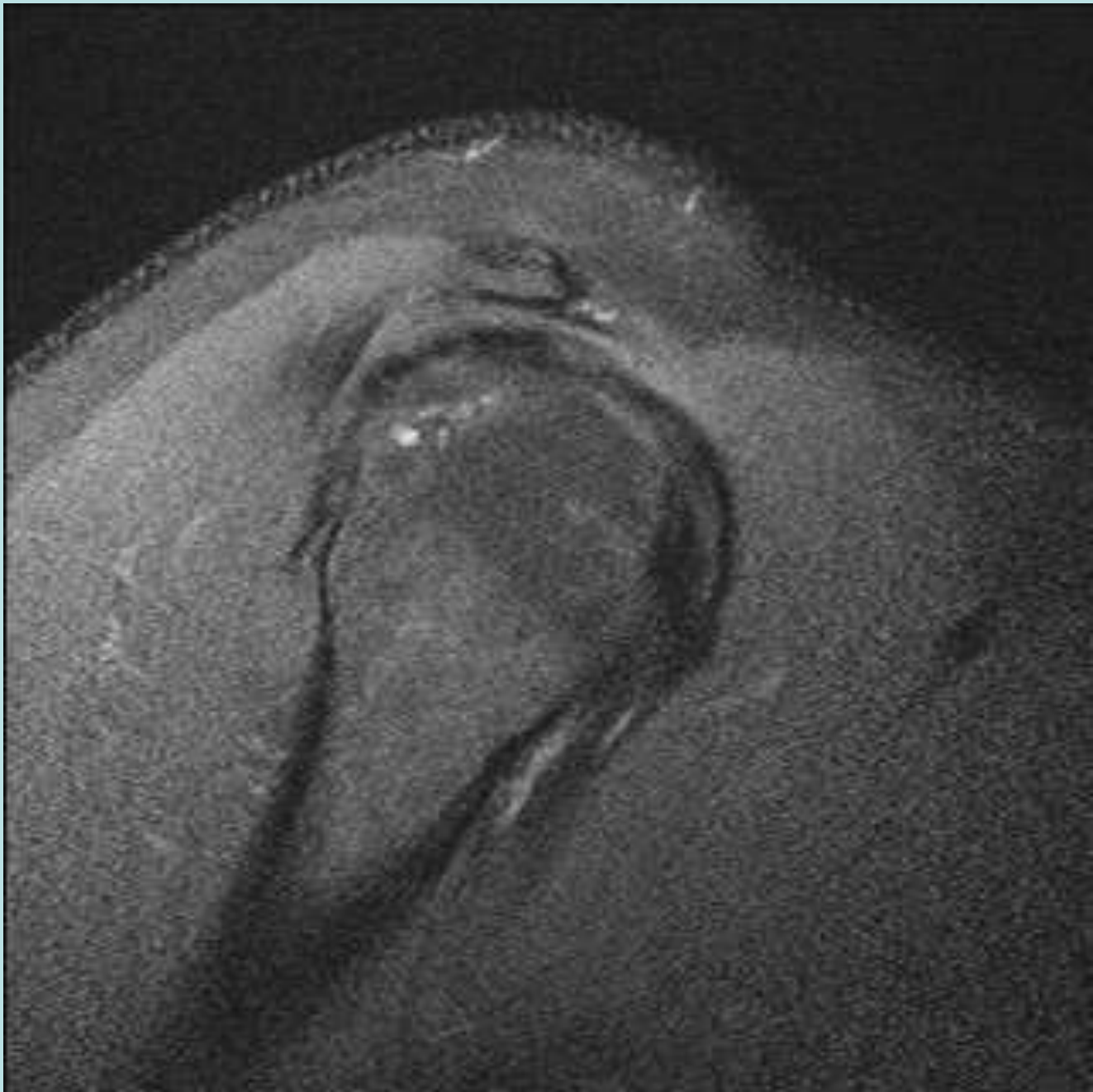


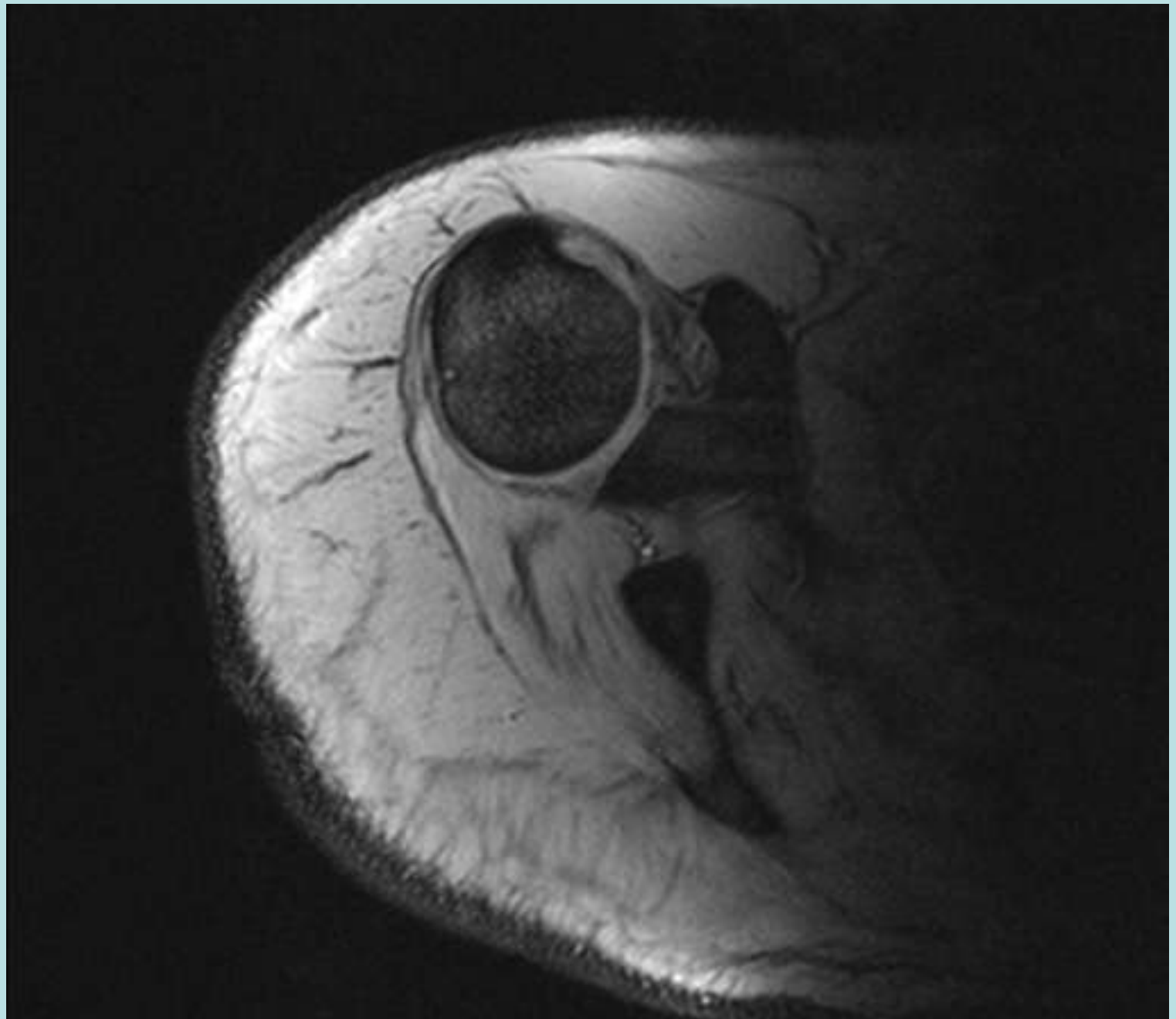


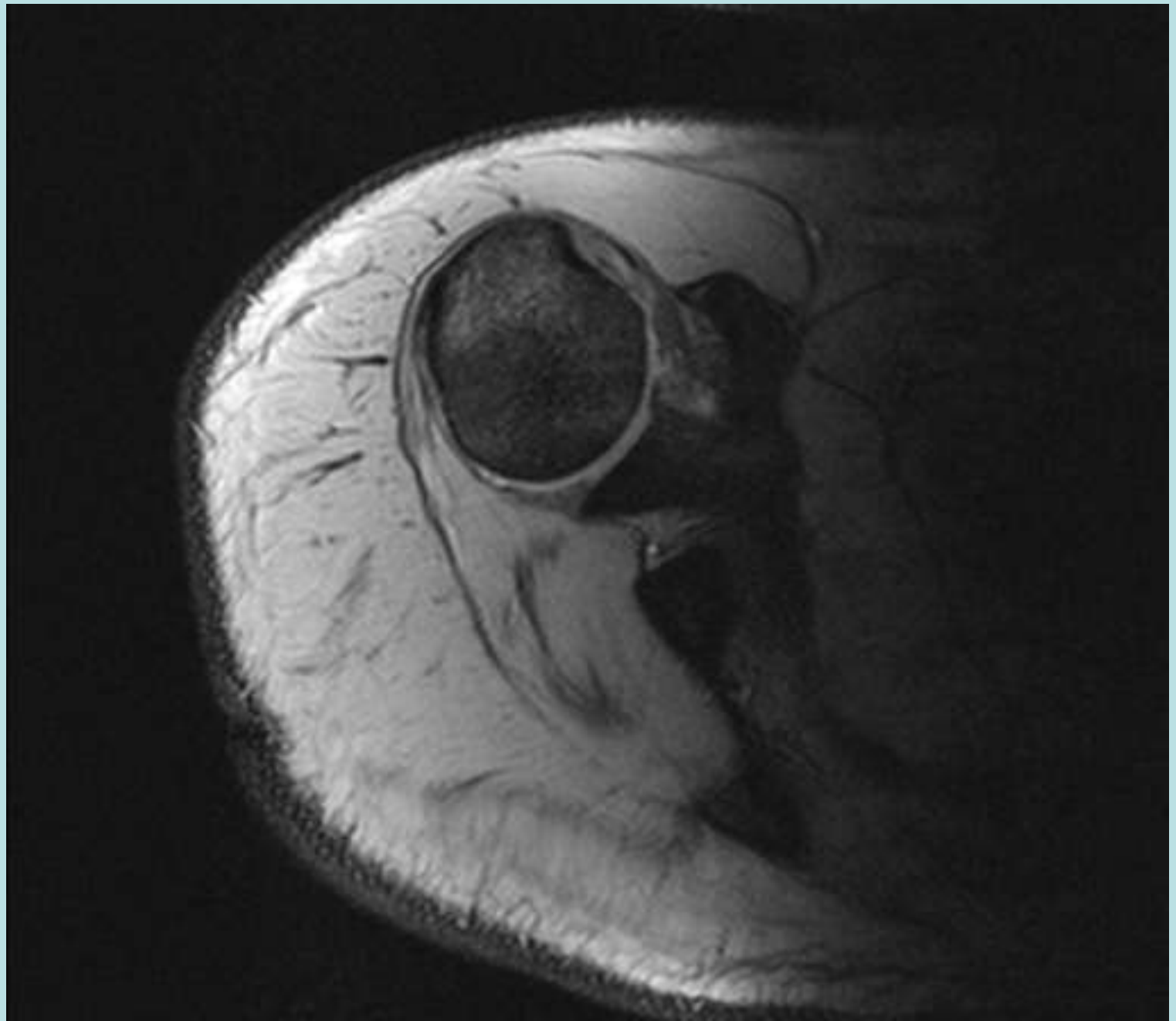


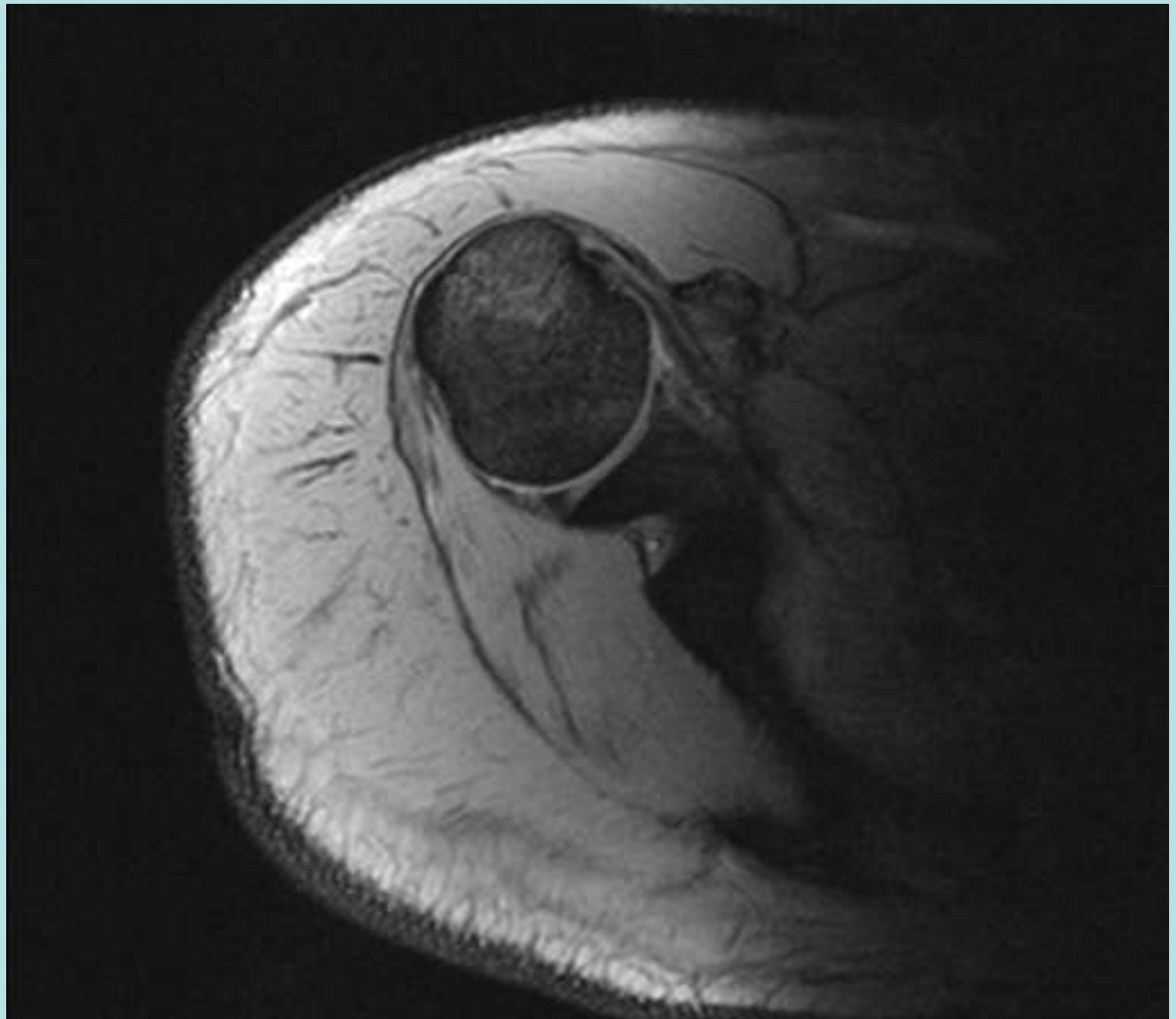


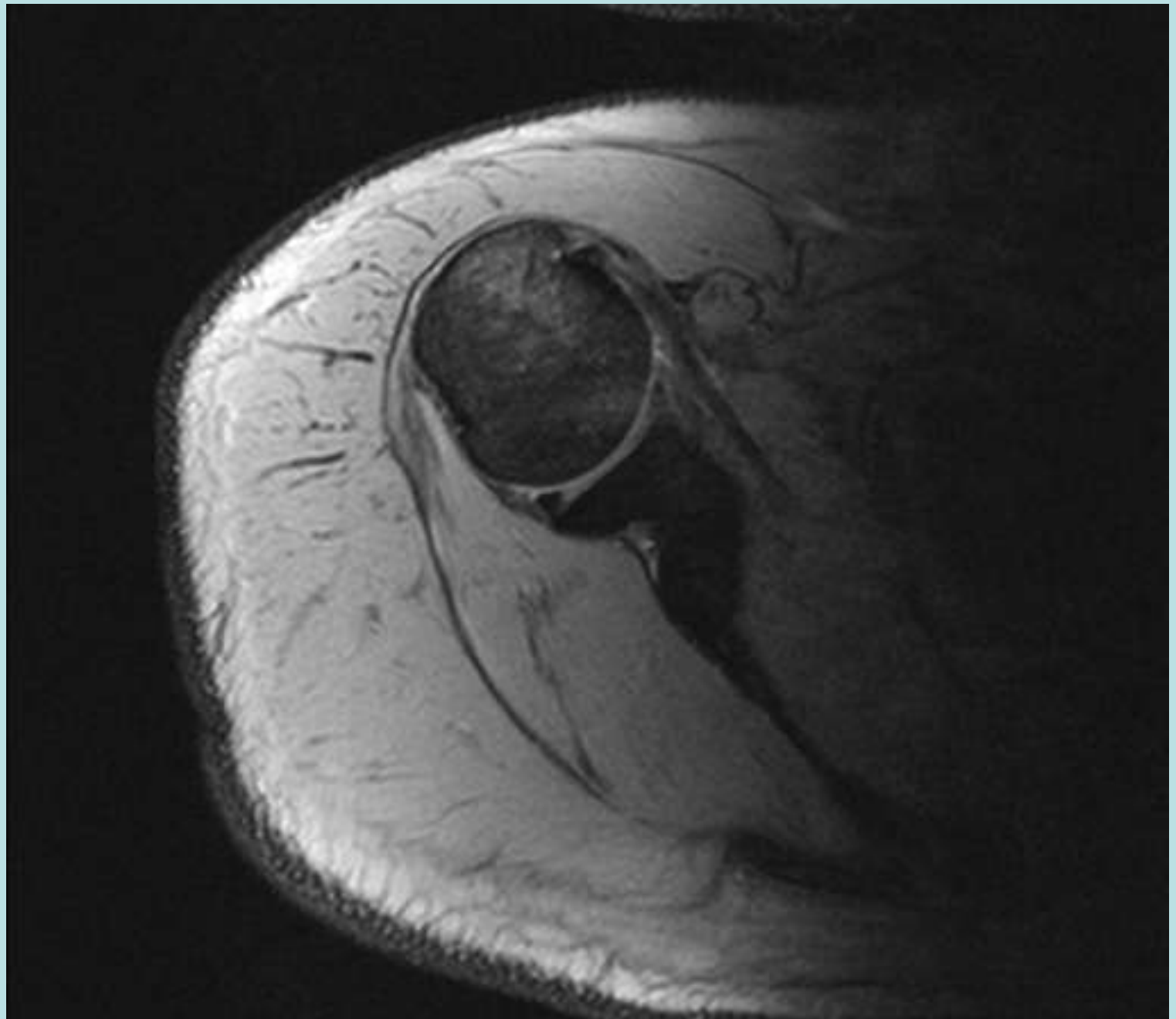


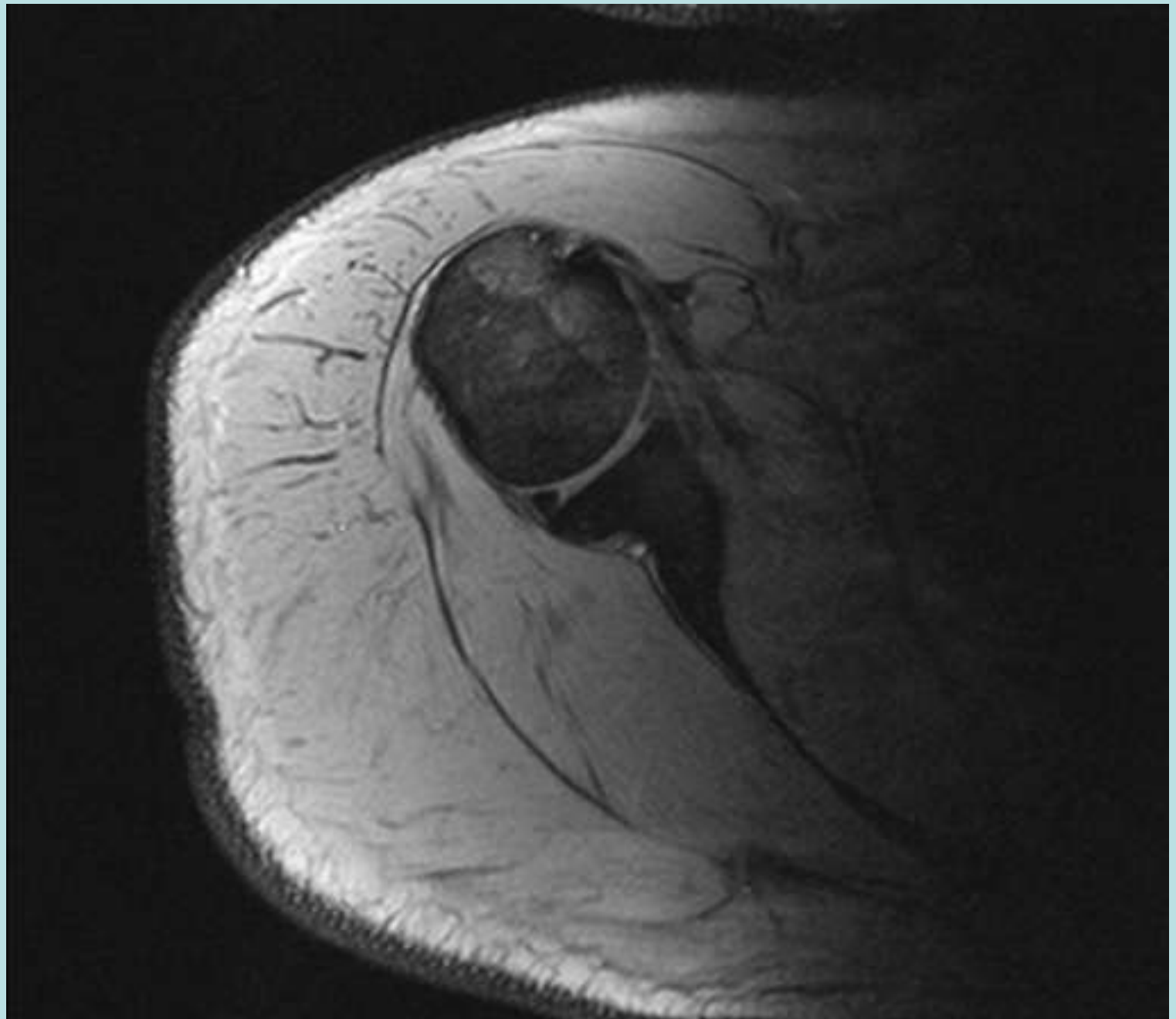


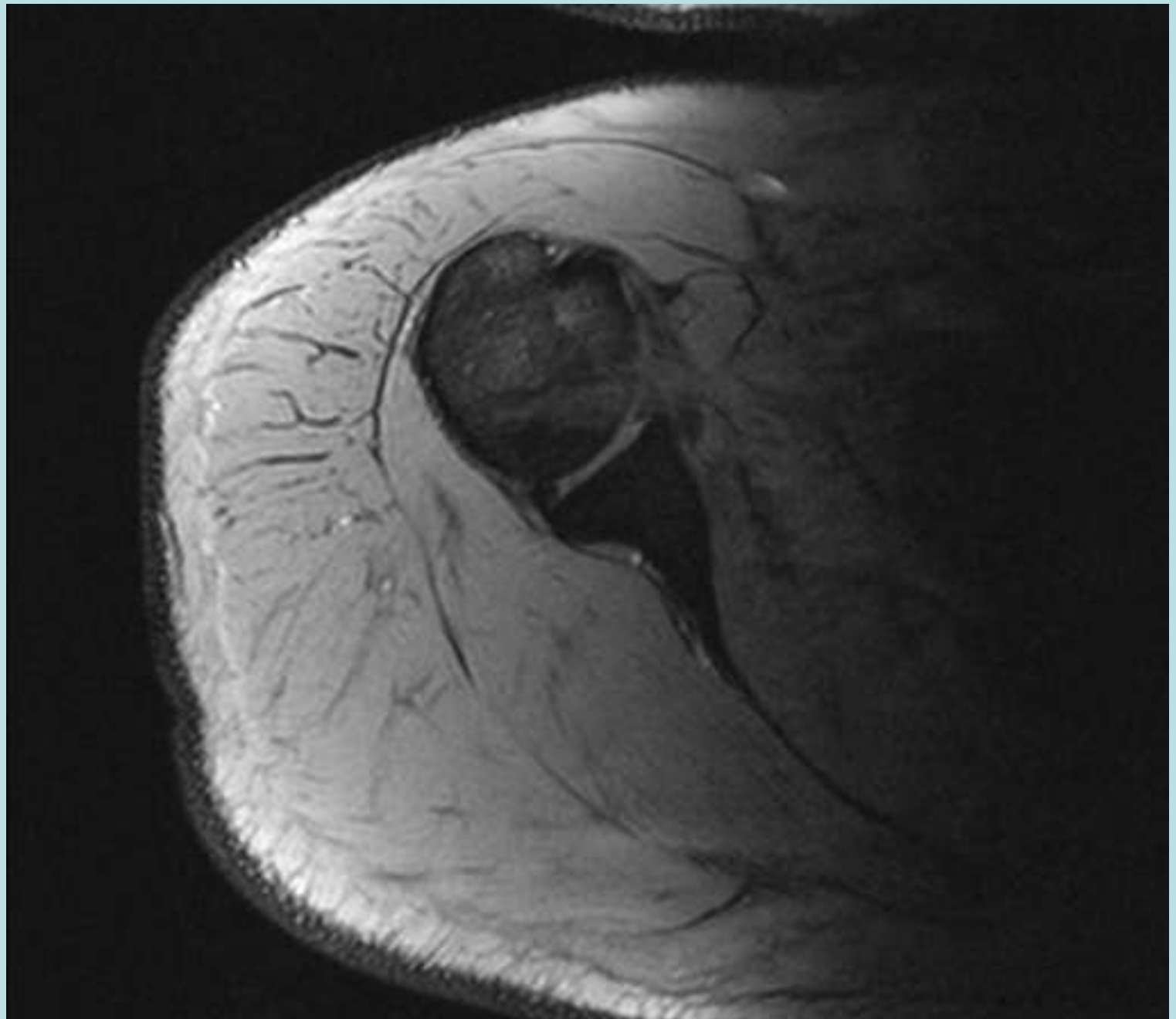








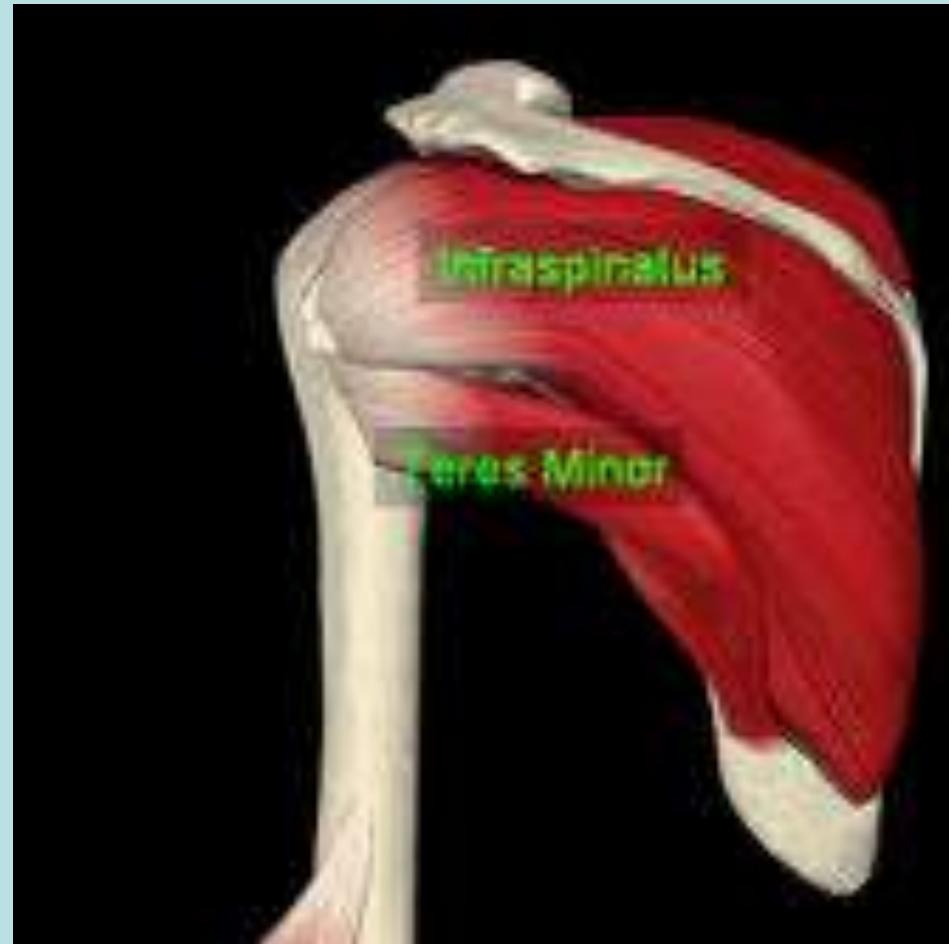


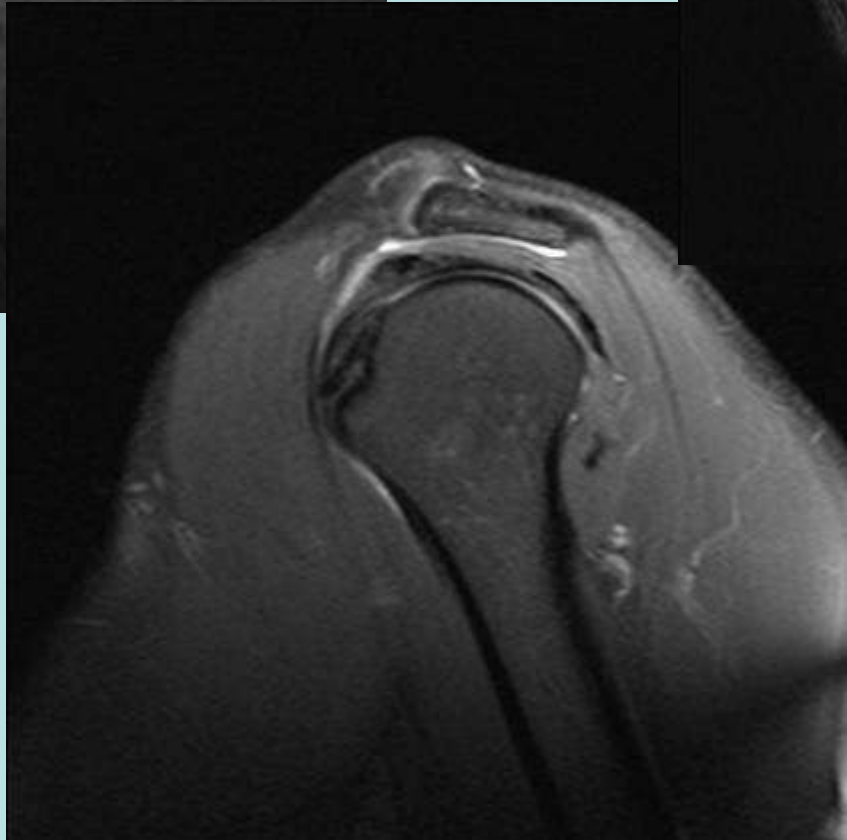
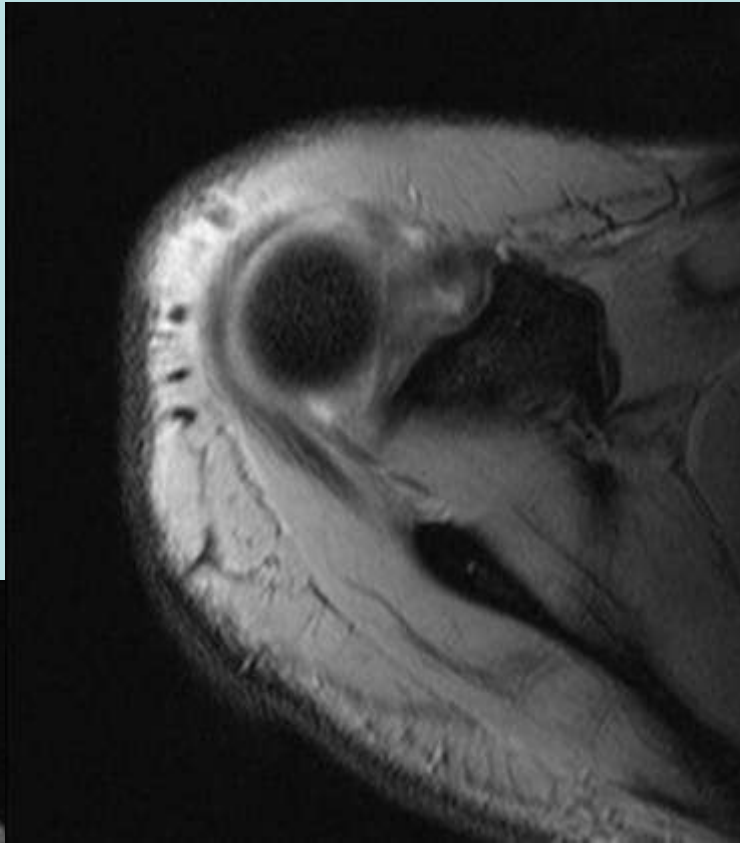

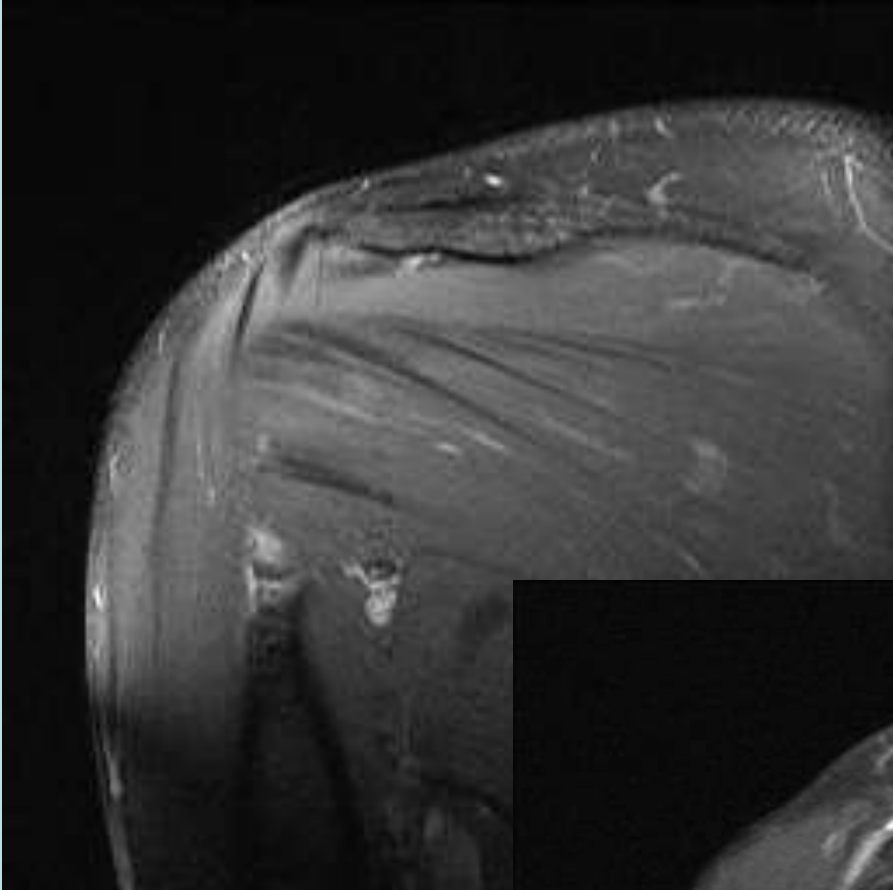



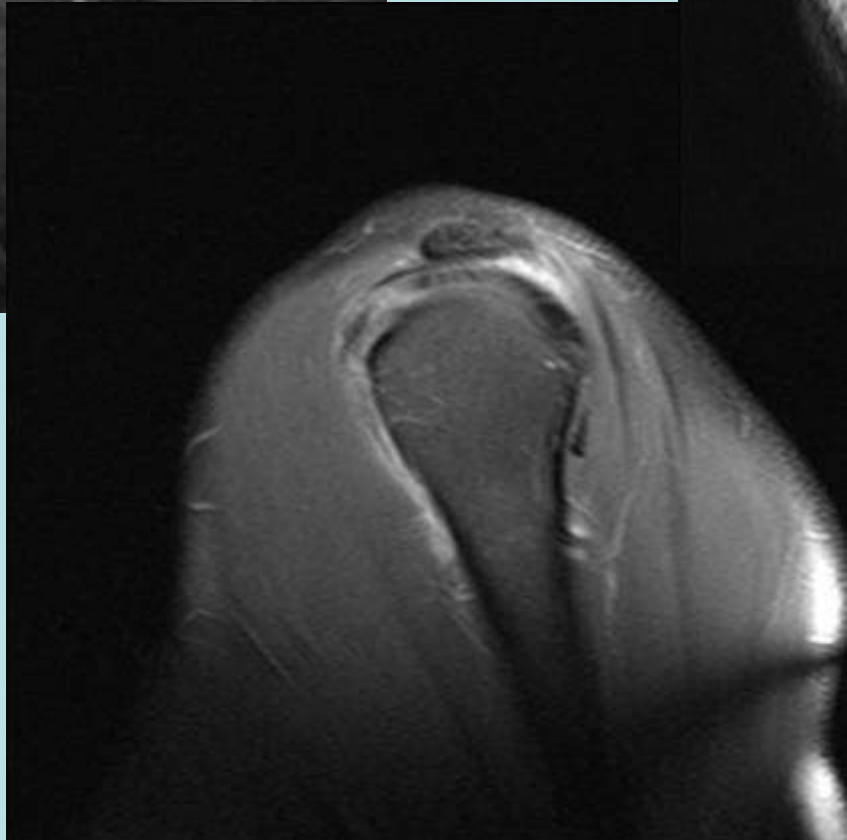
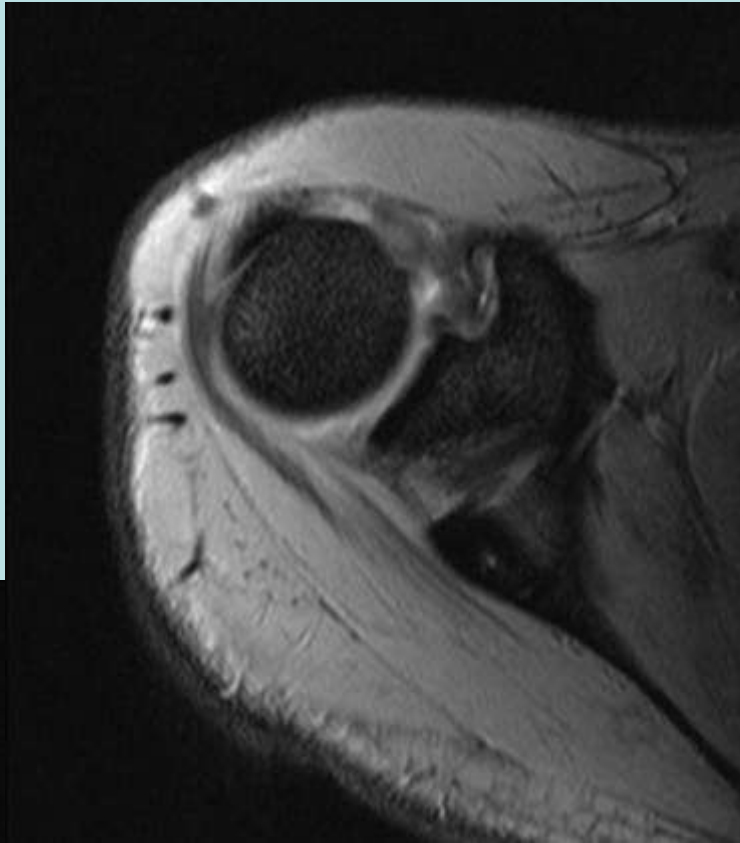

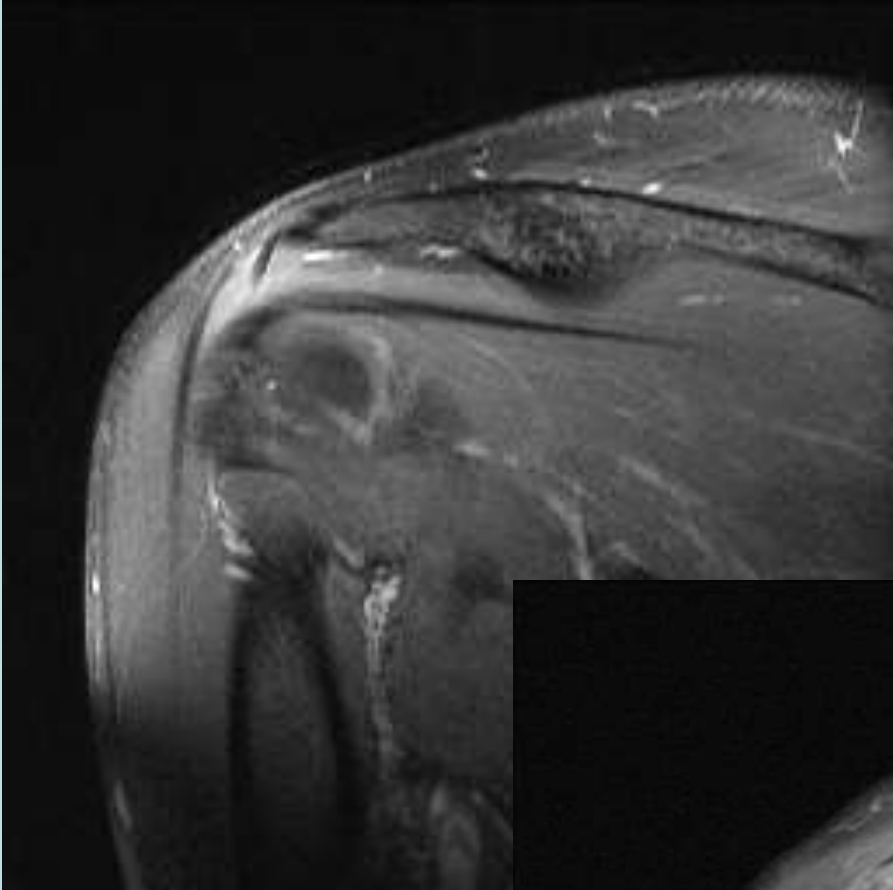


Infraspinatus

- Muscular Origin
Infraspinatus Fossa
- Multicircumpennate
- Innervated
Suprascapular Nerve
- Inserts on Oblique
Facet Greater
Tuberosity



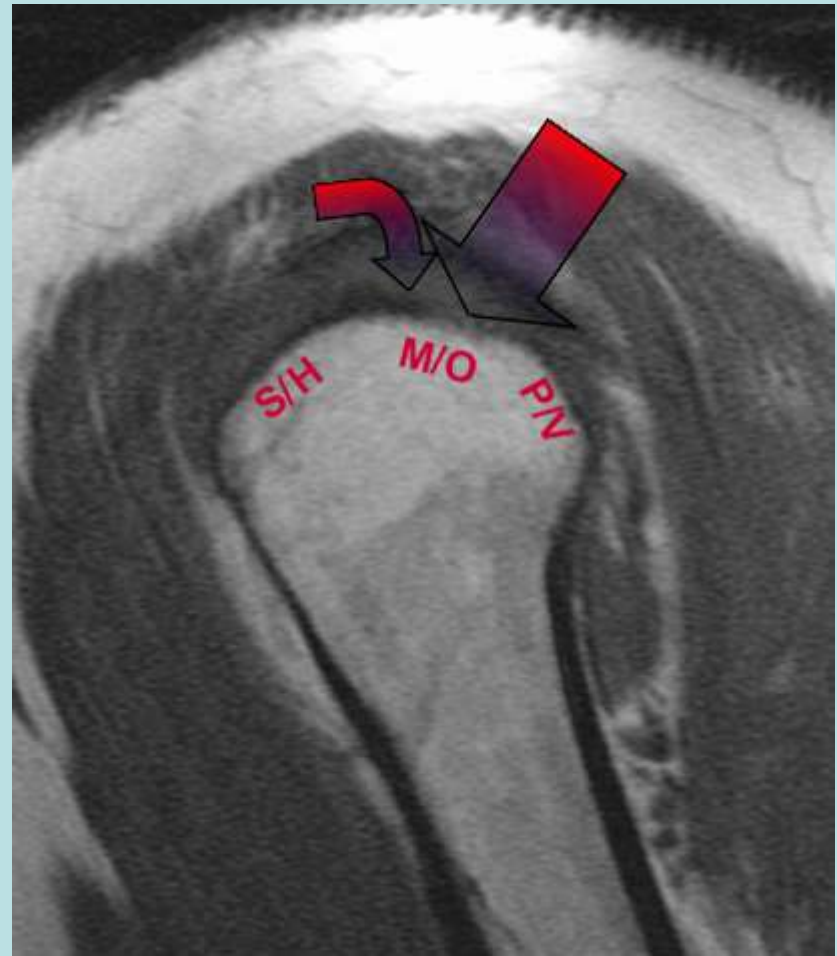
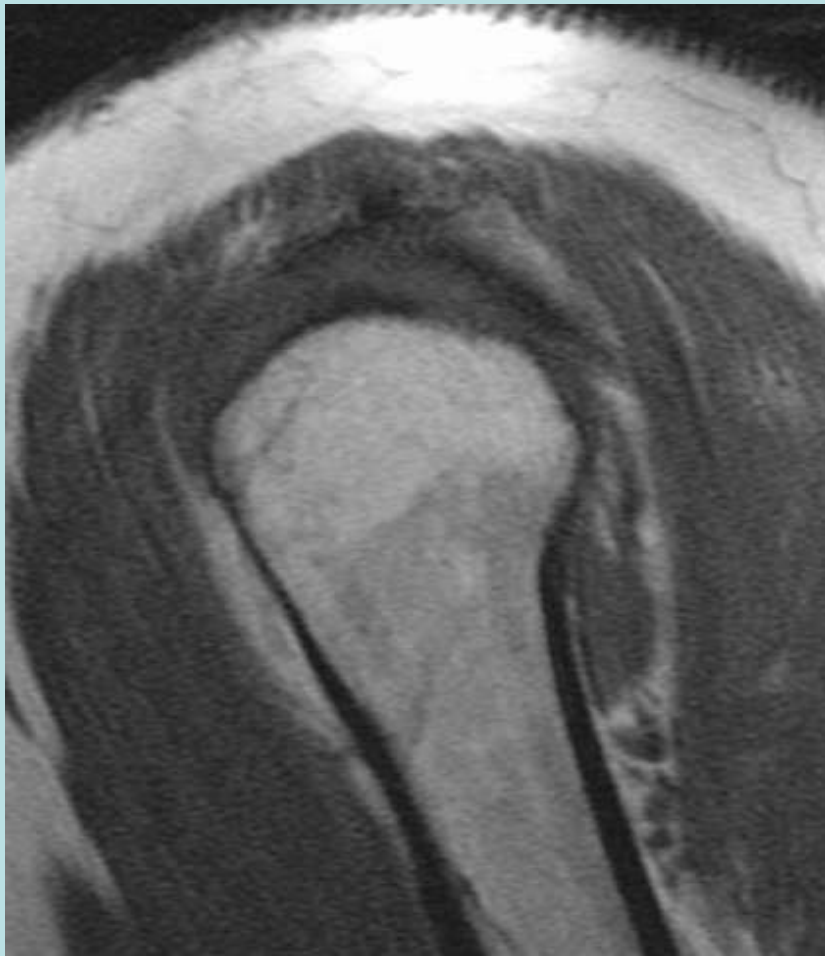



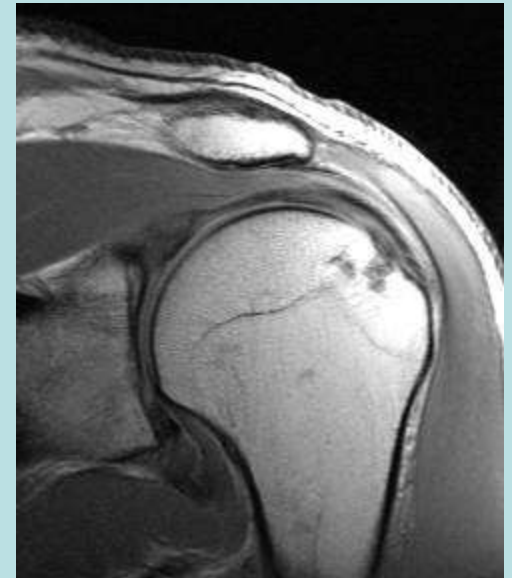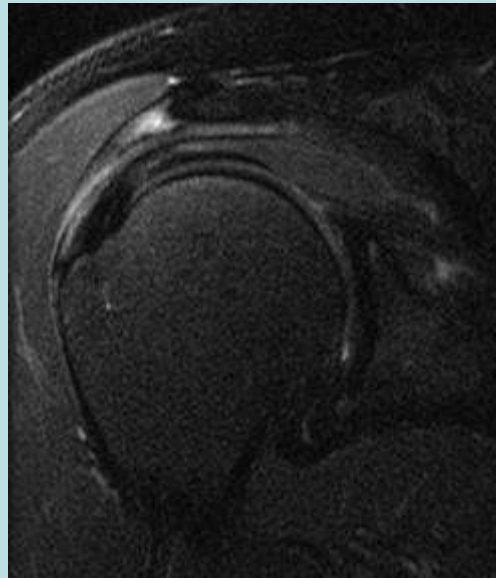
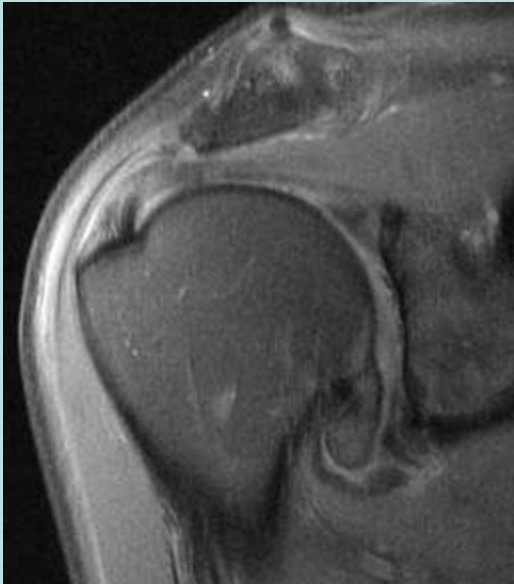
Greater Tuberosity Anatomy

- Superior/Horizontal Facet—Anterior and Mid Fibers of Supraspinatus
- Middle/Oblique Facet---Upper $\frac{1}{2}$ receives overlapping fibers of Supra and Infraspinatus, Lower $\frac{1}{2}$ Infraspinatus
- Posterior/Vertical Facet---Teres Minor

Greater Tuberosity Anatomy



Interdigitation Artifact

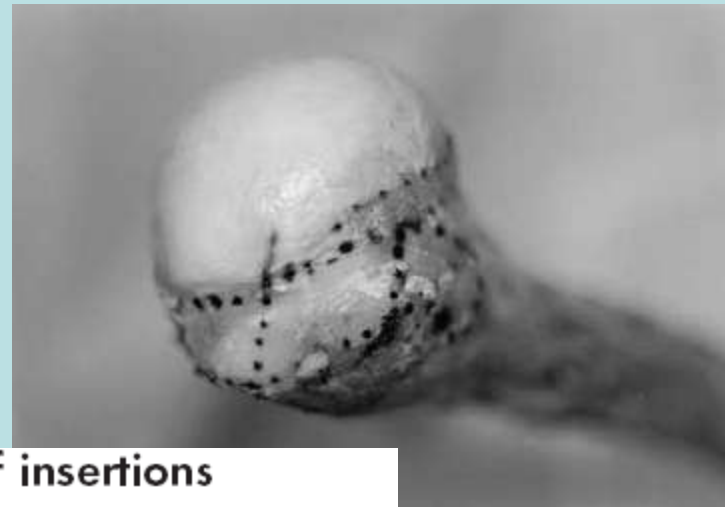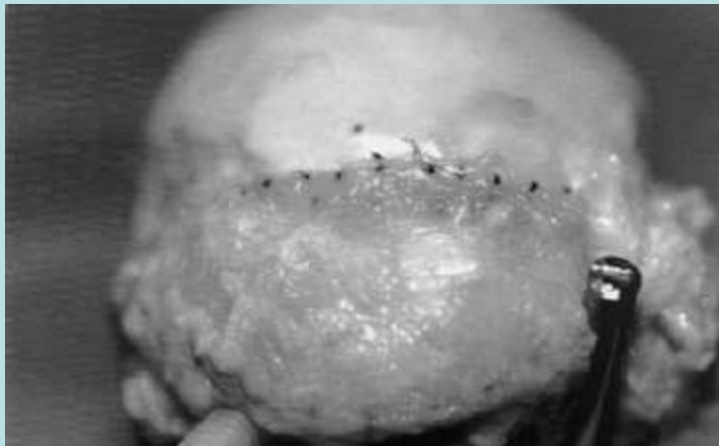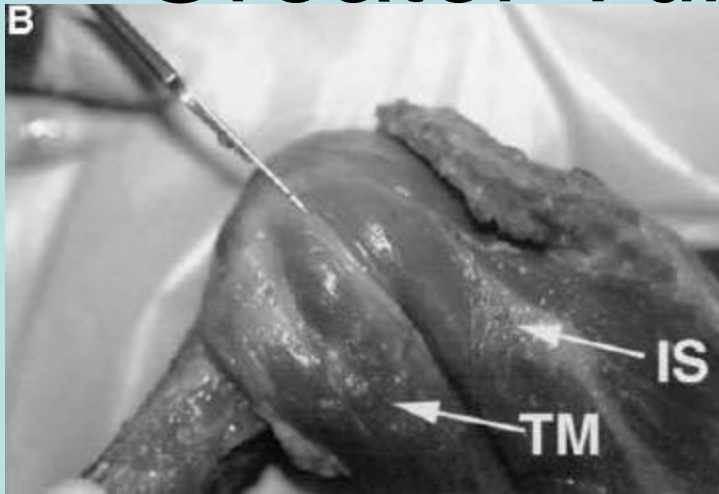


Shoulder MRI refinements: differentiation of rotator cuff tear from artifacts and tendonosis, and reassessment of normal findings.

Wright T; Yoon C; Schmit BP Seminars in US, CT, MRI

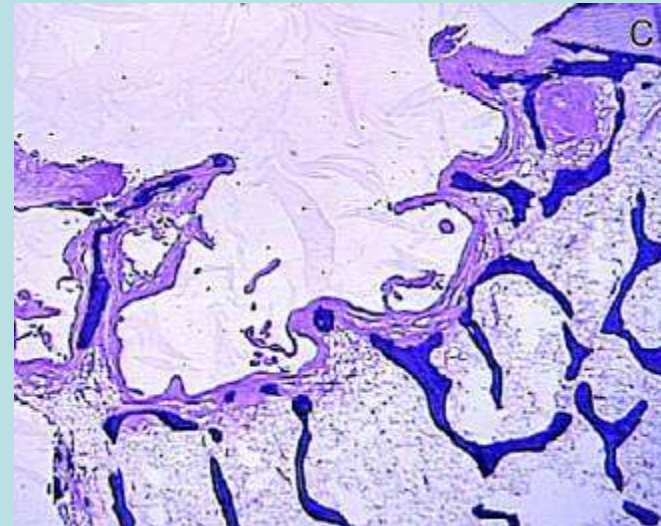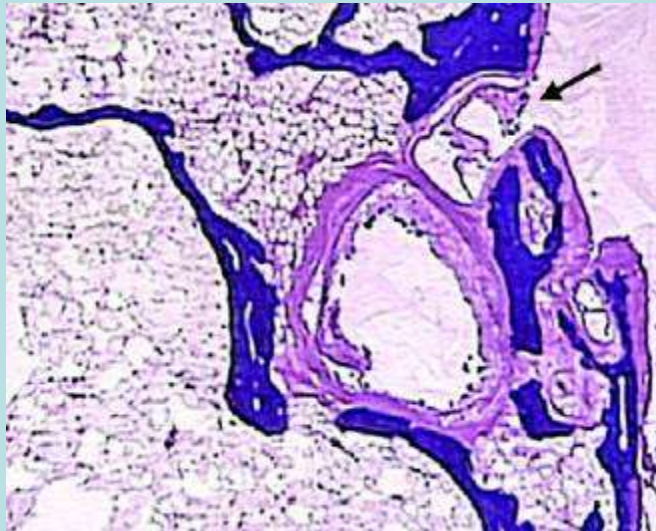
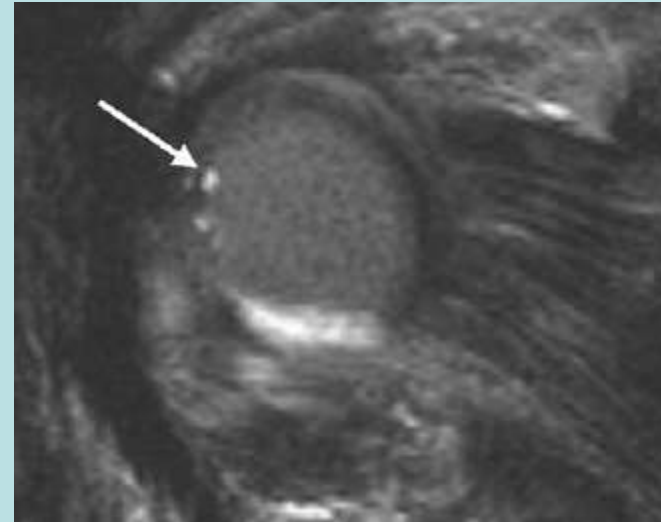
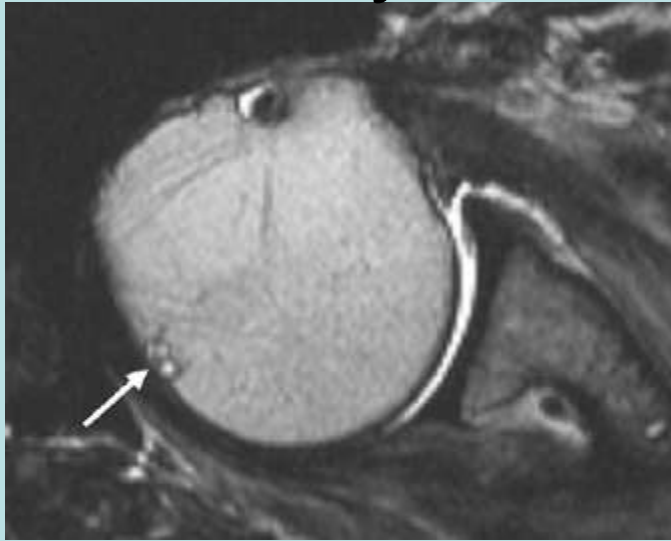
August 1, 2001 - Volume 22, Issue 4

Greater Tuberosity Anatomy



Anatomy and dimensions of rotator cuff insertions

Cystic Changes at Bare Area



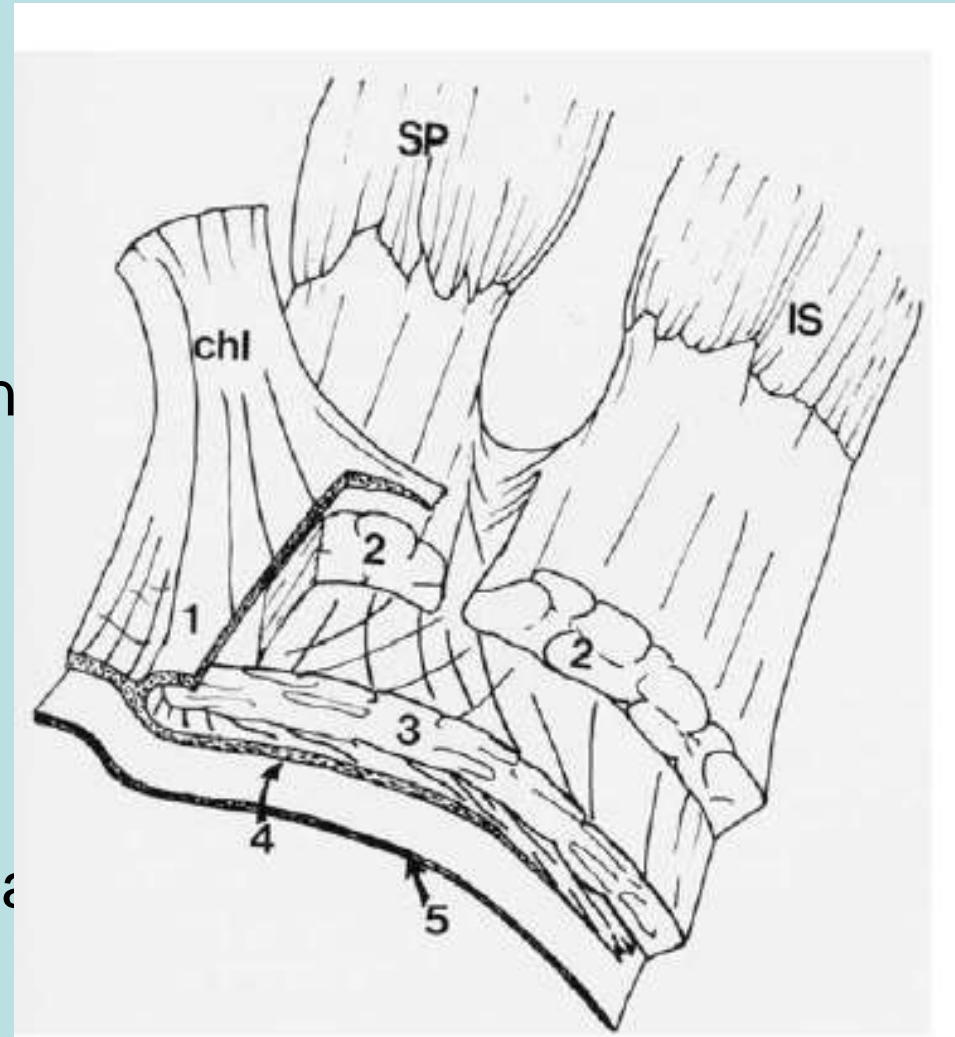
Cystic Lesions in the Posterosuperior Portion of the Humeral Head on MR Arthrography:
Correlations with Gross and Histologic Findings in Cadavers
Wook Jin¹, Kyung Nam Ryu², Yong Koo Park³, Weon Kyu Lee⁴, Sung Hye Ko² and Dal Mo Yang¹

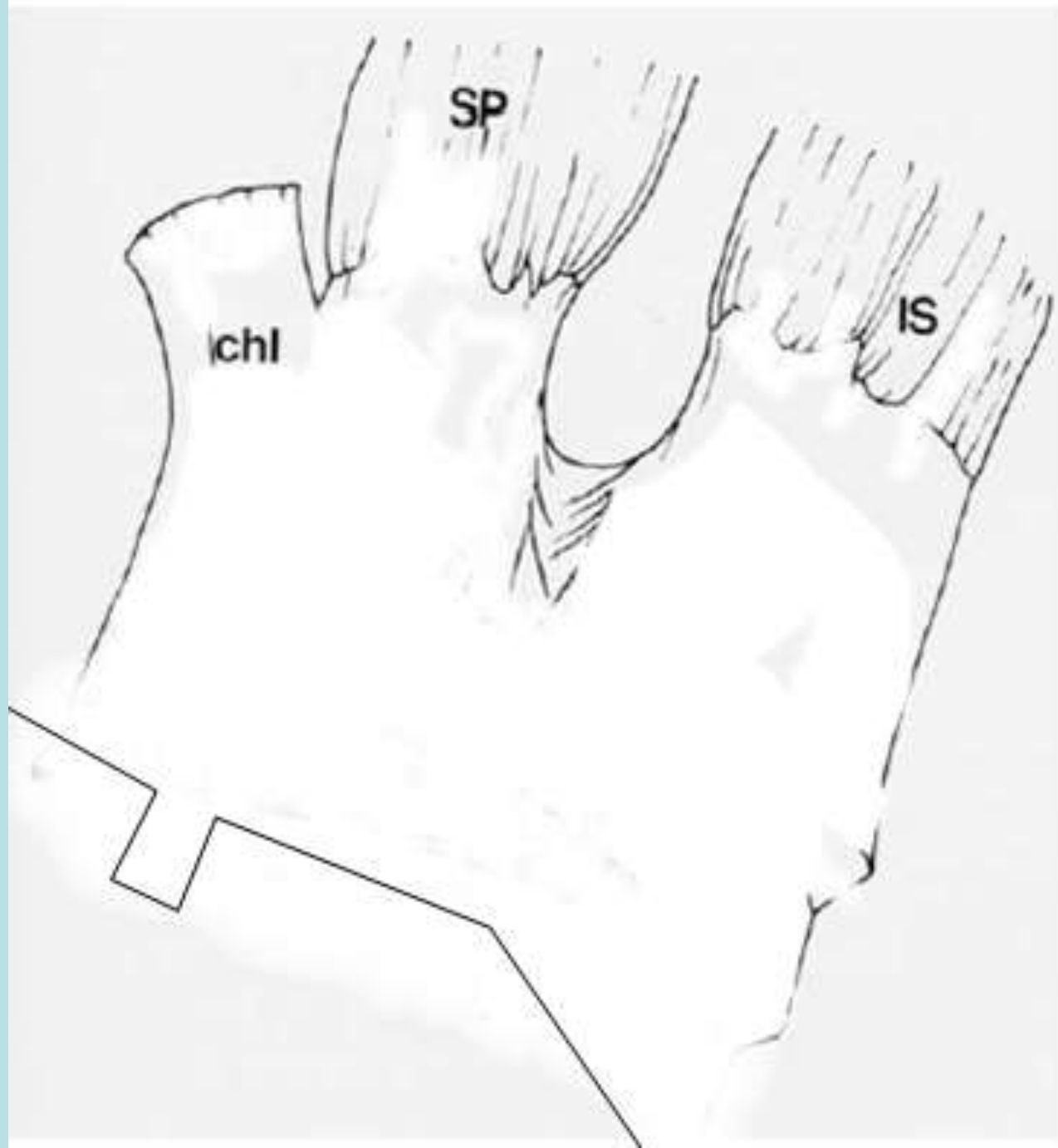
AJR 2005; 184:1211-1215

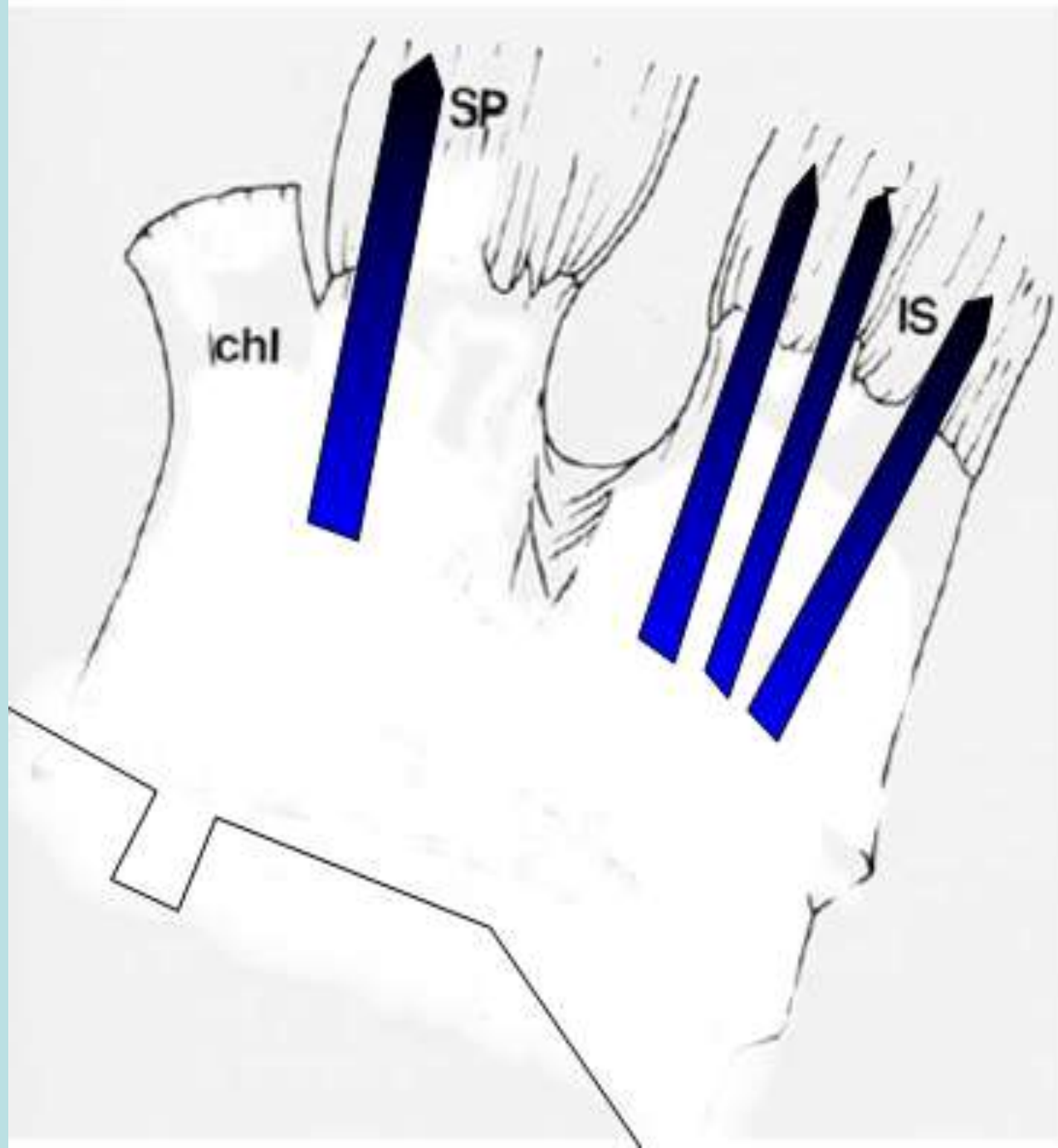


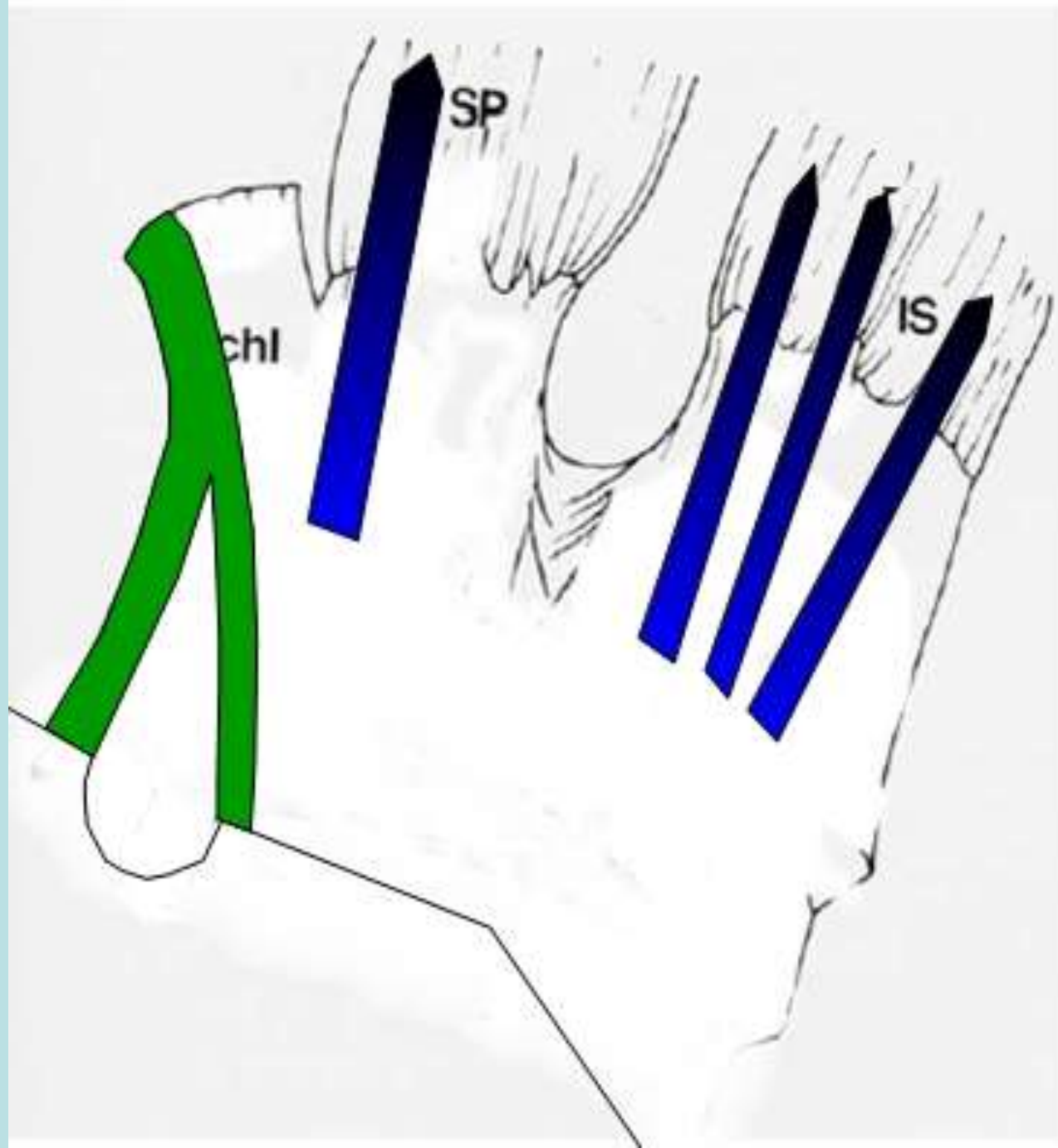
4-5 Layers of the Rotator Cuff

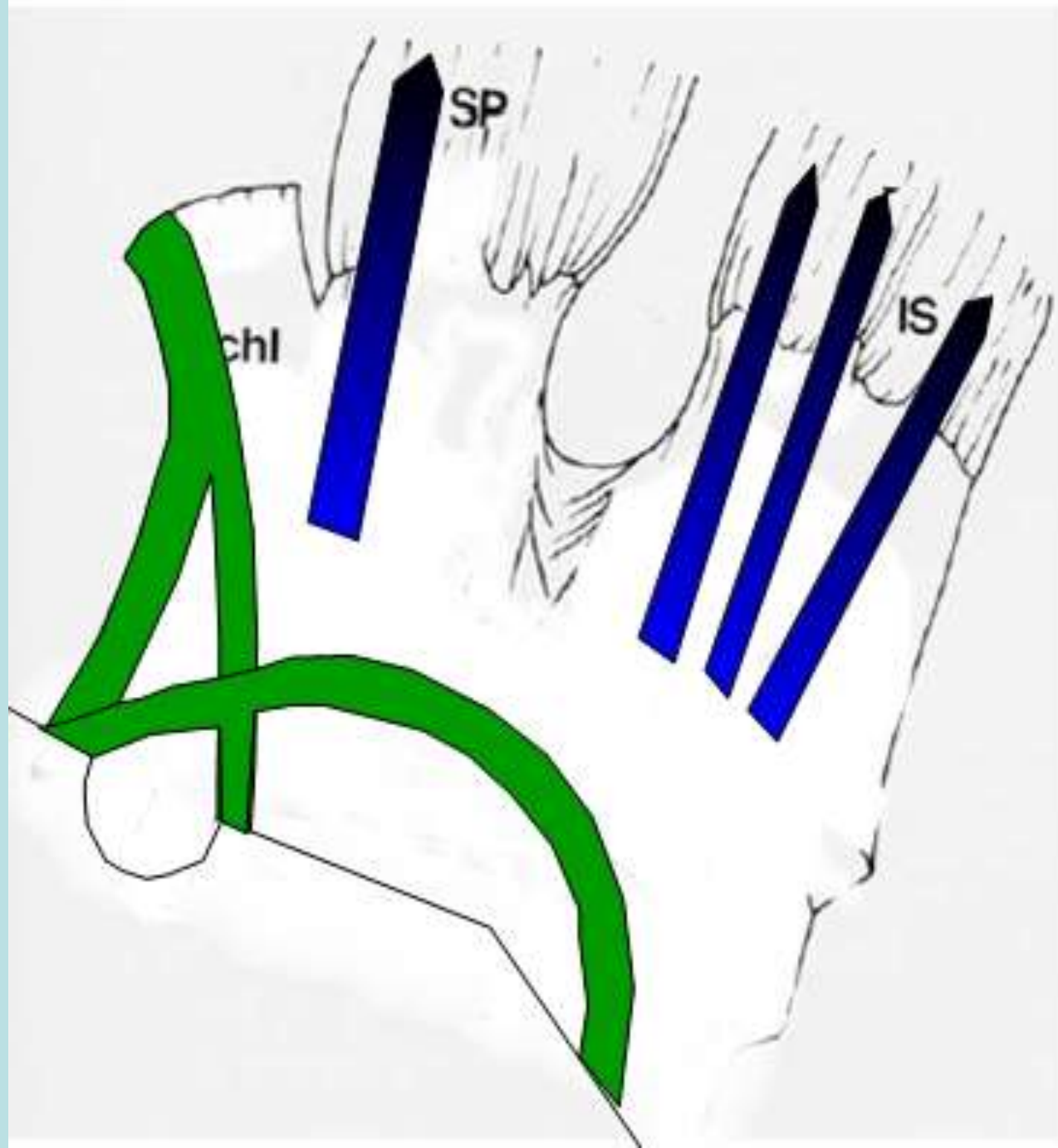
- Clark-5 layers
- CHL&Rotator Cable 1,4
- Capsule 5
- 3 and 2 differ in orientation
- Fallon's-4 layers
 - Capsule
 - CHL
 - Tendons
 - Attachment Fibrocartilage

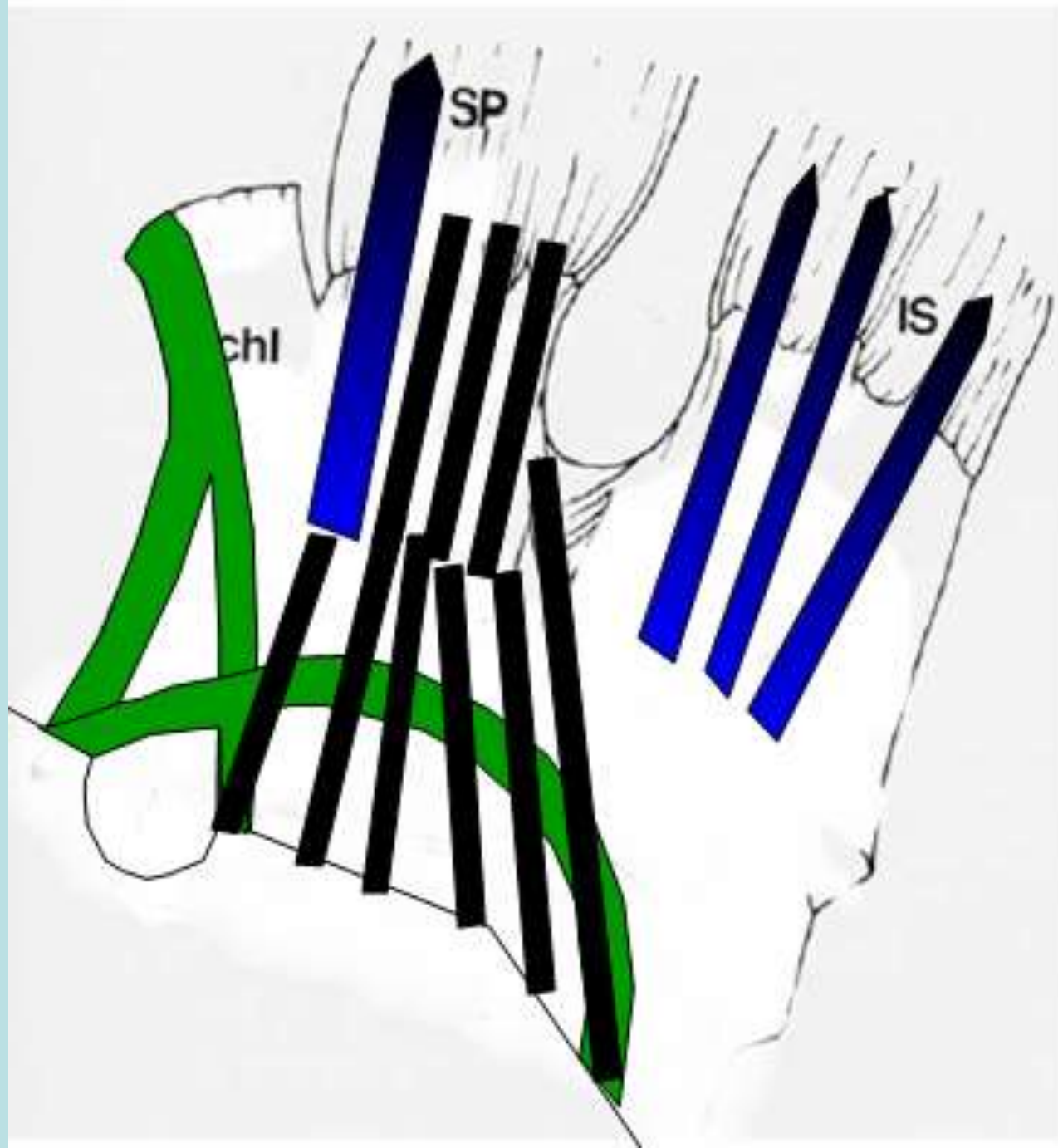


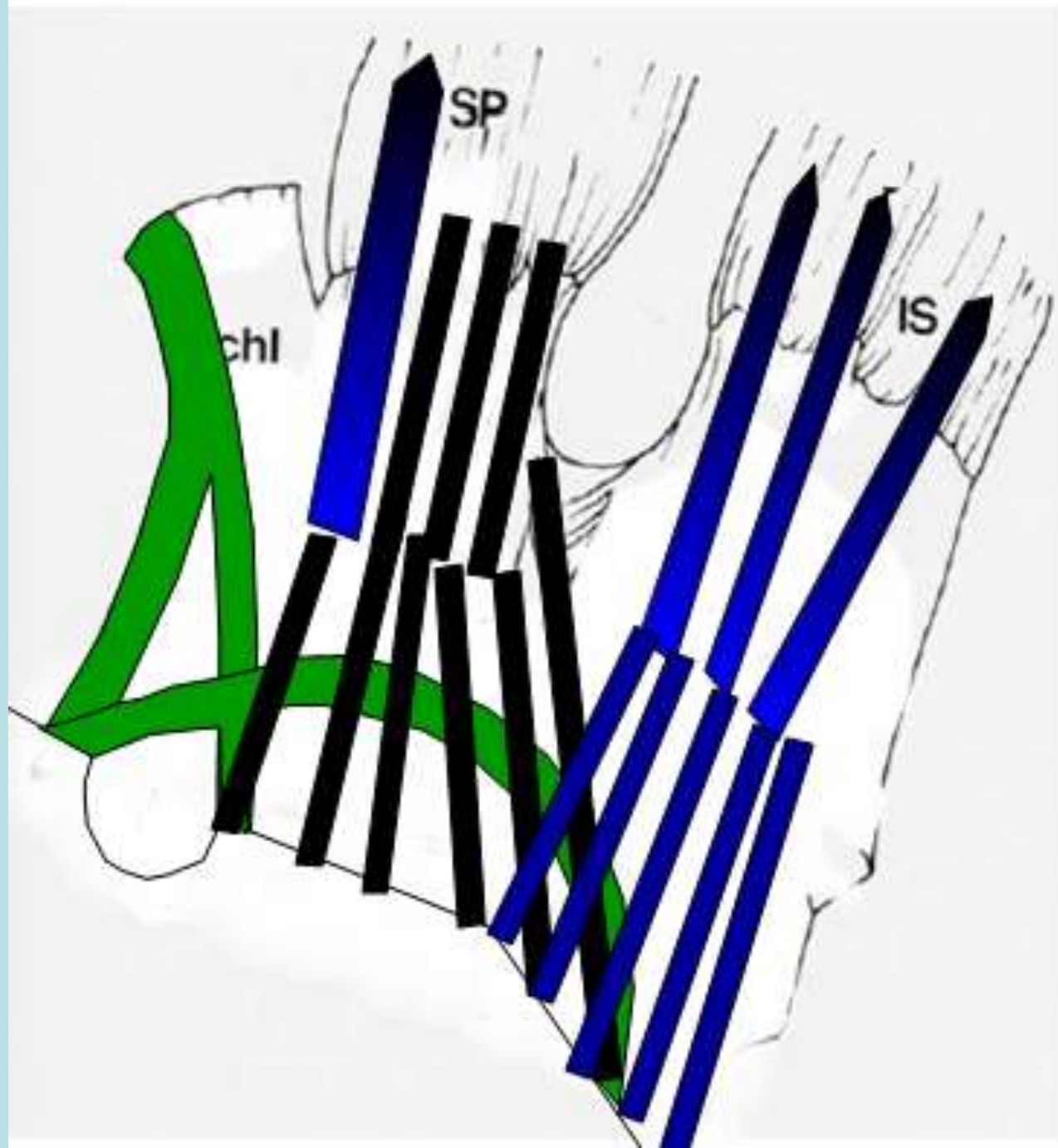


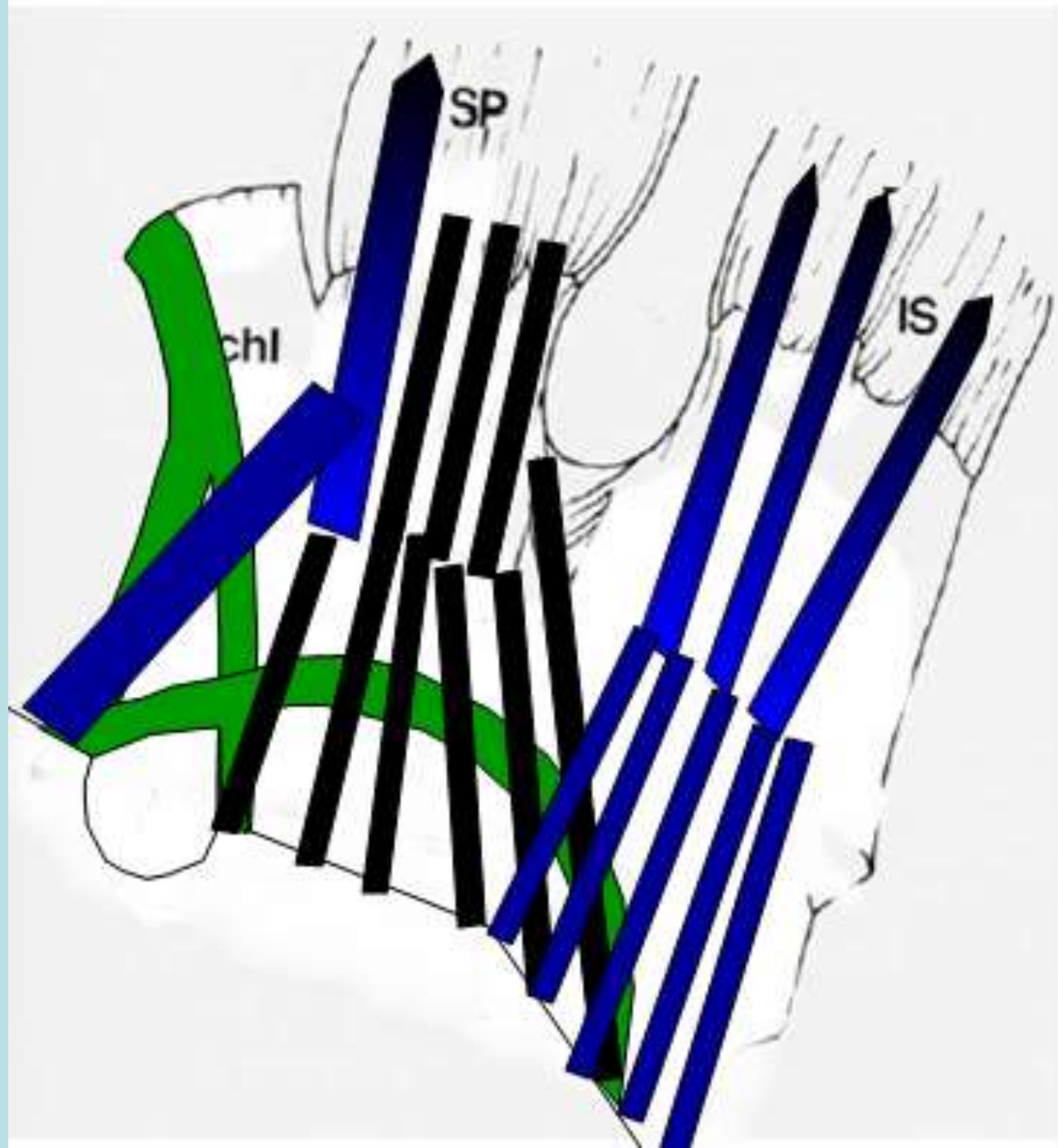




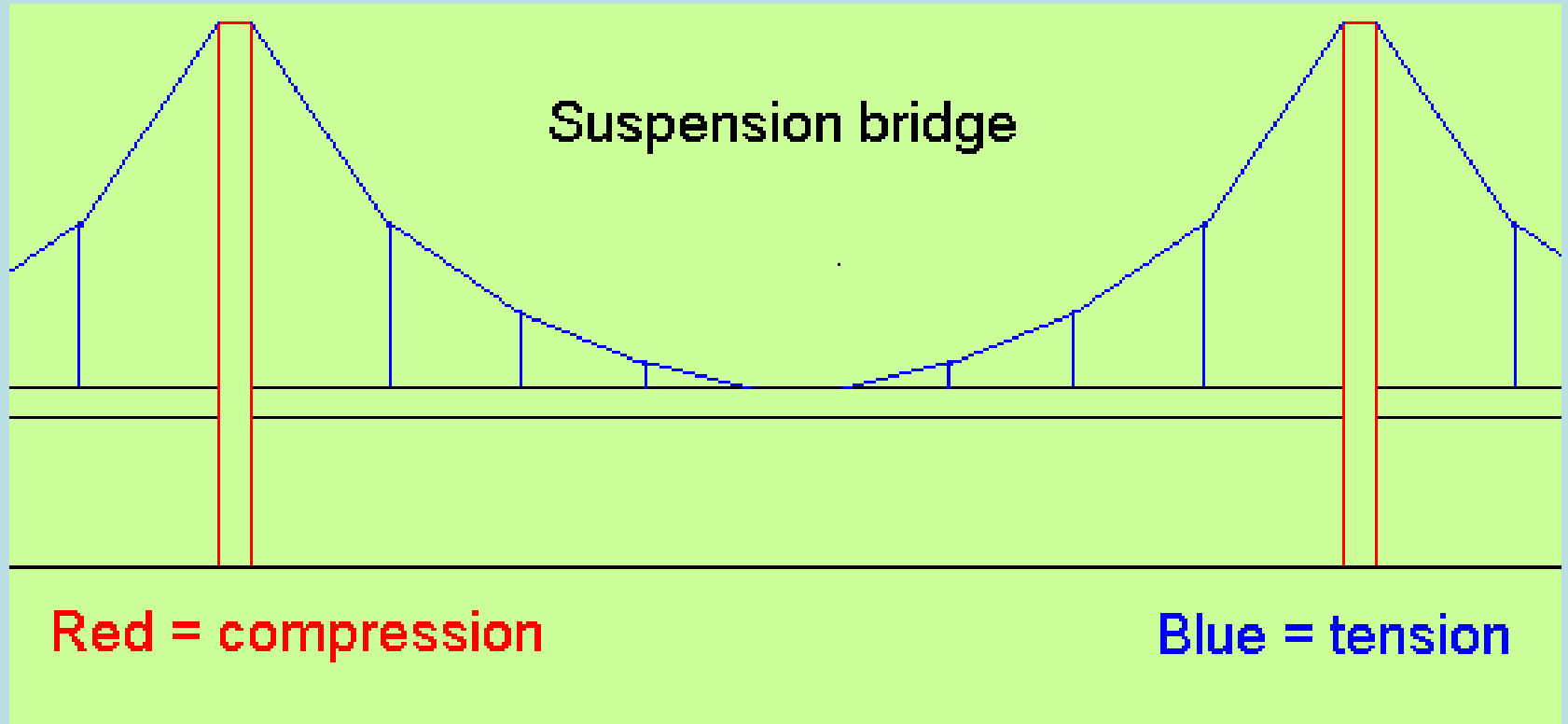








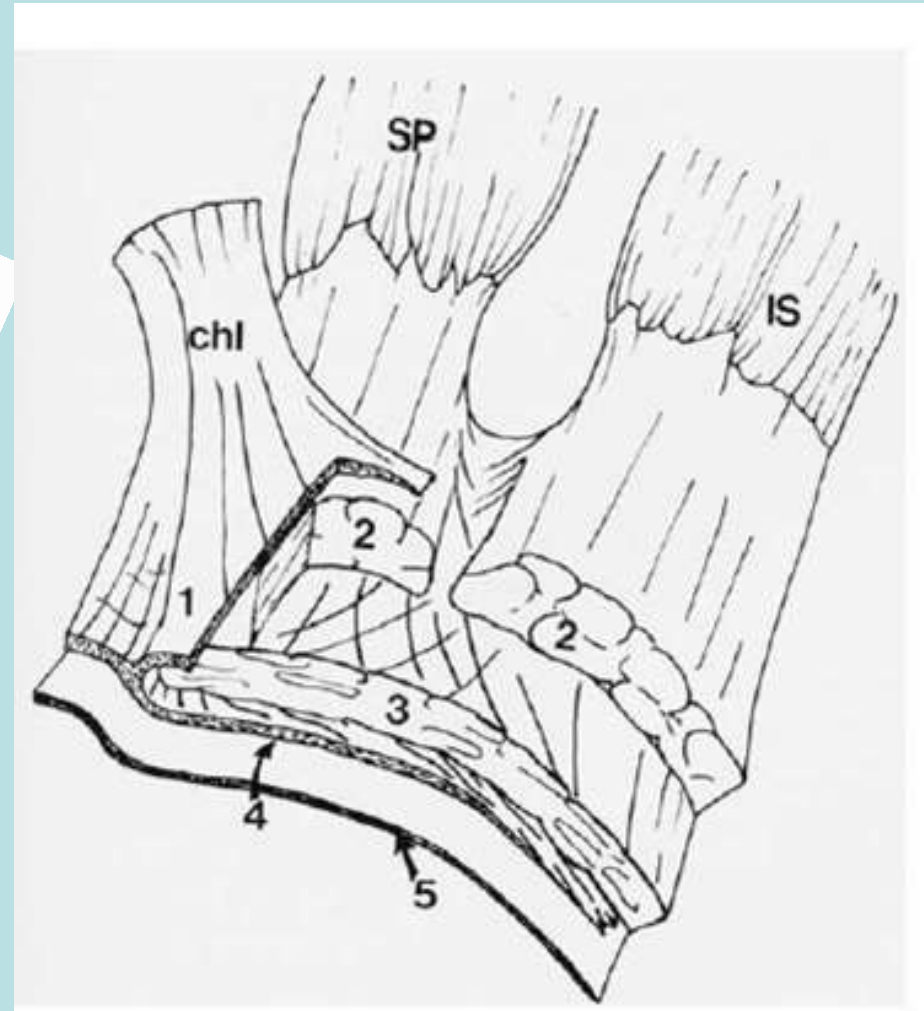
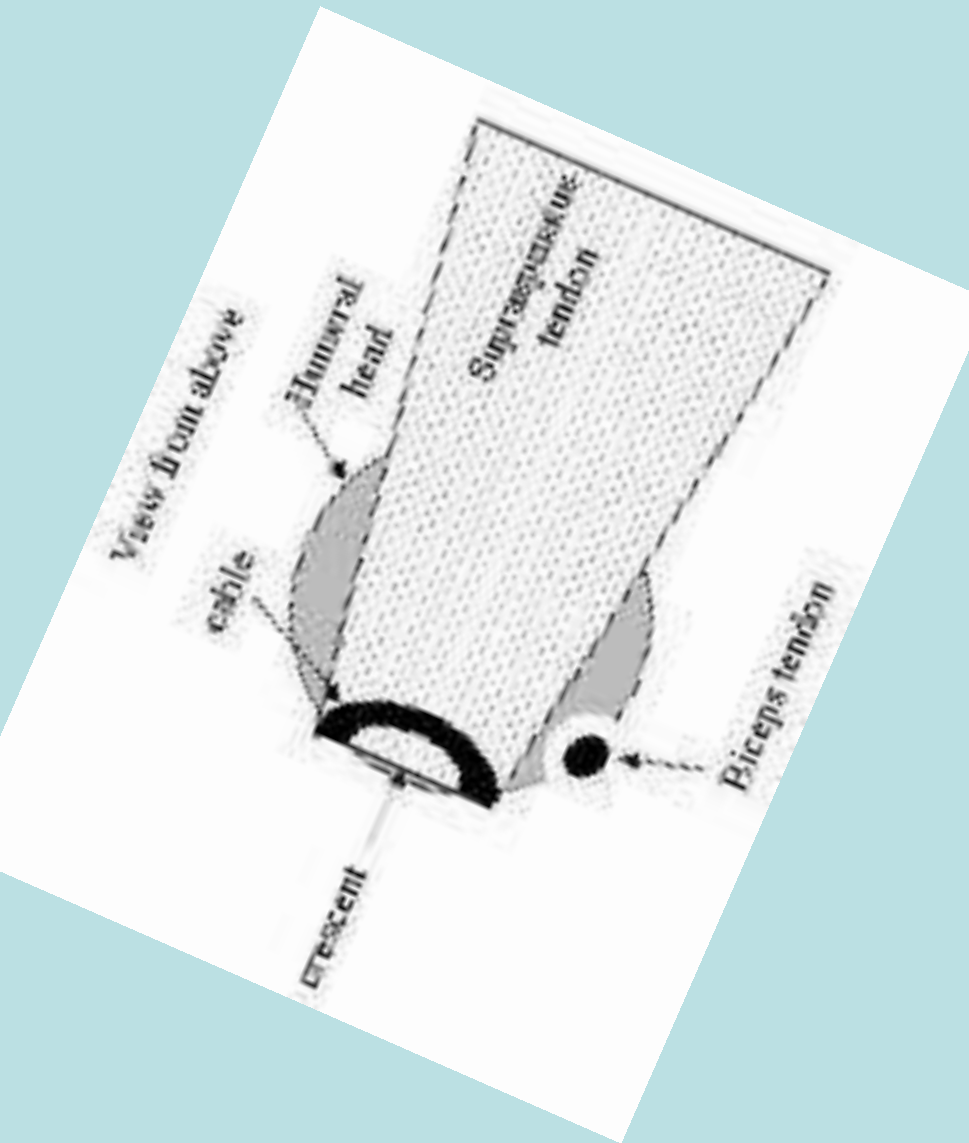
Rotator Cuff Cable/Crescent



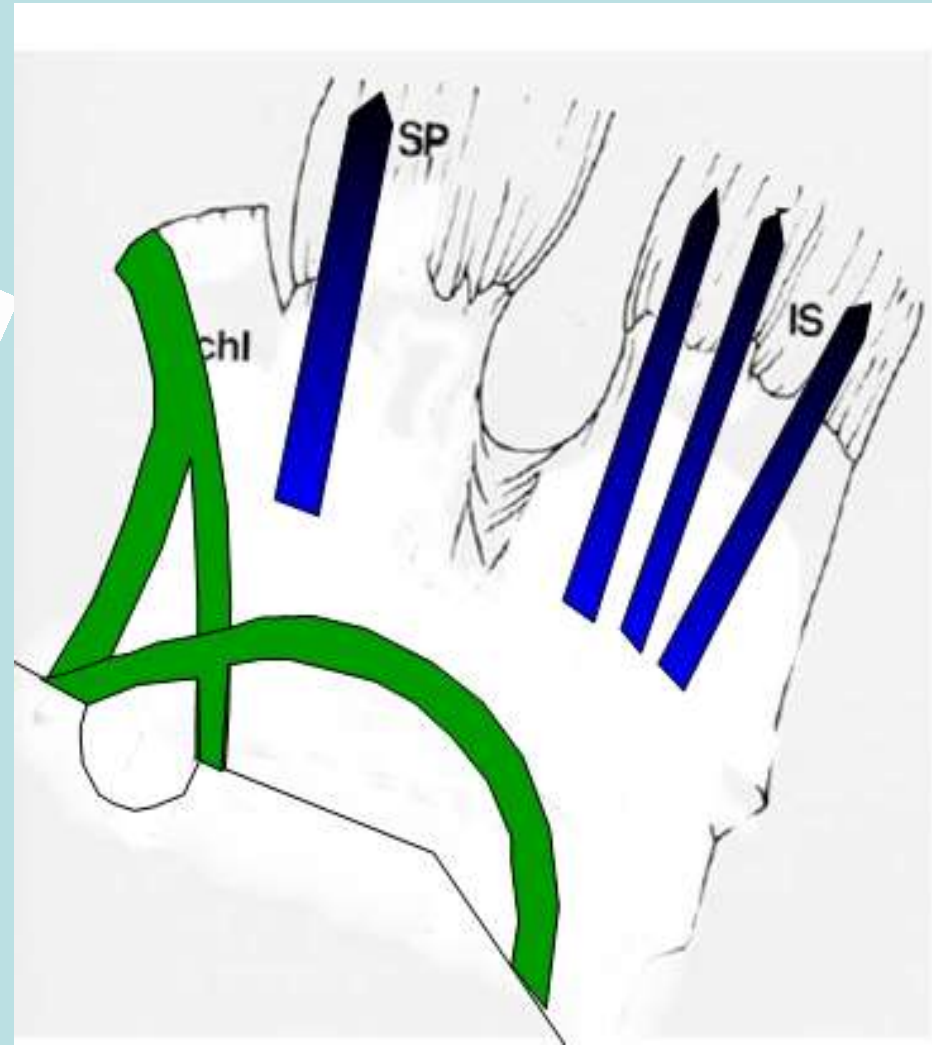
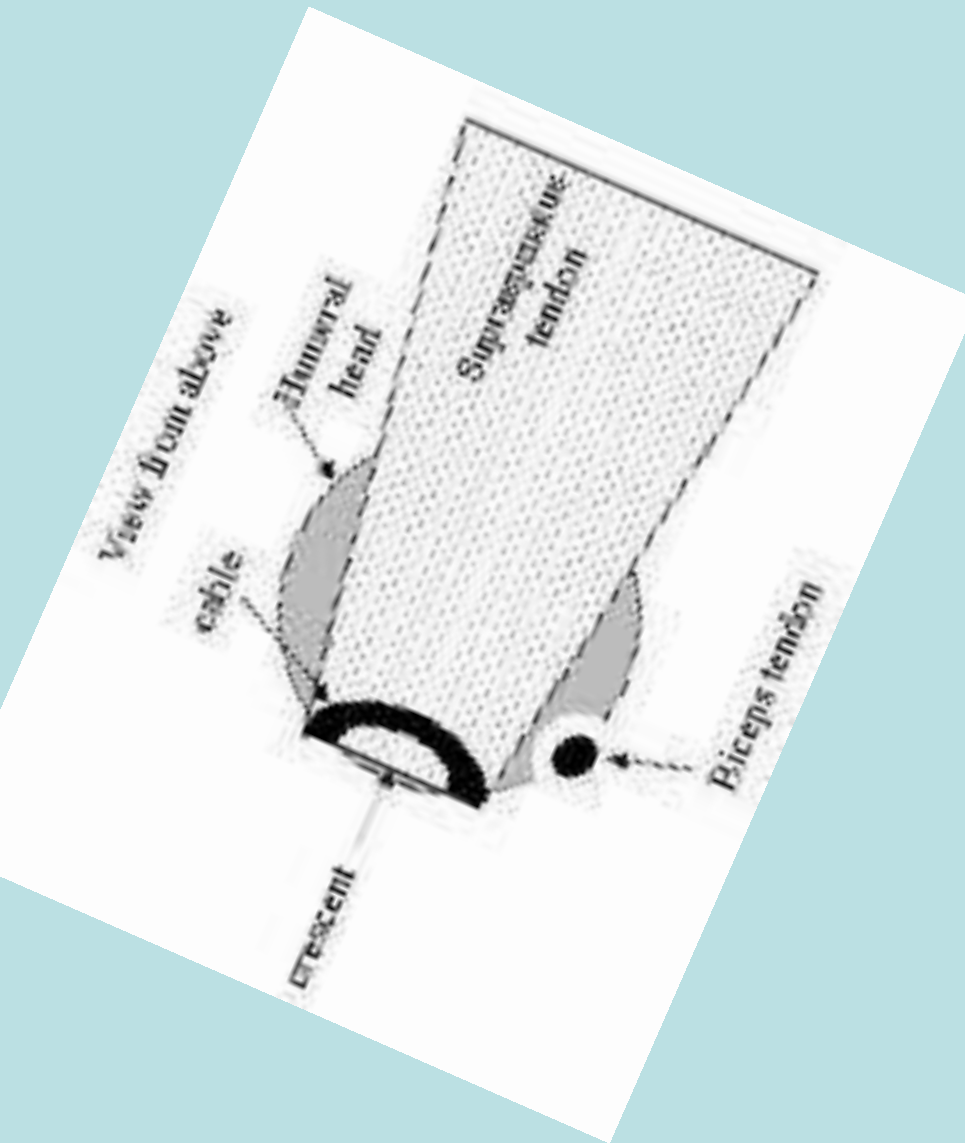
Cable/Crescent

- Cable component of the CHL (layer 4), thick fibrous tissue visible arthroscopically bounds thinner Crescent shaped portion of the distal cuff
- Extends from anterior Supra to Infra
- Functions as “Suspension Bridge”
- Shields the thinner crescent from undue stress
- Limits the degree of retraction of RCT
- Cable dominant/non dominant shoulders

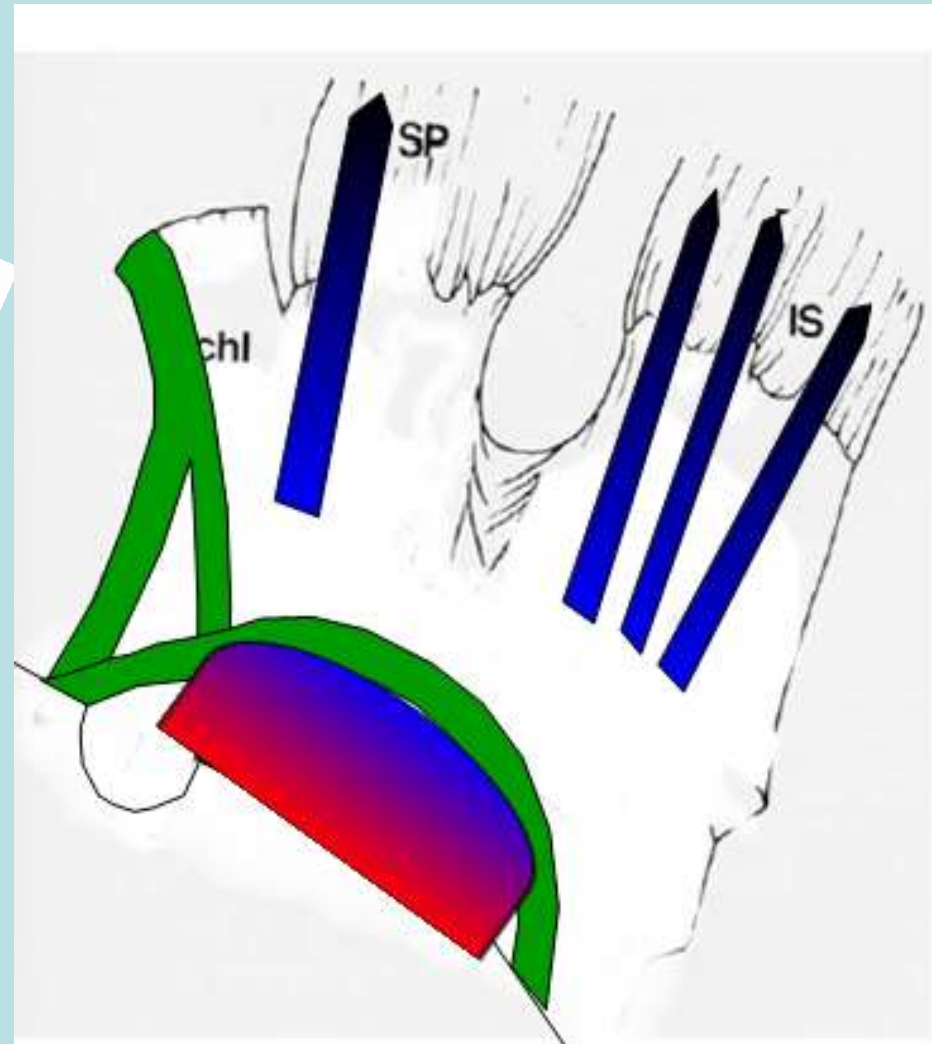
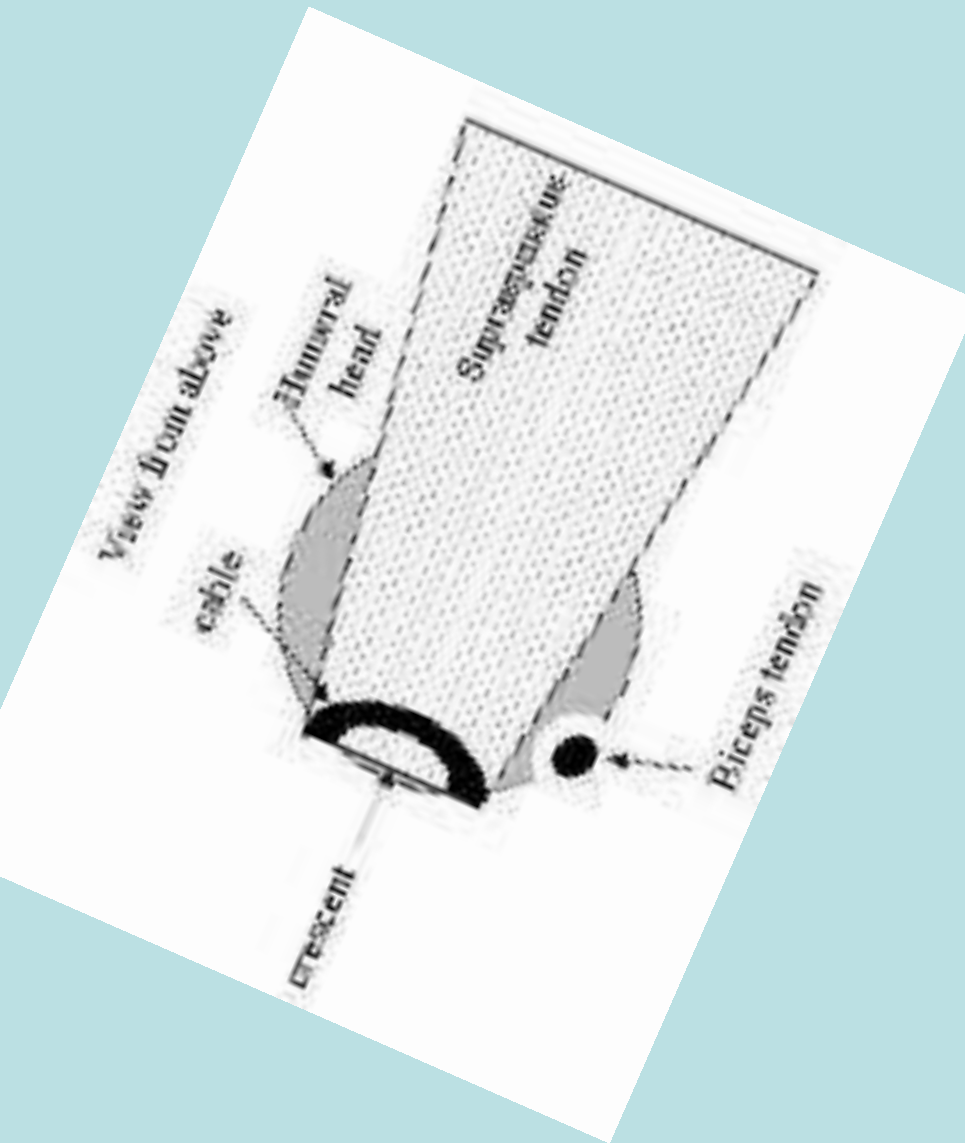
Rotator Cuff Cable/Crescent



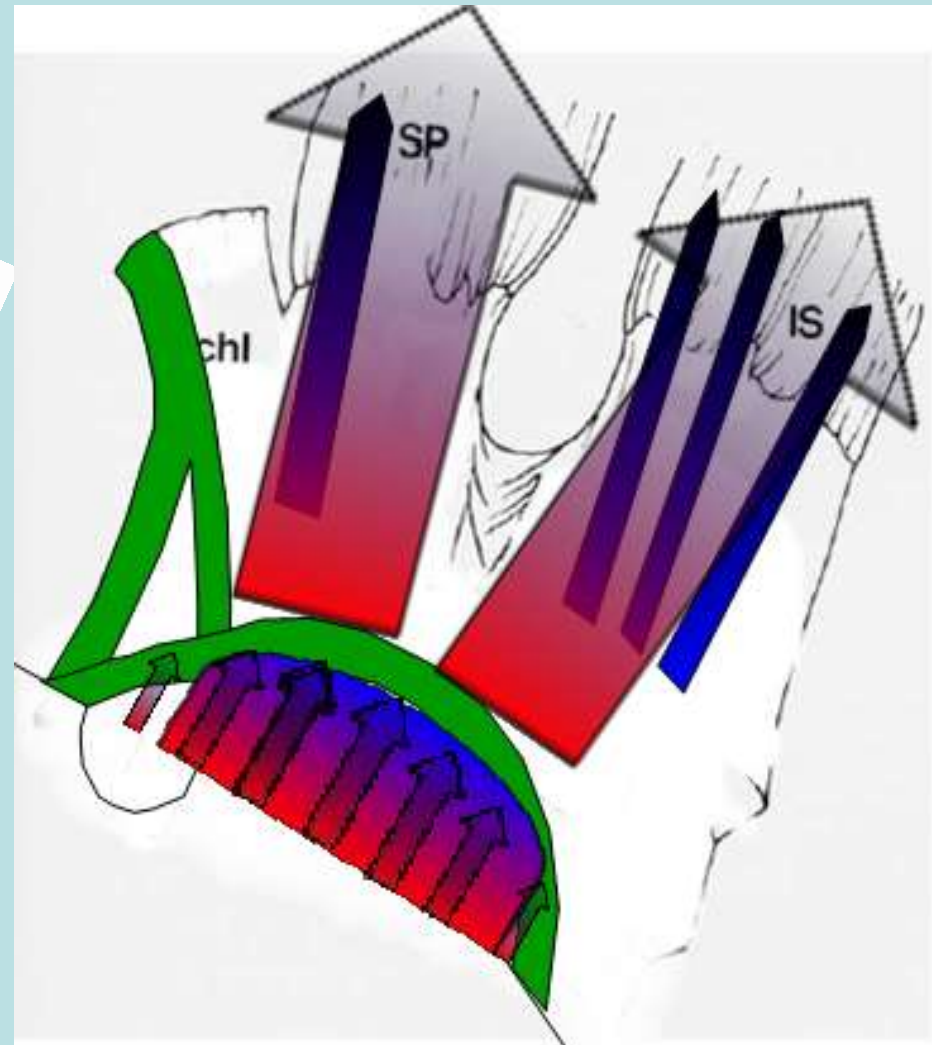
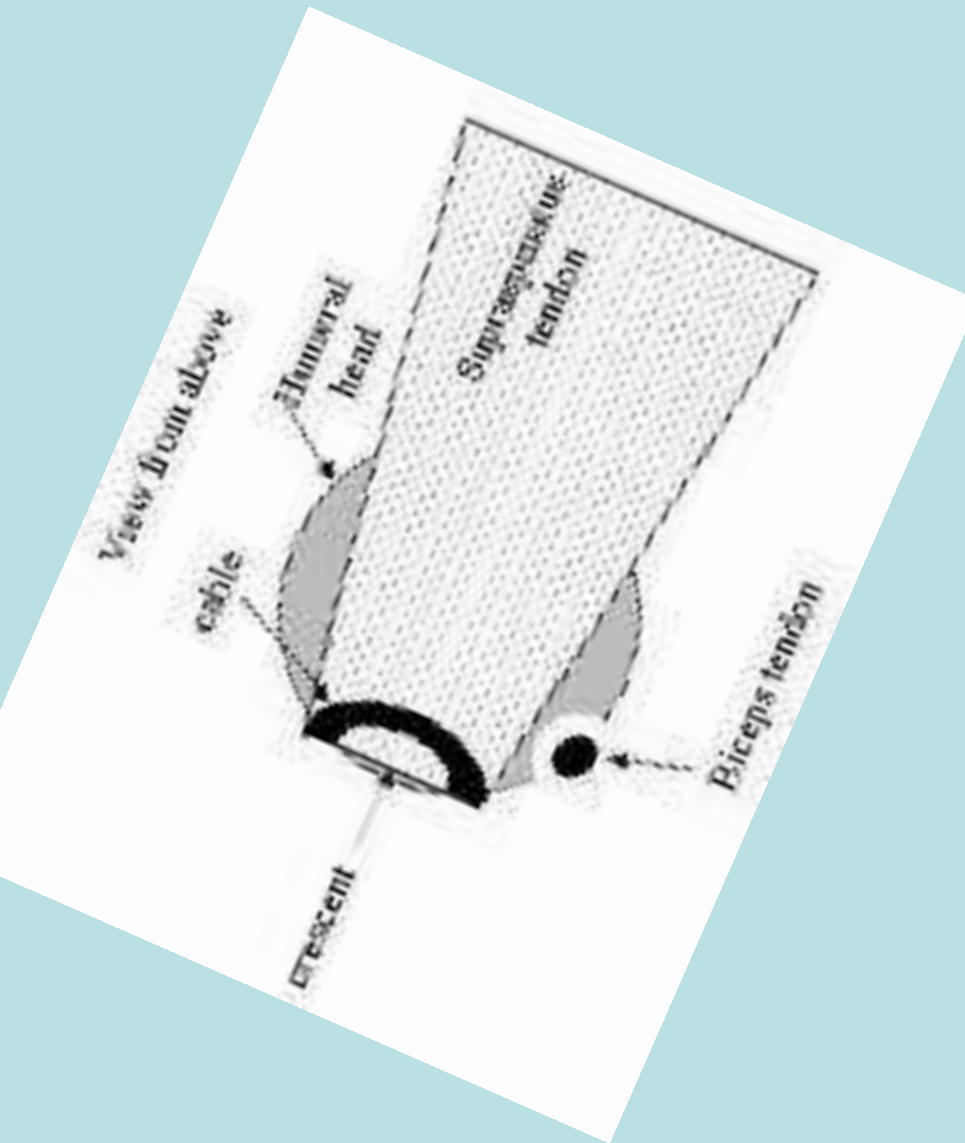
Rotator Cuff Cable/Crescent



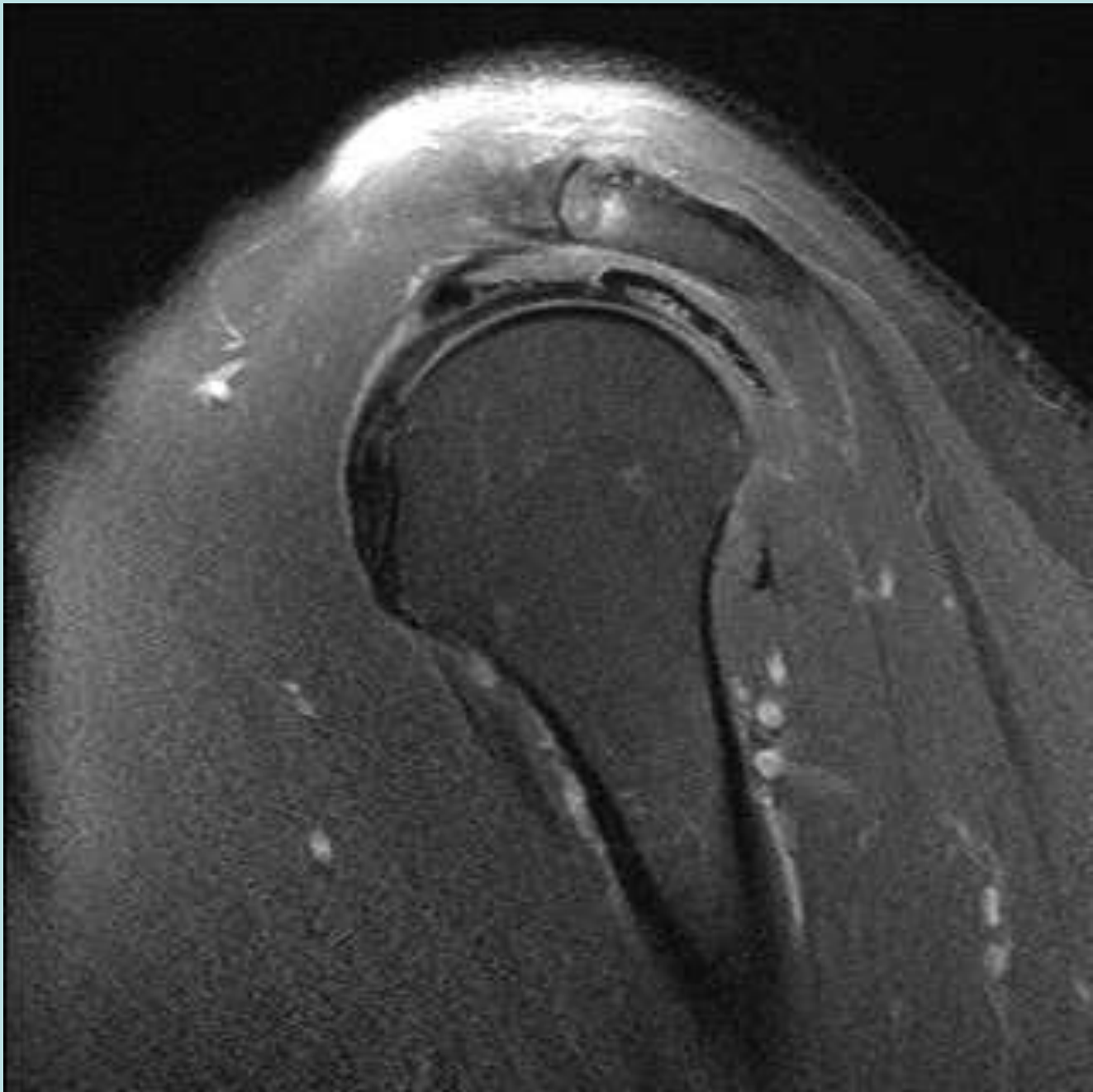
Rotator Cuff Cable/Crescent

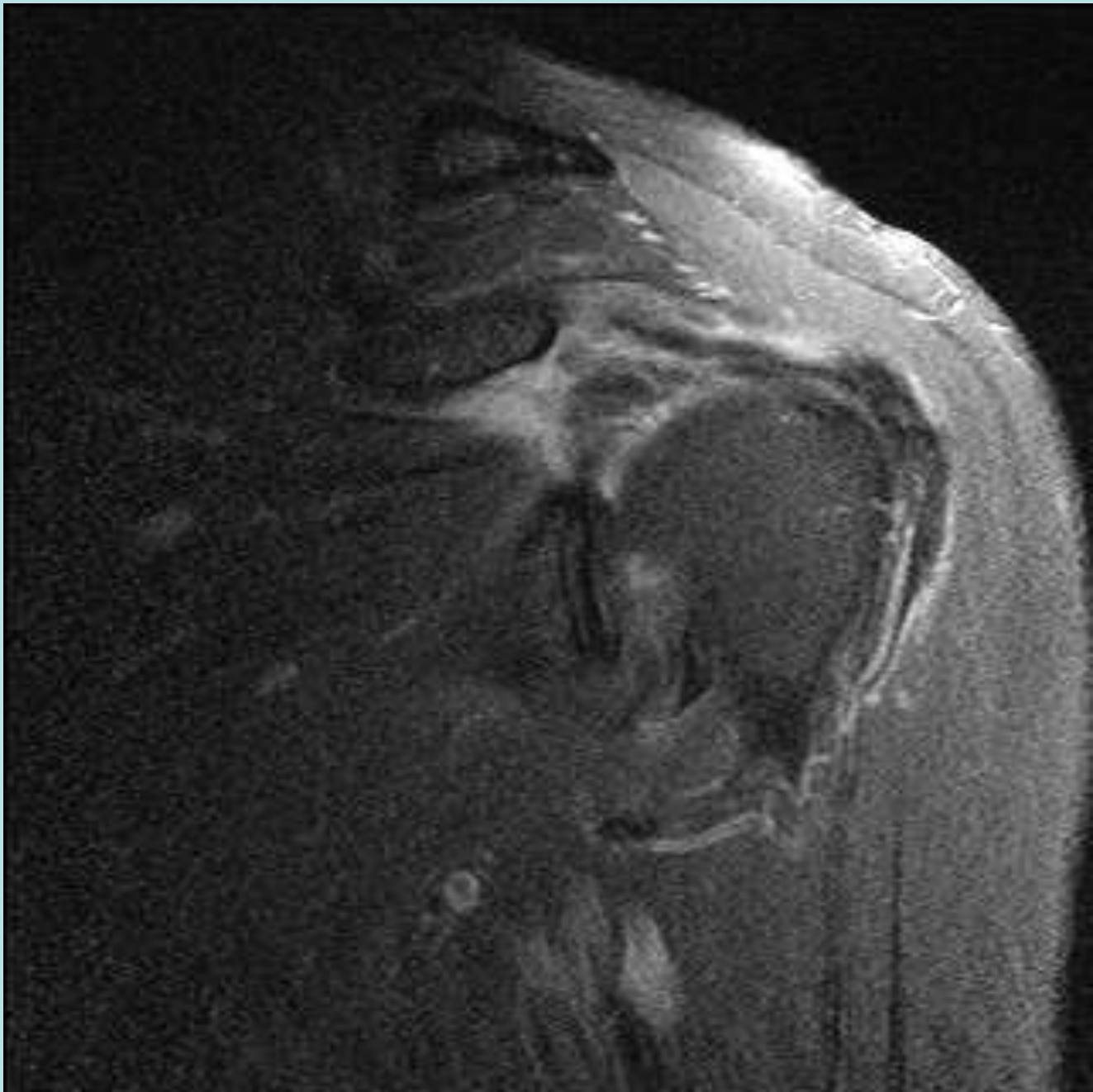


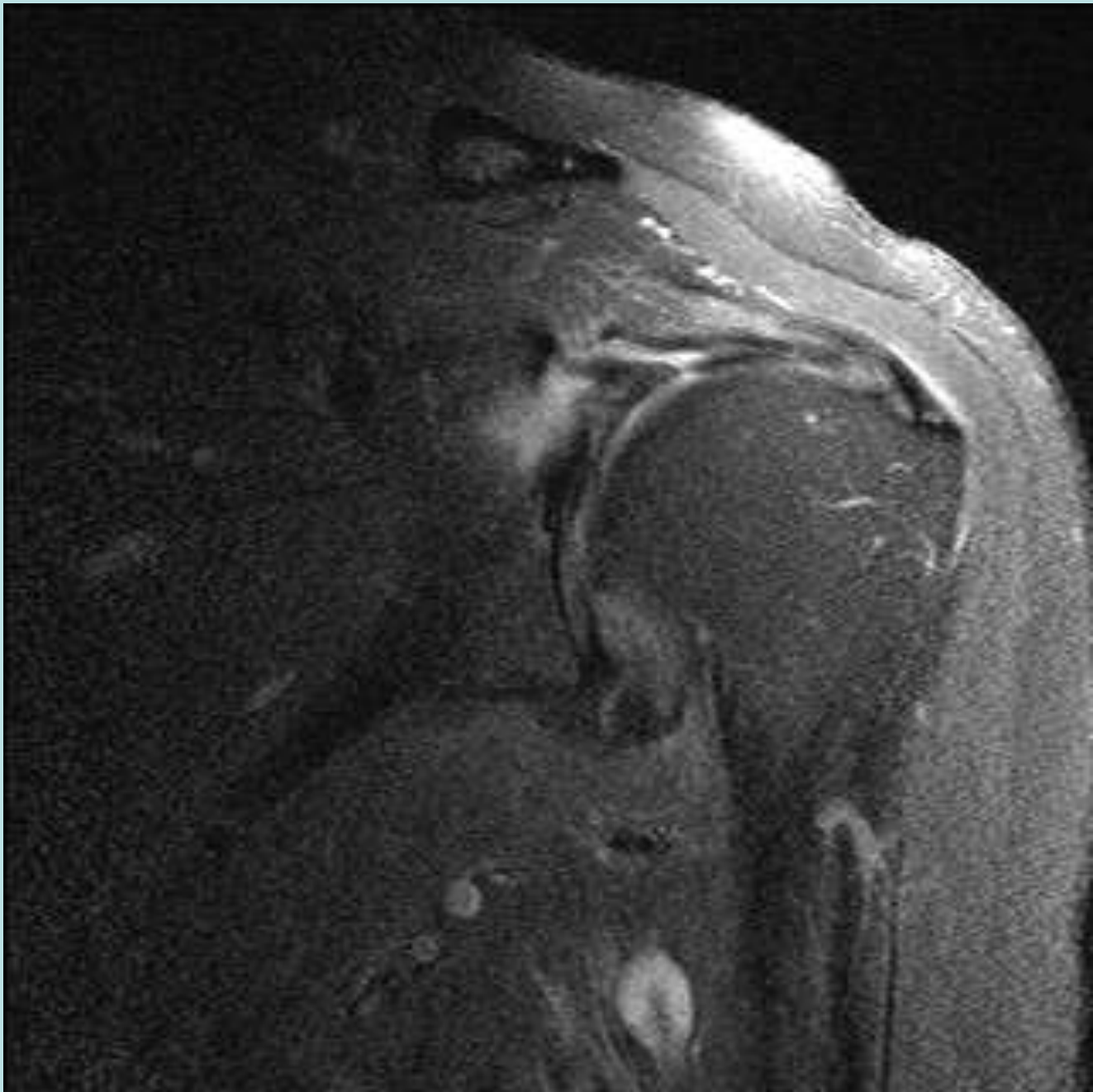
Rotator Cuff Cable/Crescent

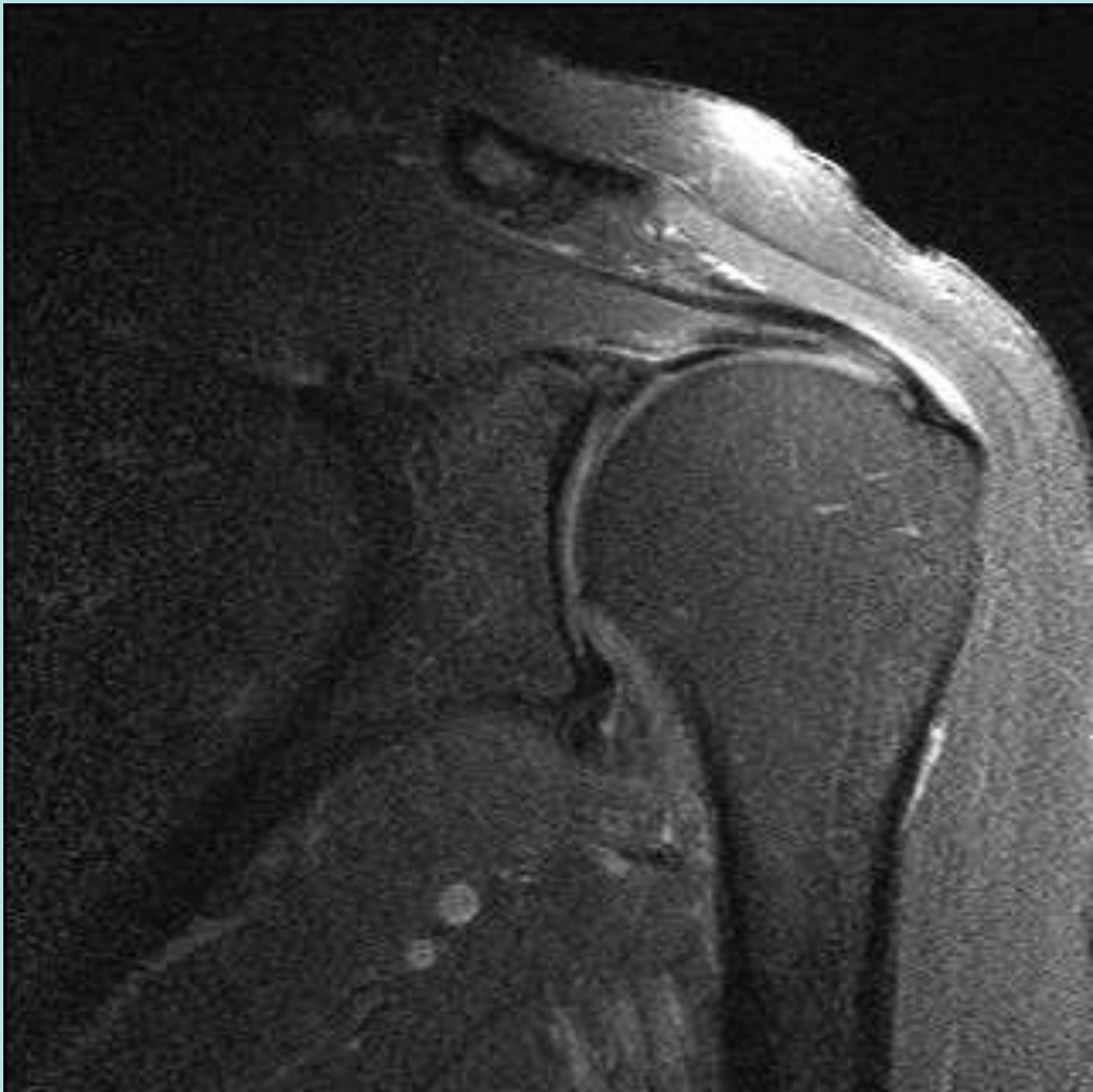


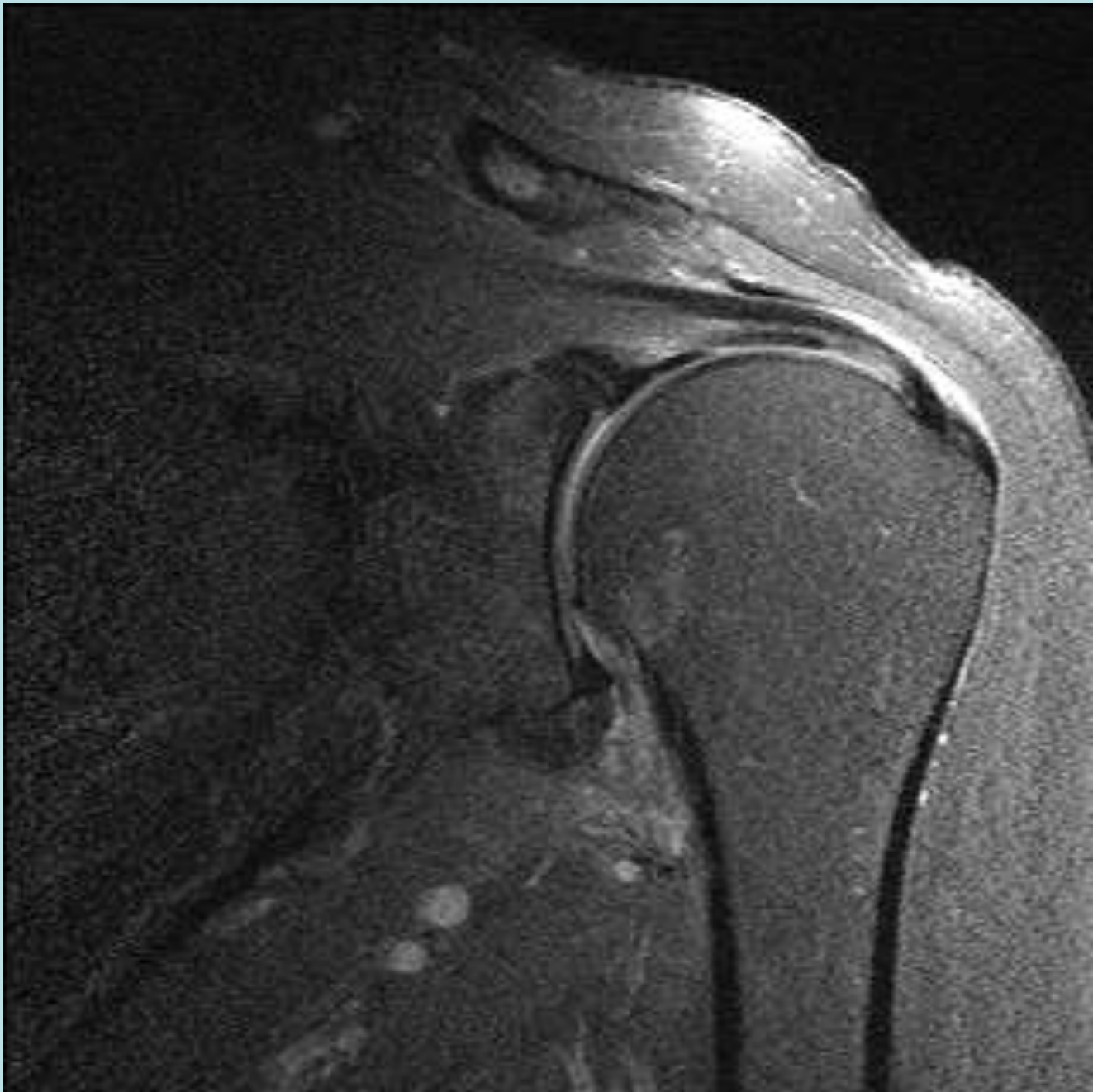
“Cable Dominant”

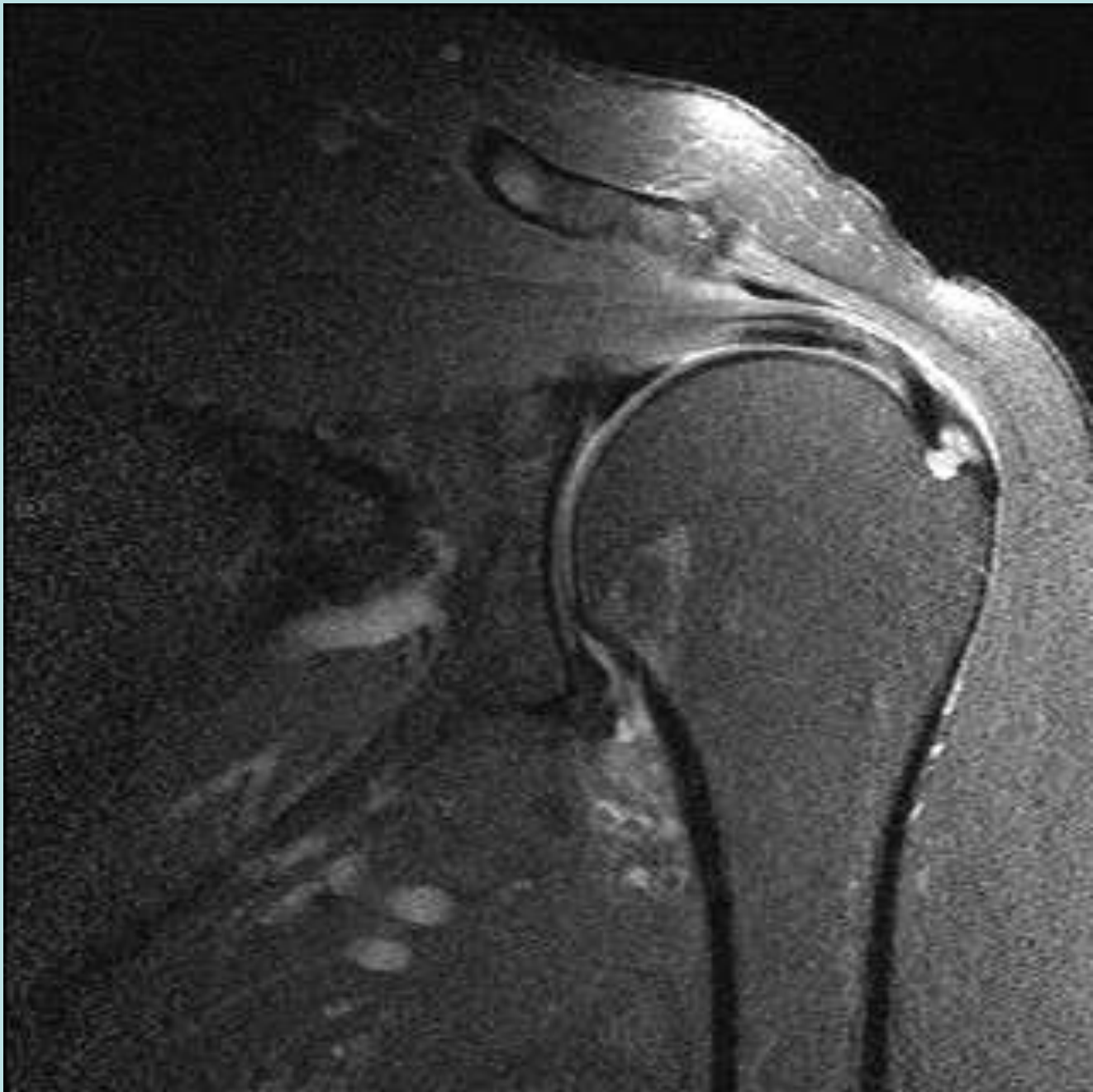


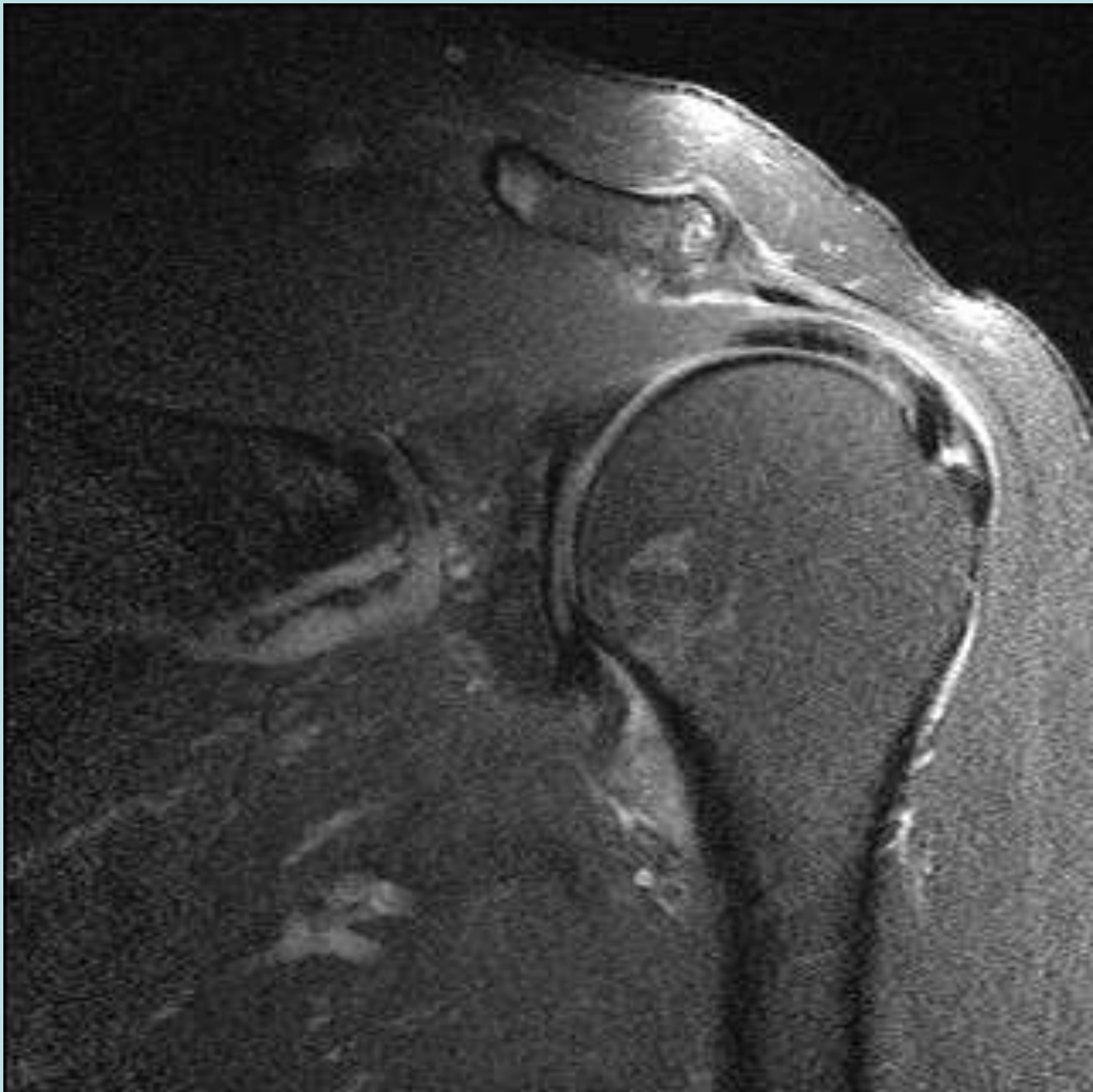

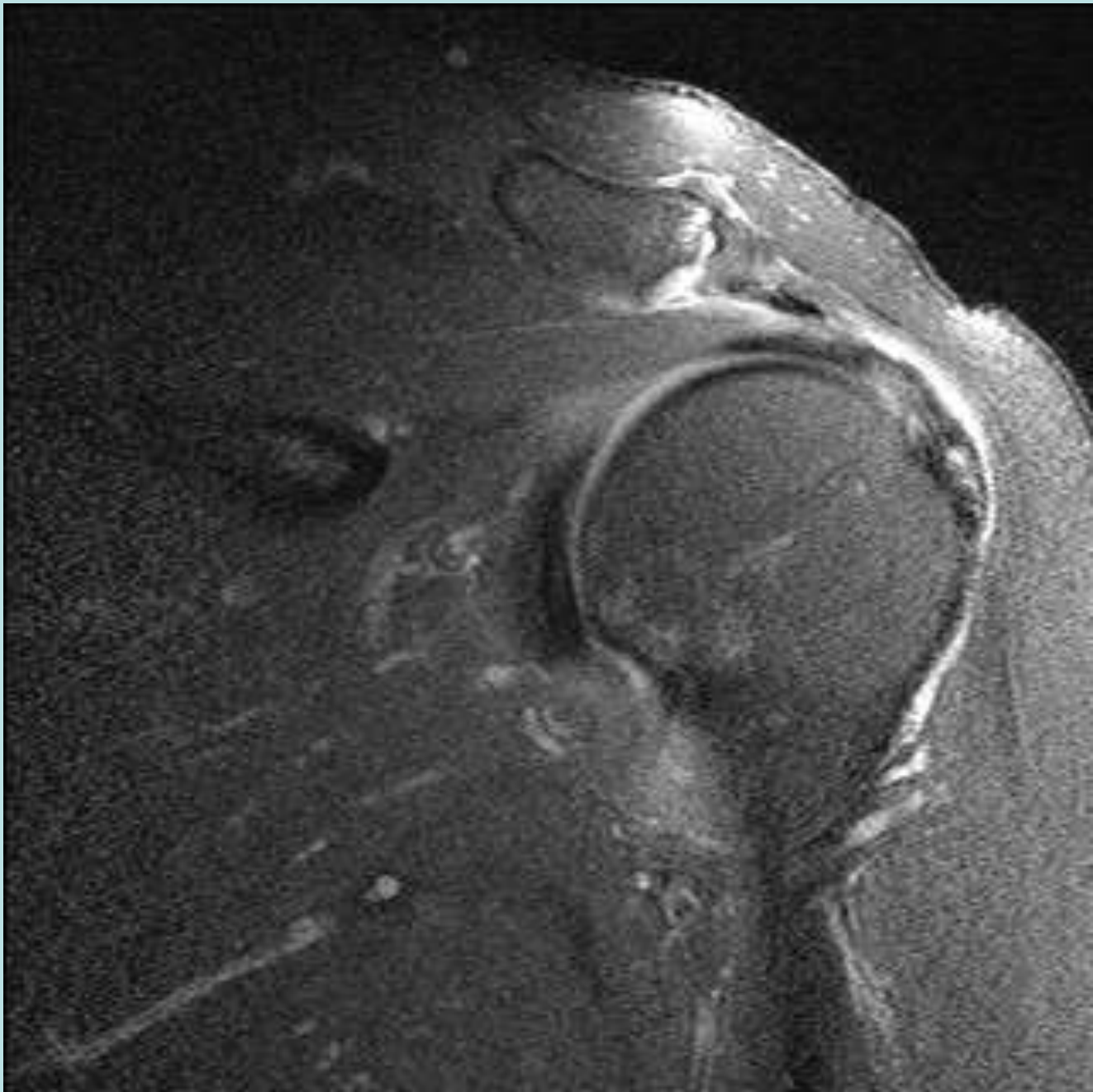


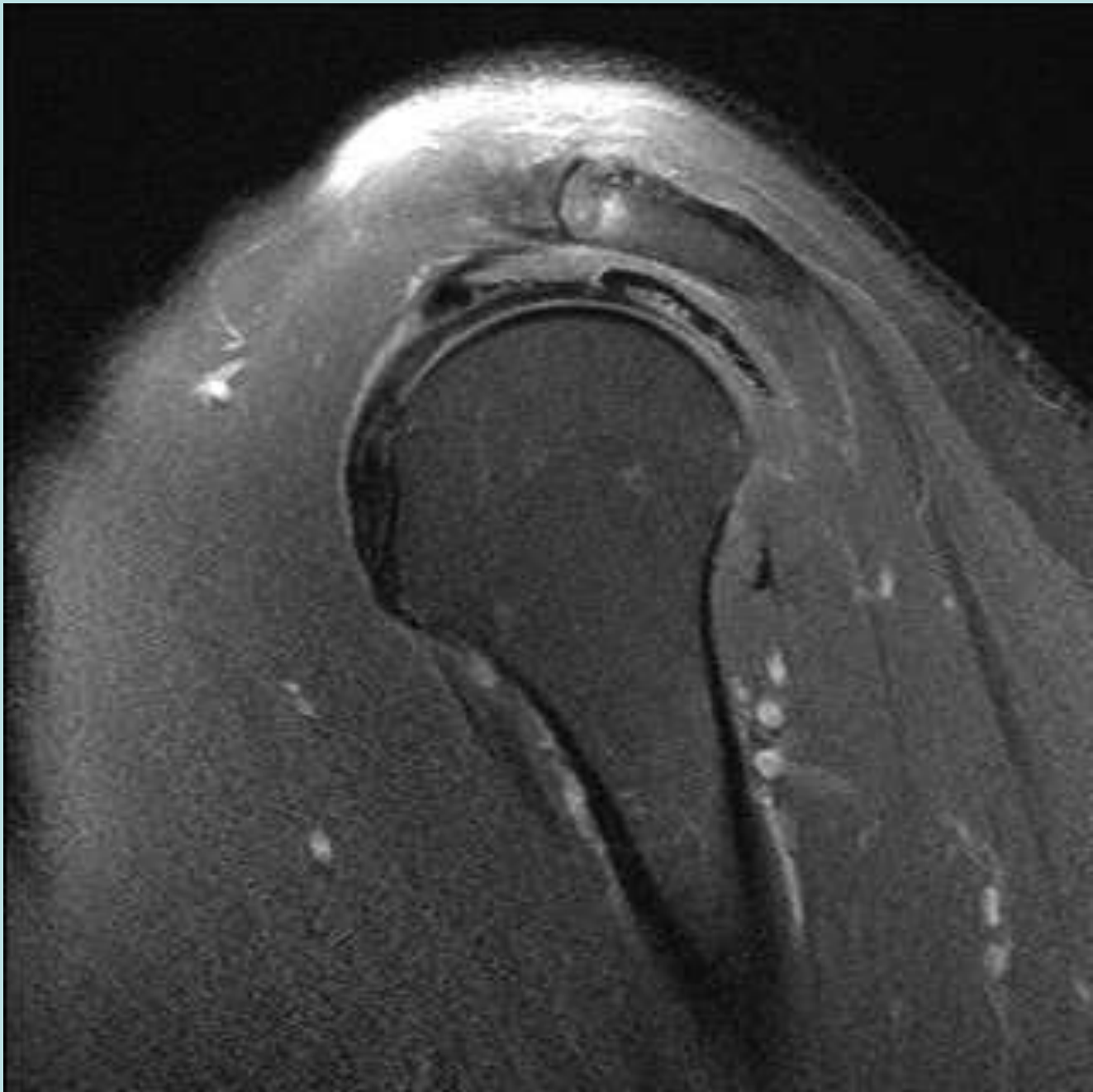


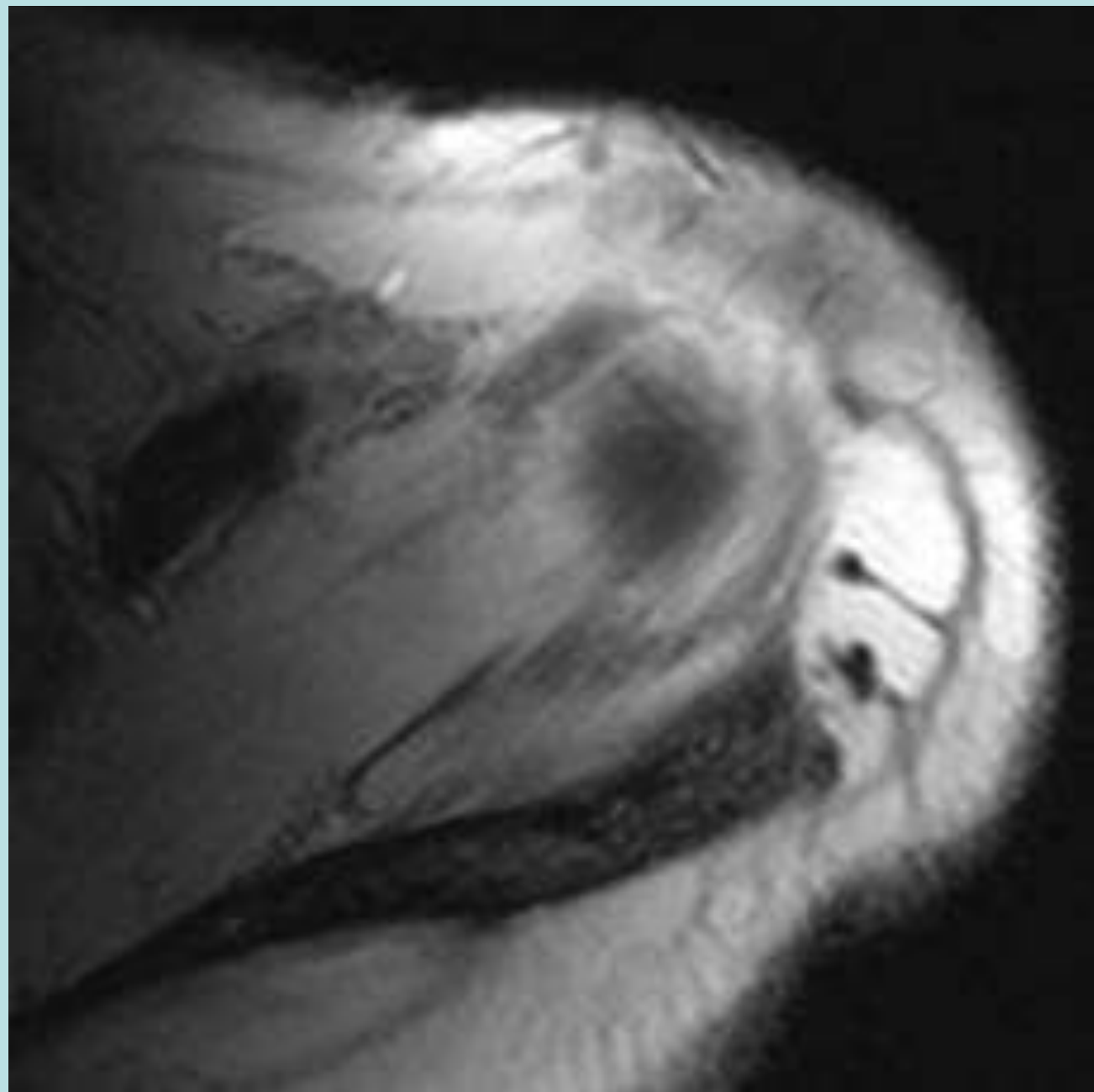




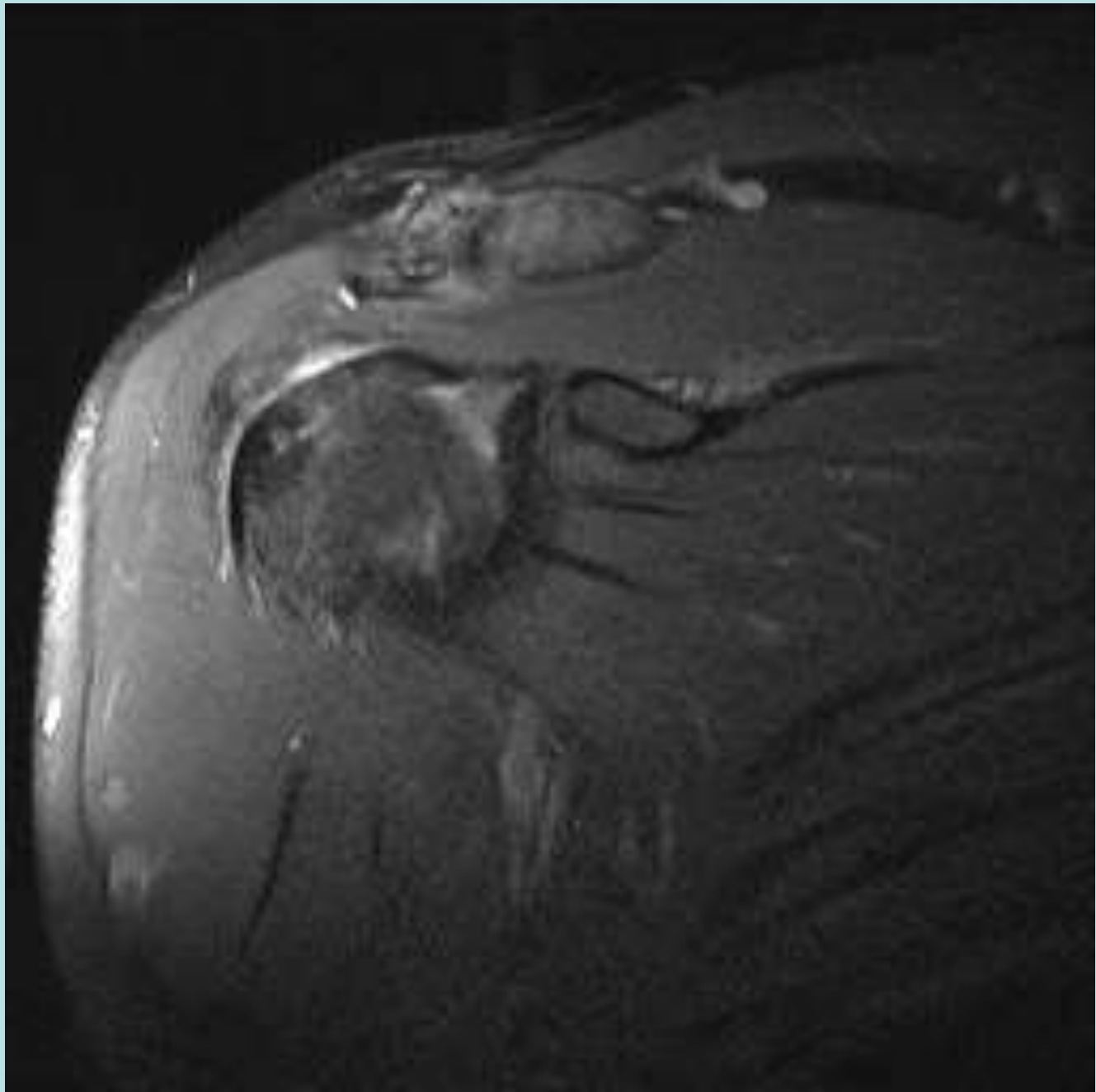


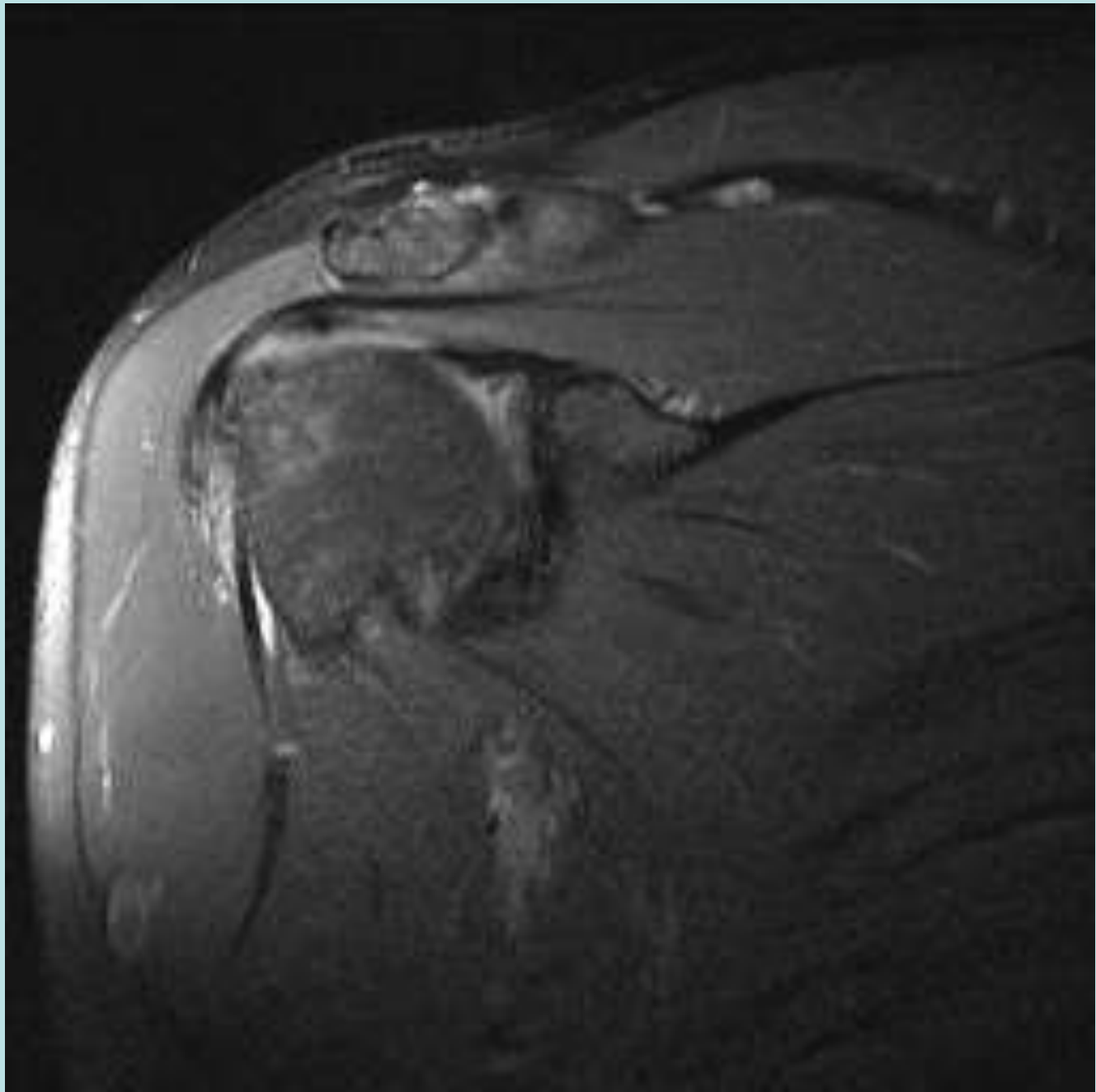


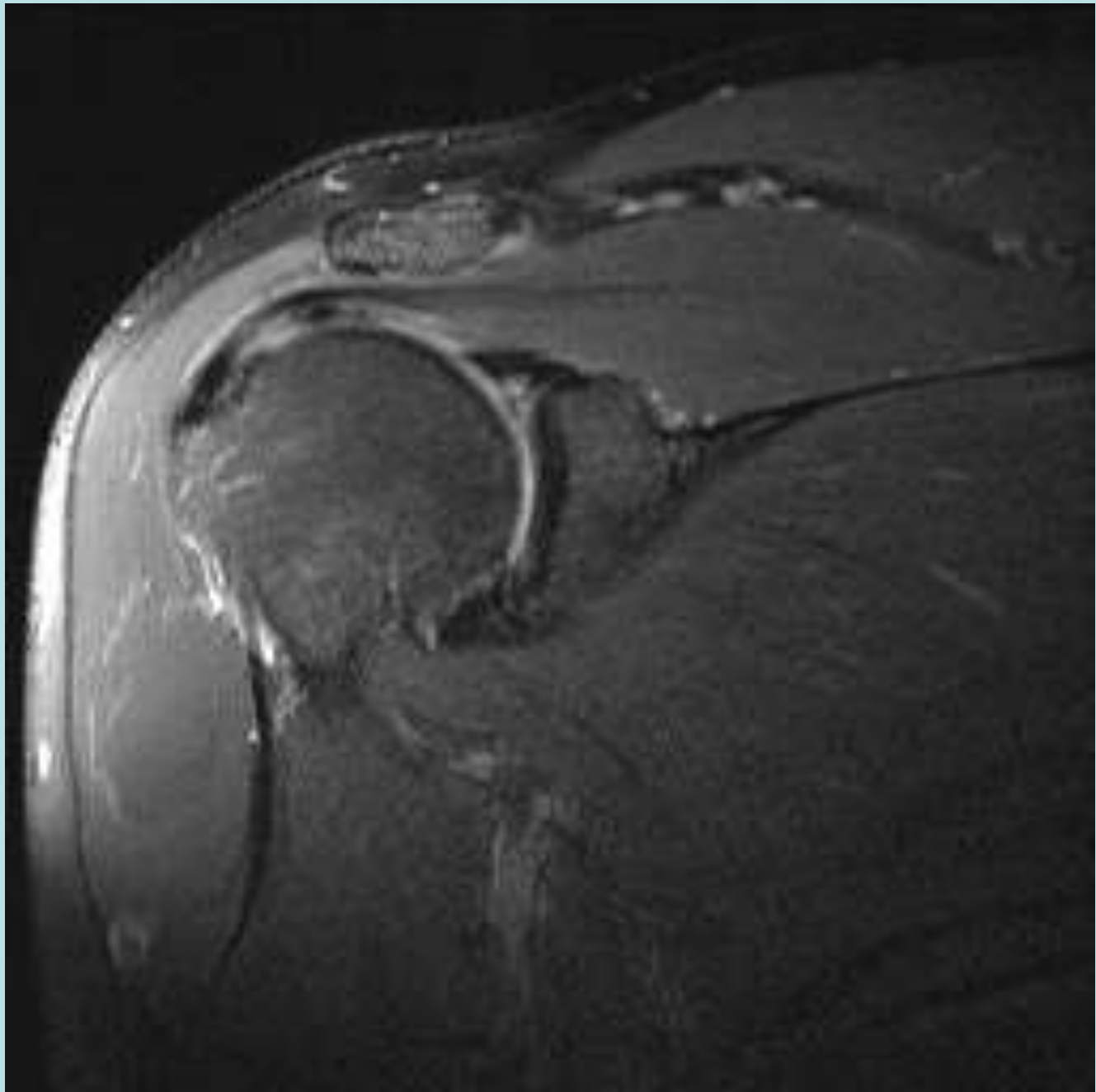


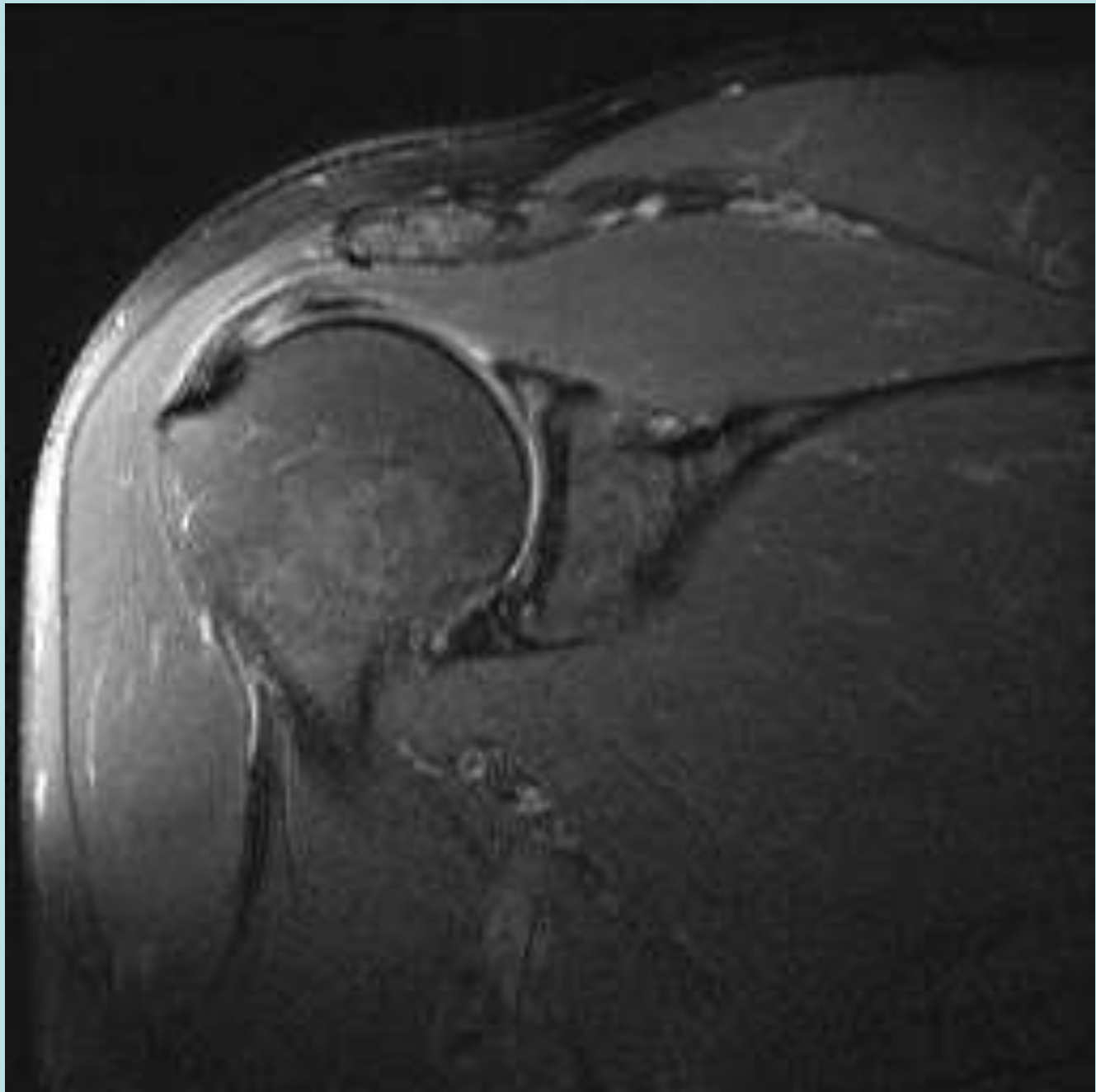


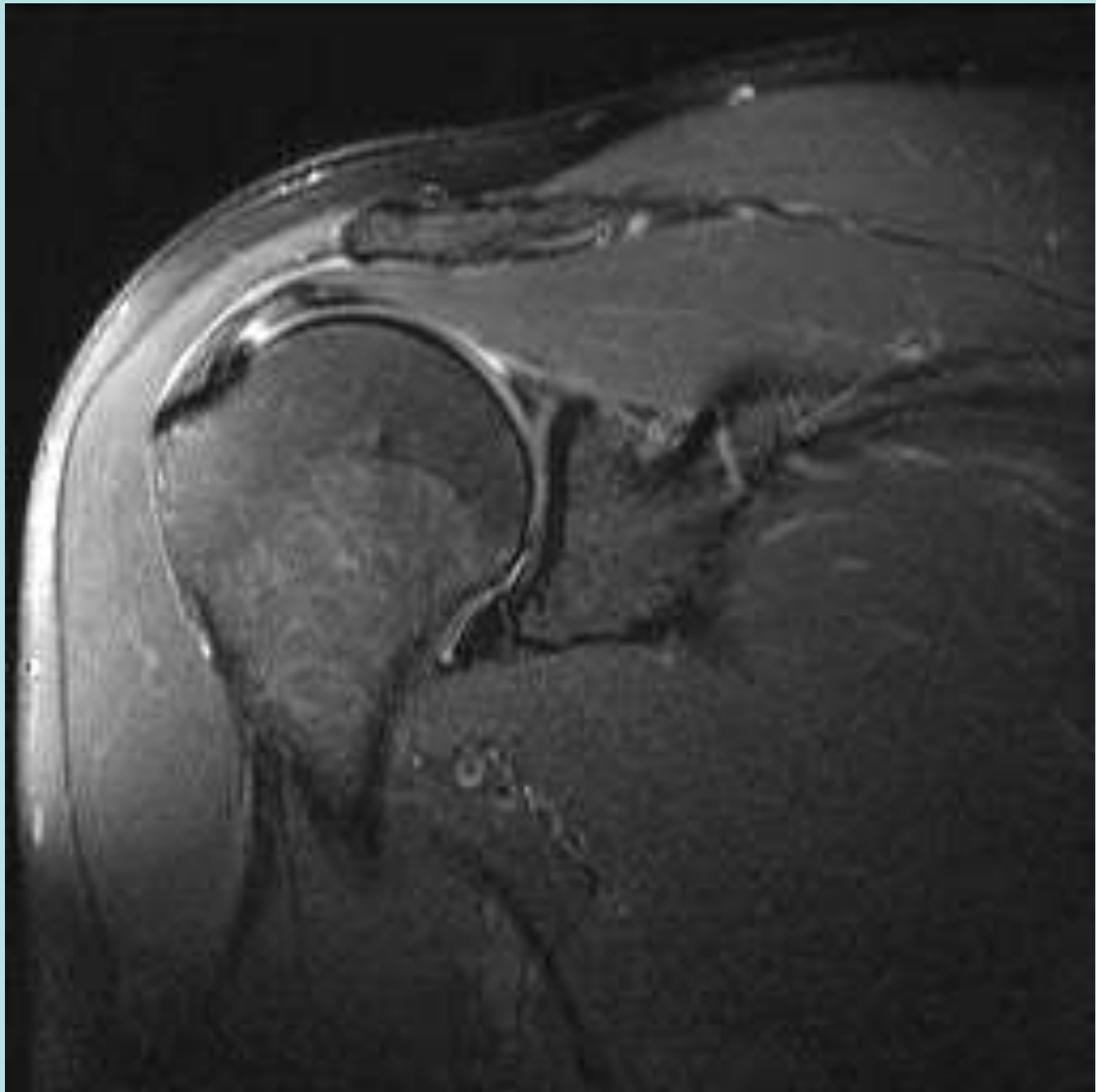
Cable Dominant PT RCT

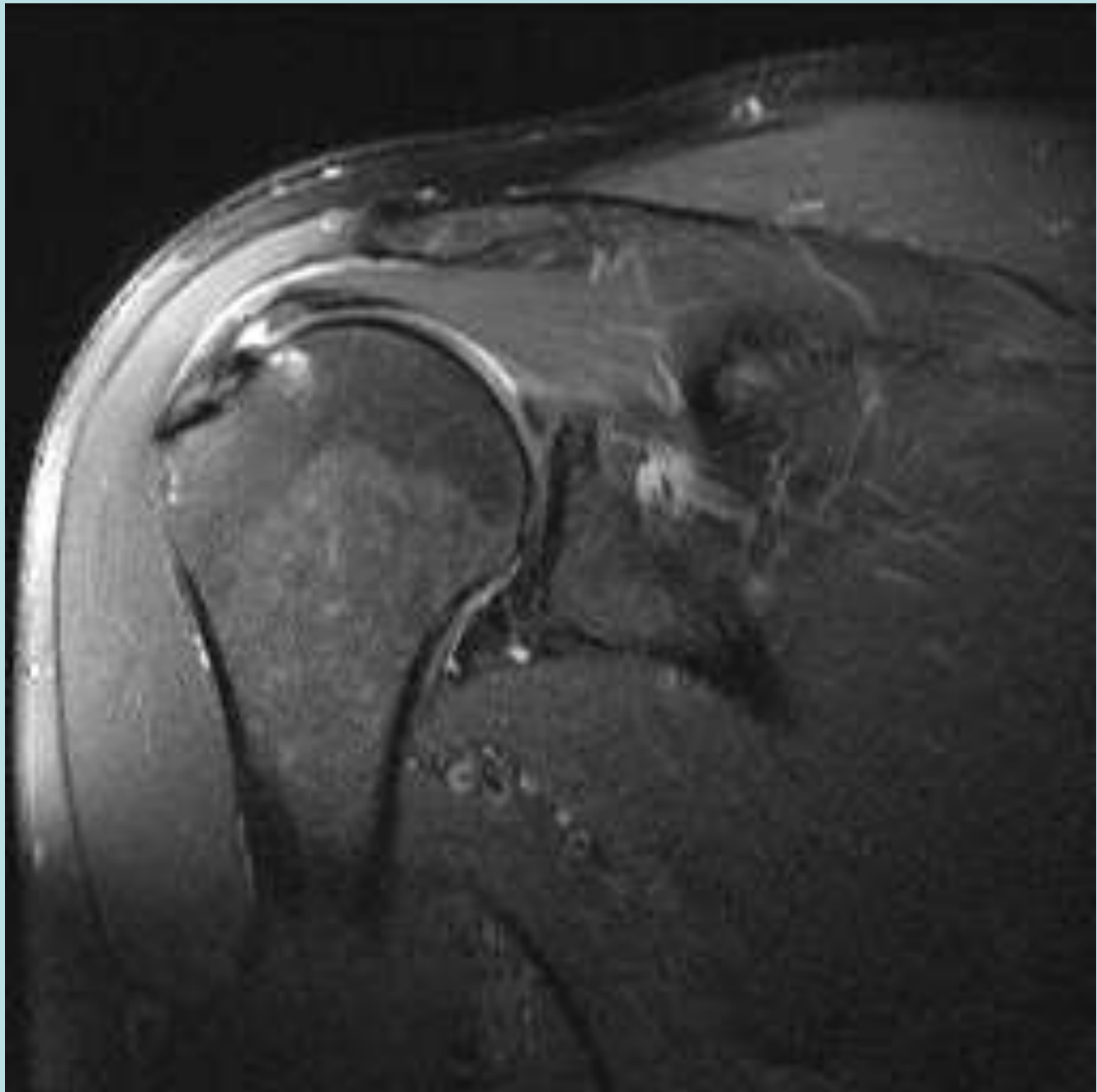




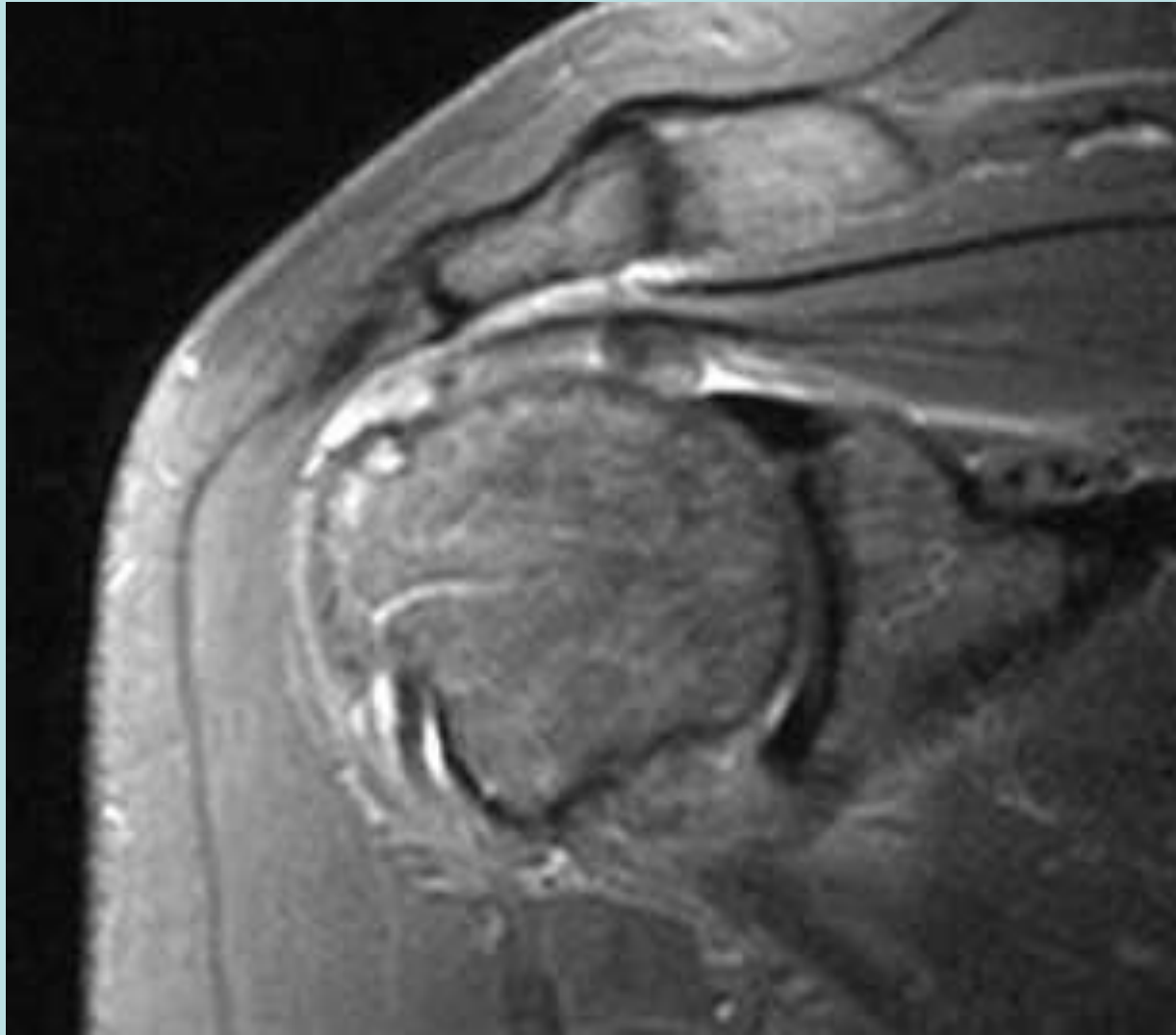








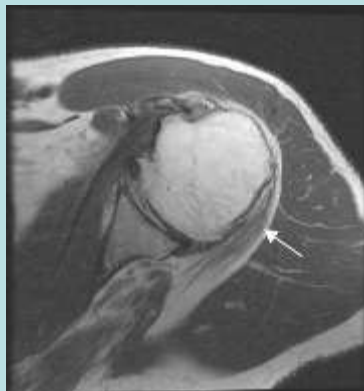
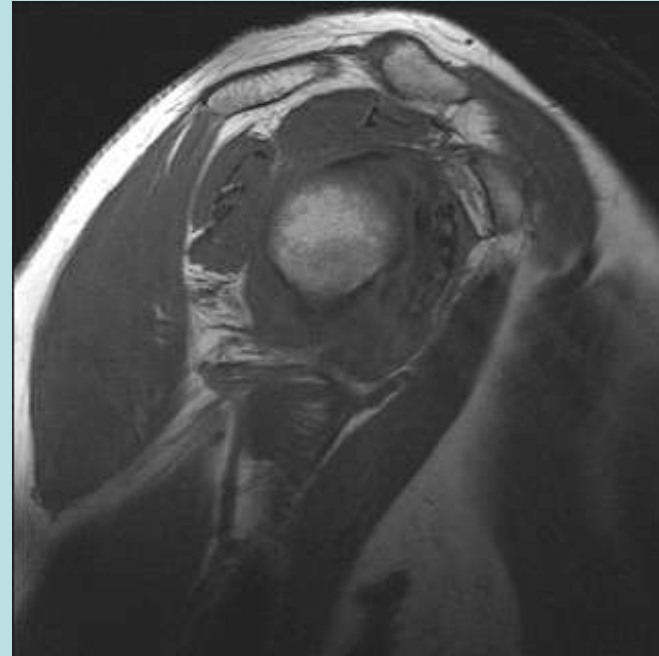
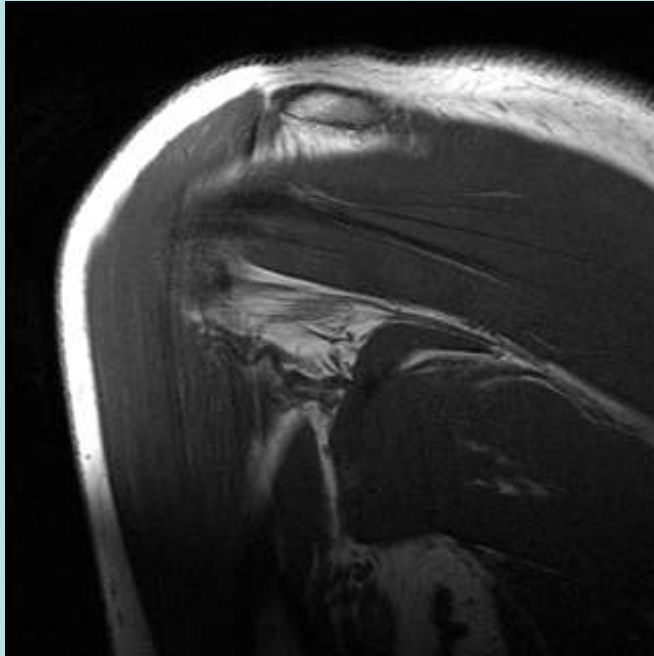
Cable Dominant with FT RCT



Teres Minor

- Originates lower inferior edge of scapula
- Inserts on Vertical Facet of Greater Tub
- Innervated by Axillary Nerve
- May show atrophy/denervation changes
“Quadrilateral Space Syndrome”/Fibrous Bands
- Isolated Teres Minor abnormality typical---
Nonspecific, d/t prior Trauma, Posterior
Dislocation, Instability

45 y/o female with Adh Capsulitis, SS PT RCT, Teres Minor Atrophy



Carolyn M. Sofka
Julie Lin
Joseph Feinberg
Hollis G. Potter

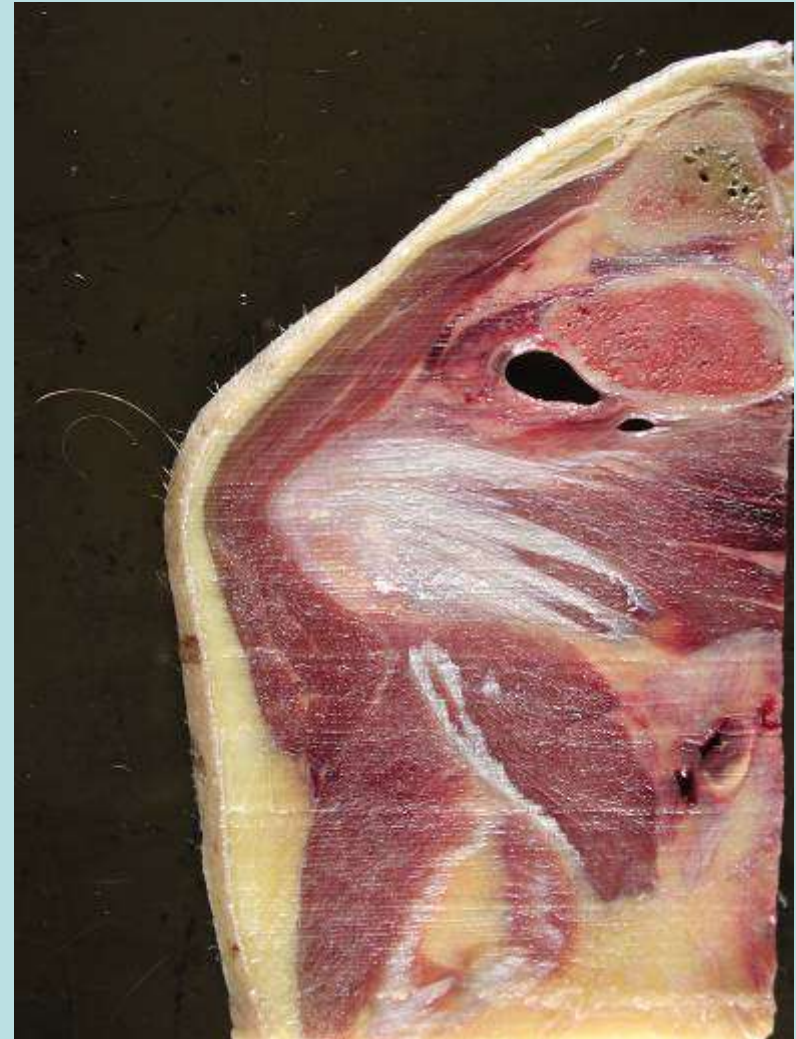**Teres minor denervation on routine
magnetic resonance imaging of the shoulder**

Skeletal Radiol (2004) 33:514-518
DOI 10.1007/s00256-004-0809-3

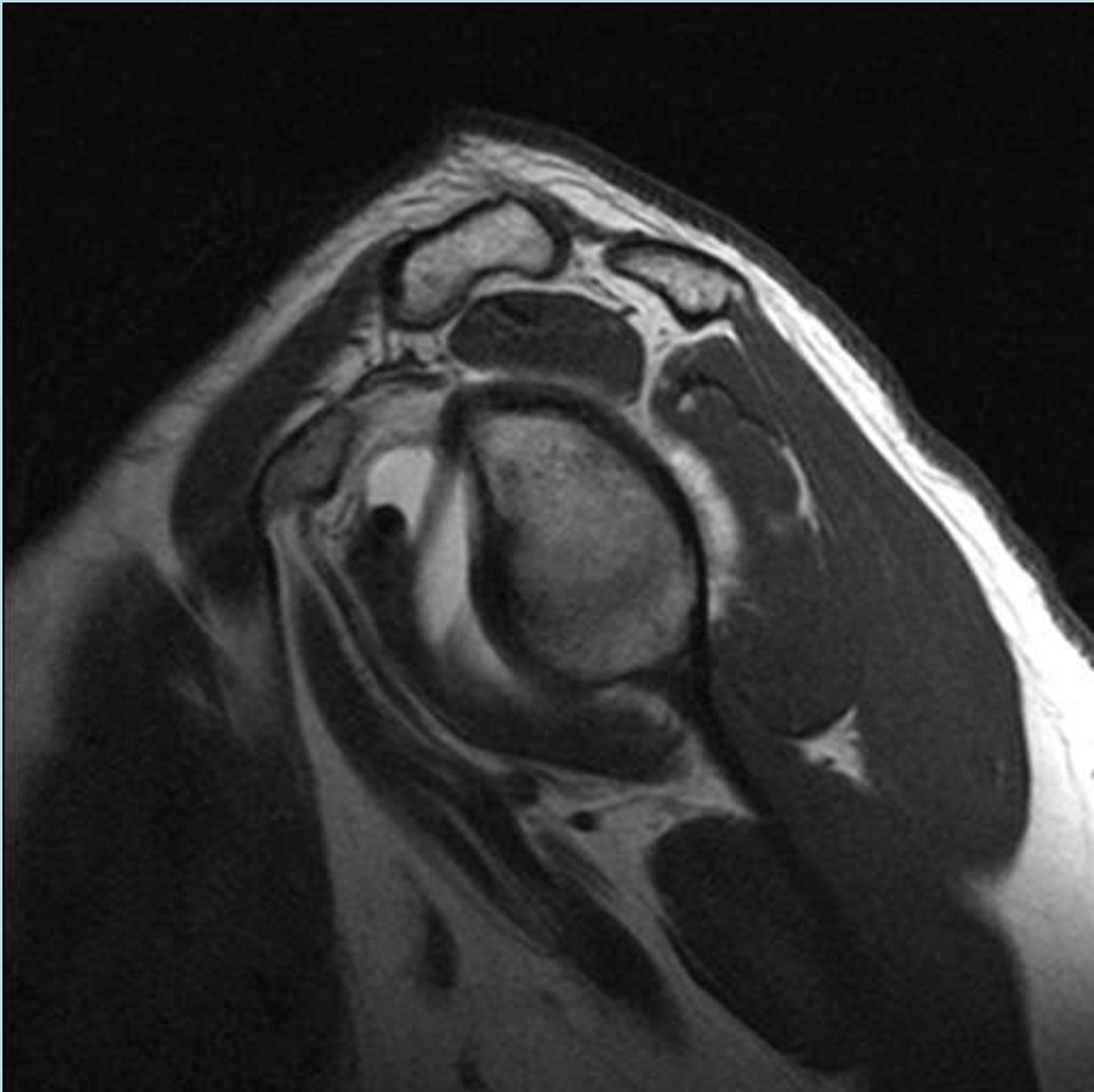
3% of Routine Shoulder
MRs

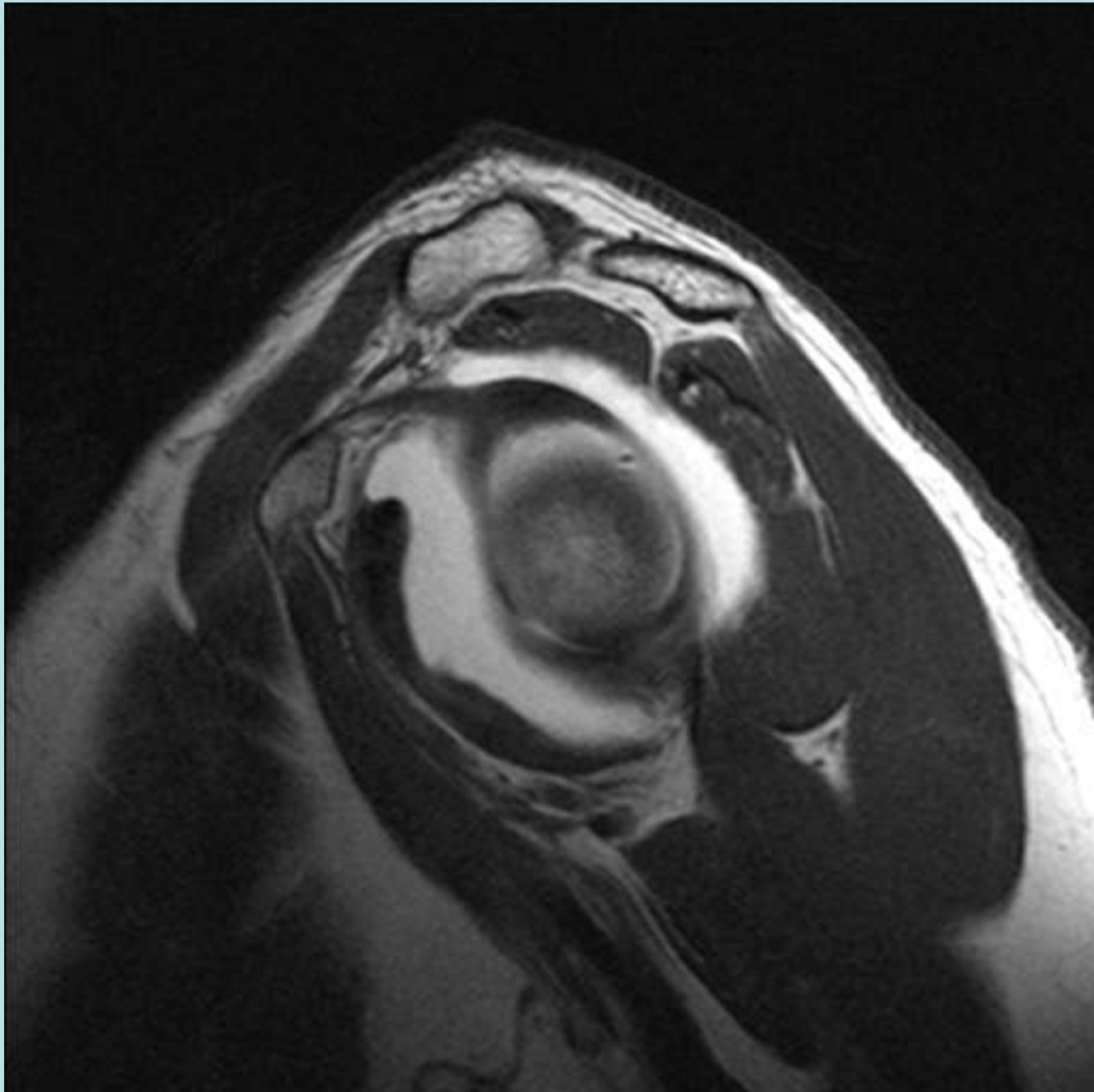
Subscapularis

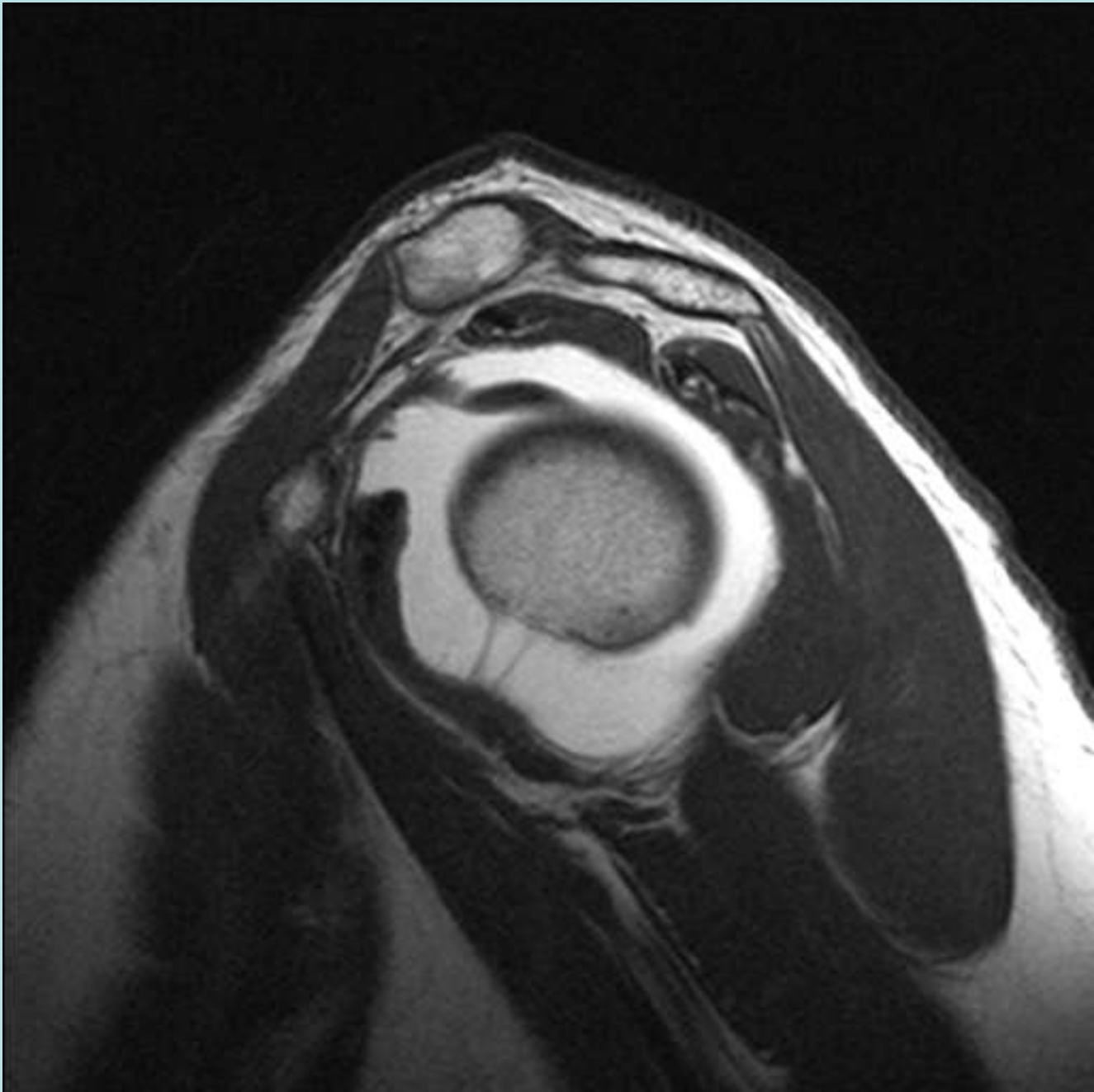
- Broad origin on the ventral surface of the scapula
- Multicircumpennate similar to infraspinatus
- Inserts on lesser tuberosity
- Contributes to “transverse humeral” ligament
- Inferior muscular portion that inserts near surgical neck of humerus

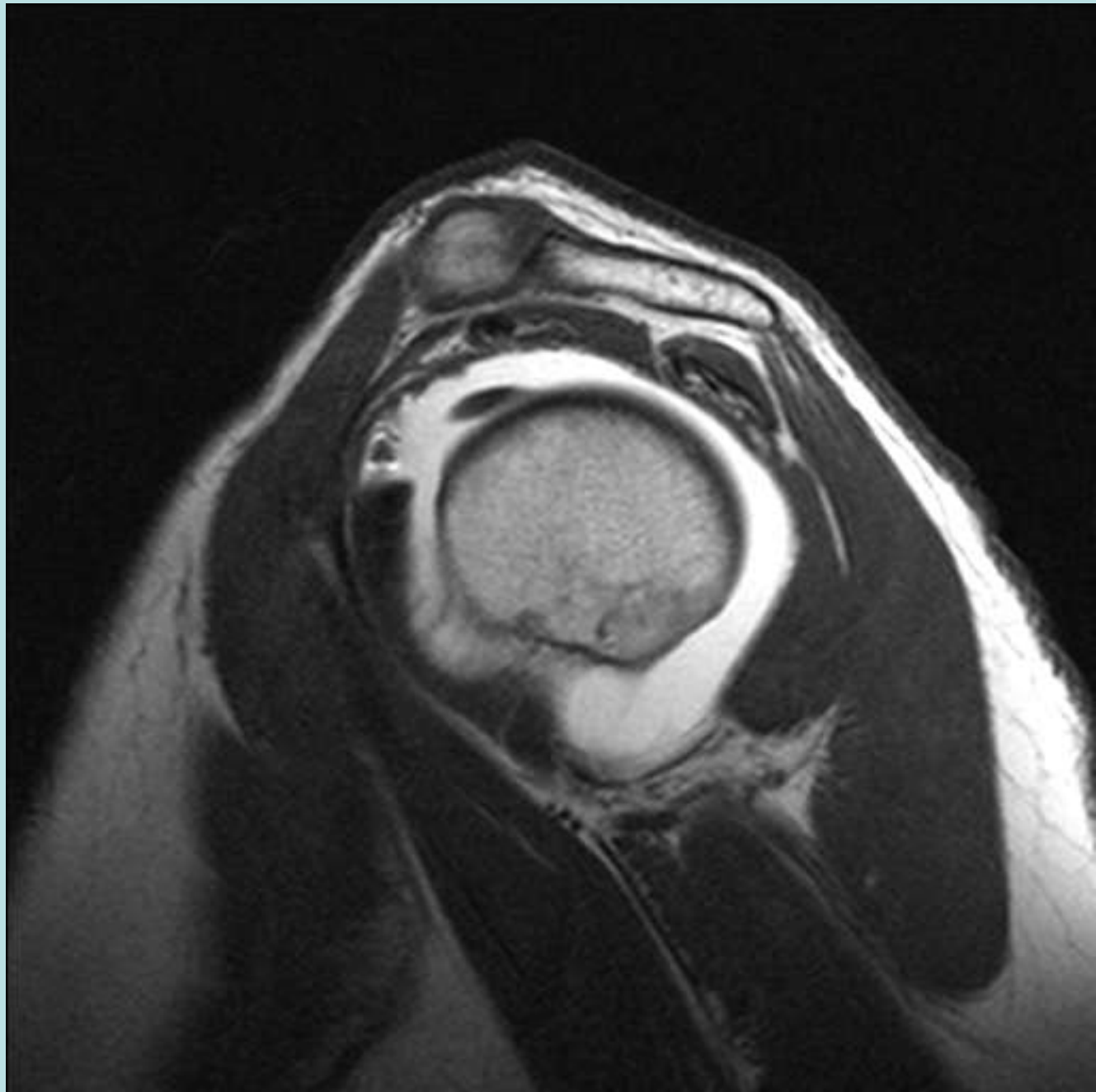


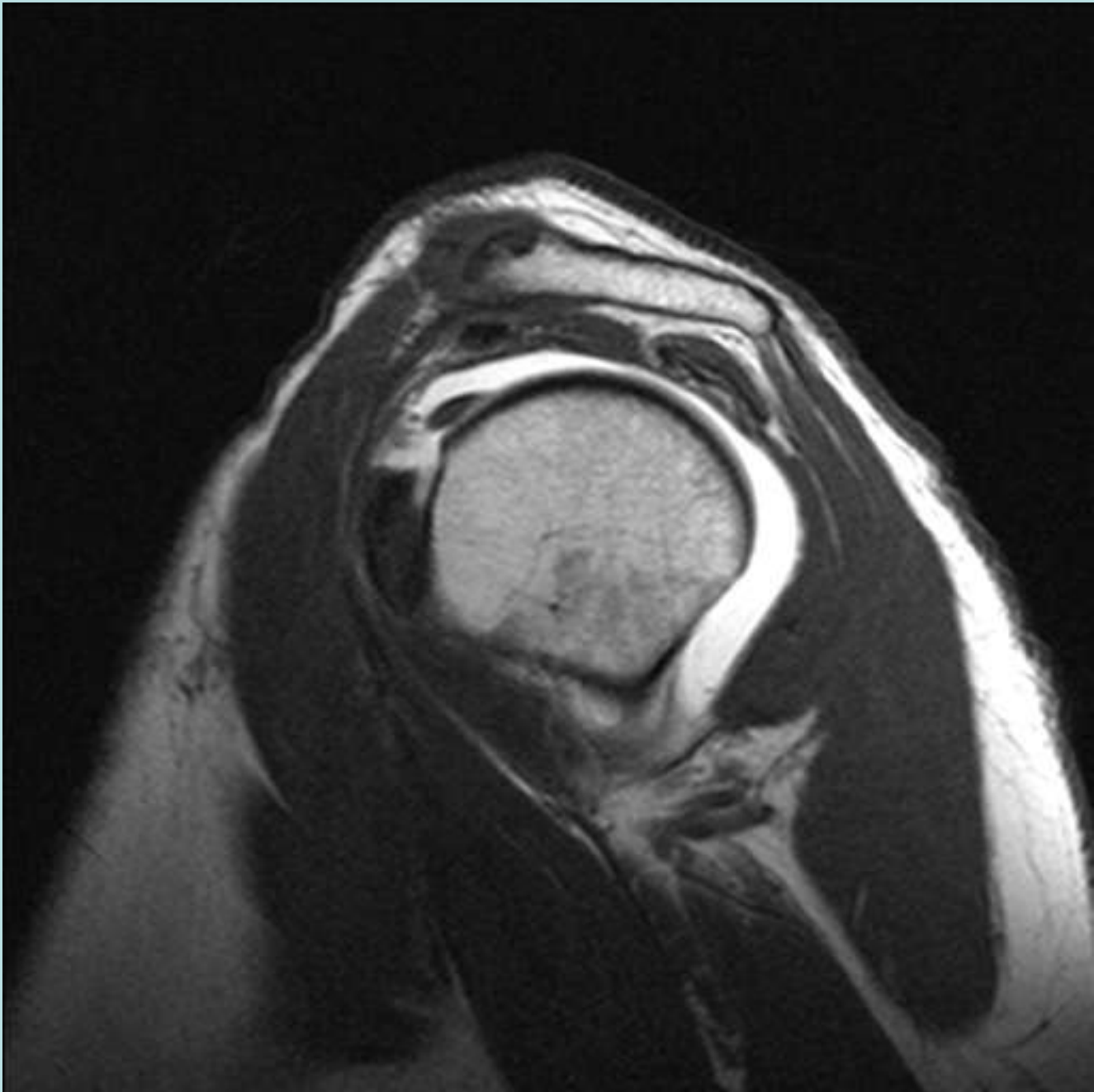
Subscapularis

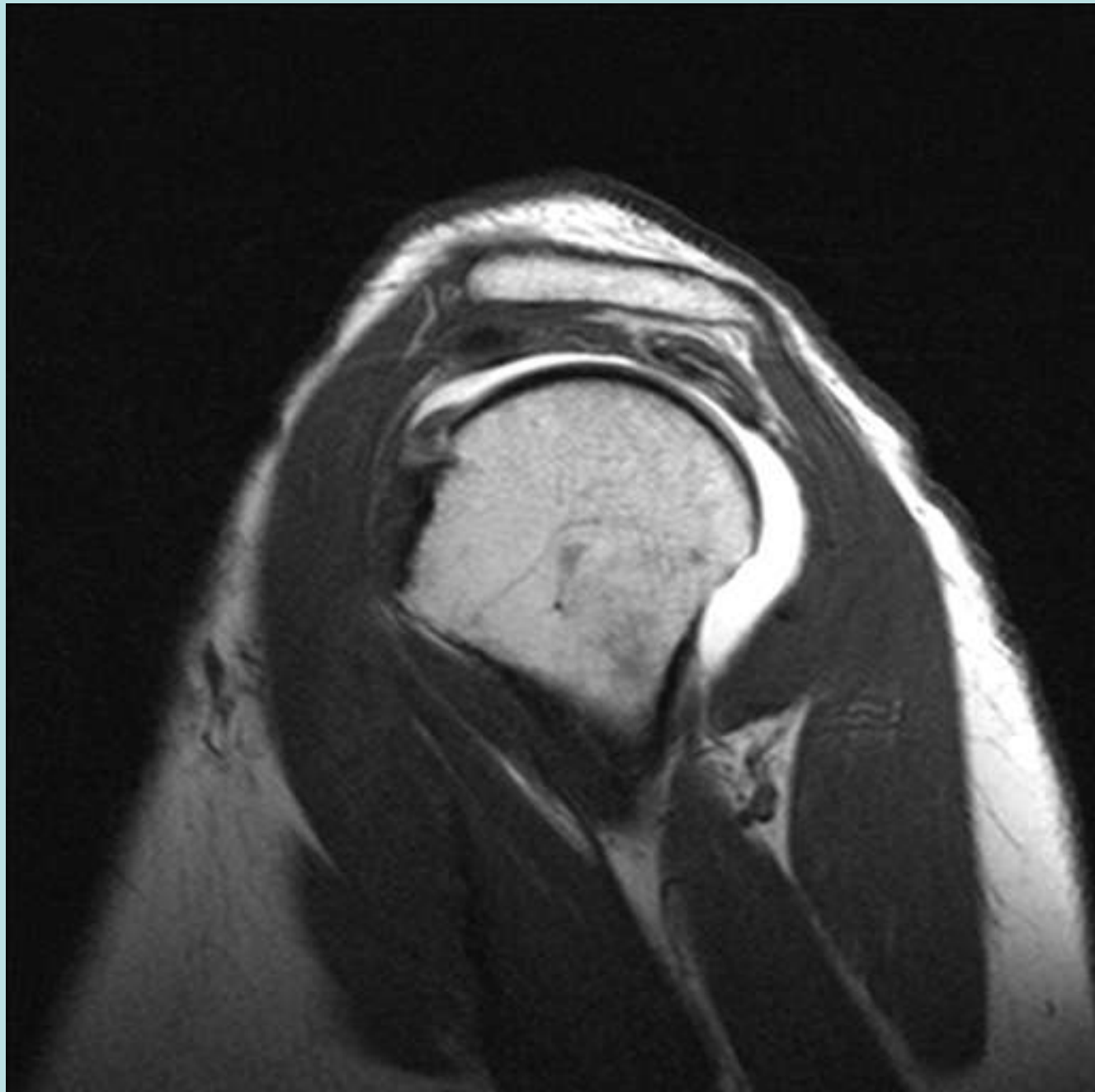


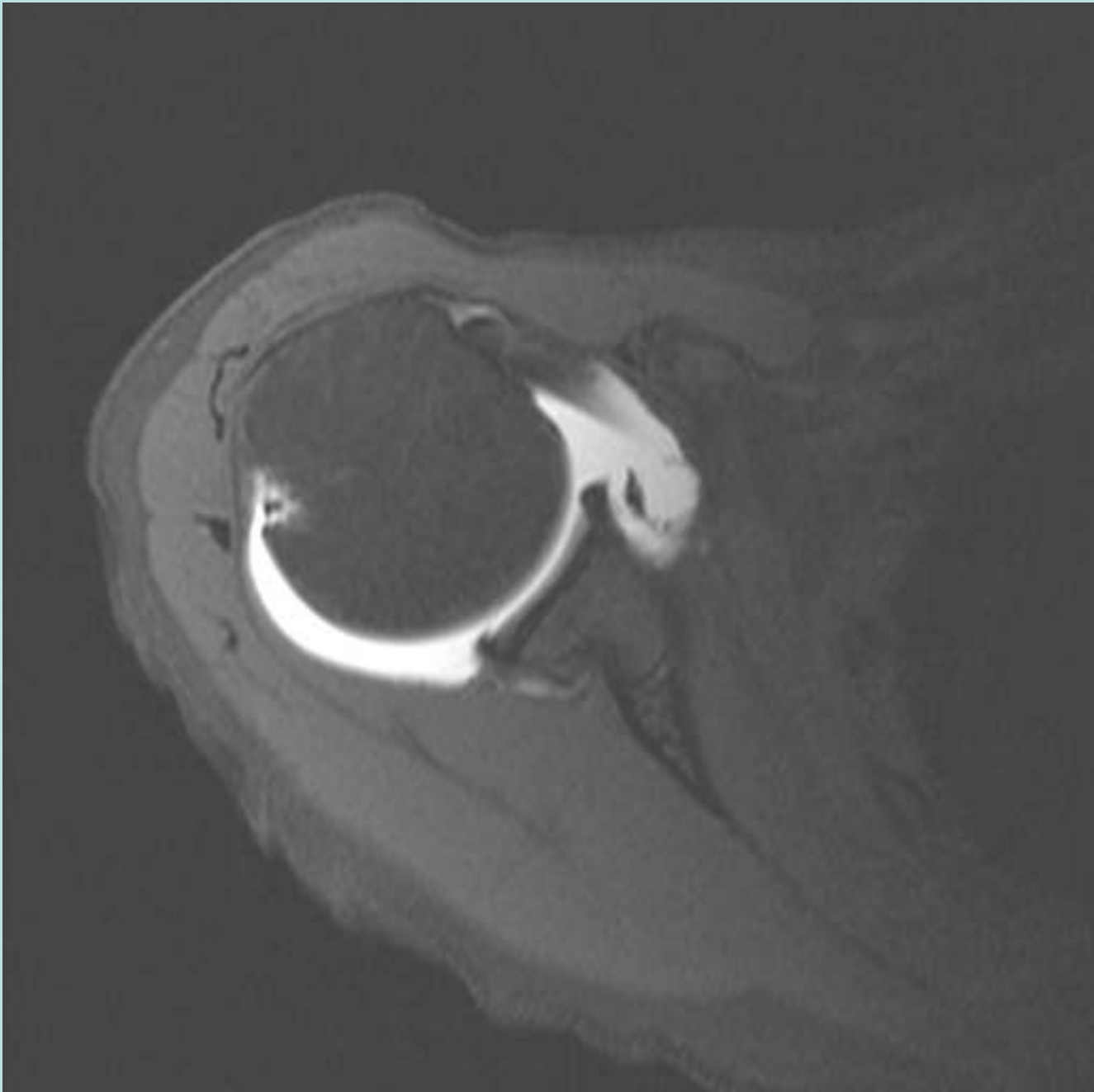


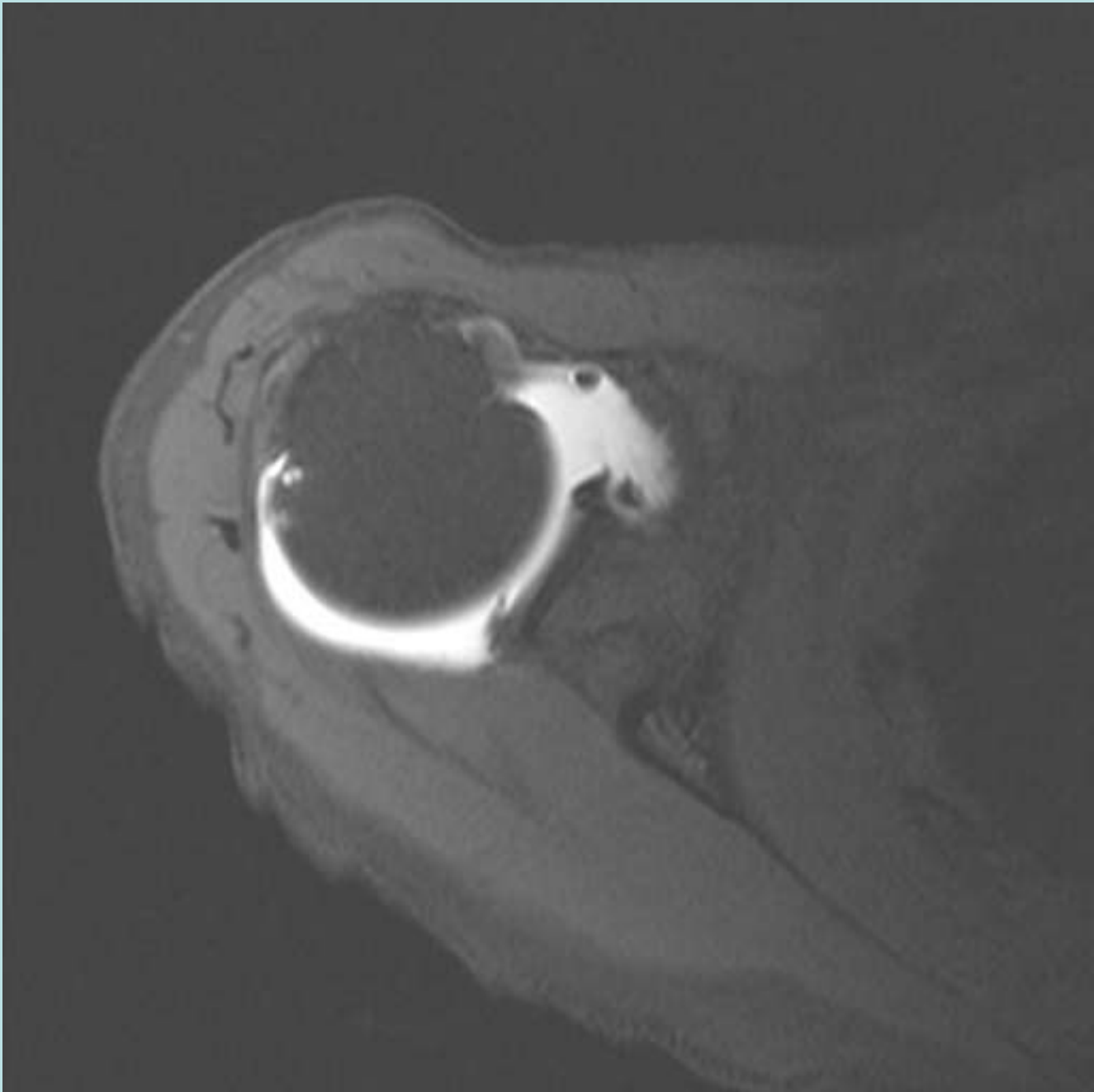


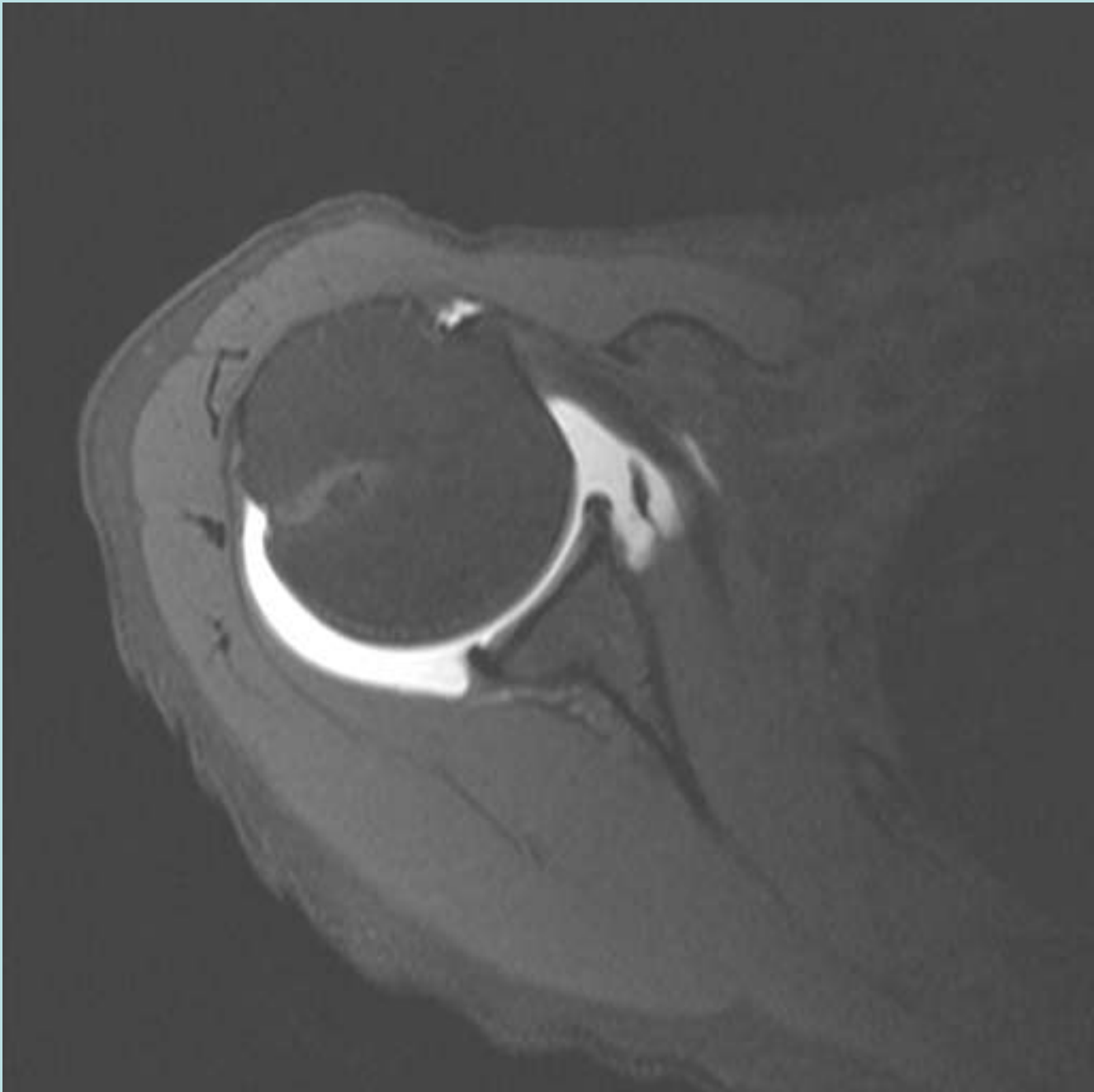


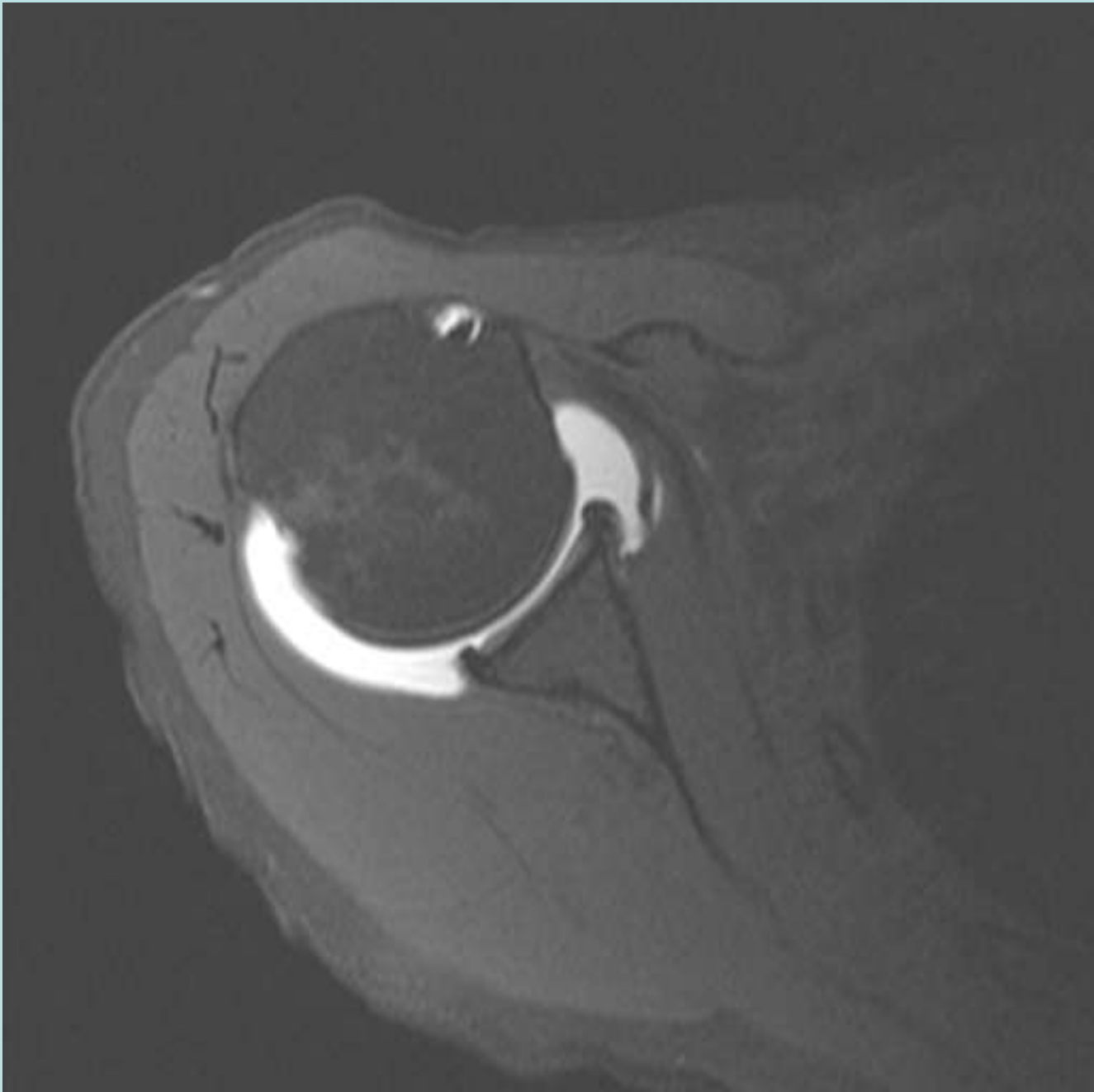


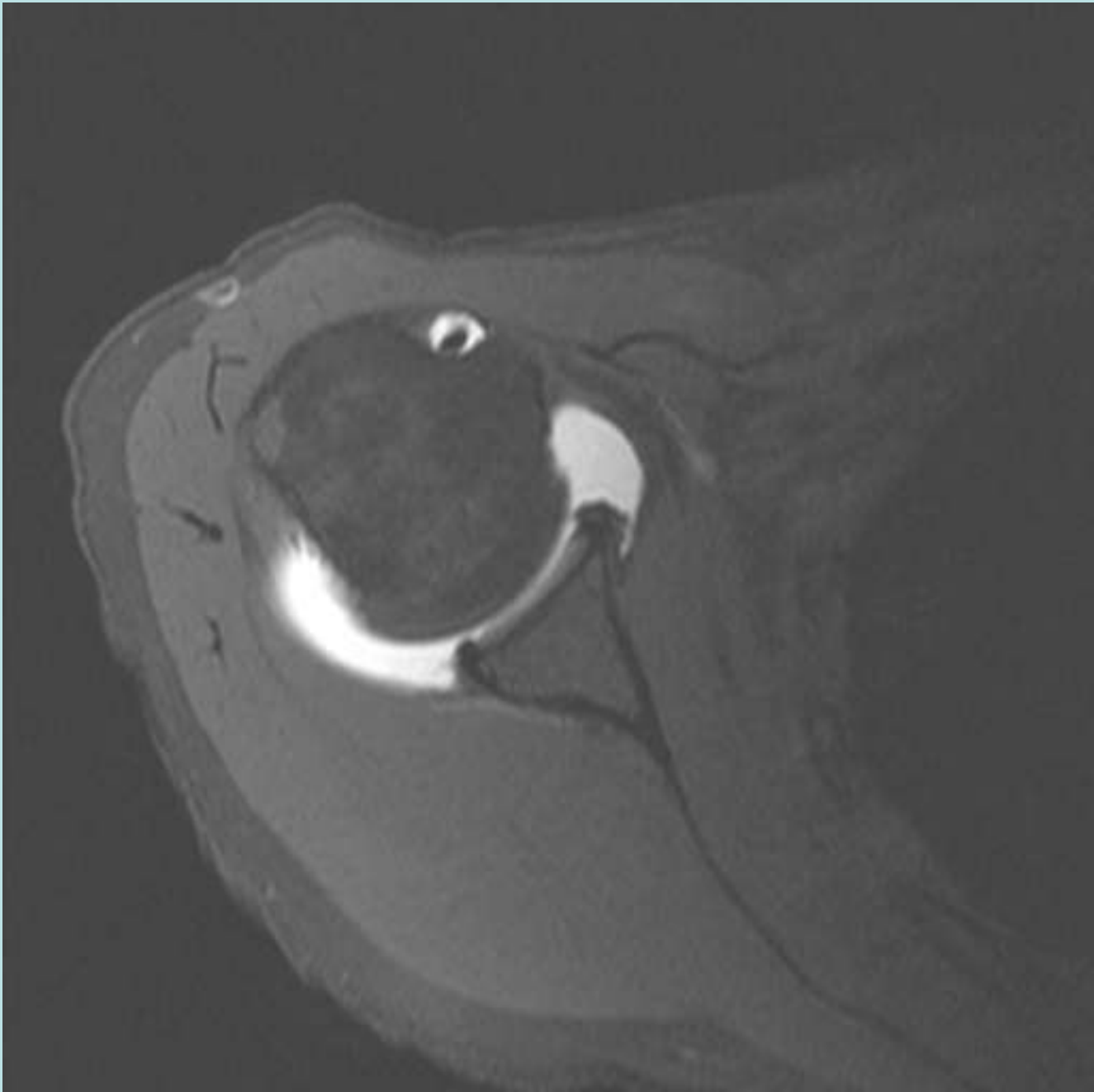


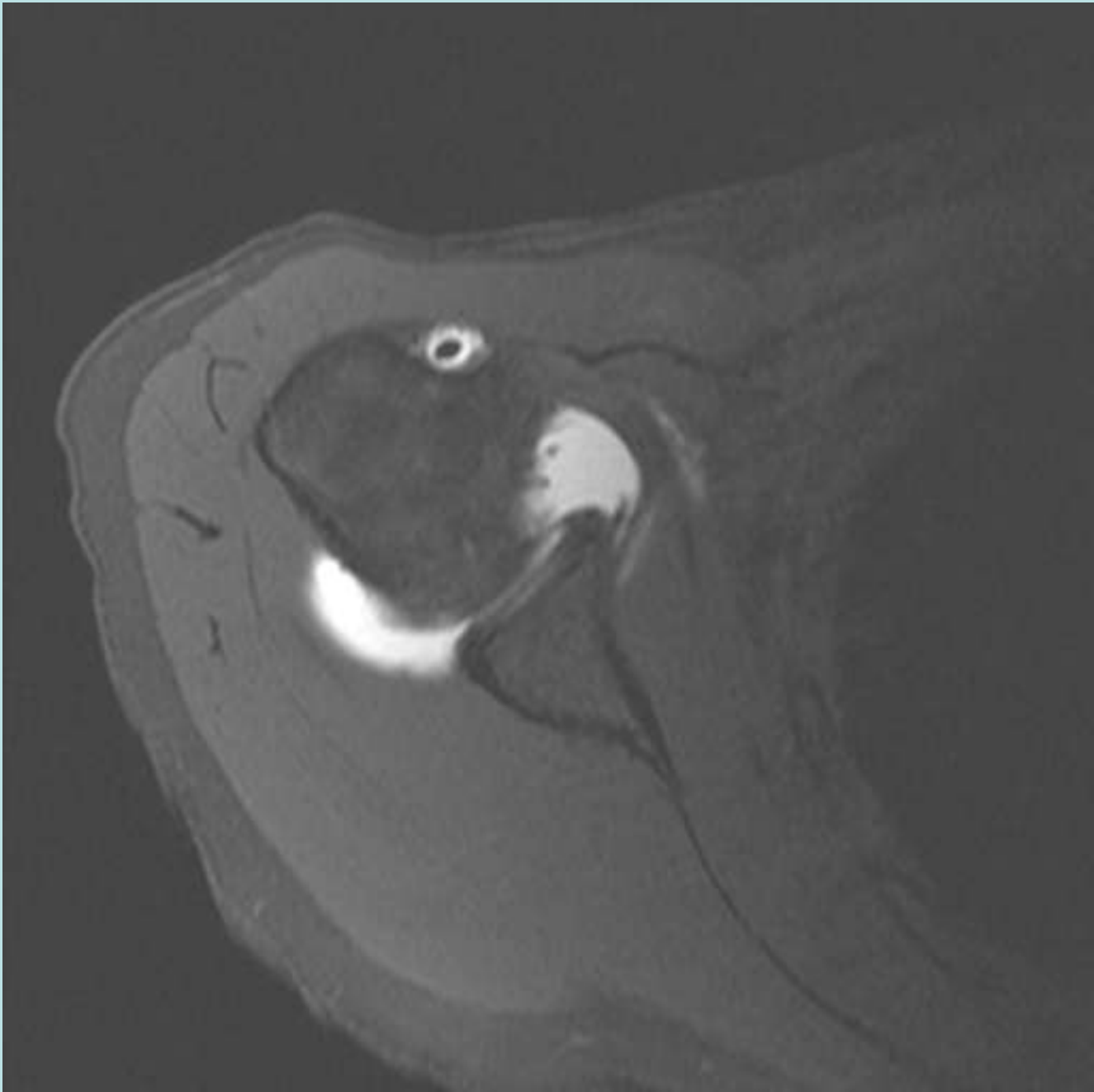


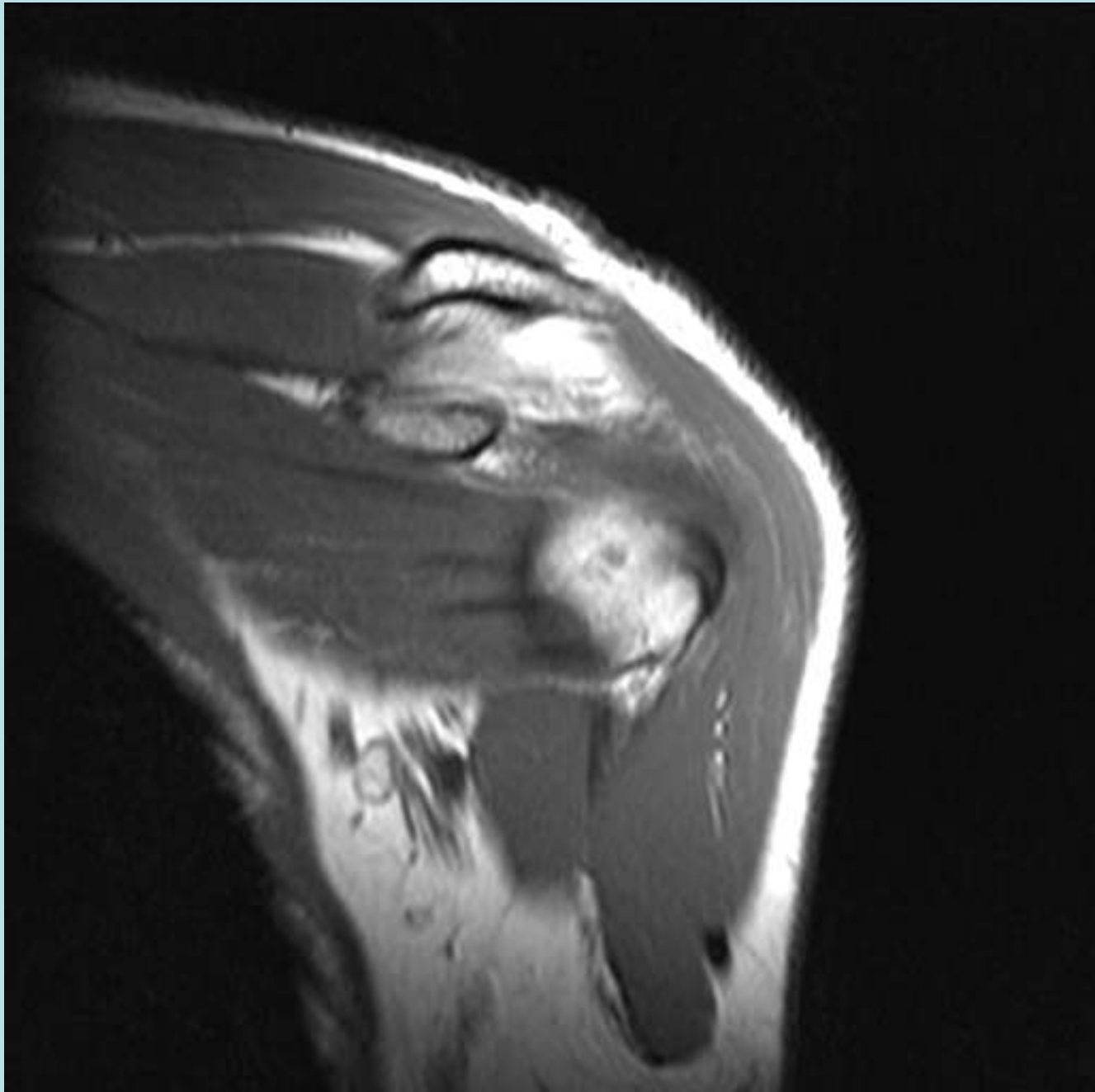


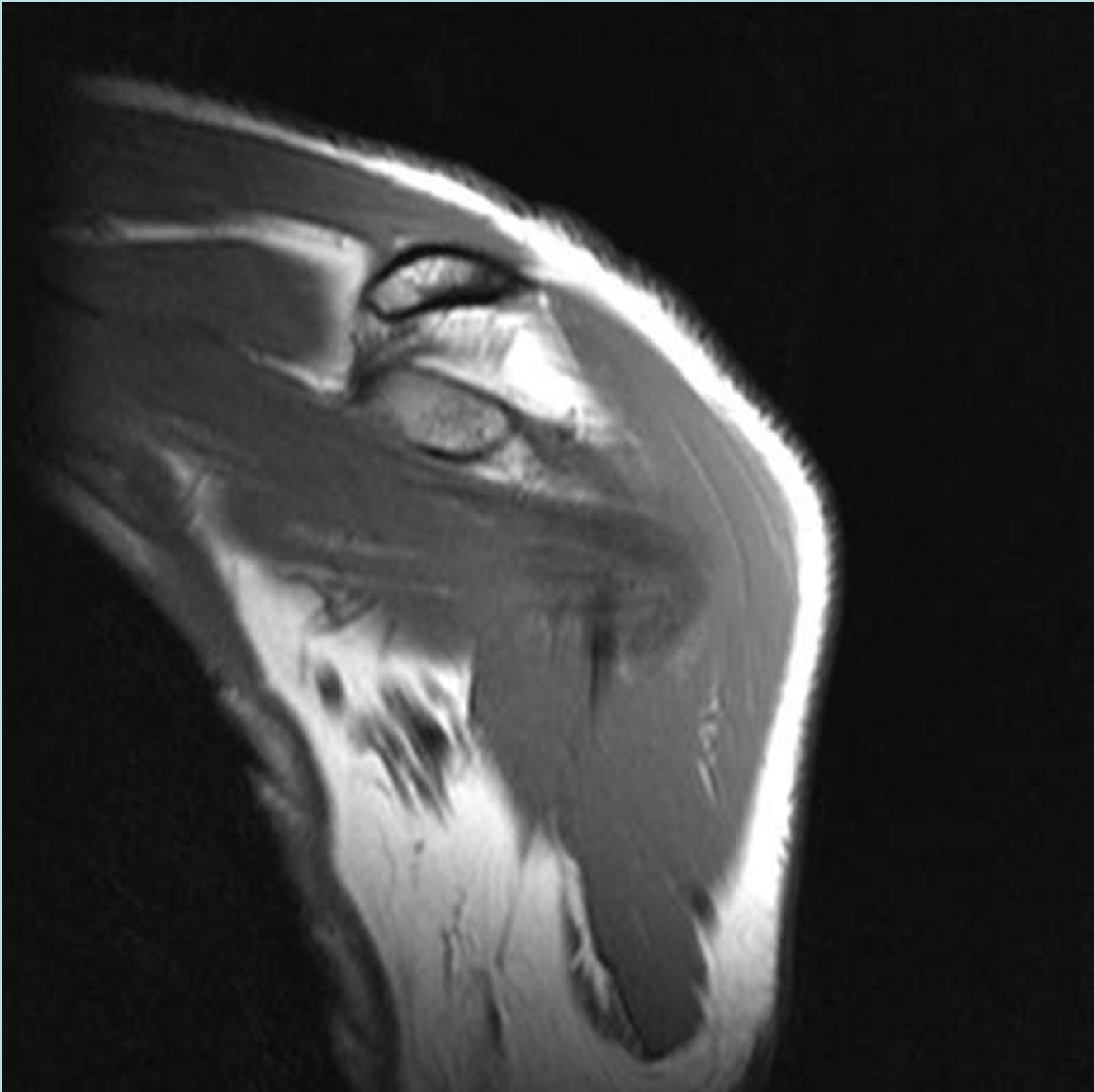




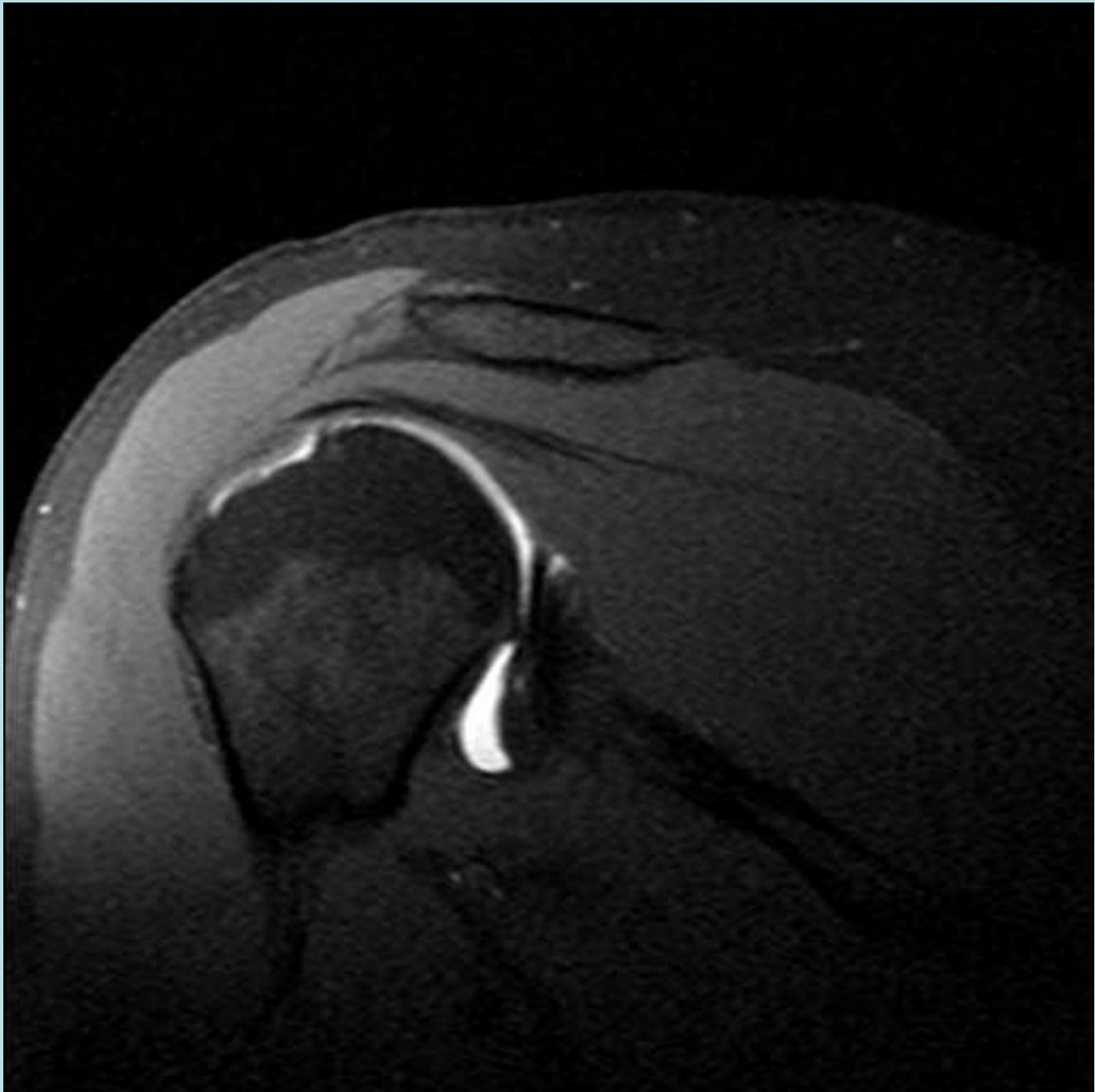


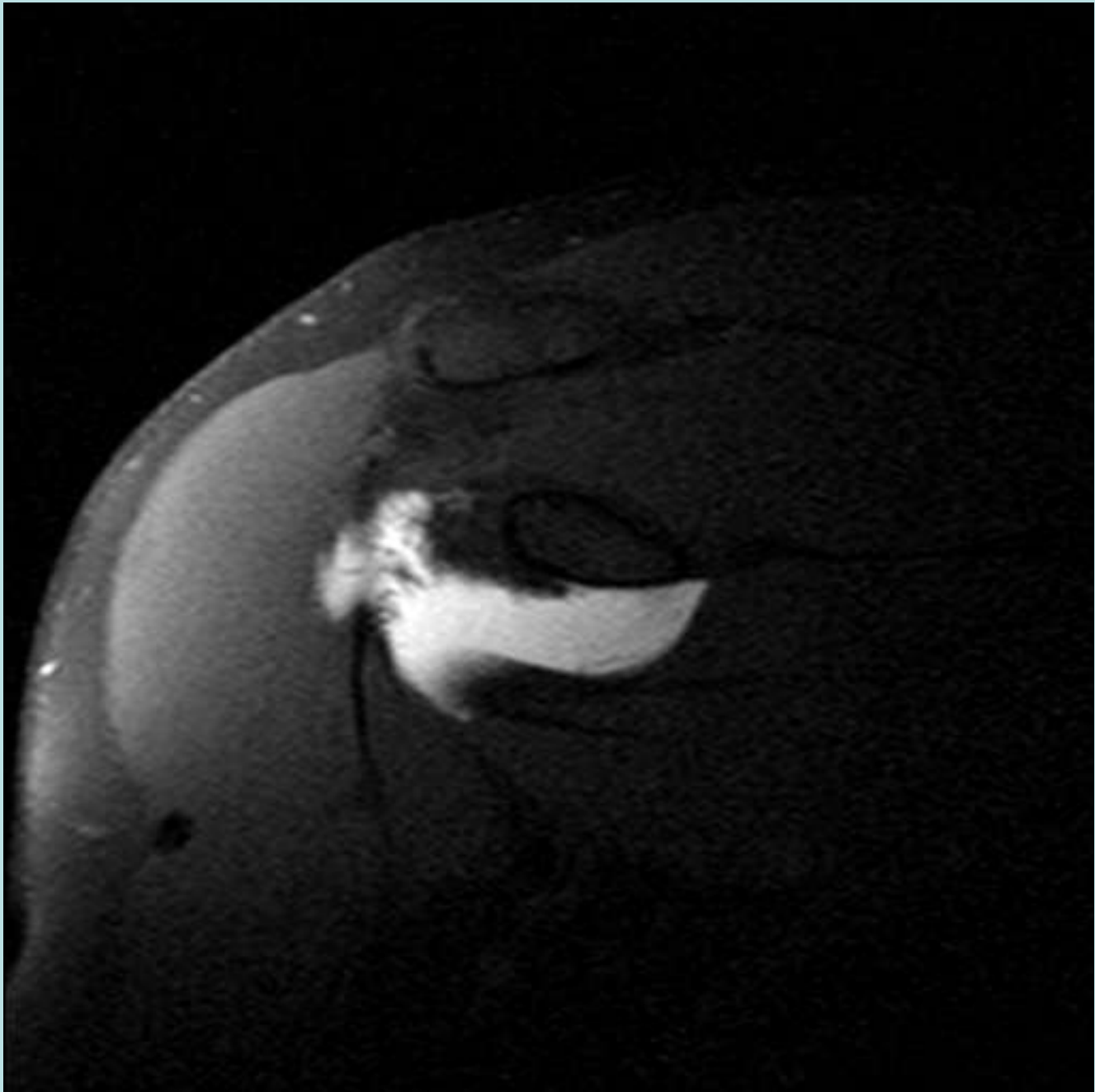


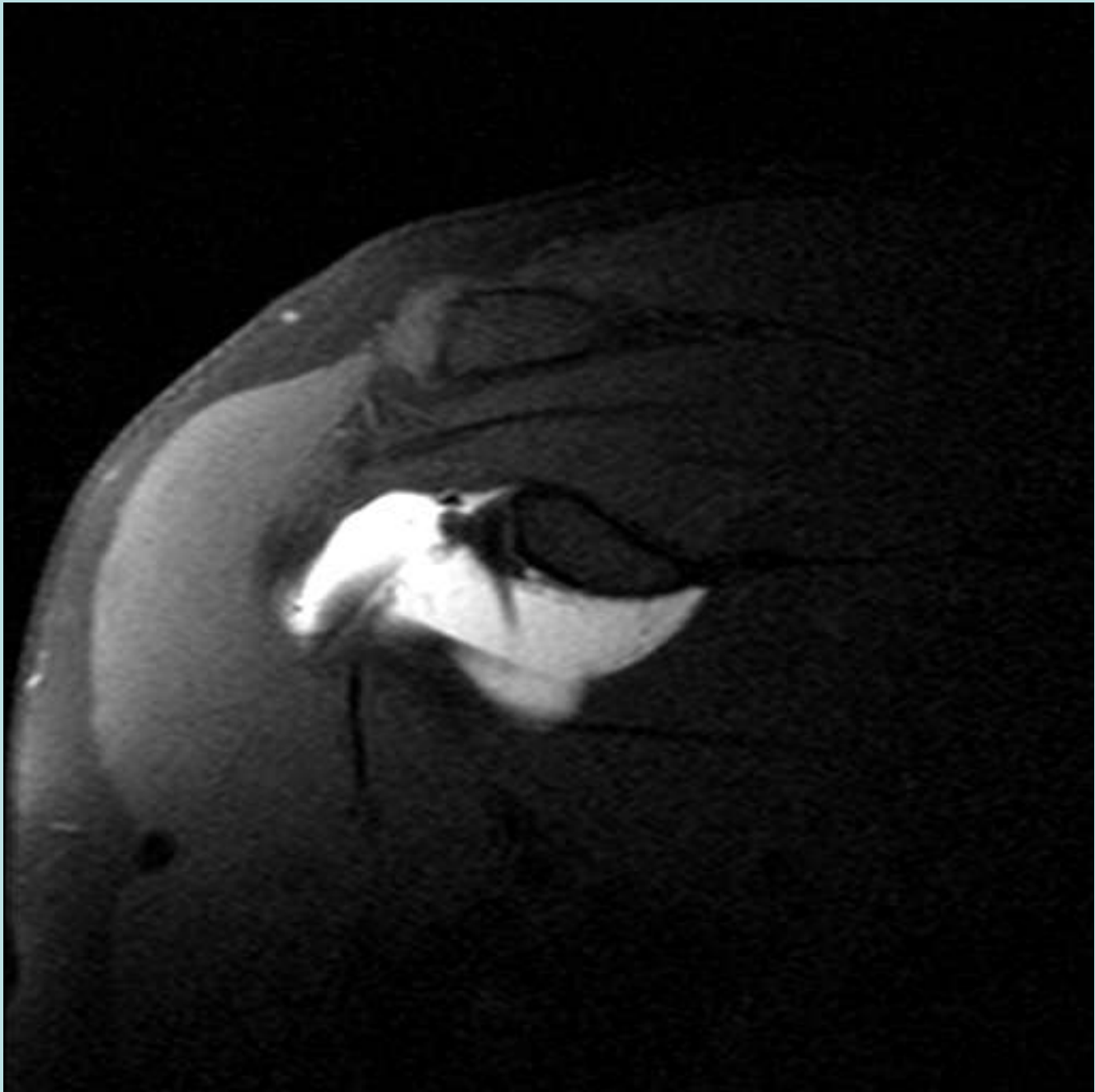


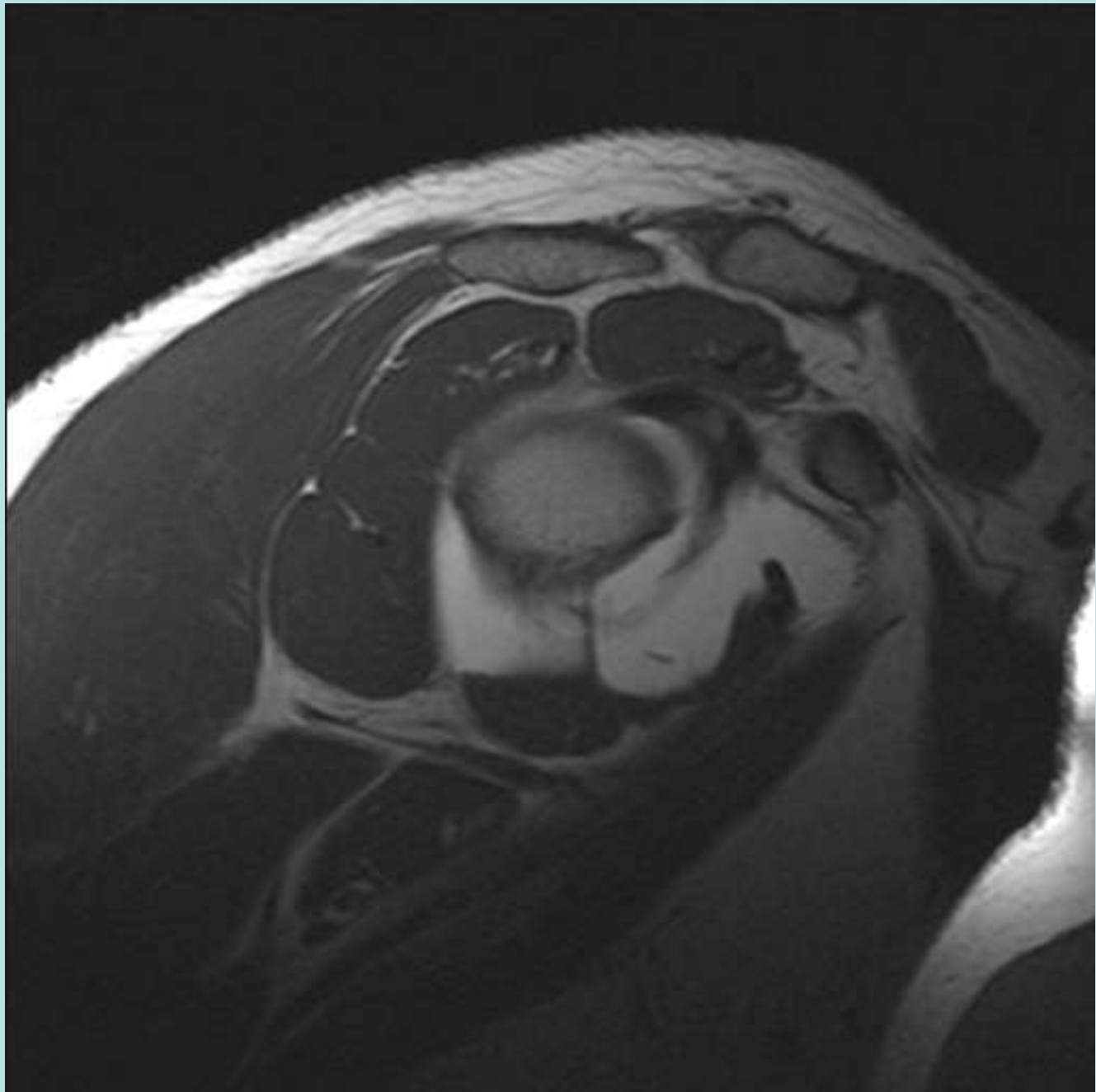


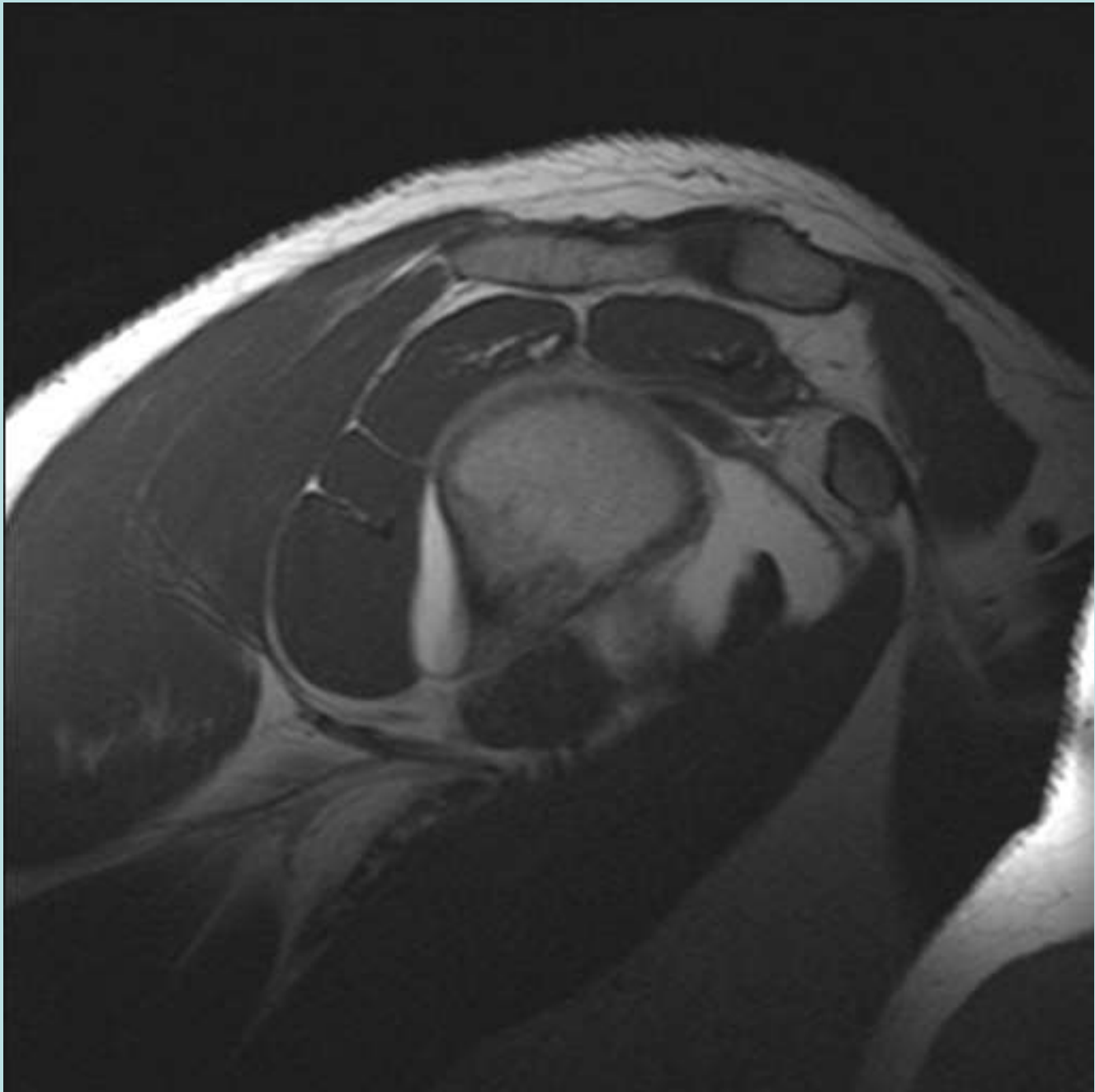
History of Dislocation



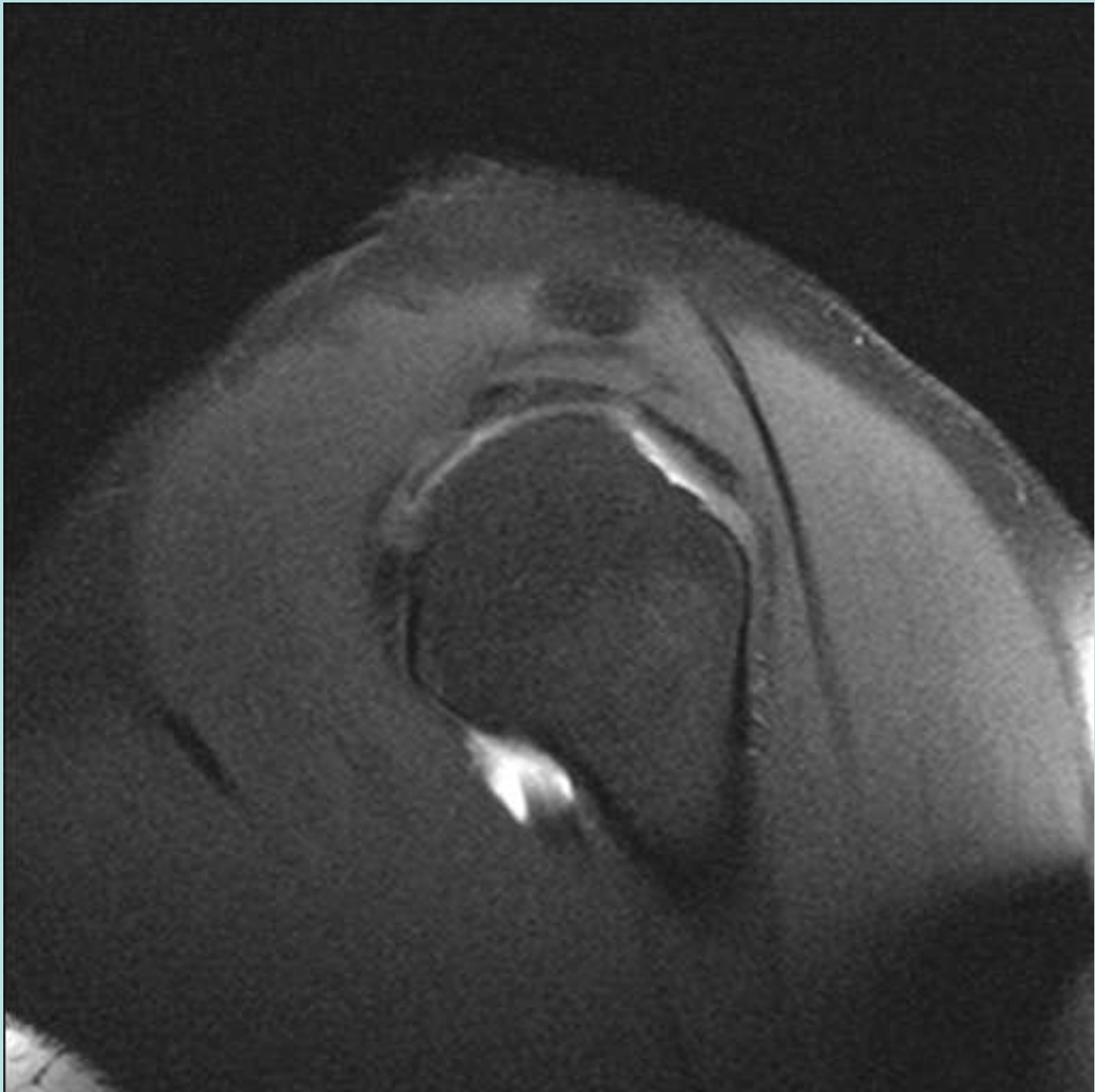


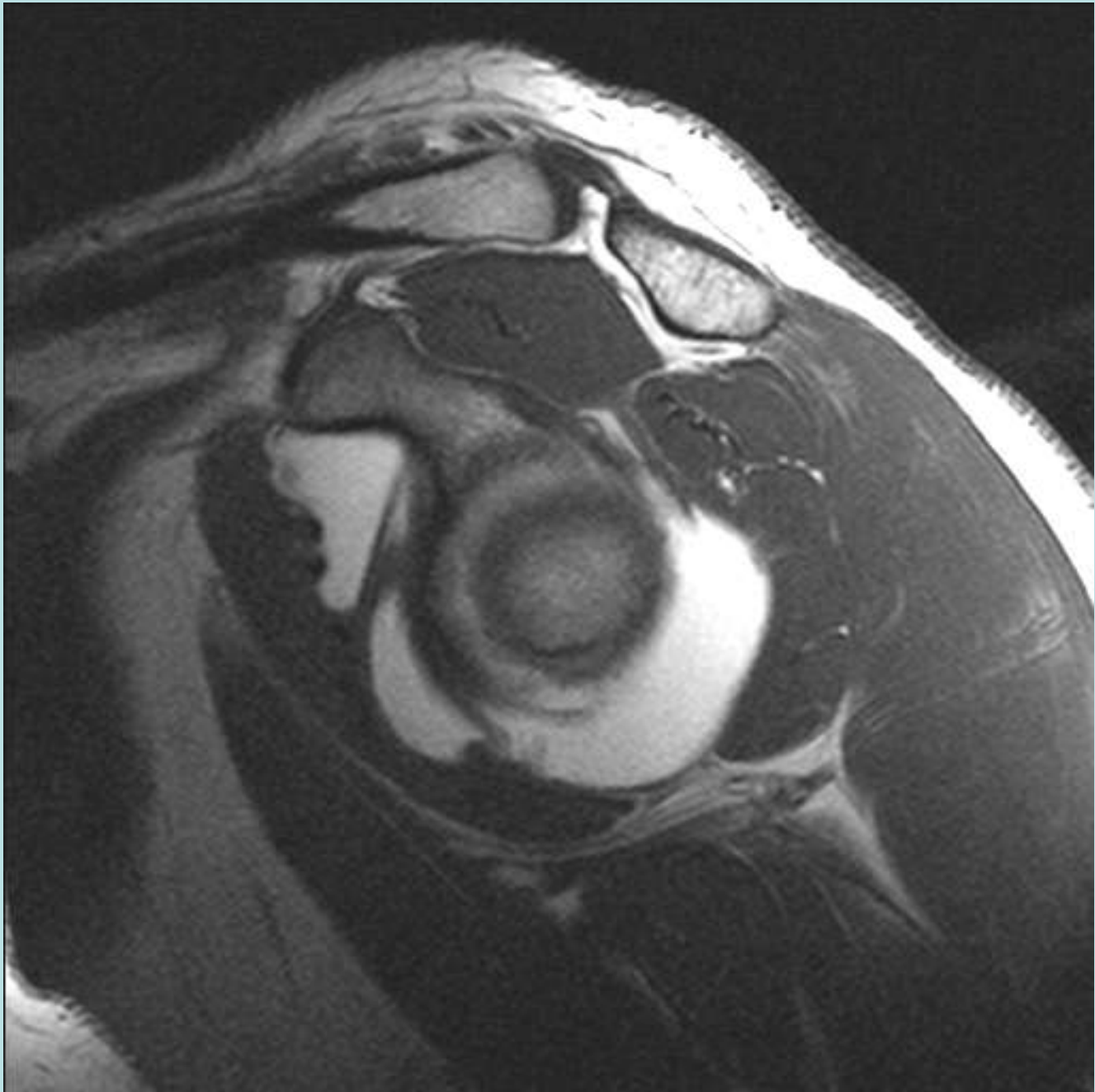


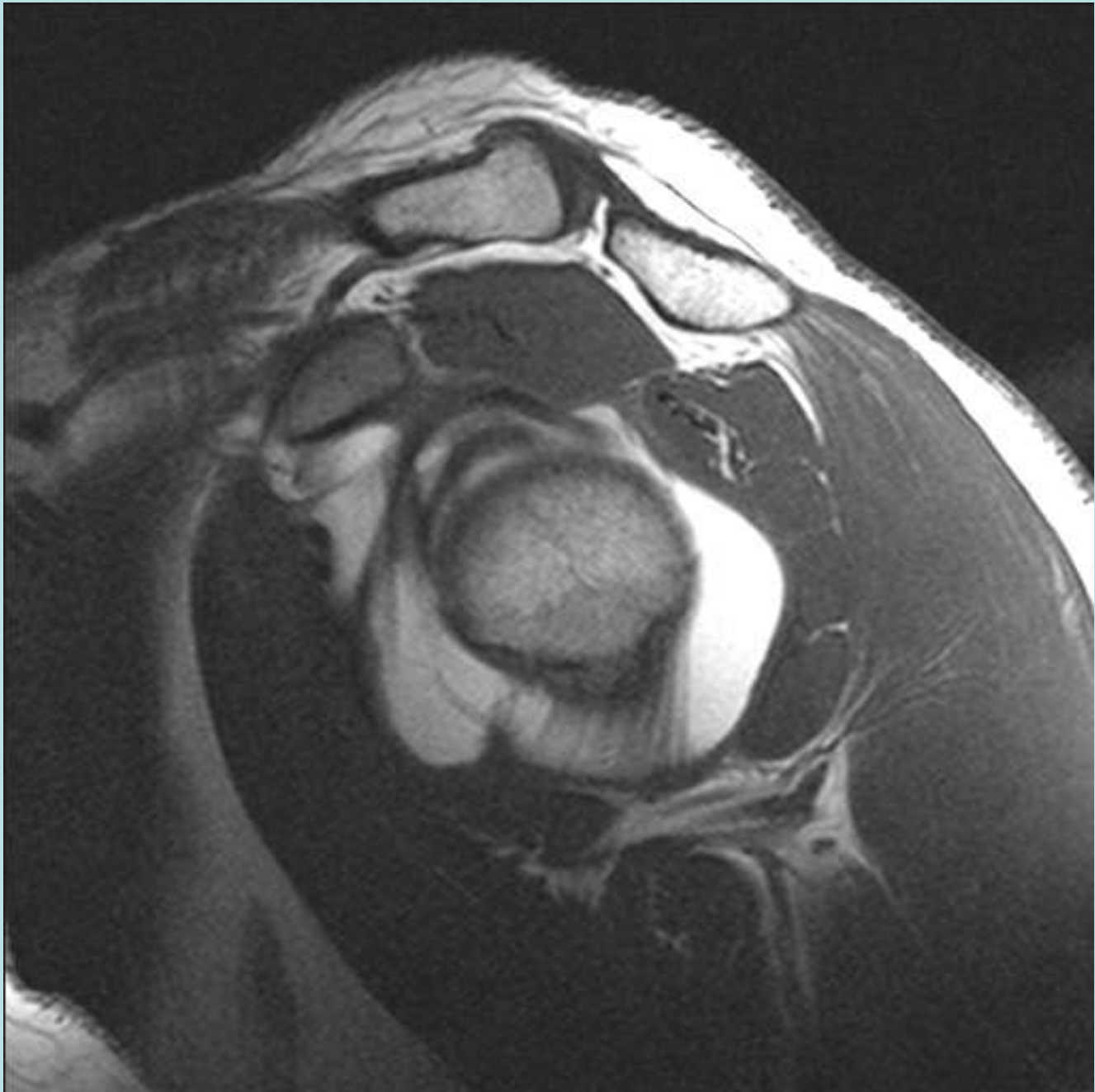


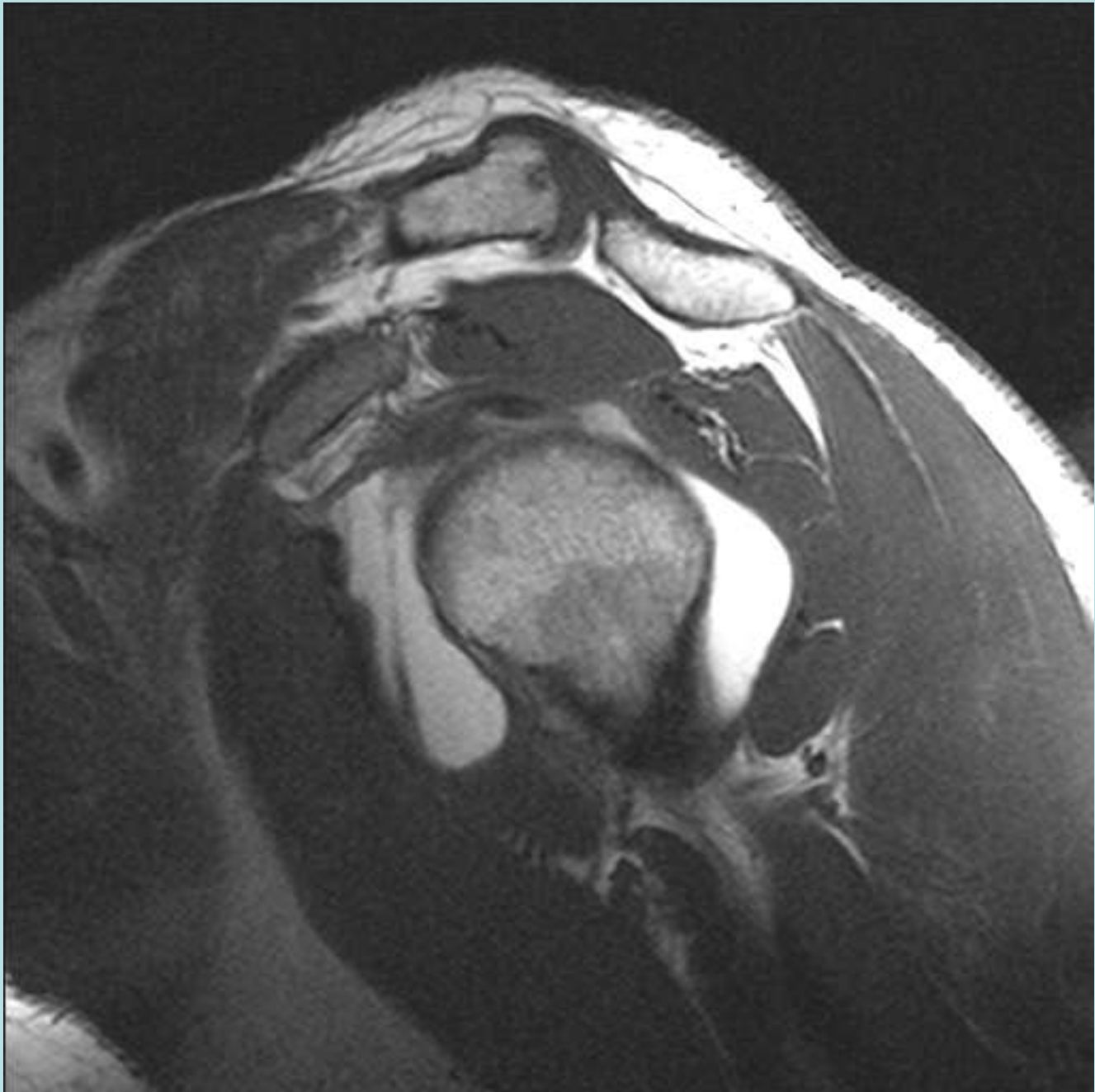


History of Dislocation





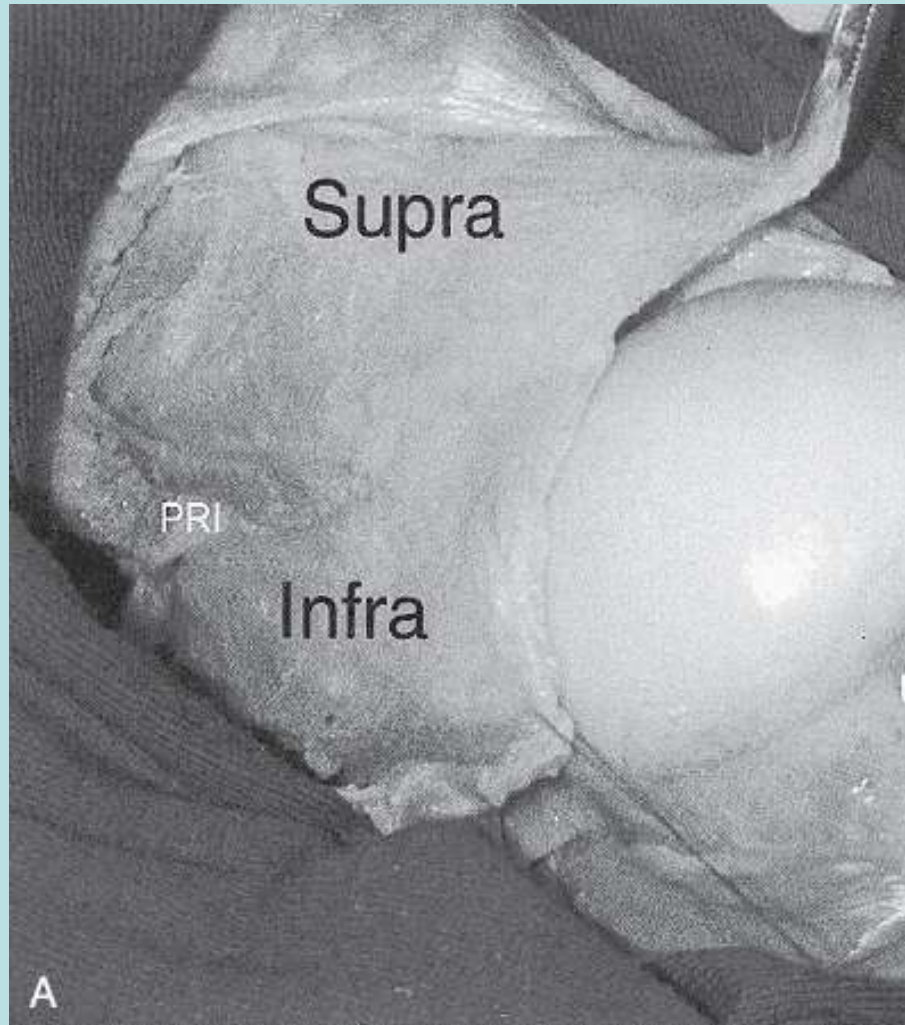




Rotator Interval(s)

- Anterior Rotator Interval Medial and Lateral Portions
- Medially-Fat, RI Capsule, CHL, SGHL
- Lateral Apex-more complex anatomy, above components plus fibers from Supraspin and Subscapularis
- Focal RI tears, Site of Fibrosis in Adhesive Capsulitis

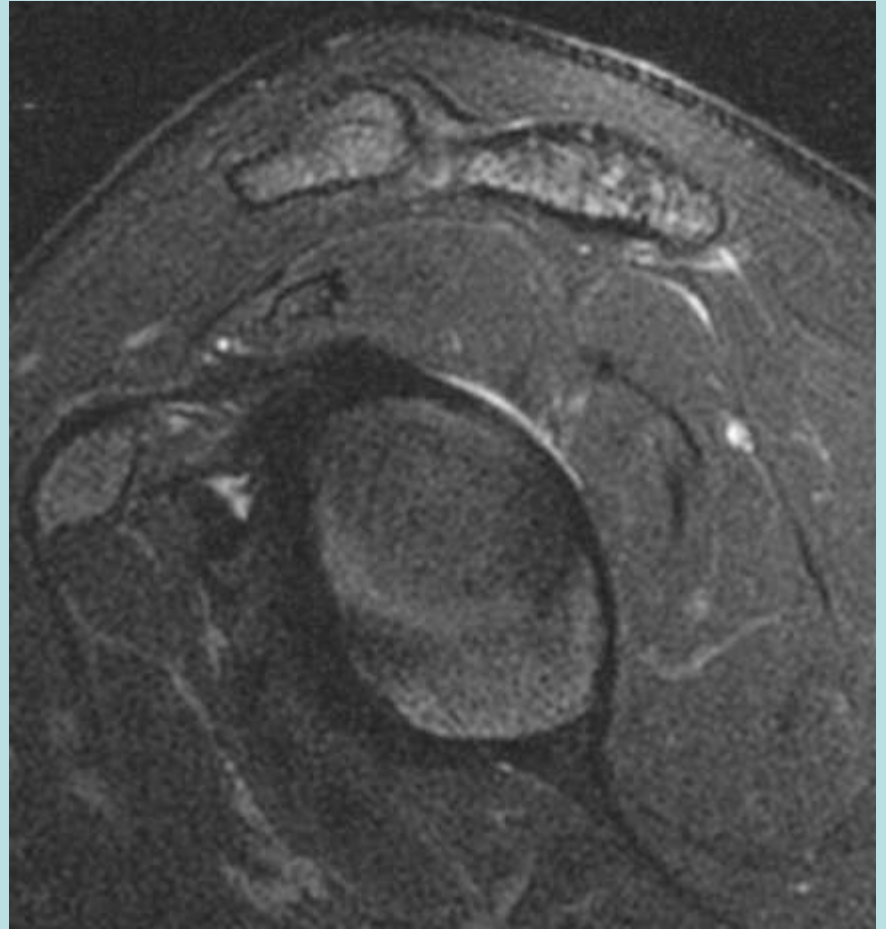
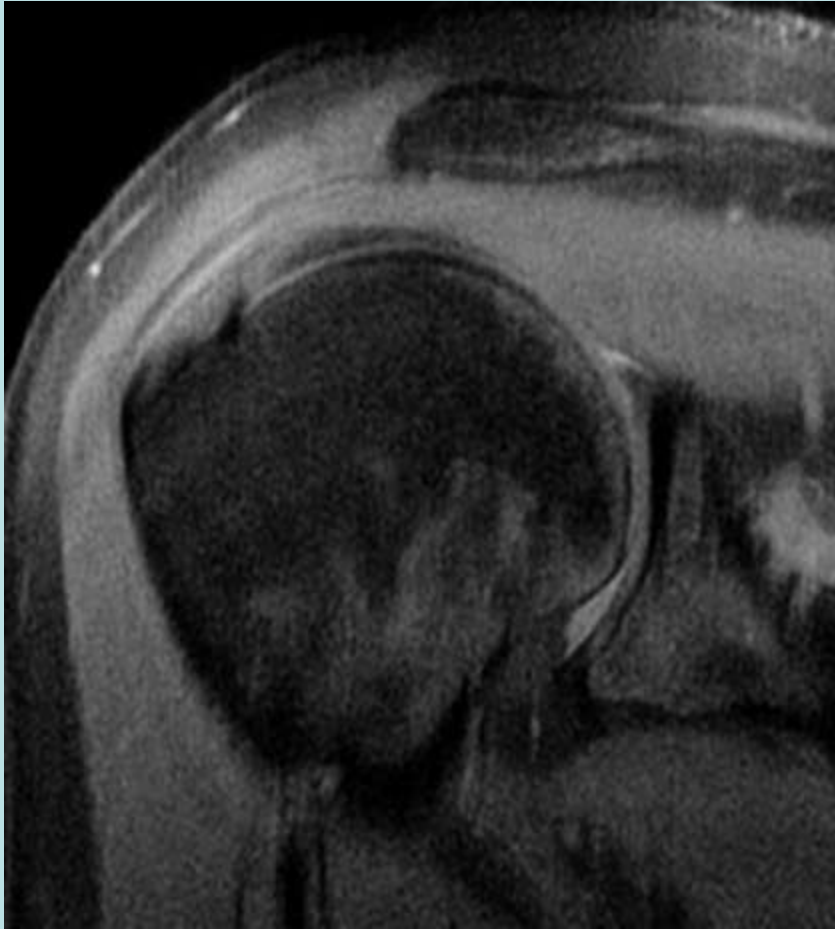
Posterior Rotator Interval



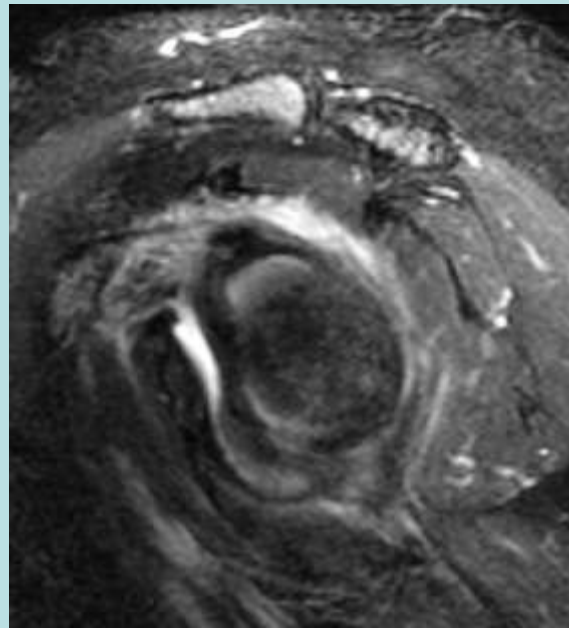
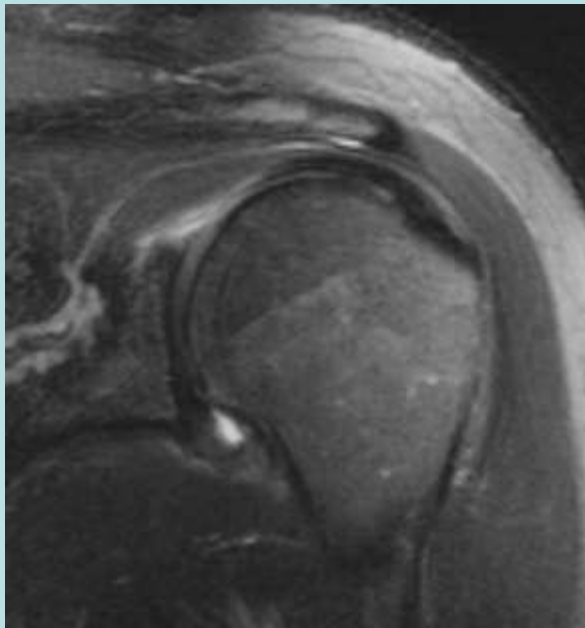
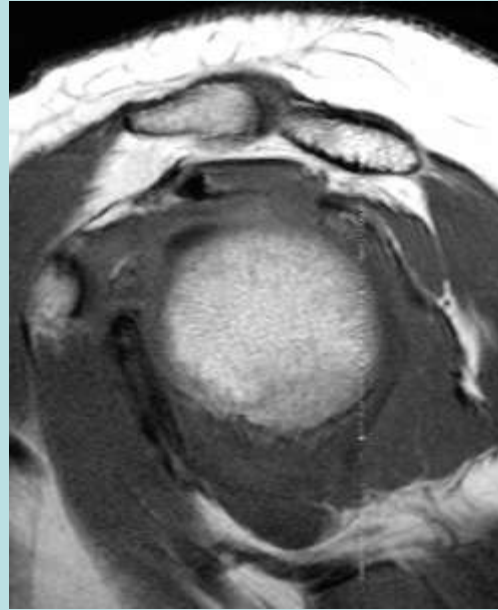
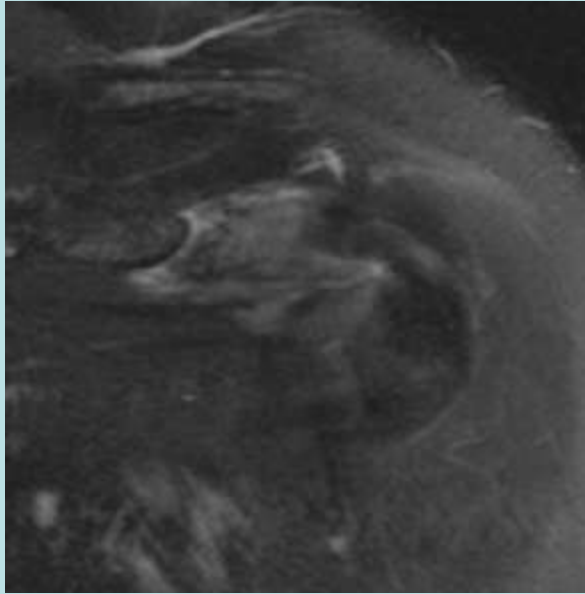
Anatomy of the Posterior Rotator Interval:
Implications for Cuff Mobilization. Miller et al.

CLINICAL ORTHOPAEDICS AND RELATED RESEARCH
Number 408, pp. 152–156
© 2003 Lippincott Williams & Wilkins, Inc.

PRI Normal



PRI Abnormal



Posterior Rotator Interval Findings

- Site for Arthroscopic Port Placement
- Normal Joint Recess
- Potential Space for Perilabral Cysts
- Adhesive Capsulitis
- Vessels

Biceps Pulley Impingement

25 y/o surfer with pain during
paddling and findings of bicipital
tendonitis on physical exam

