

Nerve Anatomy and Entrapment Neuropathies of the Lower Extremity

Andrew N. Knoll, MD

February 11, 2010



UNIVERSITY *of* CALIFORNIA, SAN DIEGO

MEDICAL CENTER

Objectives

- Review the imaging anatomy of the major nerves of the lower extremity with emphasis on anatomic landmarks
- Highlight some of the clinically important sites of nerve pathology and their associated clinical syndromes

Entrapment Neuropathy

- Peripheral nerves vulnerable to compression at specific sites, usually fibro-osseous tunnels or openings in muscle/fascia
- Most can be diagnosed clinically
- General MR features
 - Identification of site of compression and causative lesions
 - Detection of morphologic alterations of affected nerves (size, signal intensity)
 - Secondary effects (muscle edema/atrophy)

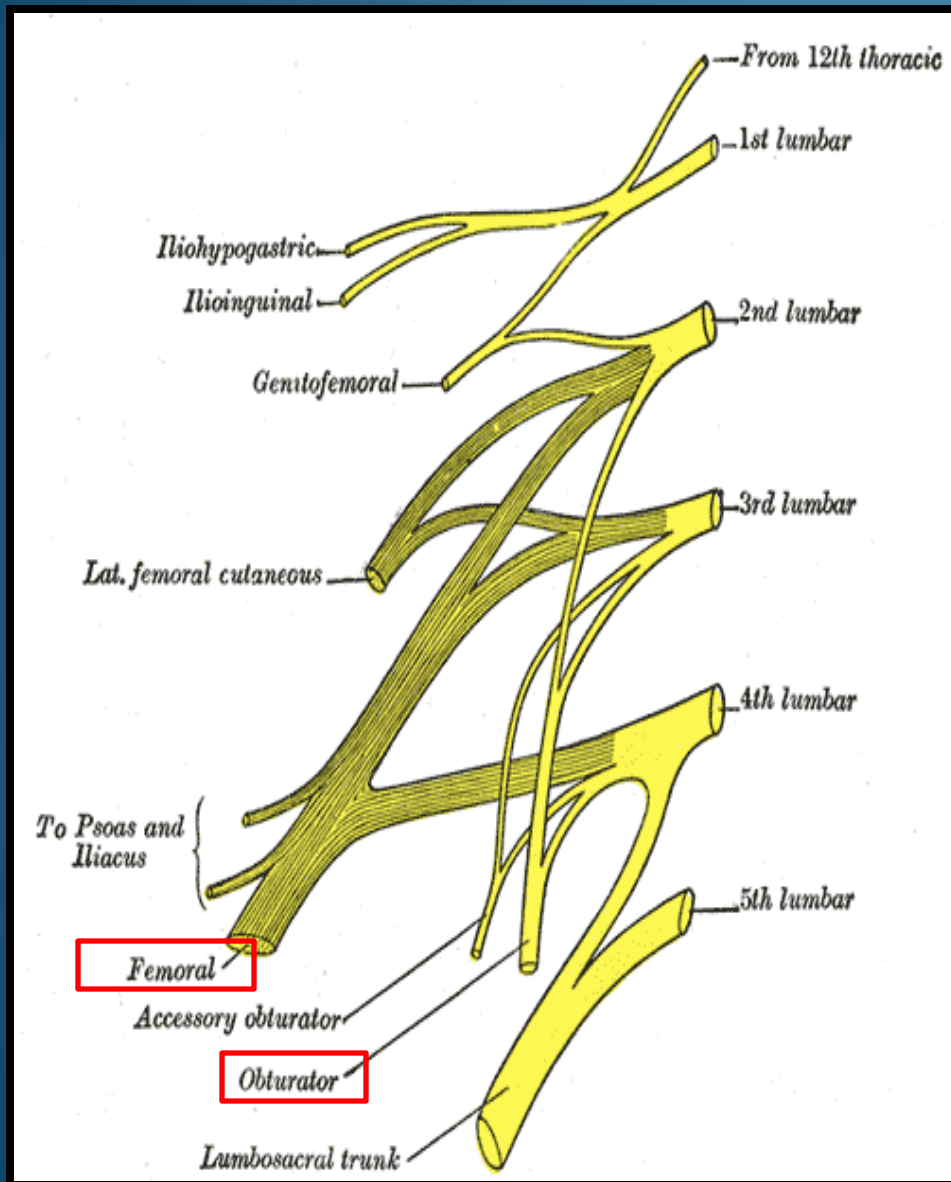
Entrapment Neuropathy

- *Double crush phenomenon*
 - Single nerve may be compressed at two separate sites, with proximal compression rendering the distal nerve more vulnerable to compression neuropathy
 - *ie* association between cervical disc disease and carpal tunnel syndrome

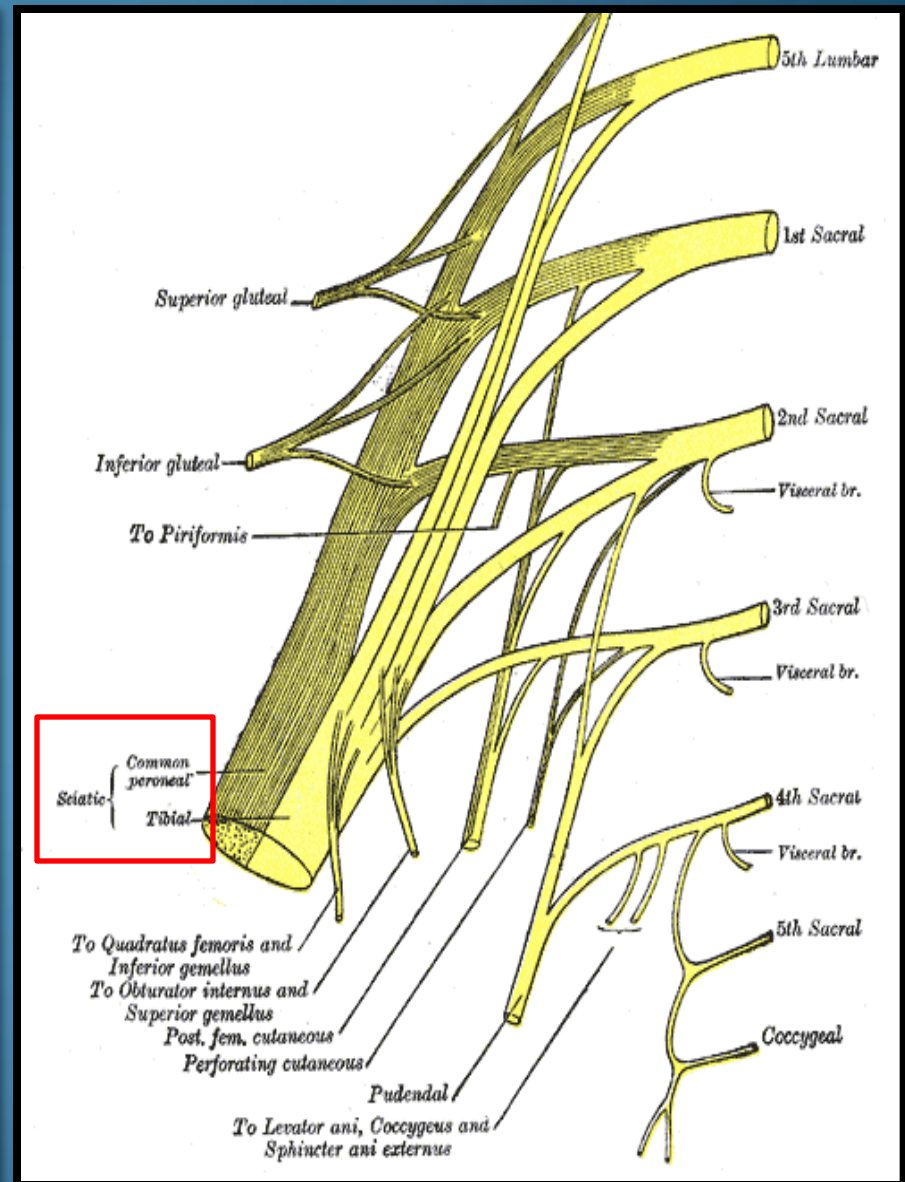
Lumbosacral Plexus

- Origin of all major nerves of the lower extremity
- Composed of separate lumbar plexus (L2-L5) and sacral plexus (S1-S4)
- 3 main nerves originating from LS plexus:
 - Femoral Nerve
 - Obturator Nerve
 - Sciatic Nerve
- Many smaller, yet important nerves

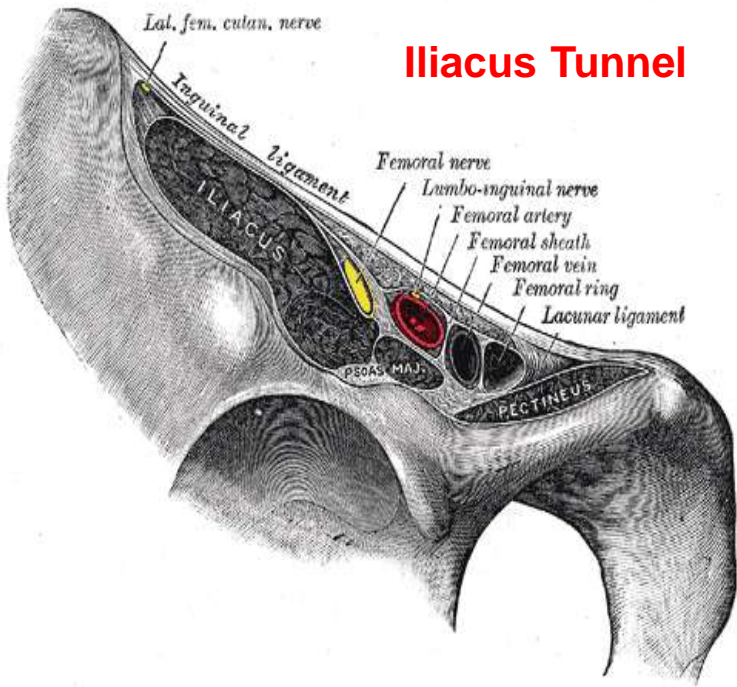
Lumbar Plexus



Sacral Plexus



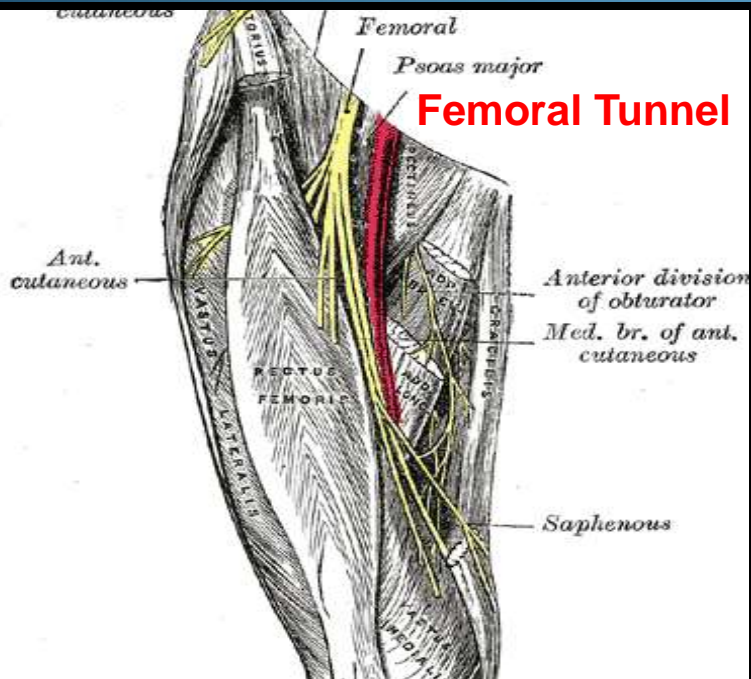
Iliacus Tunnel



Femoral Nerve

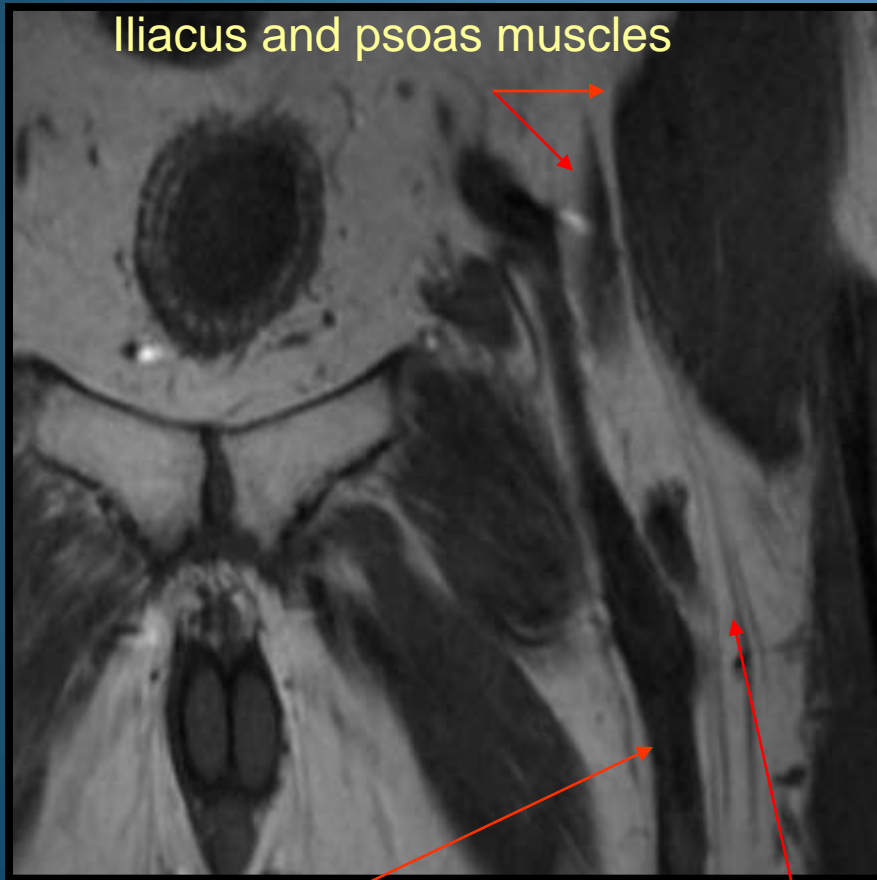
- Largest branch of lumbar plexus
- Arises from L2-L4 nerve roots
- Course
 - Initially runs in groove between **psaos** and **iliacus** muscles, supplying them
 - Courses beneath inguinal ligament through *iliacus tunnel* (formed by iliac bone, iliopsoas muscle, and inguinal ligament)
 - Then enters femoral tunnel in the thigh (lateral to artery) and divides into superficial and deep branches
 - Superficial branch supplying **pectineus** and **sartorius**
 - Deep branch supplying **quadriceps muscles** and giving off saphenous nerve (large cutaneous branch supplying sensation to medial thigh and leg)

Femoral Tunnel

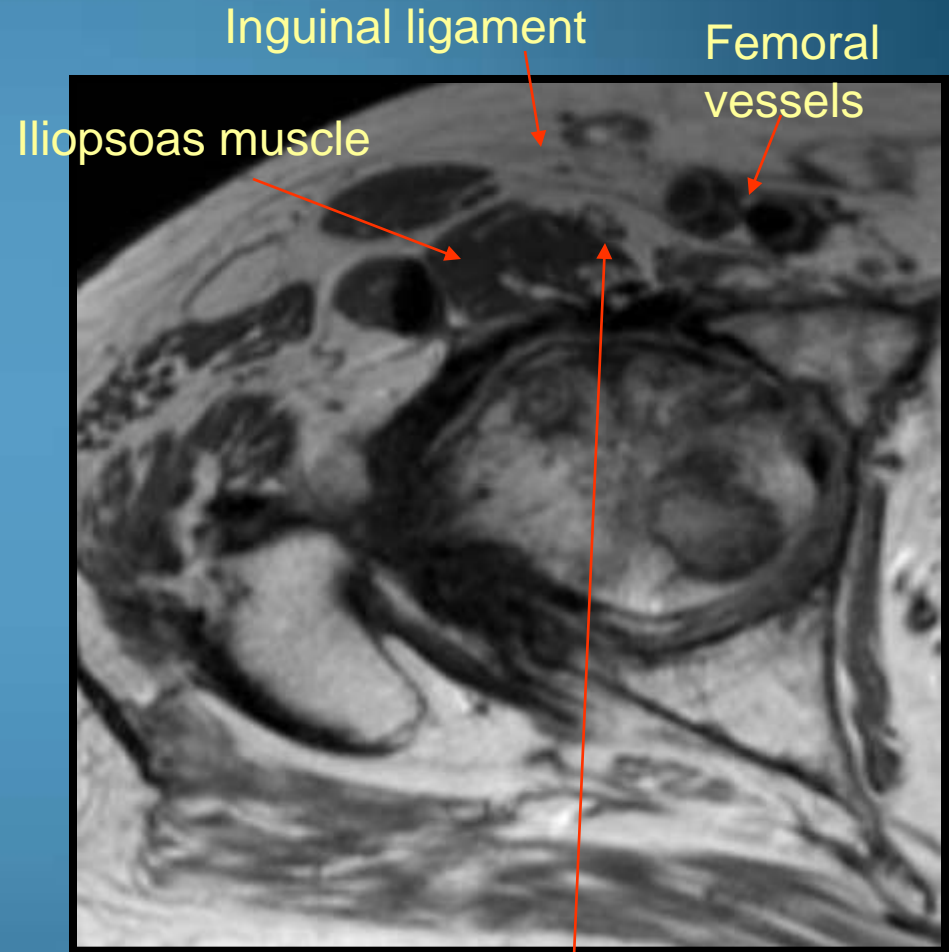


Femoral Nerve- Imaging Anatomy

NERVE WITHIN ILIOPSOAS GROOVE



NERVE WITHIN ILIACUS TUNNEL



Femoral vessels

Femoral nerve

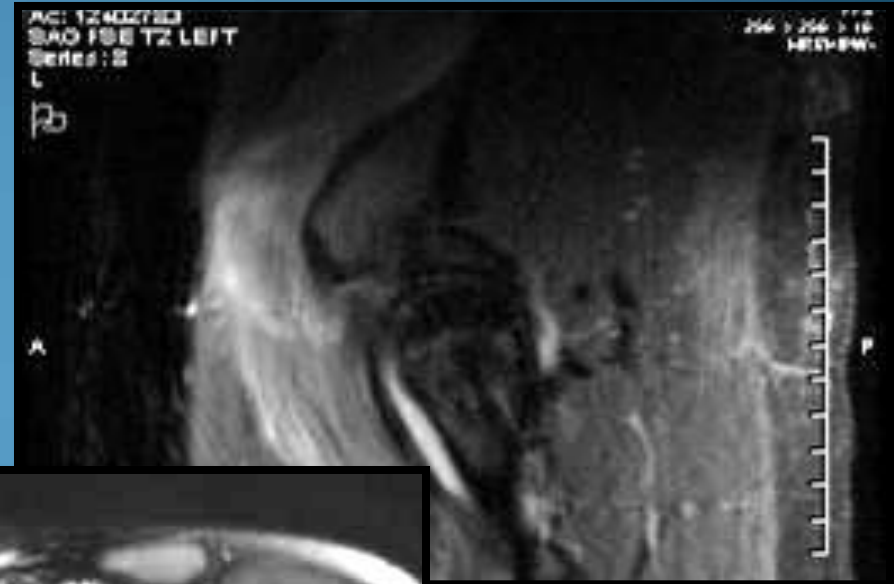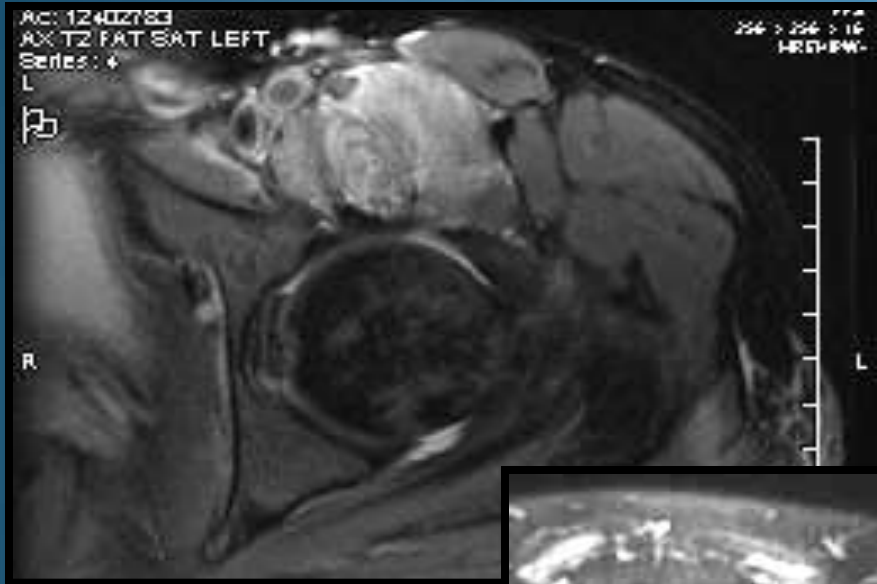
Femoral nerve

Femoral Neuropathy

- Also known as *iliacus muscle syndrome*
- Most commonly entrapped within iliacus tunnel deep to inguinal ligament
- Causes
 - Traumatic (hematomas, iliopsoas muscle tears)
 - Iatrogenic (gyn.surgery, hip replacement, femoral catheterization)
 - Inguinal hernia
 - Iliopsoas pathology (abscess, hematoma, bursitis)
 - Pelvic tumors (including lymphoma)
 - Aneurysms
- Manifestations
 - Atrophy/weakness of quadriceps muscles
 - Groin pain
 - Loss of sensation in anteromedial thigh

Femoral Neuropathy

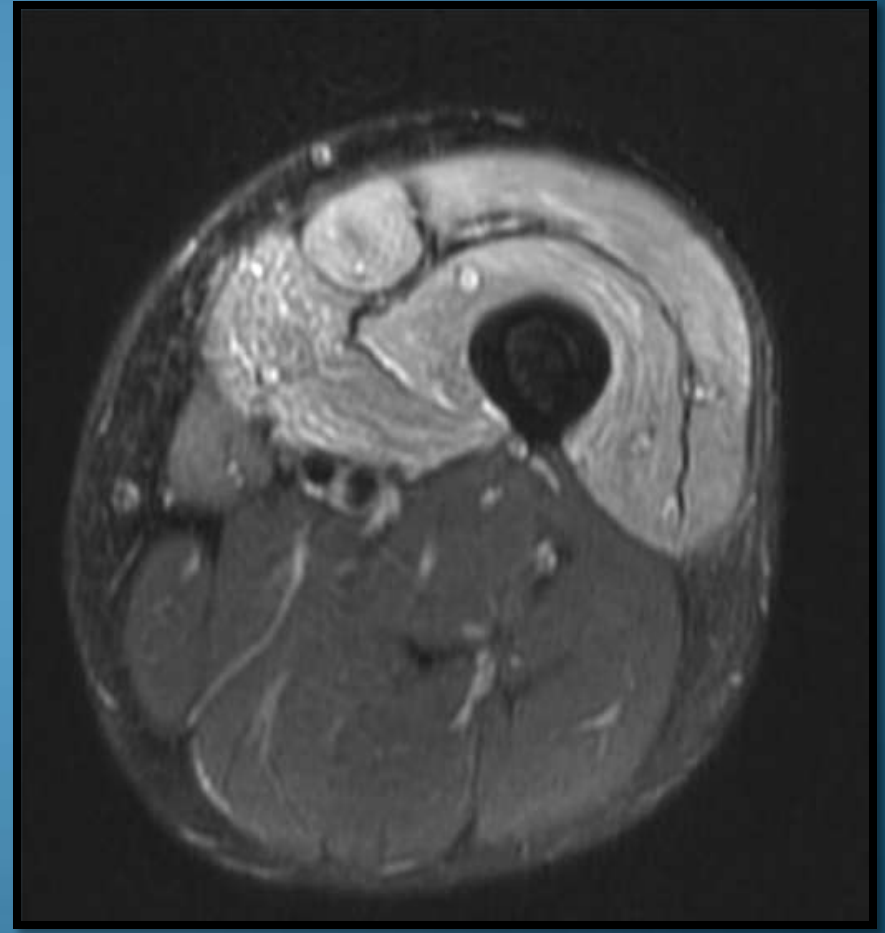
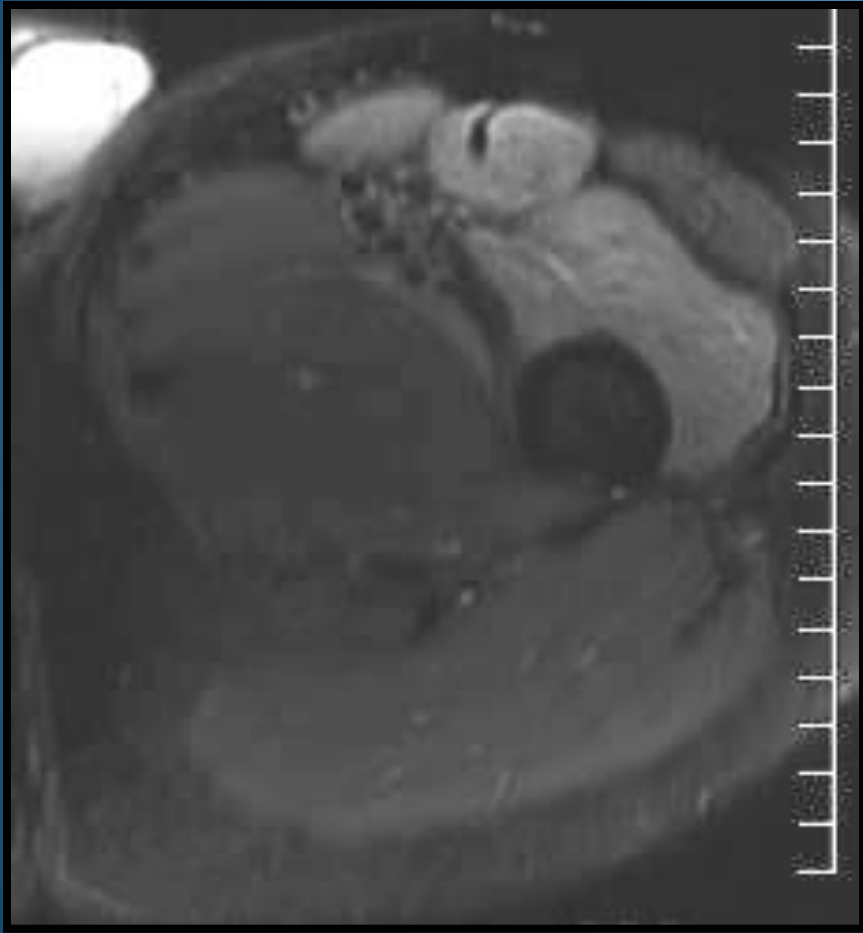
34 yo male, hip pain following a fall down stairs.



Case courtesy of
E. Fliszar, MD

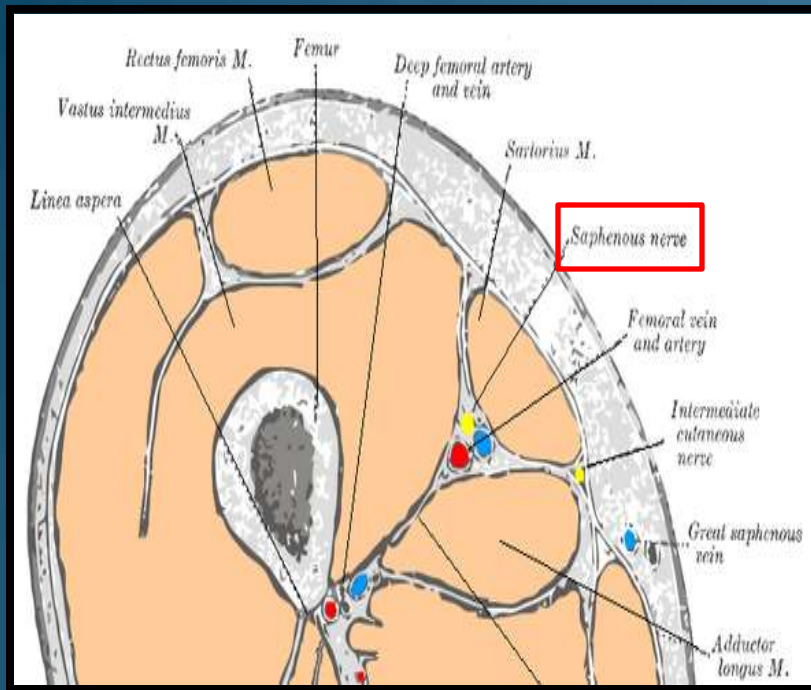
Femoral Neuropathy

8 weeks following trauma, repeat MRI due to severe weakness in quadriceps muscle.

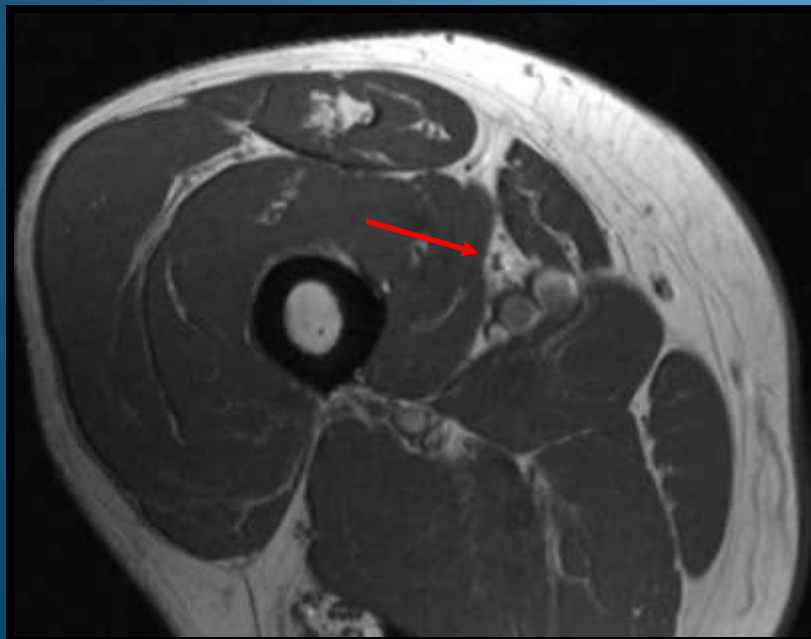

Case courtesy of
E. Fliszar, MD

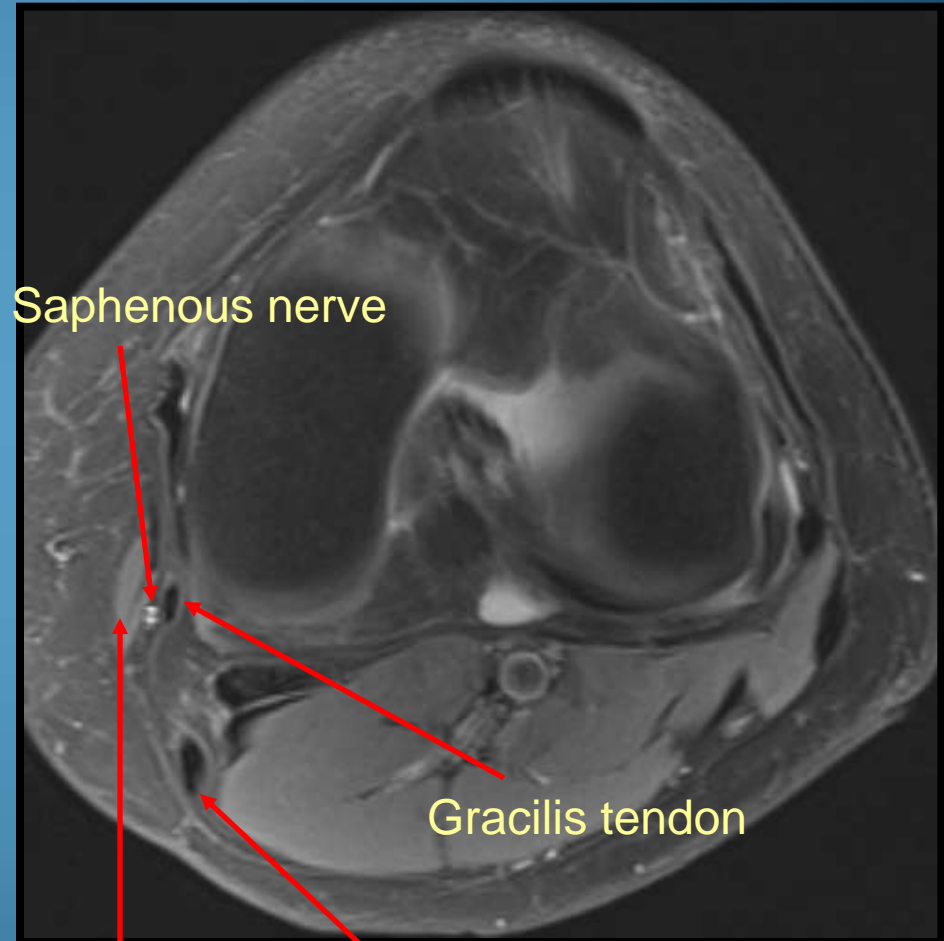
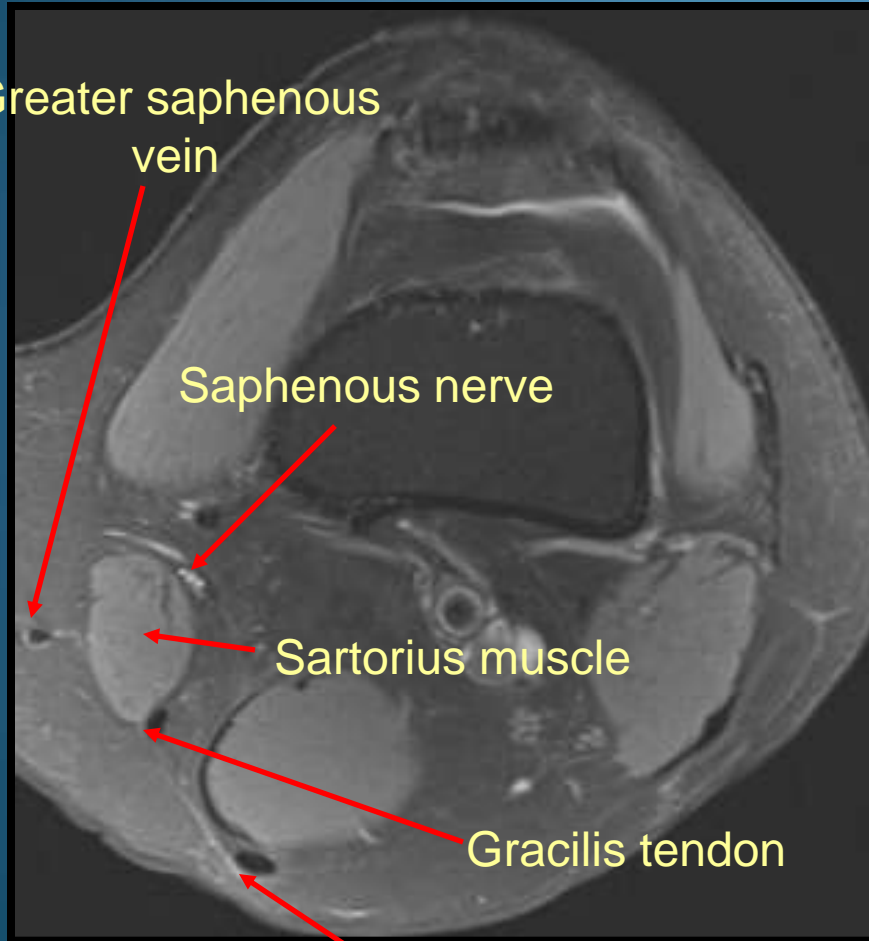
Saphenous Nerve



- Purely sensory nerve arising from deep branch of femoral nerve
- Runs deep and parallel to sartorius muscle within the thigh from an anterior position proximally to a posteromedial position distally
- Remains lateral to femoral artery in the thigh and enters *adductor canal* in middle third of thigh
- Emerges from adductor canal and descends with sartorius muscle into the medial knee (just lateral to sartorius at the knee)
- Finally, continues deep to the greater saphenous vein into the medial ankle



Saphenous Nerve at the Knee



Semitendinosus tendon

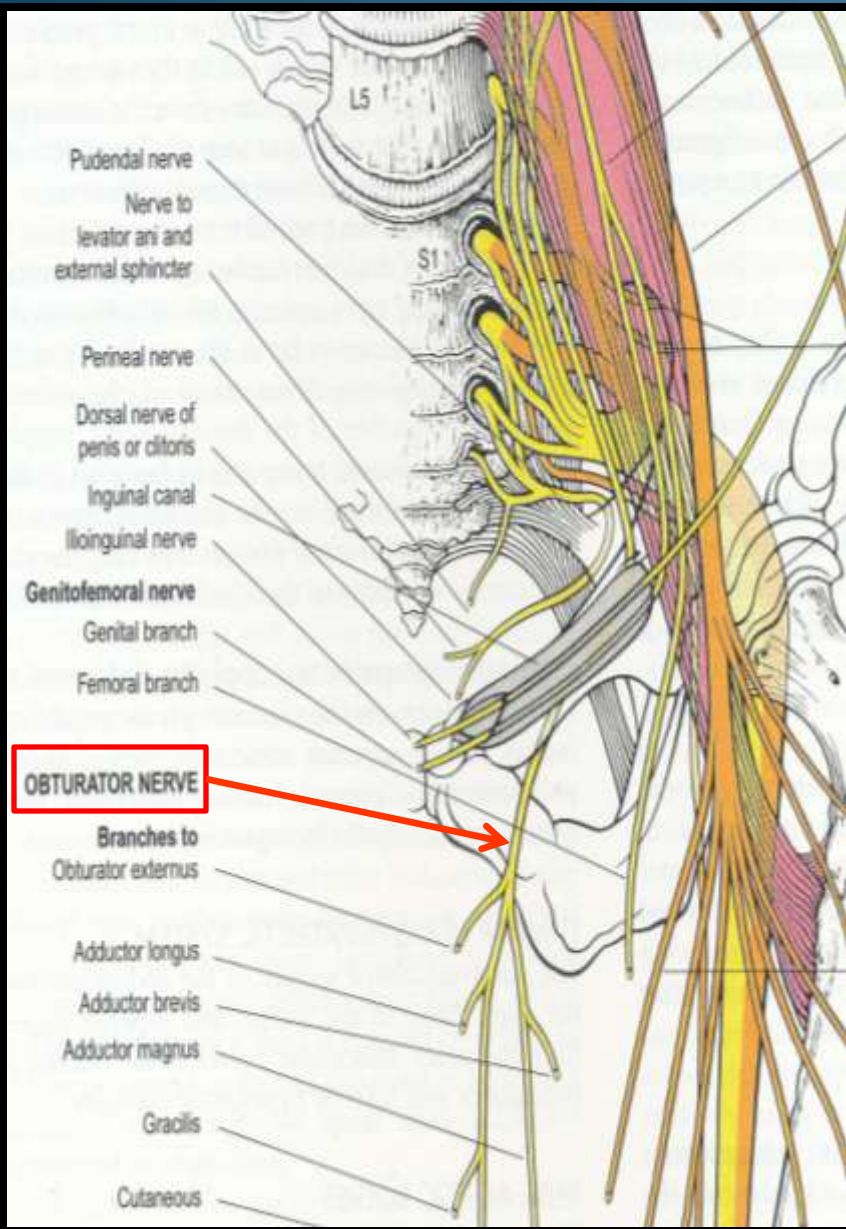
Sartorius muscle

Semitendinosus tendon

Saphenous Neuropathy

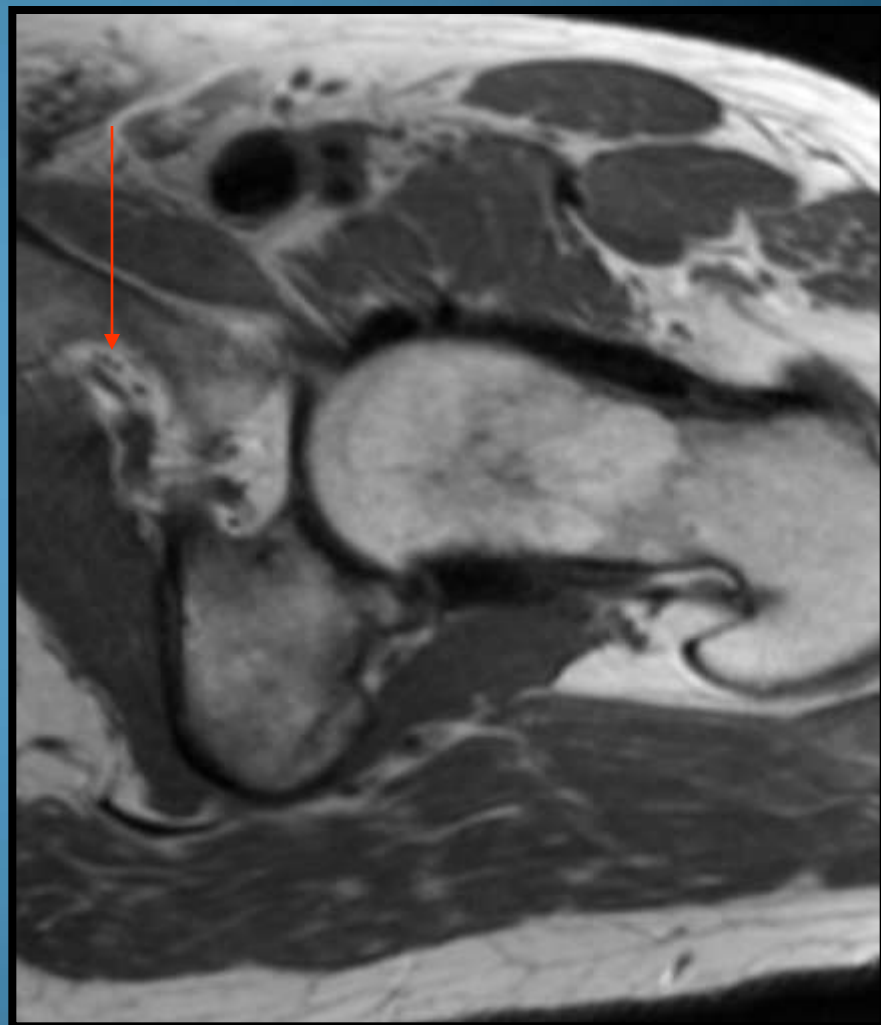
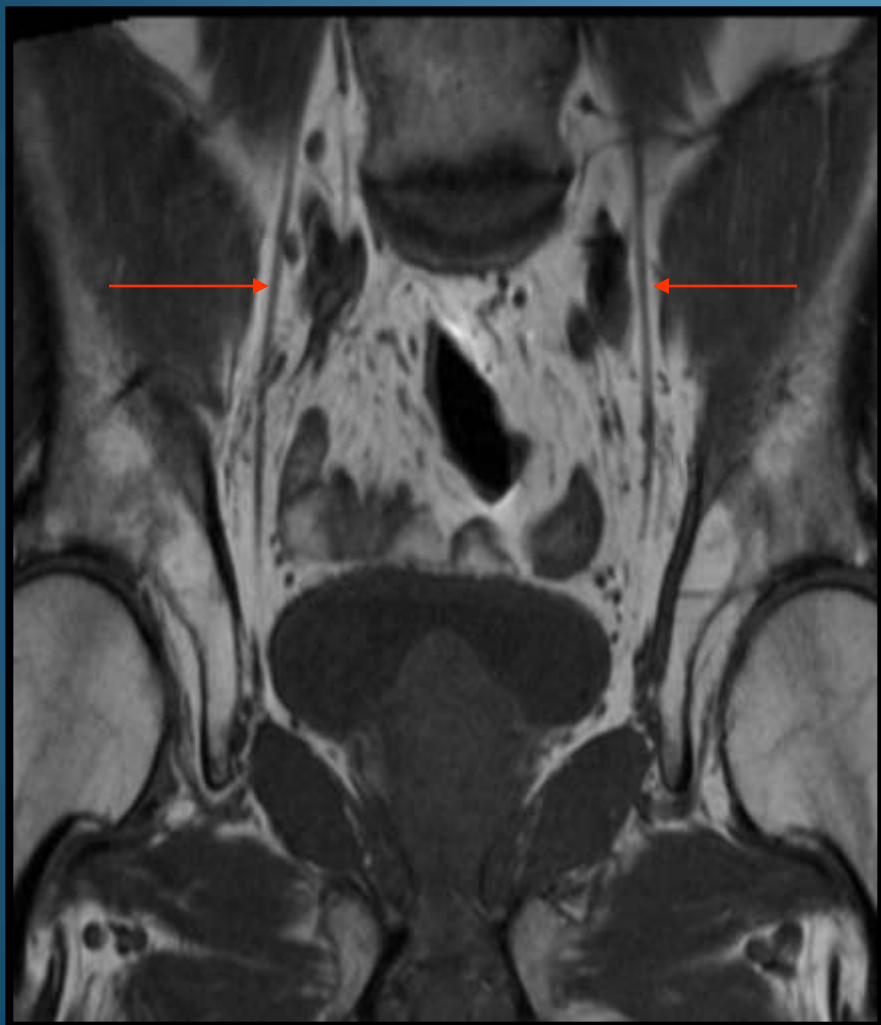- Nerve vulnerable to entrapment within adductor canal and to injury at the knee
- Important cause of persistent medial knee pain following injury or surgery
- Most common neurovascular complication following knee arthroscopy (7-22%)⁶
- Common complication of saphenous vein stripping¹⁹
- Difficult imaging diagnosis, since no muscles affected
- Clinical: pain/numbness anterior thigh and medial knee

Obturator Nerve



- Arises from L2-L4 nerve roots
- Runs deep to psoas muscle
- Courses medial to acetabulum anterior to obturator vessels
- Exits pelvis through the obturator canal in the superior aspect of the obturator foramen
- Divides into anterior and posterior branches supplying the adductor musculature
 - Anterior branch
 - runs between adductor longus and brevis
 - supplies **adductor longus, adductor brevis, gracilis** and occasionally **pectineus** muscles.
 - Posterior branch
 - runs between adductor brevis and magnus
 - supplies **adductor magnus, obturator externus**, and occasionally **adductor brevis** muscles.

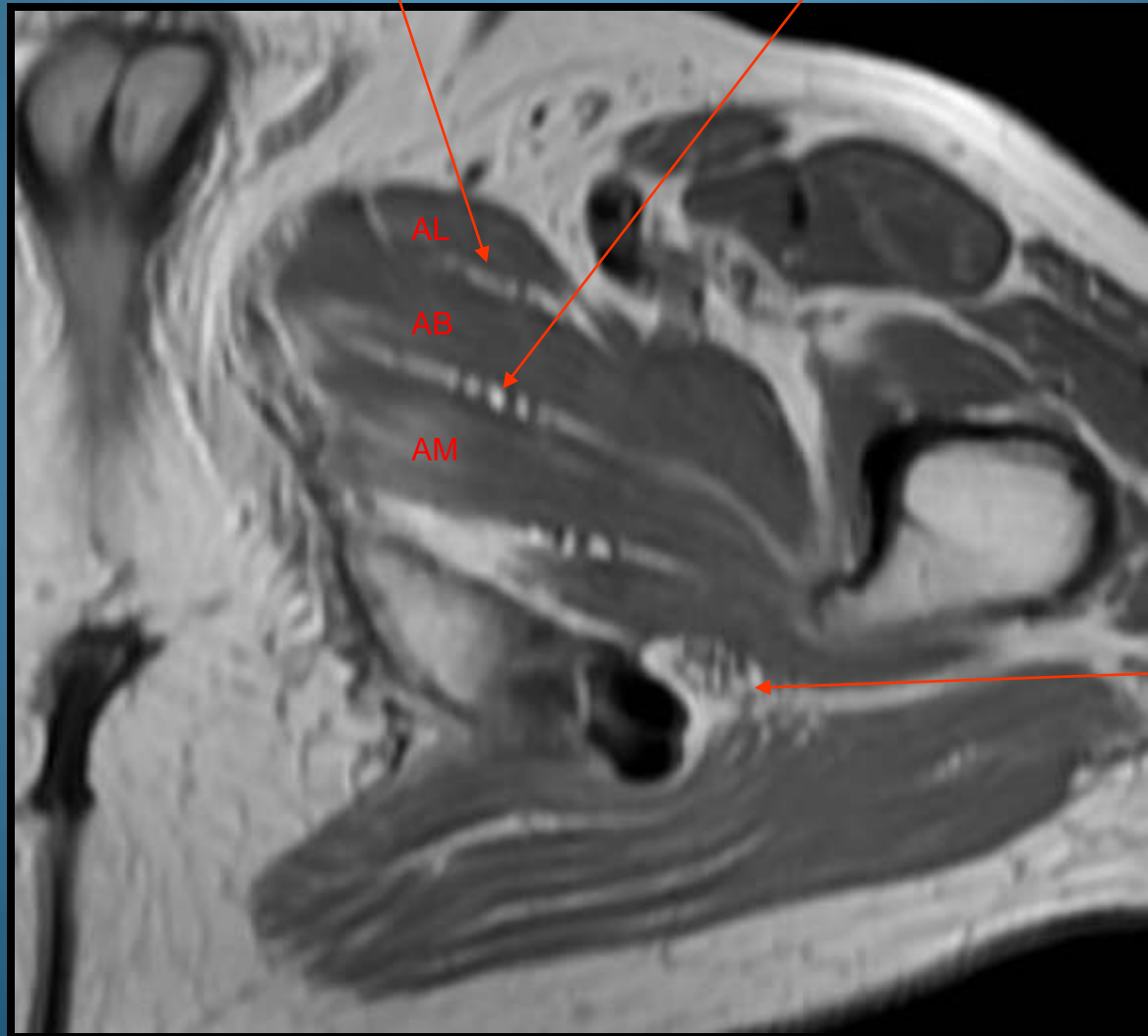
Obturator Nerve- Imaging Anatomy



Obturator Nerve- Imaging Anatomy

Anterior branch
obturator nerve

Posterior branch
obturator nerve



AL

AB

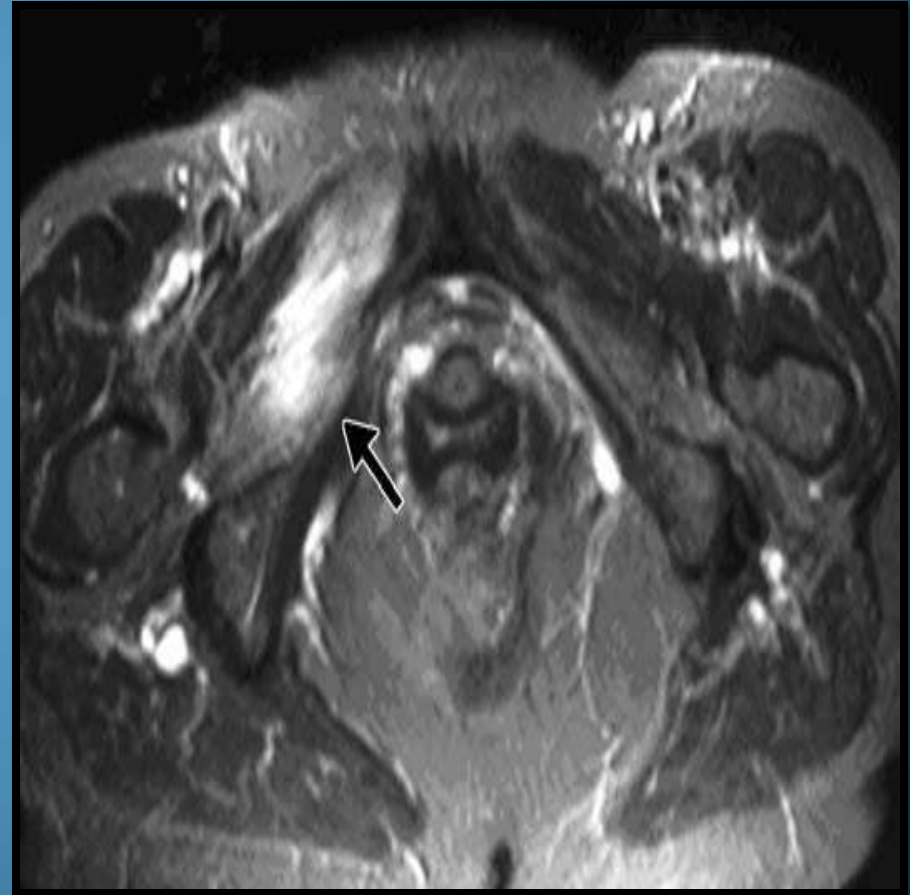
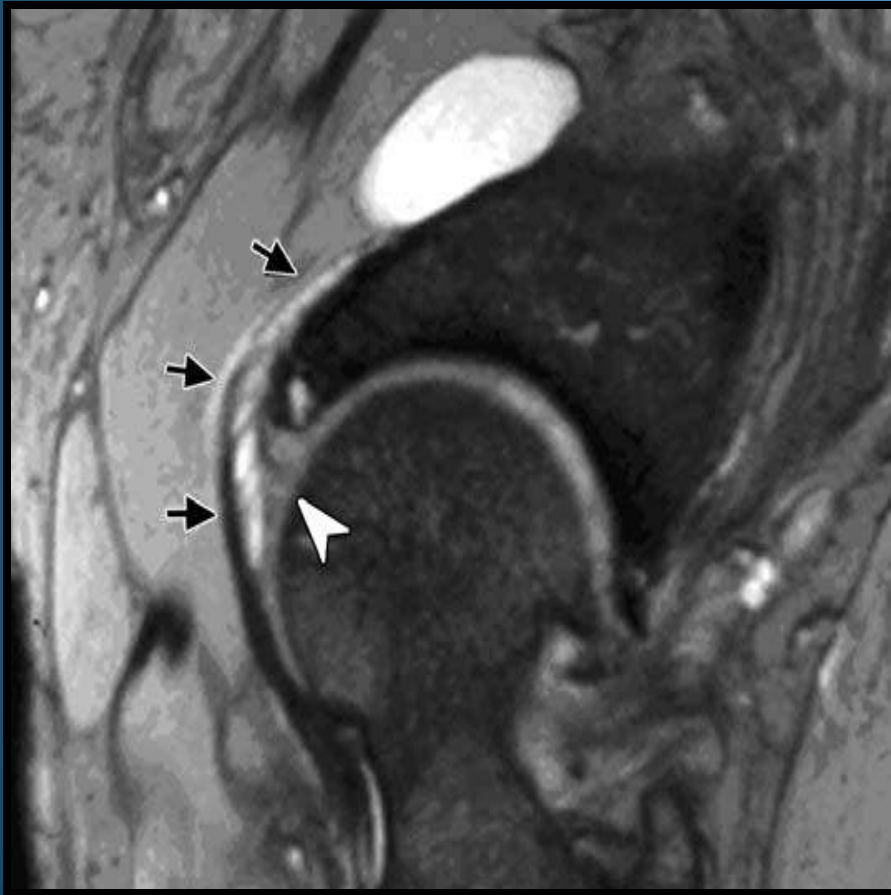
AM

Sciatic nerve

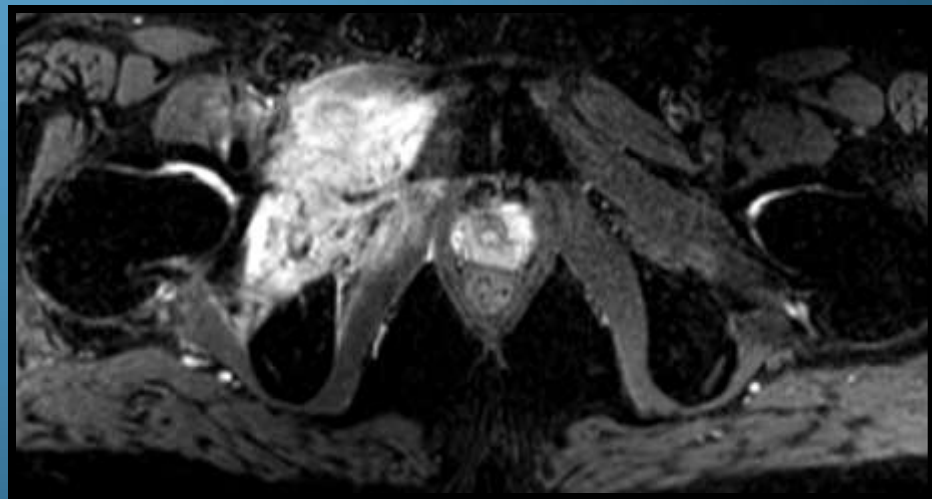
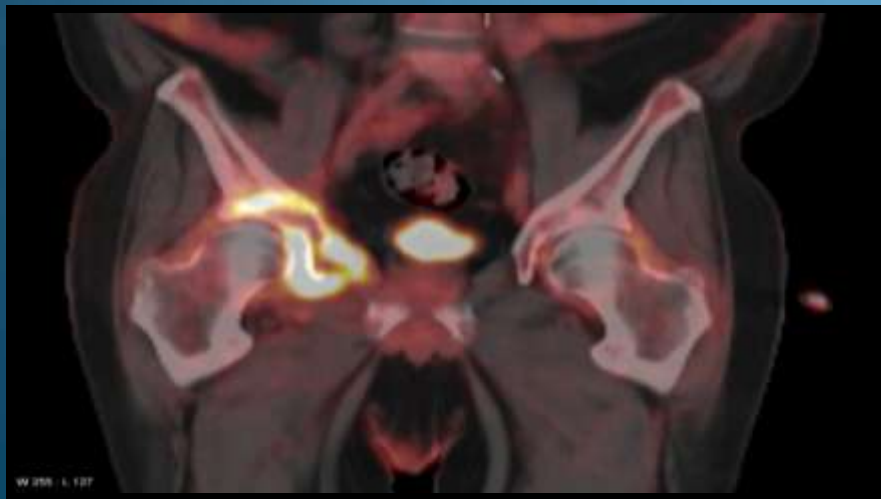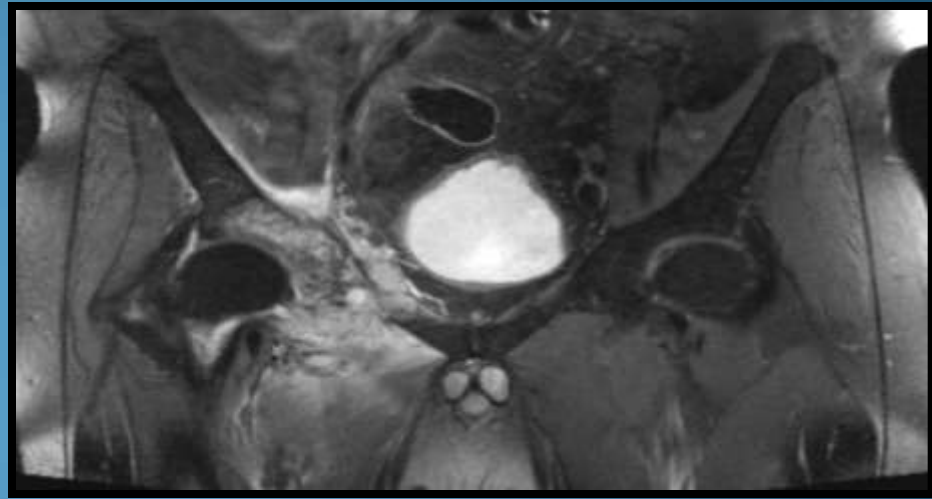
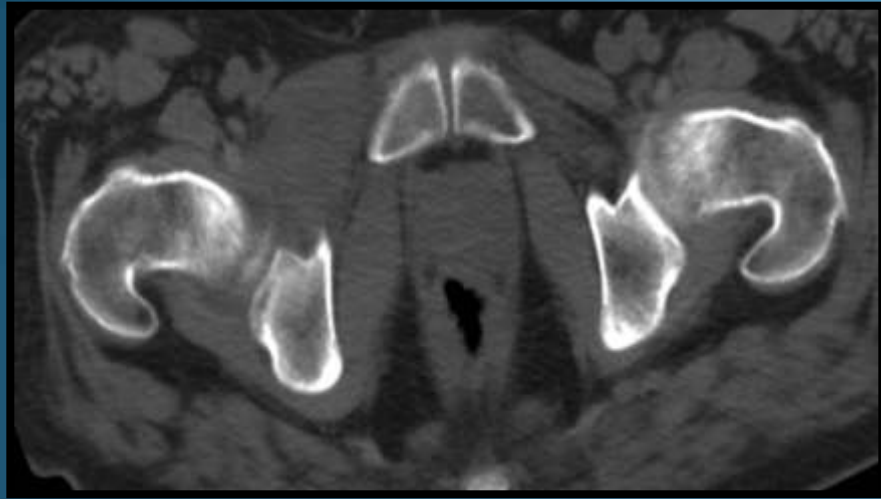
Obturator Neuropathy

- Nerve most commonly compressed within obturator canal
- Causes
 - Trauma (pelvic/acetabular fxs, hematomas)
 - Iatrogenic (ie misplaced screws during THA)
 - Tumors
 - Paralabral cysts
 - Obturator hernias (rare)
- Increasingly recognized cause of groin pain in athletes, possibly secondary to chronic adductor tendinopathy⁵
- Clinical
 - Groin pain/sensory loss
 - Weakness of adductor muscles

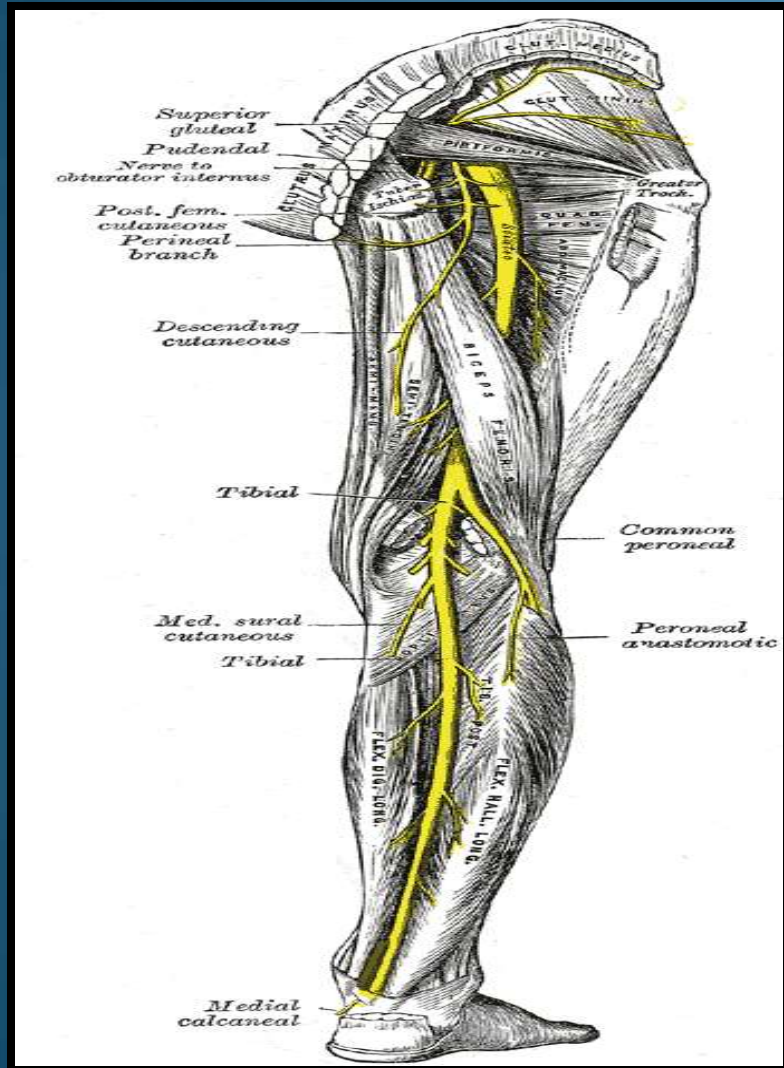
Obturator Neuropathy Secondary to an Acetabular Paralabral Cyst



45 year old male with metastatic testicular CA, with right hip pain

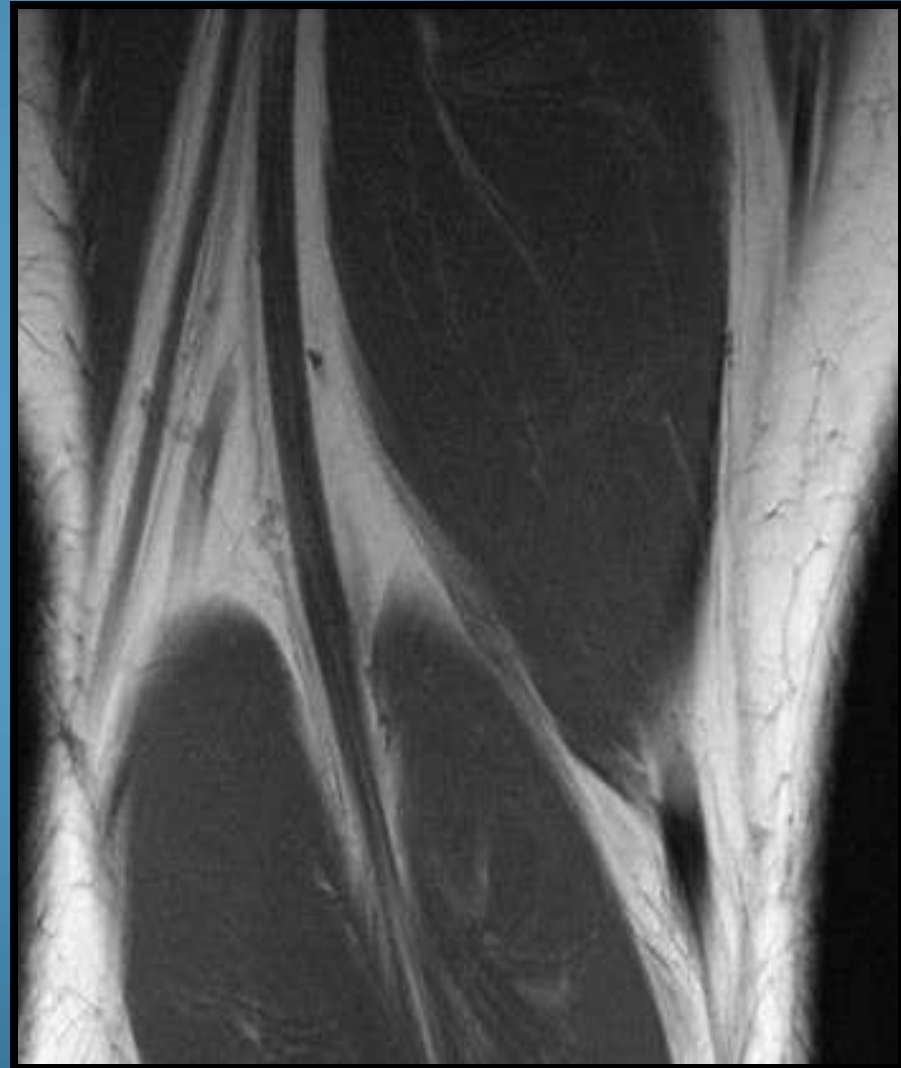
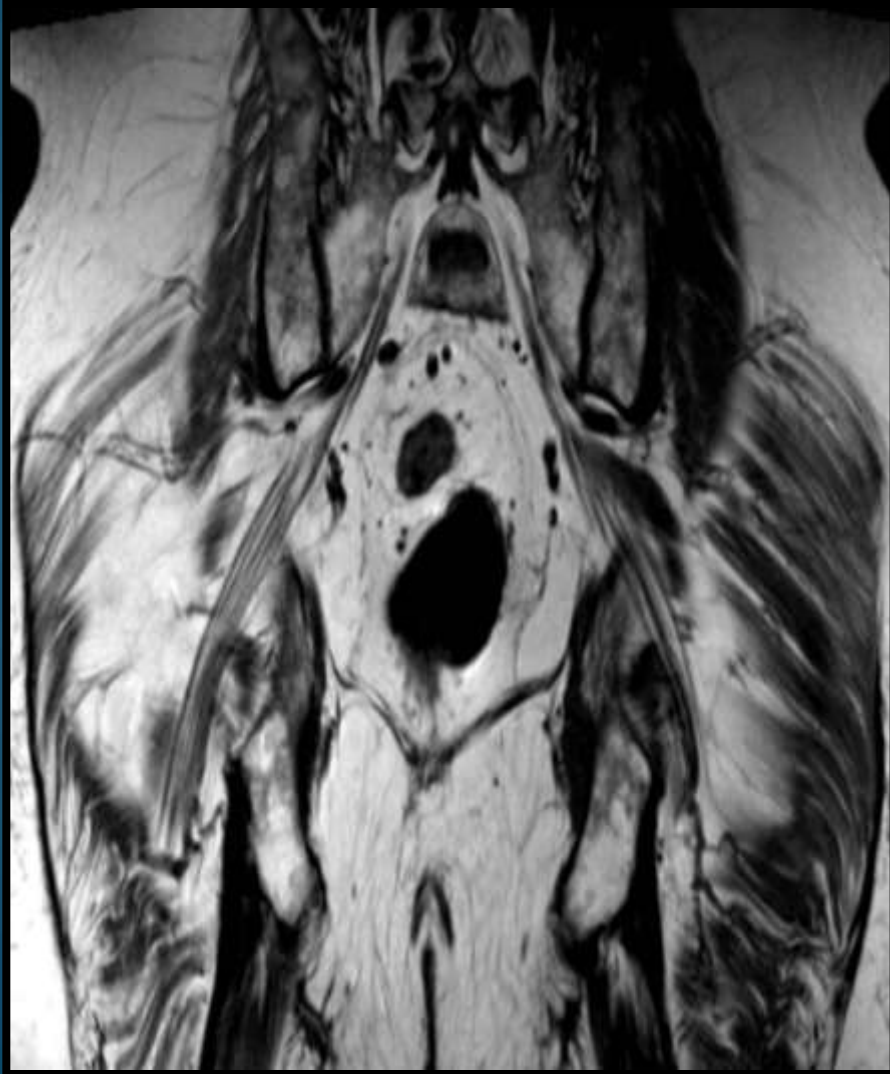
Sciatic Nerve



- Originates from L4-S2 nerve roots near the inferior aspect of the SI joint
- Composed of distinct tibial and common peroneal divisions, enclosed within common nerve sheath
- Course
 - Exits pelvis via infrapiriform portion of the greater sciatic foramen along with pudendal and inferior gluteal NV bundles
 - Descends anterior to piriformis then gluteus maximus to lie just lateral to hamstring tendons
 - More distally, nerve found between the biceps femoris and adductor magnus
- Supplies the **hamstring muscles** and, via its common peroneal and tibial branches, **all motor and sensory functions below the knee** (exception: sensation of the medial leg, supplied by the saphenous nerve).

Sciatic Nerve- Imaging Anatomy

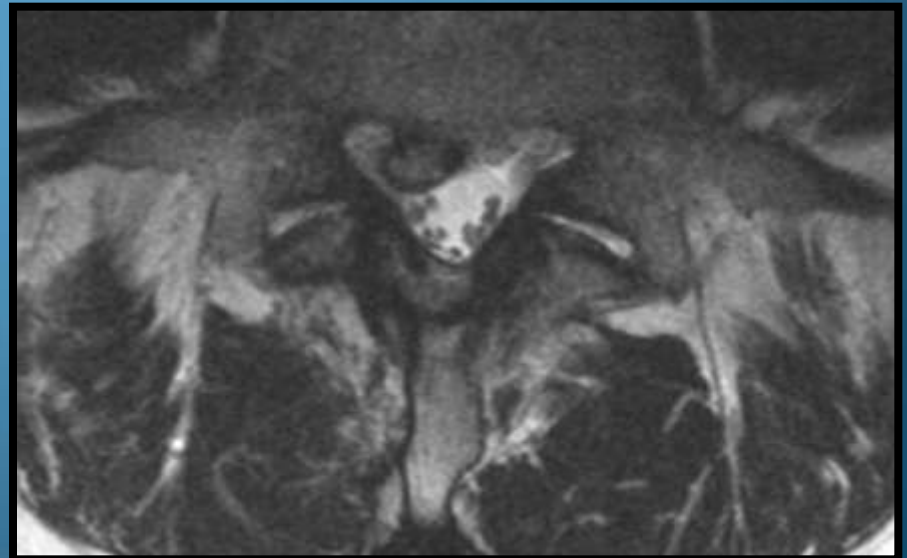
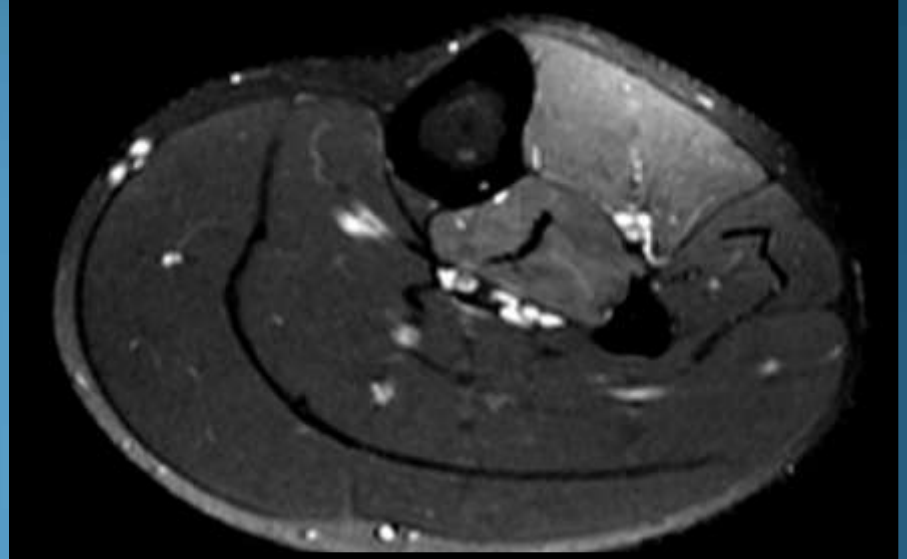


Sciatic Neuropathy

- Nerve most often compromised at level of the spine or hip
- Causes
 - Iatrogenic (THA)
 - Traumatic (hip fractures)
 - Disc pathology
 - Immobility, prolonged squatting
 - *Piriformis syndrome*
- Clinical
 - Sciatica
 - More commonly affects common peroneal division than tibial division⁵ → foot drop, loss of foot eversion, pain/numbness in lateral leg and dorsum of foot

Sciatic Neuropathy

- MR Findings:
 - Increased size/signal of nerve and/or deviation of its course
 - Muscle abnormalities in the calf and foot/ankle
 - Hamstring muscles may be spared



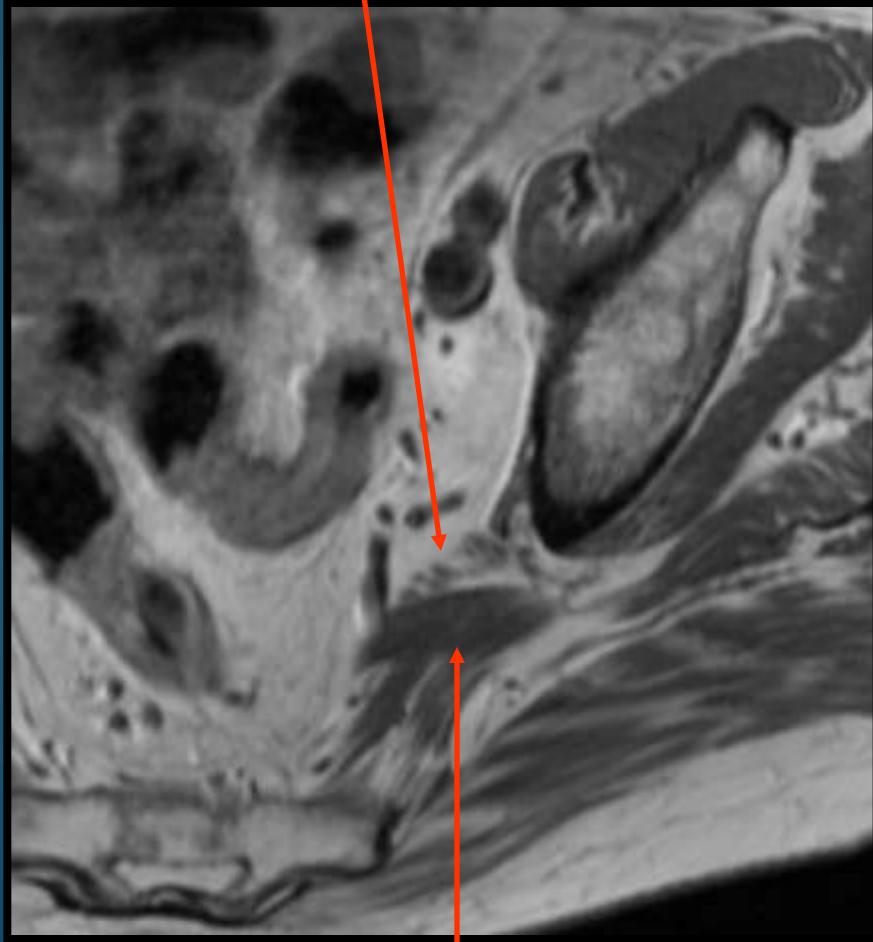
Case courtesy of M. Pathria, MD

Piriformis syndrome

- Controversial, probably overdiagnosed⁸
- Signs/symptoms closely resemble those of disc extrusion¹
- Etiology: enlargement, spasm, inflammation, or anatomic variations of piriformis muscle
- Anatomy: Piriformis muscle traverses greater sciatic foramen as it passes from sacrum to greater trochanter, dividing GSF into suprapiriformis and infrapiriformis foramina
 - Anatomic variations
 - 85% - sciatic nerve travels anterior and inferior to piriformis
 - 15% - either entire sciatic nerve or its common peroneal division travels through substance of muscle- may or may not be symptomatic
- MR
 - Mainly used to exclude other potential causes of back/leg symptoms, such as lumbar disk herniation, lumbar stenosis, and tumors.
 - Asymmetric size/signal intensity of the piriformis muscle
 - Evaluate course and signal intensity of sciatic nerve
- Treatment: resection, botulinum toxin⁹

Sciatic Nerve within Greater Sciatic Foramen

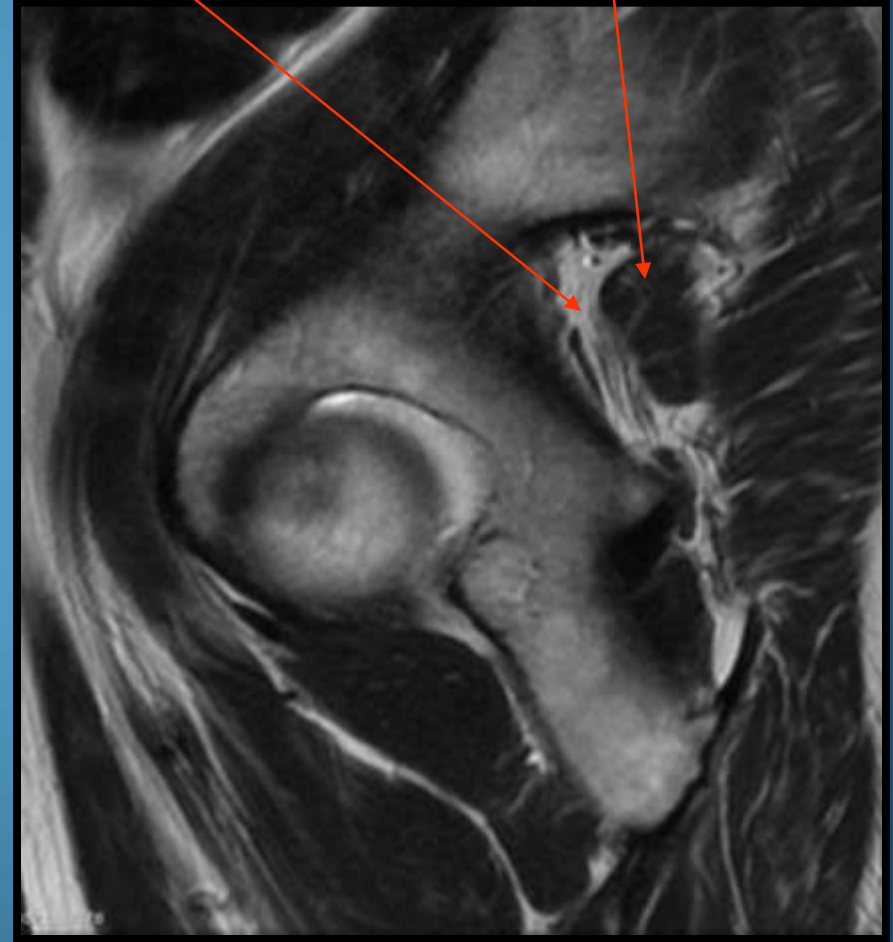
Sciatic Nerve



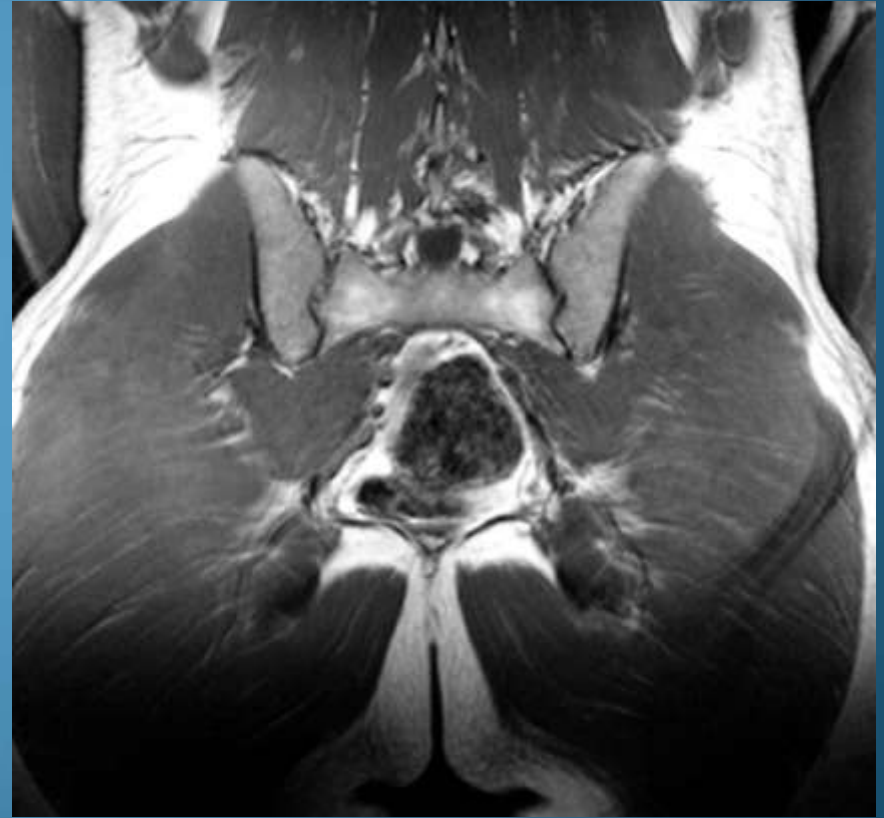
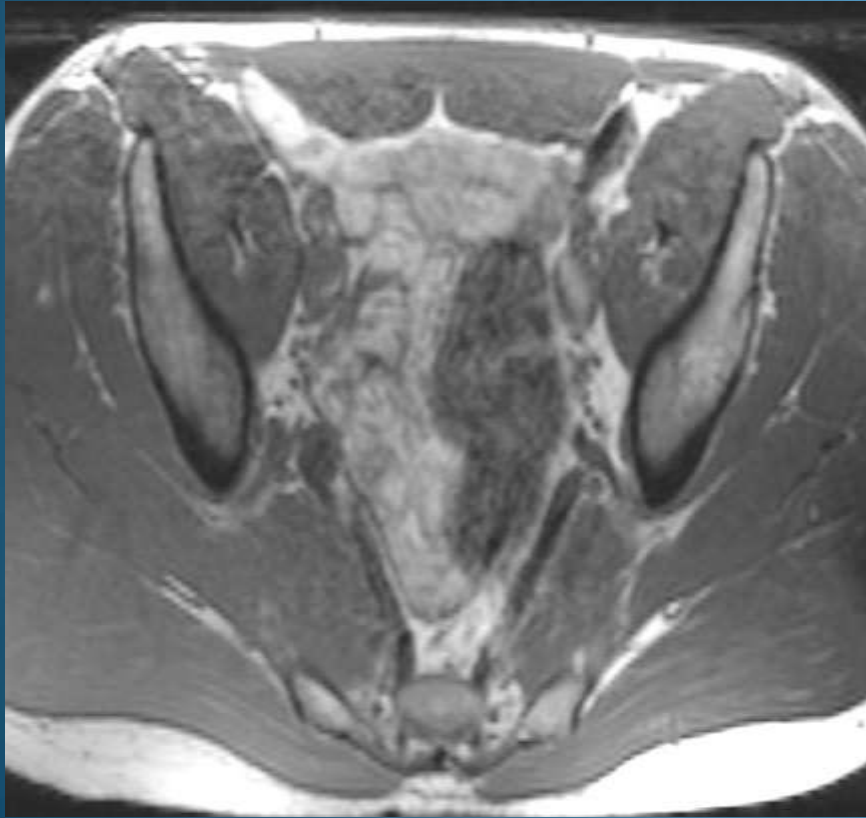
Piriformis Muscle

Sciatic Nerve

Piriformis Muscle

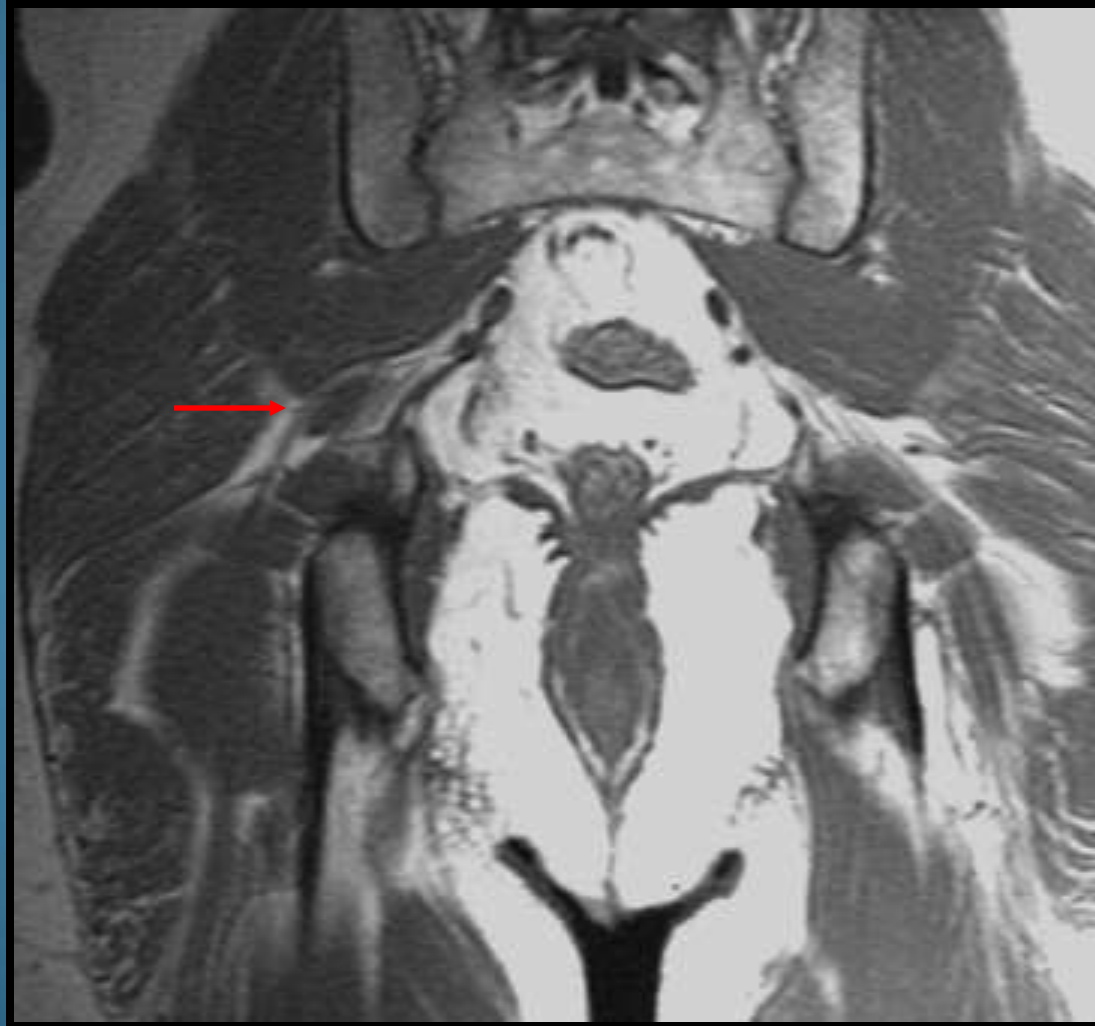


Piriformis Syndrome

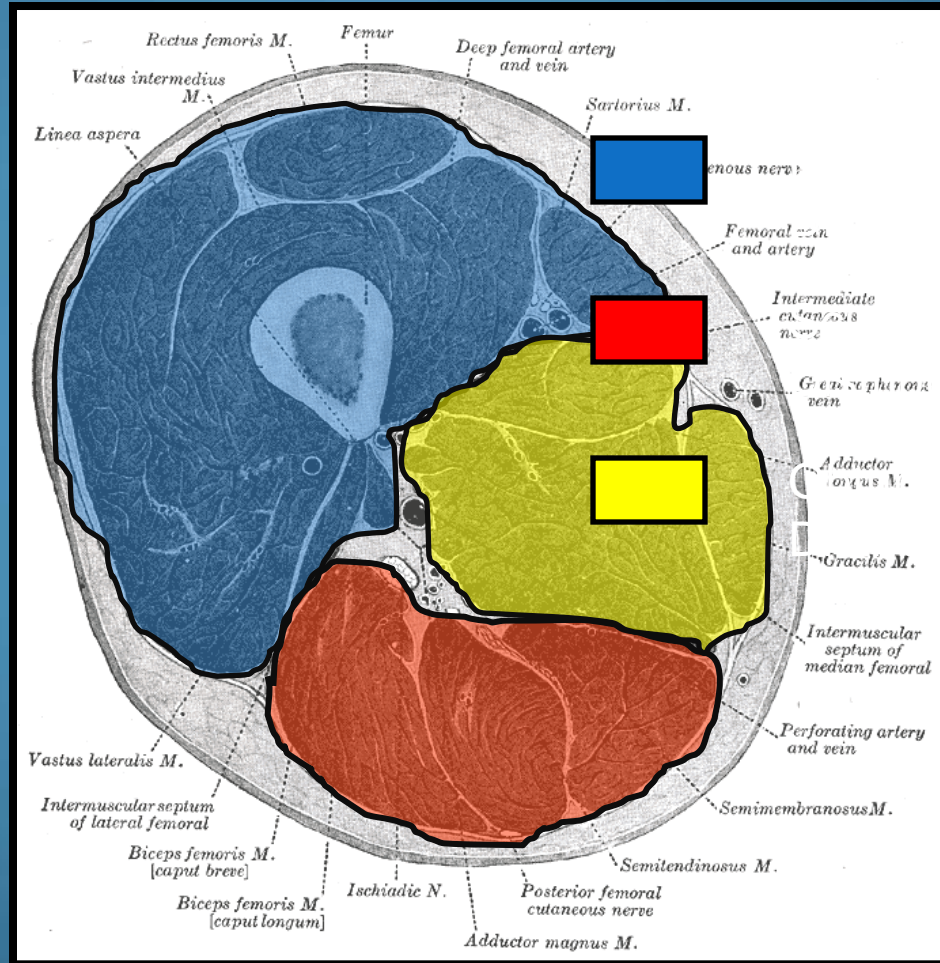


Case courtesy of M. Pathria, MD

Piriformis Syndrome



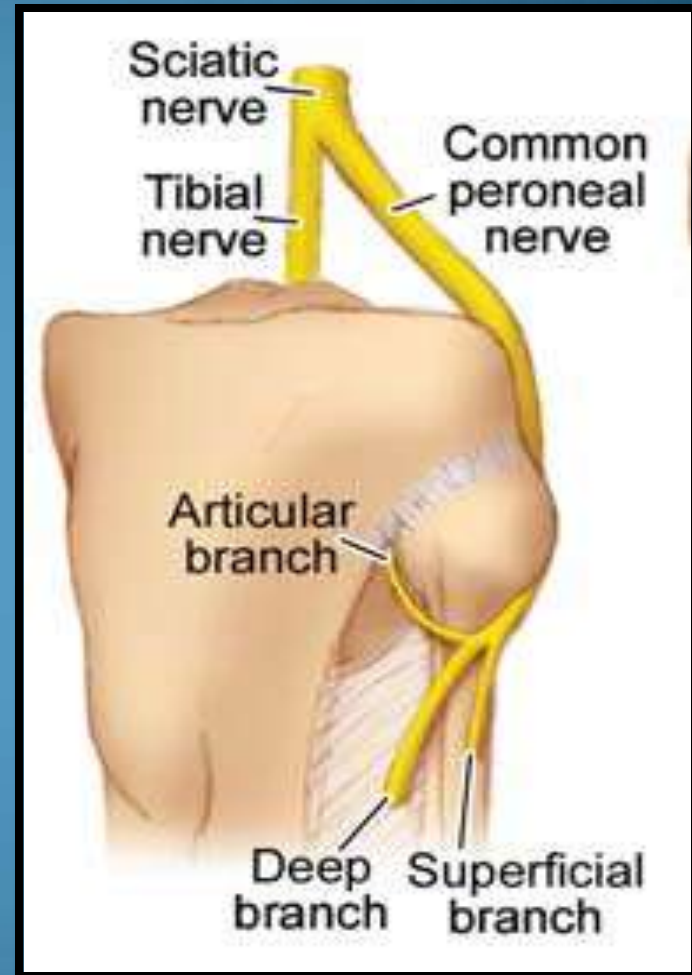
Review So Far...



al Nerve
 tion
 Nerve
 tion
 or Nerve
 tion

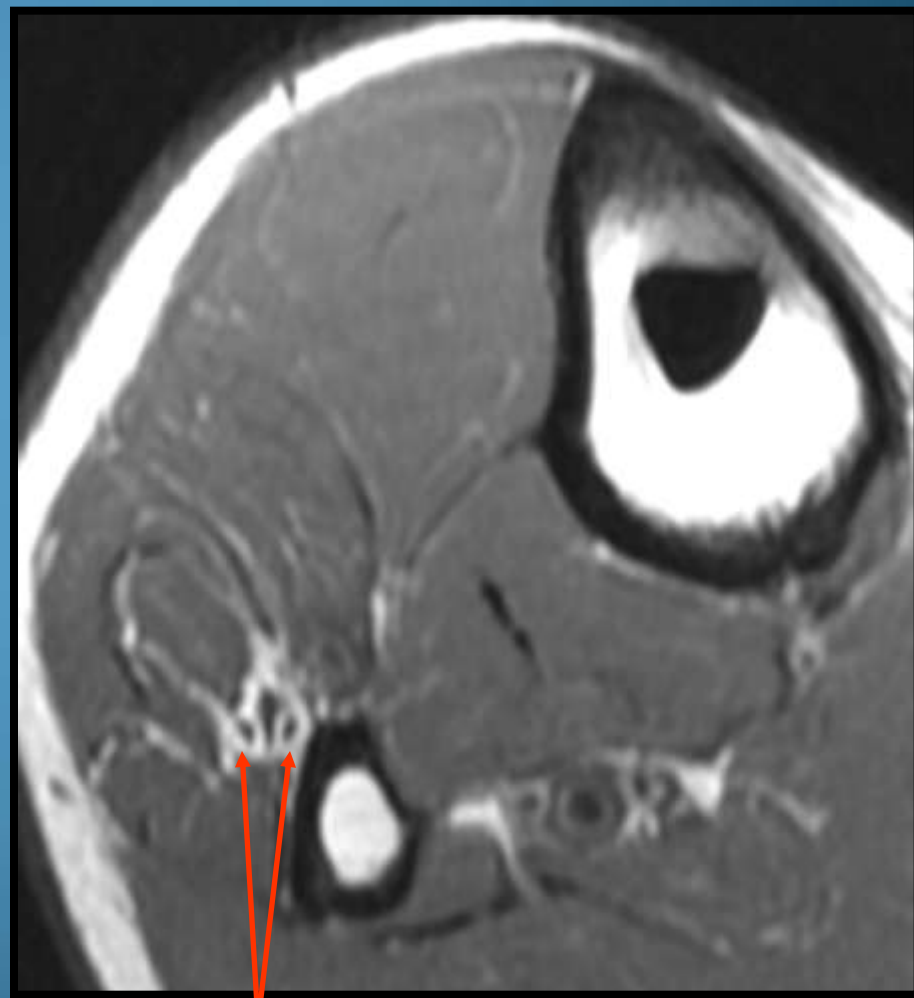
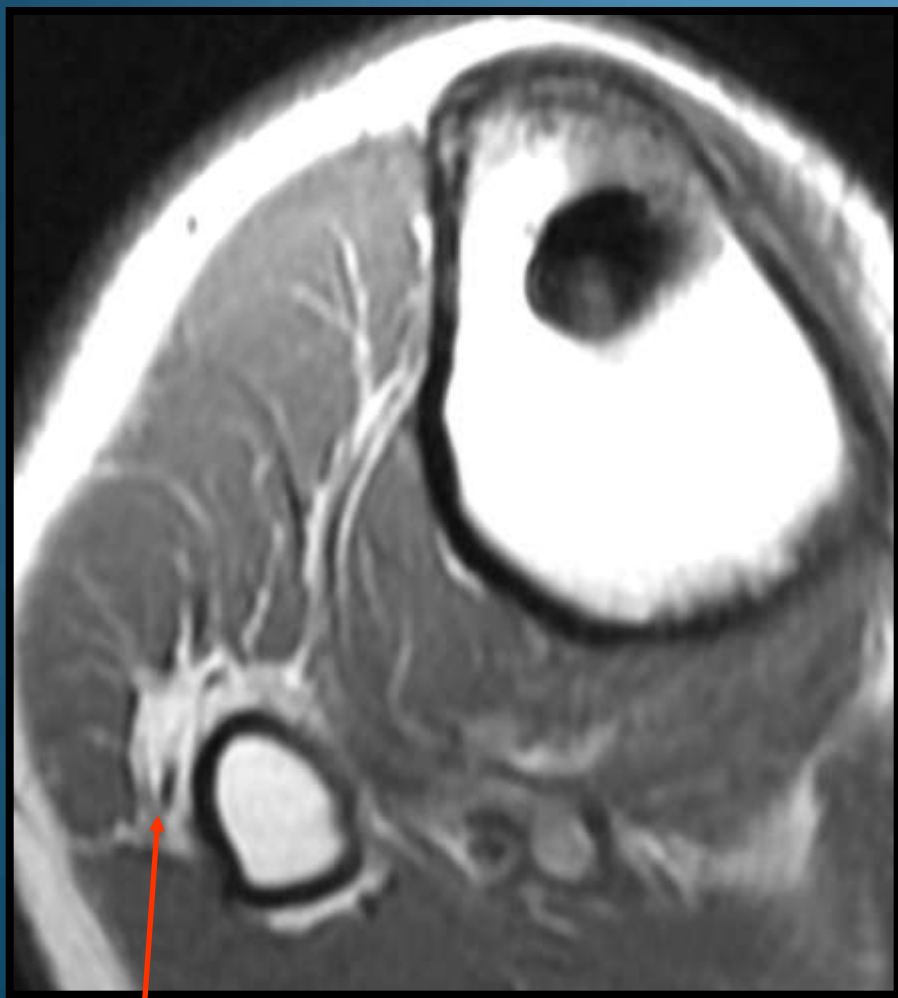
Common Peroneal Nerve

- Variable site of origin, most commonly in upper popliteal fossa
- Descends in posterolateral thigh and knee intimate with biceps femoris and lateral head gastrocnemius muscles
- Winds around fibular neck to enter *peroneal tunnel* (vulnerable site) deep to peroneus longus muscle
- Trifurcation into superficial, deep, and recurrent articular branches



Spinner RJ et al. Skeletal Radiology
2008;37:1091-1099.

Common Peroneal Nerve- Imaging Anatomy

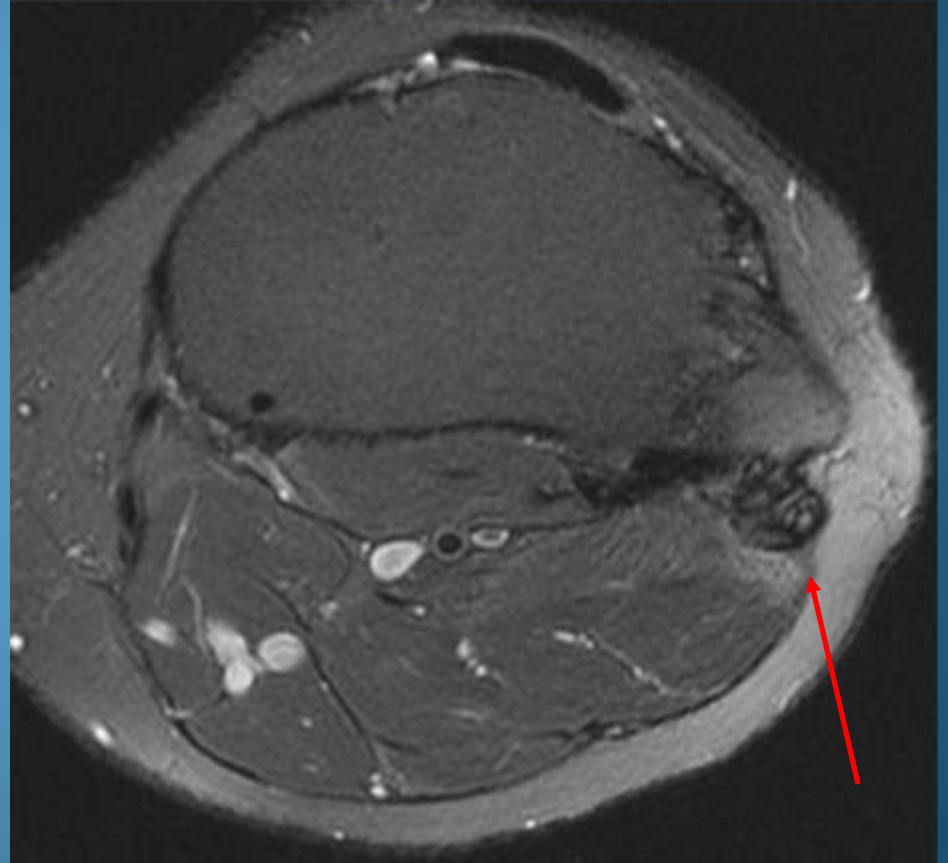
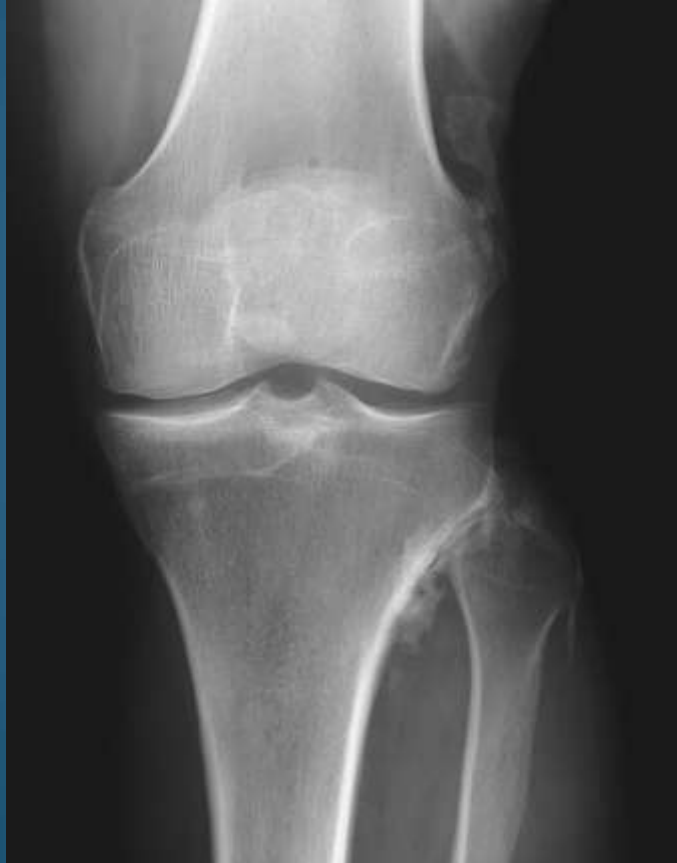

Common Peroneal Neuropathy

- Most common mononeuropathy of the lower extremity¹⁰
- Occurs at the knee as nerve crosses fibular neck
- Causes^{1,11}
 - Trauma (fibular head fracture, knee dislocation, posterolateral corner injuries)
 - Postural habits (leg-crossing), tight casts
 - Tumors, synovial cysts/popliteal cysts, ganglia (intraneural vs. extraneural), varicosities
 - Large or malpositioned fabella
 - Muscle hypertrophy or anomalous slips (lateral head gastrocnemius and biceps femoris)¹¹
 - Idiopathic
- Clinical- Footdrop, impaired foot eversion, loss of sensation in the lateral lower leg and dorsum of foot.

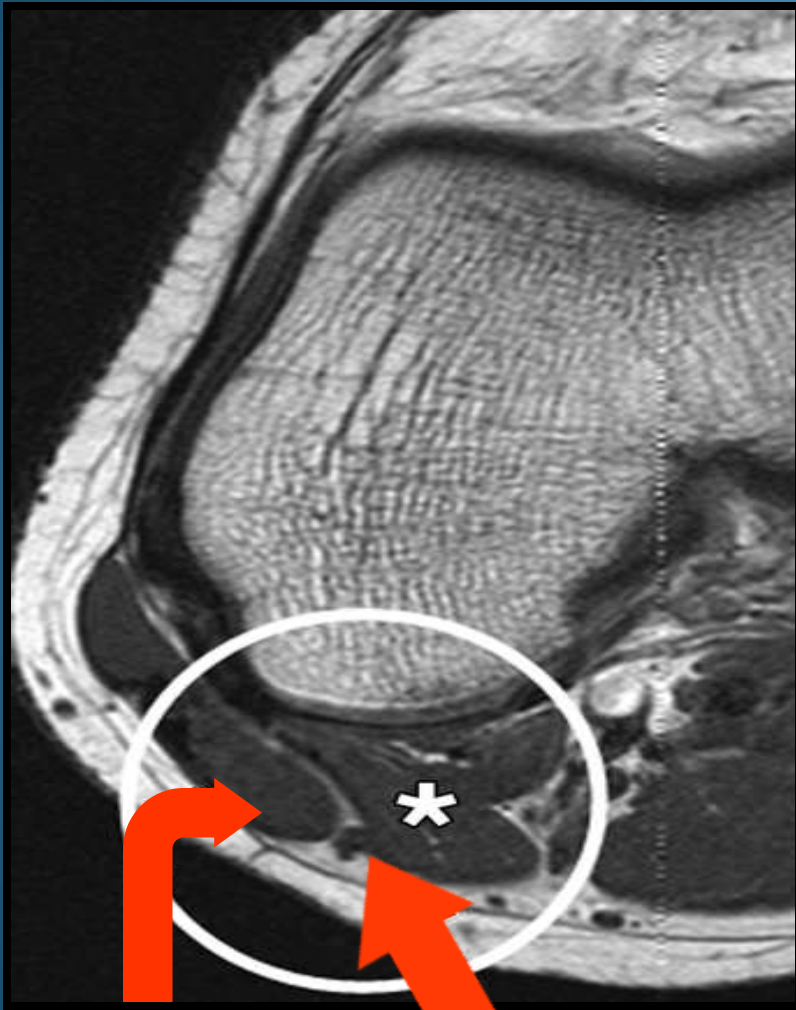
Common Peroneal Neuropathy

Hx: Trauma to knee one year ago

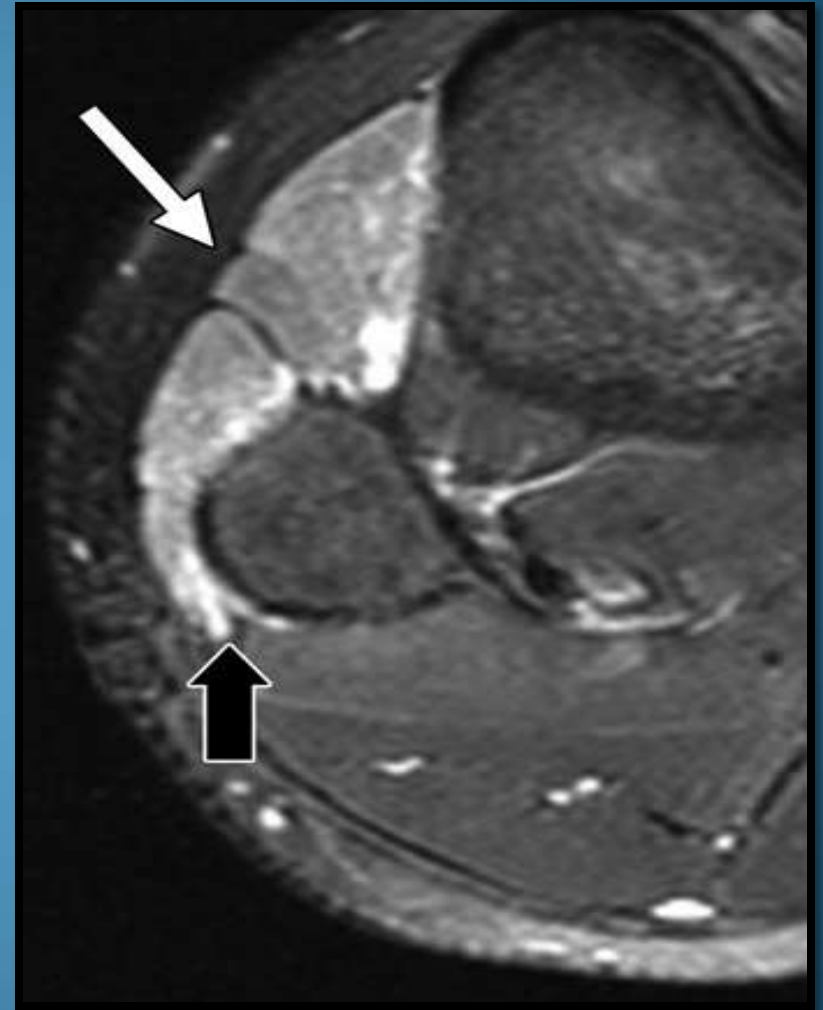


Common peroneal nerve injury with development of stump neuroma

Common Peroneal Neuropathy



hypertrophied short head of biceps femoris muscle belly

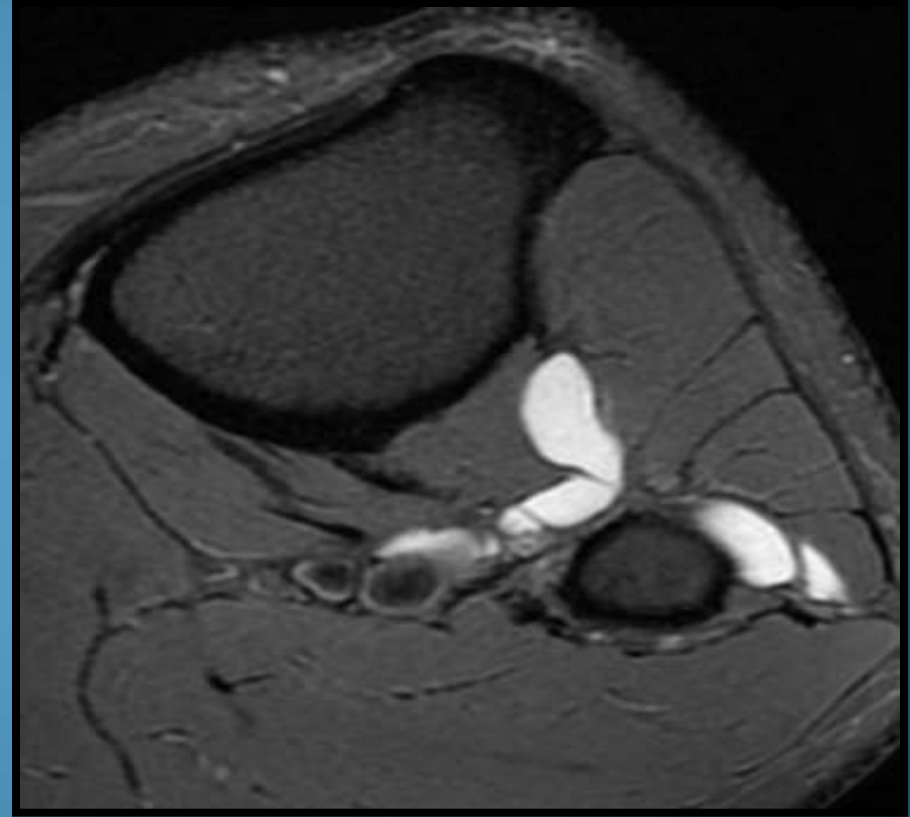
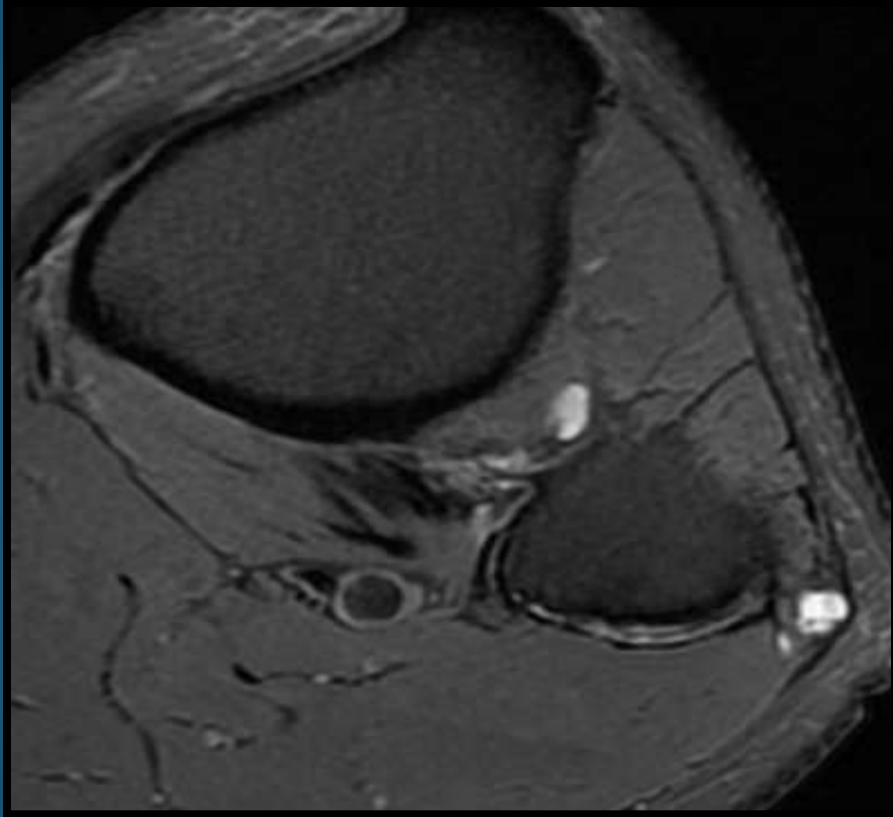


La Rocca Vieira et al. AJR 2007; 189 (3): 549.

Peroneal intraneural ganglion cysts

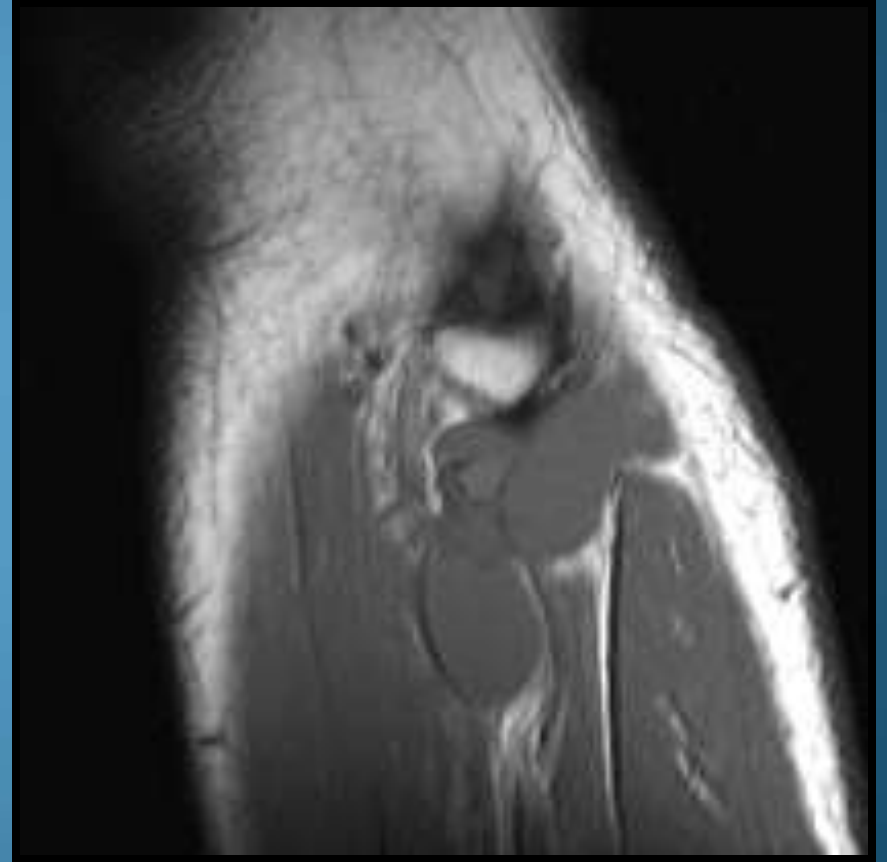
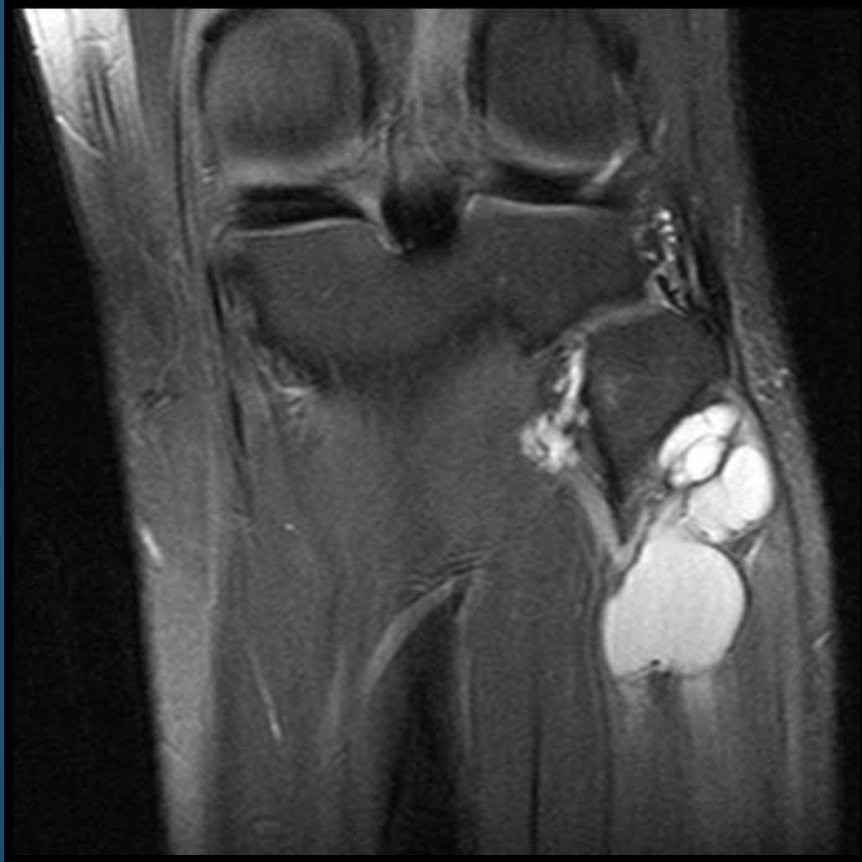- Originate from proximal tibiofibular joint
- Tend to preferentially ascend via the common peroneal nerve
- *Transverse limb sign*- cystic structure crossing from joint over the anterior surface of the fibular neck at 11-12:00 position²⁰
- *Signet ring sign*- eccentric cyst within the outer epineurium of the common peroneal nerve at the 4-5:00 position²⁰
- Ddx: extraneural ganglion- preserved fat plane between cyst and nerve
- Nearly always symptomatic, with symptoms related to the deep peroneal nerve
- Tx: decompression or resection of cysts and/or joint

Peroneal Intraneural Ganglia



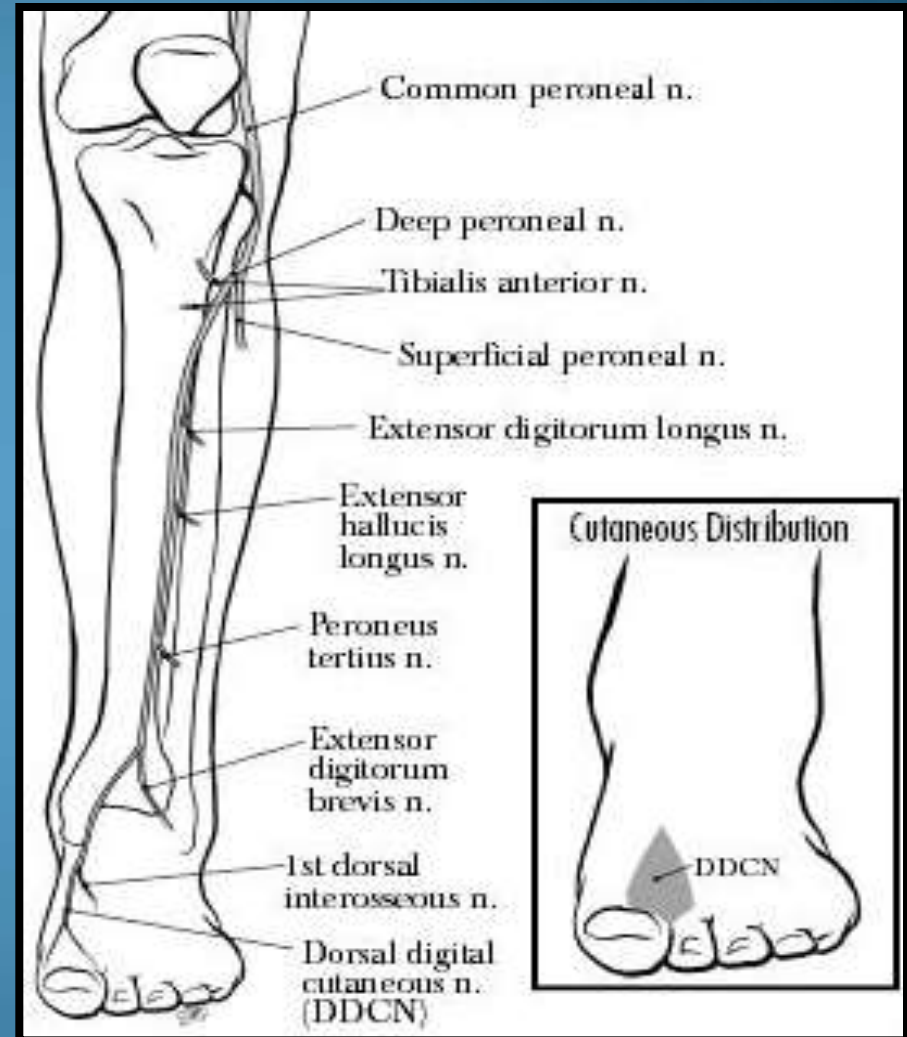
Case courtesy of
J. Buratto, MD

Peroneal Extraneural Ganglia



Deep Peroneal Nerve

- Travels in the anterior compartment of the leg along with the anterior tibial vessels deep to extensor muscles
- Courses under the superior and inferior extensor retinacula to enter “anterior tarsal tunnel”
- Divides into terminal medial and lateral branches
- Supplies **extensor muscles (TA, EHL, EDL, EDB)⁴** and sensation to 1st web space

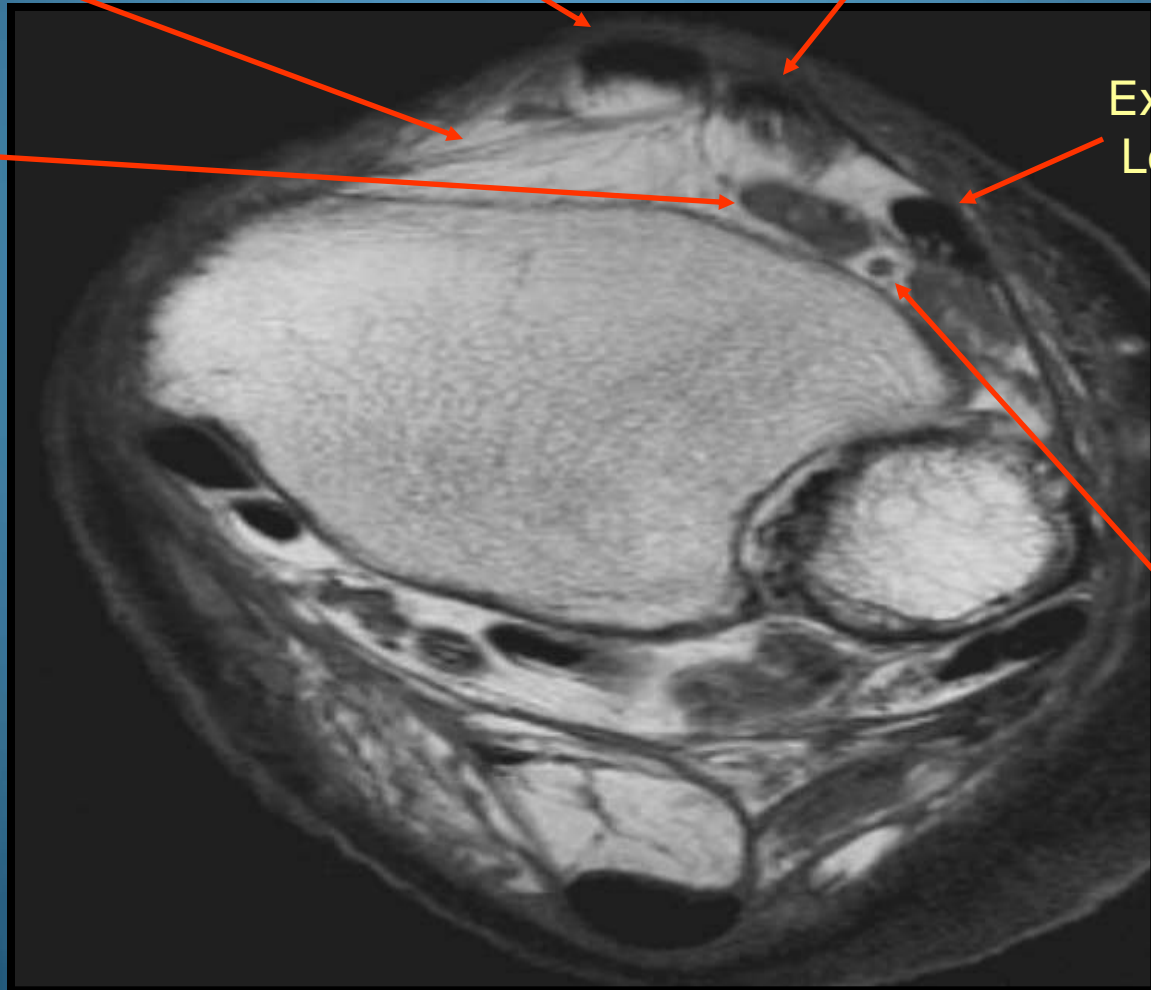


Deep Peroneal Nerve Just Before Entering the Anterior Tarsal Tunnel

Inf. Extensor Retinaculum Tibialis Anterior Extensor Hallucis Longus

Anterior tibial artery and vein

Extensor Digitorum Longus

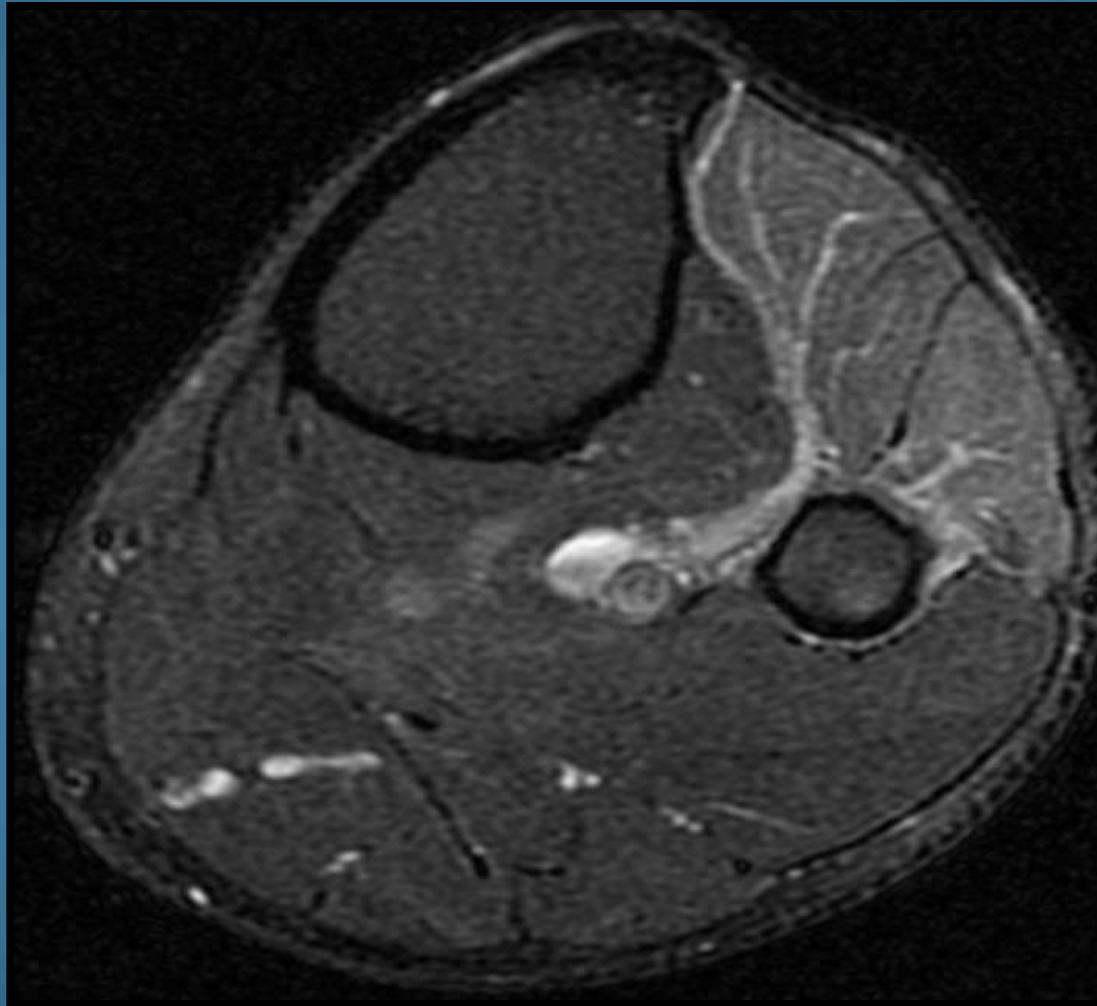


Deep Peroneal Nerve

Deep Peroneal Neuropathy

- 2 main sites of compression^{1,5}
 - 1) Beneath superior extensor retinaculum
 - 2) Dorsum of foot beneath inferior extensor retinaculum where the EHL tendon crosses over it (*anterior tarsal tunnel syndrome*)
- Causes^{1,5}
 - Trauma (ankle sprains, fractures)
 - Repetitive injuries to dorsum of foot (footwear, skiers, soccer players, excessive situps)
 - Talonavicular joint OA
- Clinical: pain and numbness on dorsum of foot, ± weakness of EDB muscle
- MR: Edema/atrophy of anterior compartment muscles with sparing of lateral compartment muscles (supplied by SPN)
- Treatment: Surgical release of extensor retinaculum

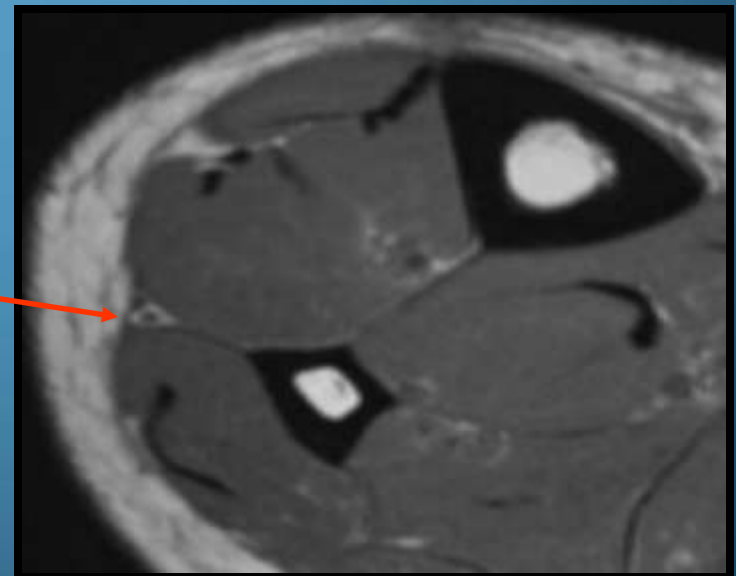
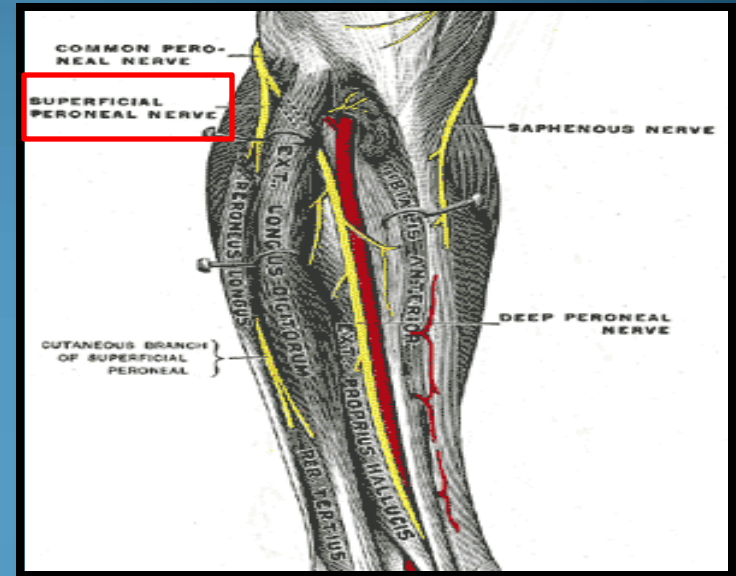
Deep Peroneal Neuropathy



Case courtesy of M. Pathria, MD

Superficial peroneal nerve

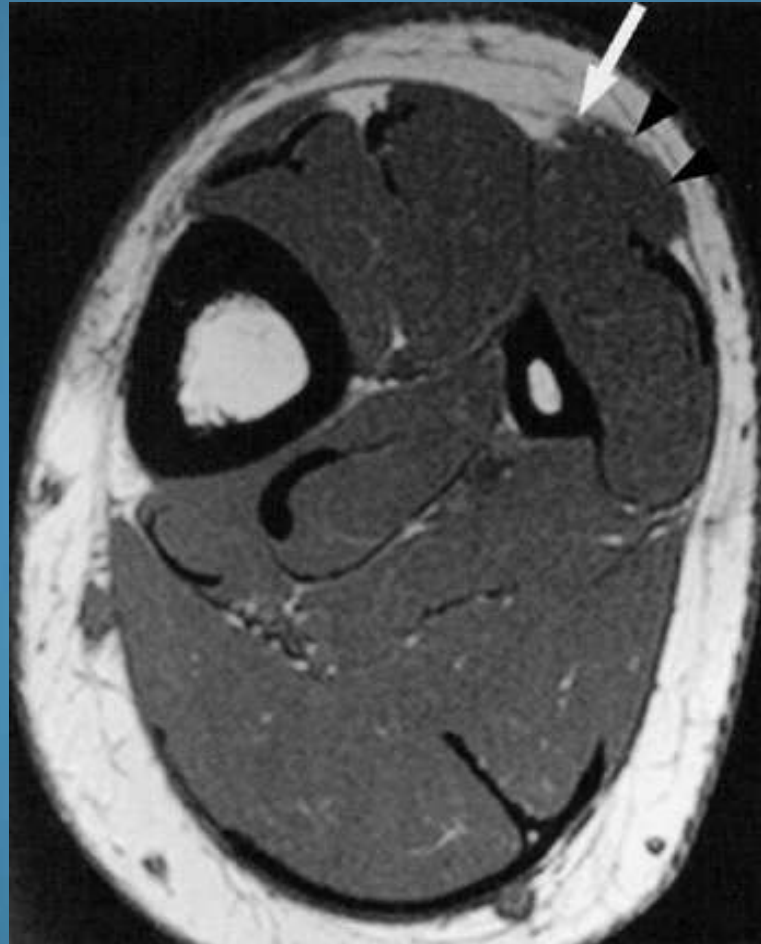- After originating from common peroneal nerve, continues distally in a plane between the anterior and lateral compartment musculature
- Pierces deep fascia (vulnerable site) to become subcutaneous ~10-12 cm above lat. malleolus
- Supplies **peroneus longus** and **peroneus brevis** muscles and sensation to dorsum of foot (except 1st web space supplied by DPN)



Superficial peroneal neuropathy

- Causes
 - Trauma (chronic ankle sprains)
 - Sports-related repetitive injuries
 - Muscle hernias (peroneus longus)
- Clinical
 - Numbness and tingling lateral aspect of the lower leg and dorsum of the foot with sparing of 1st web space
 - Focal pain/tenderness at site where nerve pierces fascia
- MR: focal fascial defect or thickening at characteristic site
- U/S useful for detection of muscle hernias in this region

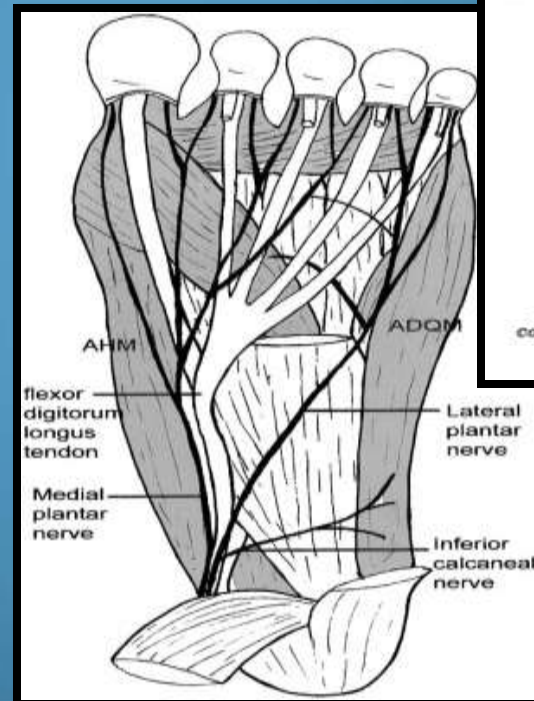
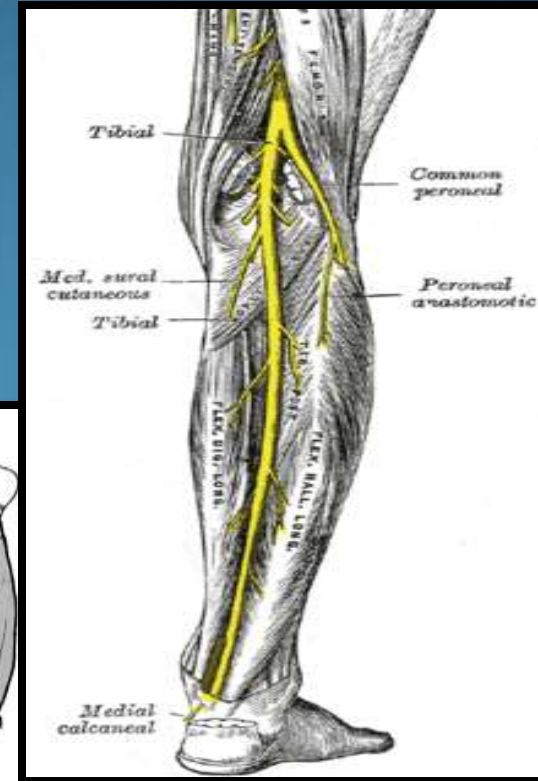
Superficial peroneal neuropathy



Stoller, David W. *Magnetic Resonance Imaging in Orthopaedics and Sports Medicine*, 3rd Edition 2007. Lippincott Williams & Wilkins.

Tibial nerve

- Largest division of sciatic nerve
- Travels with posterior tibial artery and vein (lateral to them)
- Course:
 - Proximally, found between 2 heads of gastrocnemius muscle in popliteal fossa
 - More distally, runs deep to the soleus muscle
 - Near the ankle, courses medially deep to flexor retinaculum to enter tarsal tunnel
- Terminal trifurcation into medial plantar, lateral plantar, and medial calcaneal branches
- Supplies all **posterior compartment muscles of the calf**, majority of the **motor innervation of the foot**, and sensation to sole of foot.



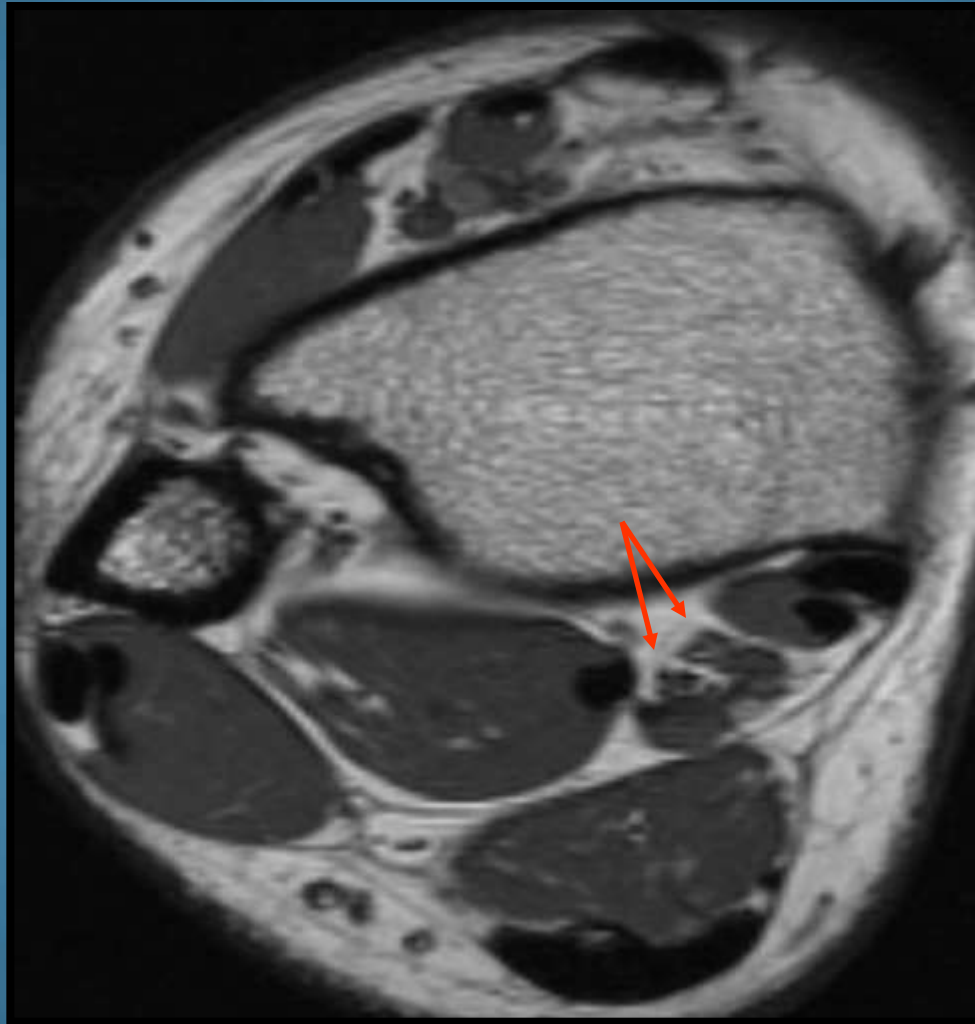
Neuropathies affecting branches of the tibial nerve

- 6 distinct tibial neuropathies:
 - Proximal tibial neuropathy (in the leg)- rare¹
 - Tarsal tunnel syndrome
 - Medial plantar neuropathy
 - Lateral plantar neuropathy
 - Interdigital neuropathy (Morton's neuroma)
 - Medial plantar proper digital neuropathy (Joplin's neuroma)

Tarsal Tunnel Anatomy

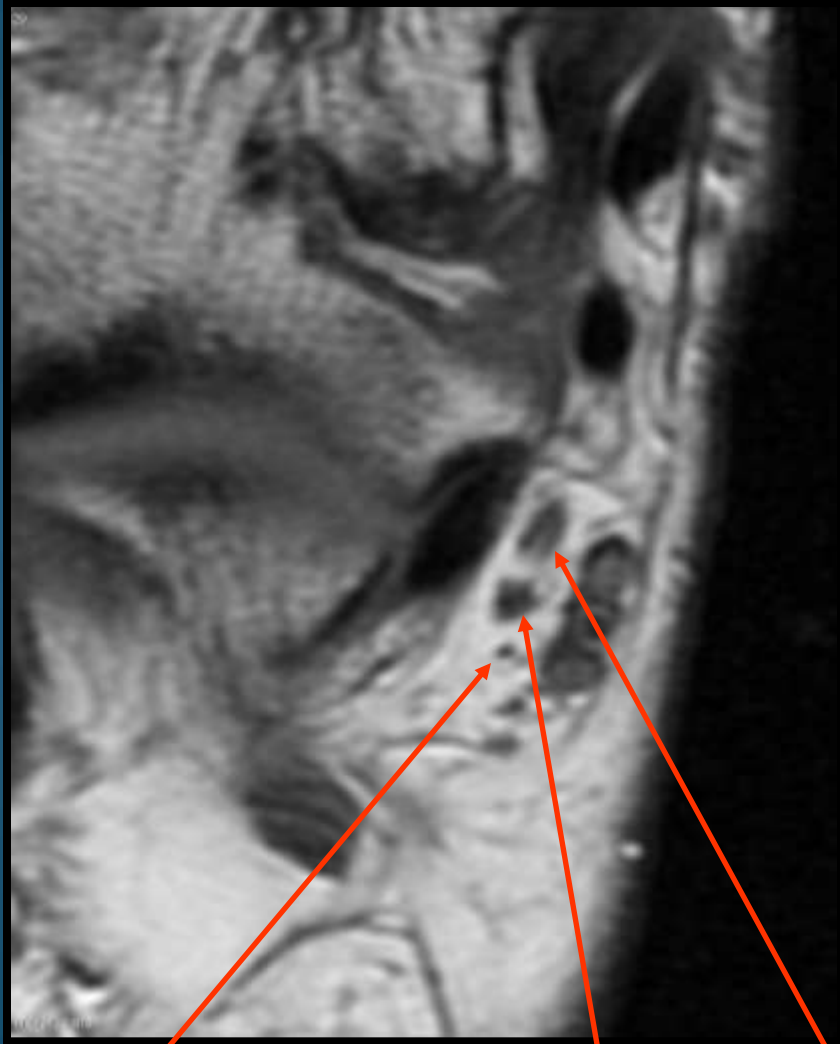
- Fibro-osseous space extending from the posteromedial aspect of the ankle to the plantar aspect of the foot.
- Divided into upper (tibiotalar) and lower (talocalcaneal) portions²
 - Upper tarsal tunnel
 - Covered by the deep aponeurosis of the leg medially
 - Osseous floor formed by the posterior aspect of the tibia and the talus laterally.
 - Contains tendons of TP, FDL, and FHL and posterior tibial neurovascular bundle, with NV bundle lying between “Dick” and “Harry”.
 - Lower tarsal tunnel
 - Covered by flexor retinaculum (created by the fusion of the superficial and deep aponeuroses of the leg) medially
 - Osseous floor formed by the talus and calcaneus laterally.
 - Contains medial and lateral plantar nerves
- Nerves consistently found deep to vessels within tarsal tunnel⁵, with the medial plantar nerve anterior to lateral plantar nerve within tunnel

Upper Tarsal Tunnel



Upper tarsal tunnel, just after bifurcation of tibial nerve into medial and lateral plantar nerves

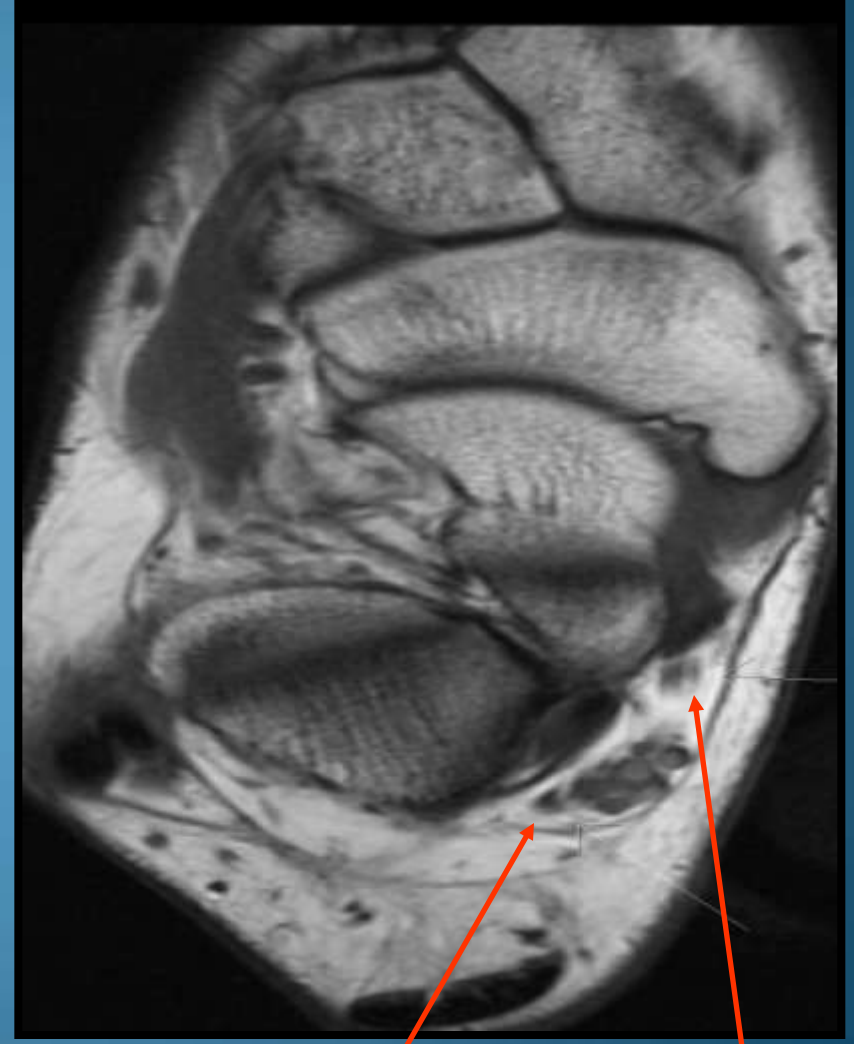
Lower Tarsal Tunnel



Inferior calcaneal
nerve

Lateral plantar
nerve

Medial plantar
nerve



Lateral plantar
nerve

Medial plantar
nerve

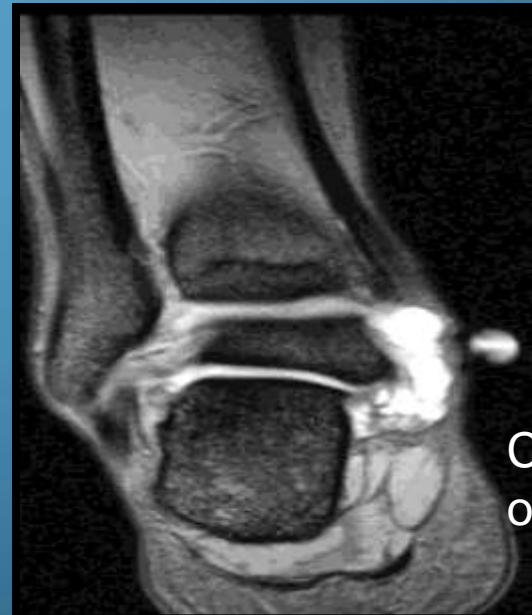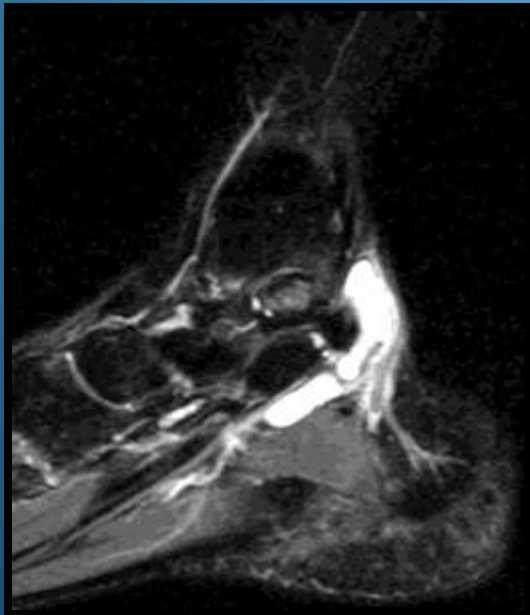
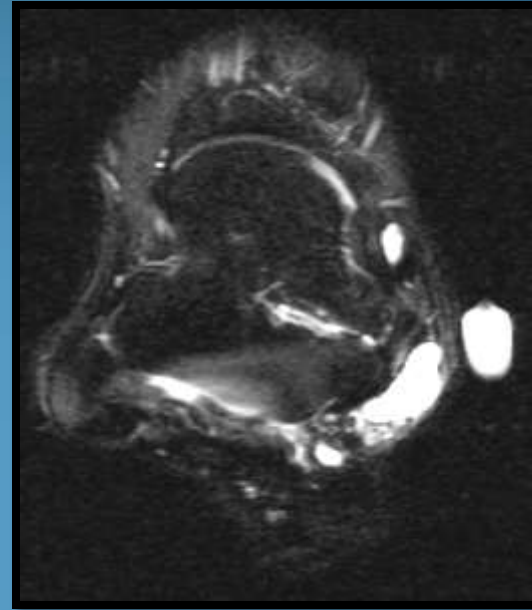
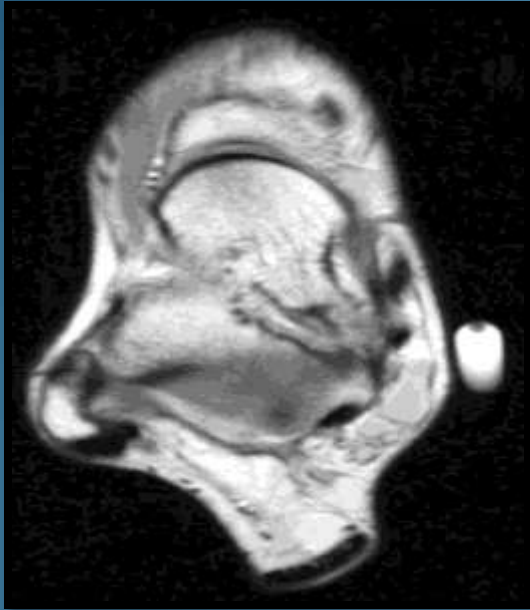
Tarsal tunnel syndrome

- Variety of clinical presentations, related to an individual's nerve anatomy and location/ extent of causative lesions
- Etiology:
 - Trauma (fractures, ankle sprains)
 - Mass lesions (tumors, ganglion cysts, synovial cysts, varicosities)
 - Foot deformities (pes planovalgus, tarsal coalition)
 - Accessory muscles (ie flexor digitorum accessorius longus, accessory soleus)
 - Synovial inflammatory disorders (RA)
 - Idiopathic (20-40%)¹⁴
- Clinical:
 - Burning pain/paresthesias at the plantar aspect of the foot exacerbated by activity
 - Muscle weakness less common and late manifestation
 - Tinel sign: Percussion over the course of the nerve reproduces symptoms
- Treatment: conservative (surgical release of flexor retinaculum in refractory cases)

Role of MR Imaging in Tarsal Tunnel Syndrome

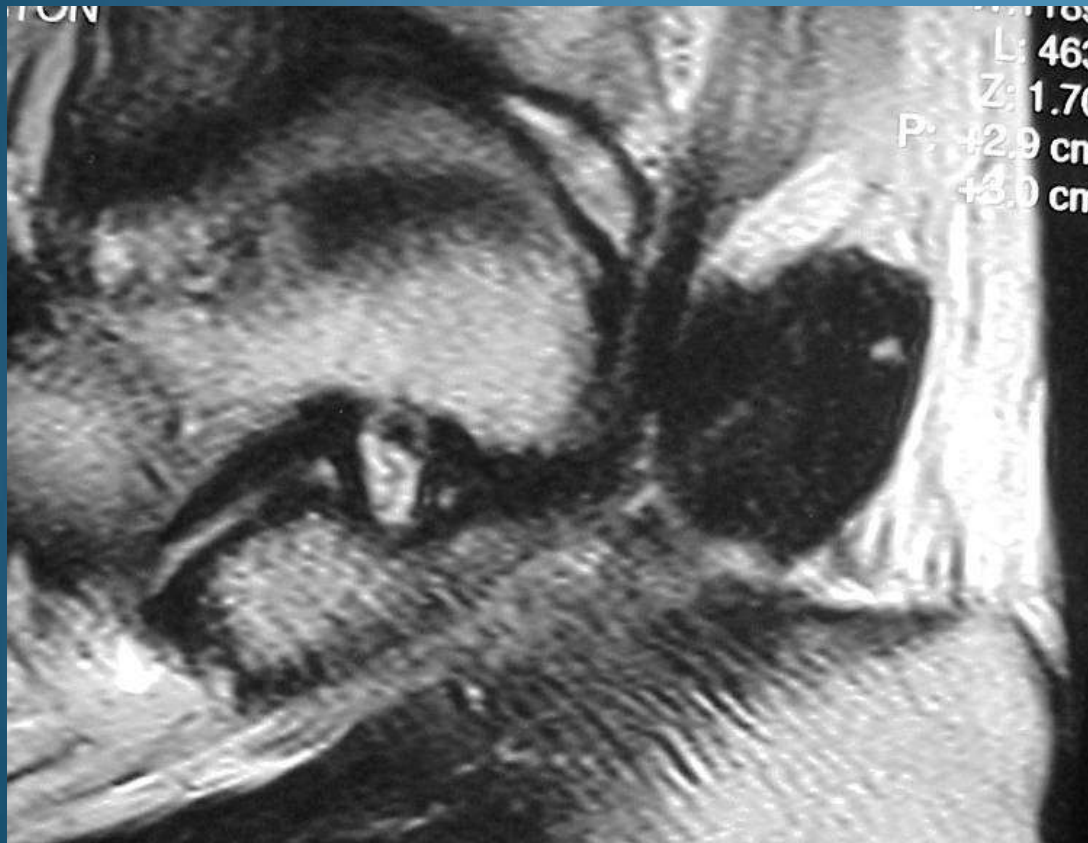
- Identification of space-occupying lesions or accessory muscles within tarsal tunnel
- Nerve displacement and obliteration of fat planes around nerves
- Muscle abnormalities related to denervation should be looked for, but not often detected since syndrome often manifests with sensory deficits only⁵

Tarsal Tunnel Syndrome

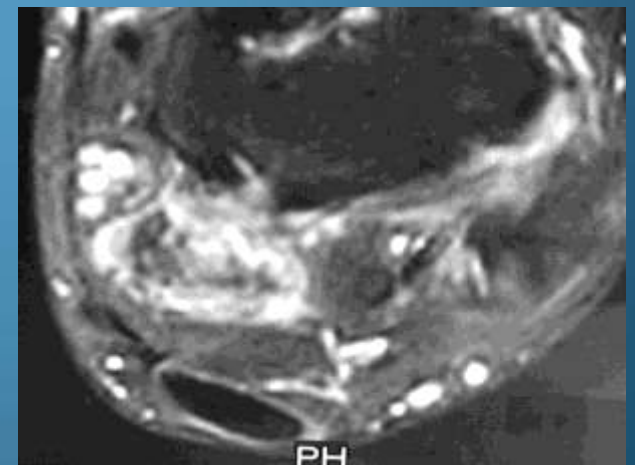
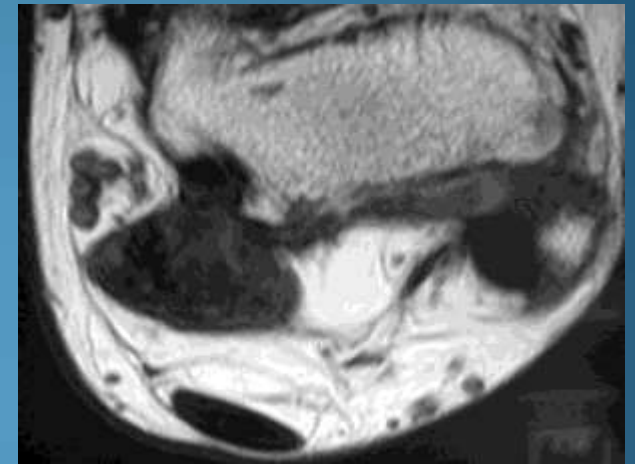


Case Courtesy
of T. Hughes, MD

Tarsal Tunnel Syndrome

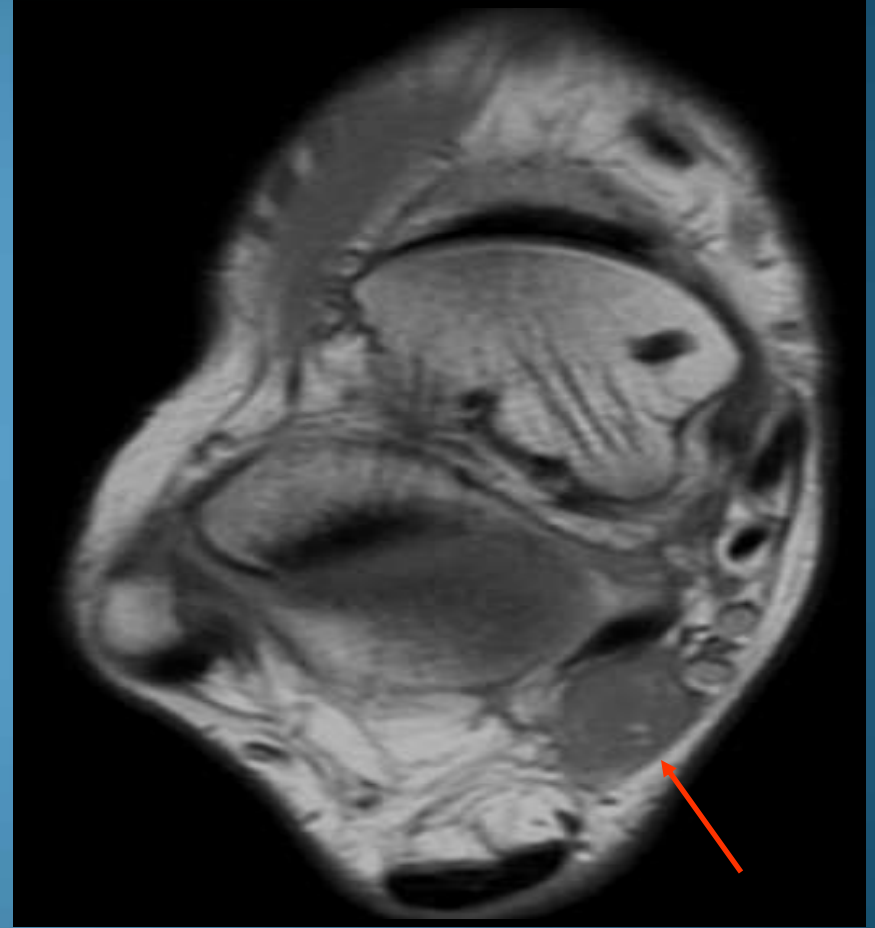
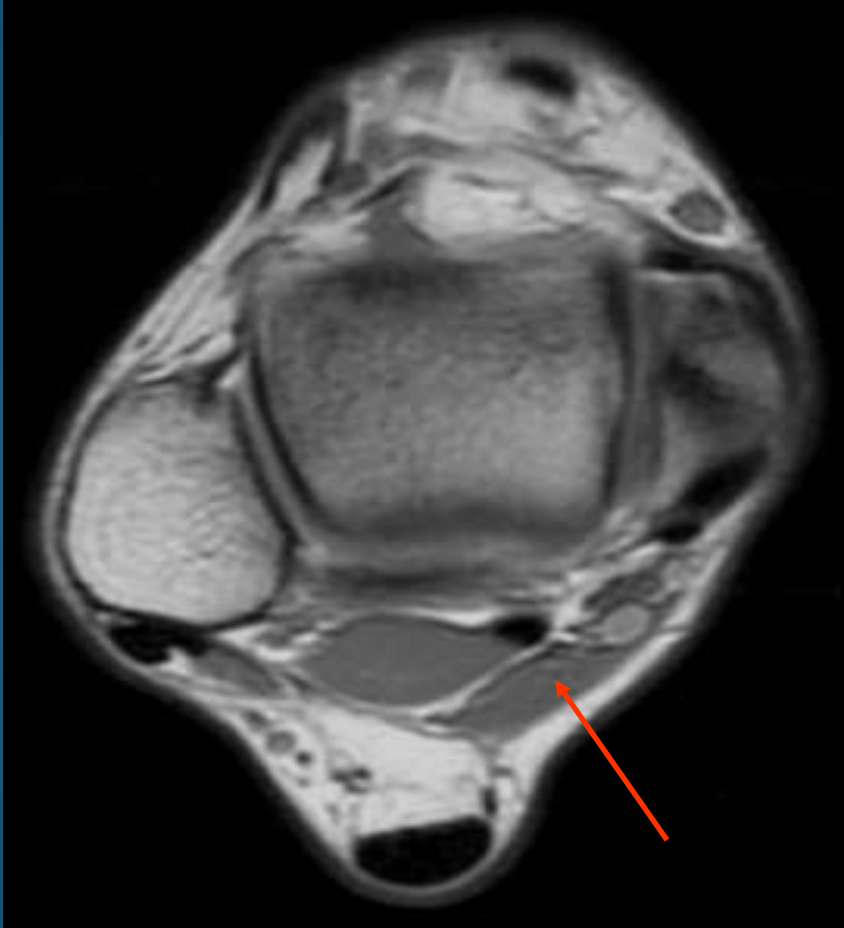


Giant Cell Tumor of Tendon Sheath
of Flexor Hallucis Longus



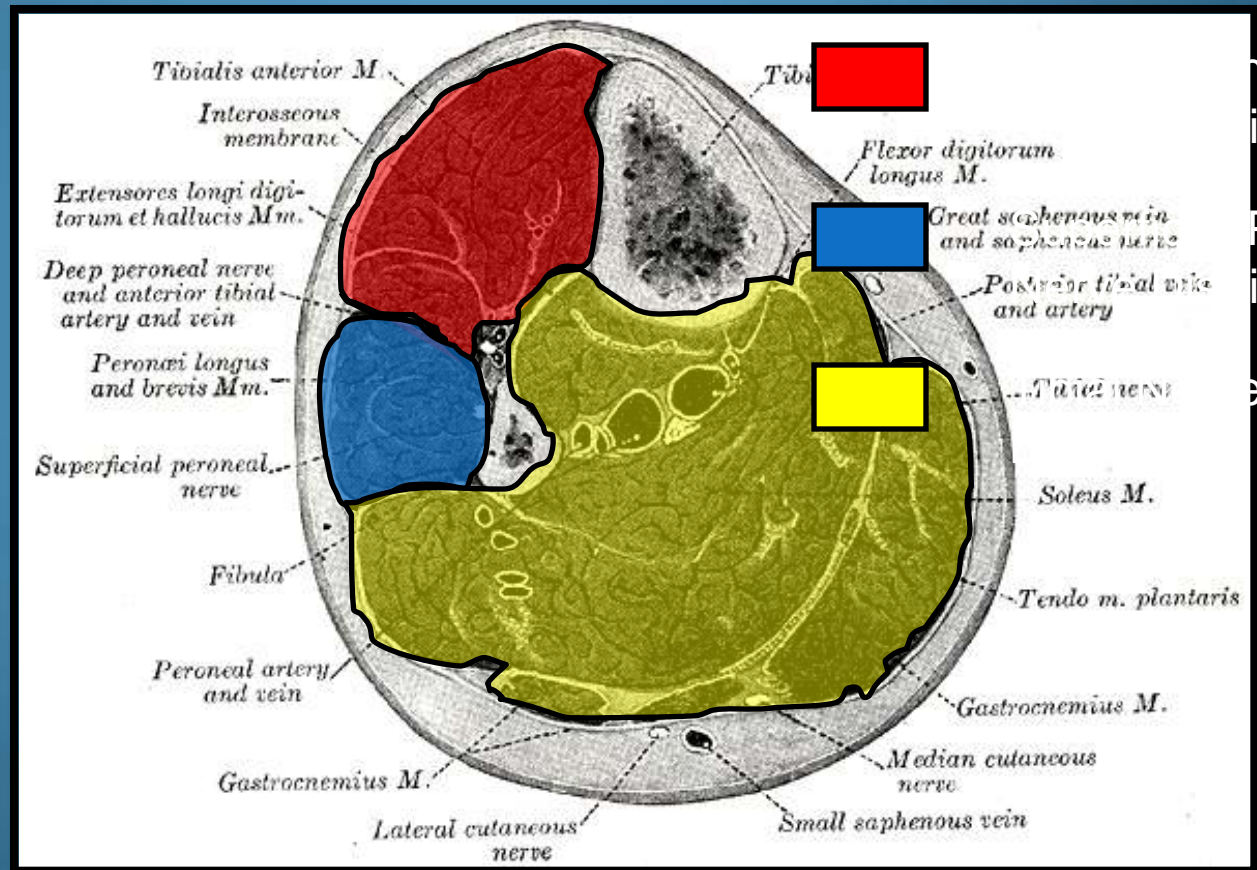
Case courtesy of T. Hughes, MD

Tarsal Tunnel Syndrome



Flexor Digitorum Accessorius Longus (FDAL)
Muscle Within Tarsal Tunnel

Summary

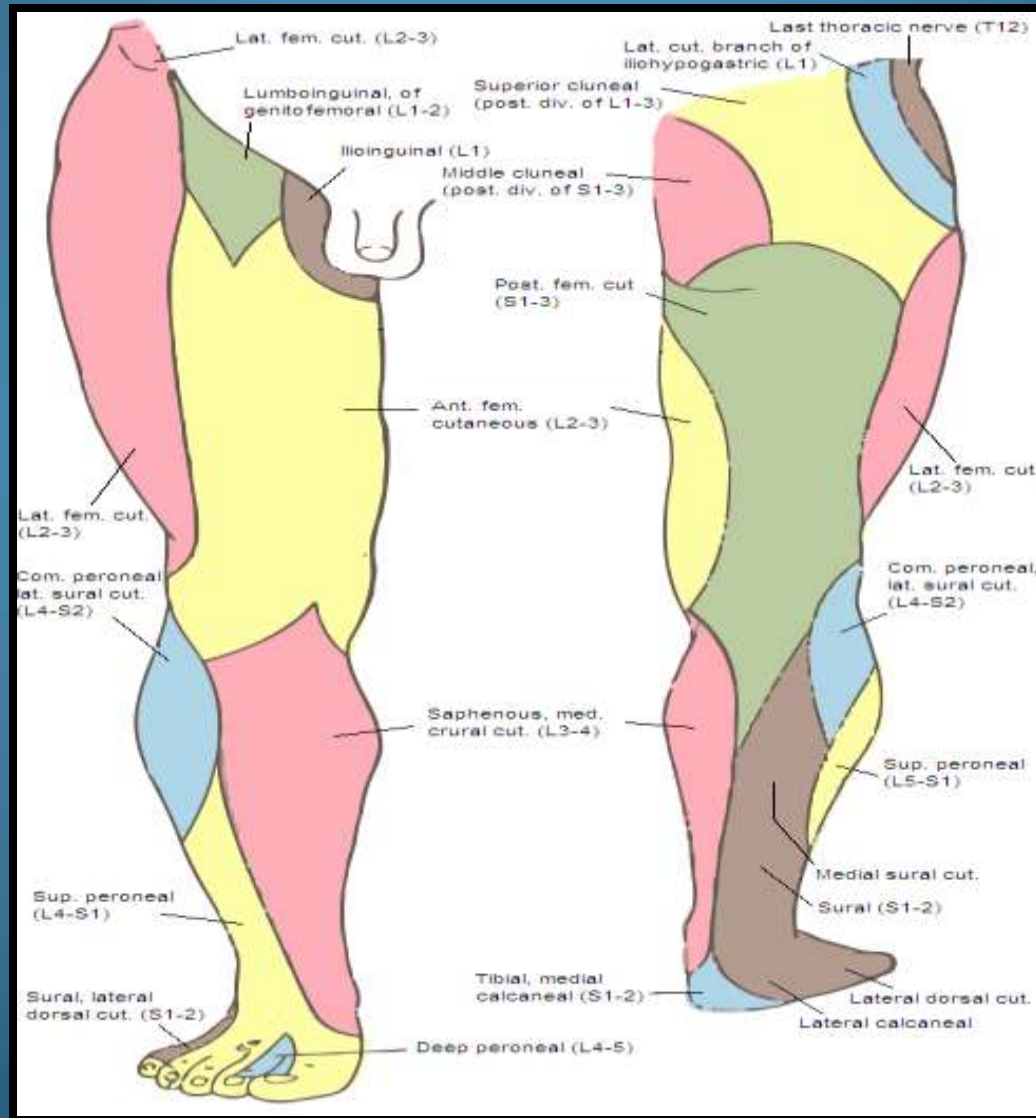


neal
distribution

Peroneal
distribution

e

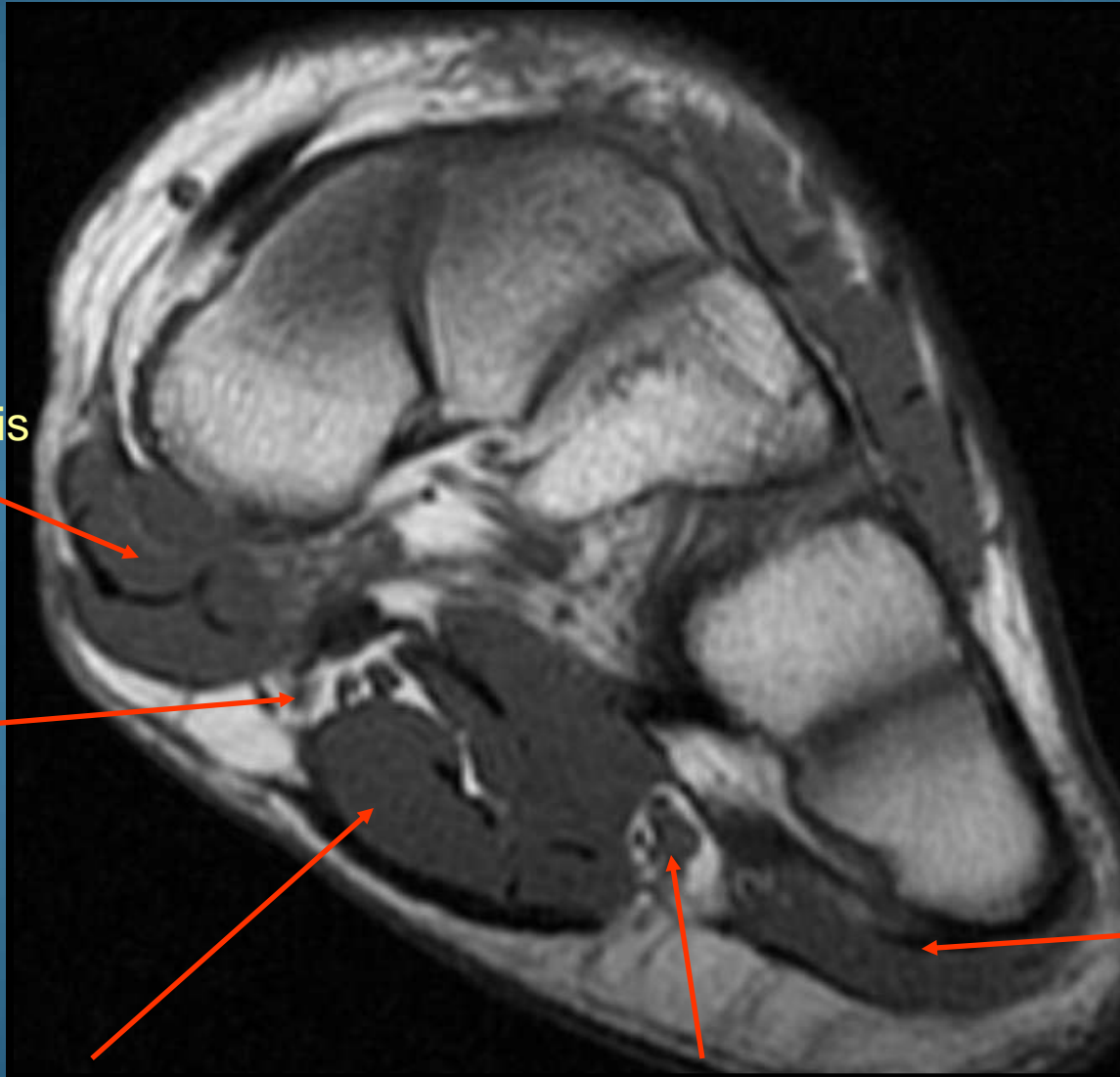
Sensory Innervation of the Lower Extremity



Trifurcation of Tibial Nerve

- **Medial calcaneal nerve**
 - Supplies sensory innervation to medial aspect of heel
- **Medial plantar nerve**
 - Supplies sensation to medial two thirds of the sole of the foot and motor supply to 4 muscles (**FDB, abductor hallucis, FHB, and 1st lumbrical**)
 - Intimate with FDL and FHL at master knot of Henry
- **Lateral plantar nerve**
 - Supplies sensation to the lateral one third of the sole of the foot and motor innervation to most of the remaining foot muscles (**abductor digiti minimi, quadratus plantae, flexor digiti minimi brevis, adductor hallucis, all interossei, 2nd-4th lumbricals**)
 - Gives rise to inferior calcaneal (Baxter's) nerve to **abductor digiti minimi**

Plantar Aspect of Foot



Abductor hallucis
muscle

Medial plantar
nerve

Flexor digitorum
brevis muscle

Lateral plantar
nerve

Abductor digiti
minimi muscle

Trifurcation of Tibial Nerve- Variations

- Tibial nerve bifurcation into medial and lateral plantar nerves occurs within the tarsal tunnel (95%) vs. proximal to tarsal tunnel (5%)¹⁴
 - Proximal bifurcation may predispose to tarsal tunnel syndrome¹⁵
- Medial calcaneal nerve originates within tarsal tunnel in 60% vs. proximal to tarsal tunnel in 40%¹³

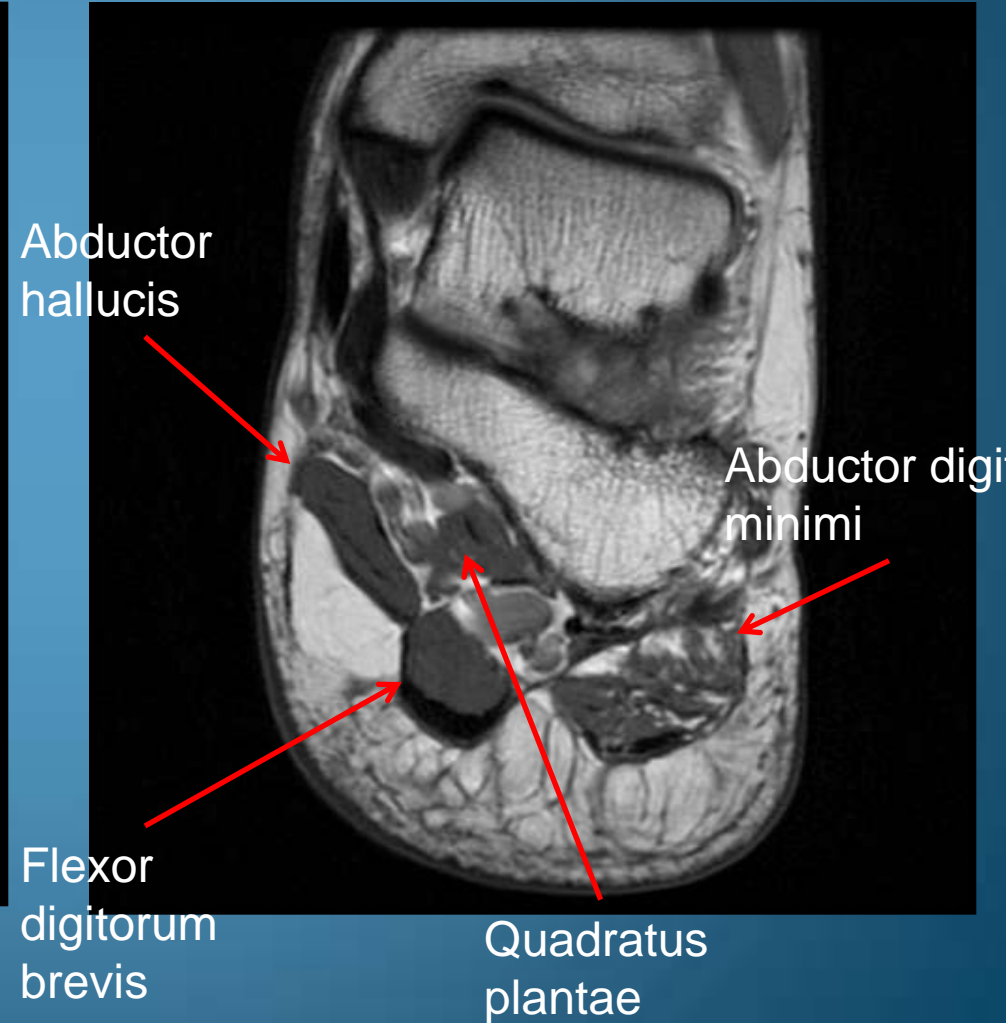
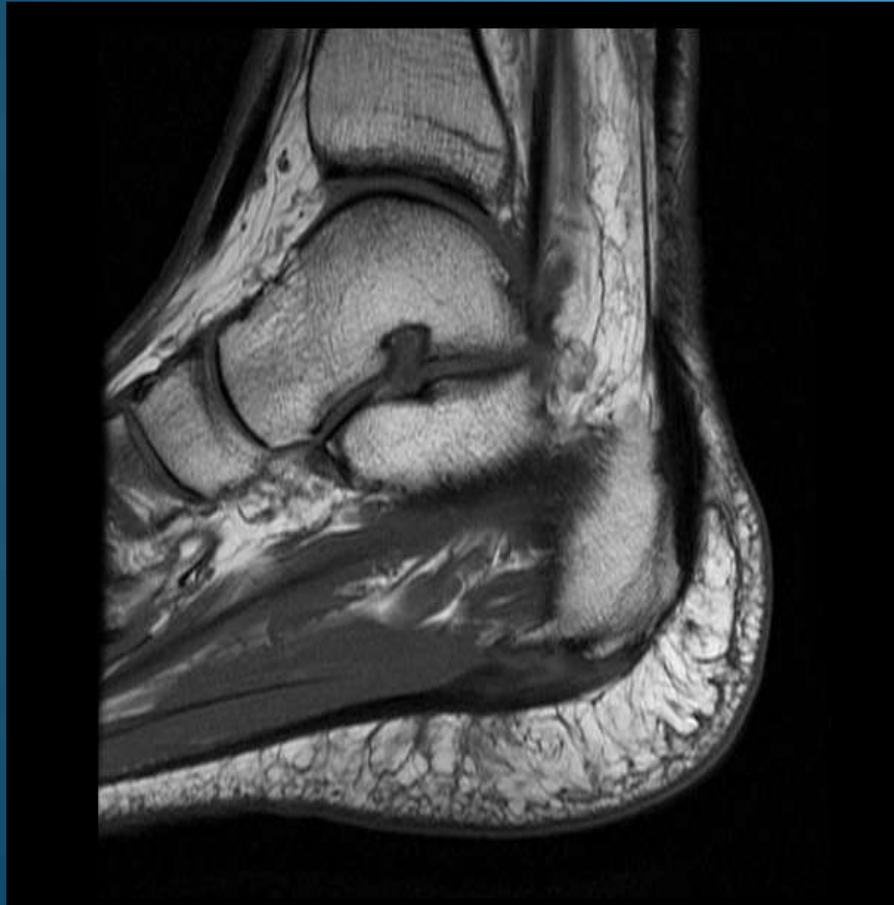
Medial Plantar Neuropathy (Jogger's Foot)

- Entrapment of medial plantar nerve beneath the talus and navicular bones in the region of the master knot of Henry
- Often associated with tenosynovitis at master knot
- Predisposing factors: running with excessive pronation or high medial arch
- Clinical: Burning plantar foot pain radiating towards 1st and 2nd toes
- MR: Edema or atrophy of the abductor hallucis and flexor digitorum brevis muscles, with sparing of abductor digiti minimi

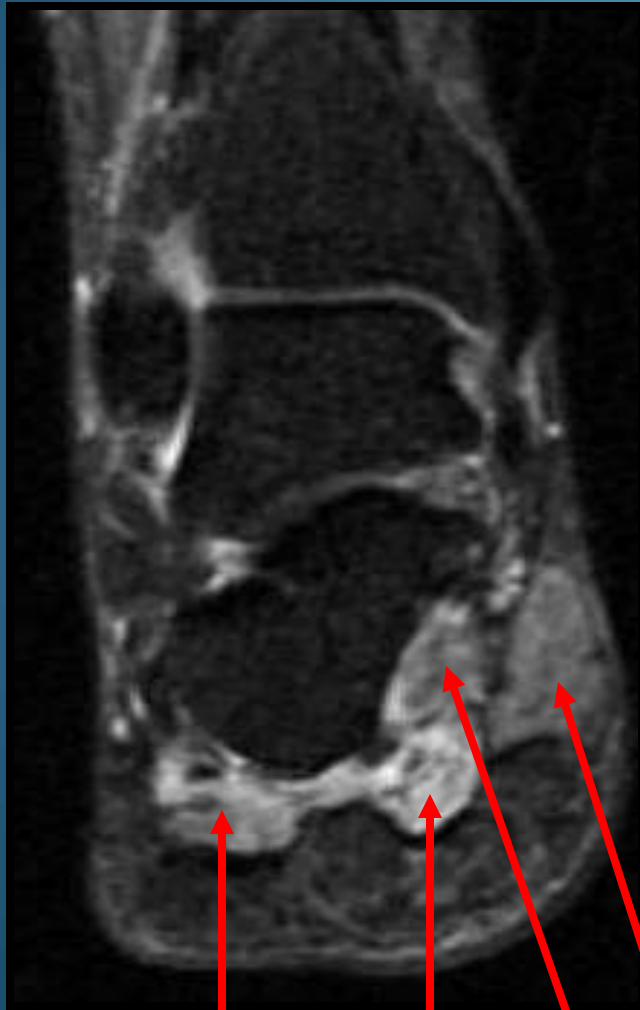Medial Calcaneal, Lateral Plantar, and Inferior Calcaneal Neuropathy

- Collectively within spectrum of Jogger's Heel
- Presents with intractable burning heel pain
- Often associated with plantar fasciitis
- Subtype: Inferior calcaneal (Baxter's) neuropathy
 - Common
 - Increased prevalence in athletes (runners)
 - Isolated atrophy of abductor digiti minimi (common, often detected incidentally)

Jogger with Heel Pain



Jogger's Heel (Lateral Plantar Neuropathy)

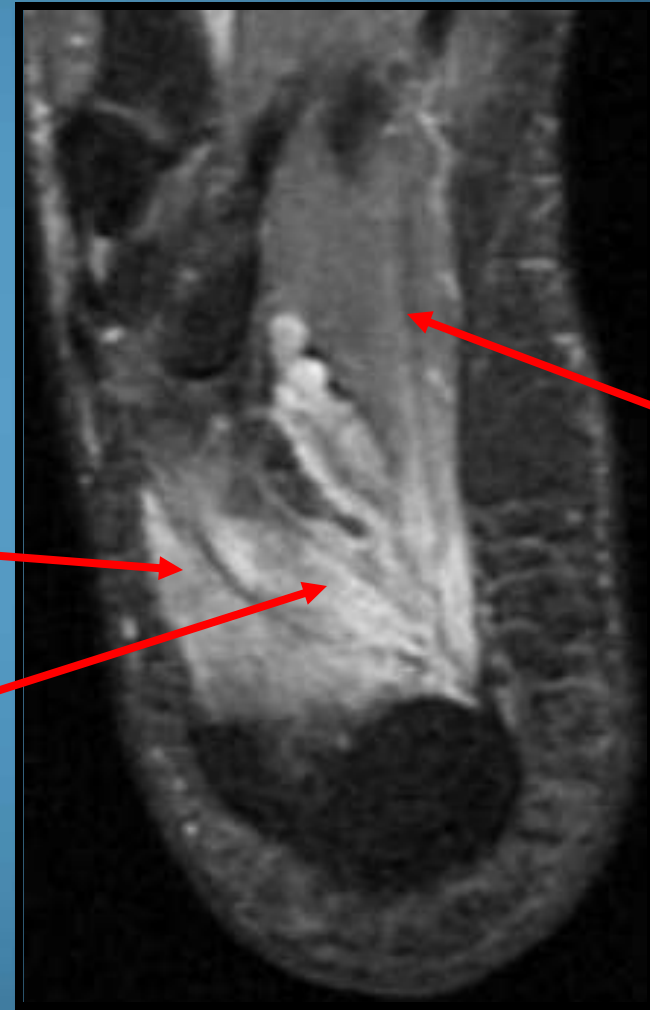

AbDM

FDB

QP

AbH



AbDM

FDB

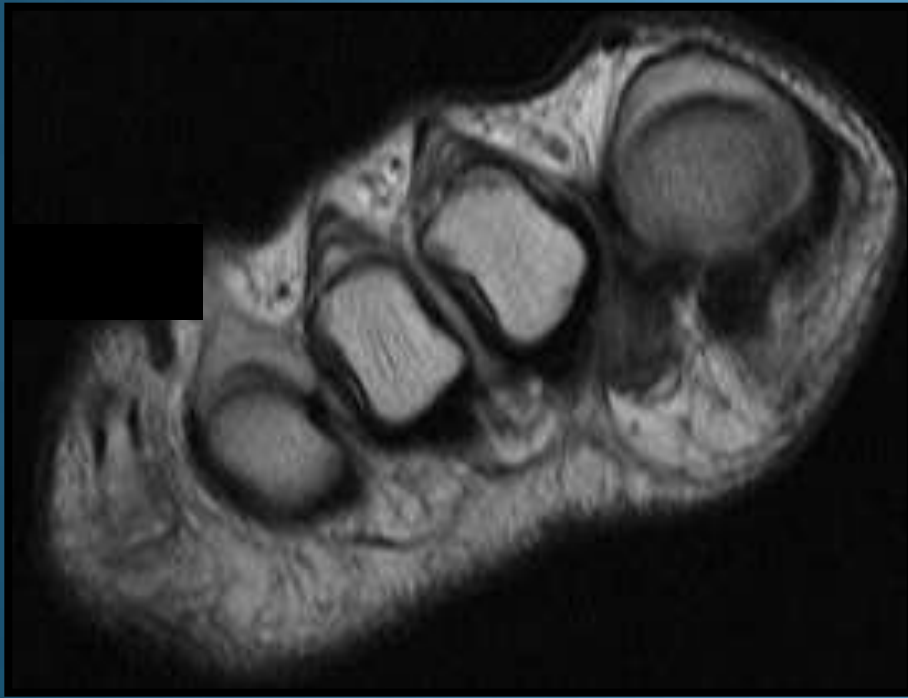AbH

Case courtesy of T. Hughes, MD

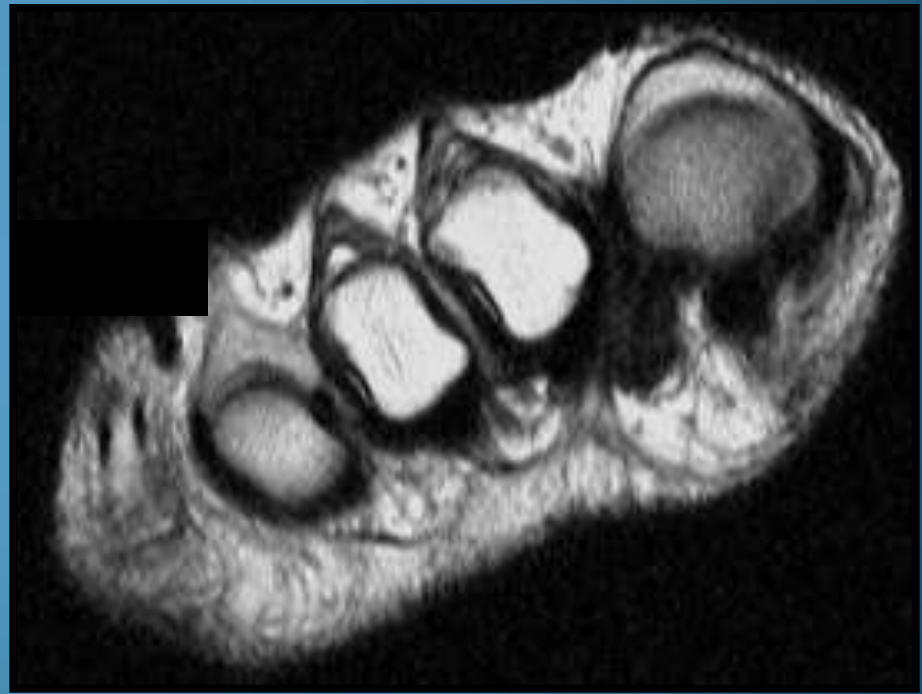Interdigital Nerves

- Terminal branches of medial and lateral plantar nerves
- Course in interspaces between toes
 - MPN- supplies 1st, 2nd, and 3rd interspaces
 - LPN- supplies 4th interspace
- Pathology common at the level of the metatarsal heads beneath the deep transverse metatarsal ligaments
- Interdigital nerve between 3rd and 4th toes most commonly affected
- Chronic nerve injury may result in interdigital neuromas
- Neuromas > 5 mm in diameter more likely to be clinically significant¹⁶
- Well imaged with MR and U/S
- Tx: orthotic devices, steroid injections, surgical excision

Interdigital Neuroma



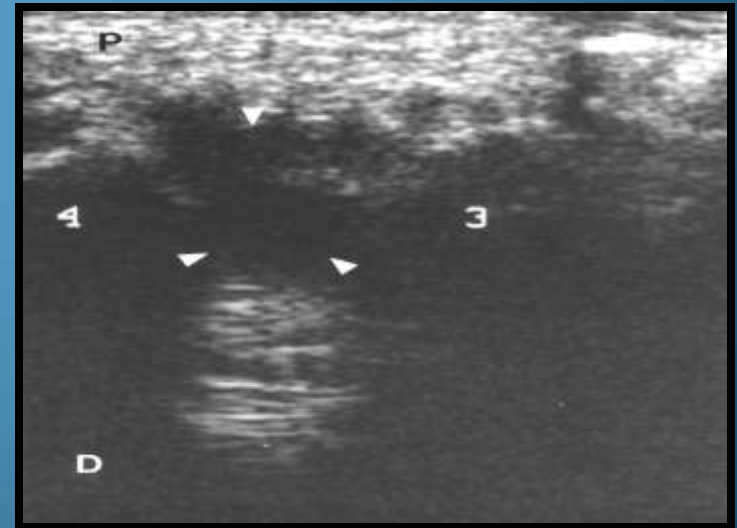
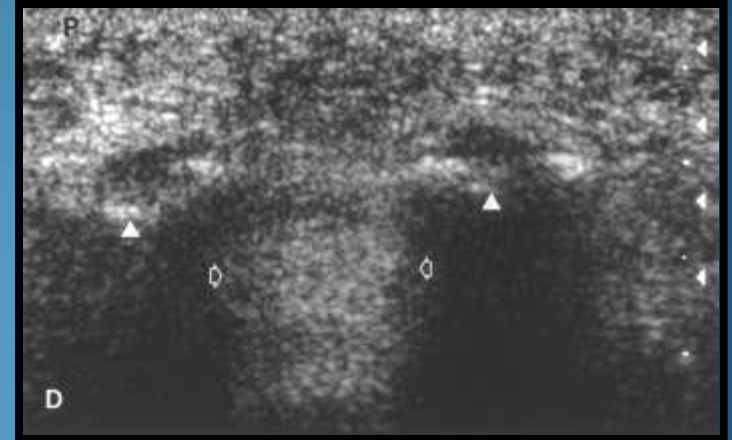
PDWI



T2WI

Interdigital Neuromas- Ultrasound

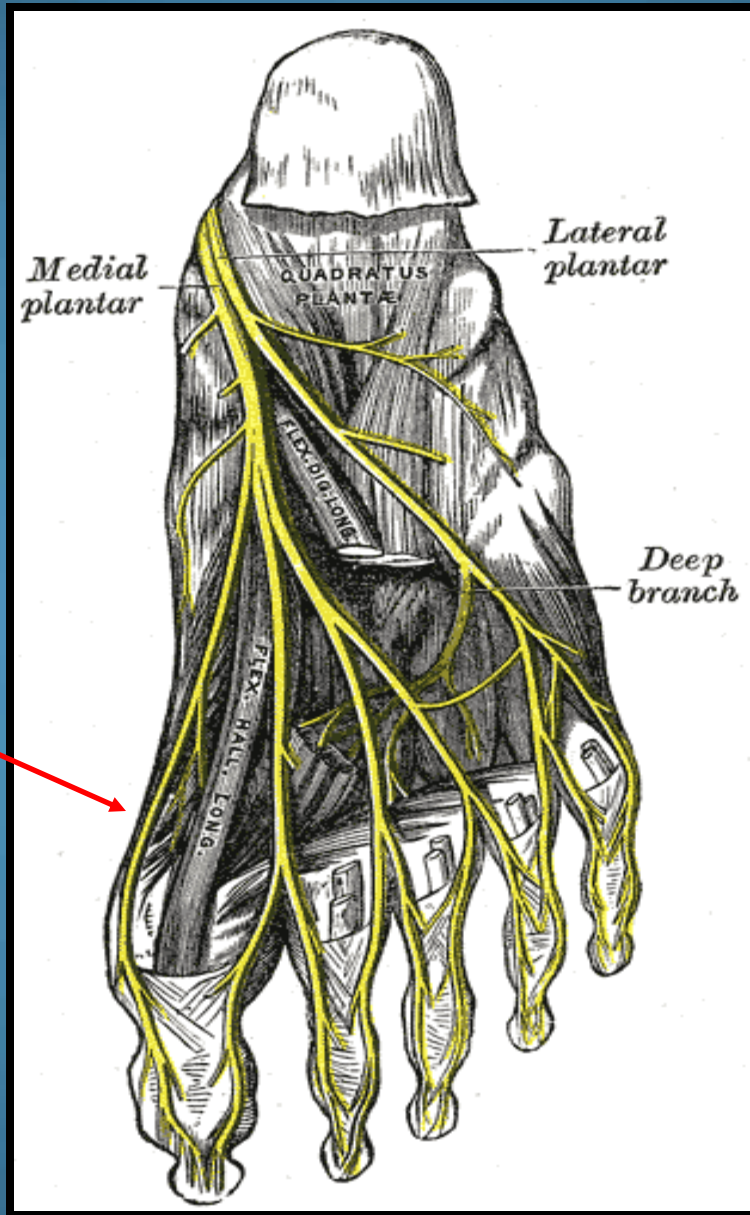
- Reported sensitivity of 85-98%²¹
- Seen as hypoechoic intermetatarsal mass with or without visible contiguity with nerve
- Often see associated intermetatarsal bursal fluid



Quinn, et al. AJR
2000; 174 (6): 1723.

Joplin's Neuroma

- Neuropathy of the plantar proper digital nerve to the great toe (terminal sensory branch arising from the medial plantar nerve)
- Supplies innervation to the medial side of the great toe
- Etiology:
 - abnormal pronation of foot
 - acute or repetitive trauma (poorly fitting shoes)
 - often associated with bunion formation
- Clinical: Burning pain and/or “cord” sensation in the *medial* plantar aspect of great toe

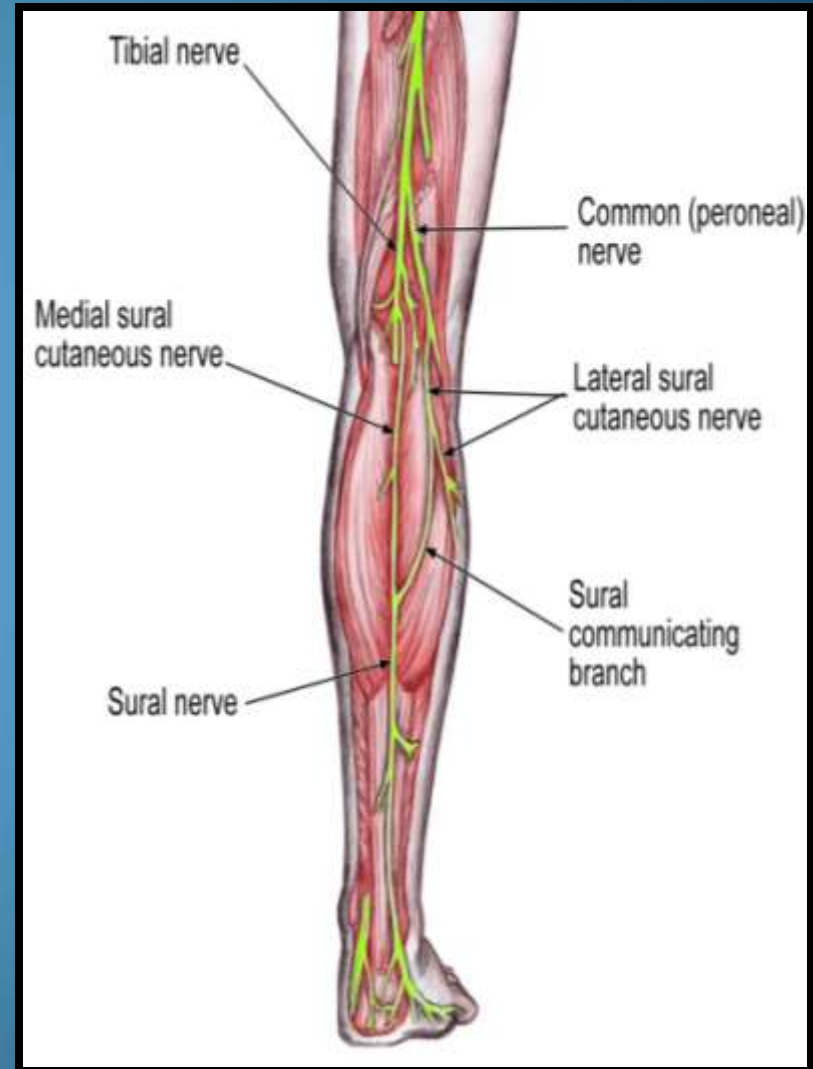


Plantar proper
Digital nerve

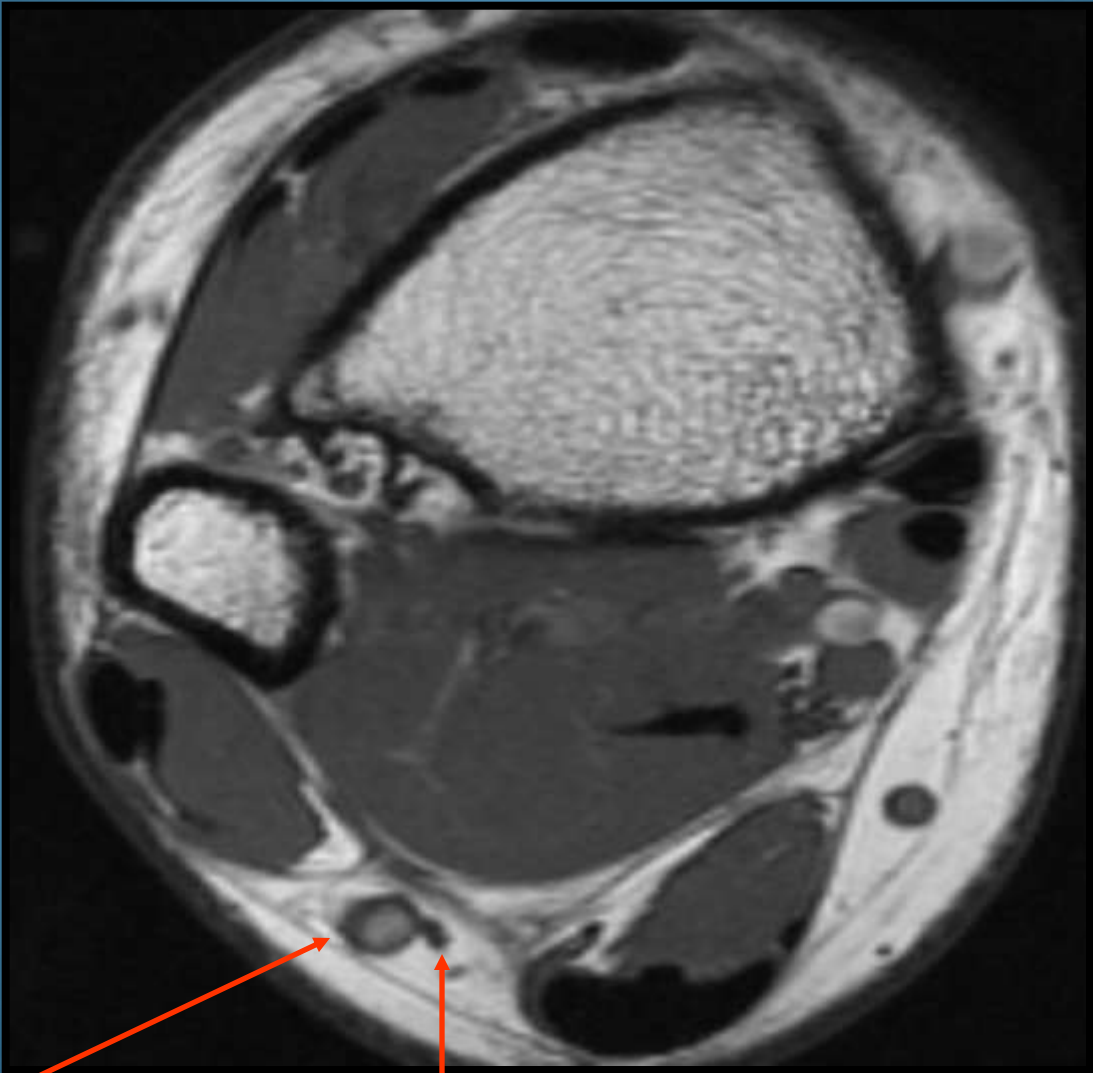


Just a few more nerves...

- Sural nerve
 - Purely sensory nerve
 - Formed by merger of medial sural cutaneous nerve (branch of the tibial nerve) and the lateral sural cutaneous nerve (branch of the common peroneal nerve)⁴
 - Courses along the calf lateral to the Achilles tendon and posterior to the peroneal tendons behind the lateral malleolus
 - Supplies a strip of sensation on the lateral aspect of the ankle and foot
 - Most commonly becomes entrapped following traumatic injury



Sural nerve- Imaging Anatomy

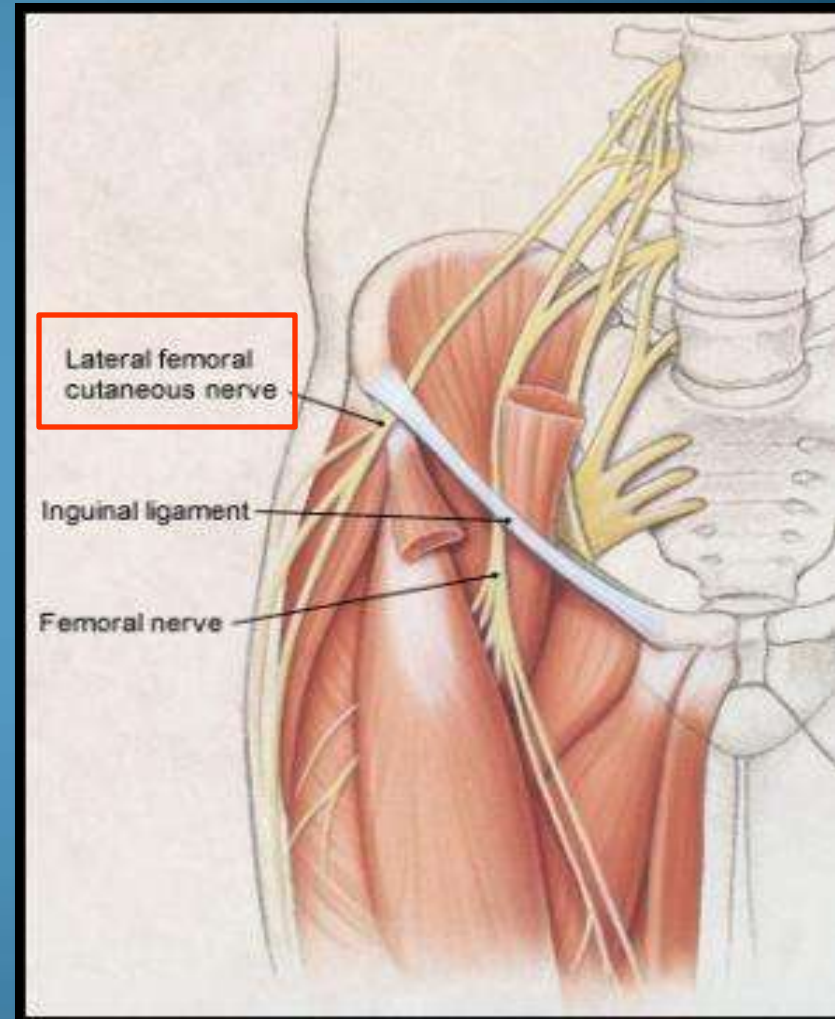


Lesser saphenous vein

Sural nerve

Lateral Femoral Cutaneous Nerve

- Purely sensory nerve originating from the L2 and L3 nerve roots
- Course:
 - Sits anterior to iliacus muscle before diving beneath the inguinal ligament at the ASIS (vulnerable site)
 - Runs anterior to tensor fascia lata more distally
- Supplies sensation to lateral thigh
- Entrapment → *meralgia paresthetica*
 - Burning pain and numbness in the lateral thigh
- Clinical diagnosis (rarely diagnosed by imaging)



Gluteal nerves

- Superior gluteal nerve
 - Originates from L4 and L5 nerve roots
 - Exits pelvis via suprapiriform foramen to supply gluteus medius, gluteus minimus and tensor fascia lata muscles
 - Nerve compromise → trendelenburg gait
- Inferior gluteal nerve
 - Originates from S1 and S2 nerve roots
 - Exits pelvis via infrapiriform foramen (along with sciatic nerve) to supply gluteus maximus muscles

Key points

- All nerves of the lower extremity originate from the lumbosacral plexus
- 3 major nerves:
 - Femoral nerve supplies quadriceps muscle group
 - Obturator nerve supplies adductor muscle group
 - Sciatic nerve supplies hamstrings and (via the tibial and common peroneal branches) nearly all motor and sensory innervation below the knee
- Knowledge of nerve anatomy and common sites of entrapment greatly enhances understanding of neuropathic syndromes

Thank you!



References

1. Resnick D, Kang HS, Pretterklieber ML. *Internal Derangements of Joints*, 2nd Ed. 2007. Elsevier Inc.
2. Delfaut EM, Demondion X, Bieganski A, Thiron MC, Mestdagh H, Cotton A. *Imaging of Foot and Ankle Nerve Entrapment Syndromes: From Well-demonstrated to Unfamiliar Sites*. *RadioGraphics* 2003; 23: 613-623
3. Martinoli, et al. *US of Nerve Entrapments in Osteofibrous Tunnels of the Upper and Lower Limbs*. *Radiographics* 2000; 20: S199-S217.
4. Standring S et al. *Gray's Anatomy : The Anatomical Basis of Clinical Practice*. New York : Elsevier Churchill Livingstone, 2005 Edition 39th ed.
5. Stoller, David W. *Magnetic Resonance Imaging in Orthopaedics and Sports Medicine*, 3rd Edition Copyright ©2007 Lippincott Williams & Wilkins.
6. Hunter LY, et al. *The saphenous nerve: its course and importance in medial arthrotomy*. *Am J Sports Med* 1979; 7(4):227-330.
7. Yukata et al. *Case Report: Obturator Neuropathy Caused by an Acetabular Labral Cyst: MRI Findings*. *AJR* 2005; 184 (3): S112.

References

8. Yuen EC, So YT. *Sciatic neuropathy*. *Neurol Clin* 1999; 17(3):617-631.
9. Fanucci E, et al. *CT-guided injection of botulinum toxin for percutaneous therapy of piriformis muscle syndrome with preliminary MRI results about denervative process*. *Eur Radiol* 2001; 11(12):2543-2548.
10. Aprile I, Caliandro P, La Torre G. *Multicenter study of peroneal mononeuropathy: clinical, neurophysiologic, and quality of life assessment*. *J Peripher Nerv Syst* 2005; 10:259–268.
11. La Rocca Vieira et al. *MRI of the Distal Biceps Femoris Muscle: Normal Anatomy, Variants, and Association with Common Peroneal Entrapment Neuropathy*. *AJR* 189; 3: 549. (2007).
12. Loredó, et al. *MRI of the Common Peroneal Nerve: Normal Anatomy and Evaluation of Masses Associated with Nerve Entrapment*. *Journal of Computer Assisted Tomography* 1998; 22(6):925-931.
13. Oh SJ, Meyer RD. *Entrapment neuropathies of the tibial (posterior tibial) nerve*. *Neurol Clin* 1999; 17(3):593-615.
14. Lau JTC, Daniels TR. *Tarsal Tunnel syndrome: A review of the literature*. *Foot Ankle* 1999; 20:201.

References

15. Dellon AL, Mackinnon SE. *Tibial nerve branching in the tarsal tunnel*. Arch Neurol 1984; 41:645.
16. Bencardino J, Rosenberg ZS, Beltran J, et al. *Morton's neuroma: Is it always symptomatic?* AJR 2000; 175:649.
17. <http://emedicine.medscape.com/article/1234809-overview> "Nerve Entrapment Syndromes of the Lower Extremity"
18. <http://emedicine.medscape.com/article/83199-overview> "Nerve Block, sural: eMedicine Clinical Procedures of the Lower Extremity"
19. Morrison C, Dalsing M. Signs and symptoms of saphenous nerve injury after greater saphenous vein stripping: prevalence, severity, and relevance for modern practice. Journal of Vascular Surgery November 2003; 38(5):
20. Spinner RJ et al. *The Clock Face Guide to Peroneal Intranerual Ganglia: "Critical Times" and Sites for Accurate Diagnosis*. Skeletal Radiology 2008;37:1091-1099.
21. Quinn, et al. *Sonography of Morton's Neuromas*. American Journal of Radiology 2000; 174 (6): 1723.