

# Evaluation of hip trauma and review of classifications

Alexander Ho

UCSD musculoskeletal radiology

3.29.2012

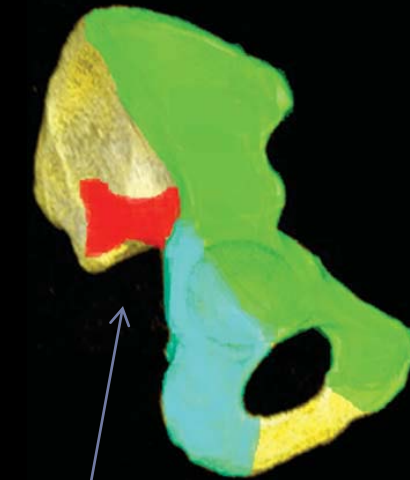
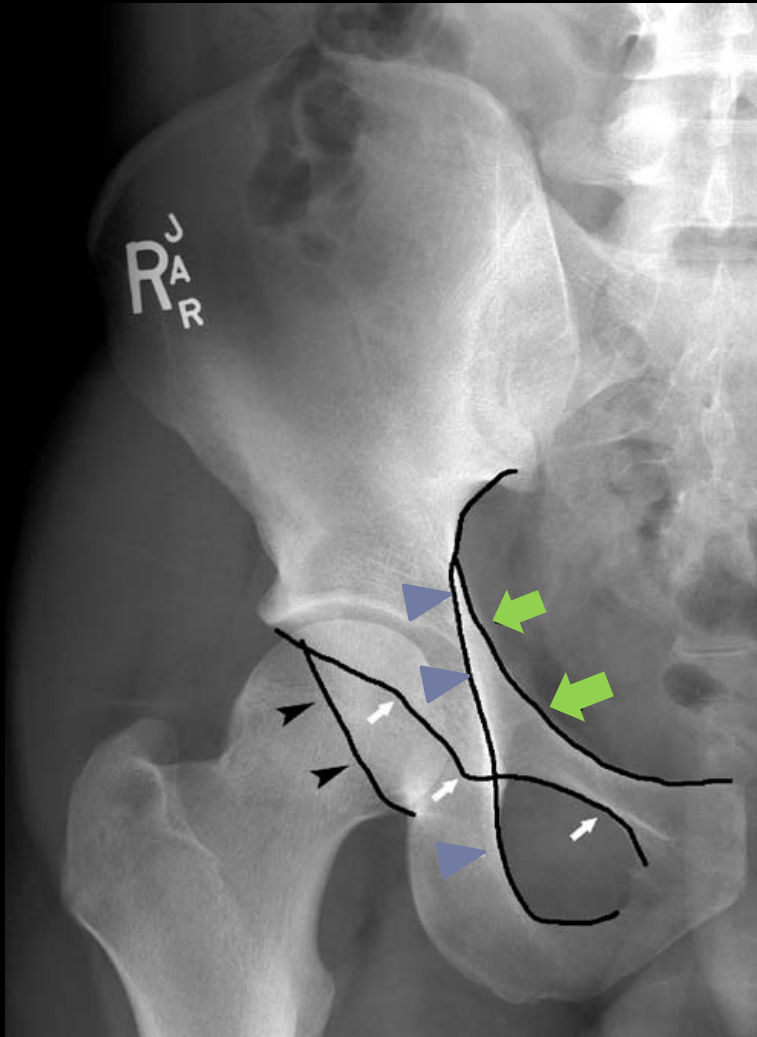
# Hip trauma

---

- ▶ Evaluation of pelvic radiographs
  - ▶ AP
  - ▶ Judet
- ▶ Role of CT
  
- ▶ Acetabular fractures
  
- ▶ Hip dislocations
  
- ▶ Femoral head fractures



# Radiographs - AP Pelvis



Sciatic buttress

Judet and Letournel

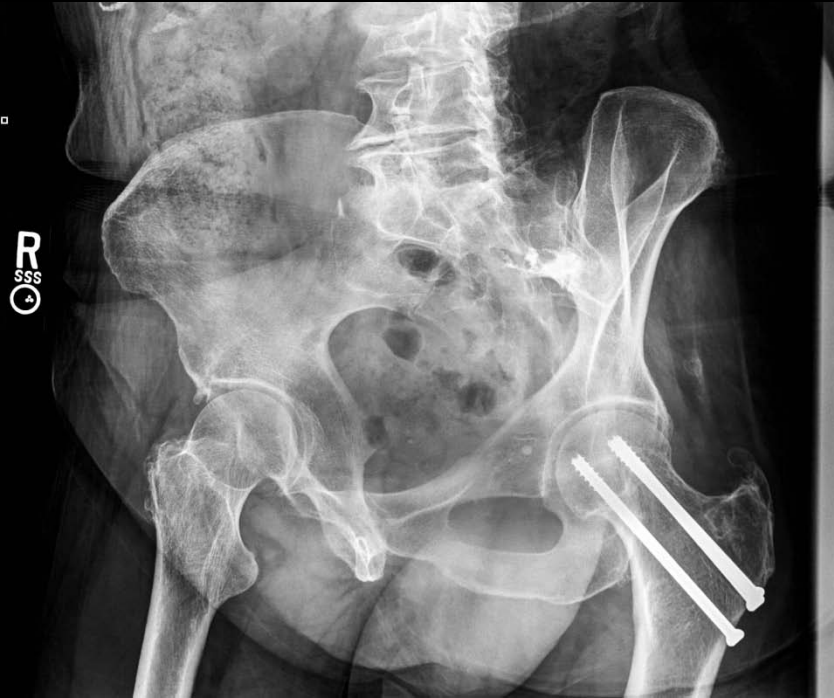- ▶ Initial injury, post-op f/u
- ▶ Acetabulum
  - ▶ Anterior wall
  - ▶ Posterior wall
- ▶ Iliopectineal line
  - ▶ anterior column
- ▶ Ilioischial line
  - ▶ posterior column



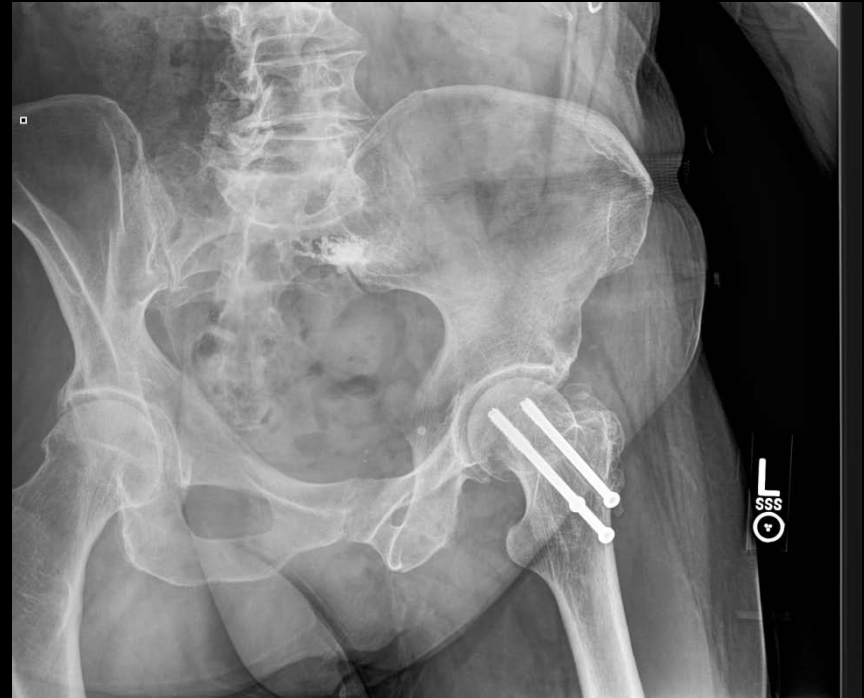
# Judet views

## Iliac/obturator oblique views

---



Right iliac oblique view  
Left obturator oblique view



Left iliac oblique view  
Right obturator oblique view

---





# Role of CT in hip trauma

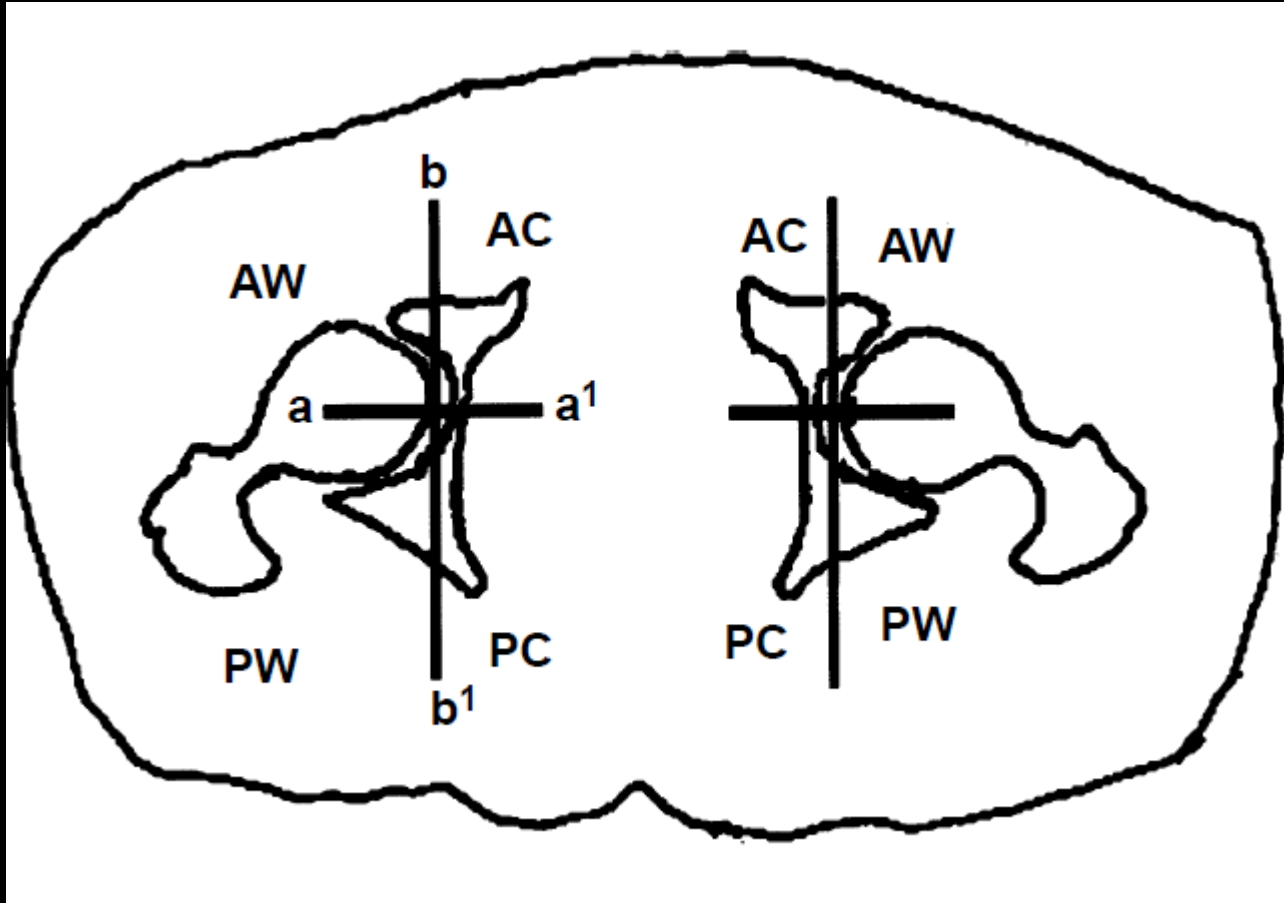
---

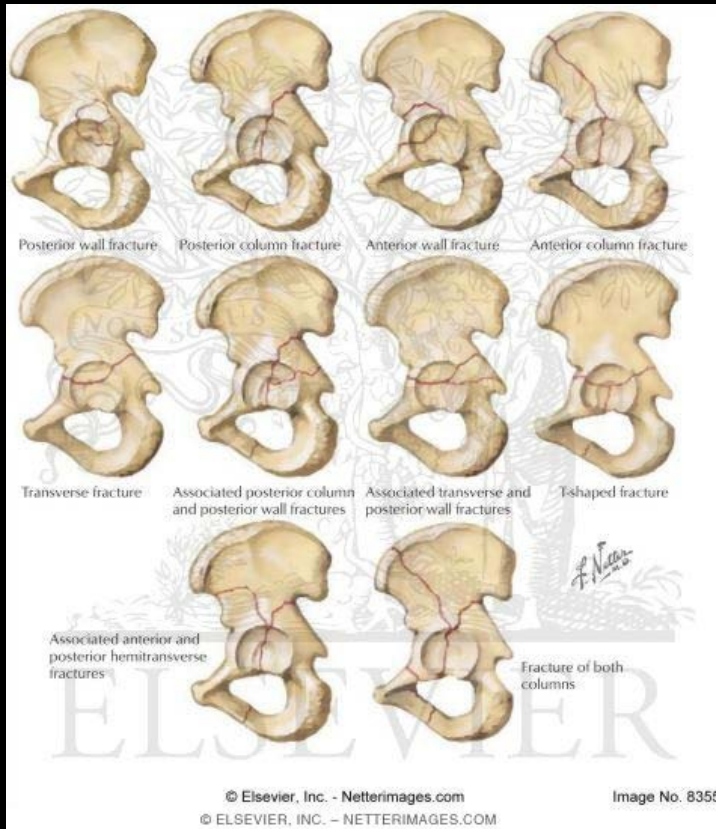
- ▶ For Pelvic Fractures
  - ▶ Detailed imaging of:
  - ▶ Fracture orientation and extent
  - ▶ Joint congruency, step-offs, gaps
  - ▶ Entrapped osteochondral fragments
  - ▶ (usually associated with other injuries)
  - ▶ Soft tissue injury; sciatic nerve course
  
- ▶ For Hip Dislocations
- ▶ Most helpful after hip reduction
  - ▶ Evaluate for:
  - ▶ Nondisplaced fractures
  - ▶ Size of fracture fragments
  - ▶ Joint congruency after reduction
  - ▶ Intra-articular fragments



# Acetabular wall vs. column on CT

---





# Acetabular fractures

# Letournel - Judet

What is the principal fracture line orientation?

**Table 3** Radiographic features of acetabular fracture types

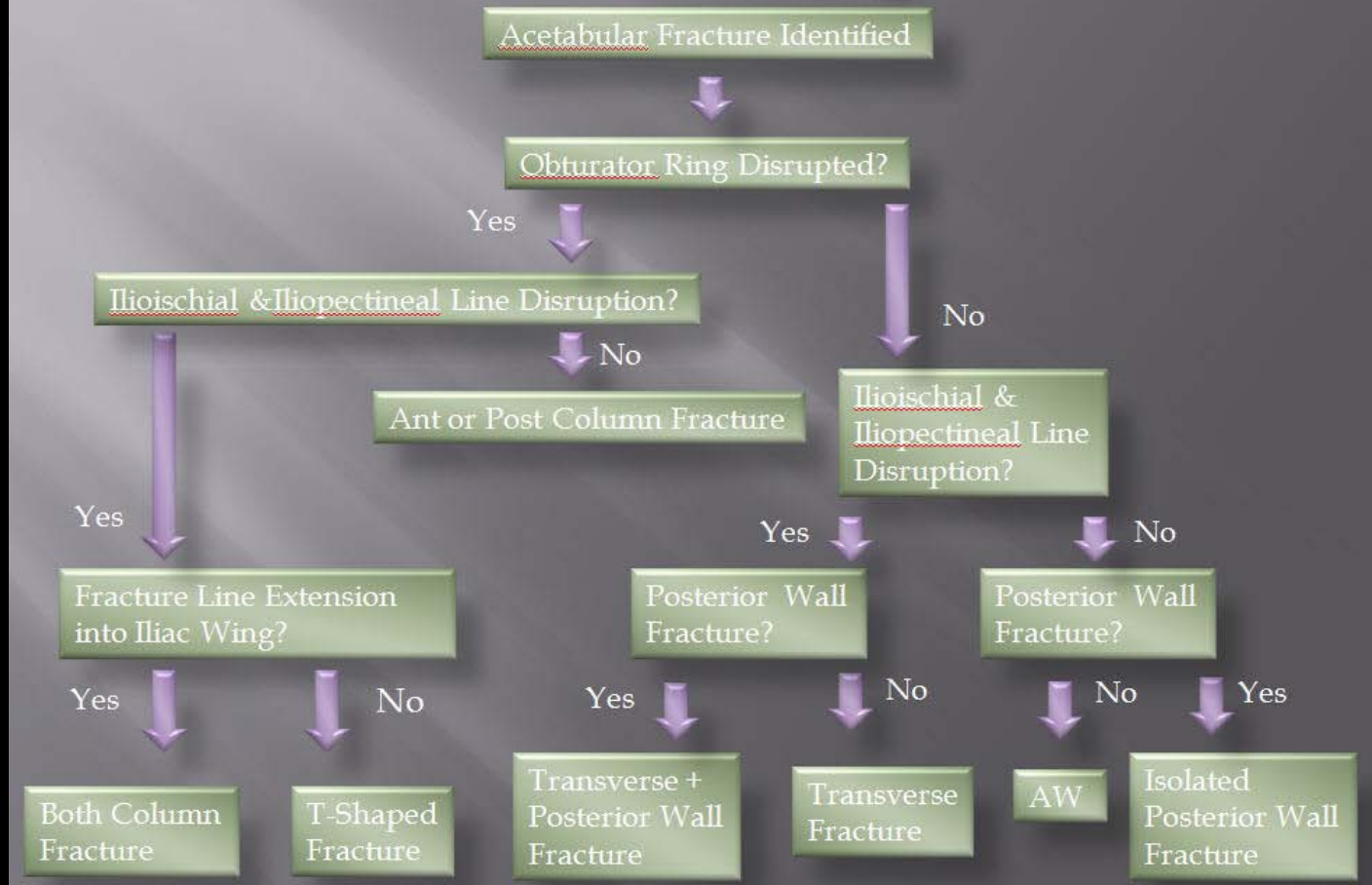
Type of fracture	Obturator ring FX	Ilioischial line disrupted	Iliopectineal line disrupted	Iliac wing FX	Posterior wall FX	Pelvic FX extension	Spur sign	Axial CT FX orientation
Both column	Yes	Yes	Yes	Yes	No	Anterior–posterior	Yes	Coronal
Anterior column	Yes	No	Yes	Yes	No	Anterior–posterior	No	Coronal
Posterior column	Yes	Yes	No	No	No	Anterior–posterior	No	Coronal
Posterior column with posterior wall	Yes	Yes	No	No	Yes	Anterior–posterior	No	Coronal and oblique
T-shaped	Yes	Yes	Yes	No	No	Superior–inferior	No	Sagittal
Transverse with posterior wall	No	Yes	Yes	No	Yes	Superior–inferior	No	Sagittal and oblique
Transverse	No	Yes	Yes	No	No	Superior–inferior	No	Sagittal
Posterior wall	No	Various	No	No	Yes	No	No	Oblique
Anterior wall	No	No	Yes	No	No	No	No	Oblique
Anterior column with posterior hemitransverse	No	Yes	Yes	Yes	No	N/A	No	N/A

Adapted from [24]. Reprinted with permission from the American Journal of Roentgenology.  
FX Fracture

# Acetabular Fracture Classification

## Letournel - Judet

### Classification Algorithm



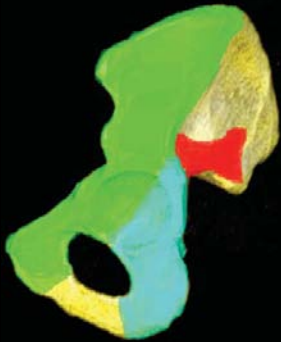
Not all fractures will fit into this classification

# Acetabular Fracture Classification x 2

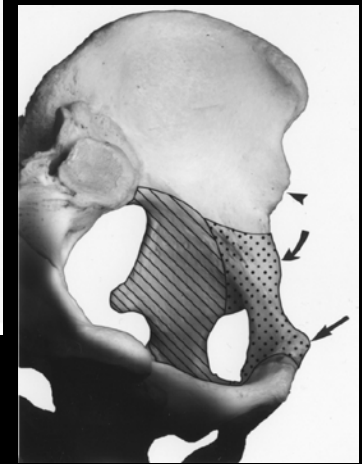
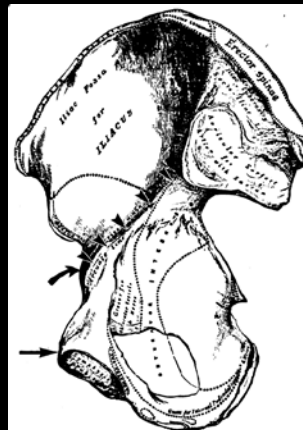
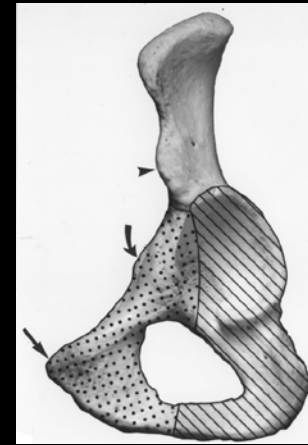
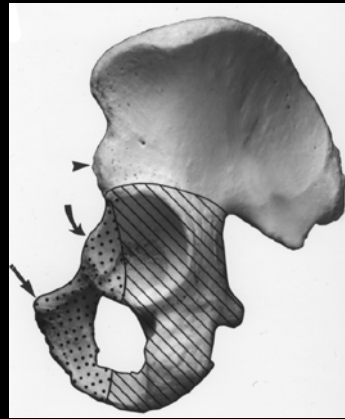
## Anatomy – redefining the anterior column

---

- ▶ 1 - Letournel – Judet
- ▶ Based on radiographs



- ▶ 2 – Harris – Coupe
- ▶ Based on axial CT images



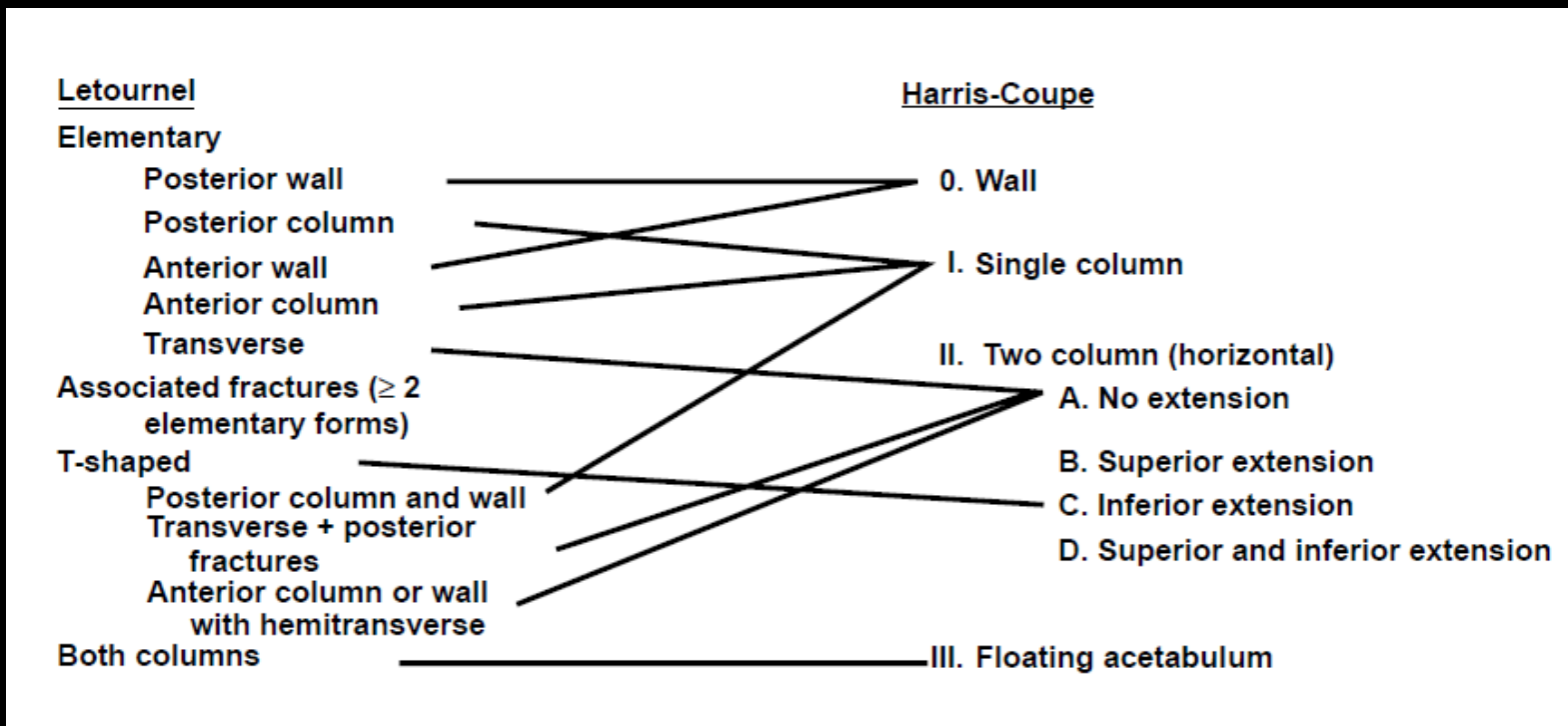
Harris, et al AJR 2004



# Acetabular Fracture Classification

- ▶ 1 - Letournel – Judet
  - ▶ Based on radiographs

- ▶ 2 – Harris – Coupe
  - ▶ Based on axial CT images



# Most common fractures

---

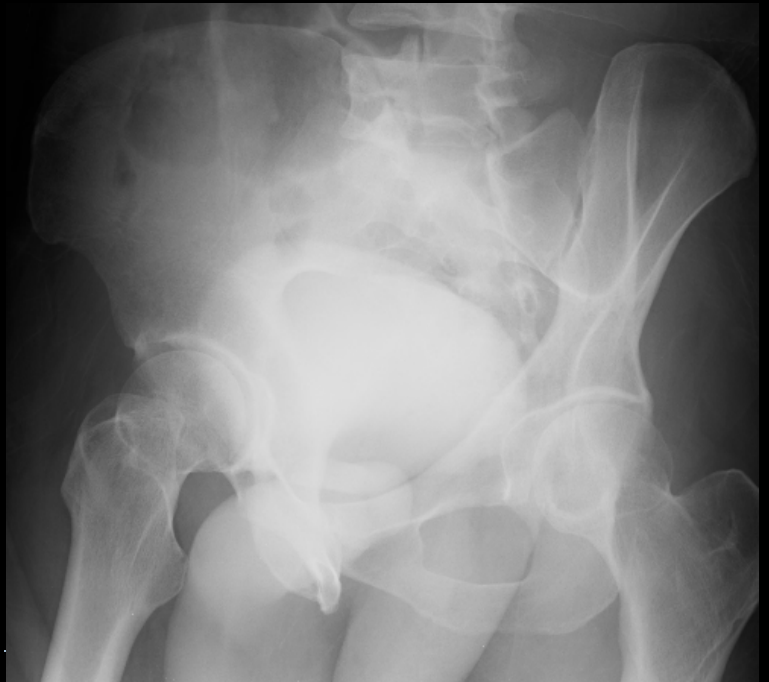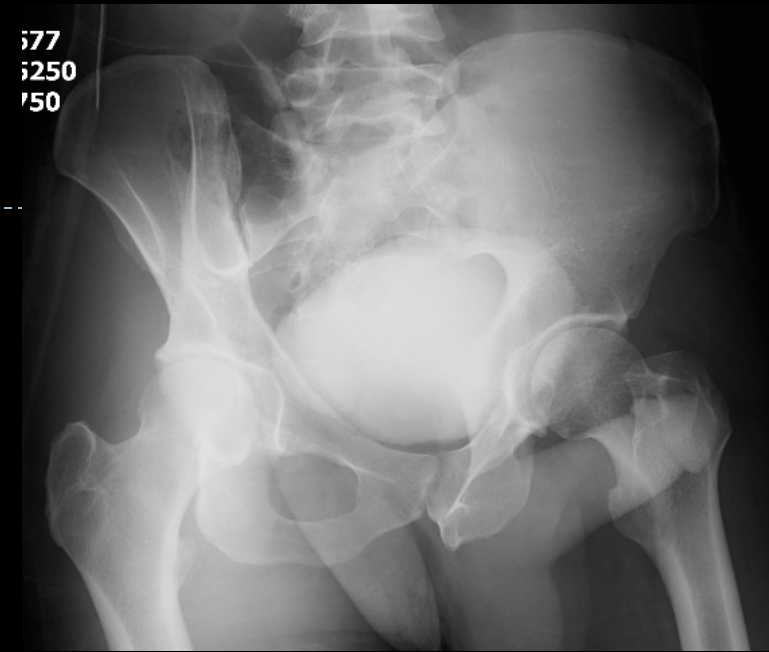
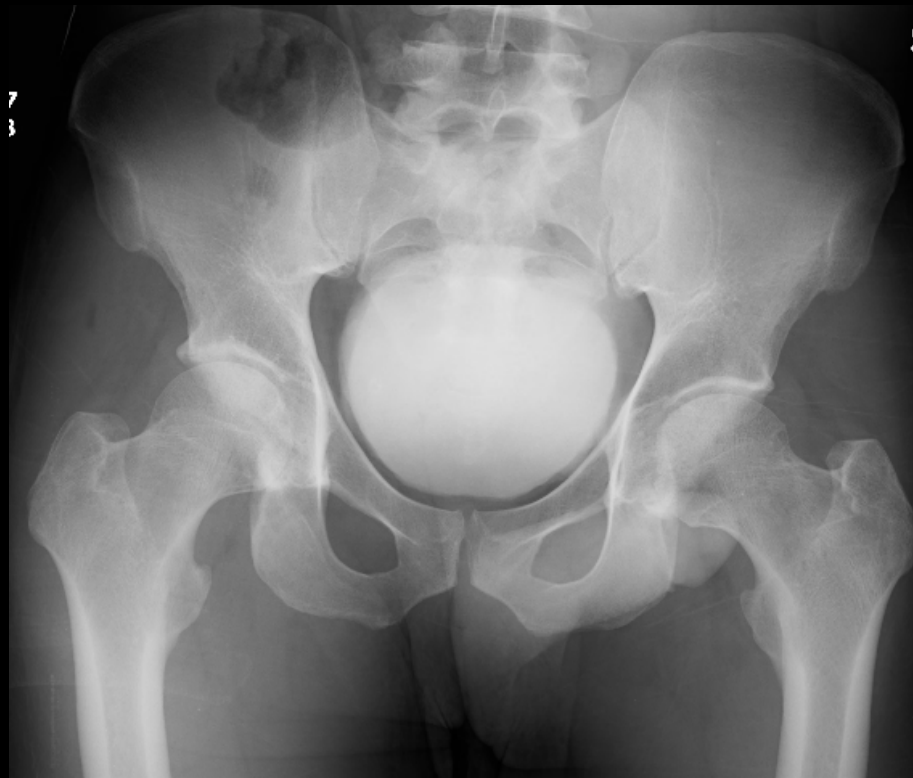- ▶ Both column 27%
  - ▶ Floating acetabulum
- ▶ Transverse w/ posterior wall 22.5%
  - ▶ (Two column)
- ▶ Posterior wall 18.3%
  
- ▶ T-shaped 7.7%
  - ▶ (Two column with inferior extension)
- ▶ Anterior column w/ post 7.1%
  - ▶ Hemitransverse
    - ▶ (Two column)





# Anterior wall

---



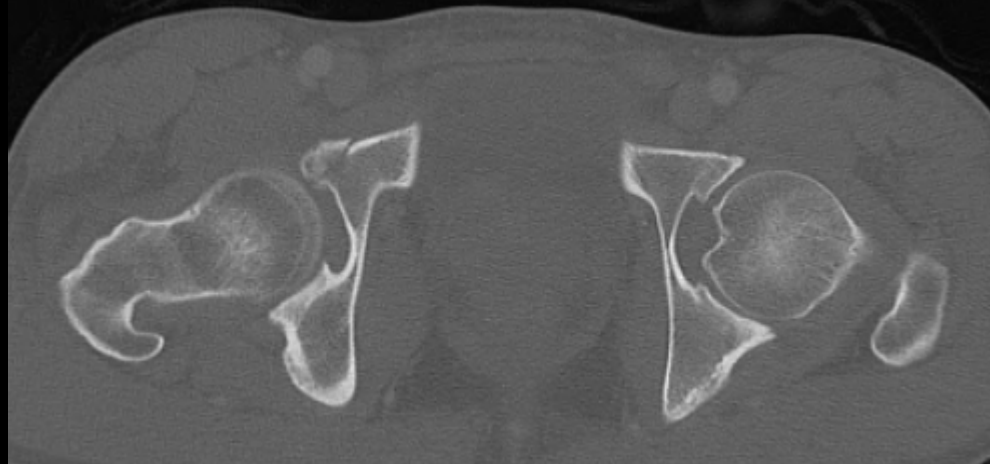
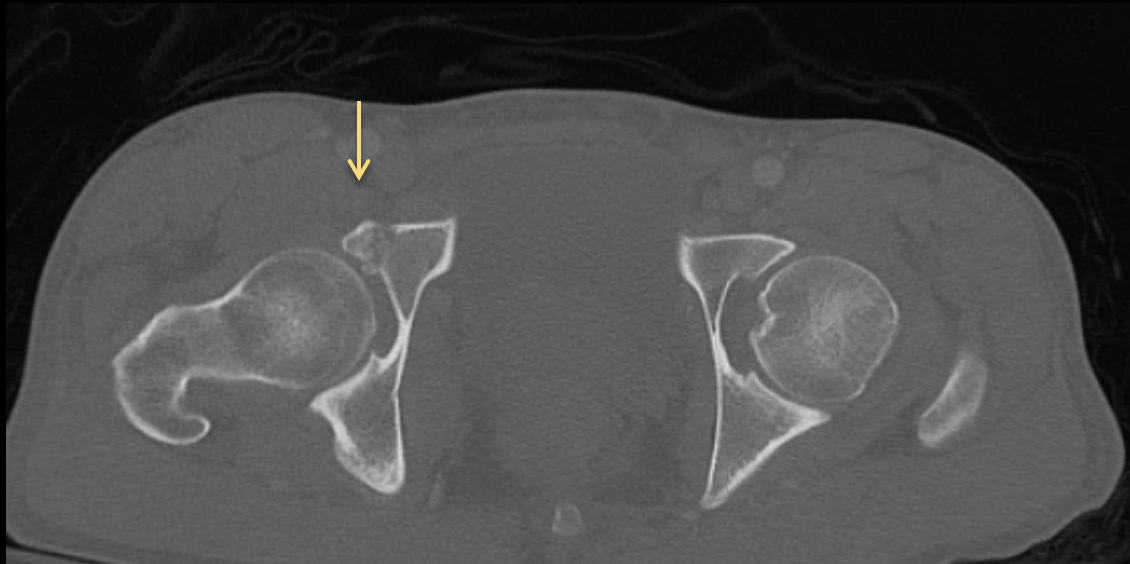
## Right anterior acetabular wall

---

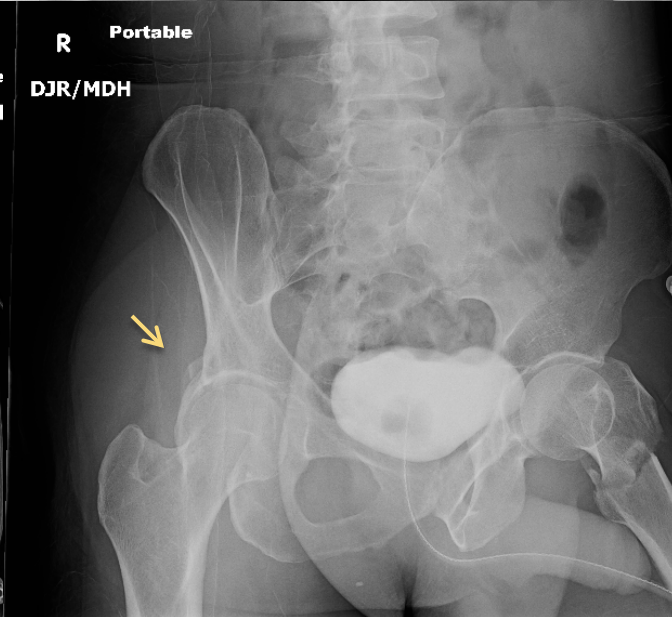
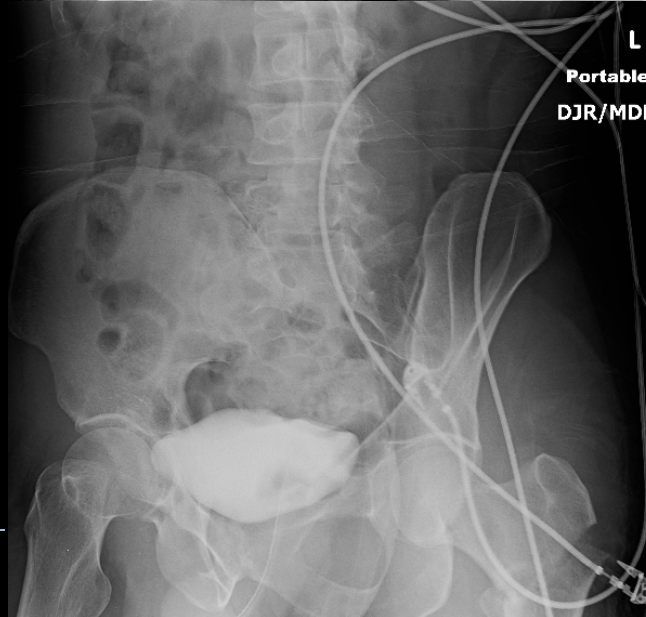
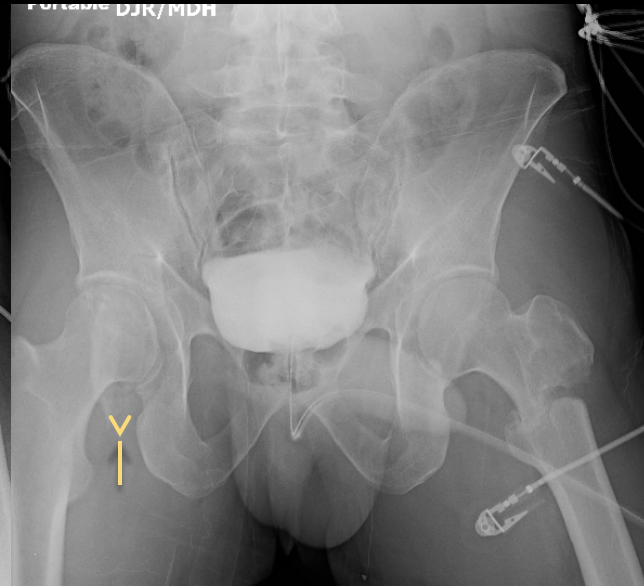
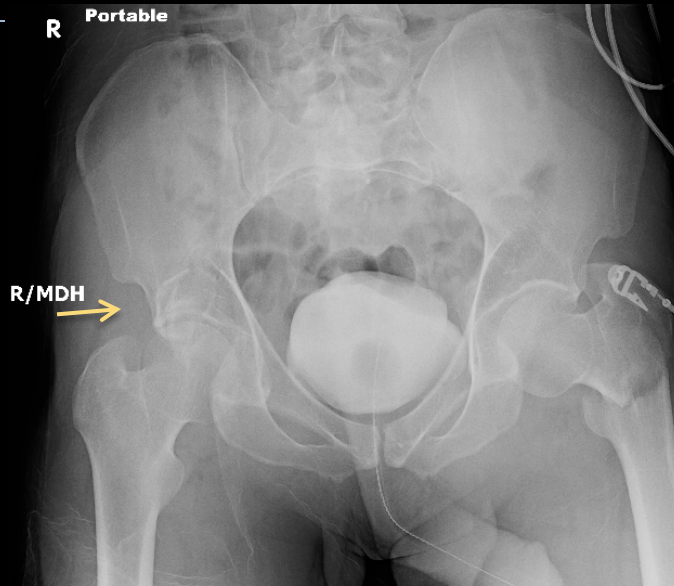


# Anterior wall

---

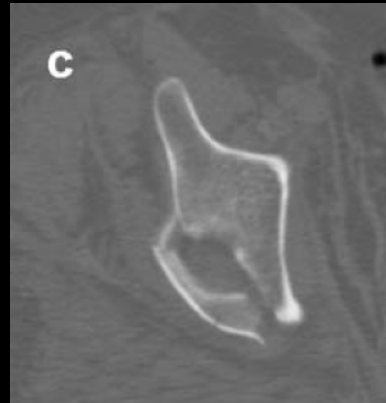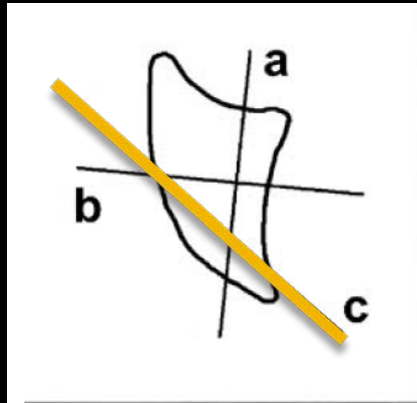


# Posterior wall



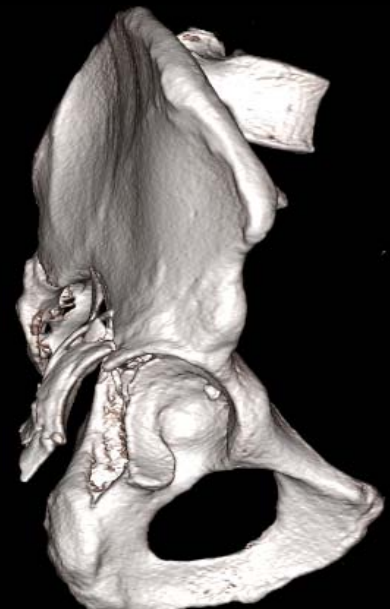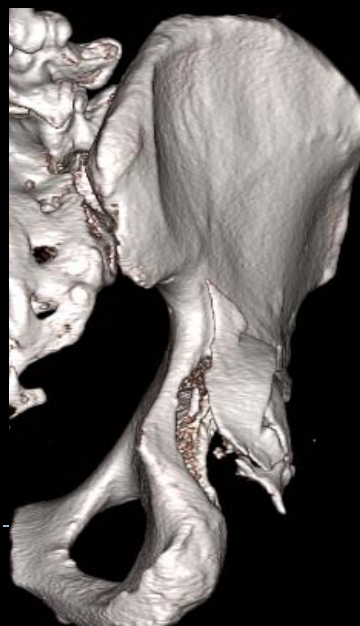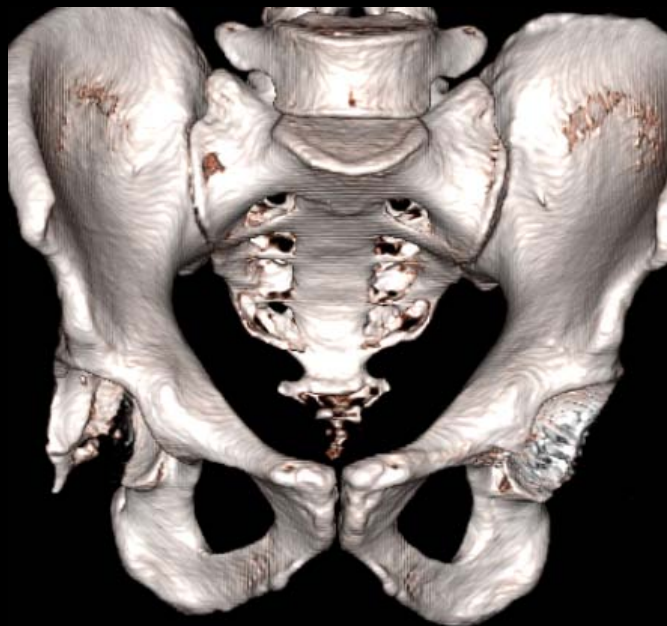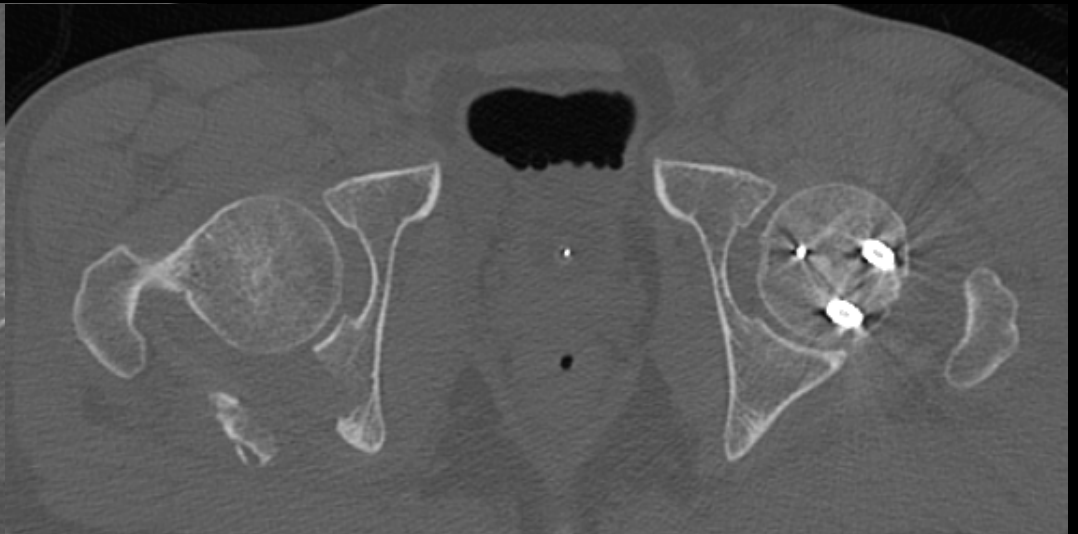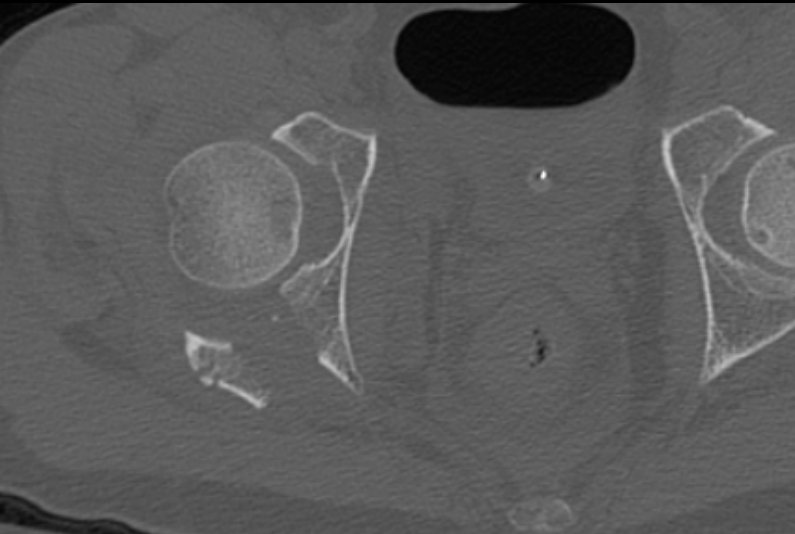
# CT- Posterior wall

---




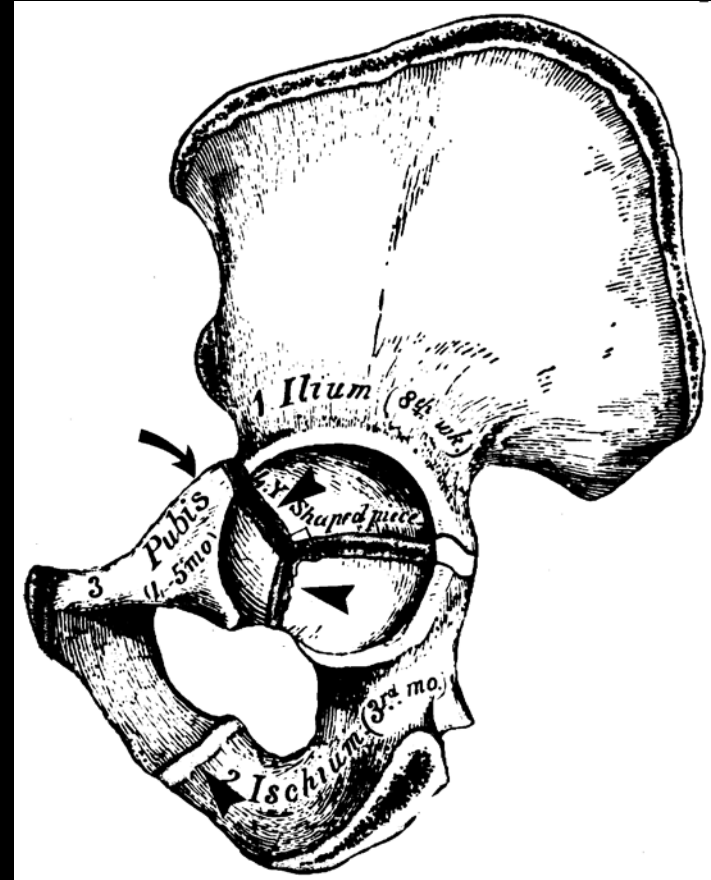
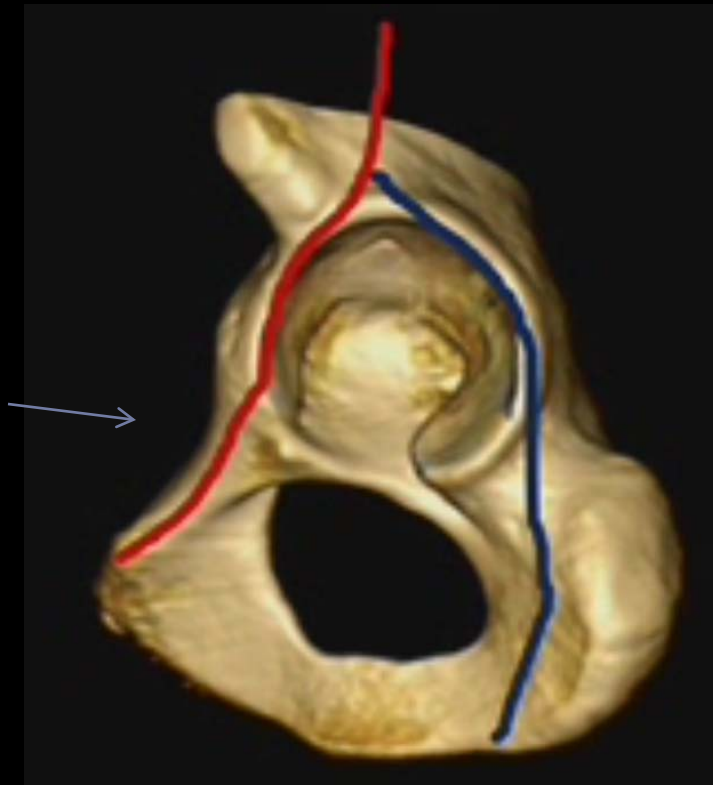


# CT- Posterior wall



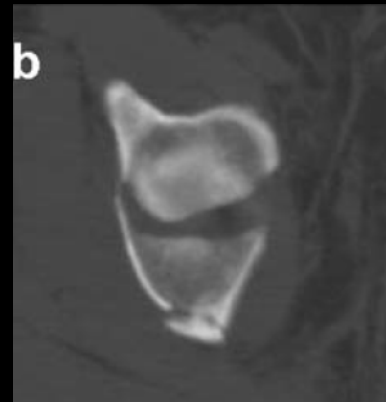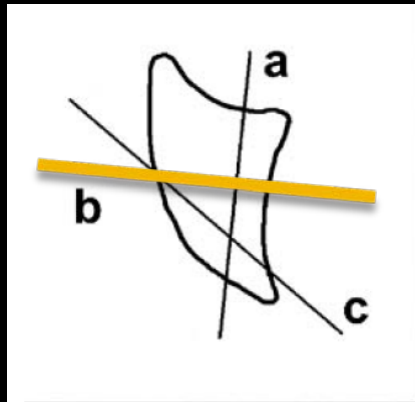
# Column fractures

---



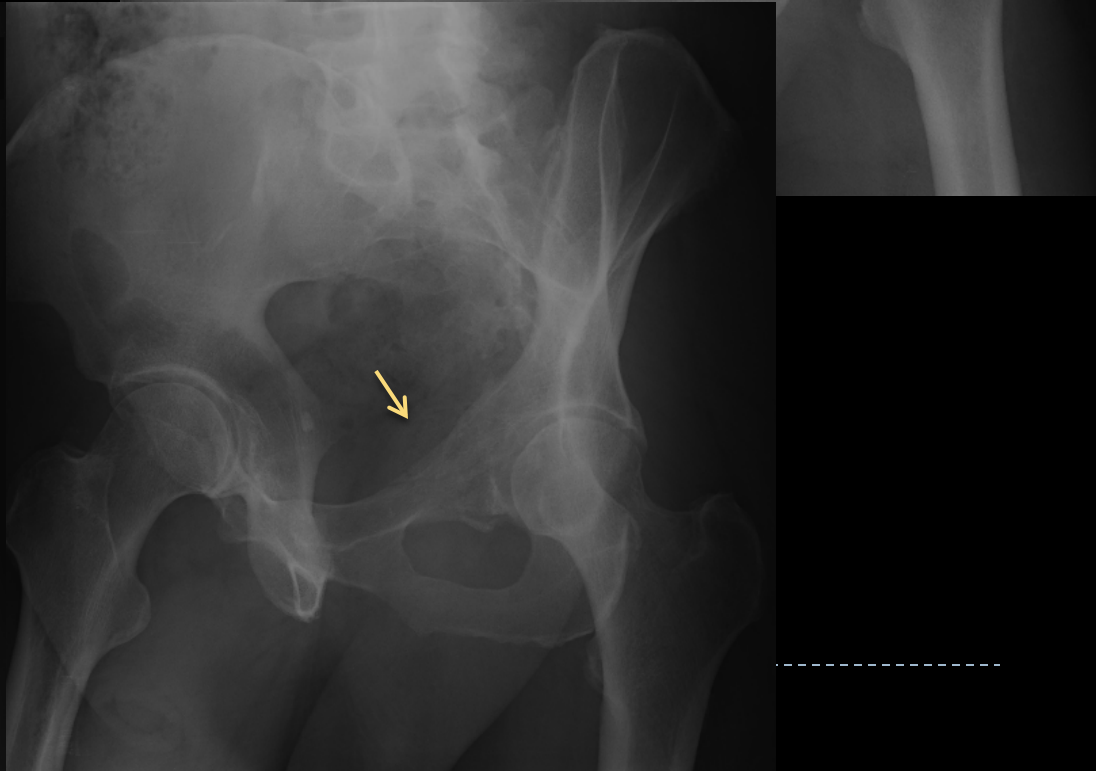
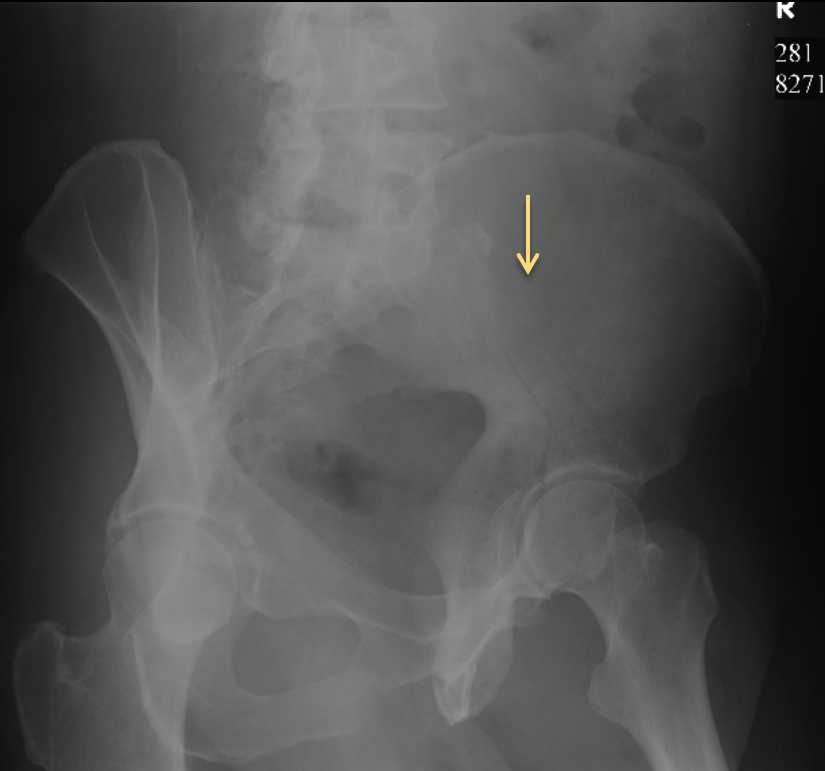
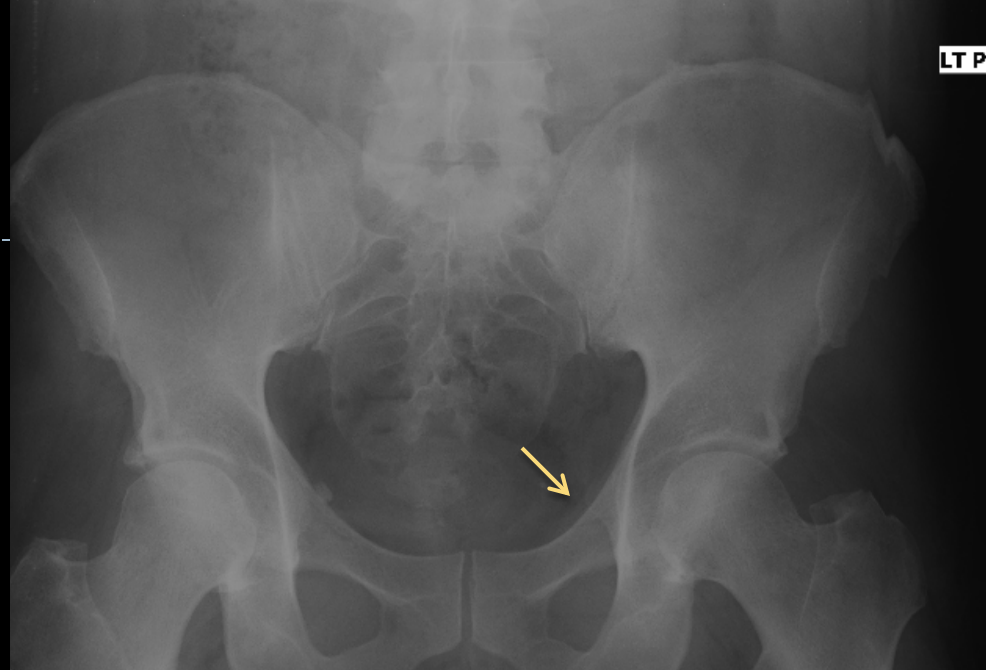
# CT- Column fractures

---



# Anterior column

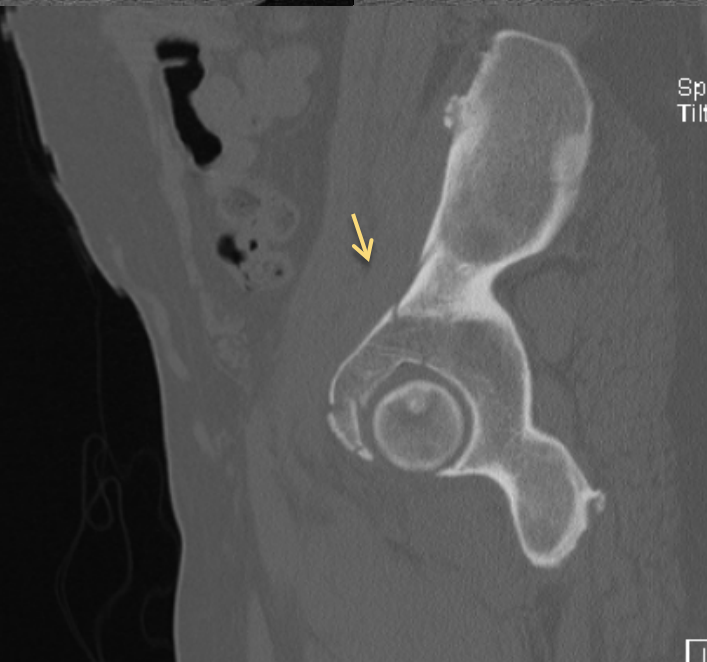
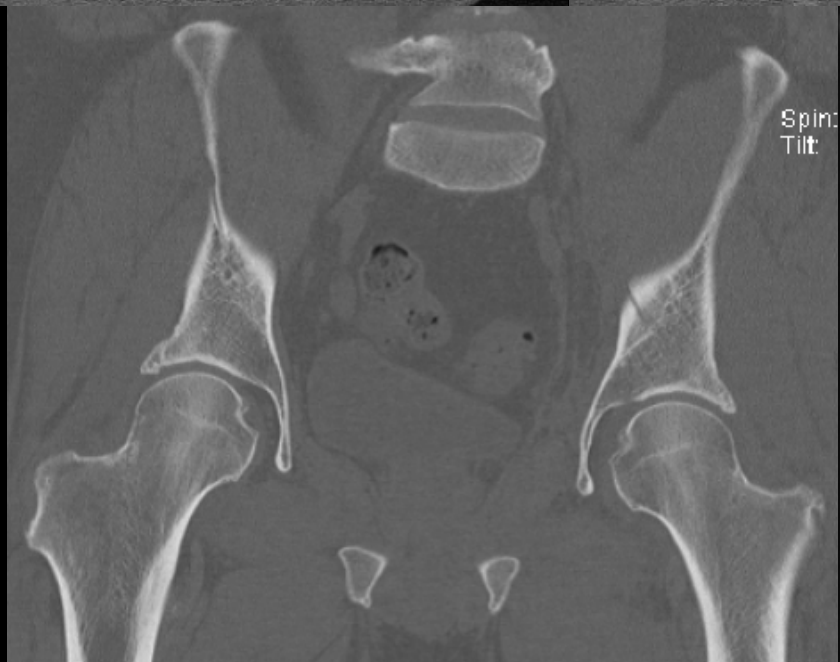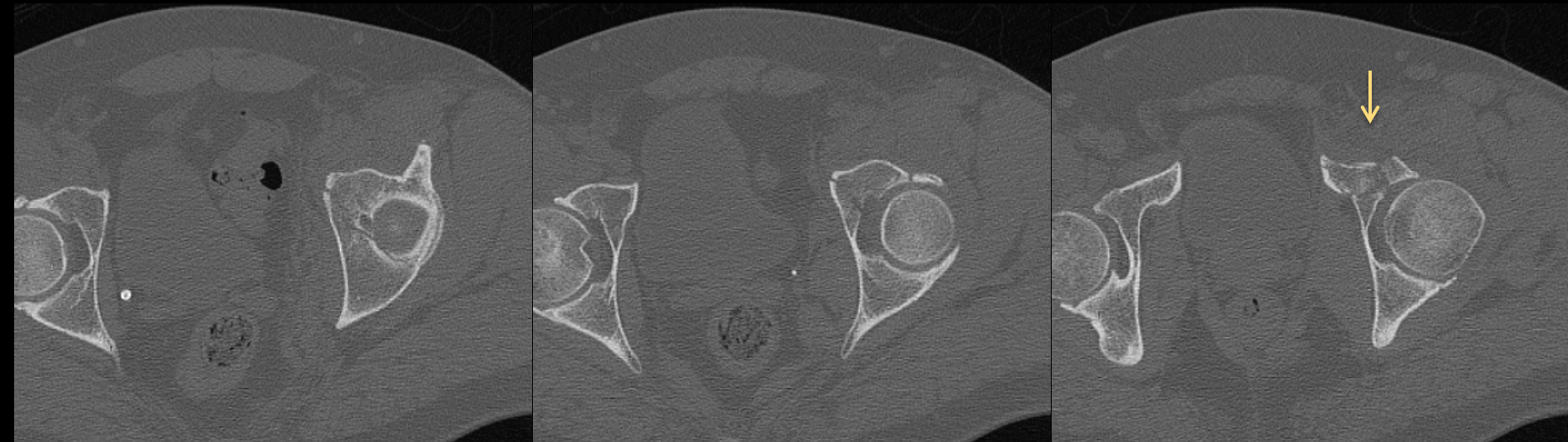---



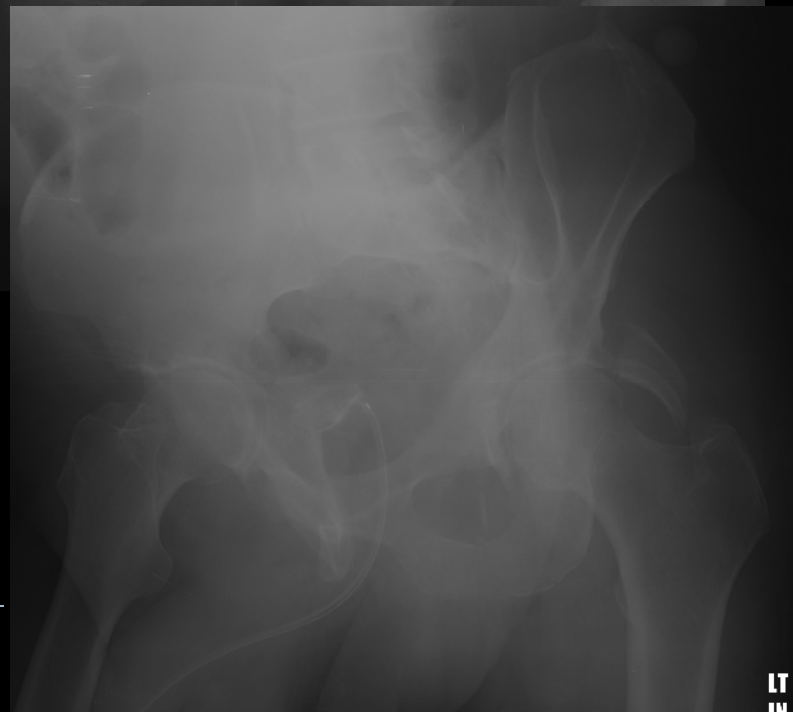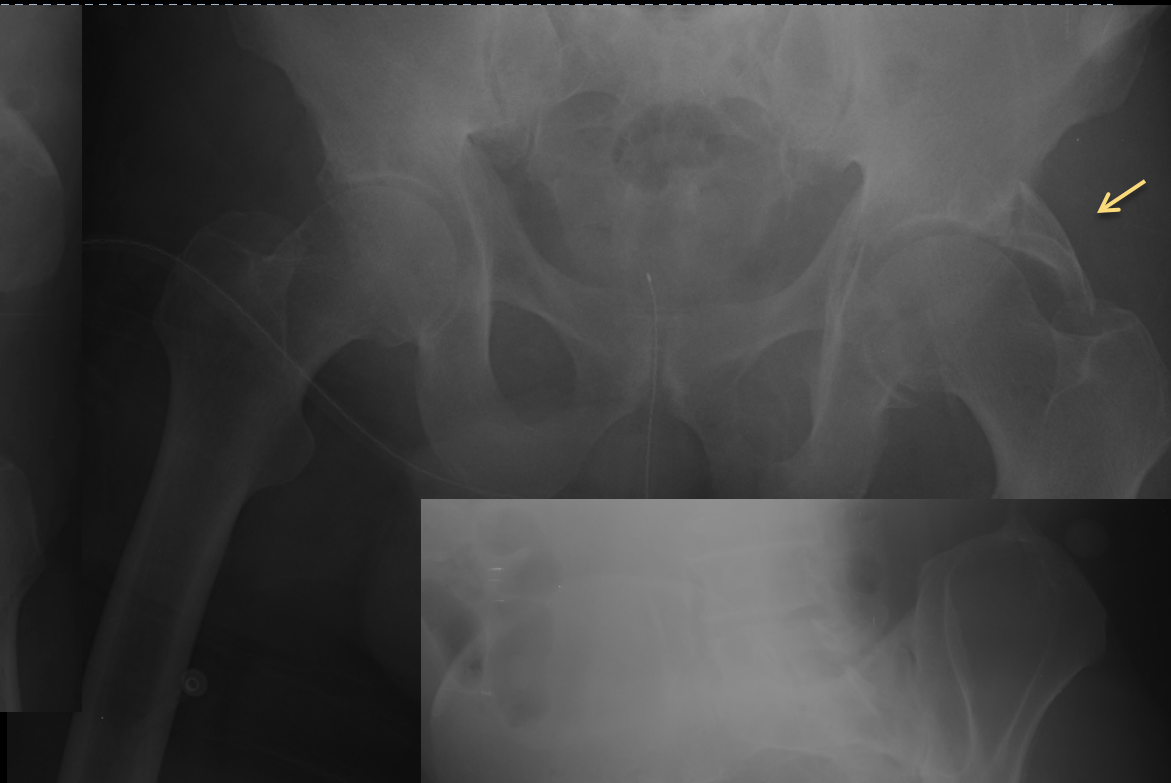

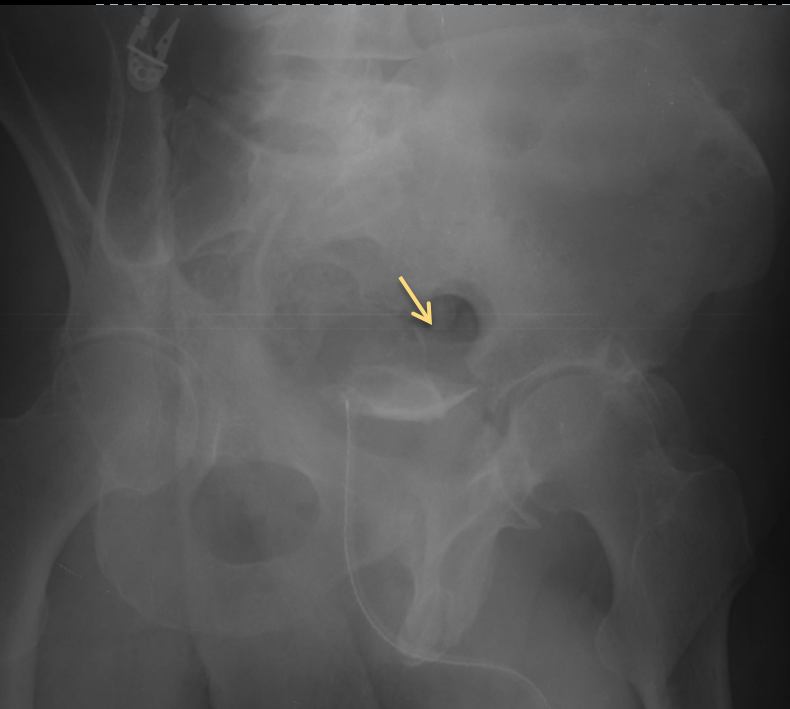
# Anterior column

---

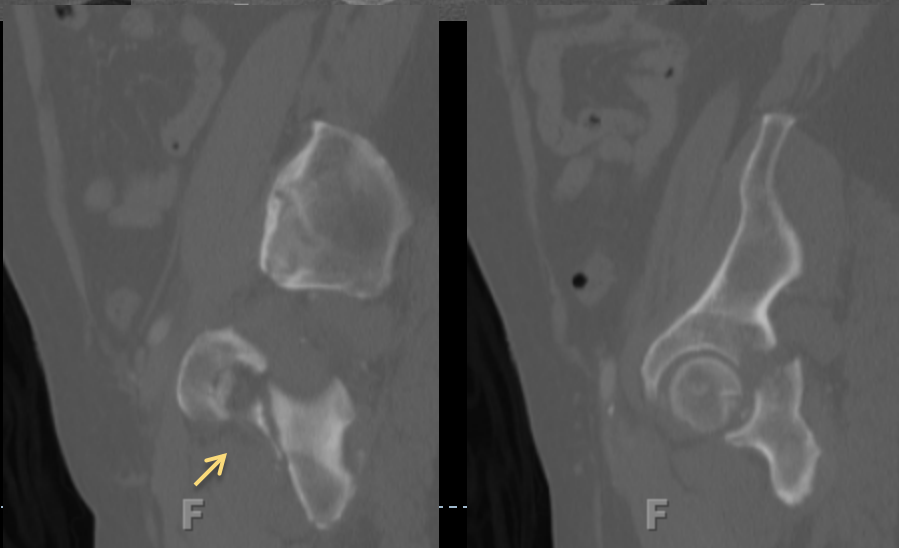
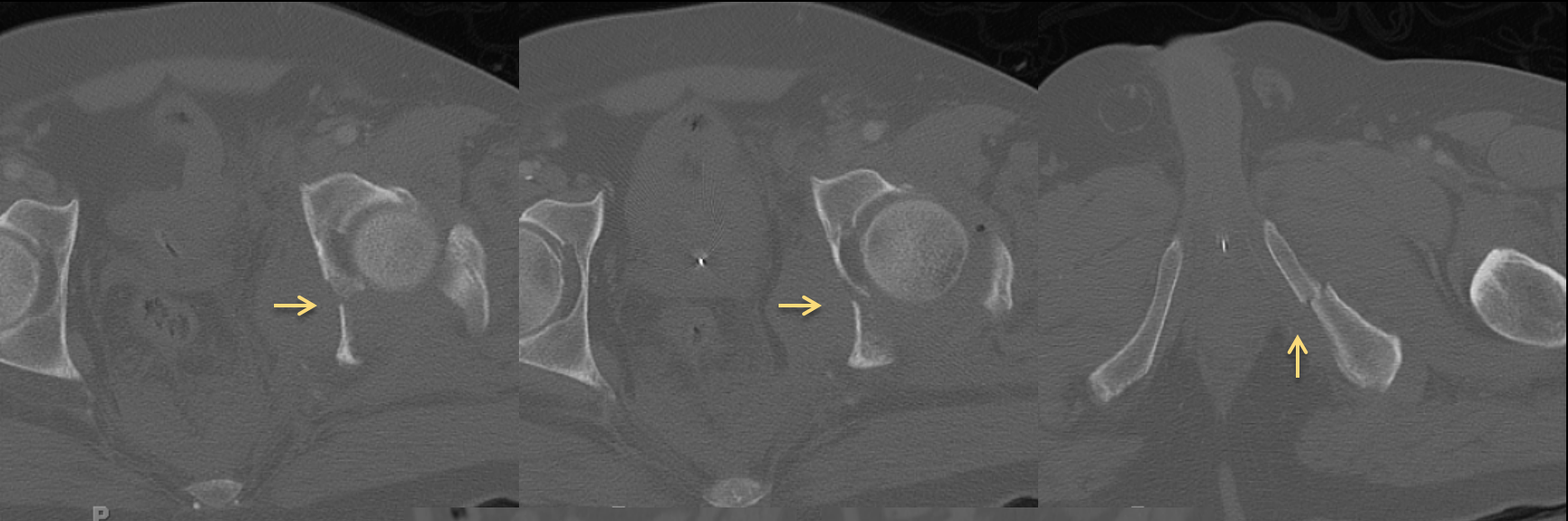

# Posterior column (w/ posterior wall)



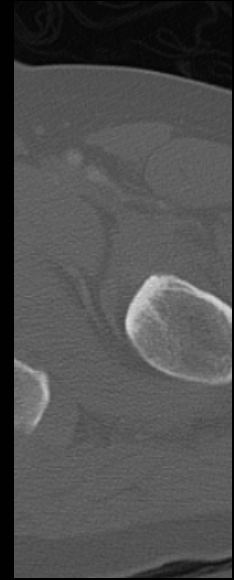
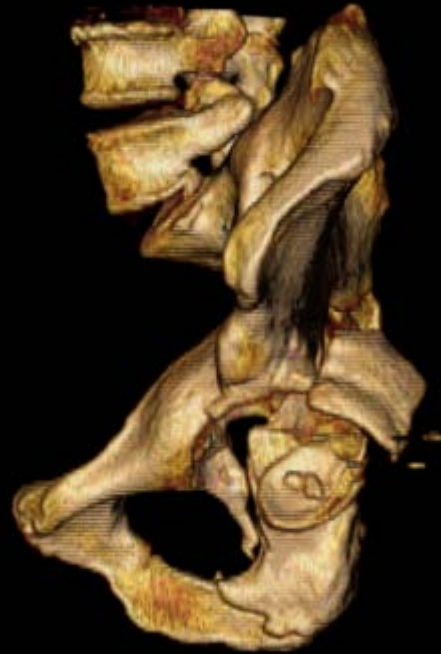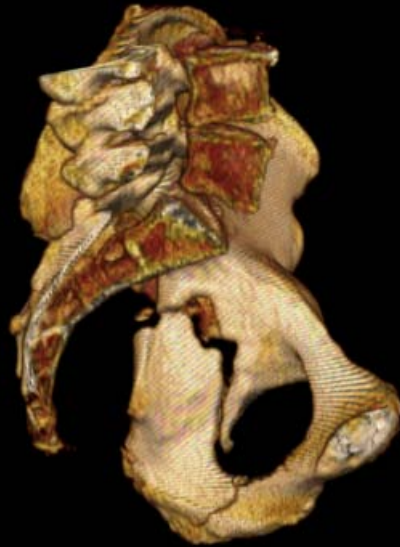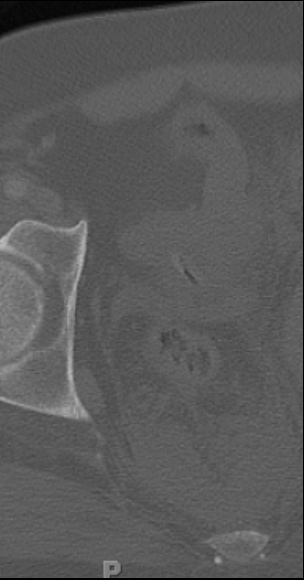# Posterior column (w/ posterior wall)

---

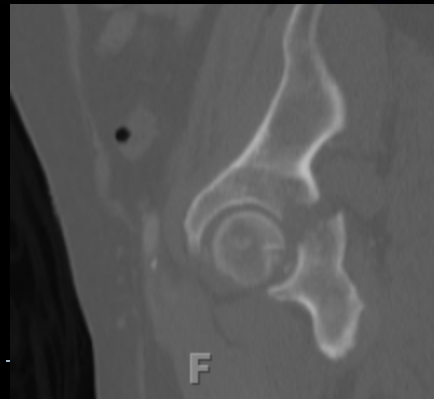
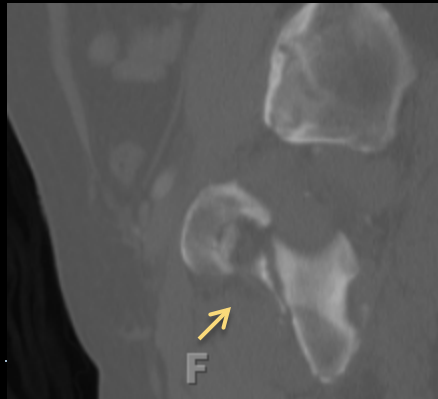

# Posterior column (w/ posterior wall)

---



Med



Lat



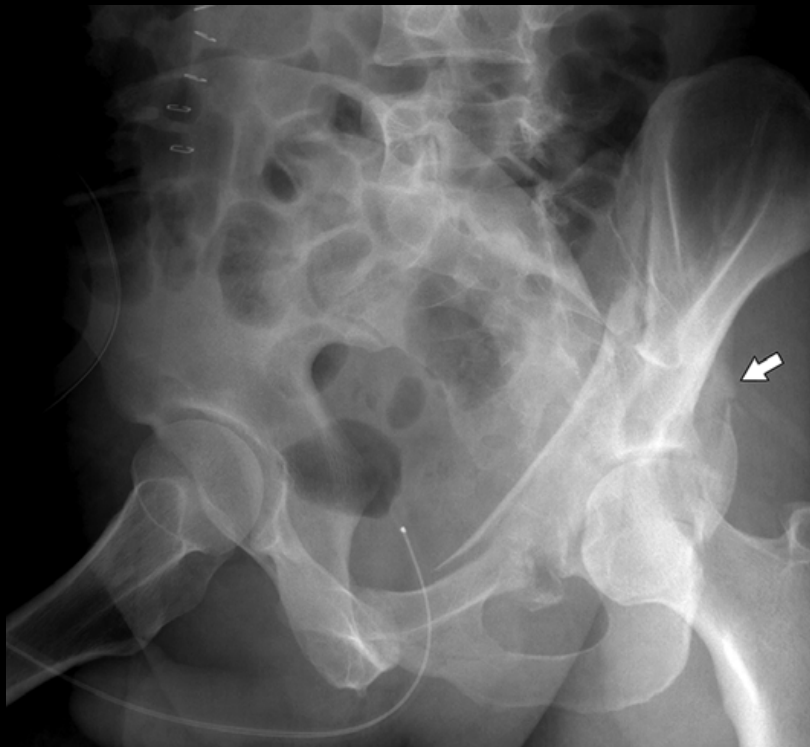


# Both column – “floating acetabulum”

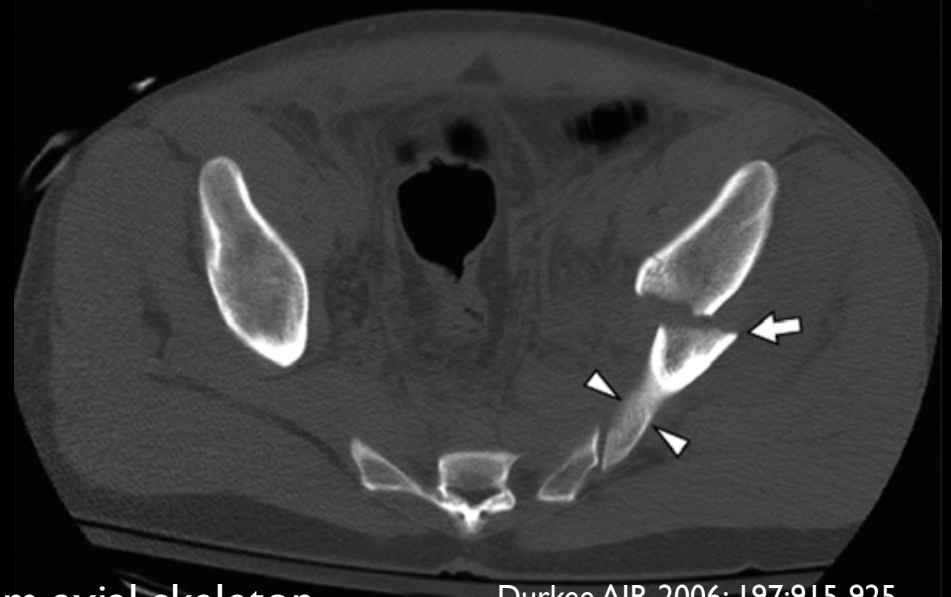---

- ▶ Obturator ring, iliac wing involvement
- ▶ Spur sign (arrow)

posterior displacement  
of the sciatic buttress of the iliac  
wing fracture, at level of superior  
acetabulum



Disconnects roof of acetabulum from axial skeleton

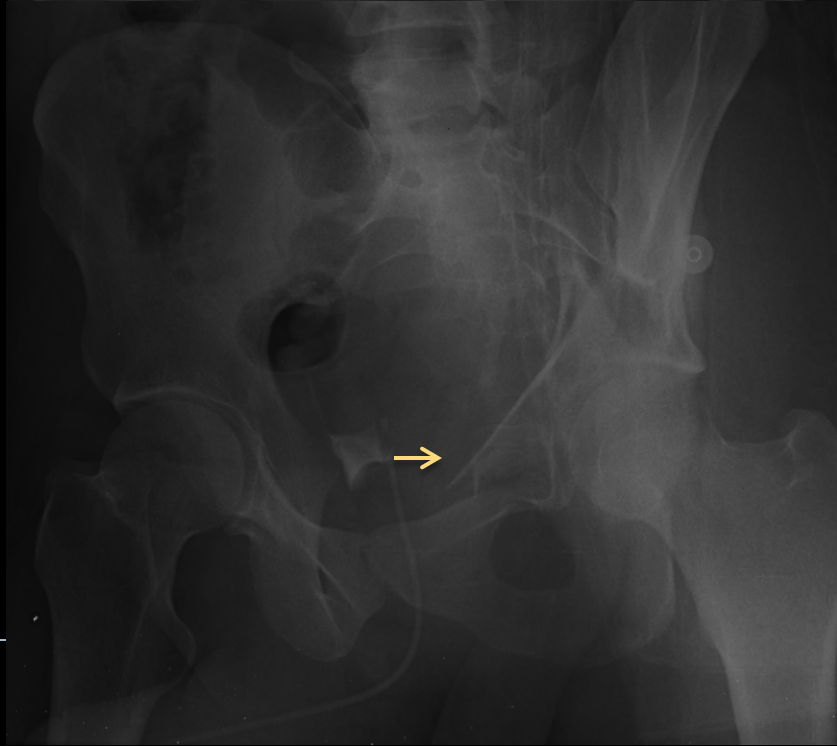
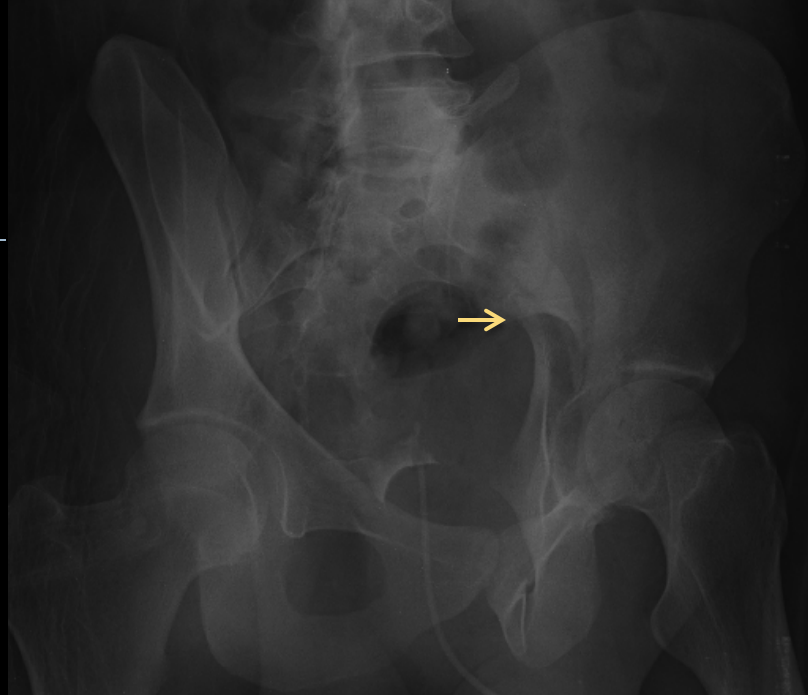
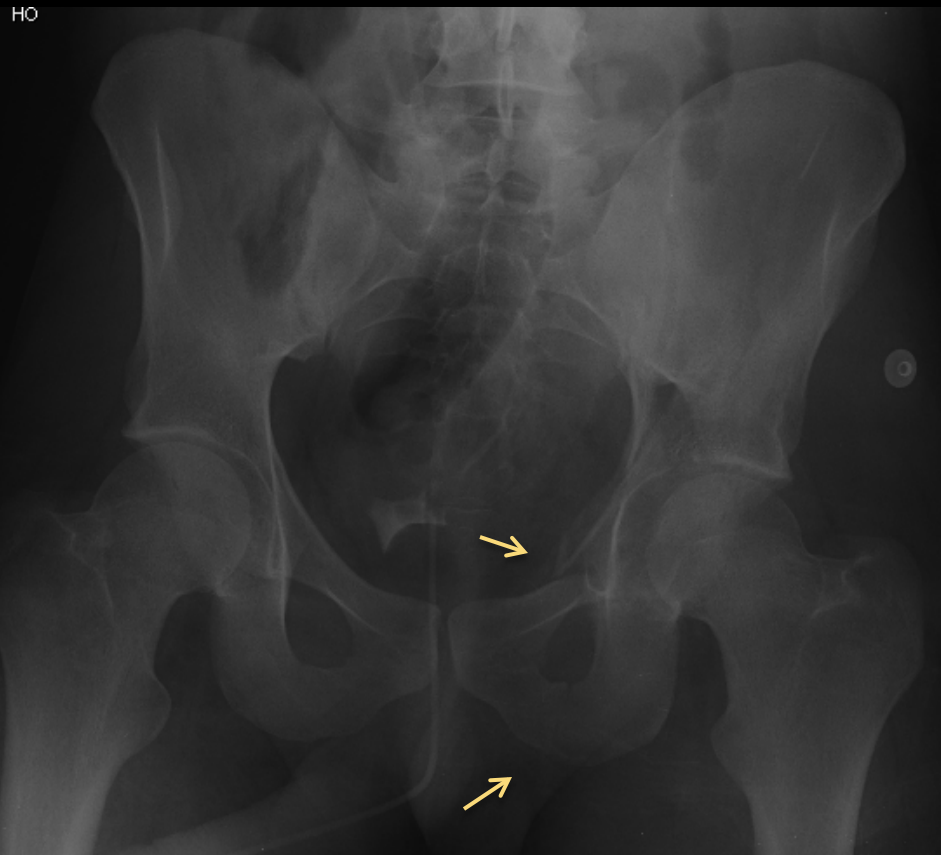


Durkee AJR 2006; 197:915-925.



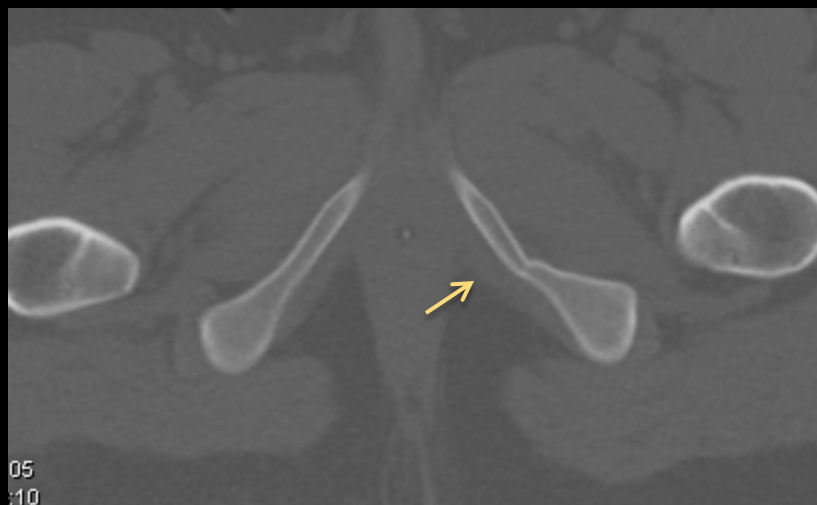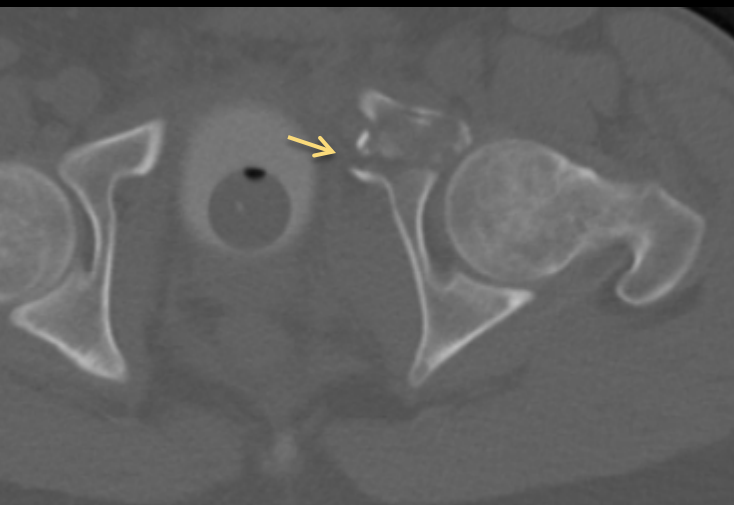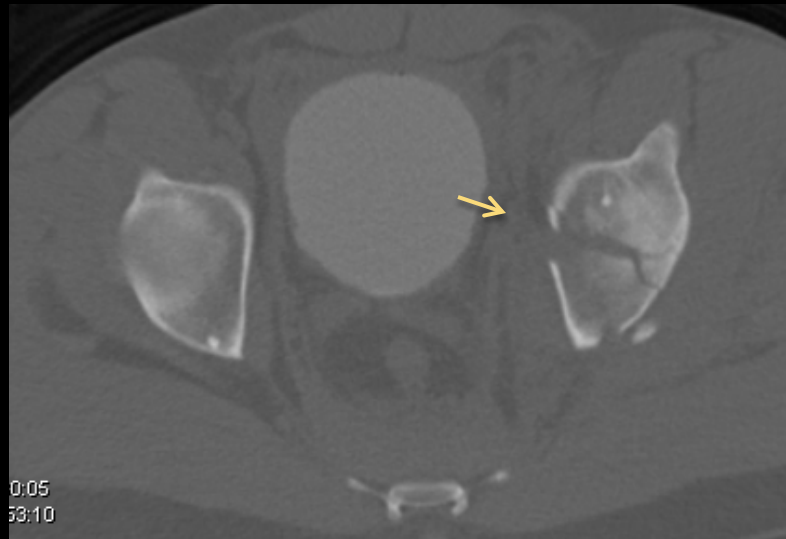
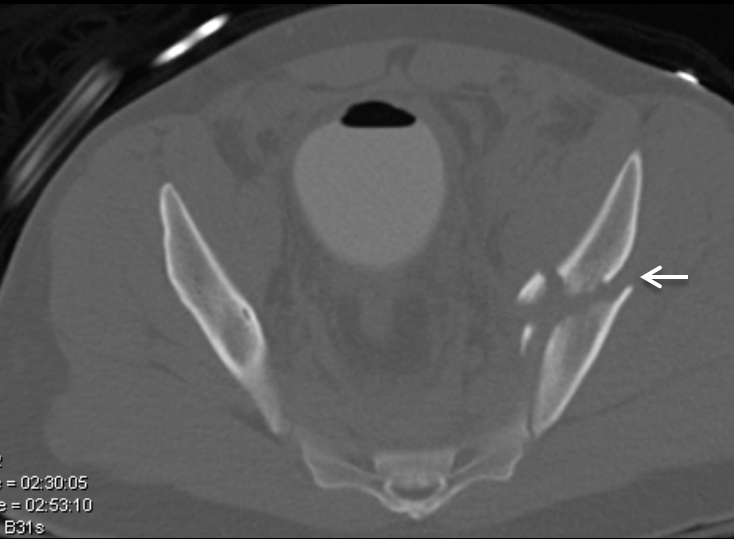# Both column – “floating acetabulum”

---



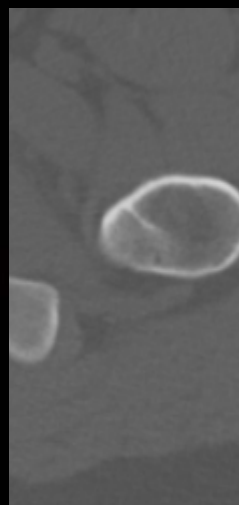
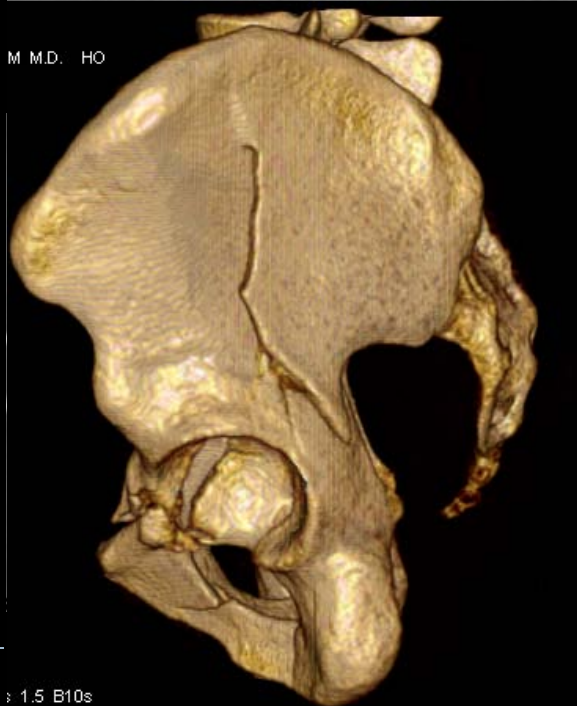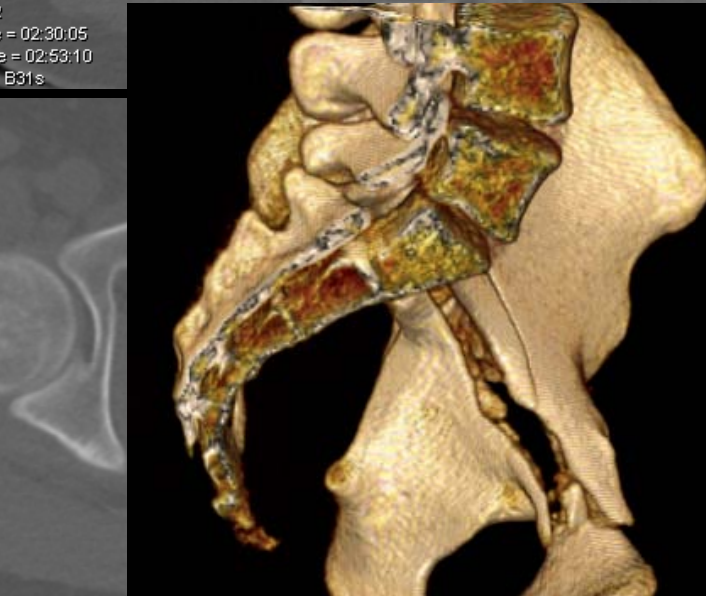
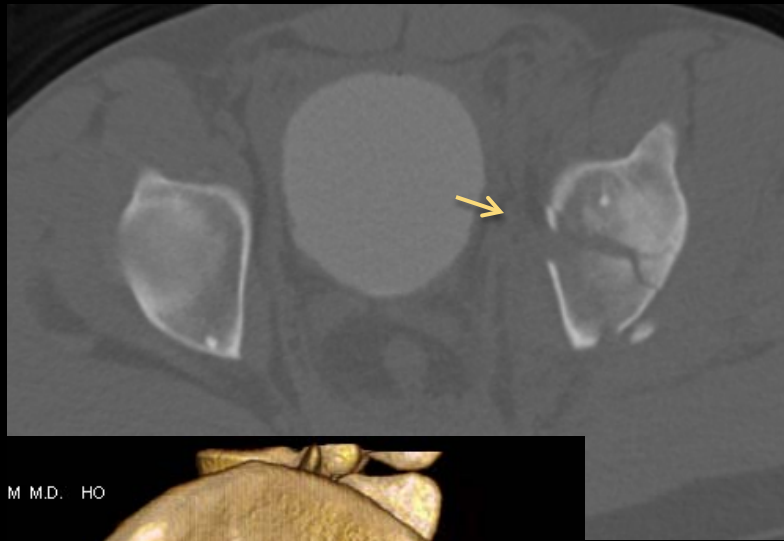
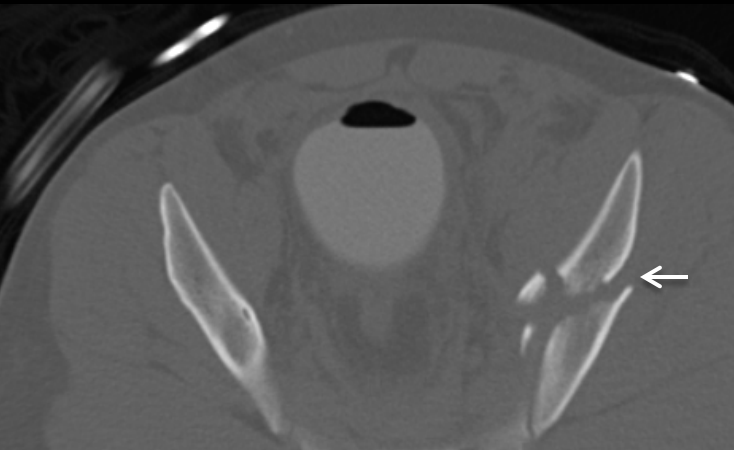
# Both column – “floating acetabulum”

---



# Both column – “floating acetabulum”

---



--:5 B10s

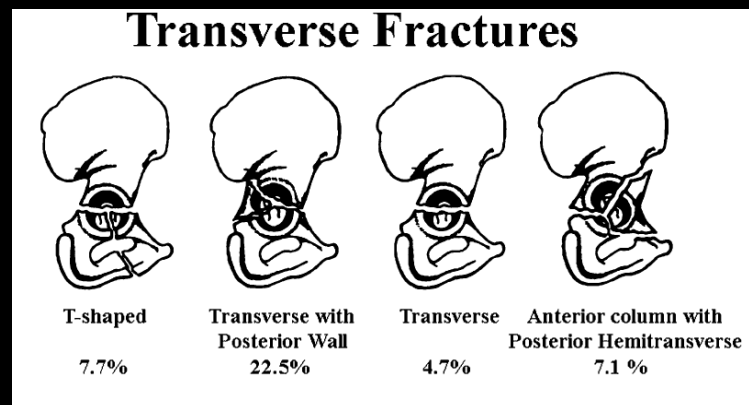
: 1.5 B10s



# Transverse “two column”

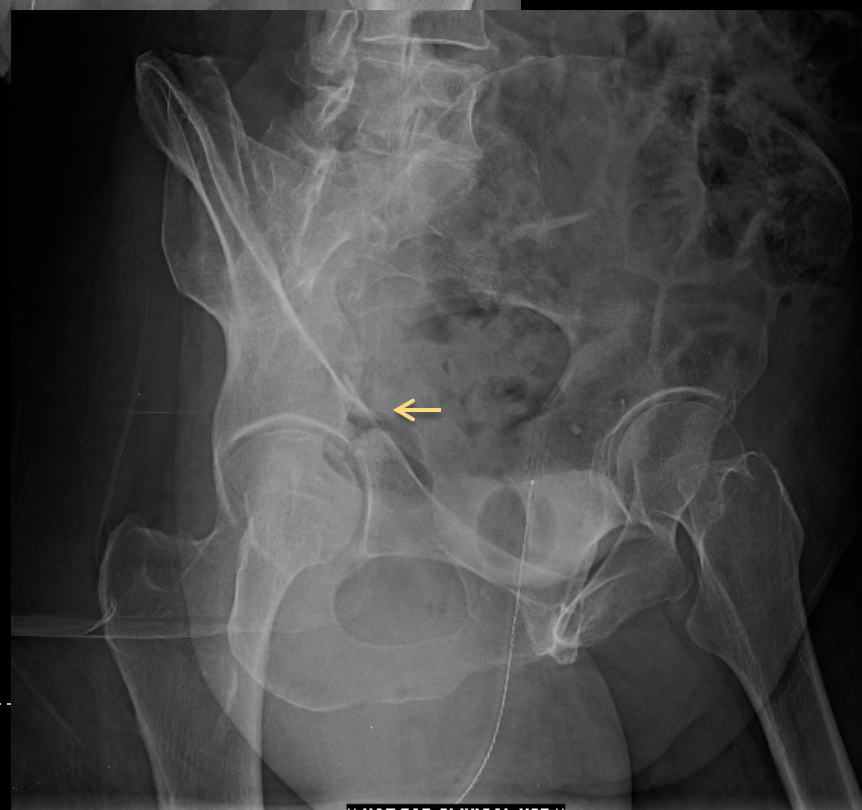
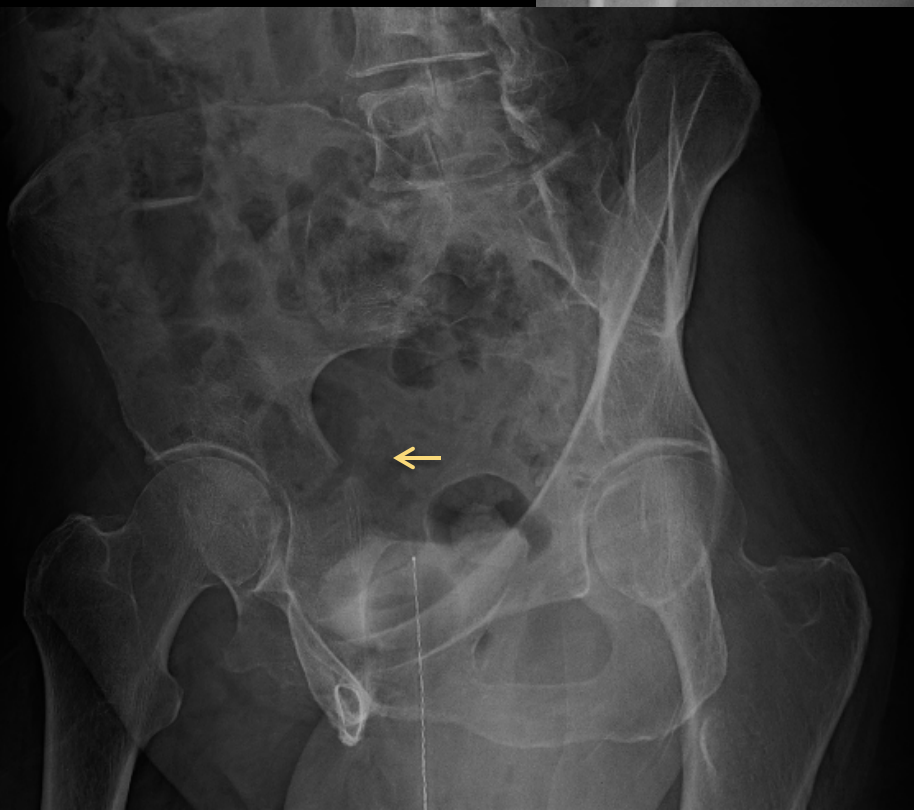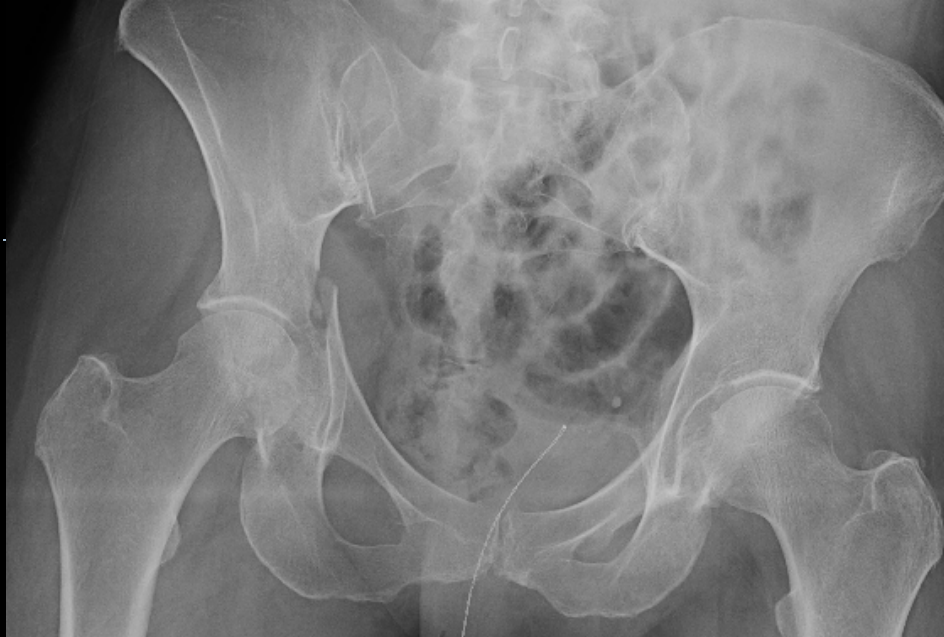---

- ▶ Splits acetabulum into superior and inferior halves
- ▶ A-P fracture line in the transverse plane of the acetabulum (not anatomic transverse plane)
  - ▶ Acetabulum tilted inferiorly and anteriorly
  - ▶ Oblique sagittal fracture through roof, coursing medial/superior
- ▶ **Obturator ring intact except with T-shaped fracture**



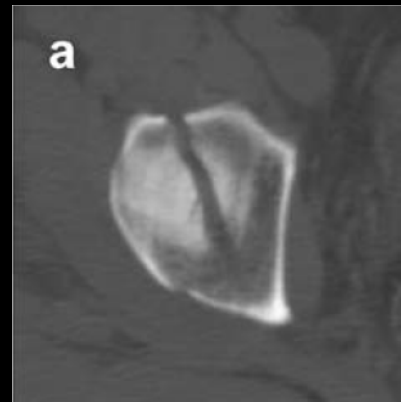
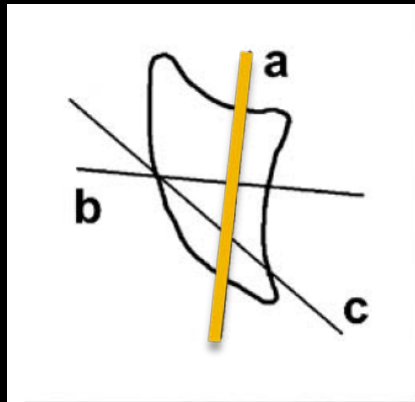
# Transverse

---



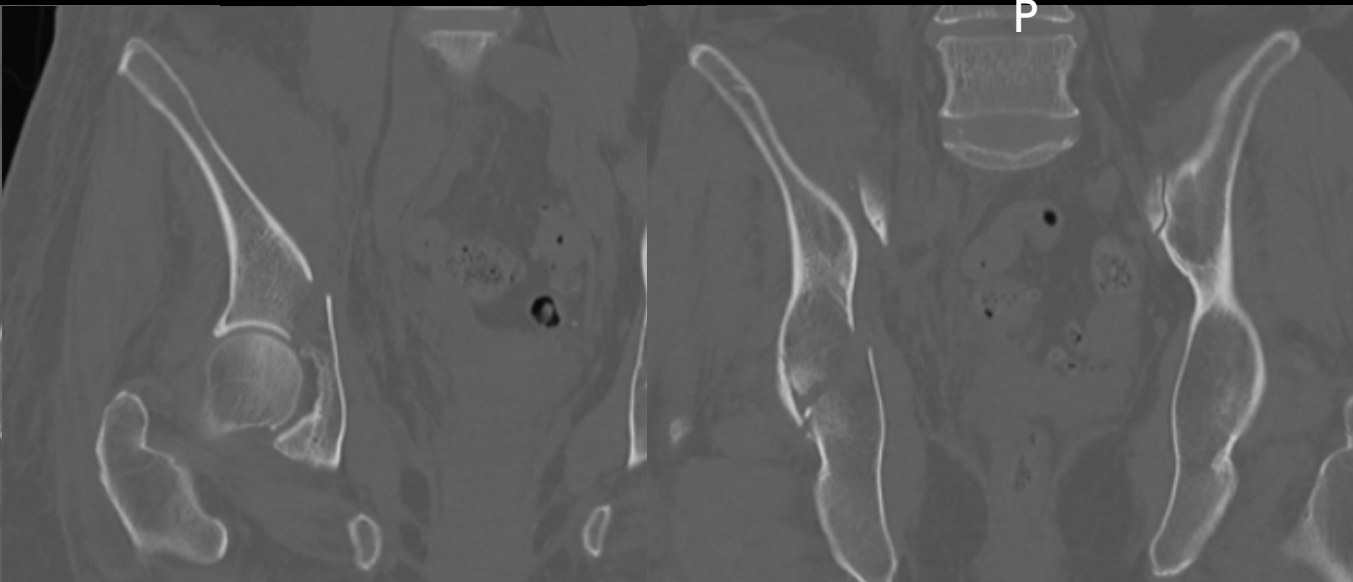
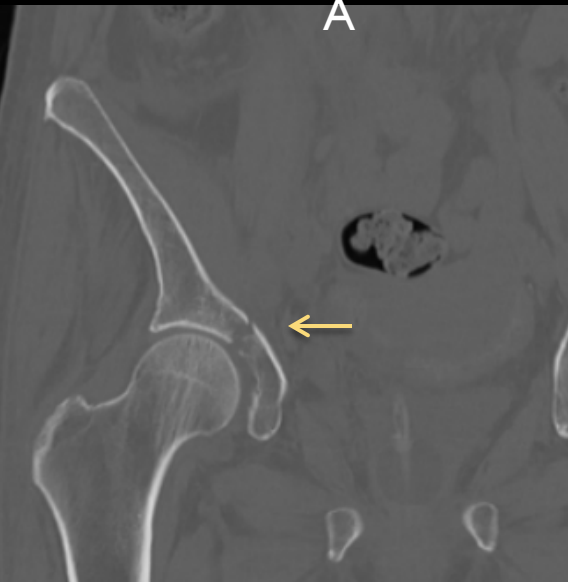
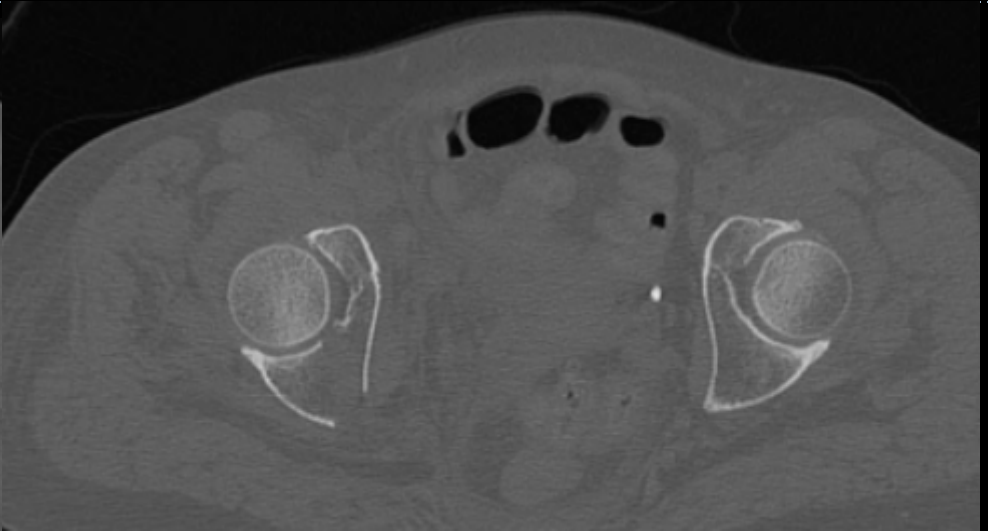
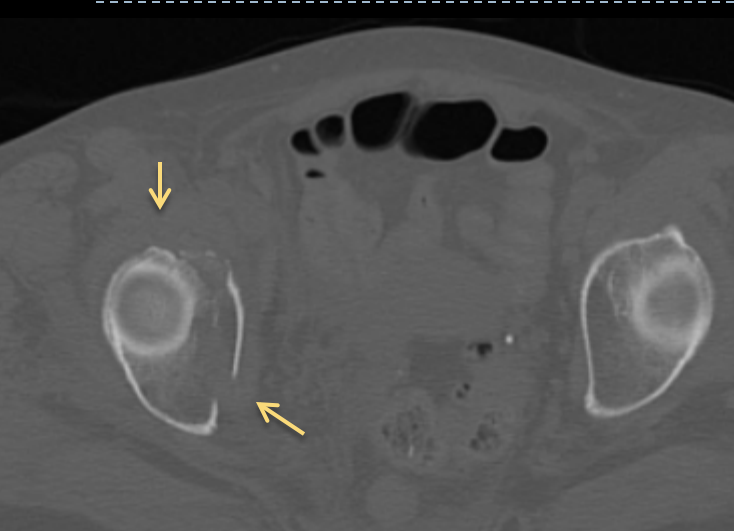
# CT – Transverse fracture “two column”

---



# Transverse “two column”

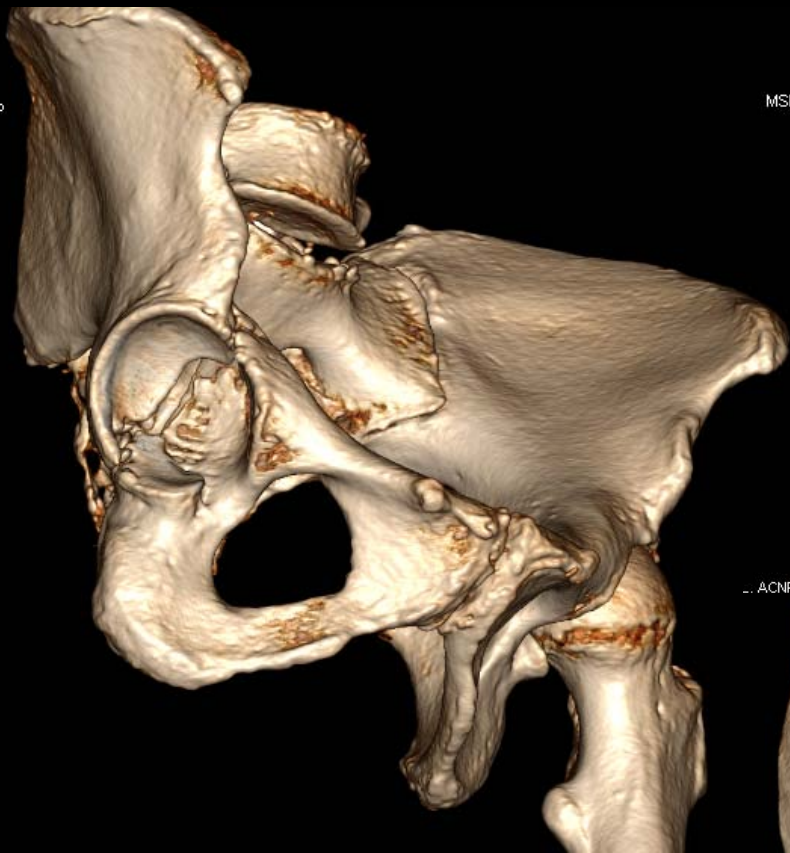
---



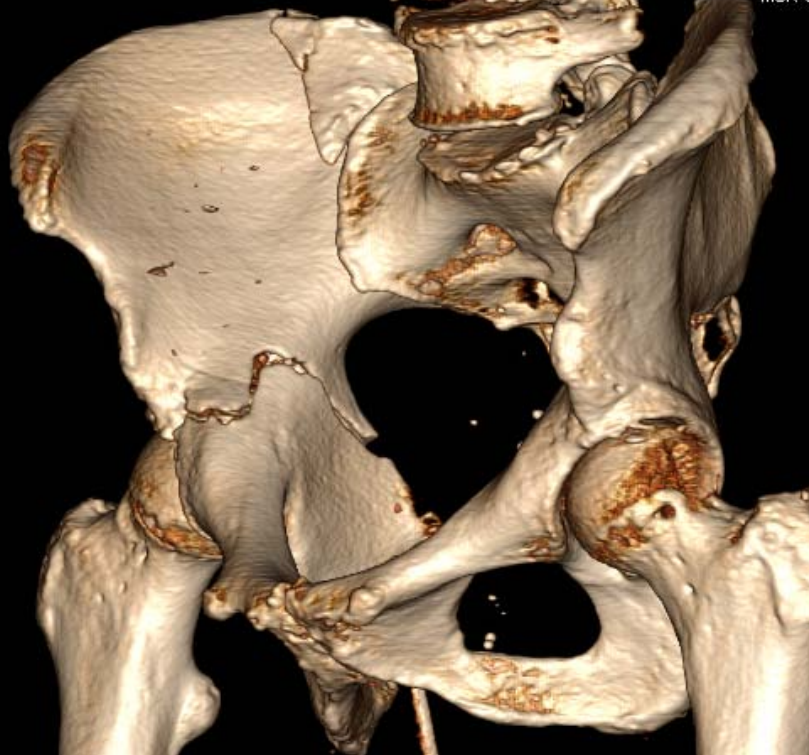

# Transverse “two c

ACNP

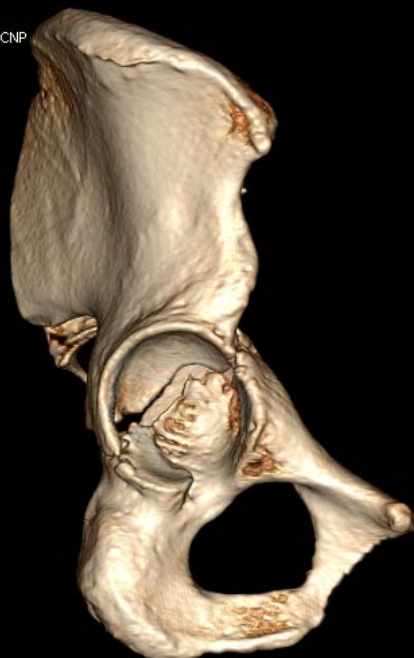

MSI

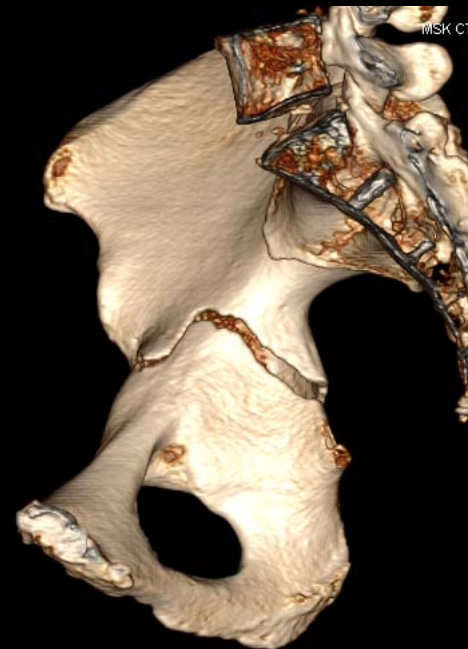


MSK C

ACNP



MSK CT



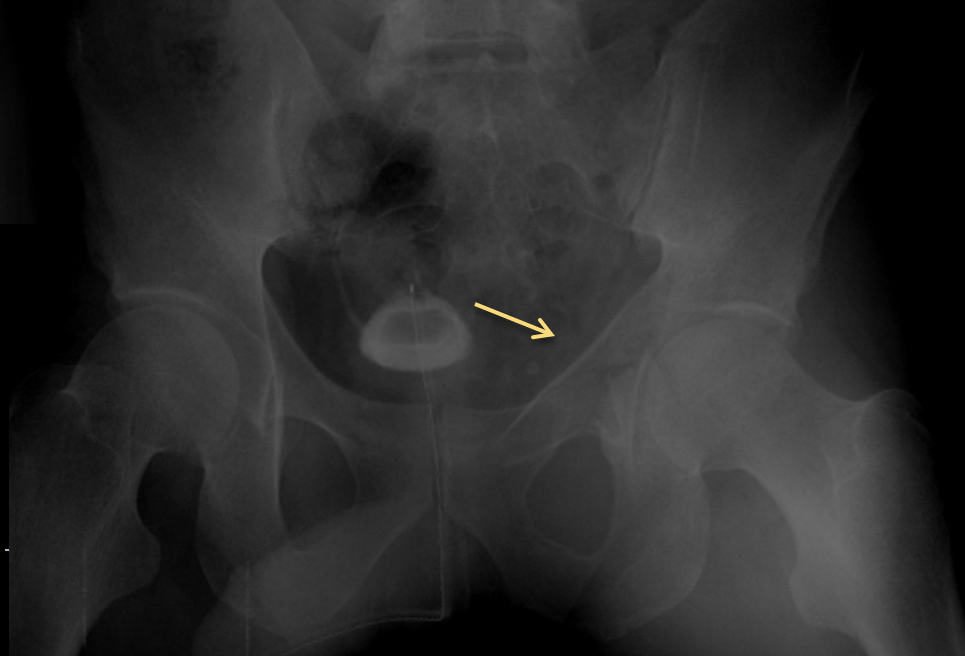
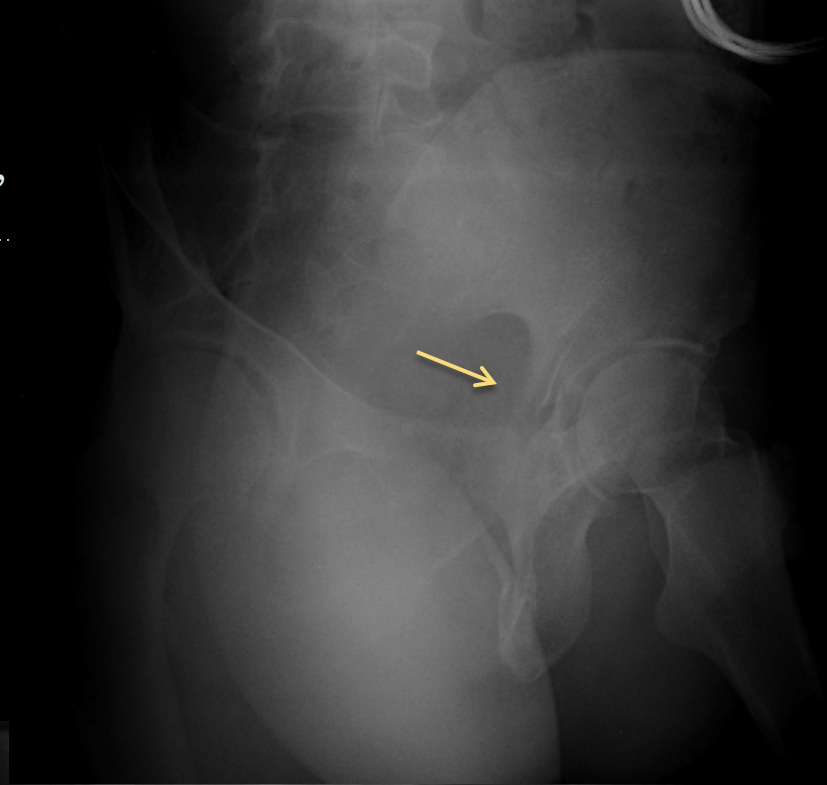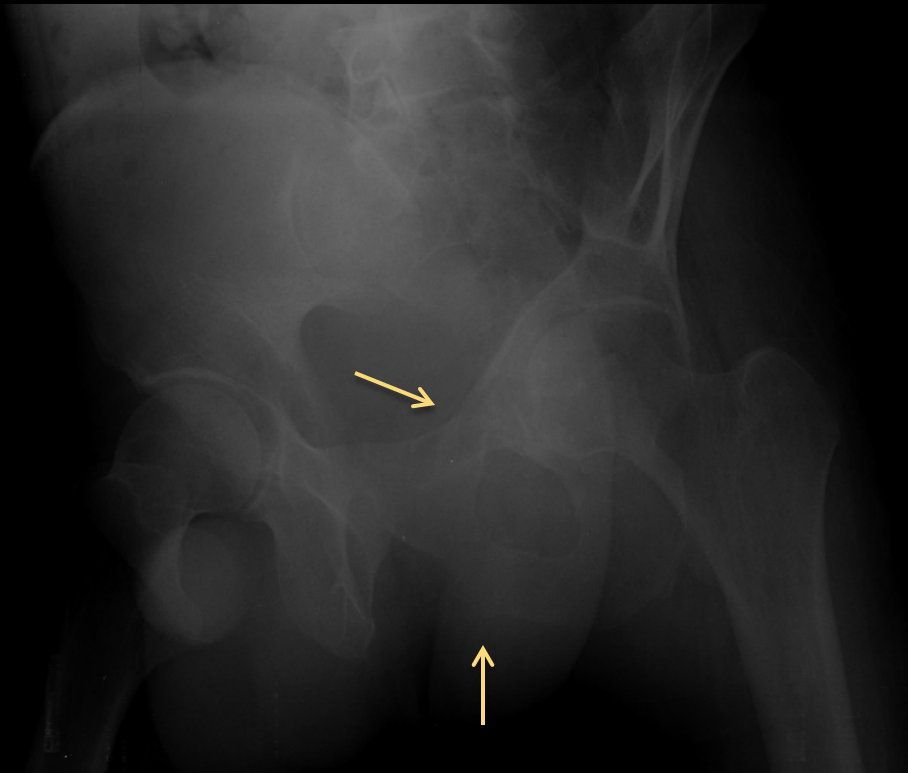
# Transverse T-shape “Two column with inferior extension”

---

- ▶ Disruption obturator ring, iliopectineal and ilioischial lines (similar to both column)
- ▶ Principal fracture line is **transverse**, NOT coronal
- ▶ But superior extension of fracture **DOES NOT** involve iliac wing

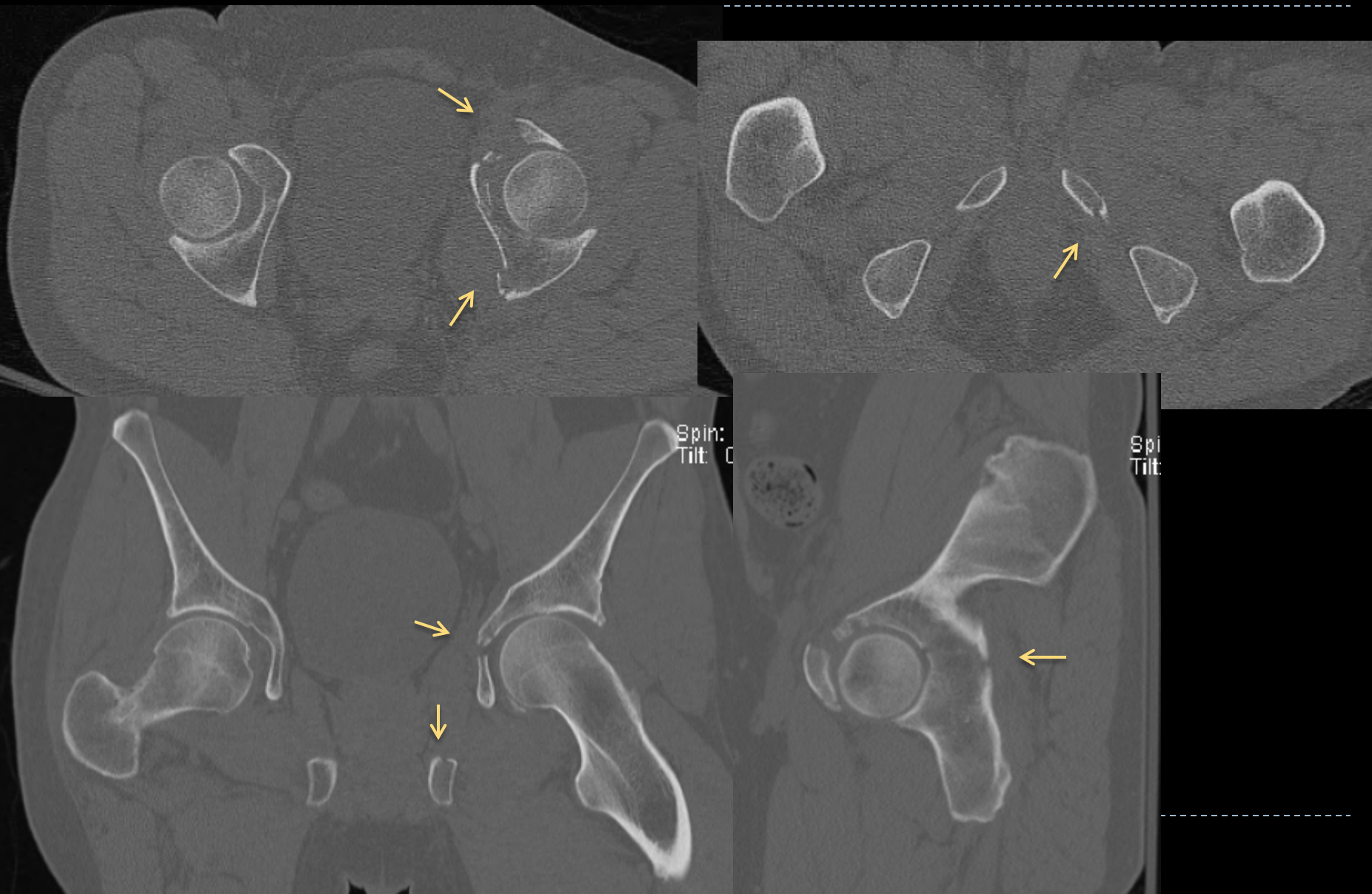


T “Two column with inferior extension”



# T “Two column with inferior extension”

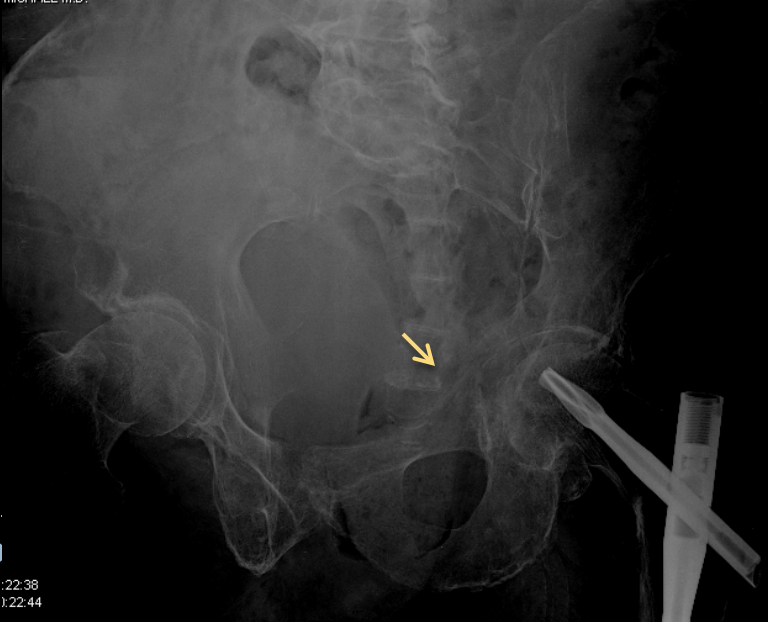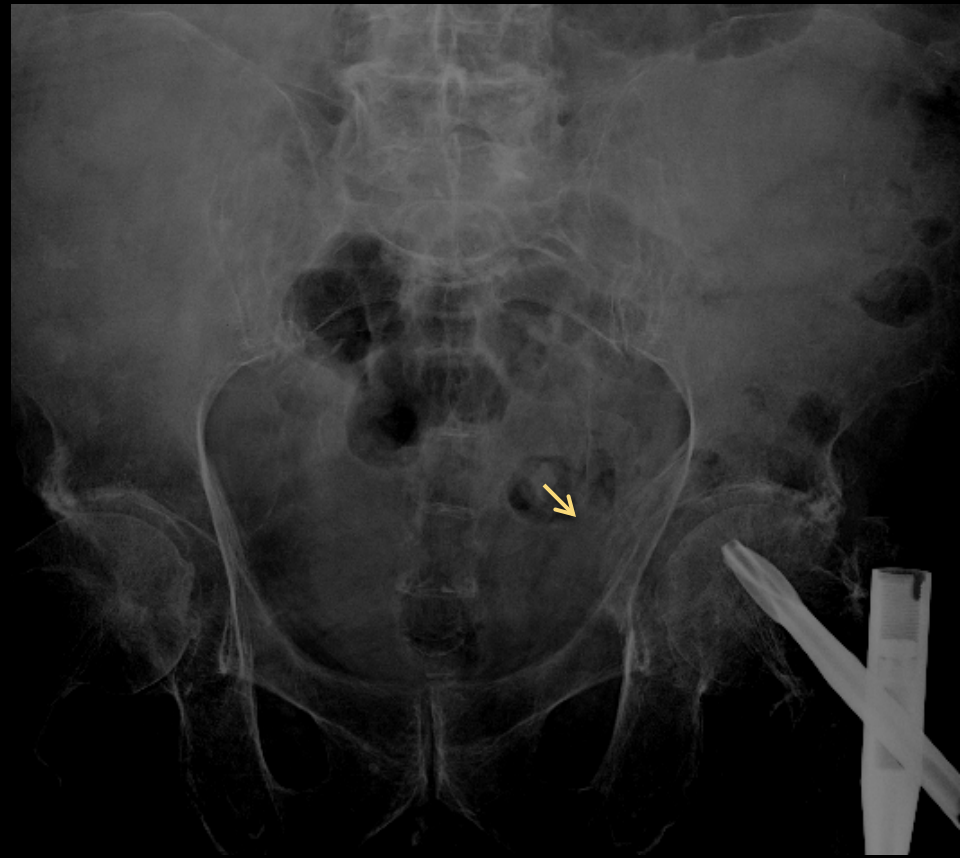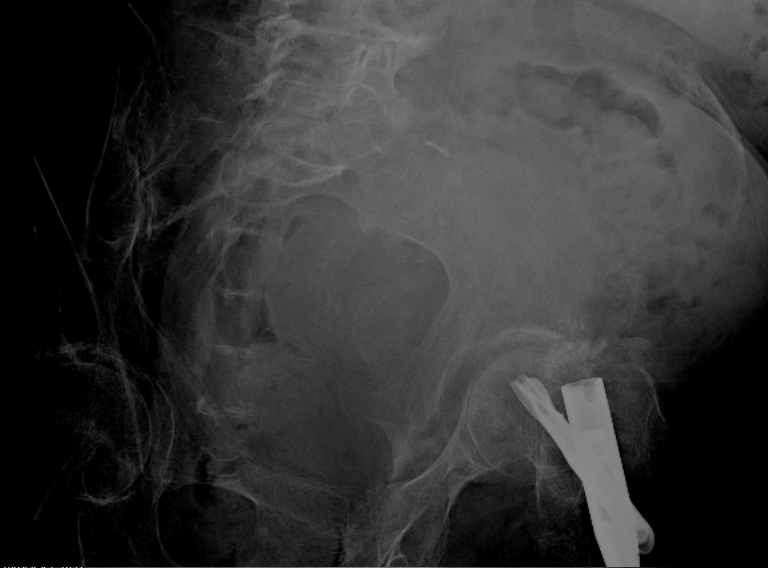
---





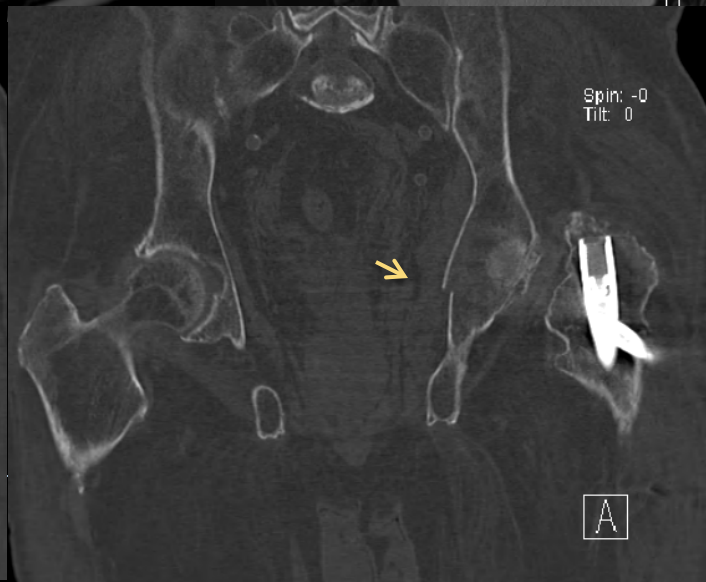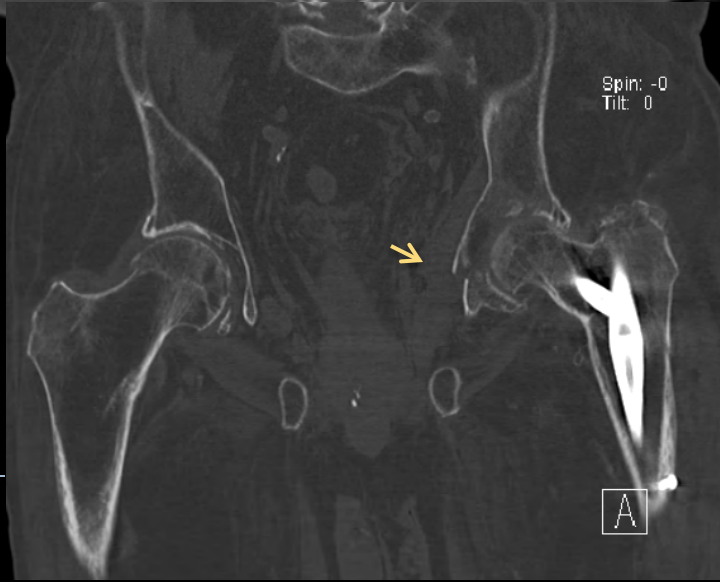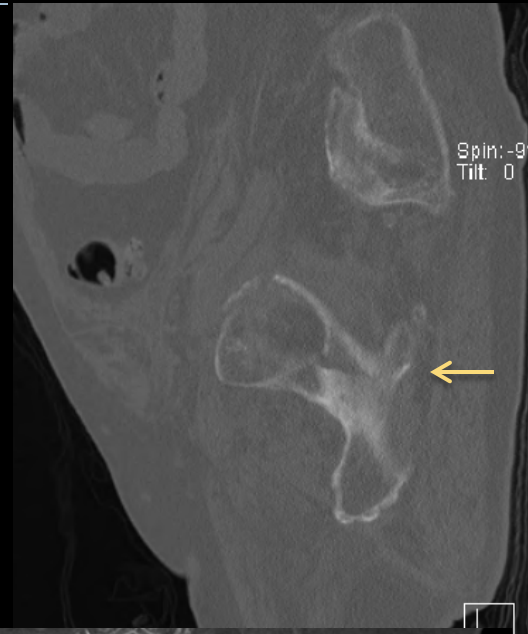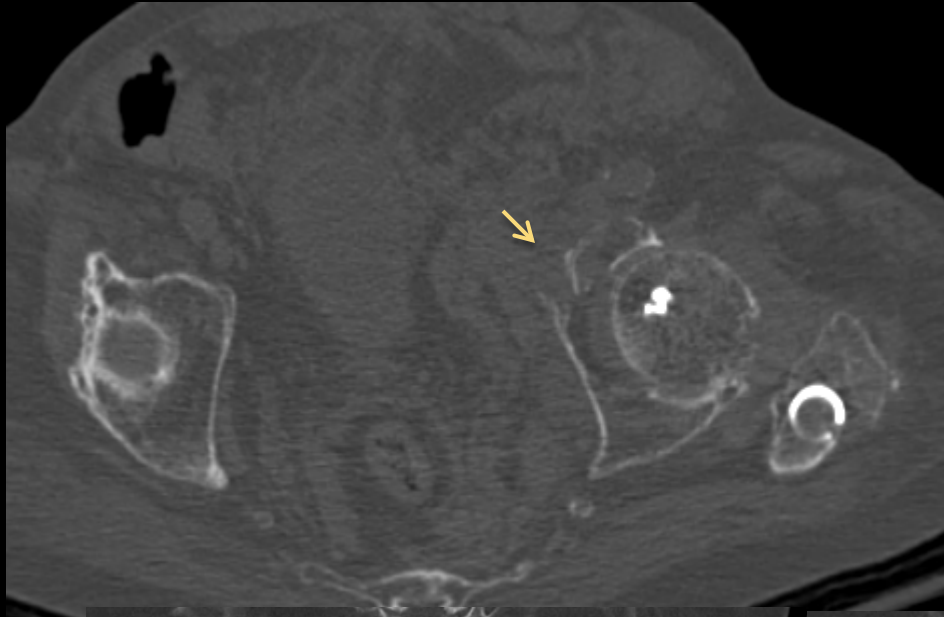
# Anterior column / Posterior hemitransverse “two column”

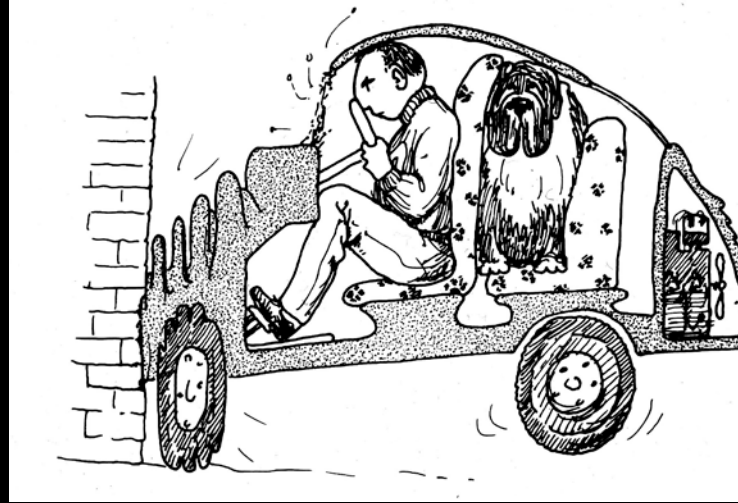
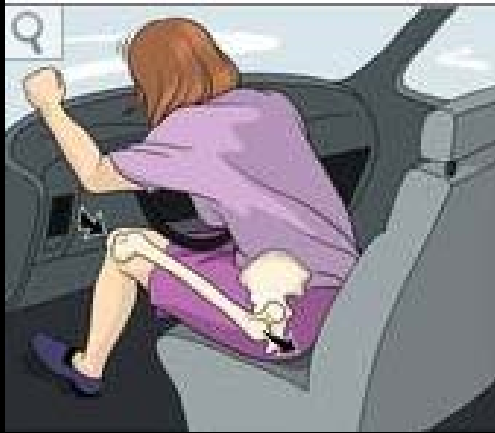---



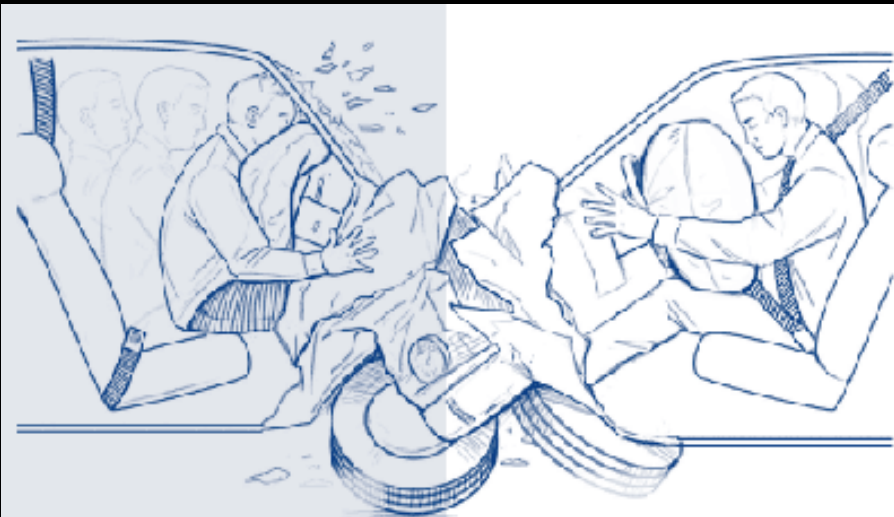
# Anterior column / Posterior hemitransverse “two column”

---





# HIP DISLOCATIONS



# Hip dislocations

---

- ▶ Hip inherently stable (substantial force to dislocate)
- ▶ Associated with other fractures and injuries
  - ▶ Acetabulum
  - ▶ Femoral head, neck, shaft
  - ▶ Ipsilateral knee
  - ▶ Sciatic nerve close by (injury 10-20%)
- ▶ Damage to vascular supply to femoral head
  - ▶ Artery ligamentum teres – most imppt in children
  - ▶ Ascending cervical branches, from base of neck from circumflex femoral arteries



# Hip dislocations

---

- ▶ Treated as surgical emergency
- ▶ Increased risk of osteonecrosis if out >6 hours
  - ▶ 4% < 6 hrs
  - ▶ 58% > 6 hrs
- ▶ Articular cartilage abrades against fracture surface
- ▶ Pressure on Sciatic N.
- ▶ GOAL: reduce risk of osteonecrosis and DJD





# Diagnosis

---

- ▶ Radiographs
- ▶ Femoral head not congruent with acetabulum
- ▶ Femoral head appears larger (anterior) or smaller (posterior) than opposite side
  
- ▶ CT
- ▶ Usually not needed prior to emergent reduction UNLESS:
- ▶ high level of suspicion for a nondisplaced femoral neck fracture

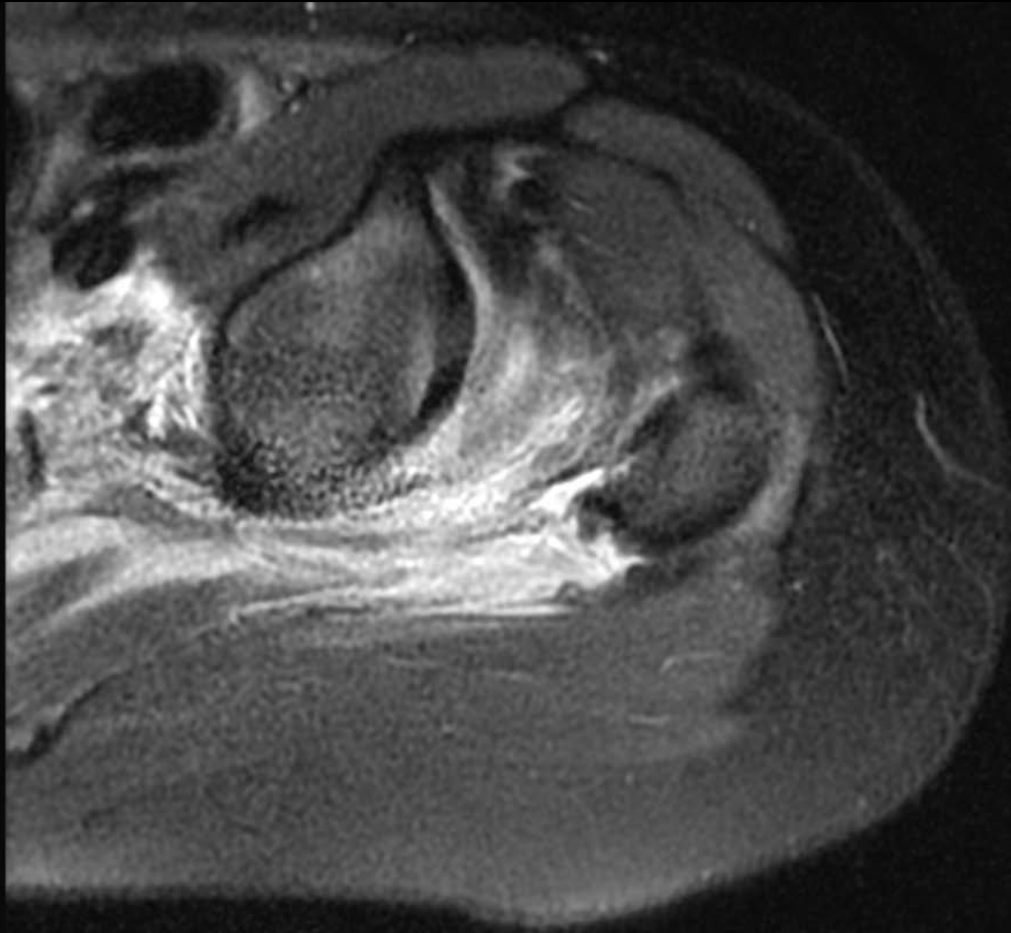


# Utility of MRI after dislocation

---

- ▶ Not shown to be benefit in acute evaluation and treatment of hip dislocations
- ▶ Evaluate for labral tears and soft tissue trauma, intra-articular soft tissue structures



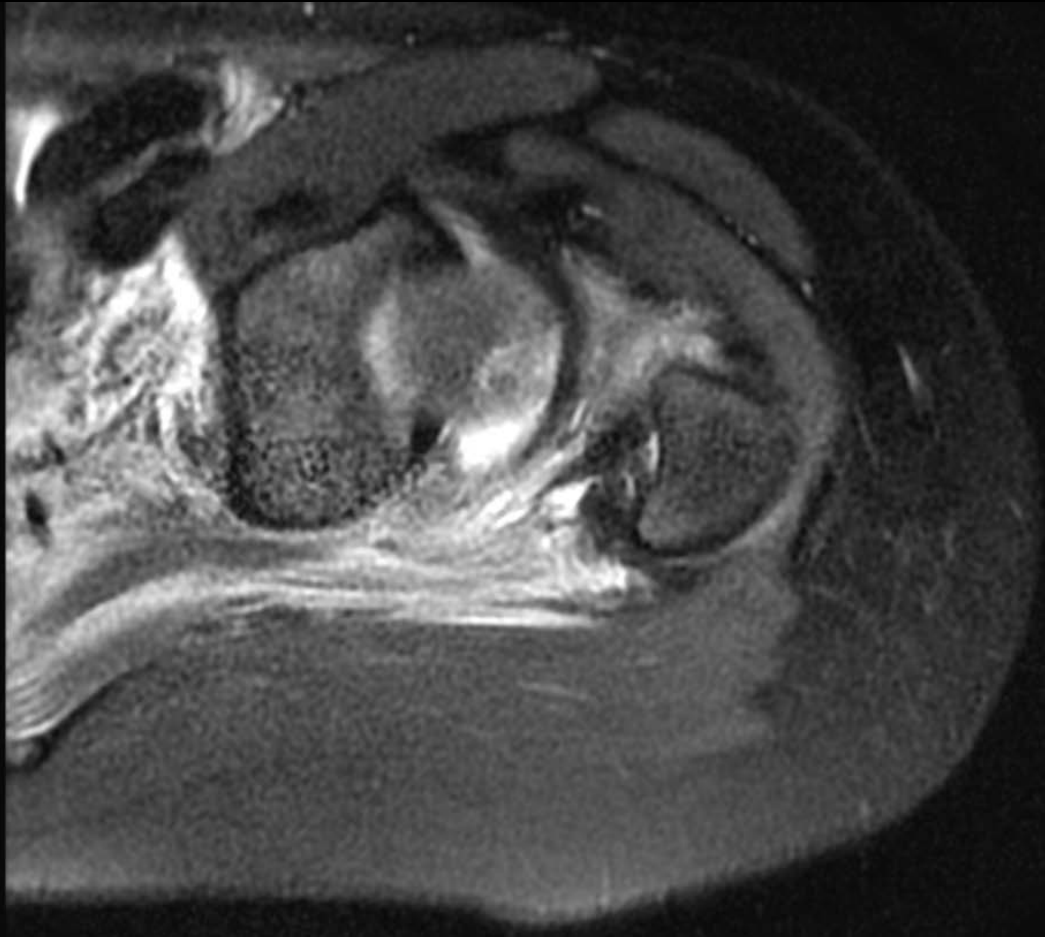


CBA  
IMG#4

P

ECHO# 1  
TR: 2233.34  
TE: 44.256



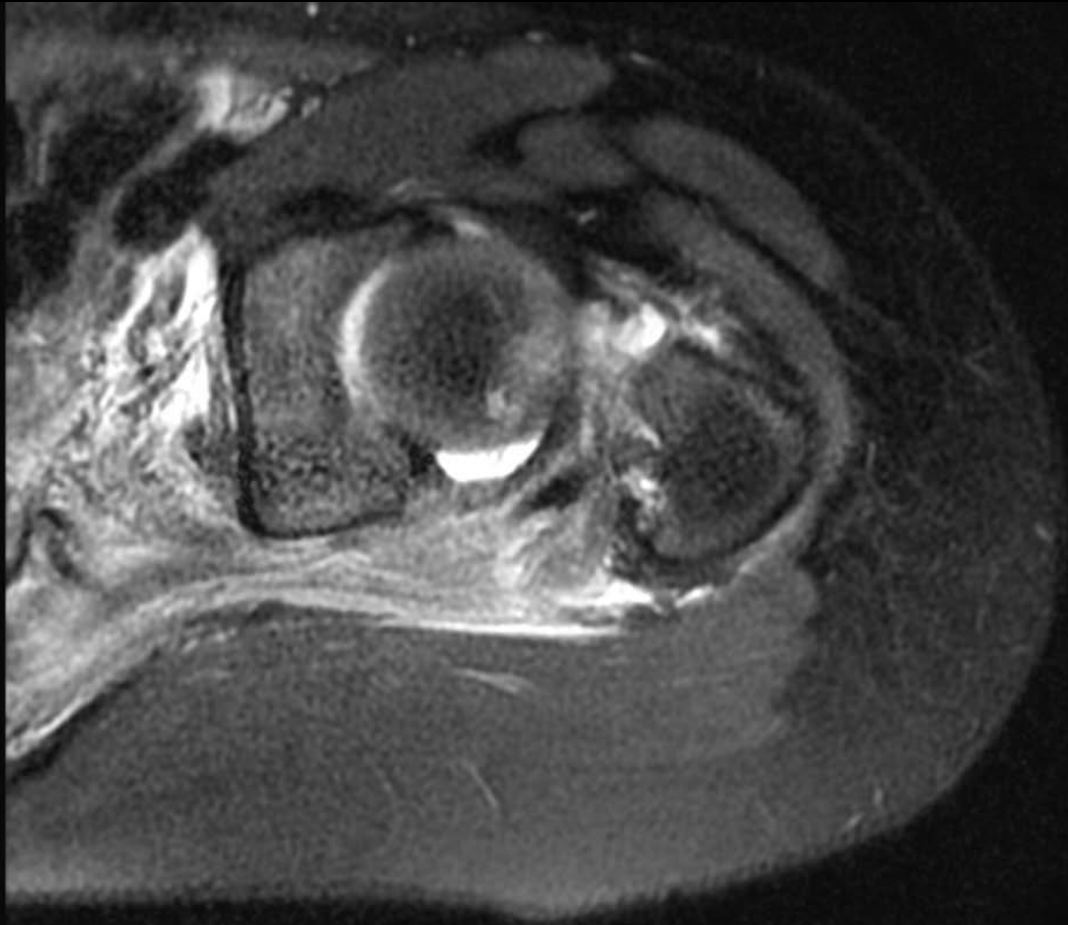


CBA  
IMG#5

P

ECHO# 1  
TR: 2233.34  
TE: 44.256





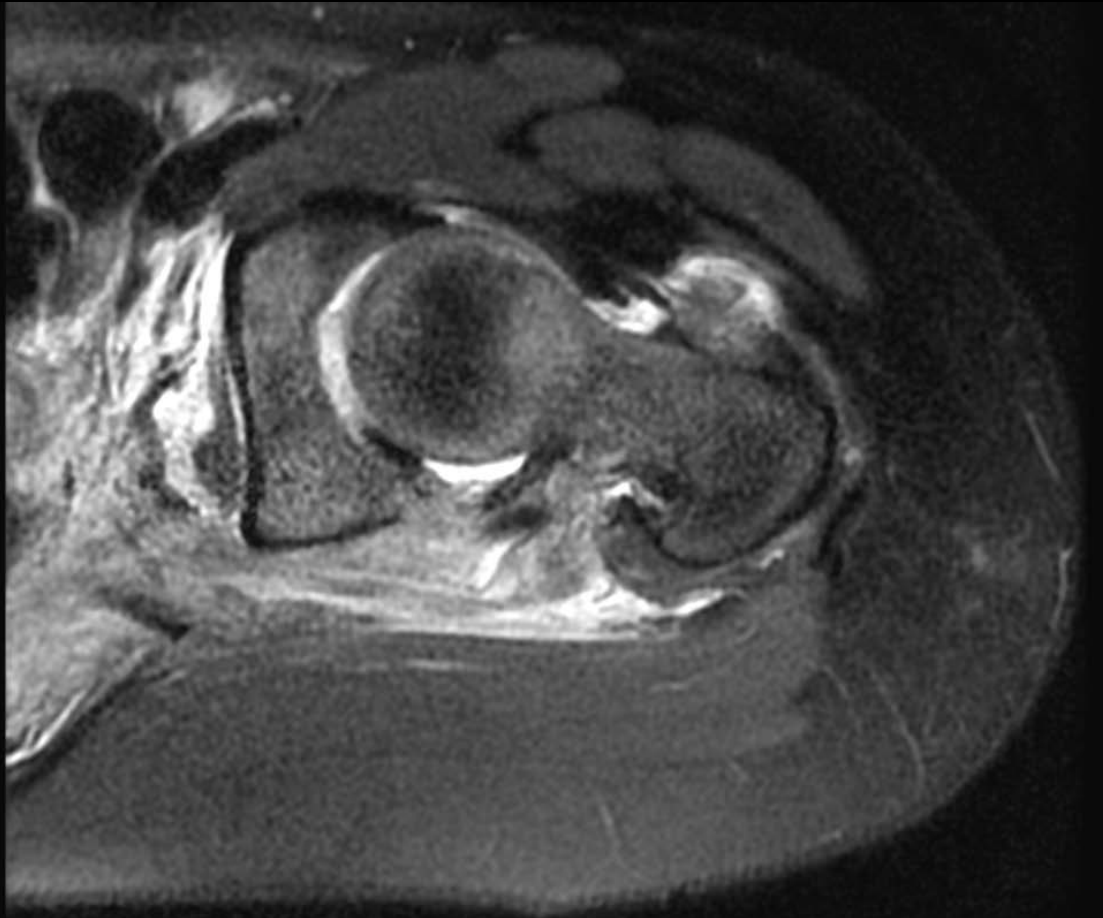
CBA  
IMG#6

P

ECHO# 1  
TR: 2233.34  
TE: 44.256





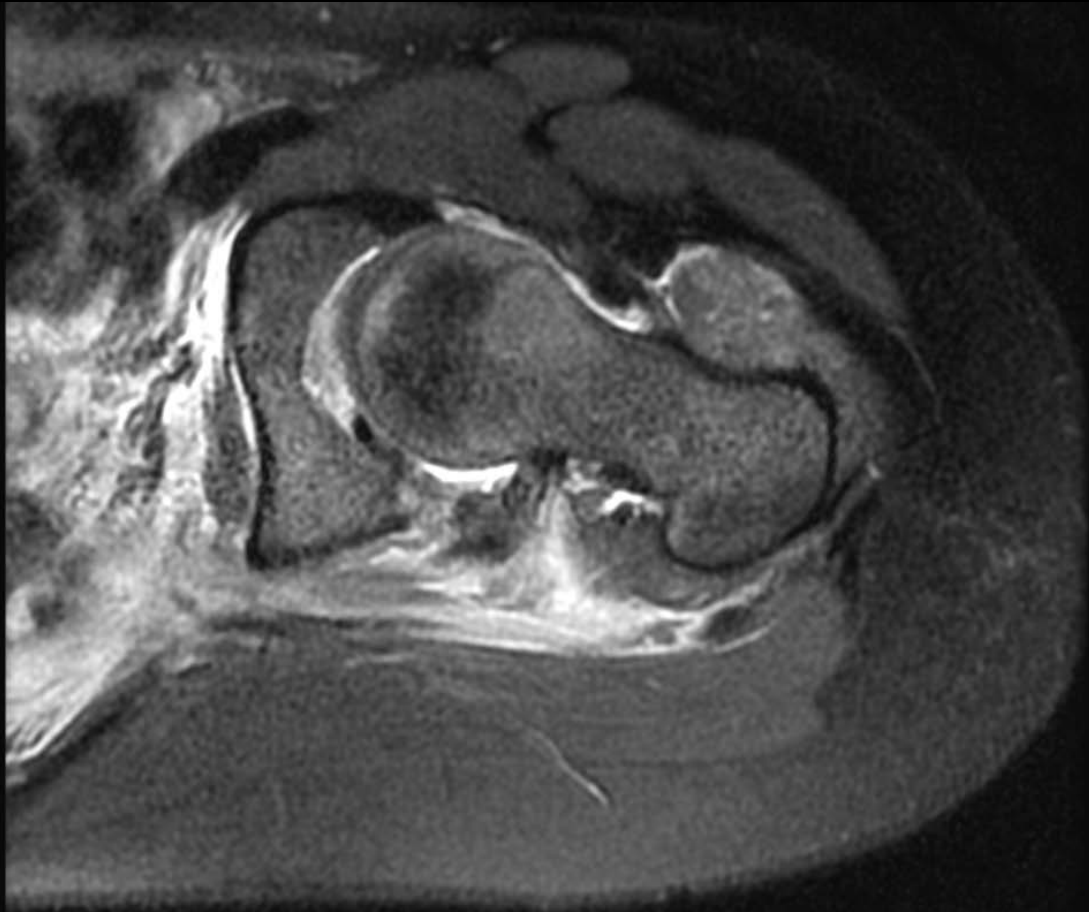


CBA:  
IMG#:7

P

ECHO# 1  
TR: 2233.34  
TE: 44.256



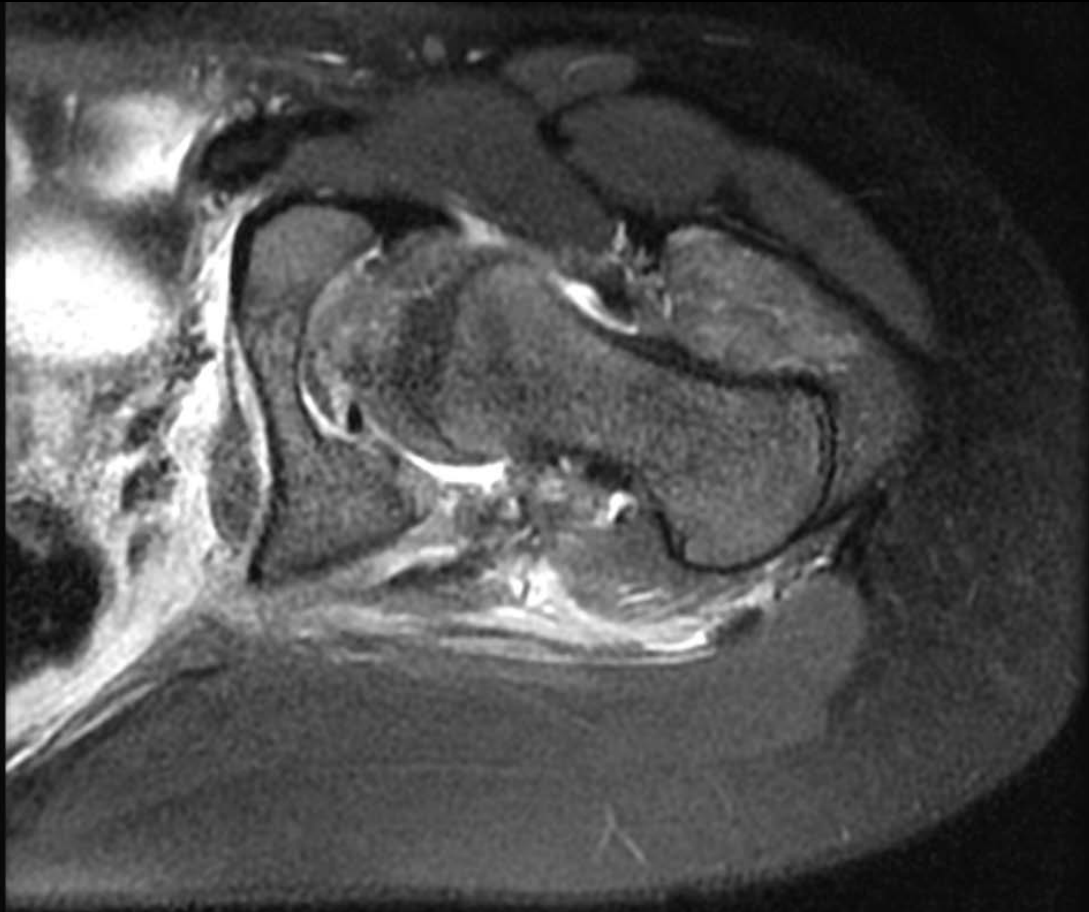


CBA  
IMG#8

P

ECHO# 1  
TR: 2233.34  
TE: 44.256



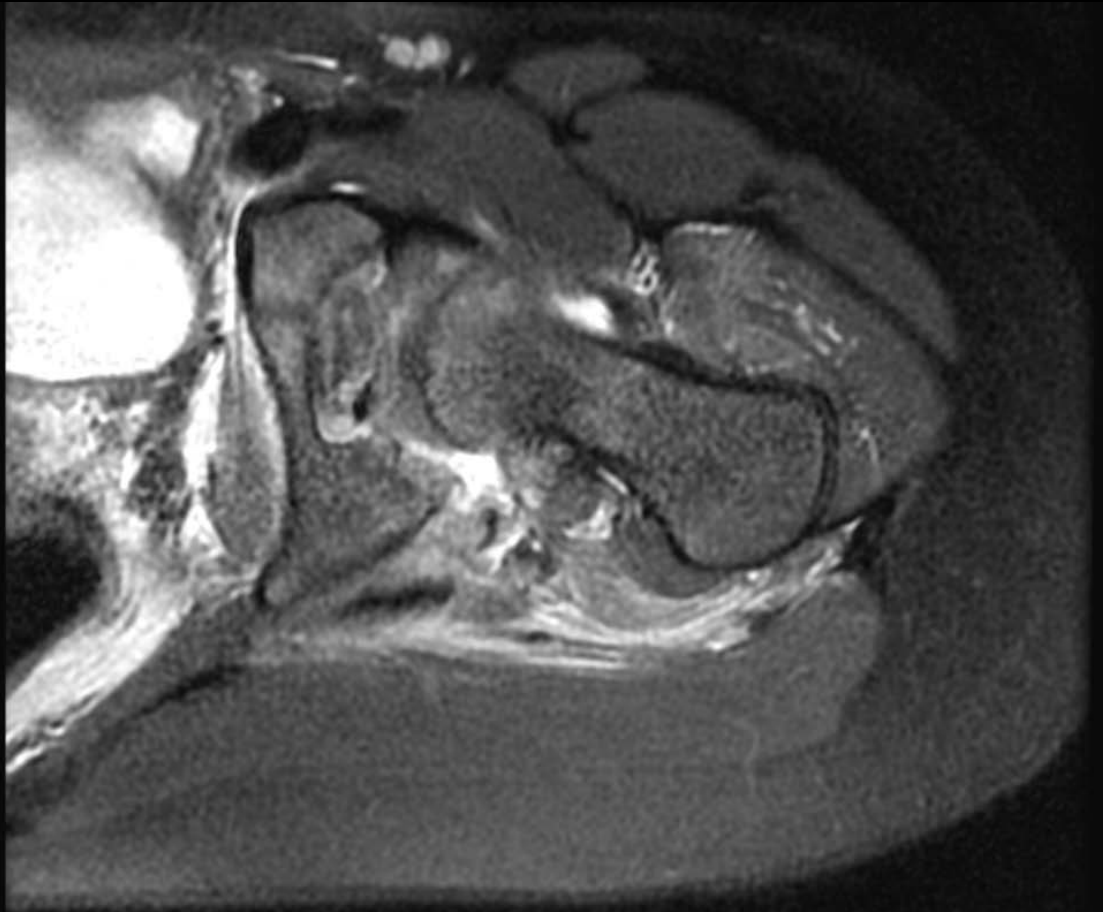


CBA  
IMG# 9

P

ECHO# 1  
TR: 2233.34  
TE: 44.256



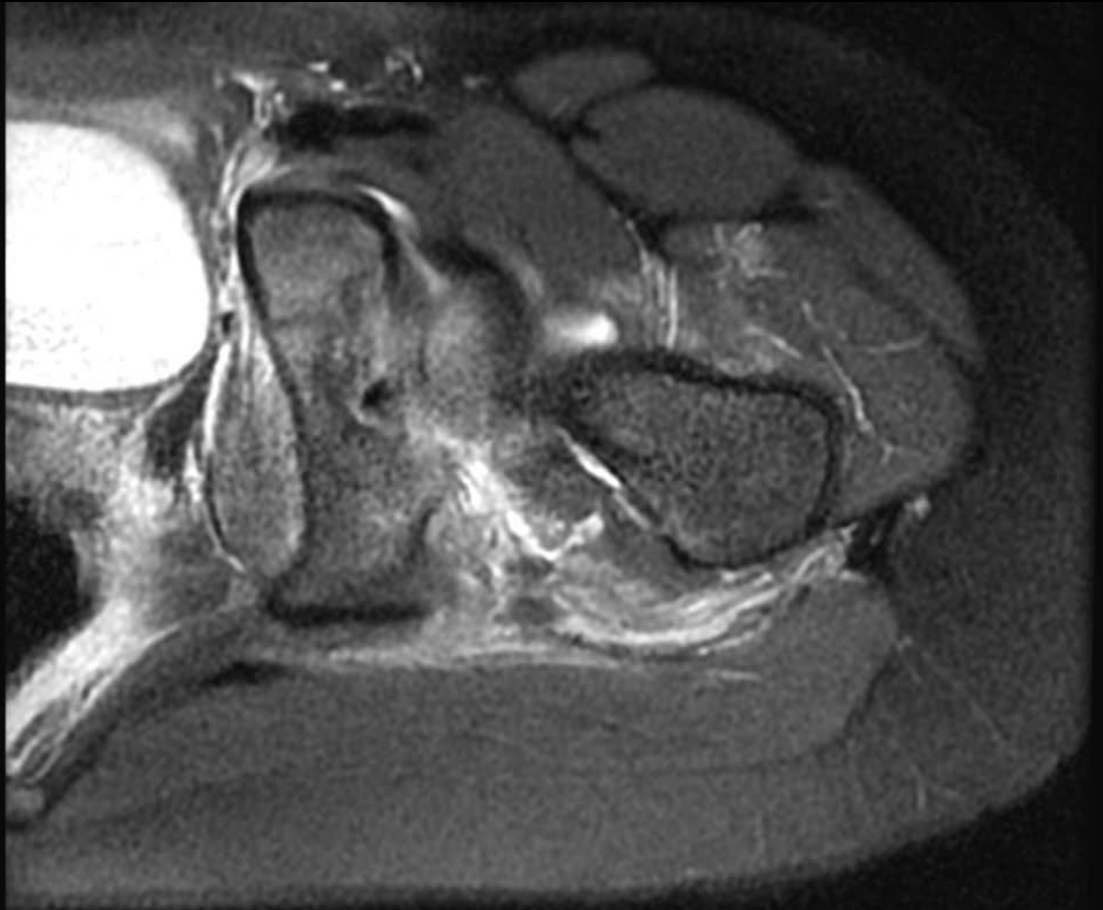


CBA  
IMG# 10

P

ECHO# 1  
TR: 2233.34  
TE: 44.256





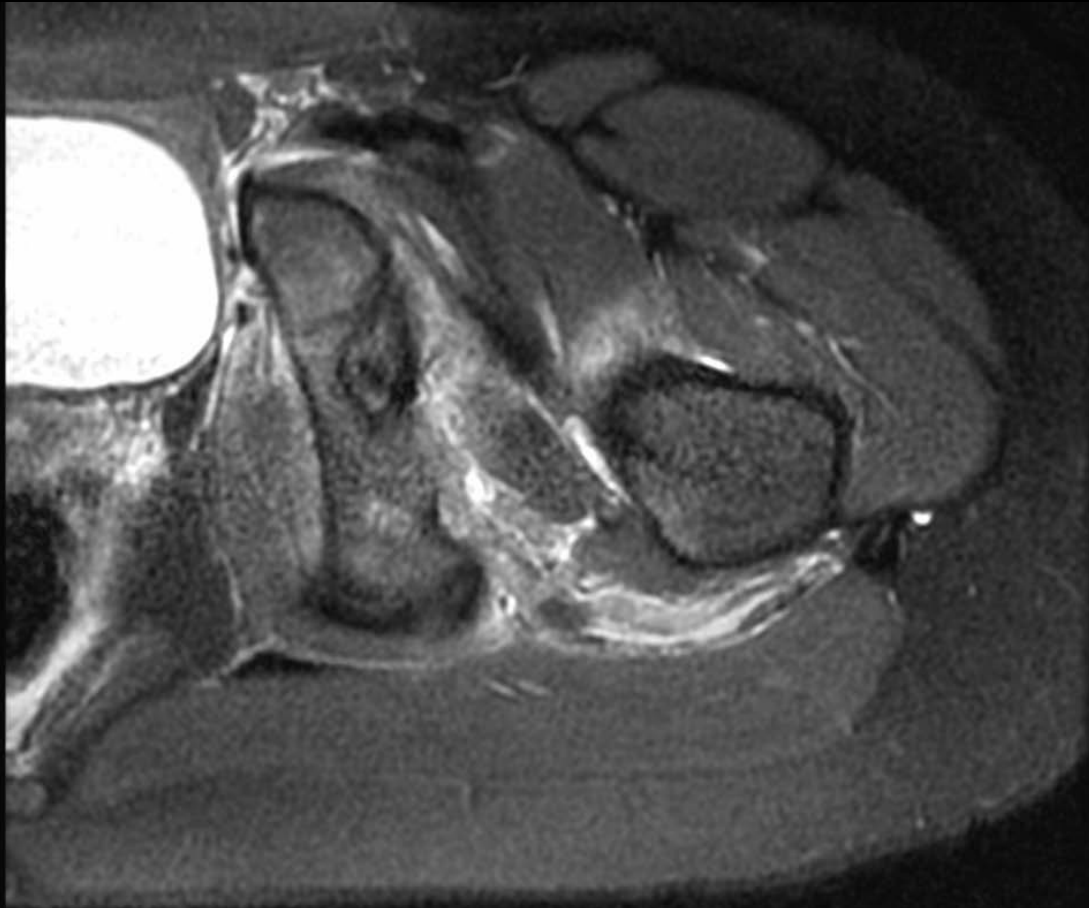
CBA  
IMG# 11

P

ECHO# 1  
TR: 2233.34  
TE: 44.256





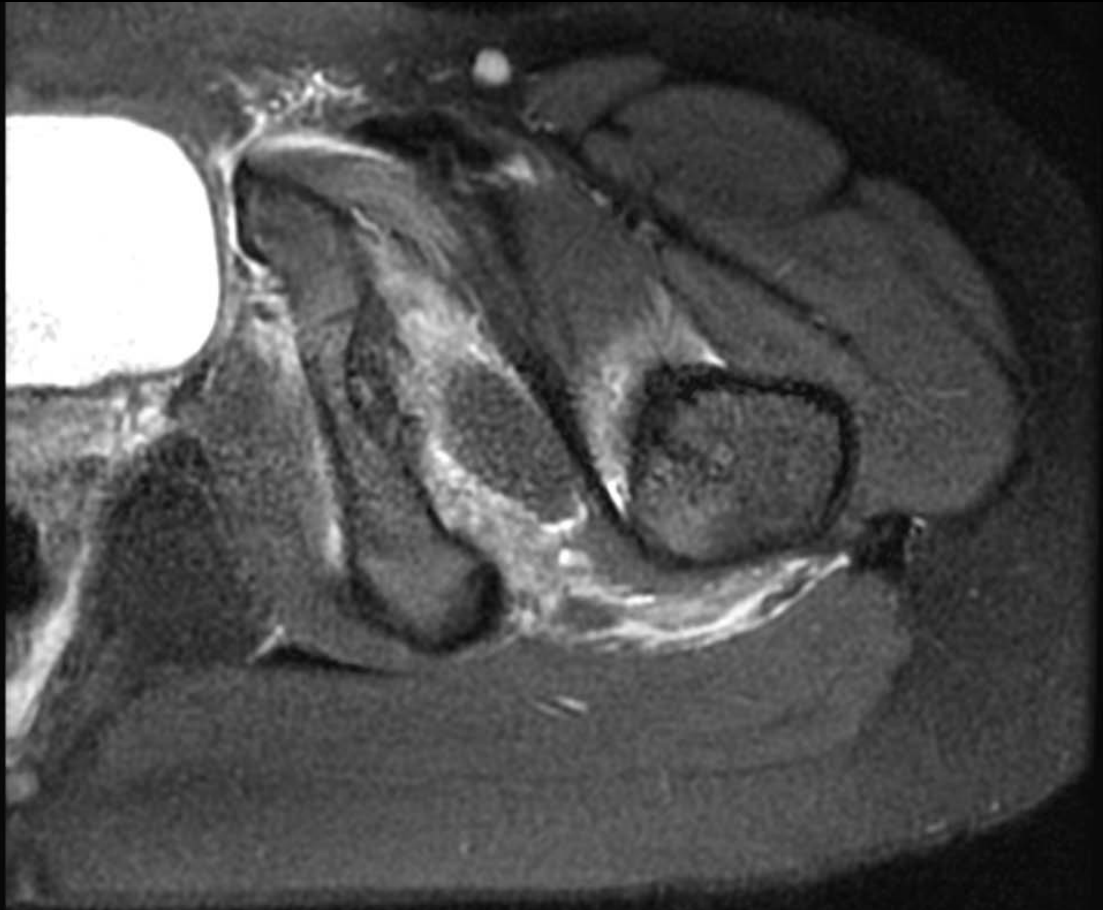


CBA  
IMG# 12

P

ECHO# 1  
TR: 2233.34  
TE: 44.256





CBA  
IMG# 13

P

ECHO# 1  
TR: 2233.34  
TE: 44.256



# Indications for operative treatment

---

1. Irreducible hip dislocation
  2. Hip dislocation with femoral neck fracture
  3. Intra-articular fragment
  4. Incongruent (nonconcentric) reduction
  5. Unstable hip after reduction (subluxation with stress testing)
- ▶ **Incongruity**
    - ▶ Intra-articular ossific fragments, or soft tissue interposition
    - ▶ Disrupted column integrity or femoral fractures
  - ▶ **Instability**
    - ▶ Usually posterior injuries (> 40% posterior wall disrupted)
    - ▶ medial instability with quadrilateral plate fractures
  - ▶ Negative CT scan does not rule out intra-articular pathology



# Irreducible hip dislocation

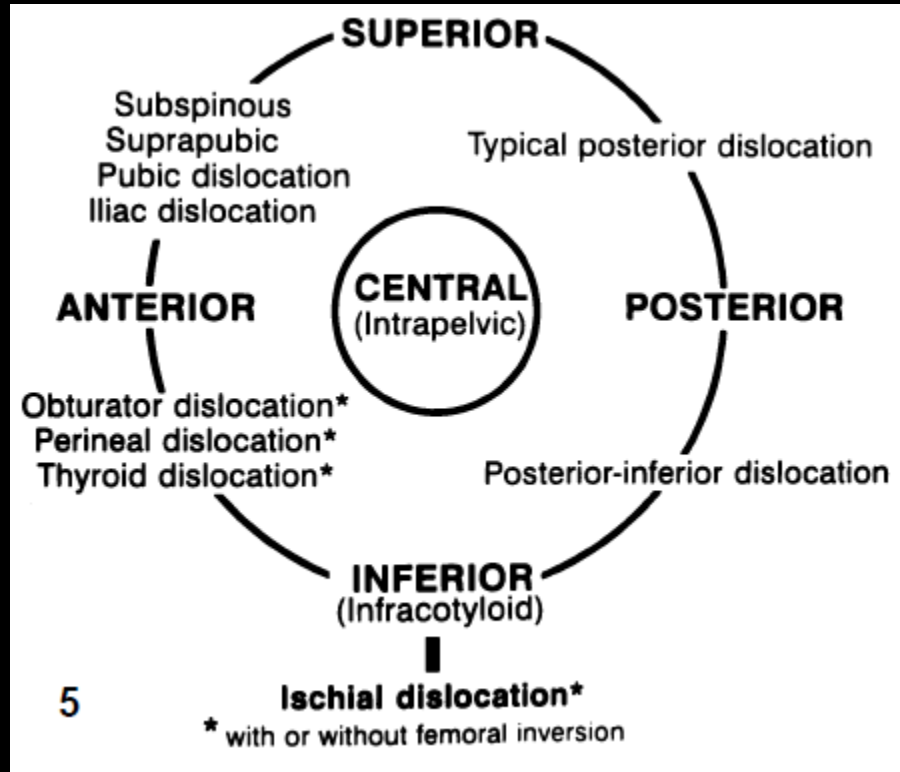
---

- ▶ “A dislocation should be considered
- ▶ irreducible when a senior member of
- ▶ the orthopaedic team fails to obtain
- ▶ reduction despite the administration
- ▶ of an anesthetic that achieves deep
- ▶ sedation and good muscle relaxation.”
  
- ▶ labrum, capsule, iliopsoas, rectus femoris, piriformis, gluteus maximus, ligamentum teres, or bone fragments from the acetabular wall or femoral head.



# hip dislocations

---

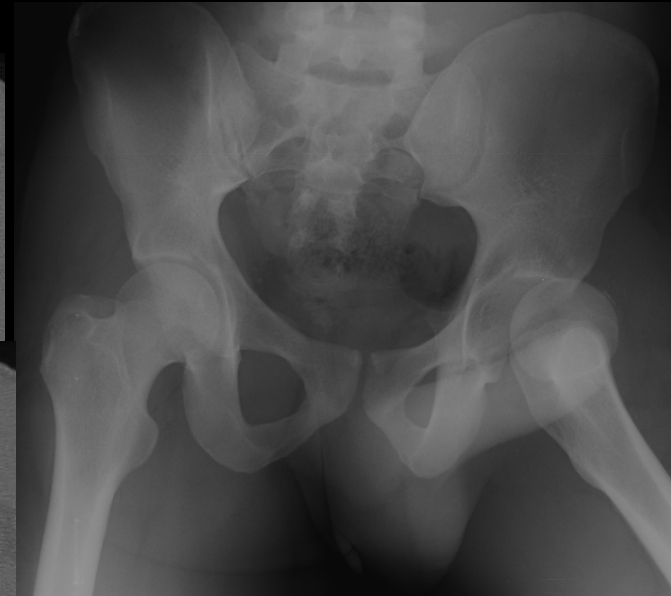
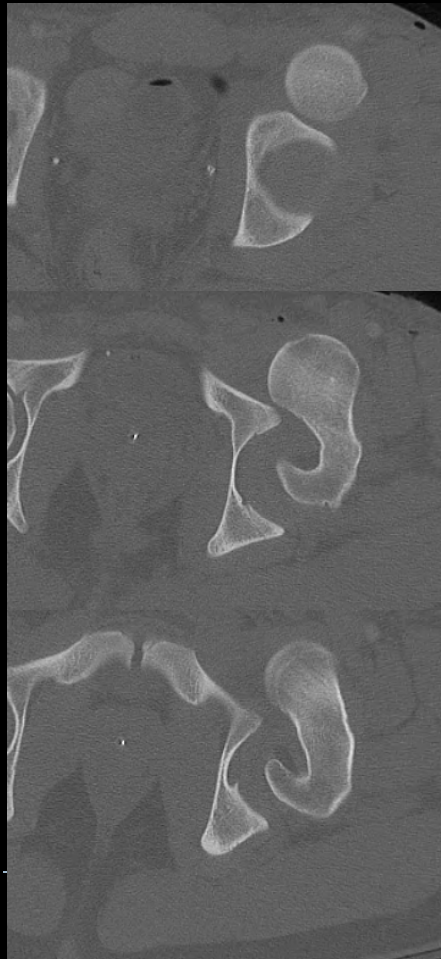




# Anterior hip dislocations

---

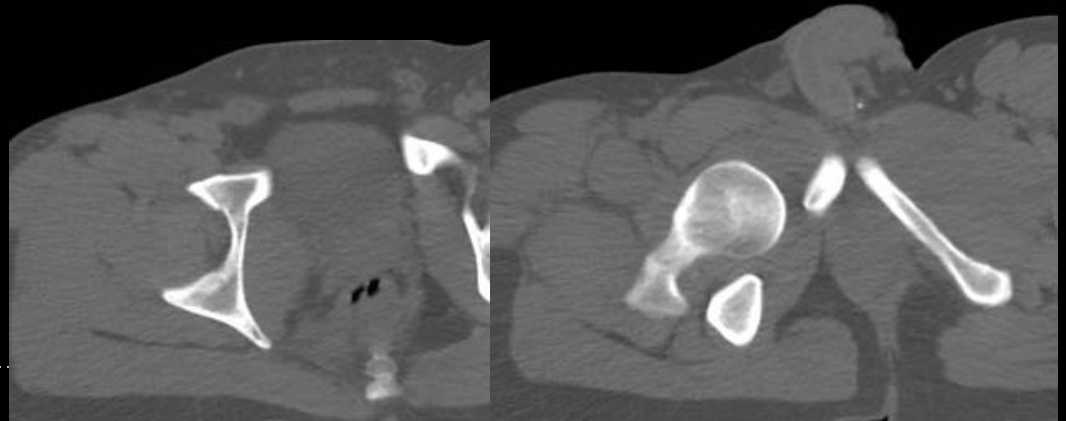
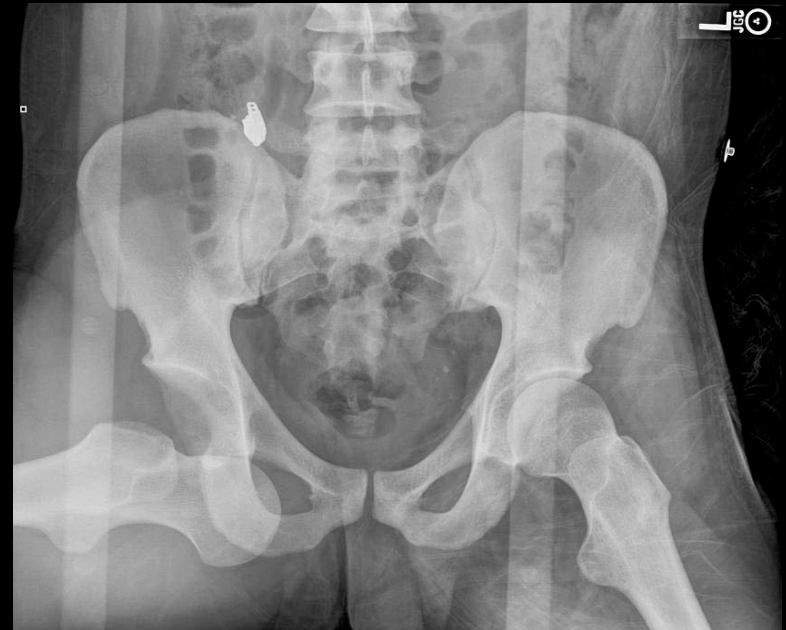- ▶ < 10%
- ▶ Femur externally rotated
  - ▶ LT more prominent
- ▶ Iliac (superolateral)
- ▶ Obturator (inferior)
- ▶ Pubic (superomedial)



# Anterior hip dislocation

22 yo dirt bike accident

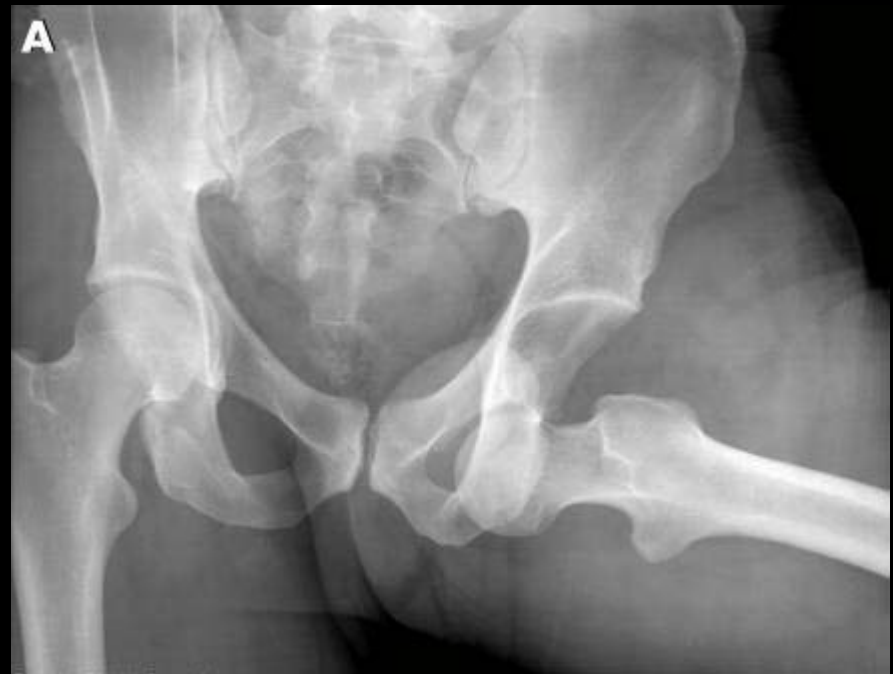- ▶ < 10%
- ▶ Femur externally rotated
  - ▶ LT more prominent
- ▶ Iliac (superolateral)
- ▶ Obturator (inferior)
- ▶ Pubic (superomedial)



# Anterior hip dislocation

---

- ▶ < 10%
- ▶ Femur externally rotated
  - ▶ LT more prominent
- ▶ Iliac (superolateral)
- ▶ Obturator (inferior)
- ▶ Pubic (superomedial)



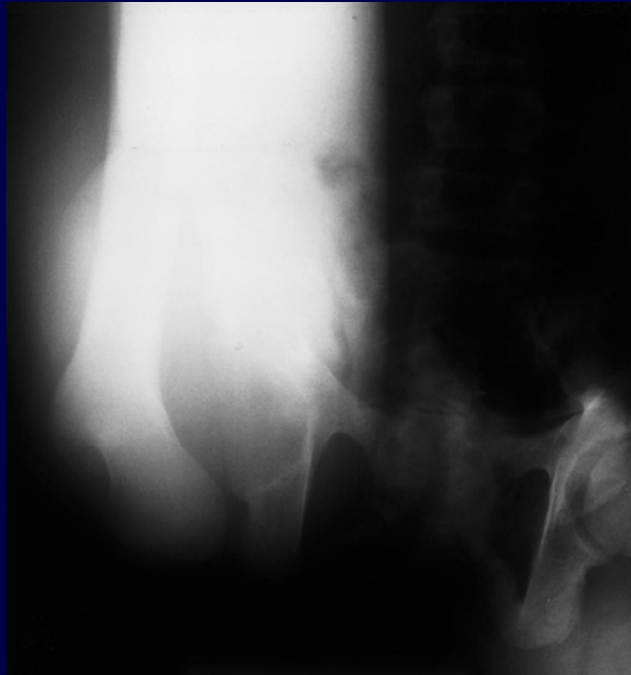
Croft SJ, brenchley J, Bradhe, SP, et al. An unusual rugby injury. Emerg Med J. 2006 June; 23(6): e40.

---

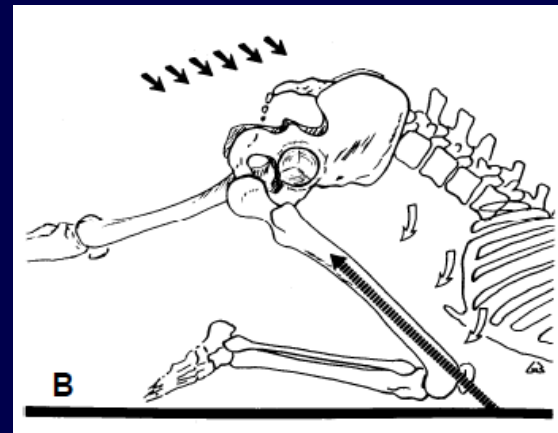
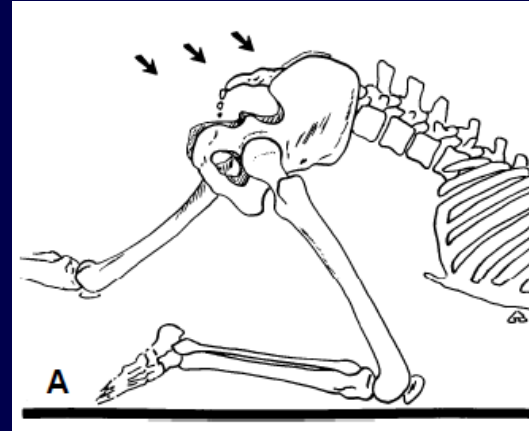


# LUXATIO ERECTA FEMORIS

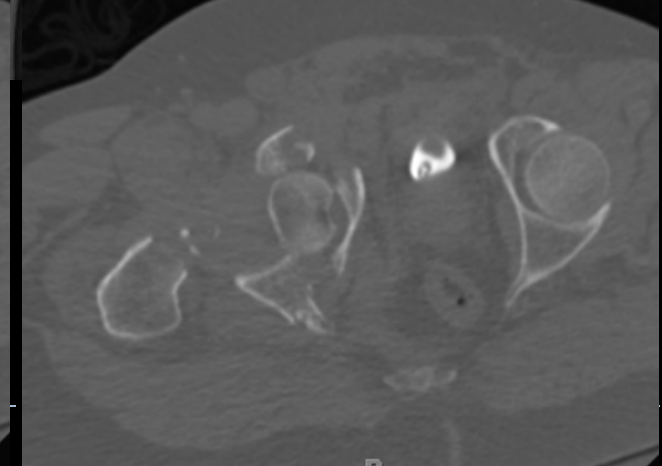
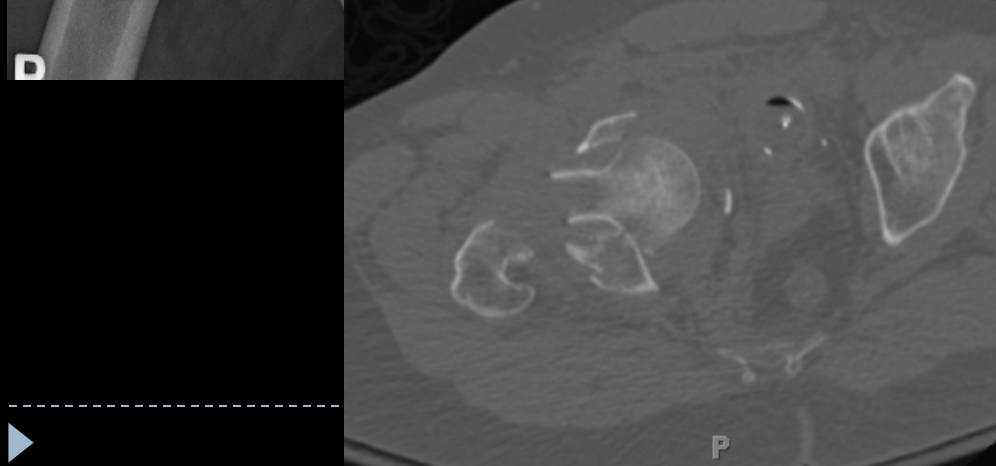
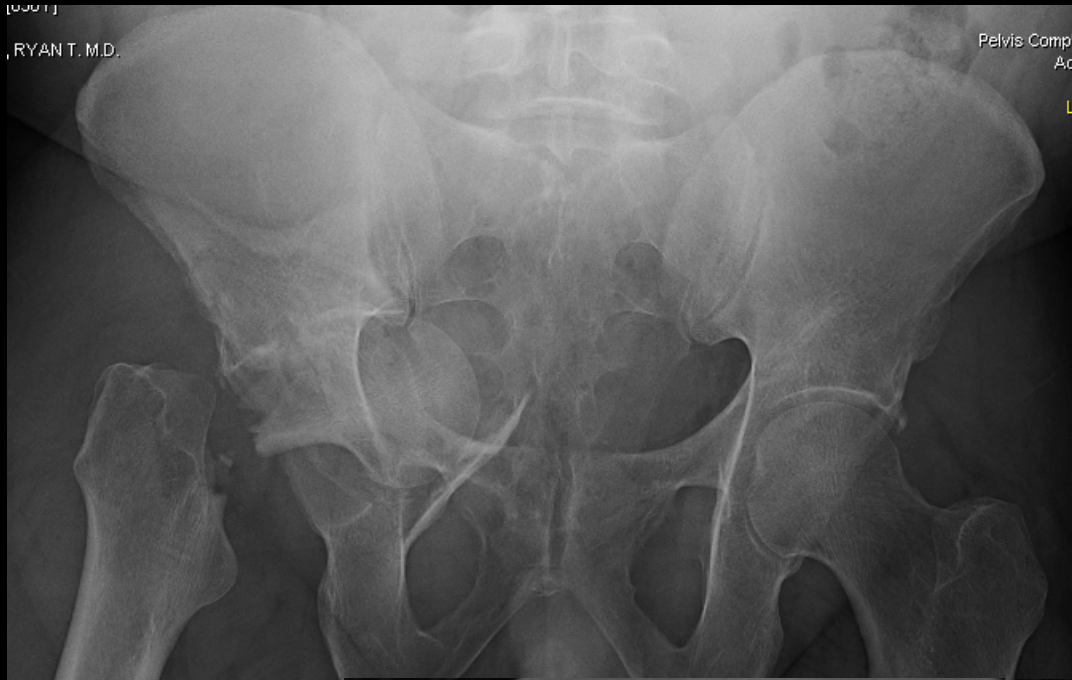- ▶ 15 yo male after football injury



Inferior ischial  
dislocation with  
femoral inversion



# Central hip dislocation



# Posterior hip dislocation

---

## Thomas/Epstein classification - Most well-known

- Type I Pure dislocation with at most a small posterior wall fragment.
- Type II Dislocation with large posterior wall fragment.
- Type III Dislocation with comminuted posterior wall.
- Type IV Dislocation with “acetabular floor” fracture (probably transverse + post. wall acetabulum fracture-dislocation).
- Type V Dislocation with femoral head fracture.

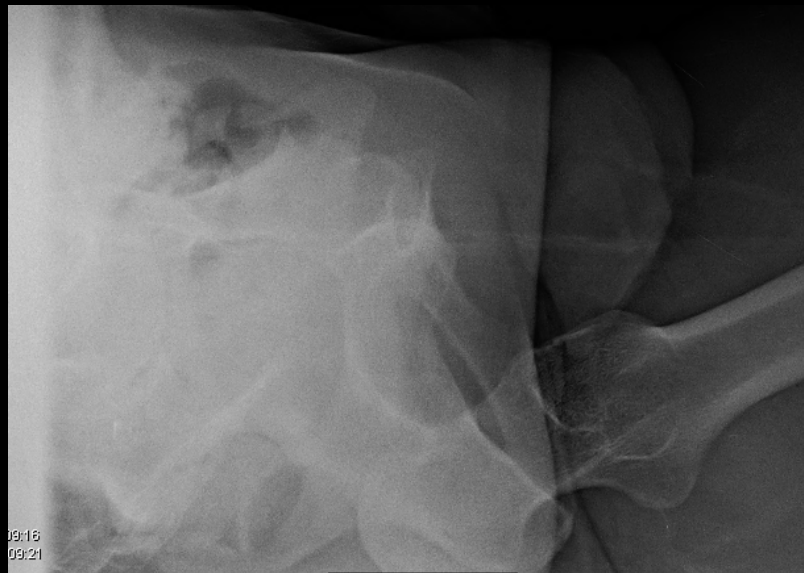
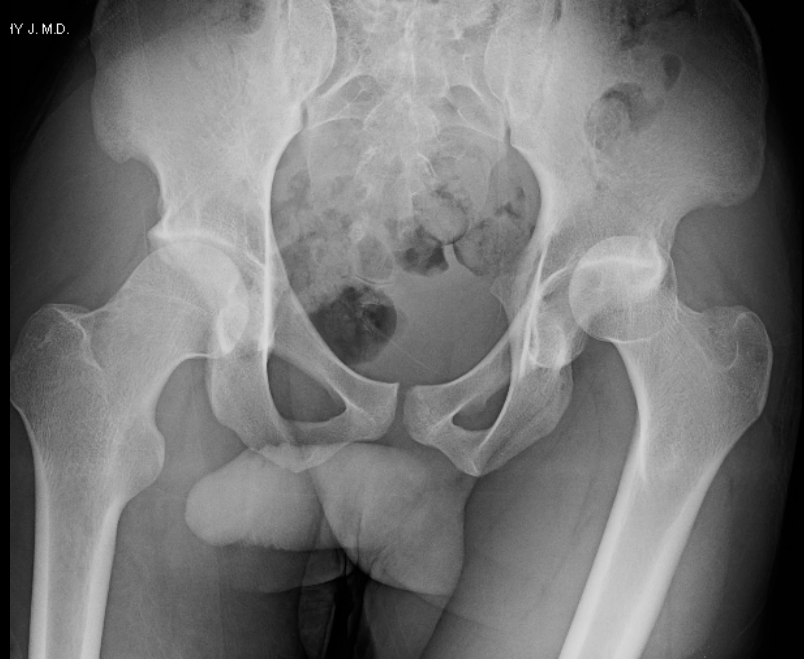


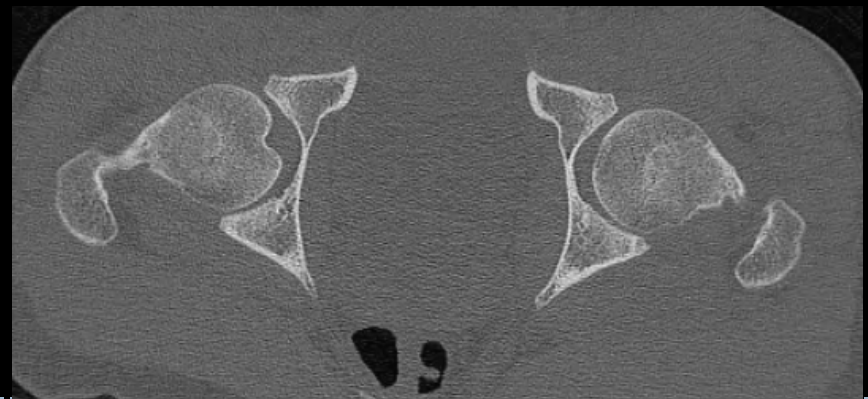
# TYPE I

---

TY J. M.D.


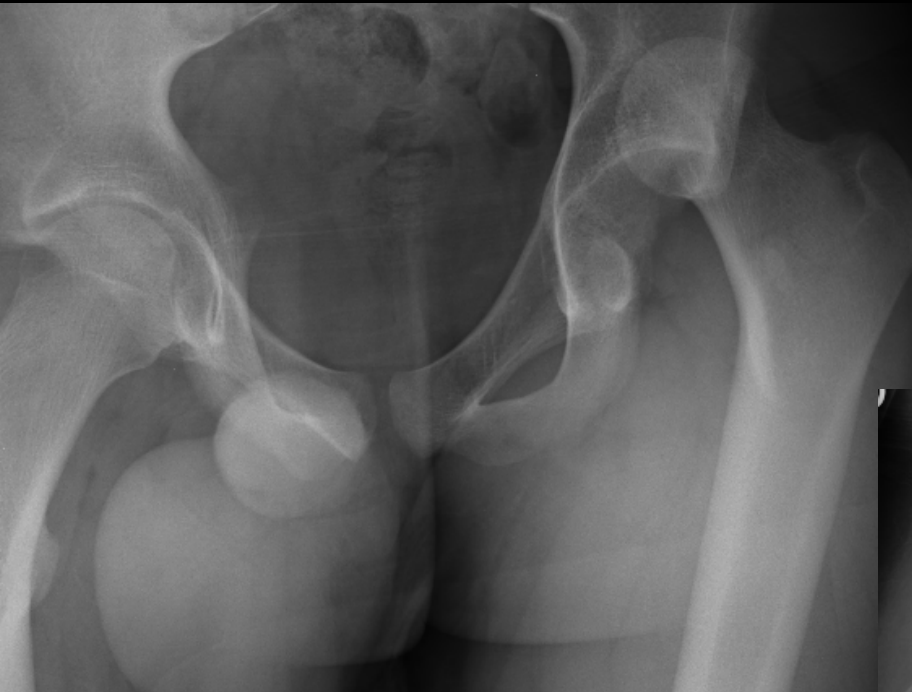


09:16  
09:21

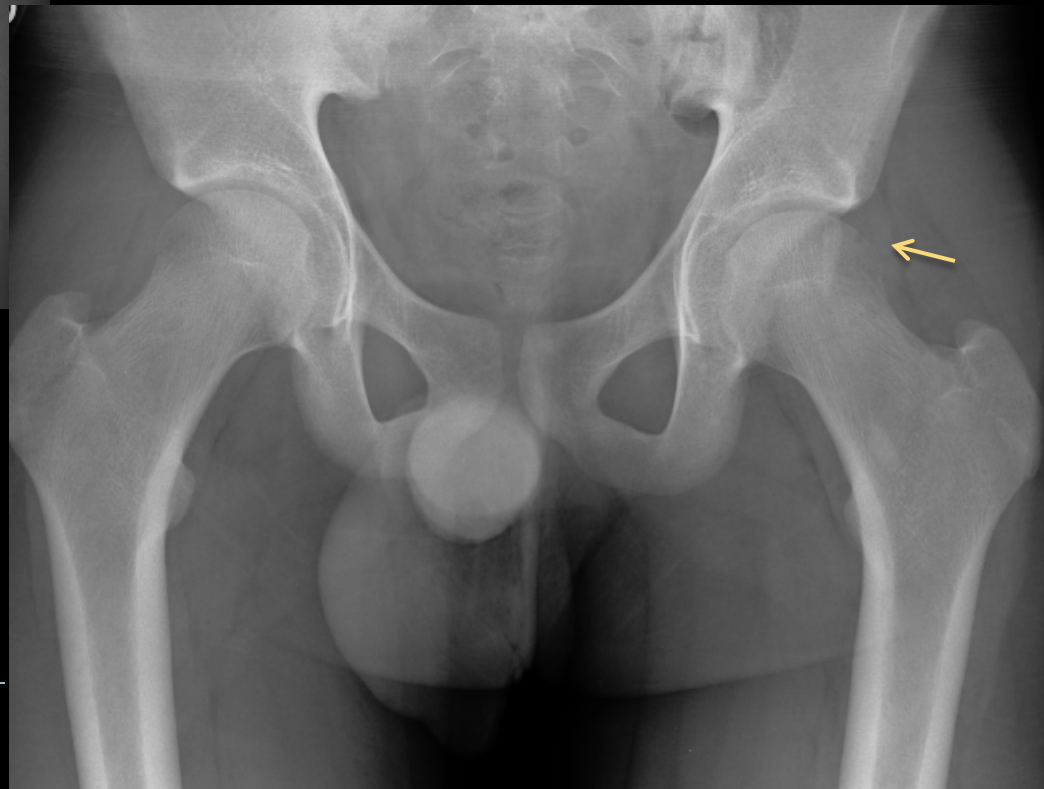

# TYPE I

---

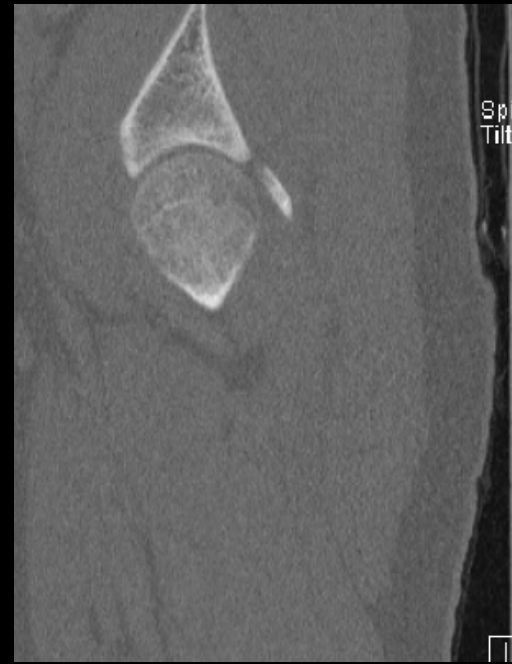
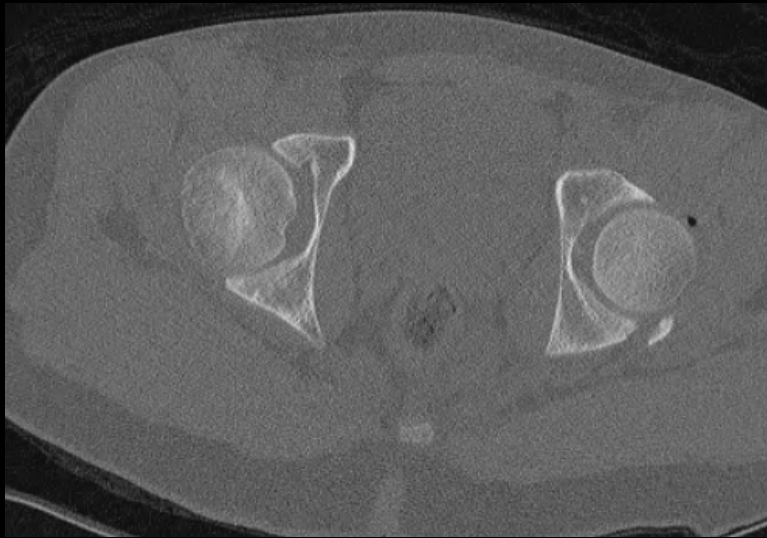
reduction



# TYPE I

---



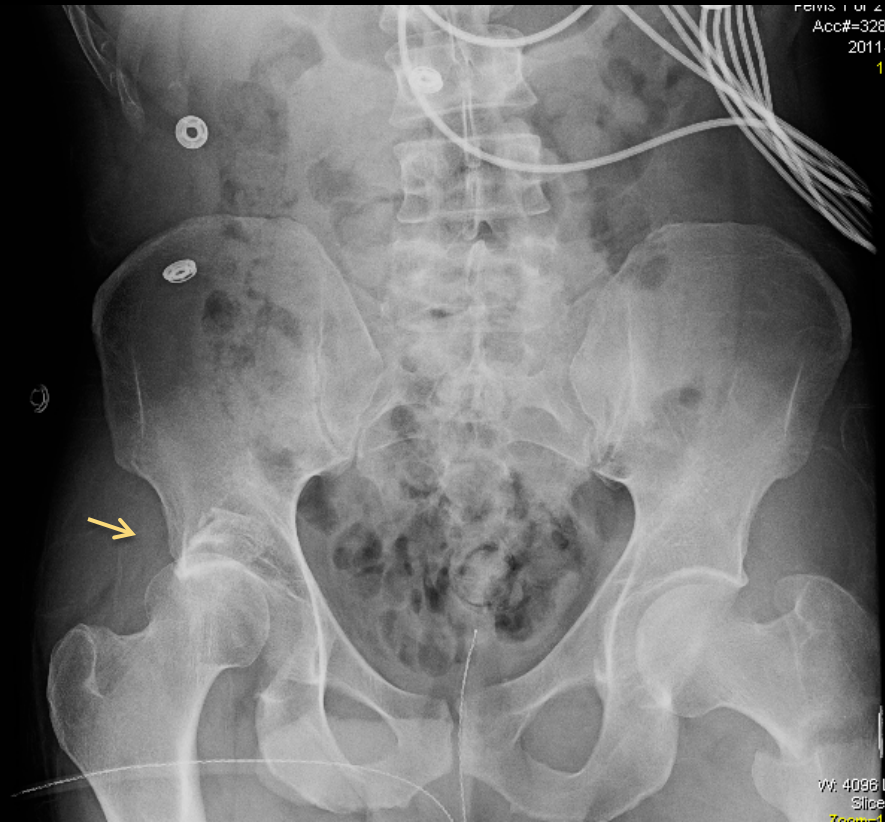
**TYPE II** - imagine posterior wall fracture is a lot bigger

---



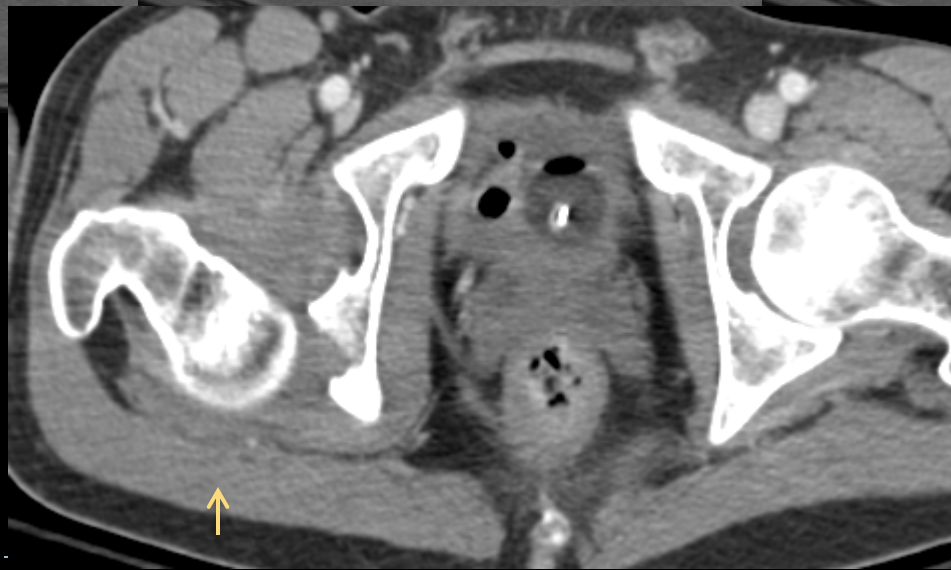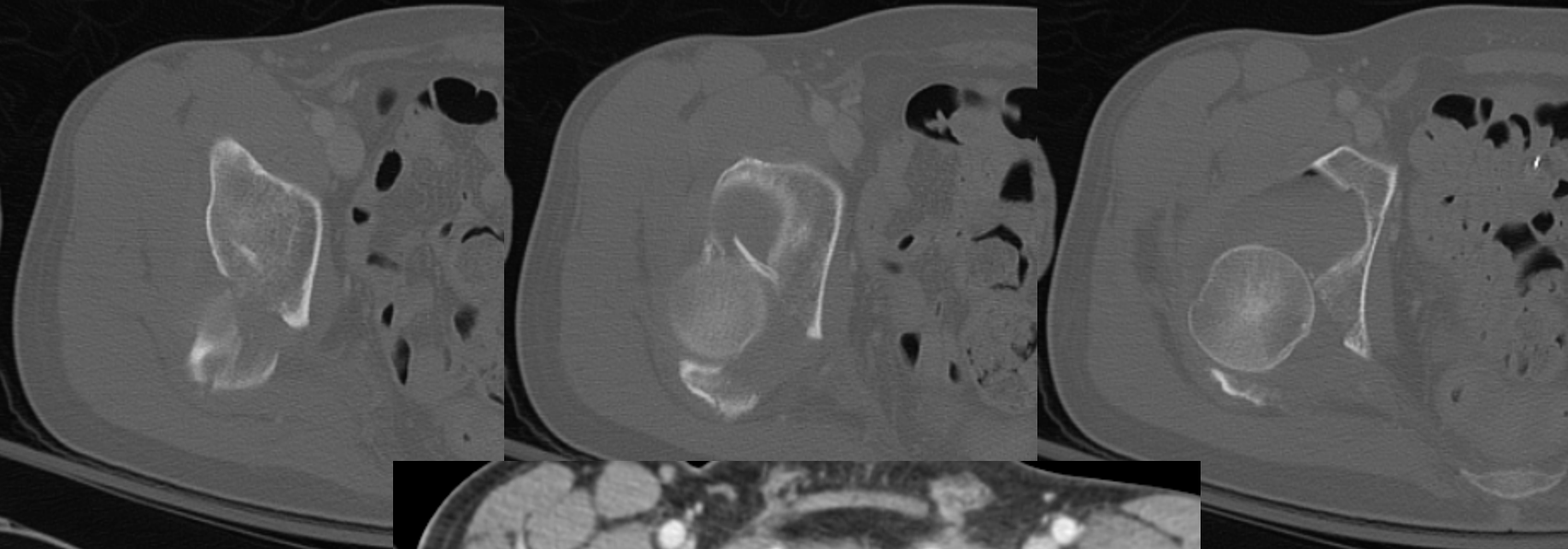
# TYPE III

---



# TYPE III

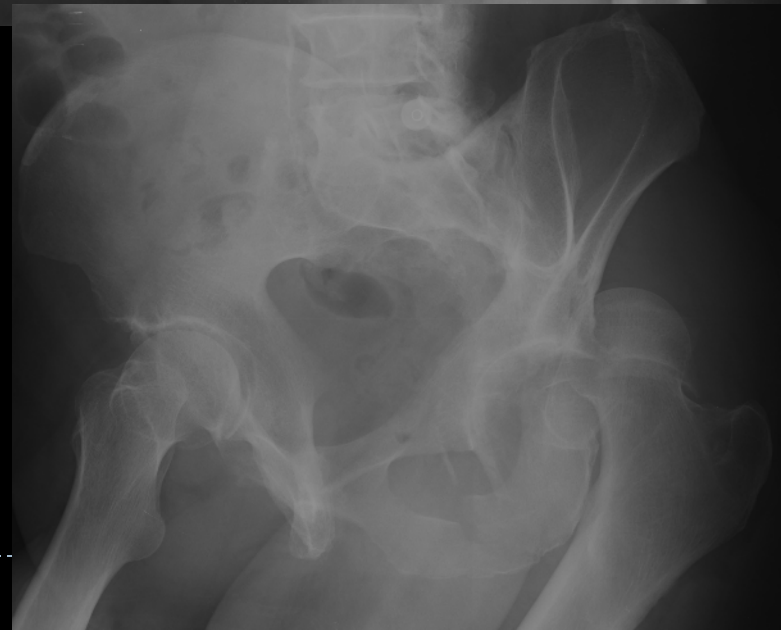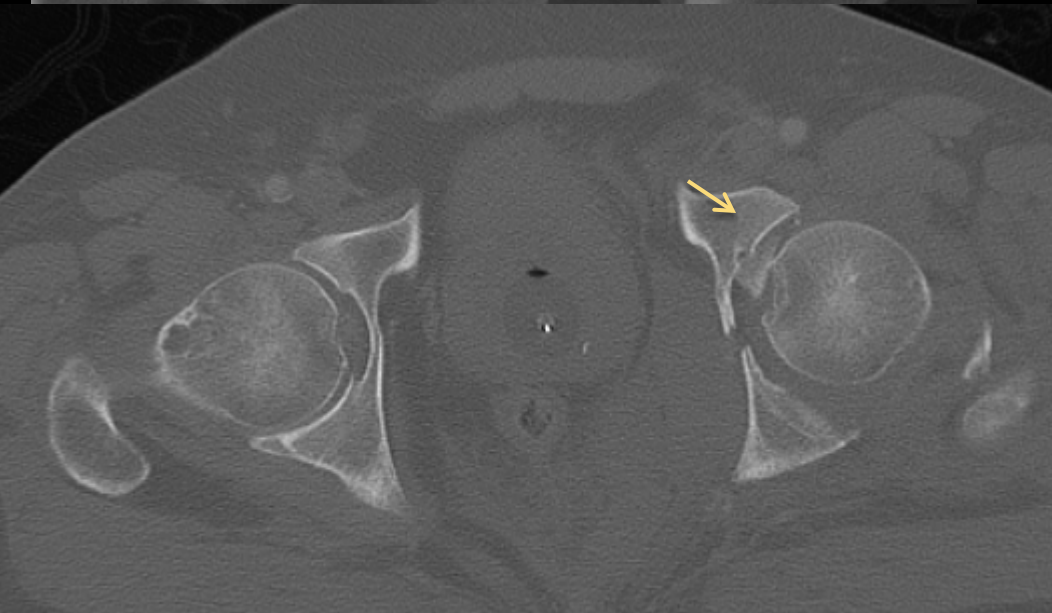
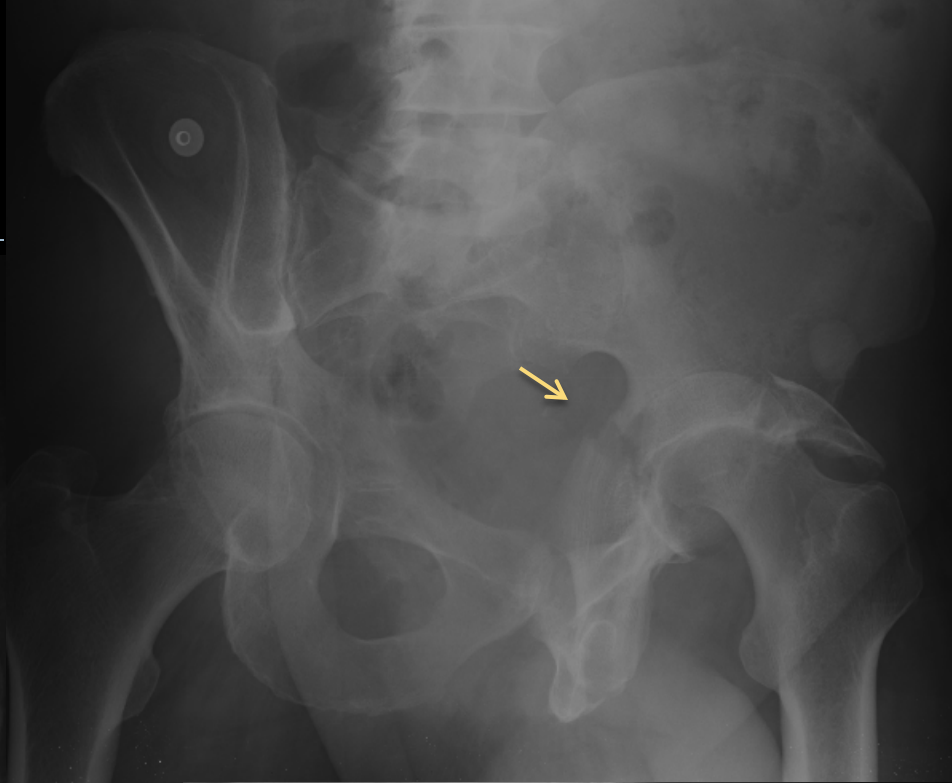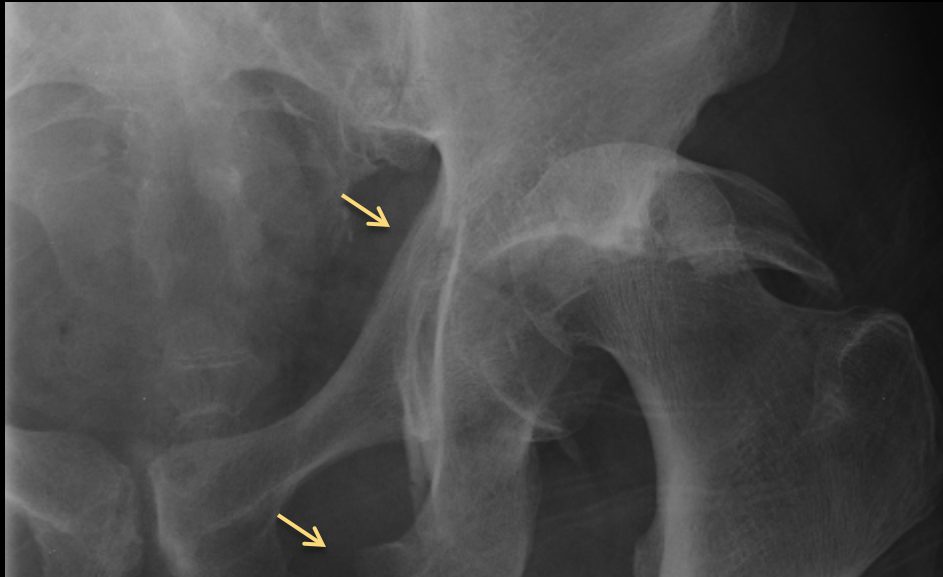
---





# TYPE IV

---

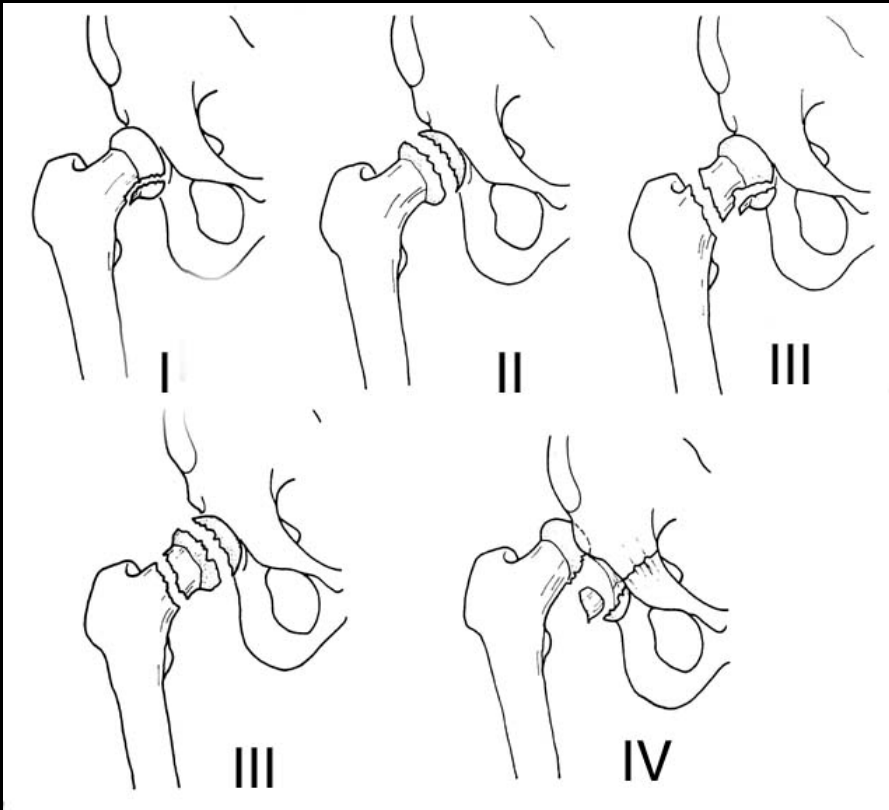




# (Type V) Femoral Head Fractures

---

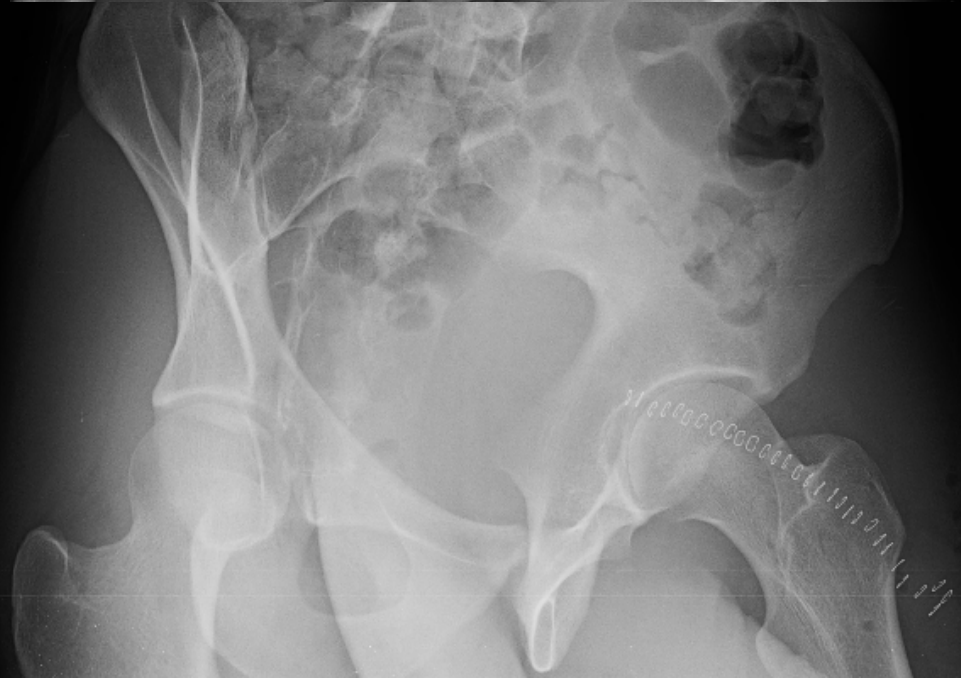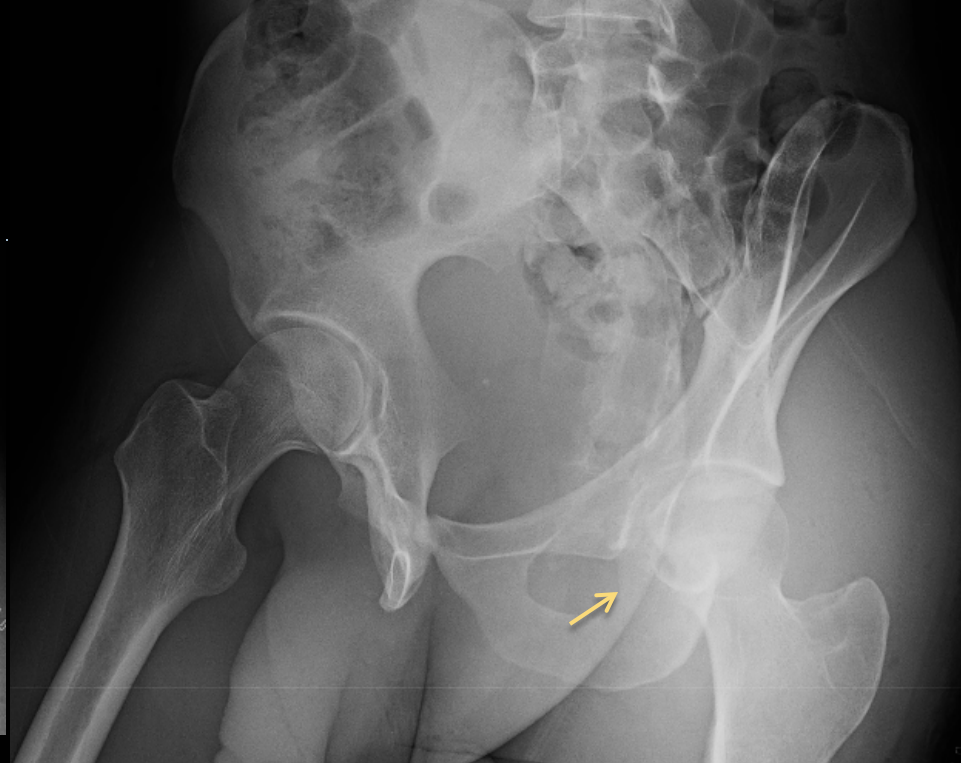
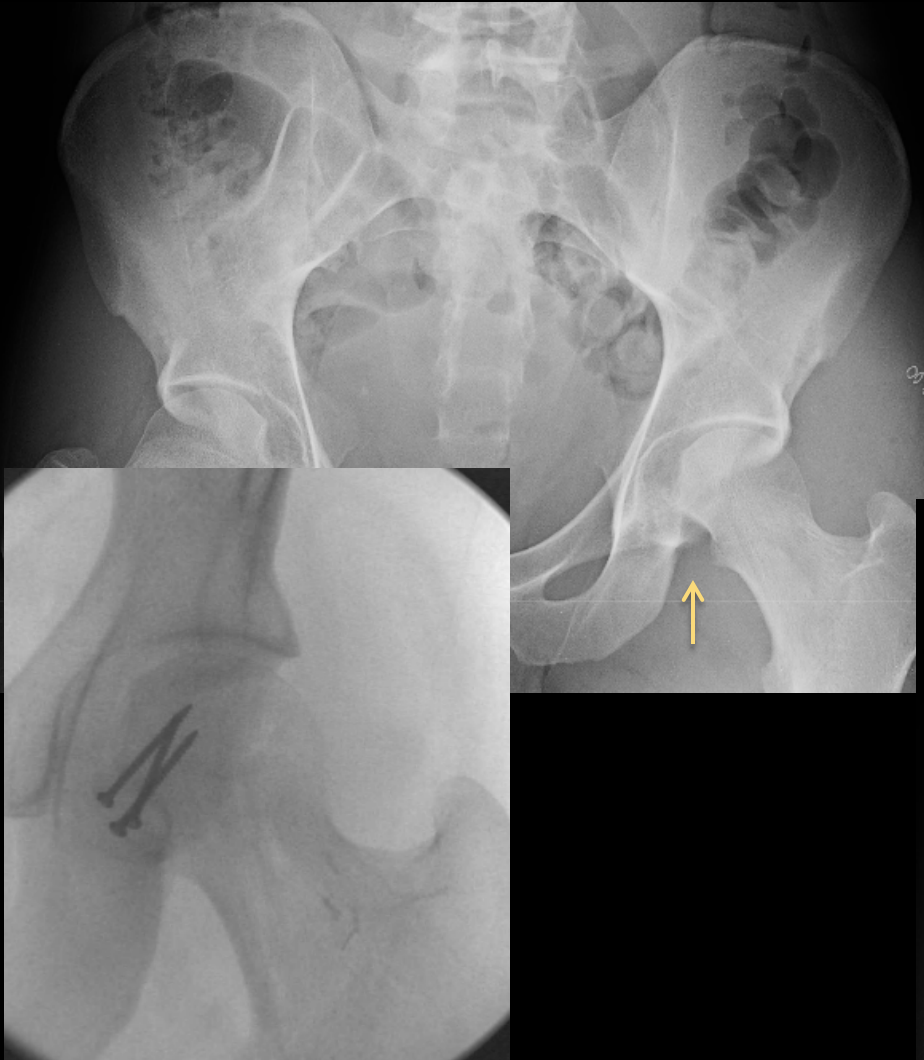- ▶ Occur by shear as femoral head dislocates
- ▶ Pipkin Classification, JBJS 1957



- ▶ I inferior to fovea
- ▶ II superior to fovea
- ▶ III fracture of femoral head and neck
- ▶ IV fracture of femoral head with acetabular fracture

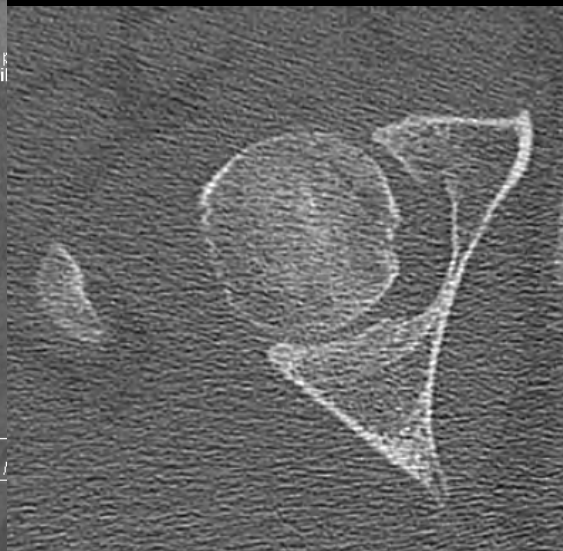
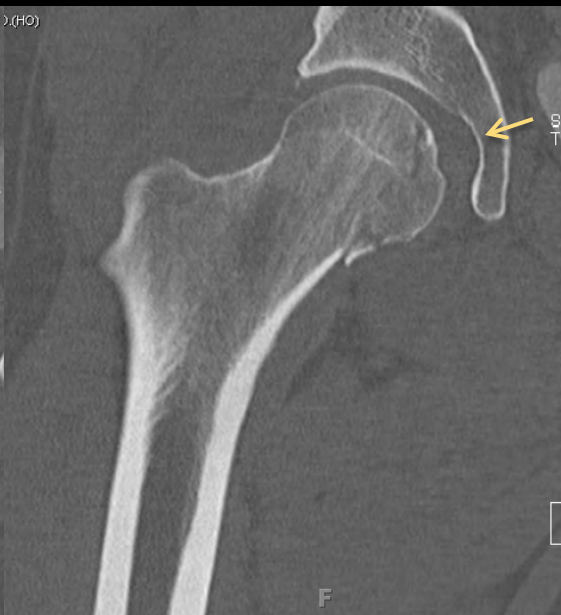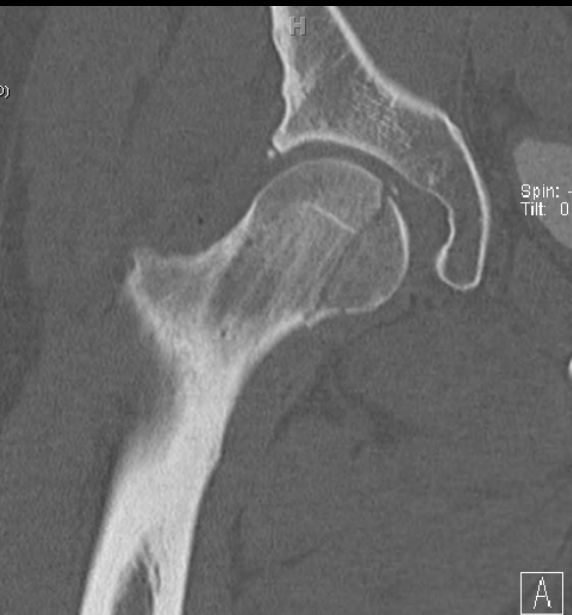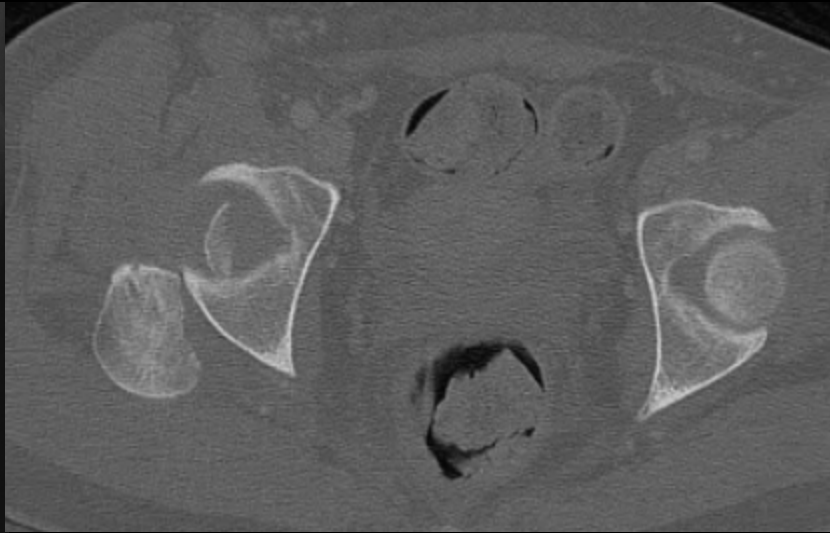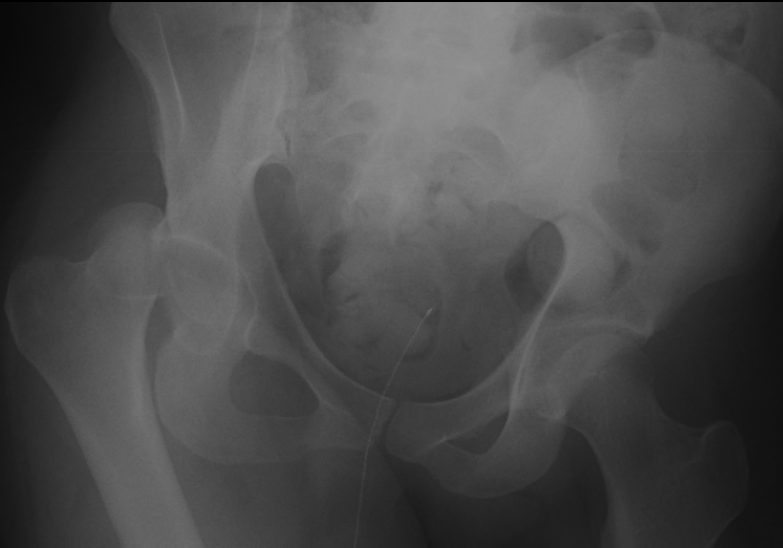


# Pipkin I



# Pipkin II

---



# Treatment

---

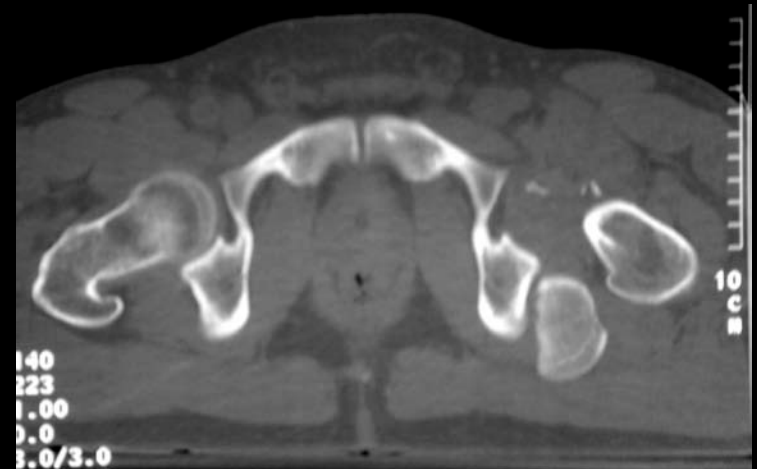
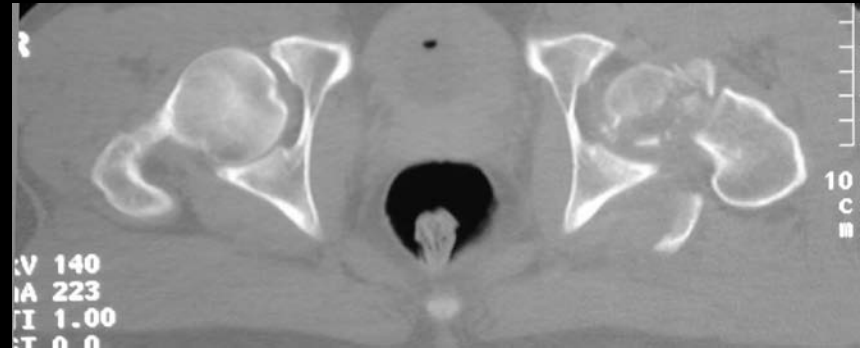
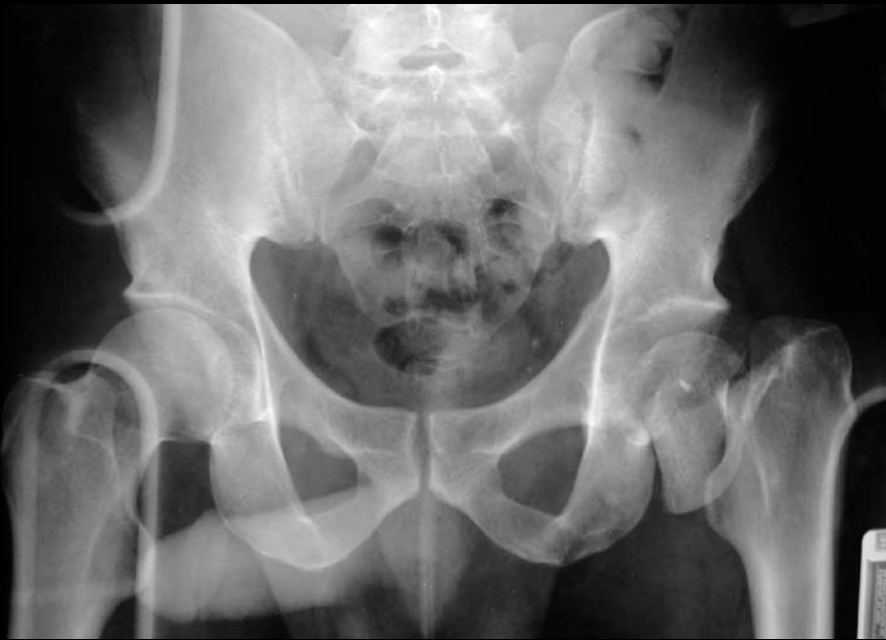- ▶ Pipkin I
- ▶ Nonsurgical IF:
  - ▶ Anatomic or near anatomic (< 2mm) reduction of fragment
  - ▶ Hip is stable
  - ▶ Hip joint is congruent without intra-articular fragments
- ▶ Pipkin II
- ▶ Most are managed surgically as fracture usually extends into weight bearing portion of femoral head

ORIF vs. excision (if nonweightbearing fragment)

---



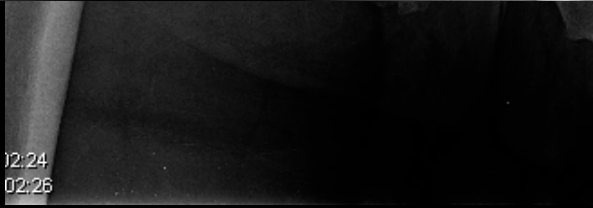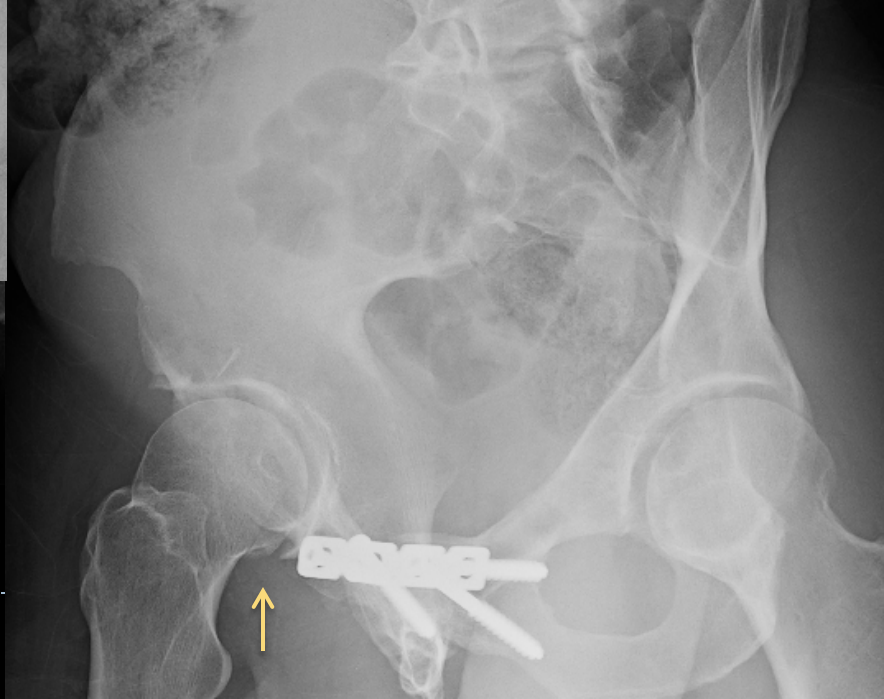
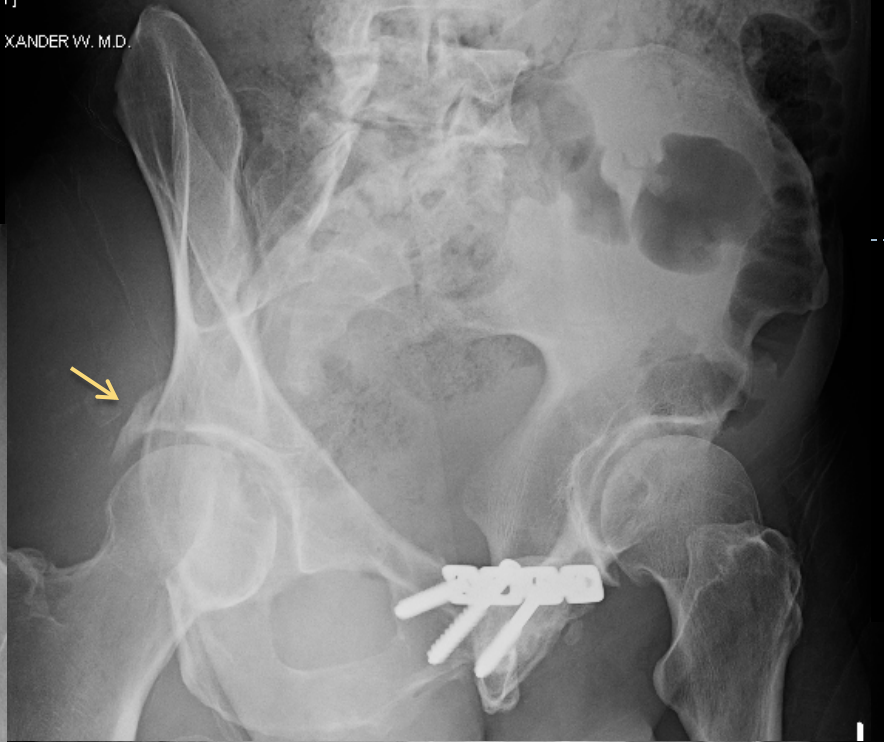
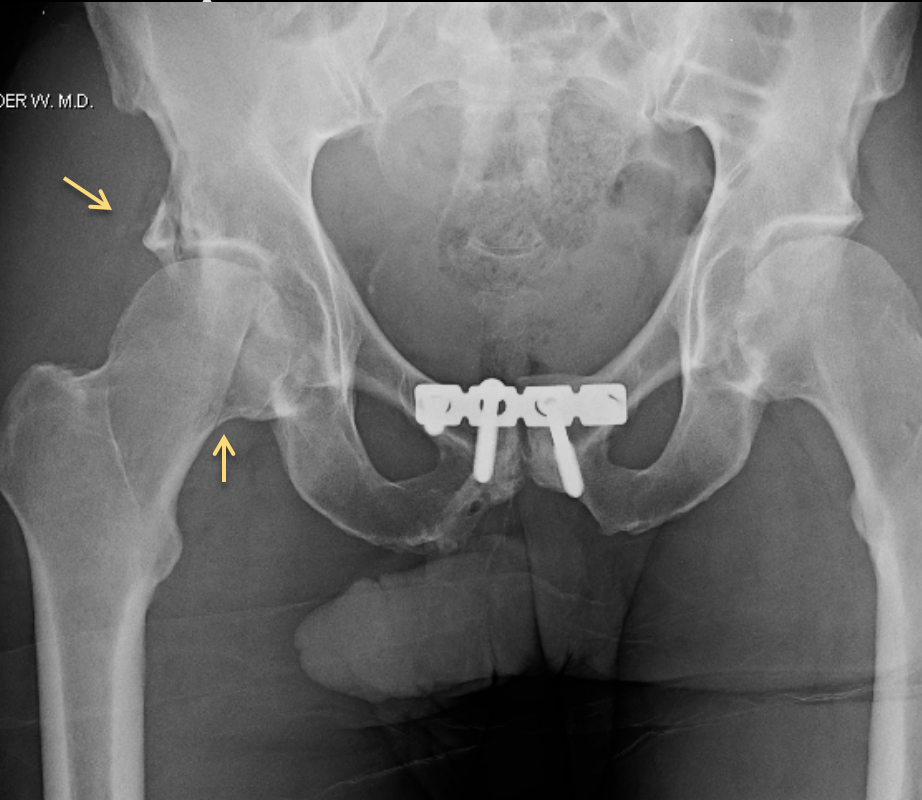
# Pipkin III – displaced vs. nondisplaced femoral neck fractures



- High incidence of osteonecrosis with displaced fractures.
- Relative indication for hemiarthroplasty in older patient.
- ORIF in young: open reduction of hip, then reduction and stabilization of femoral neck and head.
- Nondisplaced femoral neck fracture: Must consider stabilizing femoral neck fracture before performing reduction of hip.



# Pipkin IV



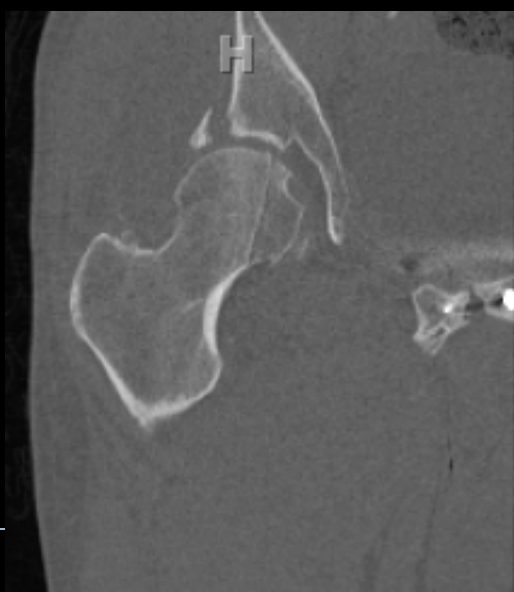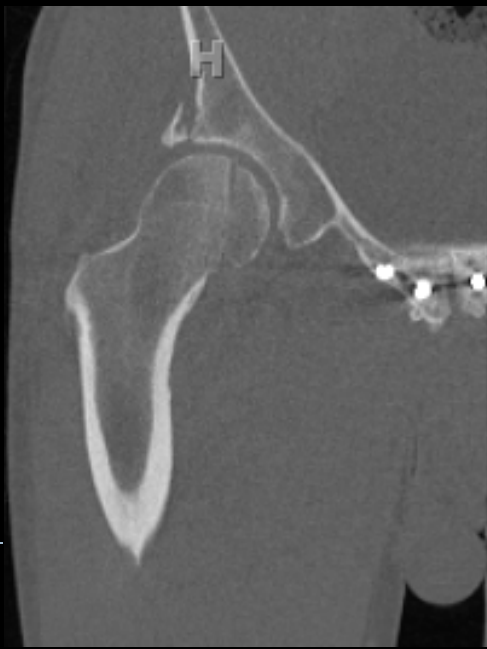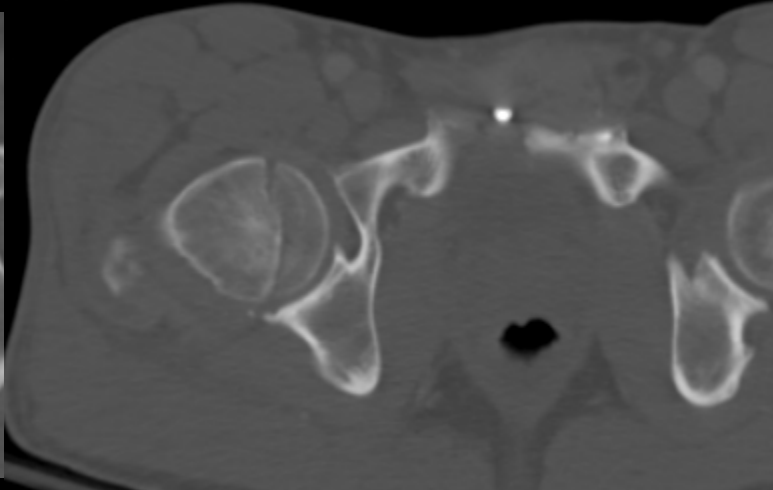
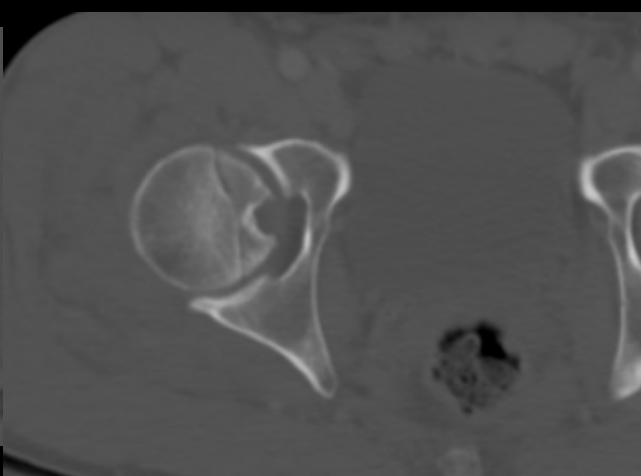
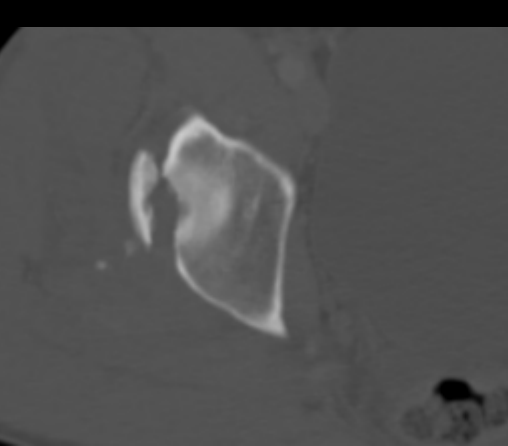
➤ Type of acetabular fracture determines





# Pipkin IV

---



# Summary

---

- ▶ Acetabular fractures -> CT with 3-D reconstructions very helpful for classification
  - ▶ Whats the principal fracture orientation?
  - ▶ Letournel column fractures – Coronal orientation on CT
    - Iliac wing involvement – anterior column
  - ▶ Transverse fractures – Sagittal orientation on CT
  - ▶ Obturator ring involvement – Column and T shaped fractures
  
- ▶ Hip dislocations
  - ▶ What direction?
  - ▶ Associated fractures?
  - ▶ Always look for femoral neck fractures



# References

---

- ▶ <http://emedicine.medscape.com/article/385838-overview>
- ▶ [www.ota.org/res\\_slide/101\\_hip\\_disloc\\_fem\\_hd\\_fxs.ppt](http://www.ota.org/res_slide/101_hip_disloc_fem_hd_fxs.ppt)
- ▶ Durkee, N, Jacobson, J, Jamadar, D, et al. Classification of Common Acetabular Fractures: Radiographic and CT Appearances. *AJR* 2006; 187:915–925
- ▶ Geijer, M, El-Khoury, G. Imaging of the acetabulum in the era of multidetector computed tomography. *Emerg Radiol* (2007) 14:271–287
- ▶ Harris, J, Lee, J, Coupe, K, et al. Acetabular Fractures Revisited: Part I, Redefinition of the Letournel Anterior Column. *AJR* 2004; 182:1363–1366
- ▶ Harris, J, Lee, J, Coupe, K, et al. Acetabular Fractures Revisited: Part 2, A New CT-Based Classification *AJR* 2004; 182:1367–1375
- ▶ Foulk, D, Mullis, B. Hip Dislocation: Evaluation and Management. *J Am Acad Orthop Surg* 2010; 18:199-209
- ▶ Droll, K, Borekhuyse, H, O'Brien, P. Fracture of the femoral head. *J Am Acad Orthop Surg* 2007; 15:716-727
- ▶ Croft SJ, Brenchley J, Bradhe, SP, et al. An unusual rugby injury. *Emerg Med J*. 2006 June; 23(6): e40
- ▶ Brogdon, BG, Woolridge, DA. Luxatio erecta of the hip: a critical retrospective. *Skeletal Radiol* (1997) 26:548–552

