


Femoroacetabular Impingement

FAI

Dr. Tudor H Hughes, M.D., FRCR
Department of Radiology
University of California School of Medicine
San Diego, California



Femoroacetabular impingement

- Previously known as
 - Acetabular rim syndrome
 - Cervicoacetabular impingement

Femoroacetabular impingement

A conflict between the proximal femur and the acetabular rim

A cause of premature osteoarthritis of the hip

Prevalence 10-15%

Leunig and Ganz 2005

Femoroacetabular impingement

Early surgical correction can prevent OA

Surgical Rx only good prior to extensive cartilage loss

Imaging to confirm diagnosis of FAI and preoperative planning

Femoroacetabular impingement Symptoms

- FAI becomes symptomatic in the 2nd or 4th decade
- Reduced range of movement precedes pain with flexion, internal rotation (and adduction)
- Pain with sitting or after sport

Femoroacetabular impingement

- Cam and Pincer types

Cam

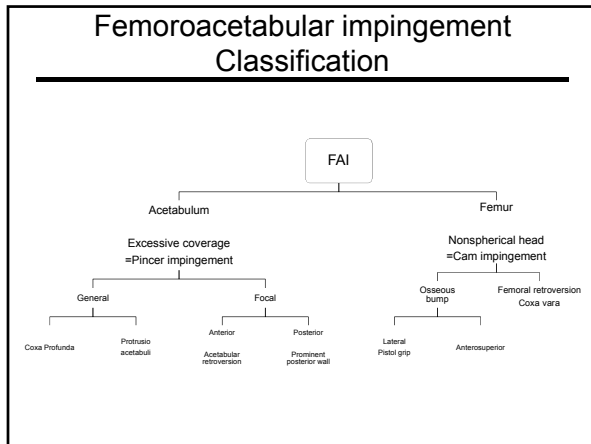
Predominance of femoral abnormalities

Pincer

Predominance of acetabular abnormalities

86% have mixed pincer and cam impingement

JBJS Br 2005;87:1012-1018

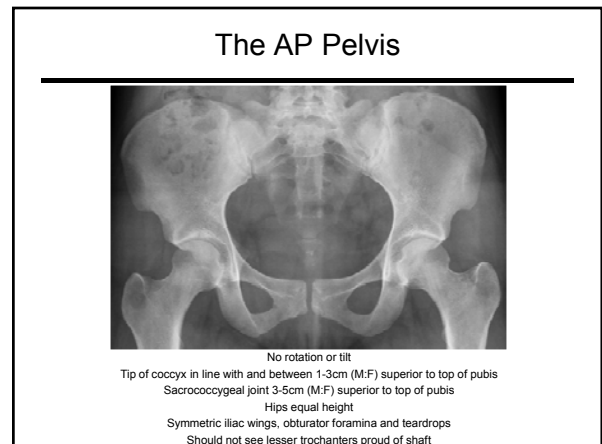


- ### Femoroacetabular impingement
-
- Acetabulum
 - Depth - Overcoverage
 - Roof inclination
 - Version
 - Femur
 - Head sphericity
 - Head-neck junction offset
 - Reduced depth of the femoral waist
 - Both
 - Congruency

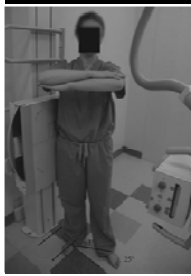- ### Epidemiology of FAI
-
- CAM type: M:F 14:1 (avg age: 32).
 - Pincer type: M:F 1:3 and usually middle age women (avg age: 40)

- ### Role of imaging
-
- Radiographs
 - Evaluate for FAI hip abnormalities
 - Exclude arthritis, AVN, other joint problems
 - CT
 - Arthritis
 - Acetabular version
 - Femoral version
 - MRI or MRI arthrography
 - Labral damage
 - Articular cartilage loss
 - α angle measurement

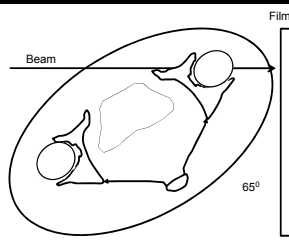
- ### Radiographic Projections
-
- AP Pelvis and hip radiographs provide information about the acetabulum, lateral femoral head neck junction and coxa vara
 - False profile shows anterior coverage of acetabulum and posteroinferior JS
 - AP, frog leg lateral, Dunn 45 and 90 and cross table lateral show femoral pathology
 - Cross table lateral (axial) also shows femoral waist deficiency



False (Faux) profile view

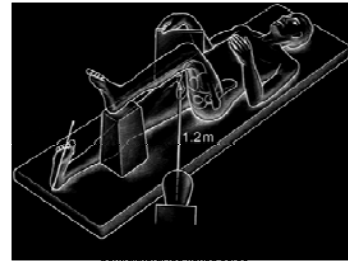


Standing
65° Affected side posterior oblique
Affected foot parallel to cassette
Center on femoral head



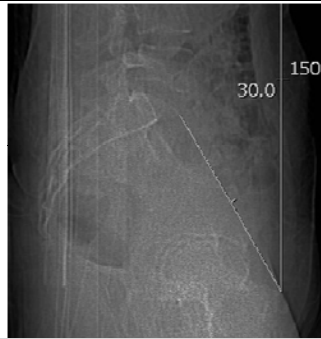Good radiograph is when the distance between the heads is approximately one femoral head.

Cross table lateral



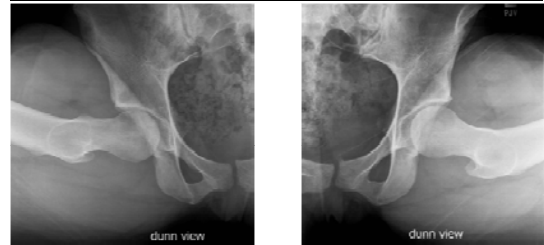Ipsilateral leg internally rotated 15°
45° cranial angulation
Center on femoral head
Visualization of lesser trochanter indicates good internal rotation
Aluminium wedge filter helps even out density range
Good for femoral waist deficiency

Lateral CT Scanogram Alternative for Strong lateral for pelvic tilt



Normal pelvic tilt from Sacral promontory to anterosuperior pubis is 30° to vertical

The 90° Dunn view



Hips flexed 90°

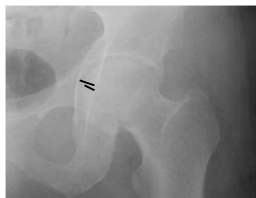Hips abducted 20°

Neutral rotation

Center midway ASIS and pubis

Pincer type Femoroacetabular Impingement

- Coxa profunda :
 - Medial wall of the acetabulum projects medial to the ilioischial line
- Protrusio acetabuli
 - Defined by measuring the distance of the medial acetabular wall and the ilioischial line
 - Males: > 1-3mm
 - Females: > 3-6mm




Familial Acetabular Protrusion

- aka *Primary Protrusio Acetabuli*
-
- aka *Otto Pelvis*
-
- aka *Arthrokatachysis*

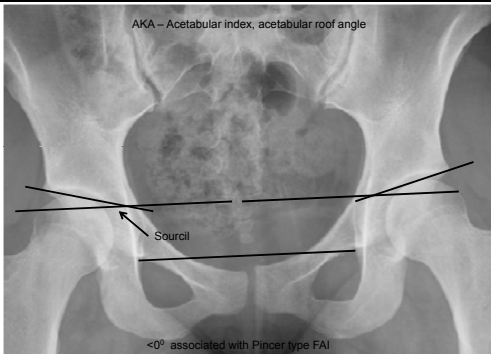
Familial Acetabular Protrusion The Otto Pelvis

- Idiopathic
- Young women
- Pain and limitation at an early age
- Deformity can progress until the greater trochanter impinges on the side of the pelvis
- Frequently associated with varus deformity of the femoral neck
- Development of osteoarthritis



Acetabular Roof Inclination The Tonnis angle - Normally 0° - 10°

AKA – Acetabular index, acetabular roof angle

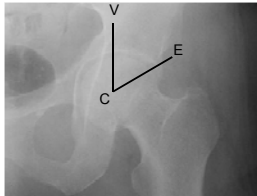


<0° associated with Pincer type FAI


18F

Pincer type Femoroacetabular Impingement

- The VCE angle (Wiberg's angle) is the angle formed by the vertical line drawn through centre of the femoral head and the line CE, E being the acetabular roof lateral brim. It measures the lateral covering of the femoral head by the acetabular roof;
 - insufficient (congenital dysplasia) when <20°
 - excessive (coxa profunda) when >40°

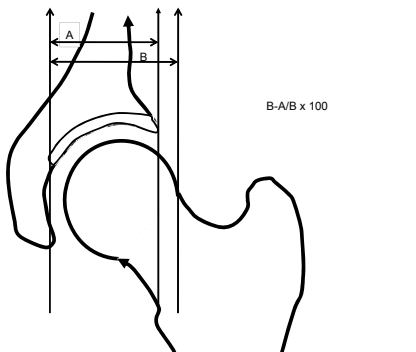


Acetabular coverage Vertical Center Anterior edge angle of Lequesne



<20° can indicate structural instability

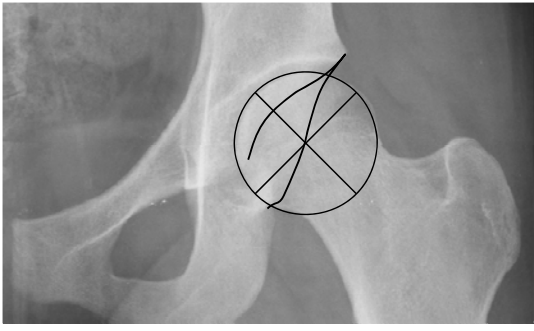
Femoral head coverage percentage



B-A/B x 100

Delaunay Skeletal Radiology 1996; 26:75-81

Acetabular Version Normal



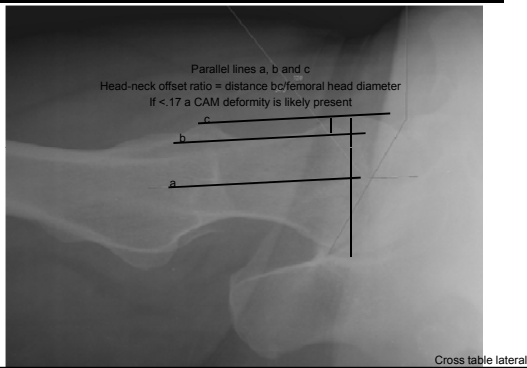
Posterior wall sign

- Normal posterior wall runs through center of femoral head
- Prominent posterior wall associated with protrusio or profunda, but can be an isolated entity
- Deficient posterior wall often correlates with acetabular retroversion or dysplasia

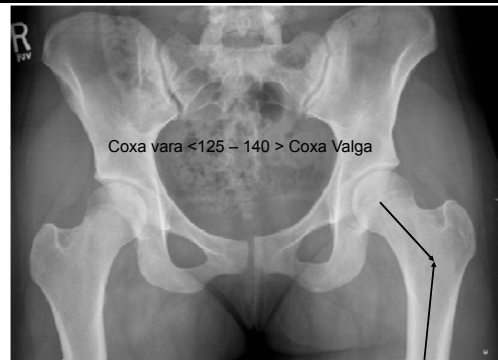Femoral head / neck shape

- A non spherical femoral head causes outside-in abrasion of the acetabular articular cartilage and damage to the adjacent labrum

The Head neck offset ratio



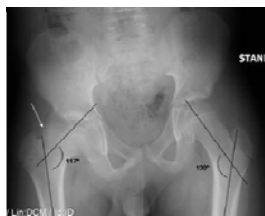Neck shaft angle Centro-diaphyso-diaphysaire (CDD) angle Caput collum diaphysis (CCD) angle



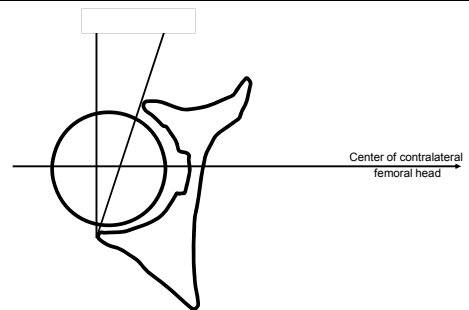
Coxa vara

- Coxa vara - Cam type FAI
 - Abnormally located femoral neck
 - Decreased caput collum diaphysis (CCD) angle
 - Normal is 125 to 135
 - <115 highly associated with CAM FAI

The varus position gives rise to an abnormally located femoral neck that is situated more superiorly than normal.



Acetabular version by CT



Osteoarthritis 4 times more common in retroverted acetabulum

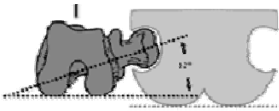
Anda: Skeletal Radiology 1991;20:267-271

Femoral retrotorsion

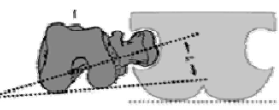
- Femoral retrotorsion – Cam type FAI
- Congenital or post traumatic
- Calculated by CT

TORSION : head and neck of the femur are measured relative to the condyles of the femur.
VERSION: head and neck are measured relative to the frontal plane of the body.

•Normal torsion





•Retrotorsion



Femoroacetabular Impingement

Normal femoral head-neck junction and acetabulum allows clearance of femoral head during flexion

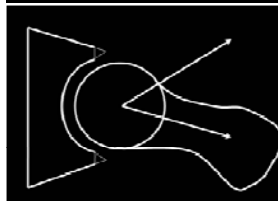
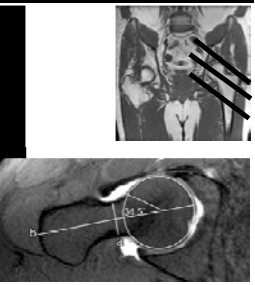
Two Mechanisms of Hip Impingement: Each causing a different pattern of articular damage.

- **CAM Impingement**
"Caused by a non-spherical head"
- Cartilage sheared off by the non-spherical femoral head.
- Cartilage damage to the Anterosuperior acetabular cartilage with separation between the labrum and cartilage

- **Pincer Impingement**
"Caused by an excessive acetabular cover"
- Labrum crushed between the acetabular rim and the femoral neck
- Cartilage damage was located circumferentially and included only a narrow strip

Beck, Kalhor, Leunig, Ganz Hip morphology influences the pattern of damage to the acetabular cartilage: femoroacetabular impingement as a cause of early osteoarthritis of the hip. J Bone Joint Surg Br. 2005 Jul;87(7):1012-8.
Kassarjian. Triad of MR Arthrographic Findings in Patients with CAM Type Femoral Acetabular Impingement. Radiology 2005; 236 588-592

Alpha Angle

Using an axial oblique plane, alpha angle measured.
Normal is 42 degrees with upper limits of 55 degrees.

Cam-type Femoroacetabular Impingement

- Offset of femoral head / neck junction
- Etiologies:
 - SCFE
 - Legg Calve Perthes disease
 - Posttraumatic retroversion of femoral head
 - Pistol grip deformity
 - Coxa vara
 - Femoral retroversion
 - Growth abnormality of femoral epiphysis

"SCFE, FAI connection validated"

- Swiss researchers, retrospective review of 840 patients with FAI, 55 patients who had pinning in situ for mild SCFE
- Of the 55 hips, 23 had advanced changes of OA requiring total hip arthroplasty
 - The mean age of patients at in situ pinning was 12.6 years (range: 11 to 14 years);
 - The mean duration between pinning and open surgical dislocation for FAI was 11.6 years (range: 2 to 30 years).
 - At the time of surgery, patients had a mean age of 24.3 years (range: 16 to 43 years old).
- The investigators found 20 hips with cam-type impingements and 13 with mixed-type impingement.

(AAOS) July 2009 Issue: <http://www.aaos.org/news/aaosnow/jul09/clinical12.asp>

AAOS 2010 Annual meeting

- “FAI and Long Term Outcome of In-situ Fixation for Slipped Capital Femoral Epiphysis (SCFE)”
- “At 20 year follow-up, 92 patients who had an in situ pinning for a SCFE demonstrated radiographic findings of FAI in 45%, clinical FAI in 32% and poor Harris Hip scores in 30%. “

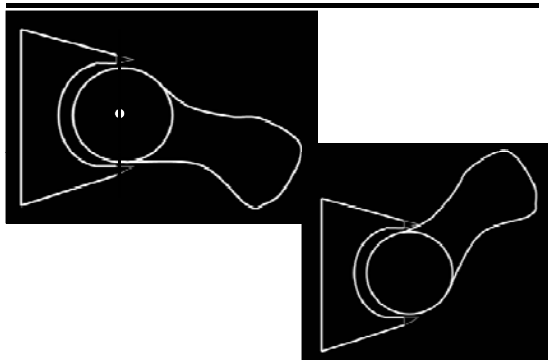
Daniel Sucato, MD <http://www3.aaos.org/education/anmeet/anmt2010/podium/podium.cfm?Event=392>

SCFE - What data suggest

- Earlier realignment because at some point, it becomes too late to realign them, and the next step is arthroplasty.
- MR arthrograms earlier rather than later to identify FAI sooner to be more aggressive in aligning the femoral heads better.
- Continue to pursue the concept of immediate reduction of moderate and severe SCFE using the surgical hip dislocation approach and make this a safe procedure to restore normal alignment.

(Dr. Sucato's thoughts)

Pincer type Femoroacetabular Impingement



Pincer type Femoroacetabular Impingement

- Older female patient population
- Abnormal acetabular morphology
- Etiologies:
 - Bladder extrophy
 - Acetabular retroversion
 - Coxa profunda
 - Protrusio
 - Trauma
 - Labral ossification

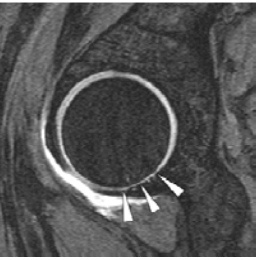
MRI: Pincer type FAI

- Anterosuperior acetabular labral tearing
- Articular surface defects (typically smaller than those seen in cam impingement)
- Evidence of osseous impaction along the anterosuperior or superior femoral neck
- Spherical femoral head
- Normal alpha angle

MRI: Pincer type FAI

- Persistent abutment in the anterior hip can lead to a slight subluxation posteroinferiorly increasing pressure between the posteroinferior acetabulum and the posteromedial aspect of the femoral head.
- Causes “contrecoup” cartilage lesions more severe posterior and posteroinferior acetabulum.
- Can lead to anterior superior labral tears and subchondral cyst.

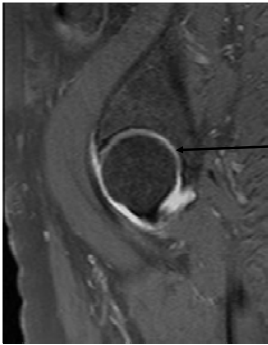
Pincer contrecoup cartilage loss



Chondral loss in posteroinferior acetabulum seen in pincer impingement.

This is a poor prognosis

Pincer type Femoroacetabular Impingement



Lack of Visualization of Cartilage at the posterolateral acetabulum

1 54 year old female presented with left hip pain

Secondary signs of FAI

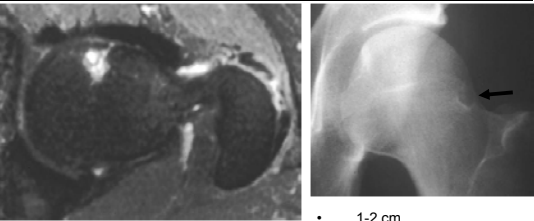
- Herniation pits
- Ossification of labrum
- Appositional bone signs
- Os acetabuli
- Posterior inferior joint space loss (on faux profile) in Pincer
- Late – classic signs of OA

Secondary signs

Synovial herniation pits

- AKA - Pitts pits
- Fibrocystic change of anterosuperior femoral neck

Synovial herniation pits



- 1-2 cm
- Round or oval lytic lesion
- Anterior femoral neck

Synovial herniation pit

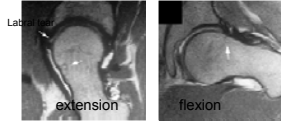
Fibrocystic Changes at Anterosuperior Femoral Neck: Prevalence in Hips with Femoroacetabular Impingement

- Hypothesis:
 - Changes at the anterior femoral neck junction are not incidental but rather they are caused by repetitive mechanical contact between the femoral head/neck and the acetabular rim
- 117 hips with femoroacetabular impingement (FAI)
 - 33% fibrocystic changes
- 132 hips with developmental dysplasia (control)
 - 0% fibrocystic changes
- MR arthrogram and AP pelvis on 61 pts with FAI
 - AP pelvis radiographs
 - 64% sensitive for fibrocystic changes
 - 93% specific
 - PPV 91%
 - NPV 71%

Leunig et al. Radiology 2005; 236: 237-246

Fibrocystic Changes at Anterosuperior Femoral Neck: Prevalence in Hips with Femoroacetabular Impingement

- Dynamic MR imaging with hip flexed (2 pts) and intraoperative observations (24 pts)
- Close spatial relationship between the region of fibrocystic change at the anterosuperior femoral neck and acetabular rim



Leunig et al., *Radiology* 2005; 236: 237-246

Secondary signs

Ossification of the labrum

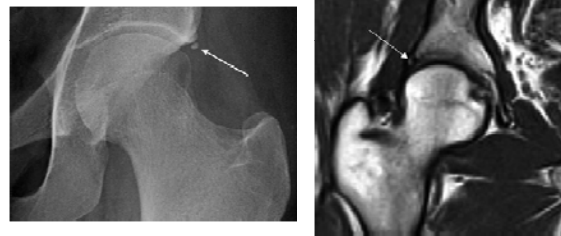- Ossification of the acetabular rim leads to further overcoverage which exacerbates the situation

Secondary signs
Os acetabuli

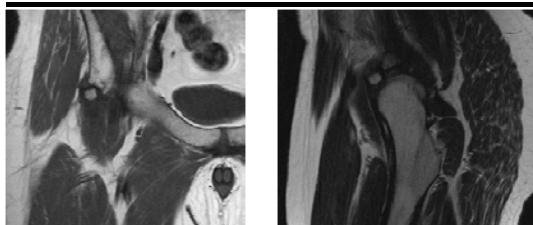
- Epiphysis of the pubis
- Develops from 8 years
- Unites with os pubis at 18 years
- Frequently observed ununited in FAI

Os acetabuli

- Associated with pincer type
- Os acetabuli

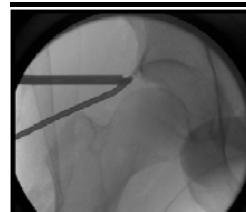


Os Acetabulum



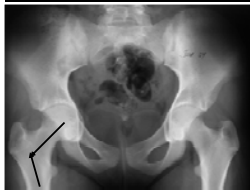- Accessory ossification center
- Superolateral location
- Corticated margins

Surgical techniques for FAI Treatment



- Arthroscopic debridement
- Remove any nonspherical portion of femoral head
- Reduce size of acetabular rim in pincer type
- Intertrochanteric flexion-valgus osteotomy femur
- Correction by arthroscopy with or without arthrotomy (but without dislocation of the femoral head)
- Surgical dislocation of the hip and for complete exposure and correction of cam impingement and/or trimming of the acetabular rim
- Periacetabular osteotomy for focal overcoverage
- Total arthroplasty in end stage disease

Surgical techniques for FAI Treatment

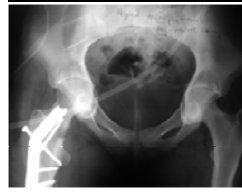

- Arthroscopic debridement
- Remove any nonspherical portion of femoral head
- Reduce size of acetabular rim in pincer type
- Intertrochanteric flexion-valgus osteotomy femur
- Correction by arthroscopy with or without arthrotomy (but without dislocation of the femoral head)
- Surgical dislocation of the hip and for complete exposure and correction of cam impingement and/or trimming of the acetabular rim
- Periacetabular osteotomy for focal overcoverage

14F Otto pelvis

•Total arthroplasty in end stage disease

Surgical techniques for FAI Treatment



- Arthroscopic debridement
- Remove any nonspherical portion of femoral head
- Reduce size of acetabular rim in pincer type
- Intertrochanteric flexion-valgus osteotomy femur
- Correction by arthroscopy with or without arthrotomy (but without dislocation of the femoral head)
- Surgical dislocation of the hip and for complete exposure and correction of cam impingement and/or trimming of the acetabular rim
- Periacetabular osteotomy for focal overcoverage

14F Otto pelvis

•Total arthroplasty in end stage disease

Surgical techniques for FAI Treatment



- Arthroscopic debridement
- Remove any nonspherical portion of femoral head
- Reduce size of acetabular rim in pincer type
- Intertrochanteric flexion-valgus osteotomy femur
- Correction by arthroscopy with or without arthrotomy (but without dislocation of the femoral head)
- Surgical dislocation of the hip and for complete exposure and correction of cam impingement and/or trimming of the acetabular rim
- Periacetabular osteotomy for focal overcoverage

•Total arthroplasty in end stage disease

FAI Summary

- Radiographic signs on AP radiographs - Pincer
 - Coxa profunda
 - Protrusio acetabuli
 - Focal acetabular retroversion (figure-8 configuration)
 - Lateral center edge angle > 39°
 - Reduced extrusion index
 - Acetabular index ≤ 0°
 - Posterior wall sign
- Radiographic signs on AP radiographs - Cam
 - Pistol-grip deformity
 - CCD angle < 125°
 - Horizontal growth plate sign
- Radiographic signs on cross-table radiographs - Cam
 - Alpha angle > 50°
 - Femoral head-neck offset < 8 mm
 - Offset ratio < 0.18
 - Femoral retrotorsion