

# Primary Bone Malignancy: Common Neoplasms, Imaging Features, & Clinical Implications

---

Suzanne Shepherd

3 March 2011

# Goals:

---

- Review criteria utilized in diagnosis of bone tumors
- Discuss role of multimodality imaging
  - ACR appropriateness criteria
  - Staging
- Discuss some of the most common malignant primary bone tumors and distinguishing features in deriving useful ddx

Primary Bone Malignancy

# IMAGING CRITERIA

---

# Characteristics in Diagnosis of Bone Tumors

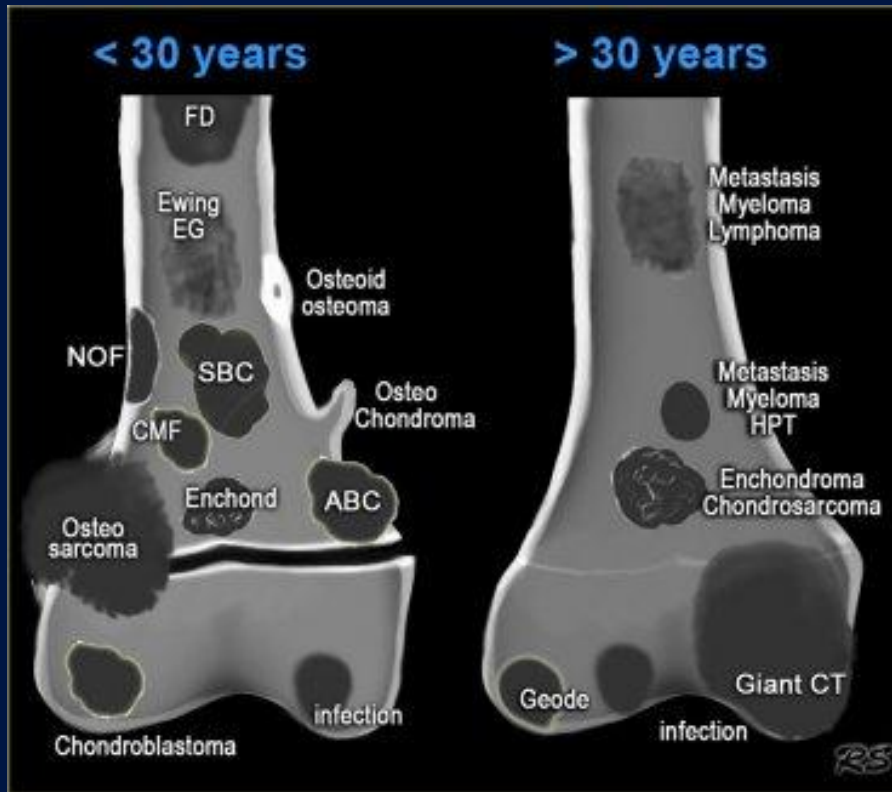- Patient age (#1 factor to consider) & gender
- Tumor location
- Lesion margin
- Matrix formation
- Periosteal reaction

# Generalizations by patient age

(adapted from Table 1, Miller TT. Rad 2008; 246:662-674)

Age (yrs)	Benign	Malignant
< 20	Fibrous cortical defect/NOF Simple bone cyst ABC Chondroblastoma LCH Osteoblastoma Osteoid osteoma Osteofibrous dysplasia Chondromyxoid fibroma FD Enchondroma	Leukemia Ewings sarcoma Osteosarcoma (conv, periost, telang) Mets (rare) NBoma RBoma Rhabdomyosarcoma Hodgkin lymphoma
20-40	Enchondroma GCT Osteoblastoma Osteoid osteoma Chondromyxoid fibroma FD	Osteosarcoma (parosteal) Adamantinoma
> 40	FD Pagets dis Non-Hodgkin Lymphoma Chondrosarcoma Malig fibrous histiocytoma O-sarc (d/t Pagets or rad'n)	Mets (most common) Myeloma

# Generalizations by patient age & location



- Location

- Flat vs. tubular bone

- Longitudinal location:

- Epiphyseal vs. metaphyseal vs. diaphyseal

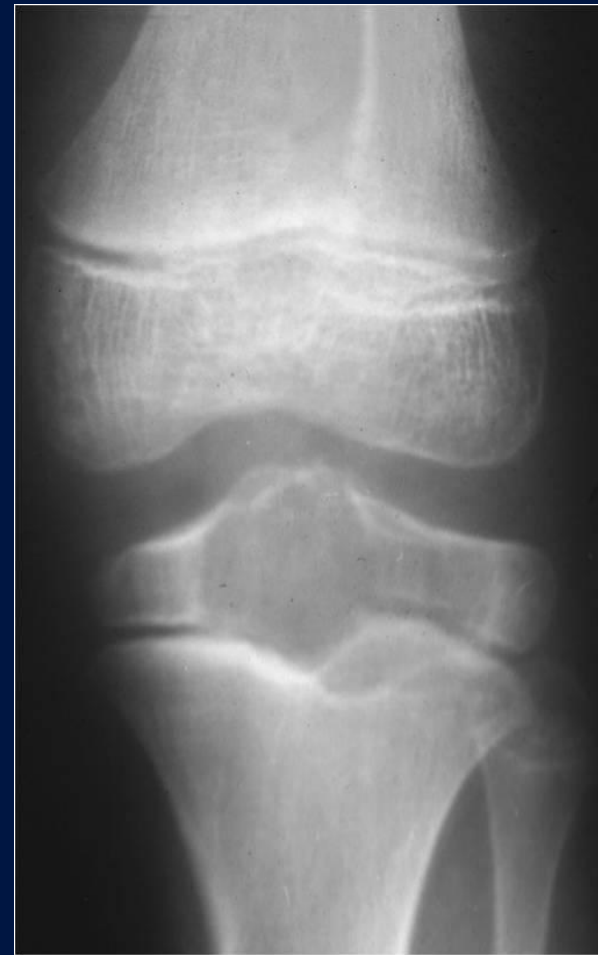- Axial location:

- Central vs. eccentric
- Cortical vs. juxtacortical vs. soft tissue

# Generalizations about Location

- Epiphyseal:
  - Subchondral cyst (sk mature, OA)
  - Chondroblastoma (sk immature)
- Metaphyseal: active area of bone formation
  - NOF
  - Osteochondroma
  - Sarcomas
- Diaphyseal:
  - Ewing sarcoma

Chondroblastoma

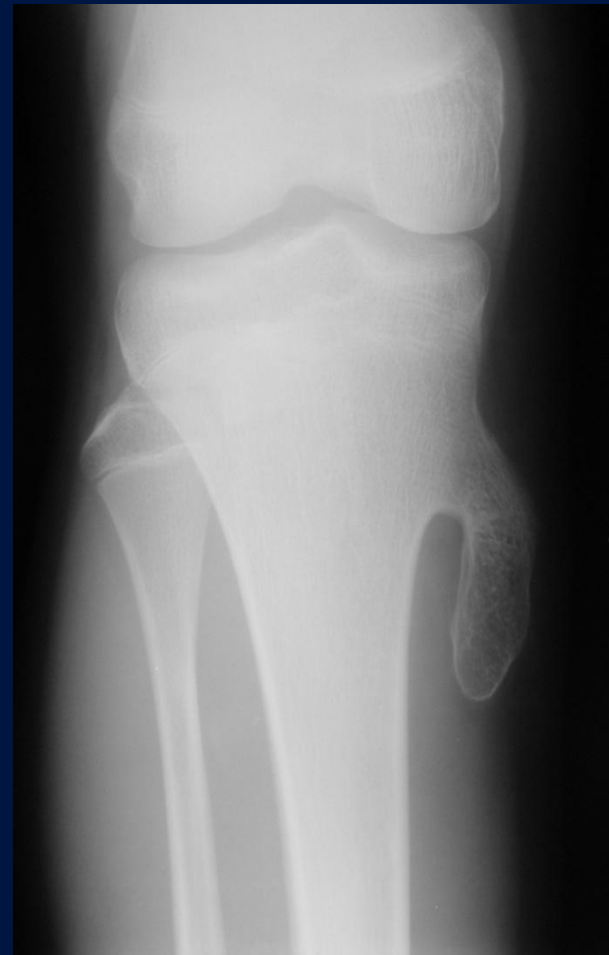

Courtesy, George Nomikos

# Generalizations about Location

- Epiphyseal:
  - Subchondral cyst (sk mature, OA)
  - Chondroblastoma (sk immature)
- Metaphyseal: active area of bone formation
  - NOF
  - Osteochondroma
  - Sarcomas
- Diaphyseal:
  - Ewing sarcoma

Osteochondroma

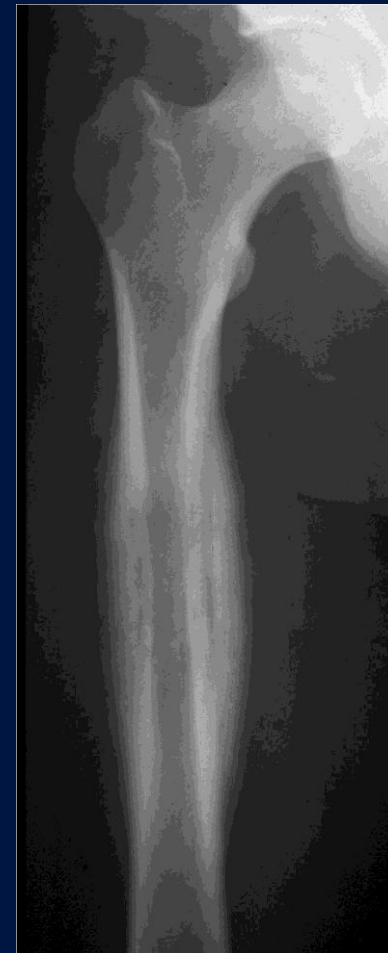




# Generalizations about Location

- Epiphyseal:
  - Subchondral cyst (sk mature, OA)
  - Chondroblastoma (sk immature)
- Metaphyseal: active area of bone formation
  - NOF
  - Osteochondroma
  - Sarcomas
- Diaphyseal:
  - Ewing sarcoma

Ewing sarcoma



Courtesy ,George Nomikos

# Pattern of Bone Destruction: Lesion Margin

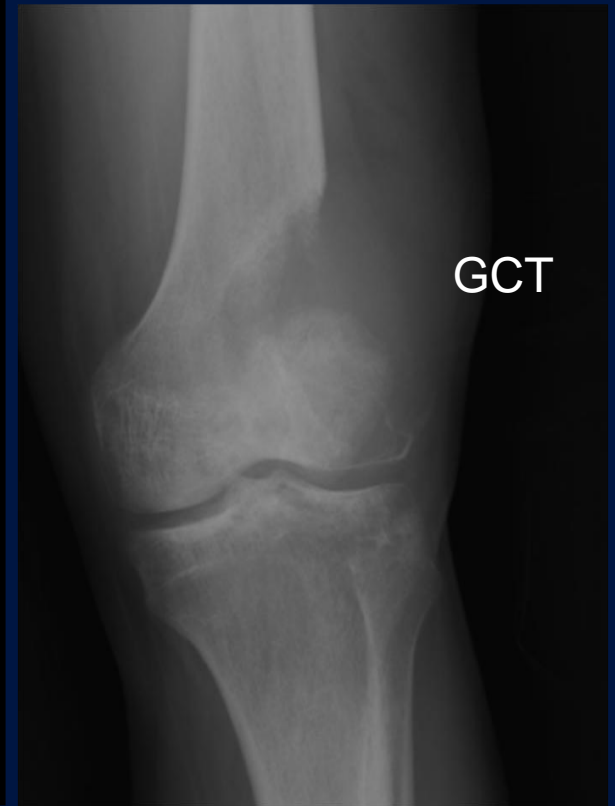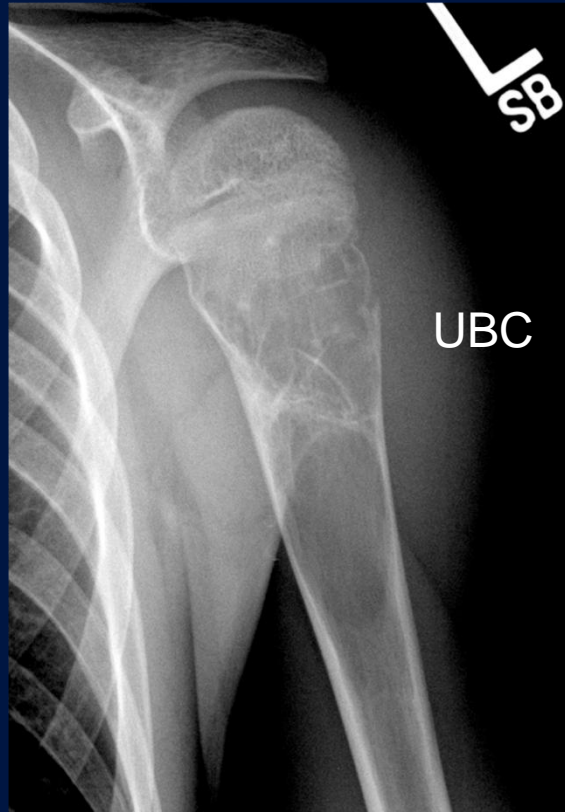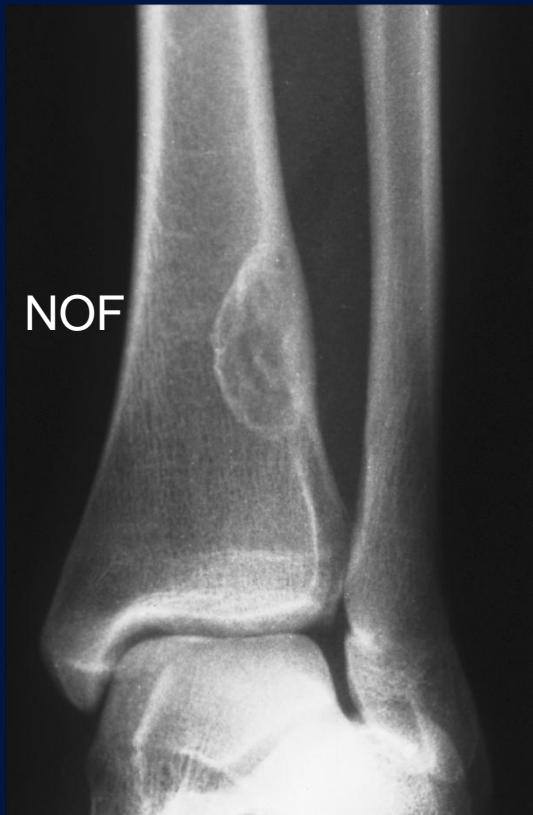- Type I: Geographic
  - A: Well-defined, with surrounding sclerosis
  - B: Well-defined, without surrounding sclerosis
  - C: Ill-defined
- Type II: Motheaten
- Type III: Permeative

# Geographic Lesions, Type I

A

B

C

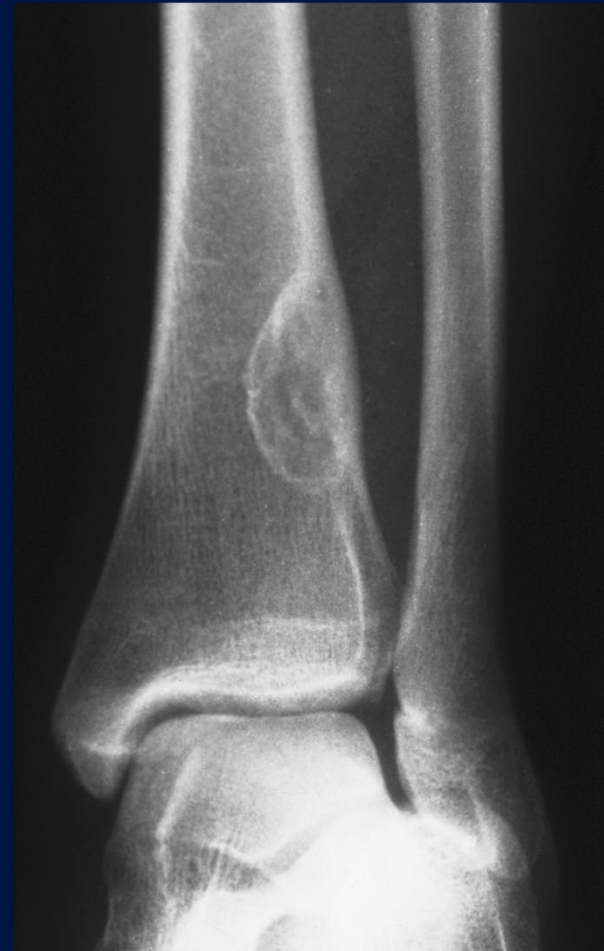

Courtesy, George Nomikos

# Margins reflect biological activity

NOF

- Nonaggressive
  - Geographic, well-defined lesion
  - Narrow zone of transition
  - Sclerotic lesion margins
- Aggressive
  - Permeative, moth-eaten
  - Wide zone of transition
  - Nonsclerotic lesion margins

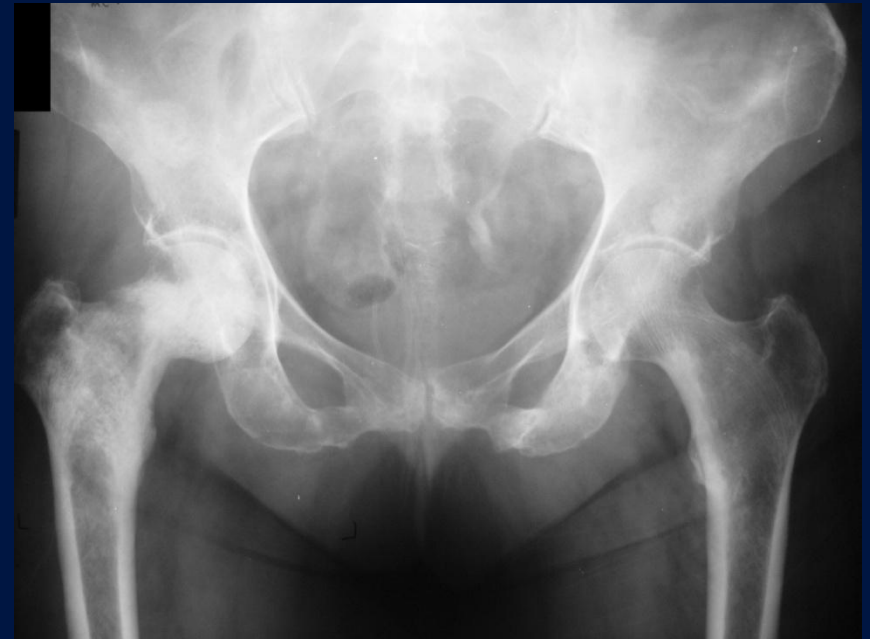

Courtesy, George Nomikos

# Margins reflect biological activity

- Nonaggressive
  - Geographic, well-defined lesion
  - Narrow zone of transition
  - Sclerotic lesion margins
- Aggressive
  - Permeative, moth-eaten
  - Wide zone of transition
  - Nonsclerotic lesion margins

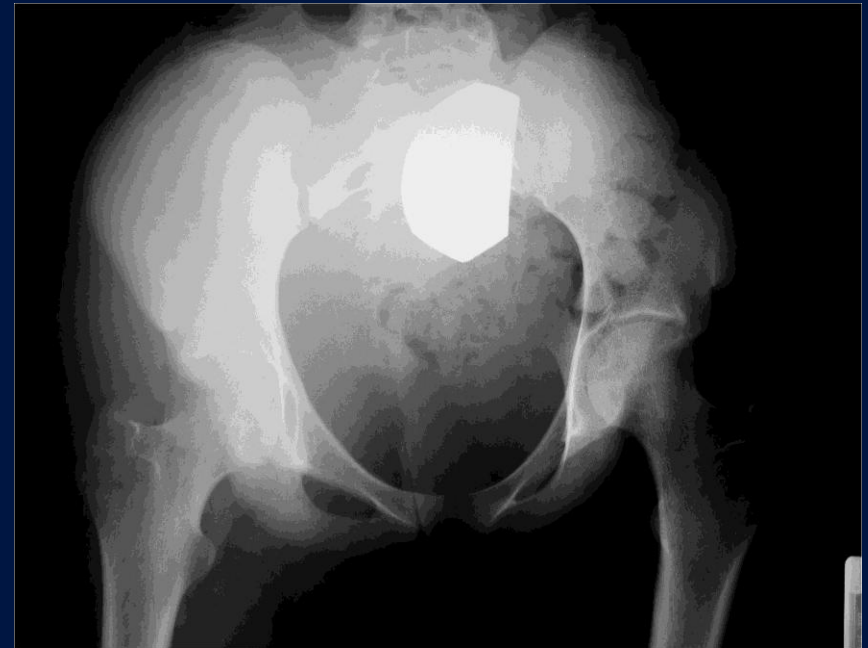Metastatic breast cancer



# Tumor Matrix

- Osteoid
  - Ivory
  - Fluffy
  - Cloud-like
- Chondroid
  - Arcs/rings
  - Punctate
  - Stippled
- Fibrous
  - Ground glass
  - Hazy

Osteosarcoma

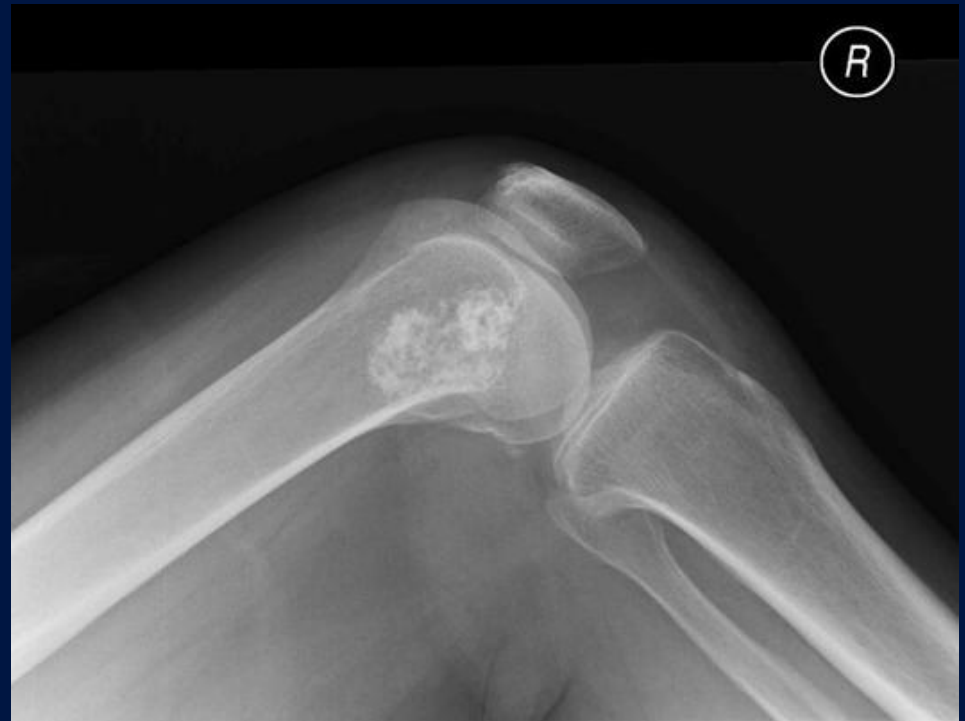

Courtesy, George Nomikos

# Tumor Matrix

- Osteoid
  - Ivory
  - Fluffy
  - Cloud-like
- Chondroid
  - Arcs/rings
  - Punctate
  - Stippled
- Fibrous
  - Ground glass
  - Hazy

Enchondroma

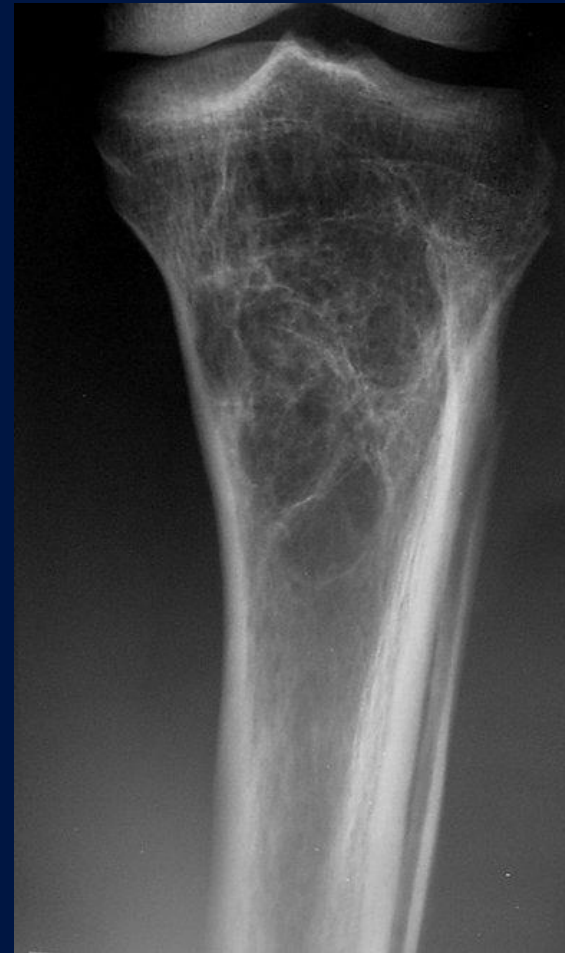

Courtesy, George Nomikos

# Tumor Matrix

- Osteoid
  - Ivory
  - Fluffy
  - Cloud-like
- Chondroid
  - Arcs/rings
  - Punctate
  - Stippled
- Fibrous
  - Ground glass
  - Hazy

Fibrous dysplasia

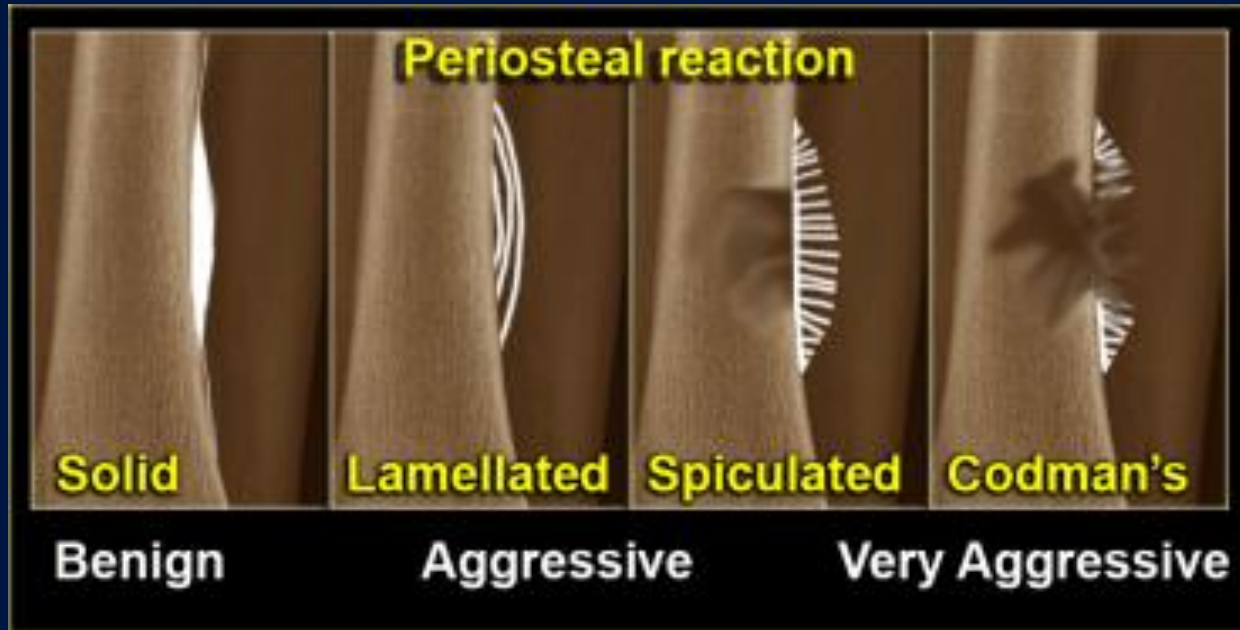


Dr. Sartoris Teaching File



# Periosteal Reaction

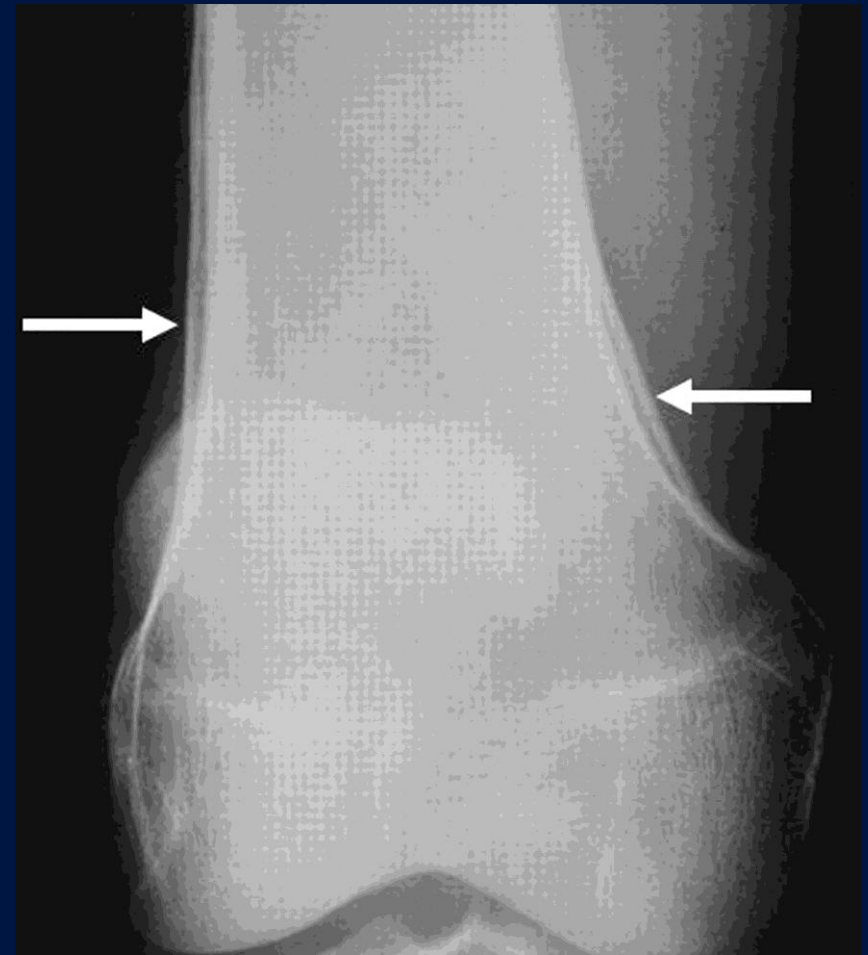([www.radiologyassistant.nl/en/494e15cbf0d8d](http://www.radiologyassistant.nl/en/494e15cbf0d8d))



# Periosteal Reaction

Unilamellated

- Non-aggressive:
  - Solid
  - Buttressing
  - Expansion
  - Septation
- Aggressive:
  - Codman triangle
  - Sun-burst
  - Hair-on-end
  - Laminated

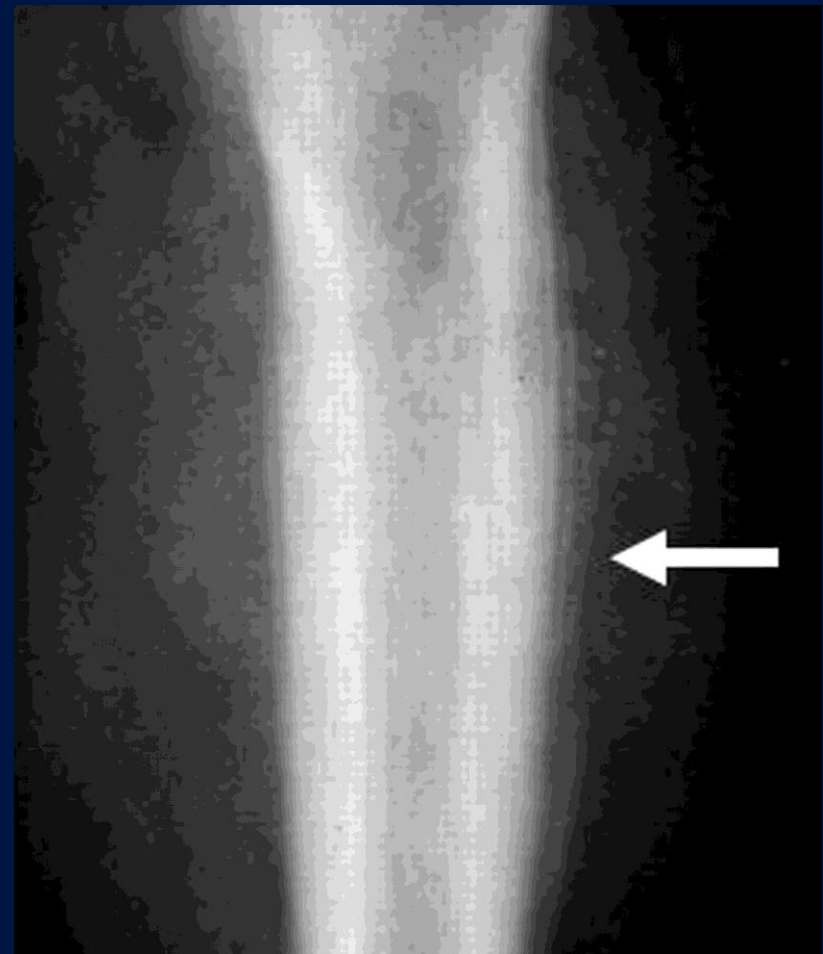

Miller T T Radiology 2008;246:662-674

# Periosteal Reaction

Multilamellated

- Non-aggressive:
  - Solid
  - Buttressing
  - Expansion
  - Septation
- Aggressive:
  - Codman triangle
  - Sun-burst
  - Hair-on-end
  - Laminated

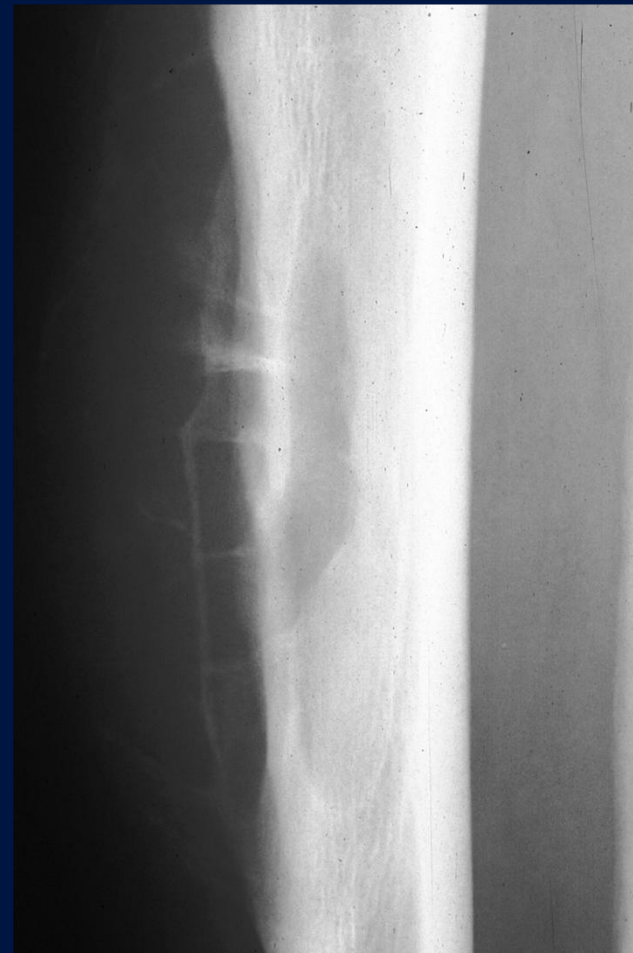

Miller T T Radiology 2008;246:662-674

# Periosteal Reaction

- Non-aggressive:
  - Solid
  - Buttressing
  - Expansion
  - Septation
- Aggressive:
  - Codman triangle
  - Sun-burst
  - Hair-on-end
  - Laminated

Periosteal OGS

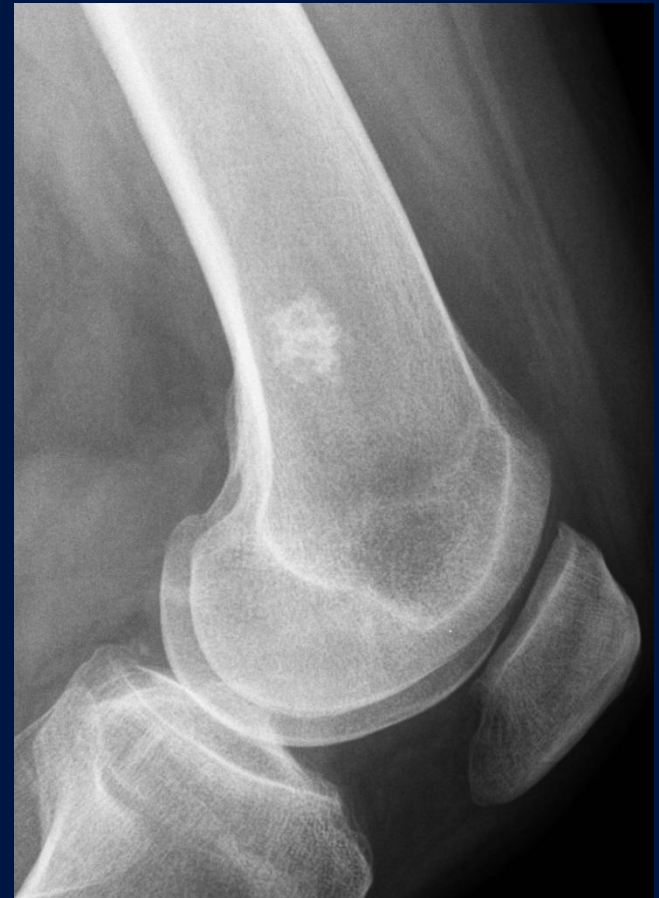

Courtesy, George Nomikos

# Lesion Number

- Monostotic
- Polyostotic
  - Benign
    - LCH
    - Enchondromatosis
    - FD
  - Malignant
    - Mets/Myeloma

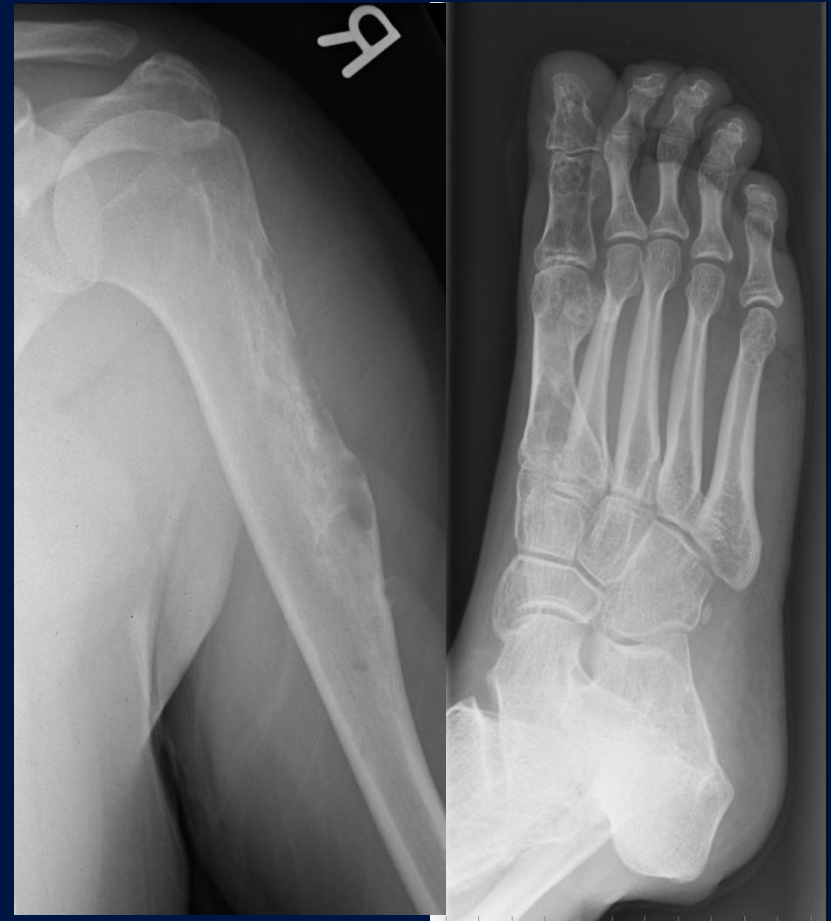Solitary enchondroma



# Lesion Number

- Monostotic
- Polyostotic
  - Benign
    - LCH
    - Enchondromatosis
    - FD
  - Malignant
    - Mets/Myeloma

Multiple enchondromas



Primary Bone Malignancy

# **ROLE OF MULTIMODALITY IMAGING**

---

# ACR Appropriateness Criteria for Evaluation of Bone Tumors

- **Radiographs** for initial evaluation of bone lesion
- Additional imaging dept on 1 of 4 conditions:
  - 1. nl XR, but pt has persistent sxs
    - Lytic lesions not seen on XR till 30-50% loss of mineralization
    - If pt can localize sxs, go to MR; if not, go to scintigraphy
  - 2. abnl XR, clinician suspects mets or MM on basis of hx, lab values or both
    - Next step, bone scan
  - 3. abnl XR, non-aggressive-appearing tumor
  - 4. abnl XR, aggressive-appearing primary bone tumor



# ACR Appropriateness Criteria for Evaluation of Bone Tumors

- Radiographs for initial evaluation of bone lesion
- Additional imaging dept on 1 of 4 conditions:
  - 1. nl XR, but pt has persistent sxs
    - Lytic lesions not seen on XR till 30-50% loss of mineralization
    - If pt can localize sxs, go to **MR** (r/o occult frx, infection, etc)
    - If not, go to **scintigraphy**
  - 2. abnl XR, clinician suspects mets or MM on basis of hx, lab values or both
  - 3. abnl XR, non-aggressive-appearing tumor
  - 4. abnl XR, aggressive-appearing primary bone tumor

# ACR Appropriateness Criteria for Evaluation of Bone Tumors

- Radiographs for initial evaluation of bone lesion
- Additional imaging dept on 1 of 4 conditions:
  - 1. nl XR, but pt has persistent sx
  - 2. abnl XR, clinician suspects mets or MM on basis of hx, lab values or both
    - Next step, **bone scan**
  - 3. abnl XR, non-aggressive-appearing tumor
  - 4. abnl XR, aggressive-appearing primary bone tumor

# ACR Appropriateness Criteria for Evaluation of Bone Tumors

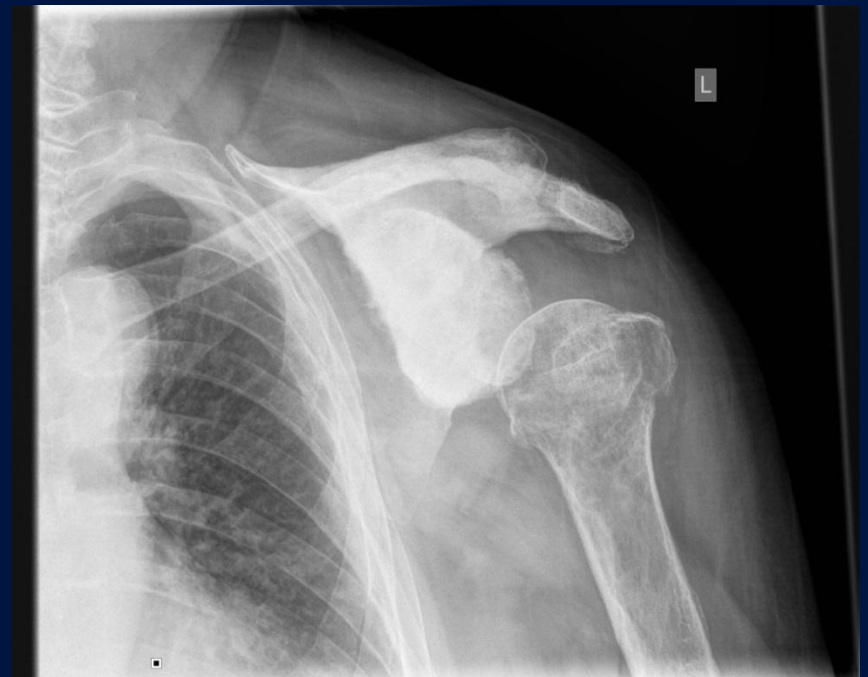- Radiographs for initial evaluation of bone lesion
- Additional imaging dept on 1 of 4 conditions:
  - 1. nl XR, but pt has persistent sx
  - 2. abnl XR, clinician suspects mets or MM on basis of hx, lab values or both
  - 3. abnl XR, non-aggressive-appearing tumor
  - 4. abnl XR, aggressive-appearing primary bone tumor

# ACR Appropriateness Criteria for Evaluation of Bone Tumors

- Radiographs for initial evaluation of bone lesion
- Additional imaging dept on 1 of 4 conditions:
  - 1. nl XR, but pt has persistent sx
  - 2. abnl XR, clinician suspects mets or MM on basis of hx, lab values or both
  - 3. abnl XR, non-aggressive-appearing tumor
  - 4. abnl XR, aggressive-appearing primary bone tumor

# Modalities

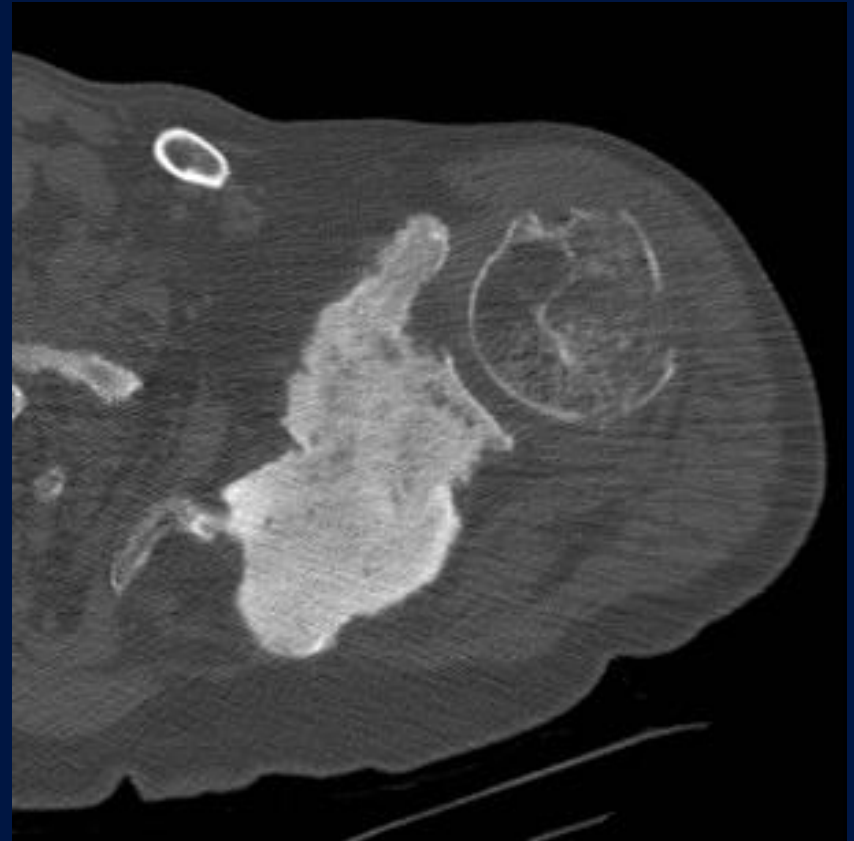- Conventional radiographs
  - Ddx is best derived from XR
- CT/MRI
  - Pre-operative assessment, biopsy, & staging
  - Further matrix characterization
  - ST component
- Bone scintigraphy
  - Degree of lesion radiotracer uptake
  - Lesion multiplicity



Courtesy, Evelyn Fliszar

# Modalities

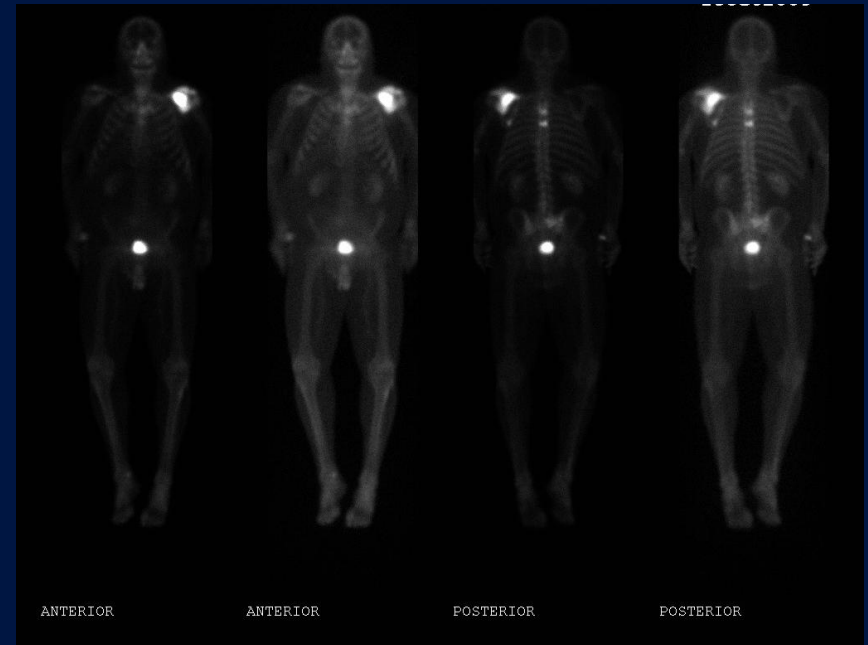- Conventional radiographs
  - Ddx is best derived from XR
- CT/MRI
  - Pre-operative assessment, biopsy, & staging
  - Further matrix characterization
  - ST component
- Bone scintigraphy
  - Degree of lesion radiotracer uptake
  - Lesion multiplicity



Courtesy, Evelyn Fliszar

# Modalities

- Conventional radiographs
  - Ddx is best derived from XR
- CT/MRI
  - Pre-operative assessment, biopsy, & staging
  - Further matrix characterization
  - ST component
- Bone scintigraphy
  - Degree of lesion radiotracer uptake
  - Lesion multiplicity



Courtesy, Evelyn Fliszar

# Staging

- 2 systems
  - Enneking 1<sup>st</sup> in 1980 (3 criteria)
  - American Joint Committee on Cancer (AJCC) in 1983 and revised in 2003 (4 criteria)
    - Does NOT apply to lymphoma or myeloma



# Enneking Staging System for Primary Malignant Bone Tumors

## 1. Tumor extent

- T1: intracompartmental
- T2: extracompartmental

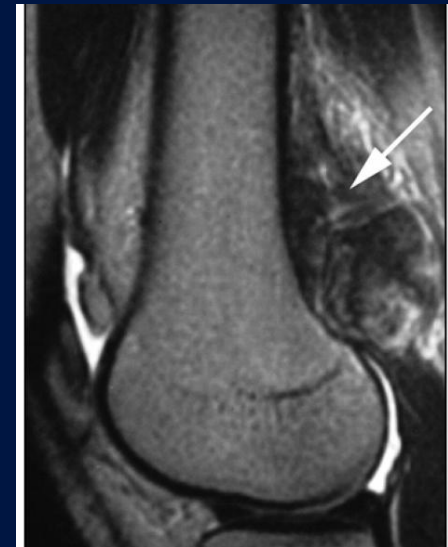
## 2. Mets

- M0: no mets
- M1: + mets

## 3. Histologic grade

- G1: low grade (<25% risk of mets)
- G2: high grade (>25% risk of mets)

- **INTRAc**ompartmental = entirely intraosseous or parosseous (ex: parosteal o-sarc)

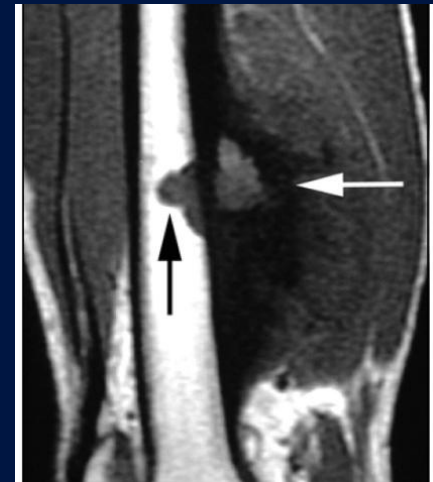


Stacy, G. S. et al. Am. J. Roentgenol. 2006;186:967-976

# Enneking Staging System for Primary Malignant Bone Tumors

- Based on 3 criteria
  1. Tumor extent
    - T1: intracompartmental
    - T2: extracompartmental
  2. Mets
    - M0: no mets
    - M1: + mets
  3. Histologic grade
    - G1: low grade (<25% risk of mets)
    - G2: high grade (>25% risk of mets)

- **EXTRA**compartmental = intraoss. w/ST-extension or parosseous w/ intraoss. or extrafascial extension (ex: parosteal o-sarc)



Stacy, G. S. et al. Am. J. Roentgenol. 2006;186:967-976

# Enneking Staging System for Primary Malignant Bone Tumors

- Based on 3 criteria
  1. Tumor extent
    - T1 = intracompartmental
    - T2 = extracompartmental
  2. Mets
    - M0 = no mets
    - M1 = + mets
  3. Histologic grade
    - G1 = low grade (<25% risk of mets)
    - G2 = high grade (>25% risk of mets)

**TABLE 2: Enneking Staging System [14] for Primary Malignant Tumors of Bone**

Stage	Tumor	Metastases	Grade
IA	T1	M0	G1
IB	T2	M0	G1
IIA	T1	M0	G2
IIB	T2	M0	G2
III	T1 or T2	M1	G1 or G2

Note—T1 = tumor is intracompartmental, T2 = tumor is extracompartmental, M0 = no regional or distant metastasis, M1 = regional or distant metastasis, G1 = low grade, G2 = high grade.

Stacy, G. S. et al. Am. J. Roentgenol. 2006;186:967-976

# AJCC Staging System for Primary Malignant Bone Tumors (after 1/1/2003)

- Based on 4 criteria

(**bold** = worse px):

- Tumor size:
  - T1 = < 8cm
  - T2 if > 8cm
  - T3** if skip mets
- Regional LN mets:
  - N0 = absent
  - N1 = present
- Mets:
  - M1a = lung mets only
  - M1b** = mets other sites/LNs
- Grade:
  - G1 = well-, G2 = moderately-, **G3** = poorly-, **G4** = un-differentiated

Stage	Tumour	Lymph node	Metastases	Grade
IA	T1	N0	M0	G1 or G2
IB	T2	N0	M0	G1 or G2
IIA	T1	N0	M0	G3 or G4
IIB	T2	N0	M0	G3 or G4
III	T3	N0	M0	Any G
IVA	Any T	N0	M1a	Any G
IVB	Any T	N1	Any M	Any G
IVB	Any T	Any N	M1b	Any G

# AJCC Staging System for Primary Malignant Bone Tumors (after 1/1/2003)

- Rather than intra- or extra-osseous tumor extent, **tumor size** found to be better px indicator
- Stage III if **skip mets**
- Stage IV if **distant mets**:
  - Lung mets are IVA
  - Elsewhere is IVB

Stage	Tumour	Lymph node	Metastases	Grade
IA	T1	N0	M0	G1 or G2
IB	T2	N0	M0	G1 or G2
IIA	T1	N0	M0	G3 or G4
IIB	T2	N0	M0	G3 or G4
III	T3	N0	M0	Any G
IVA	Any T	N0	M1a	Any G
IVB	Any T	N1	Any M	Any G
IVB	Any T	Any N	M1b	Any G

# MRI vs CT

- MRI superior to CT in detecting intraosseous extent
- Best sequence is debatable:
  - For osarc, must include a T1-wted spin echo
  - STIR may overestimate intraosseous tumor when compared to histopath specimens

# Epiphyseal involvement

- Physis was thought to be barrier to tumor extension
- MRI = extension of intermed T1 SI across GP w/ physeal destruction
  - Hi sensitivity
  - Low specificity due to FP cases from low SI red marrow at the physis
- T1 more specific and STIR more sensitive to determine epiphyseal involvement

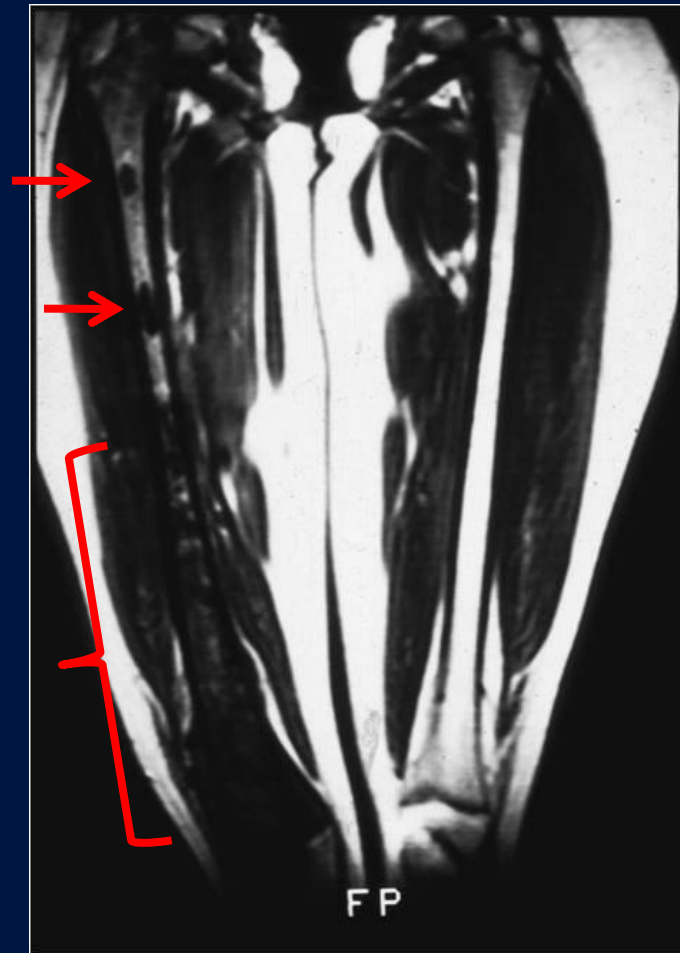# Sample MR protocol for assessing primary tumor

- Large field-of-view coronal or sagittal sequence covering the entire bone
- Small field of view sequences to cover the primary tumor in its entirety:
  - T1- and fat-suppressed T2-weighted sequences in the axial plane
  - T1- and fat-suppressed T2-weighted sequences performed in at least one orthogonal plane



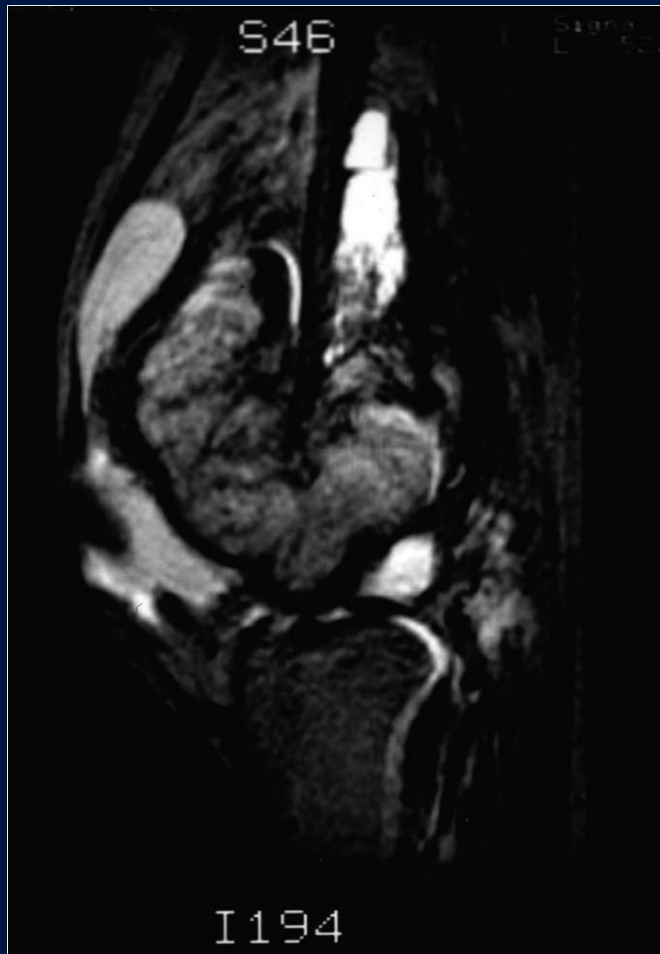
# Skip mets

- Intramedullary osteosarcoma (}) with skip mets (arrows) on coronal T1 MR image
- Must include entire length of bone



Courtesy, George Nomikos, AFIP

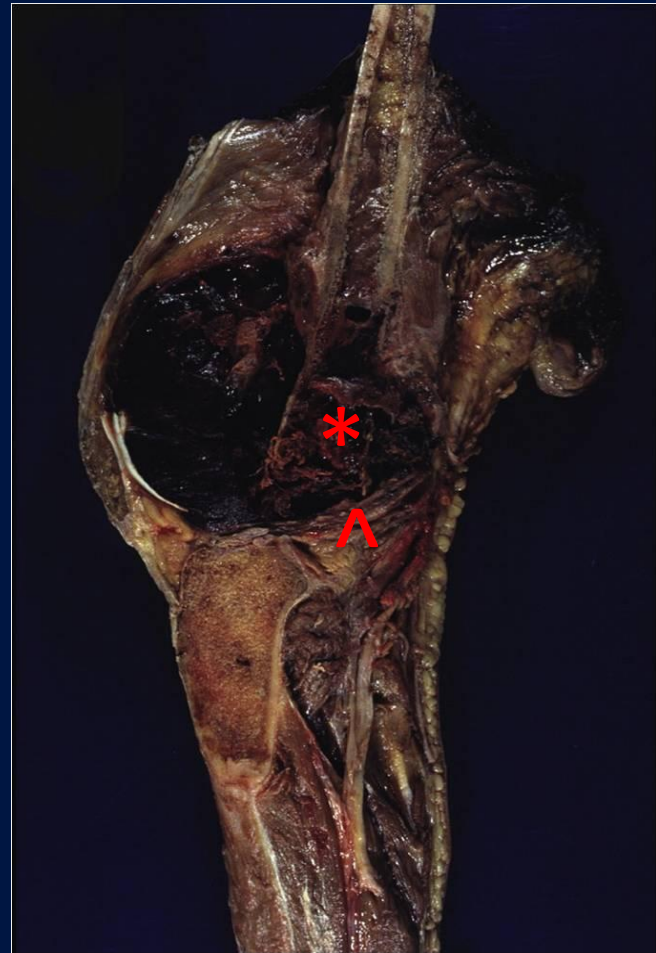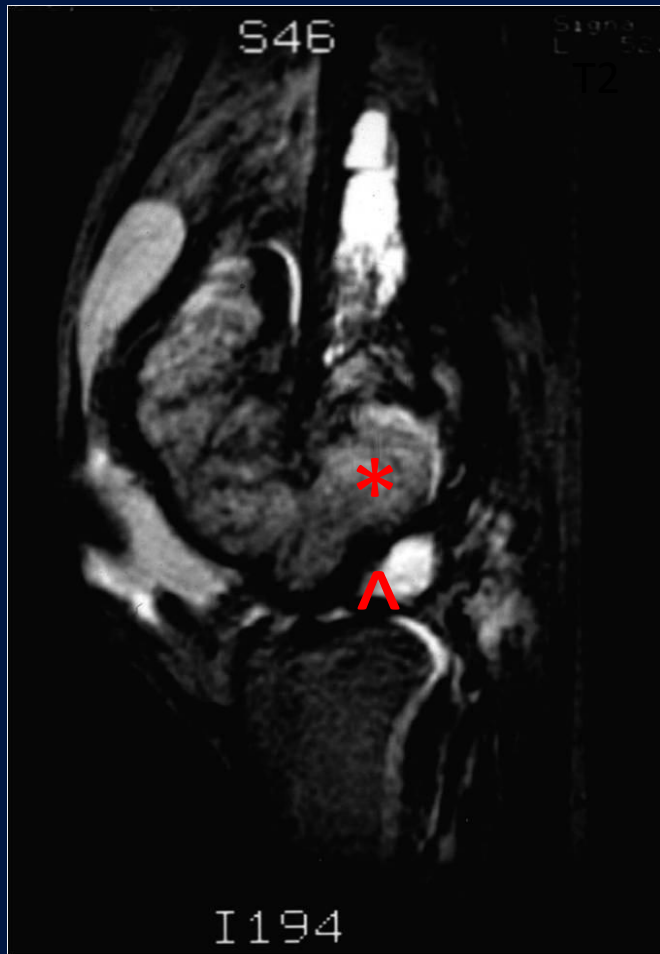
# Determining joint invasion:



- Important for surgical planning:
  - Limb sparing surgery
  - Vs. joint amputation
- Joint effusion does not = Joint involvement

Courtesy, George Nomikos, AFIP

# Joint invasion: osteosarcoma (\*) along ACL (^)



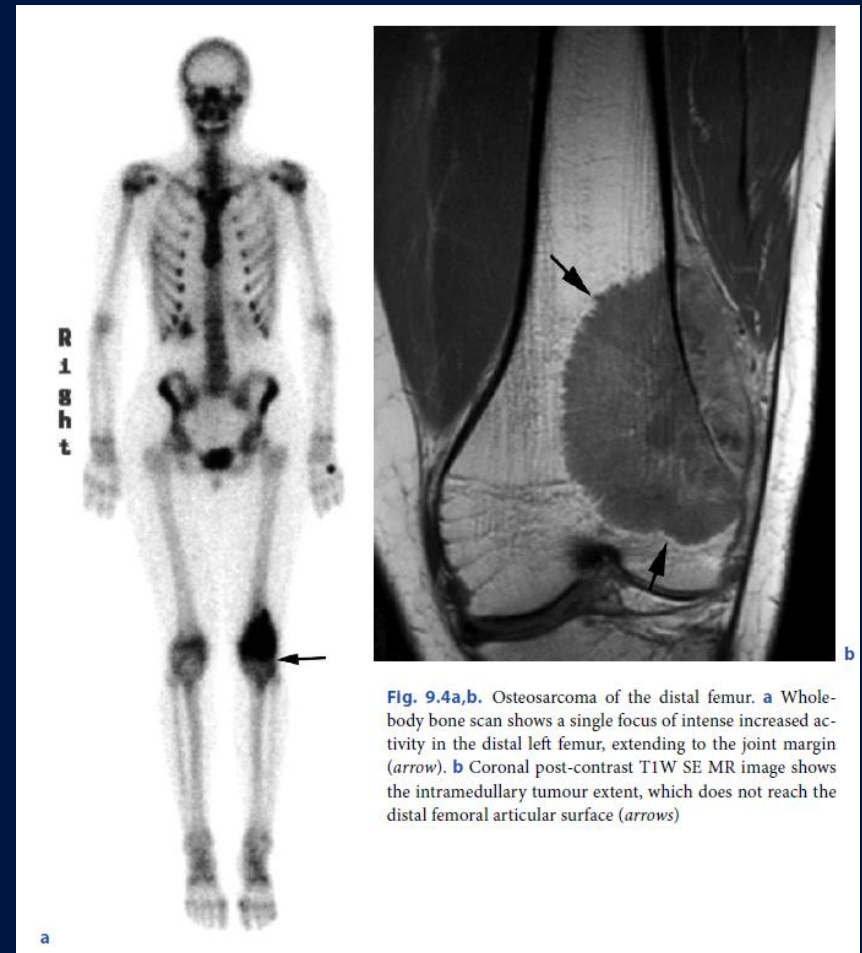
Courtesy, George Nomikos, AFIP

# Role of IV Gad

- Limited value b/c of inherent contrast b/t the tumor and normal marrow signal
  - Intermed/low T1 and nl/high SI marrow fat
- Helpful to differentiate solid f/ hemorrhage & necrosis
  - Aids in **biopsy** planning
  - Arguably, T2 can be of similar utility
- Dynamic CE-MRI → not useful in initial staging
  - May help discern tumor f/ reactive edema post chemotx or to see residual tumor postop

# Bone Scan (Scintigraphy)

- Can overestimate extent of intraosseous tumor d/t falsely extended uptake
- May show apparent joint involvement
- Correlates poorly with path specimens, underestimates and overestimates

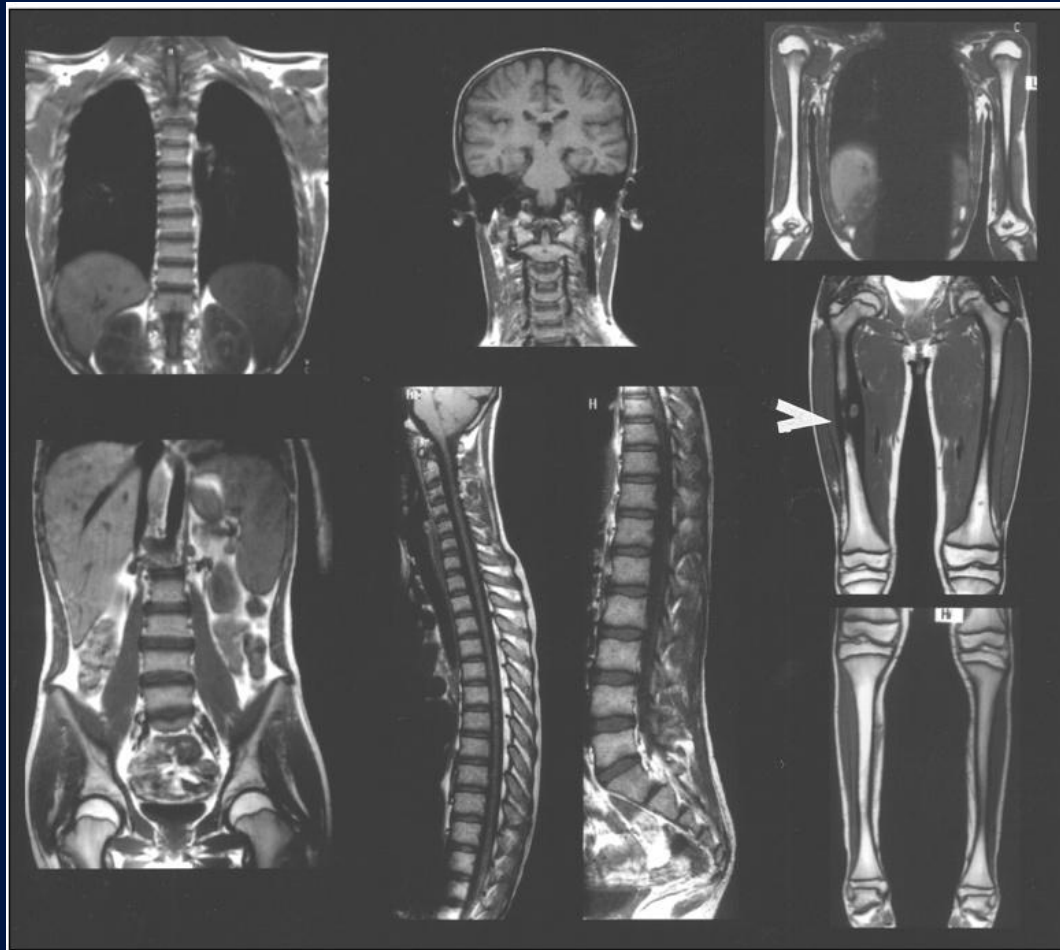


**Fig. 9.4a,b.** Osteosarcoma of the distal femur. **a** Whole-body bone scan shows a single focus of intense increased activity in the distal left femur, extending to the joint margin (*arrow*). **b** Coronal post-contrast T1W SE MR image shows the intramedullary tumour extent, which does not reach the distal femoral articular surface (*arrows*)

# Role of advanced imaging

- Traditionally, relied on bone scan during initial w/u
- More recent advances include **WB MRI**
  - Improved techniques have reduced imaging time to < 1hr
  - (rolling platform, parallel imaging, phased-array coils)
- WB MRI better than PET for brain & liver mets
- Chest CT preferred for evaluating lung mets, lymph nodes
  - PET limited for detecting sub-cm nodules
- Currently, PET best to confirm suspicious or equivocal findings & assess areas not in FOV on other modalities
- MRI best for skip lesion detection
  - PET shows promise in peds as red marrow can limit assessment for skip mets on MRI & bone scan

# Sample images Whole Body MRI – LCH (arrowhead)



# Role of whole body MRI and FDG-PET

- Some evidence that WB-MRI + PET have higher sensitivity for primary bone mets detection than skeletal scintigraphy



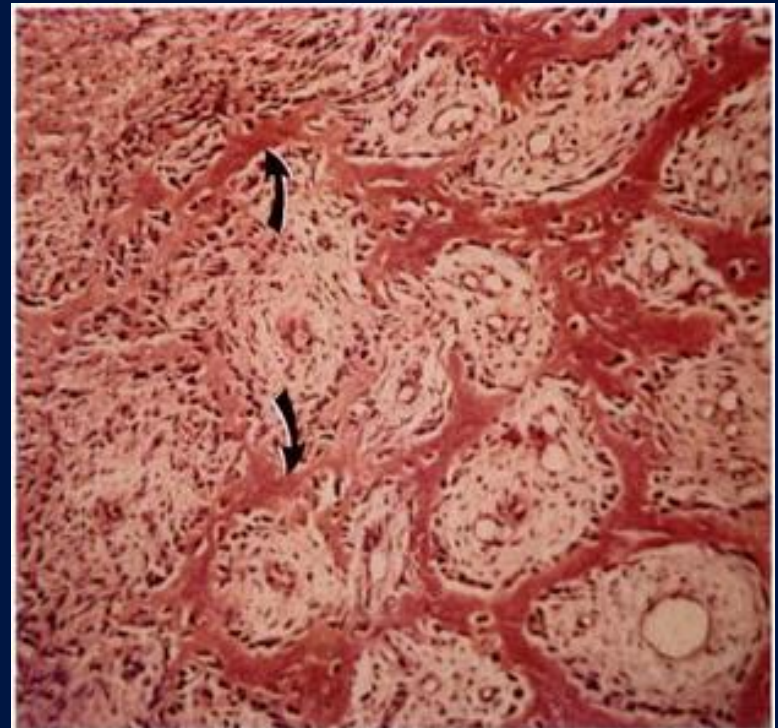
Primary Bone Malignancy

# OSTEOSARCOMA

---

# Osteosarcoma (Osteogenic Sarcoma (OGS))

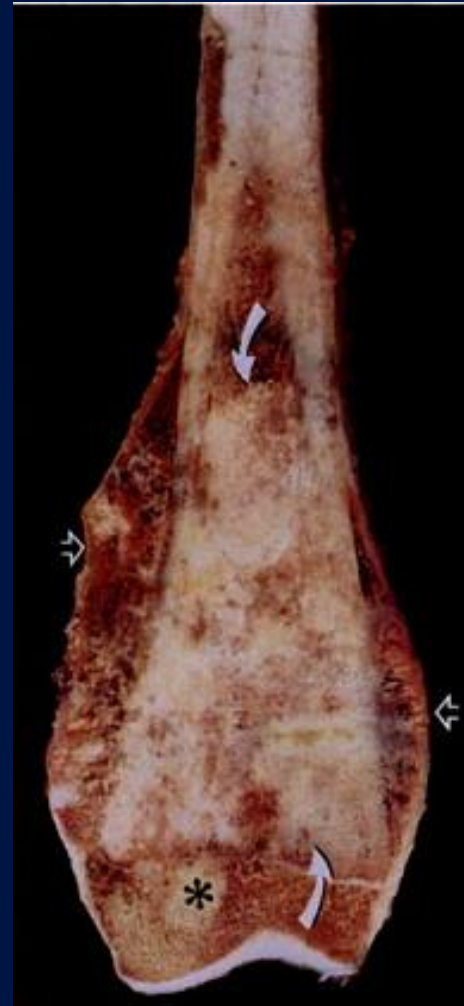
- Malignant mesenchymal neoplasm which makes **osteoid** (arrows) or immature bone
- Histo:
  - Osteoblastic (predominates in 50-80%)
  - Chondroblastic
  - Fibroblastic



Murphey MD, RG 1997;17:1205-1231

# Osteosarcoma Types

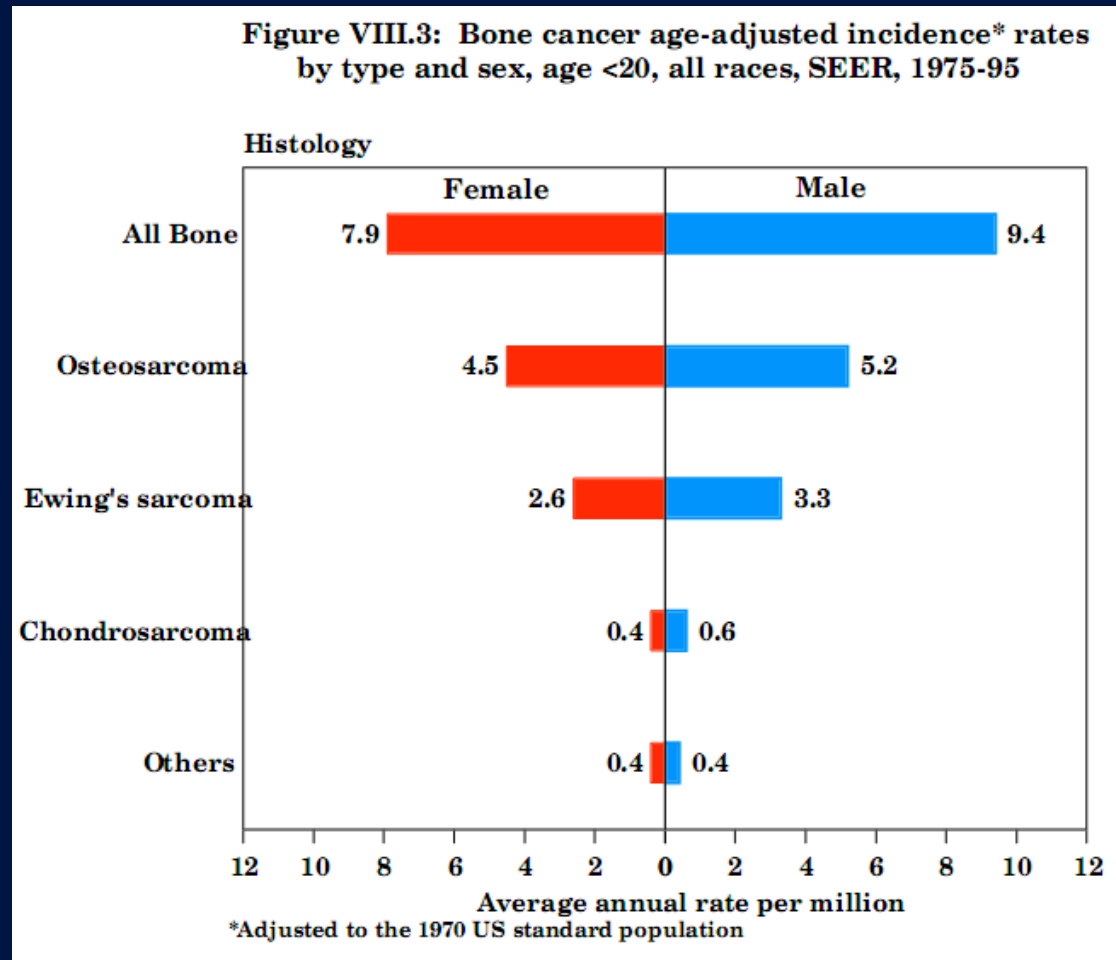
- Intramedullary (75%)
  - High-grade\*
  - Telangiectatic\*
  - Low-grade
  - Small cell
  - Osteosarcomatosis\*
  - Gnathic tumors
- Surface (10%)
  - Intracortical
  - Parosteal\*
  - Periosteal\*
  - High-grade surface tumors
- Extraskeletal
- Secondary (malignant transformation)\*



Murphey MD, RG 1997;17:1205-1231

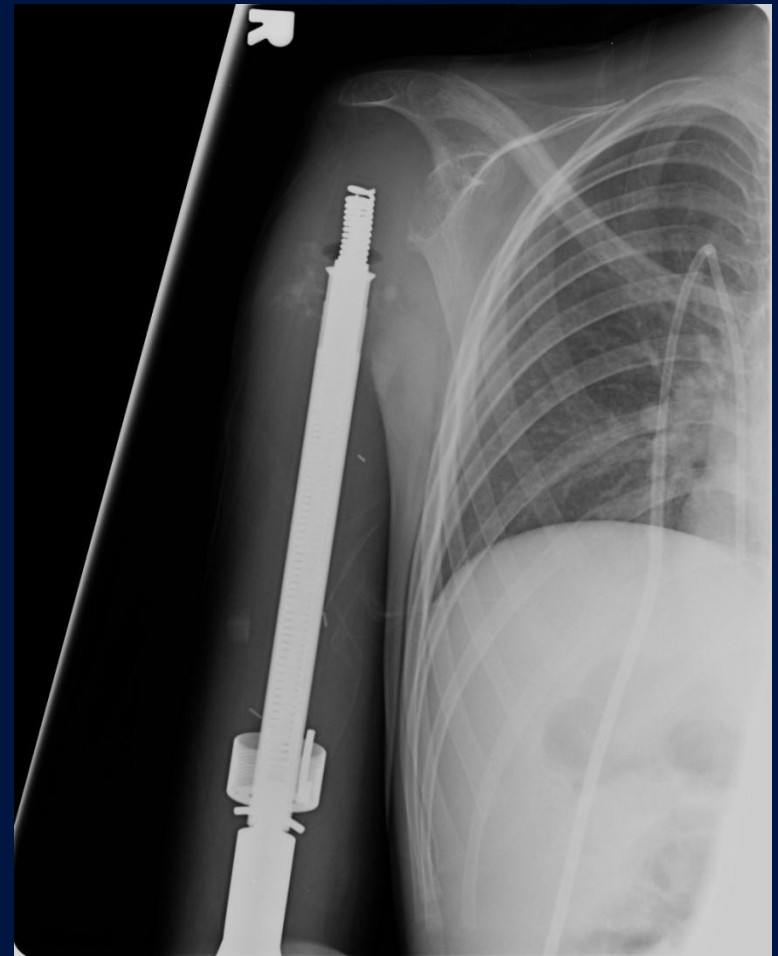
# Osteosarcoma – Epidemiology

- Most common primary bone malignancy in pts < 20 yo
  - <6 or >60 yo unusual
- 2<sup>nd</sup> most common in all ages following myeloma
- More common in white pts
- M:F, 1.5:1



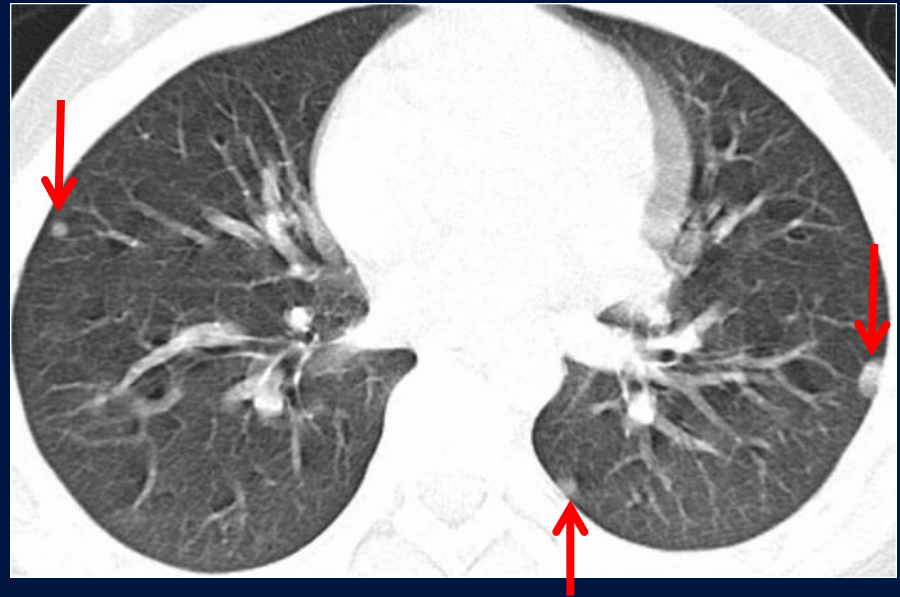# Osteosarcoma Treatment

- Chemotx
- Wide surgical resection
- Limb salvage if possible (or amputation)



# Osarc - Metastatic disease

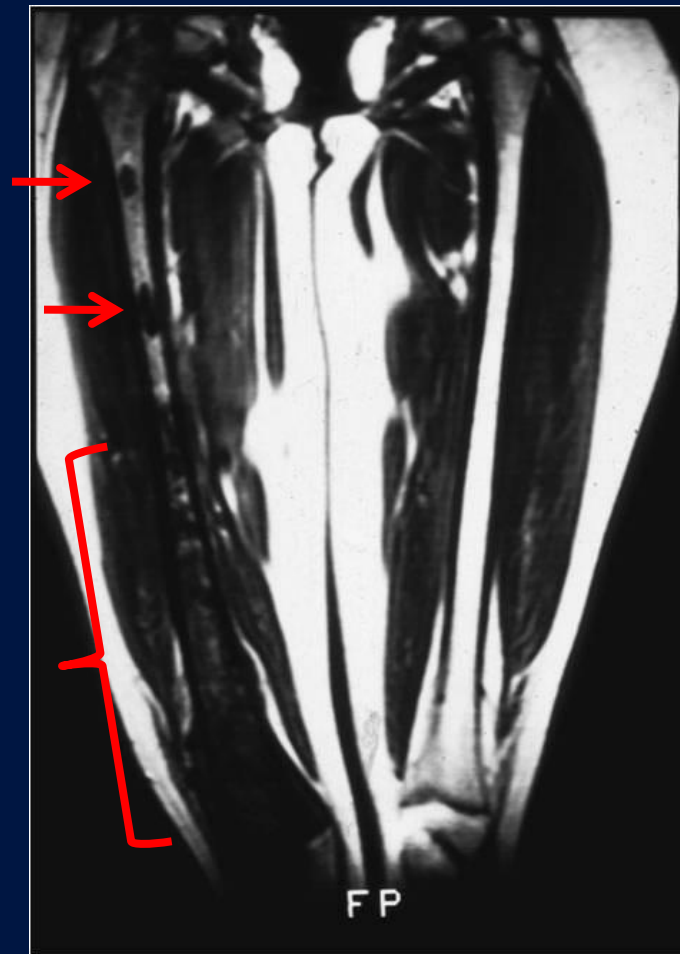- Lungs
  - Spontaneous ptx
- Regional/distant LNs
- Bones



Courtesy, George Nomikos

# Osarc - Metastatic disease

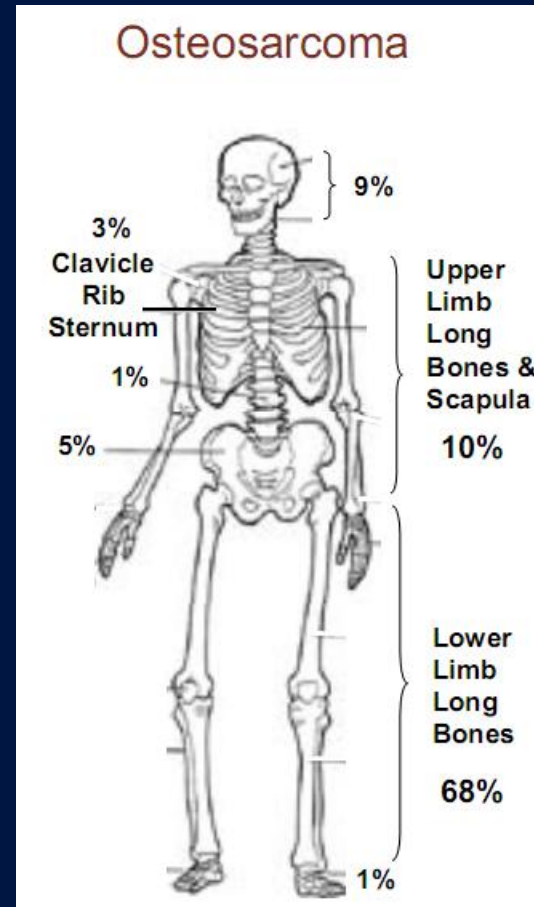
- Lungs
- Regional/distant LNs
- Bones:
  - Skip mets (MR of entire length of bone)
    - Intramedullary osteosarcoma ({} with skip mets (arrows) on coronal T1 MR image



Courtesy, George Nomikos

# Osteosarcoma: high-grade intramedullary

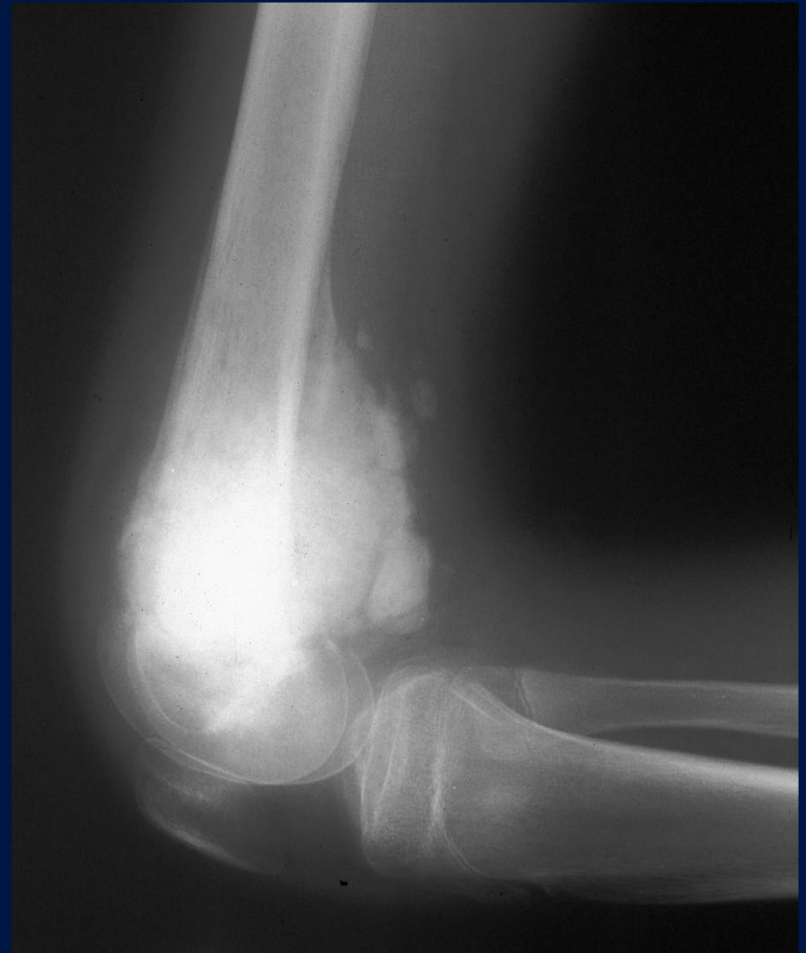- Also called central or conventional
- 75% of all osarcs
- 15-25 yo
- 5 yr survival of 60-80%
- About the knee (50-55%)
  - Femur > tibia > humerus





# Osteosarcoma: high-grade intramedullary

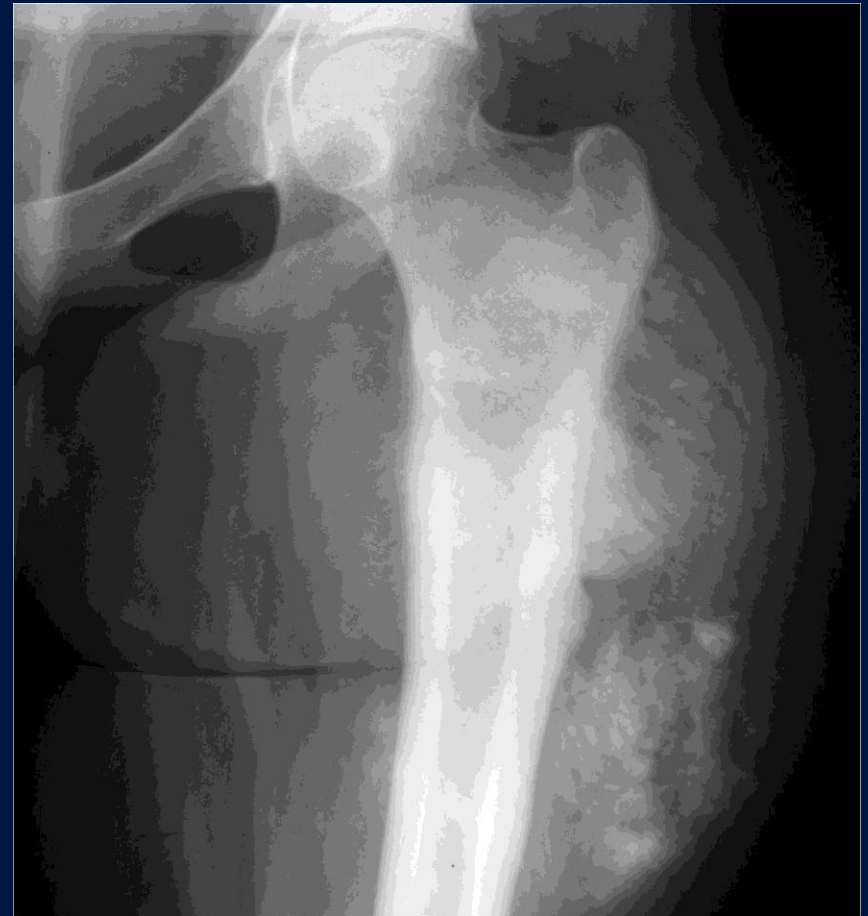- 90% metaphyseal
  - Majority cross to epiphysis
- 5-10% diaphyseal
- < 1% epiphyseal
- (Murphey, AFIP notes)



Courtesy, George Nomikos

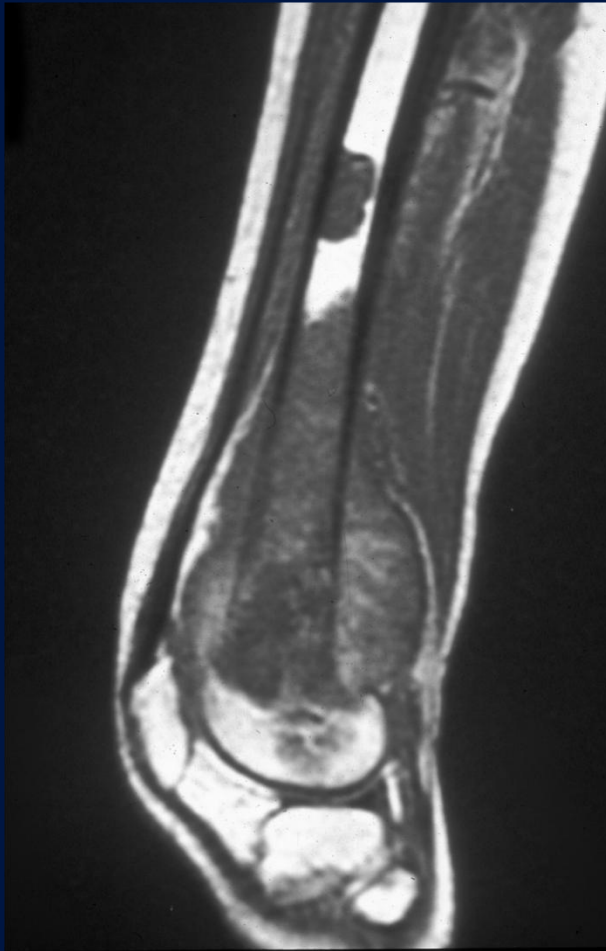# Osteosarcoma: high-grade intramedullary - XR

- Mixed sclerosis/lysis
- Aggressive periostitis & ST mass
- Violates cortex w/o expanding it
- Large at dx, > 6cm
- Rapid growth (doubles in 20-30 days)



Courtesy, George Nomikos

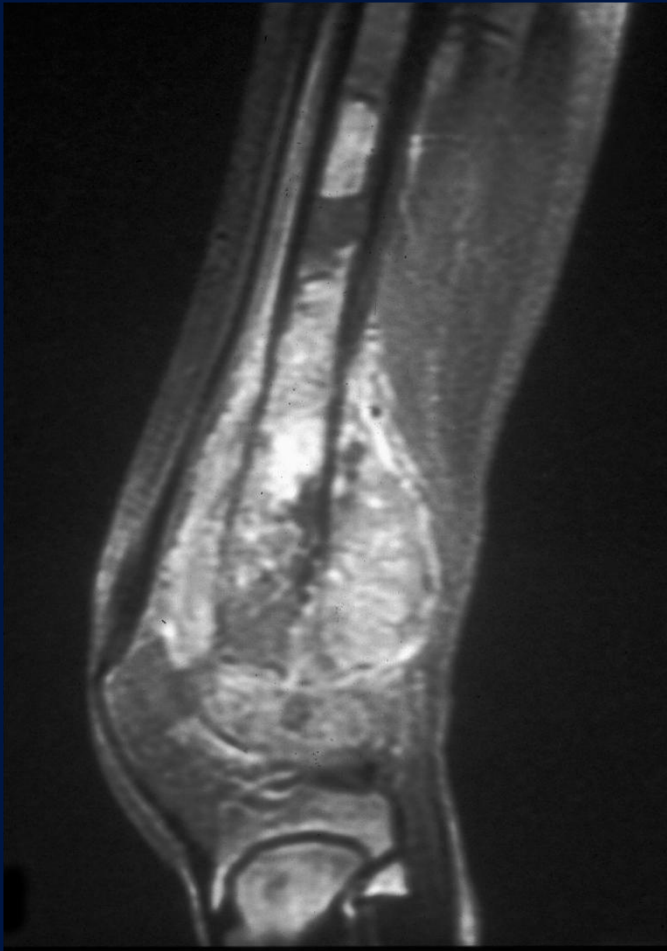
# Osteosarcoma: high-grade intramedullary - MR



- Essential for staging and preoperative planning
- Tumor is intermediate SI on T1

Courtesy, George Nomikos

# Osteosarcoma: high-grade intramedullary - MR

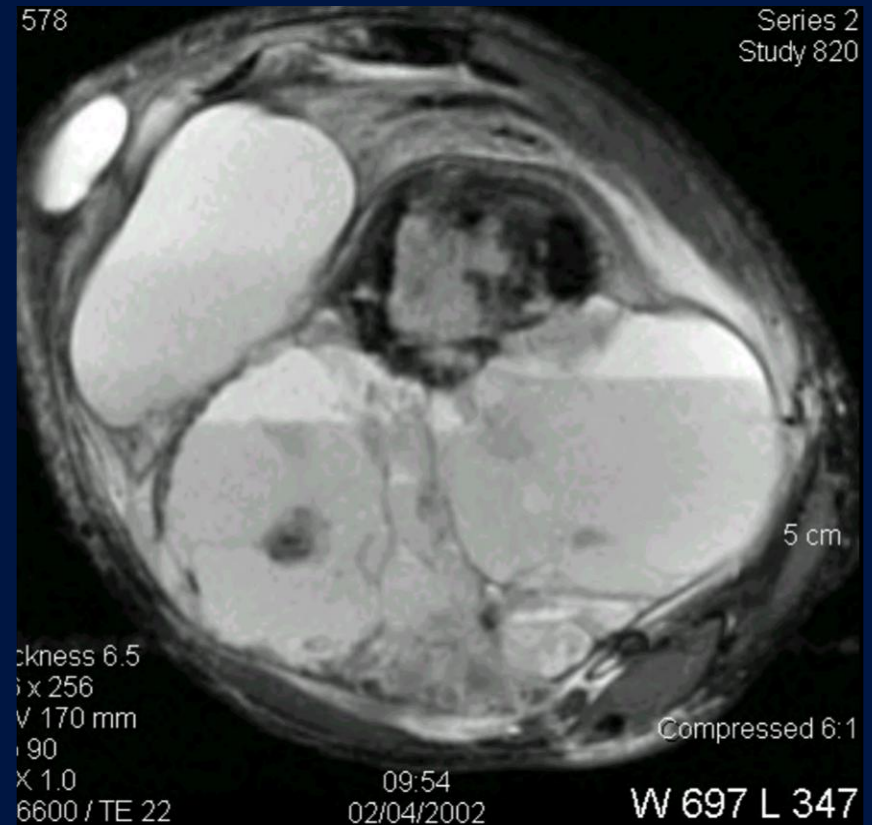

- Tumor is high SI on T2
- Mineralized matrix = areas of low SI on both T1 and T2
- Areas of hemorrhage = high SI on both T1 and T2
- Areas of necrosis (ST or bone) = low T1, high T2

Courtesy, George Nomikos

# Telangiectatic osteosarcoma

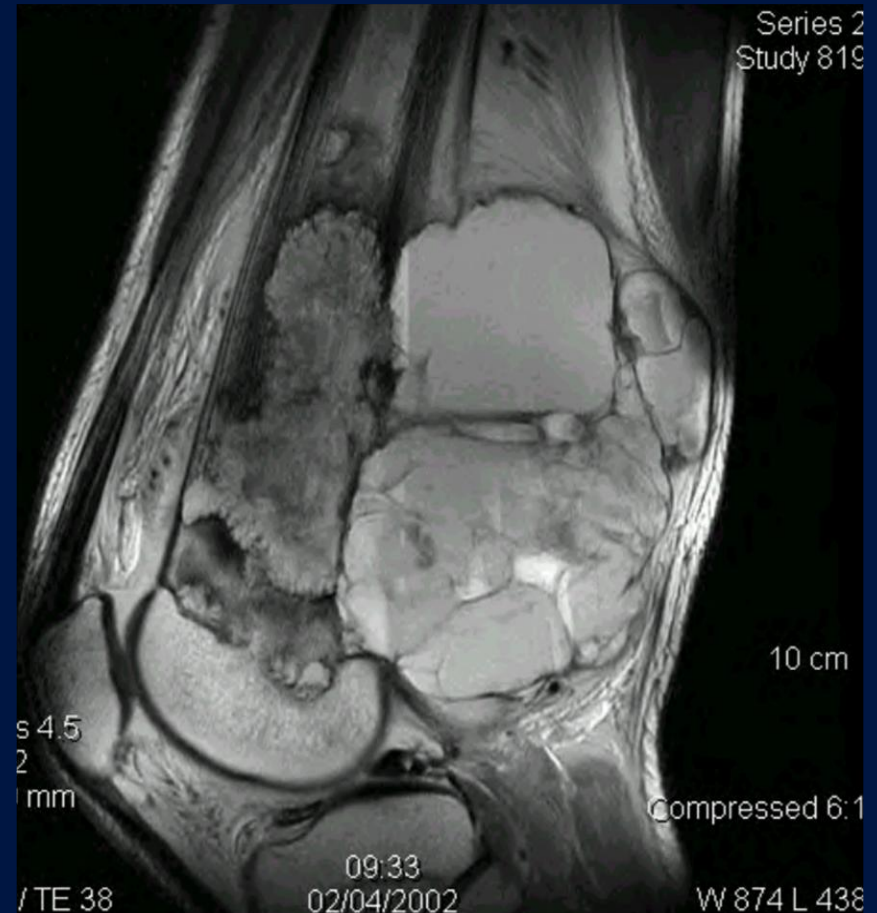- 4.5-11% of all osarcs
- Sim distribution to intramedullary:
  - Most around knee
  - 90% metaphyseal, 10% diaphyseal
  - May have better px t/ others (68% 5-yr survival)
- Can be secondary (FD, Paget, & after XRT)
- Rarely extraskeletal



Courtesy, George Nomikos

# Telangiectatic osteosarcoma

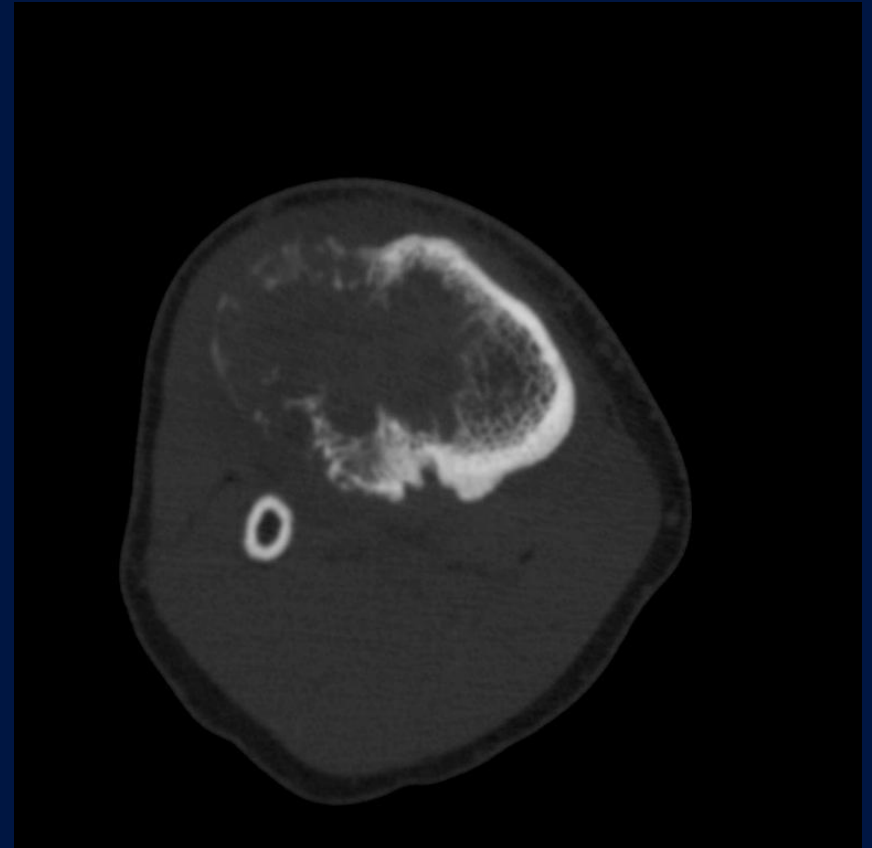
- Must have hemorrhagic, cystic, or necrotic spaces occupying  $> 90\%$  lesion
- Cystic cavities = cavernous vessels, blood filled spaces
  - Fluid/fluid levels



Courtesy, George Nomikos

# Telangiectatic osteosarcoma

- Largely osteolytic & expansile
  - Geographic bone destruction
  - Wide zone of transition
- Osteoid formation in periphery
  - “Donut sign” on bone scan
  - RN accumulation in periphery, central photopenia

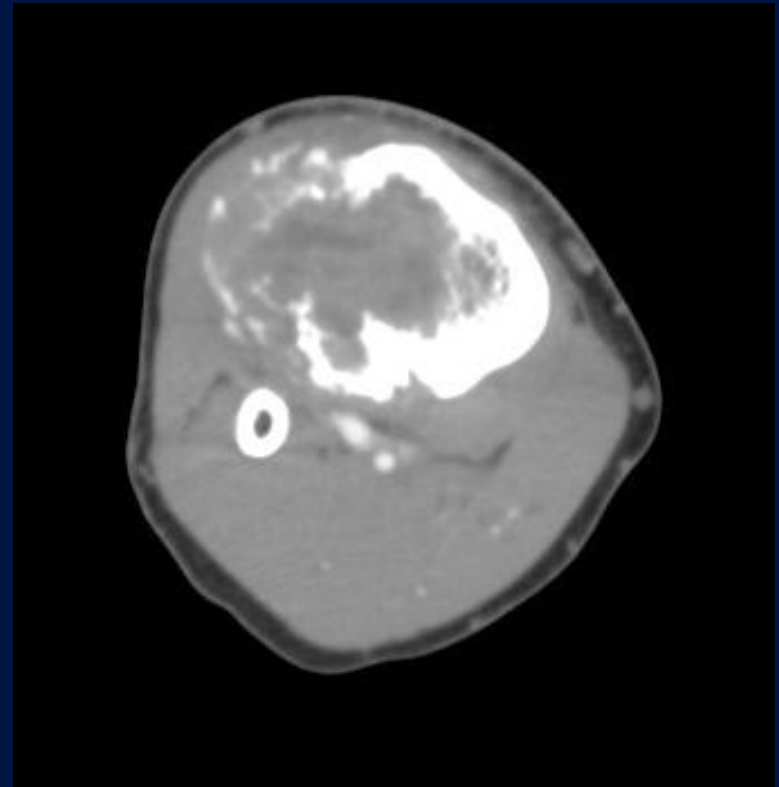


Courtesy, George Nomikos



# Telangiectatic osteosarcoma

- Aggressive periosteal rxn
- Cortical destruction
- ST mass
- Pathologic frx

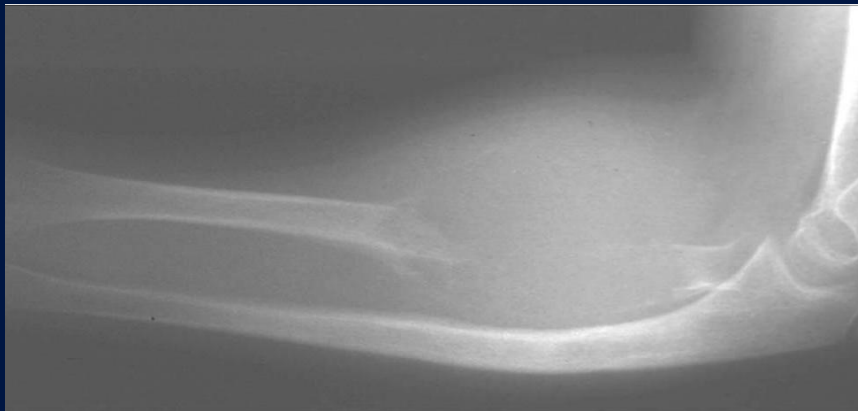
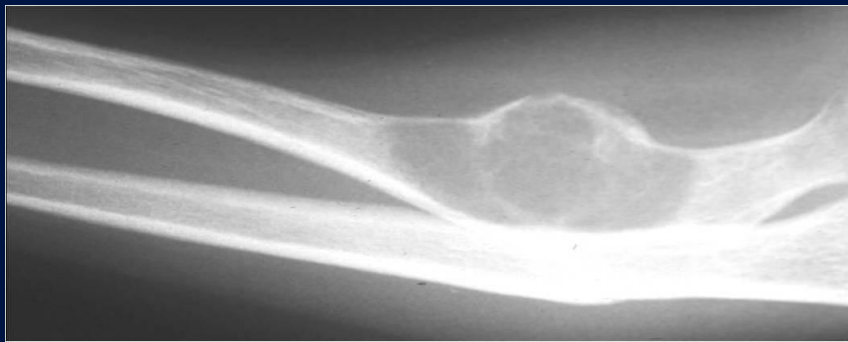

Courtesy, George Nomikos



# ... Not to be confused with Aneurysmal Bone Cyst (ABC)

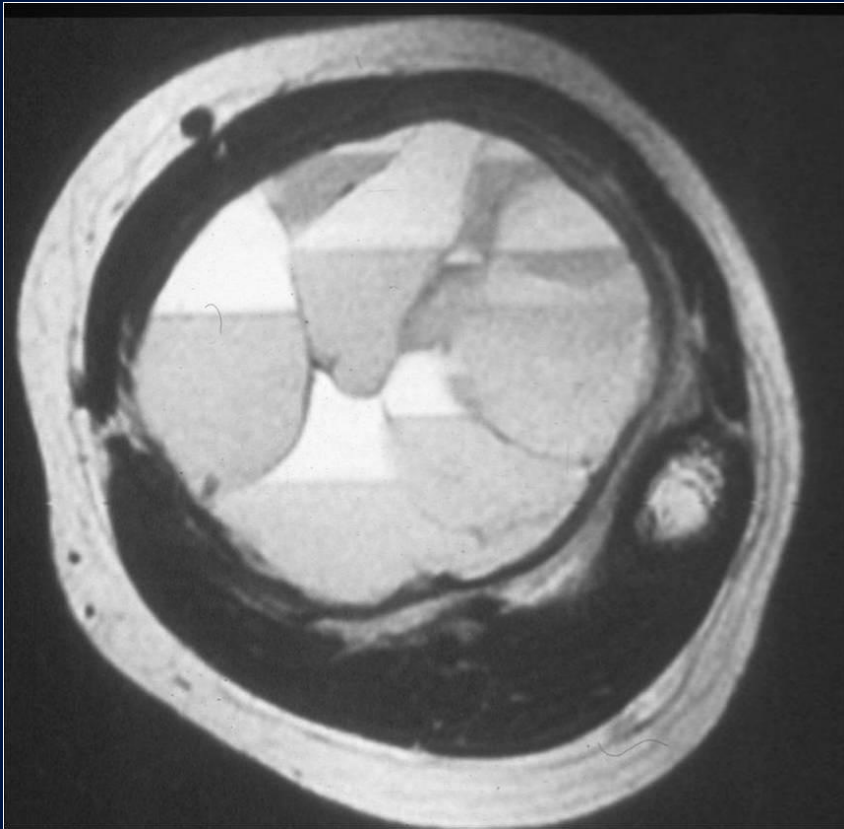
---



- Term aneurysmal is based on its radiographic appearance
- Interval of 4 mos b/t images
- Rapid lesion expansion has been reported
- <http://www.bonetumor.org/tumors-bone/aneurysmal-bone-cyst>

# ... Not to be confused with Aneurysmal Bone Cyst (ABC)

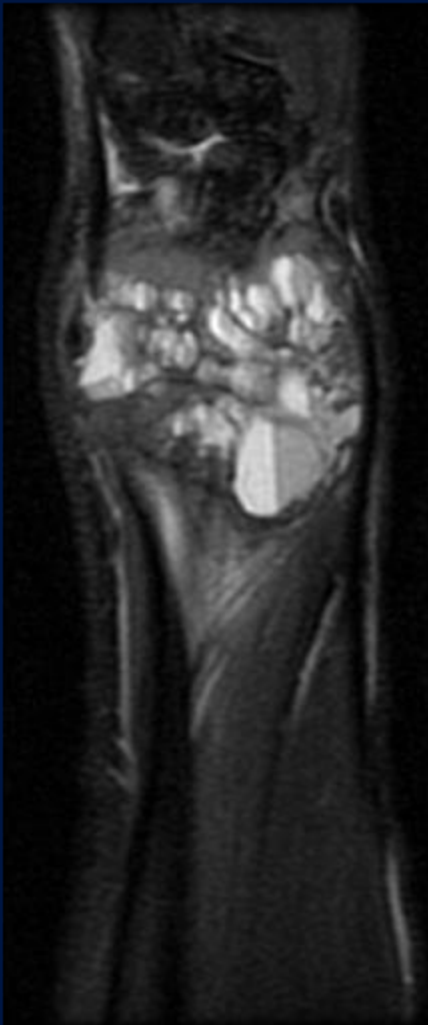---



- Expansile osteolytic lesion with a thin wall, containing blood-filled cystic cavities
- True cause unknown (possibly post-traumatic)

# Ddx of Secondary ABC includes . . .

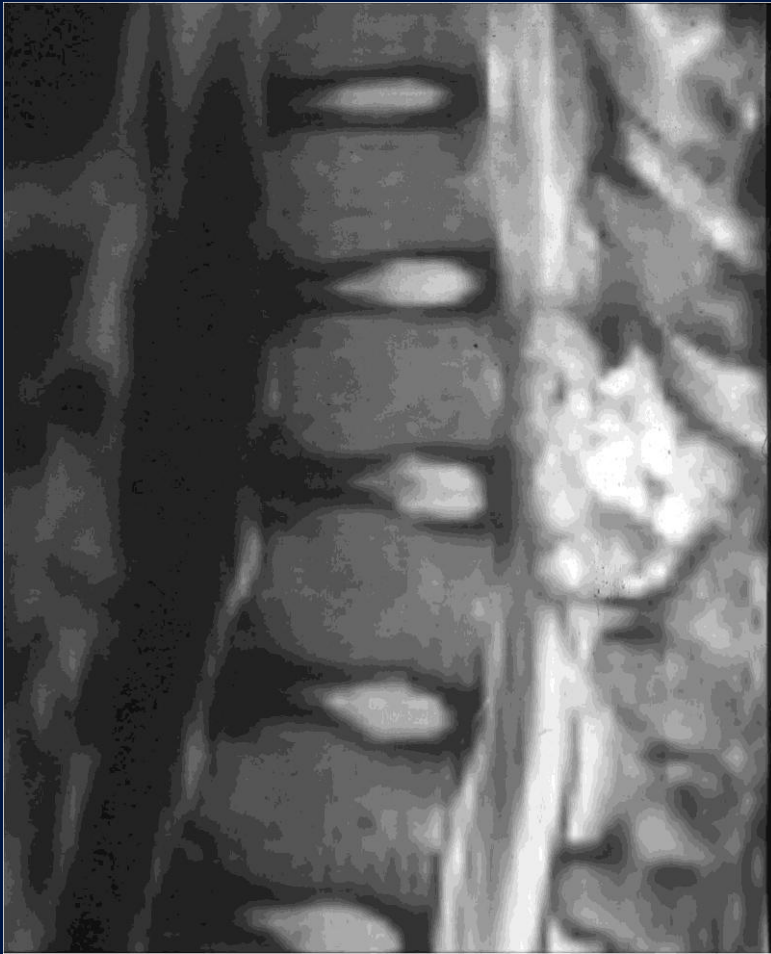---



- Giant cell tumor of bone (distal radius)
- Osteoblastoma
- Chondroblastoma

Courtesy, Brady Huang

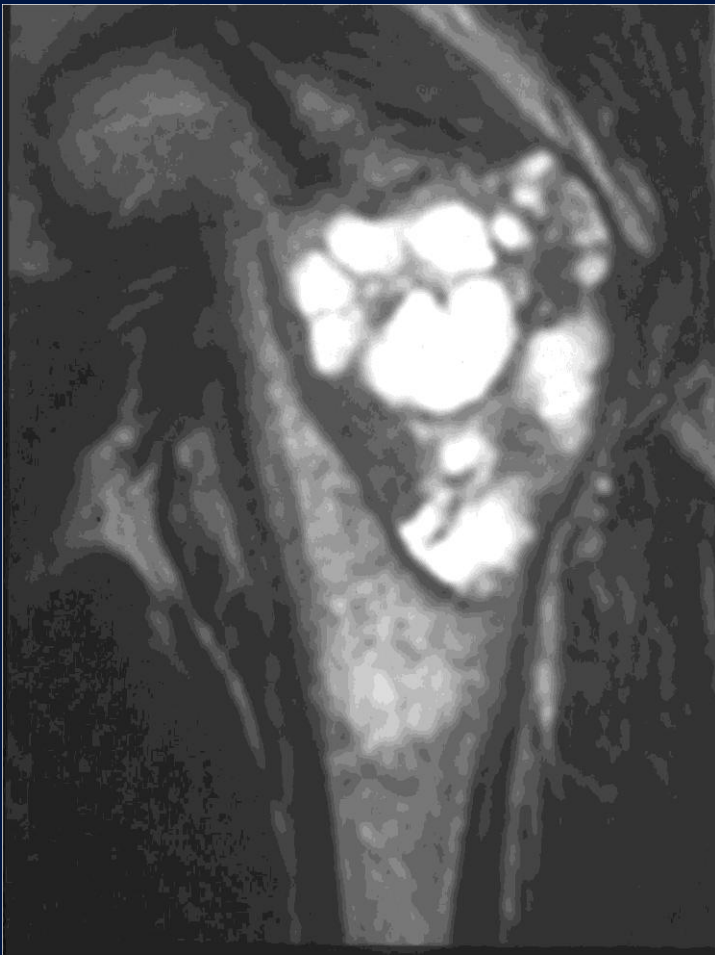# Ddx of Secondary ABC includes . . .



- Giant cell tumor of bone
- Osteoblastoma
- Chondroblastoma

Courtesy, George Nomikos

# Ddx of Secondary ABC includes . . .

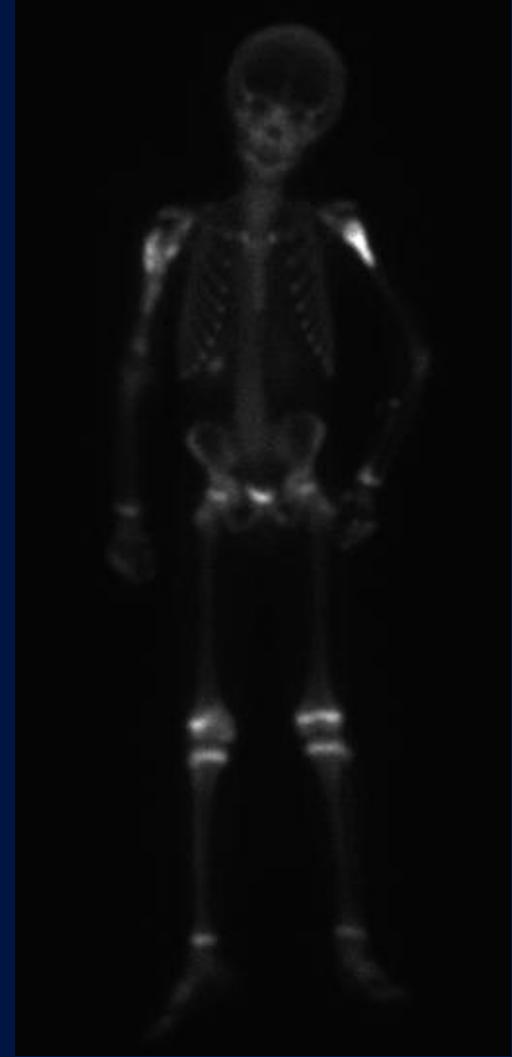

- Giant cell tumor of bone
- Osteoblastoma
- Chondroblastoma

Courtesy, George Nomikos , AFIP

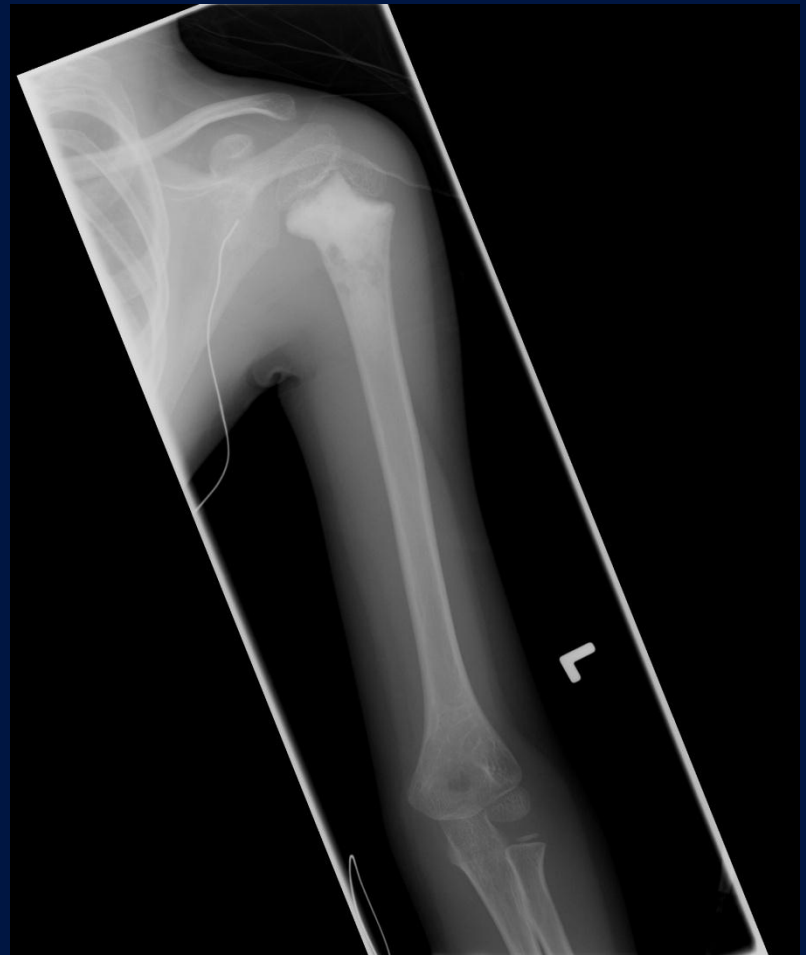# Osteosarcomatosis

- Also known as multifocal osteosarcoma, or multiple sclerotic osteosarcoma
- Multiple intraosseous foci of osarc at time of presentation
- Uncommon, 3-4% of osarc cases



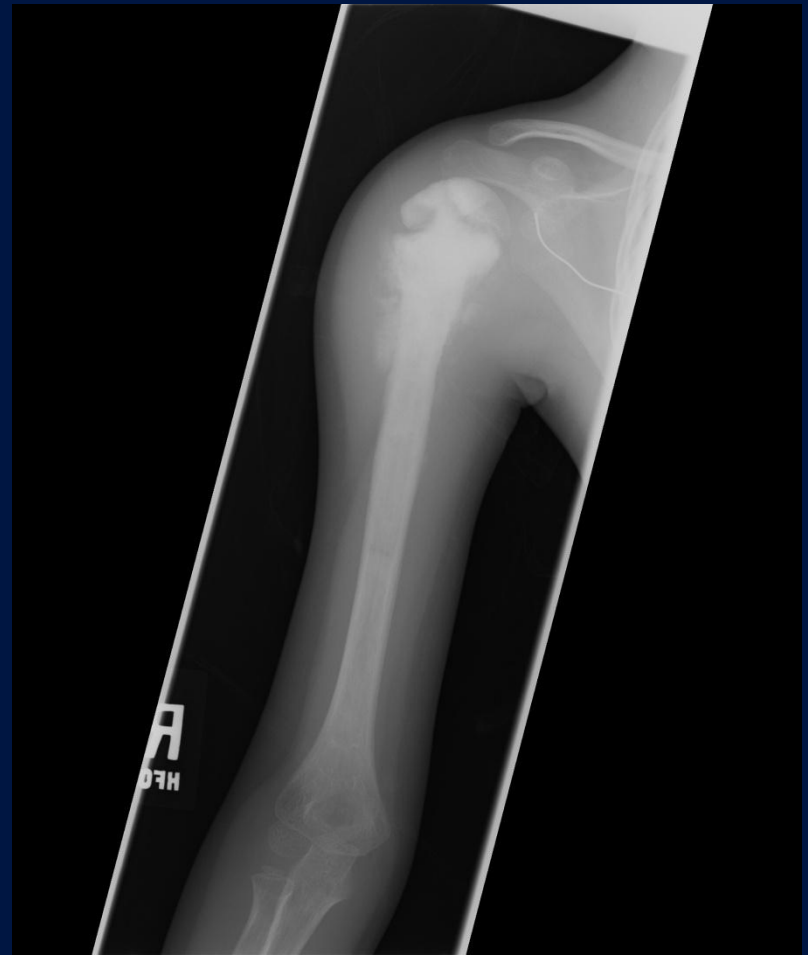# Osteosarcomatosis

- Possibly represents rapidly progressive metastatic disease
  - Murphey strongly believes this
- Rapidly appearing, usually symmetric, sclerotic lesions



# Osteosarcomatosis

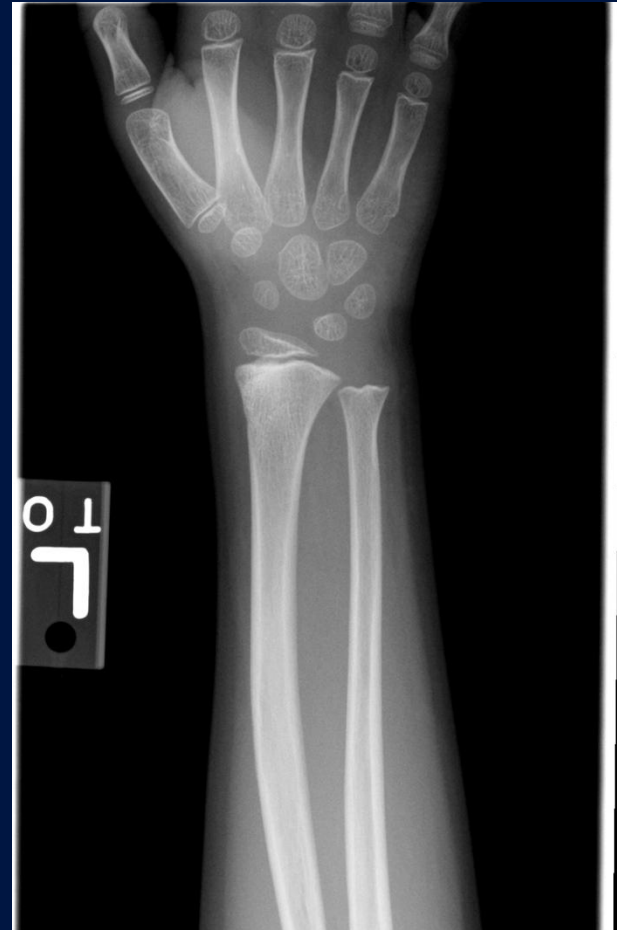- Typically a large, dominant lesion can be identified
- Dominant lesion:
  - Ill-defined margins
  - Aggressive periosteal rxn
  - Cortical disruption
  - Adjacent ST extension
  - Can be sclerotic or lytic



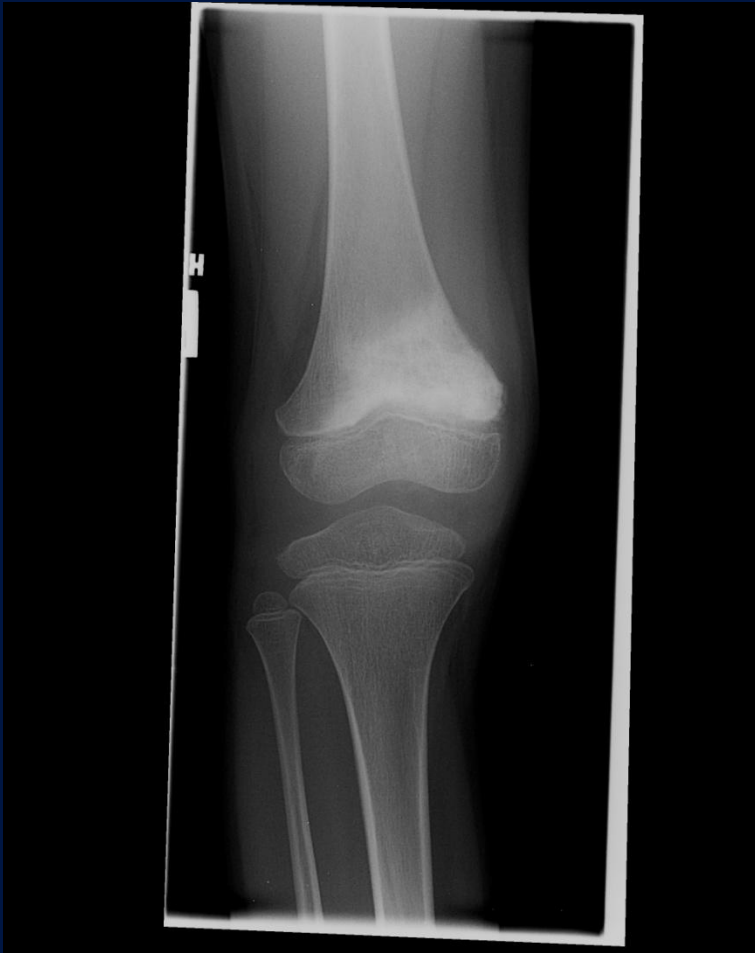

# Osteosarcomatosis

- Secondary foci:
  - Smaller
  - More sclerotic
  - Better defined
  - Lack periosteal rxn or cortical destruction

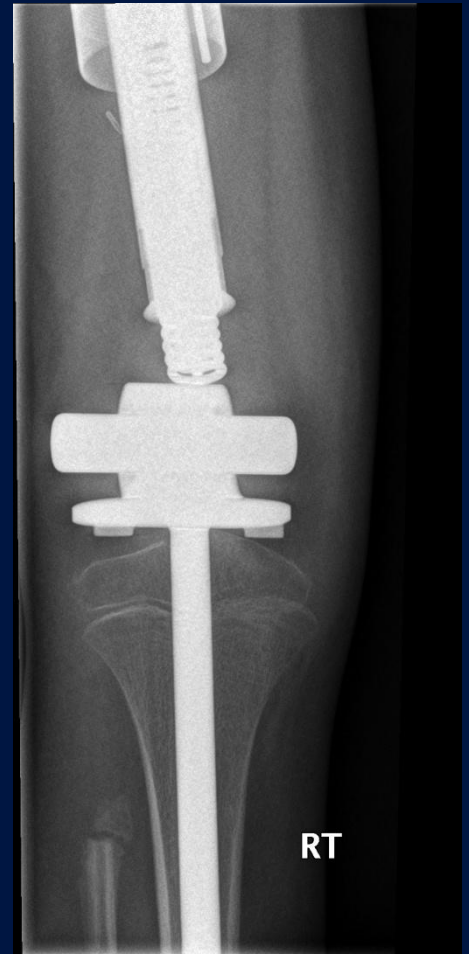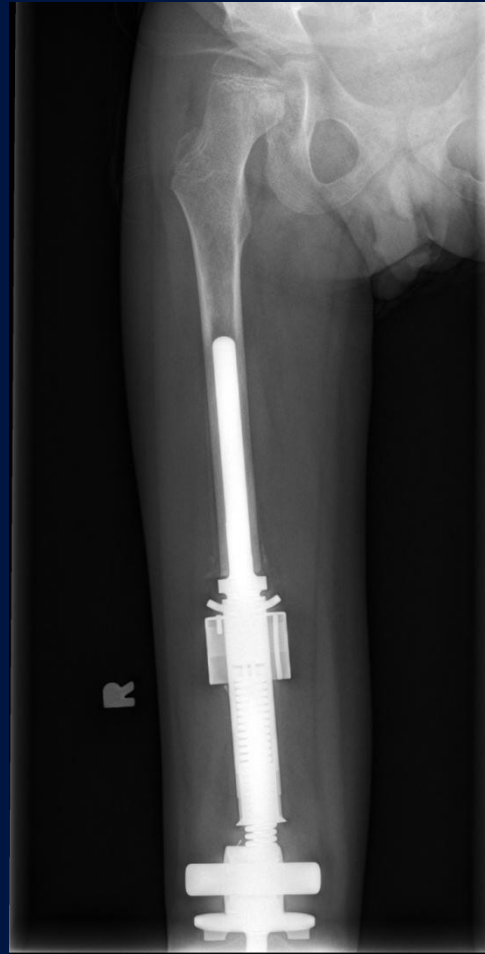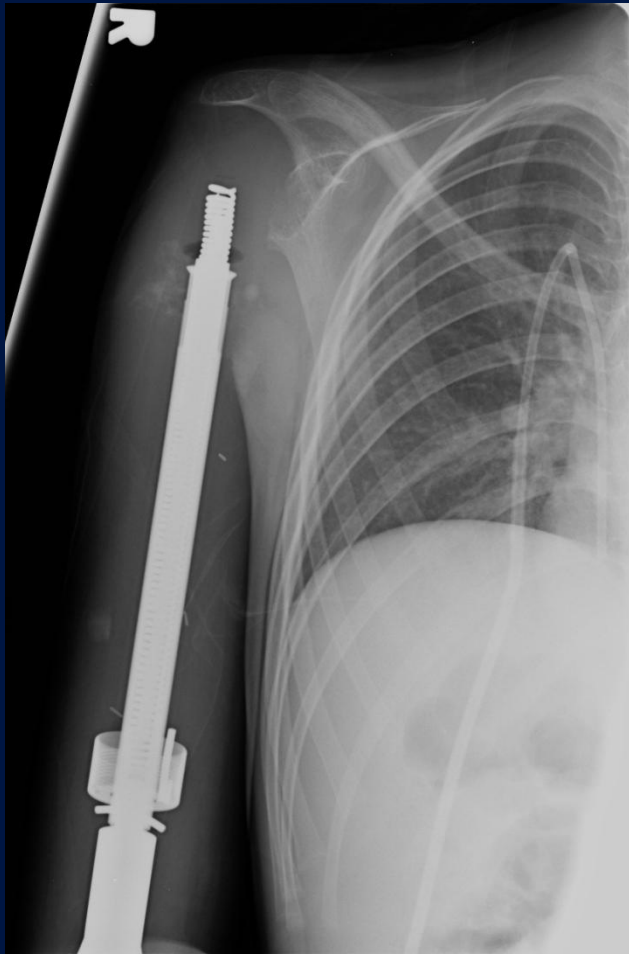


# Osteosarcomatosis

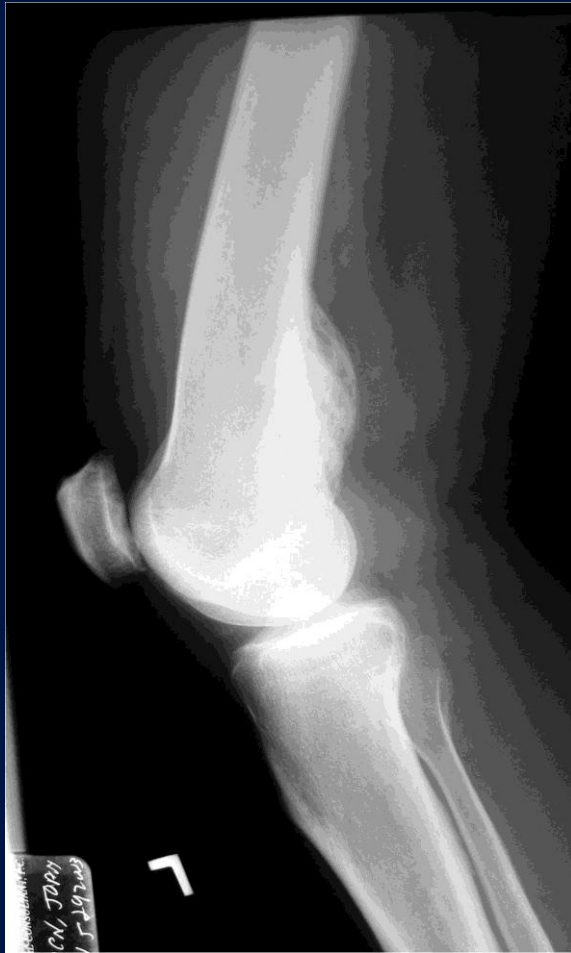

- Horrible prognosis
- Despite chemotherapy, aggressive surgery, reported mean survival of 12 months

# Osteosarcomatosis



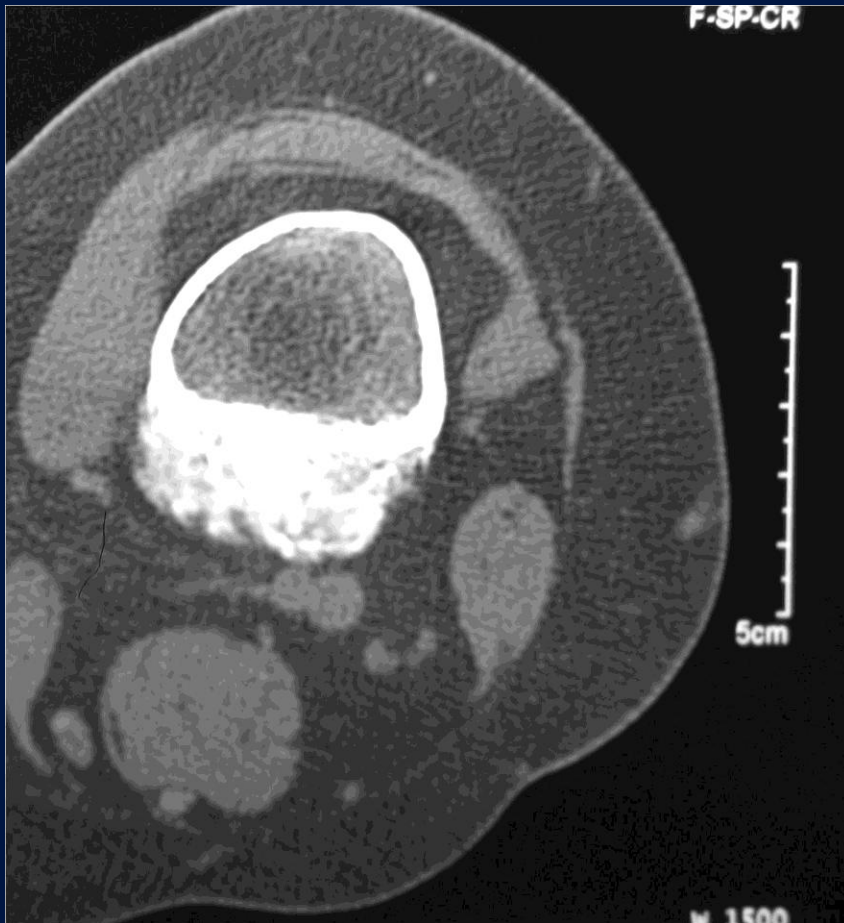
# Surface osteosarcoma: Parosteal OGS



- 65% of all juxtacortical osteosarcomas
- 3<sup>rd</sup>-4<sup>th</sup> decades of life
- Slight female predominance
- 80-90% long-term survival
- Presents as palpable mass

Courtesy, George Nomikos

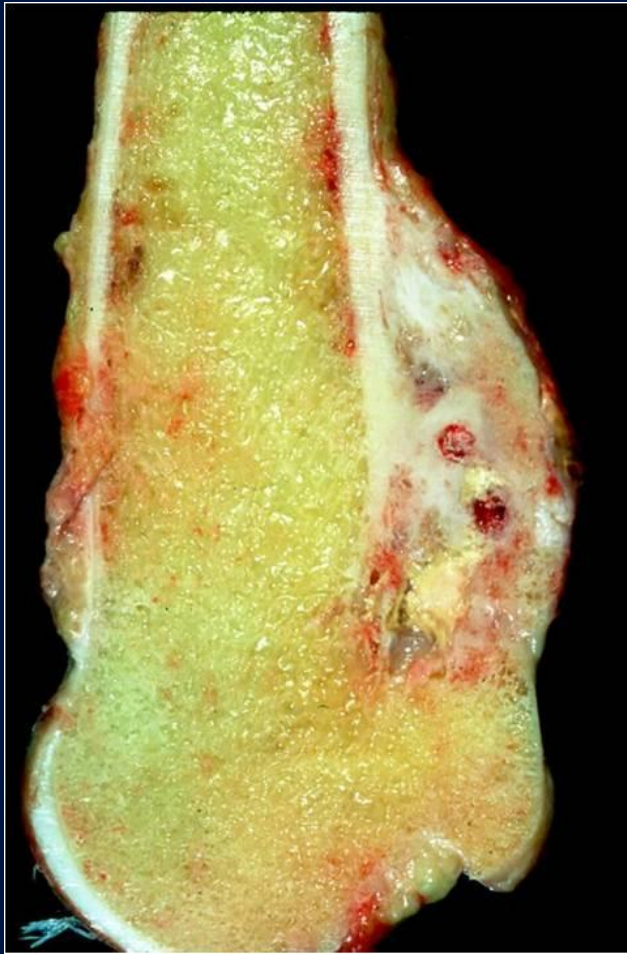# Parosteal OGS



- Metaphyseal (80-90%)
- Post distal femur (50-65%)
- Arise f/ outer layer of periosteum
- Exophytic sclerotic mass

Courtesy, George Nomikos

# Parosteal OGS

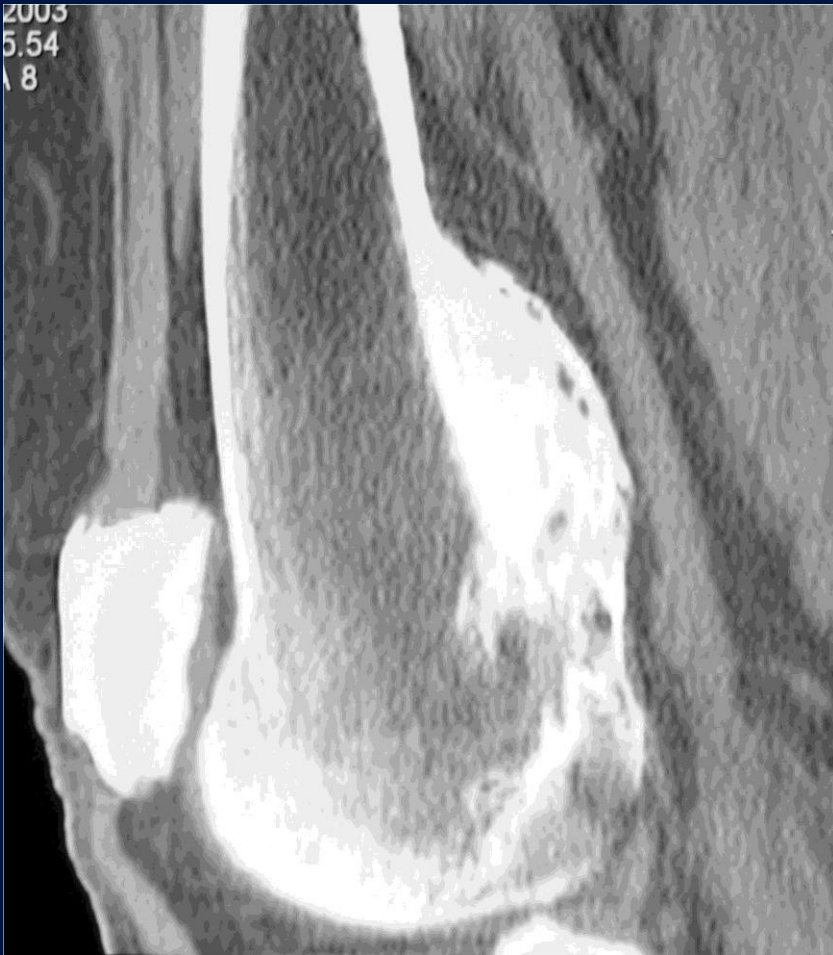

- Large, lobulated, ossific, juxtacortical mass
- “Cauliflower-like”
- Excellent px
  - Surgical resection
  - No neoadjuvant chemotx or XRT

Courtesy, George Nomikos



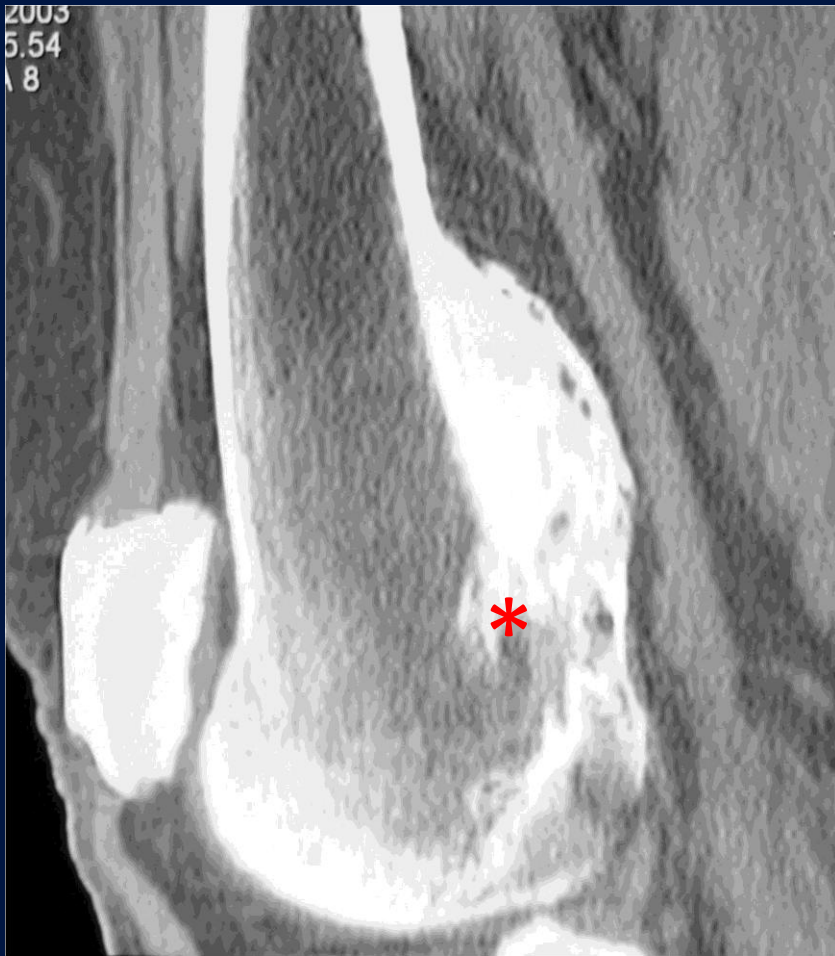# Parosteal OGS



- CT & MR
- Important for planning surgical resection
  - Show ST-extent
  - Determine if medullary involvement
  - Look for lucent cleavage plane

Courtesy, George Nomikos

# Parosteal OGS



- Determine medullary involvement (\*)
  - Deep medullary invasion may require limb salvage
  - Joint replacement if involved

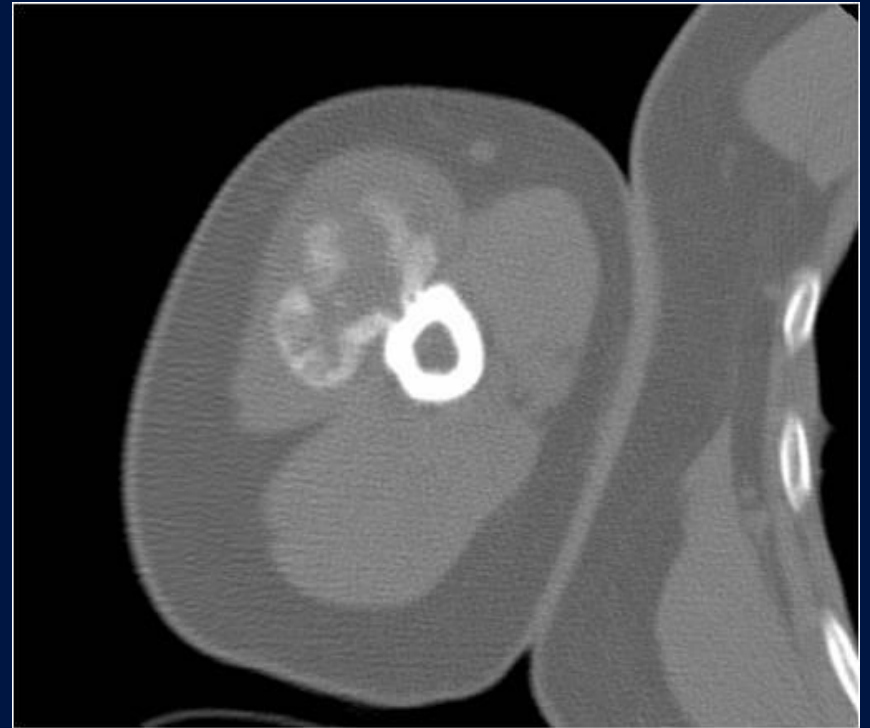
Courtesy, George Nomikos



# Parosteal OGS Mimic = Myositis Ossificans

---

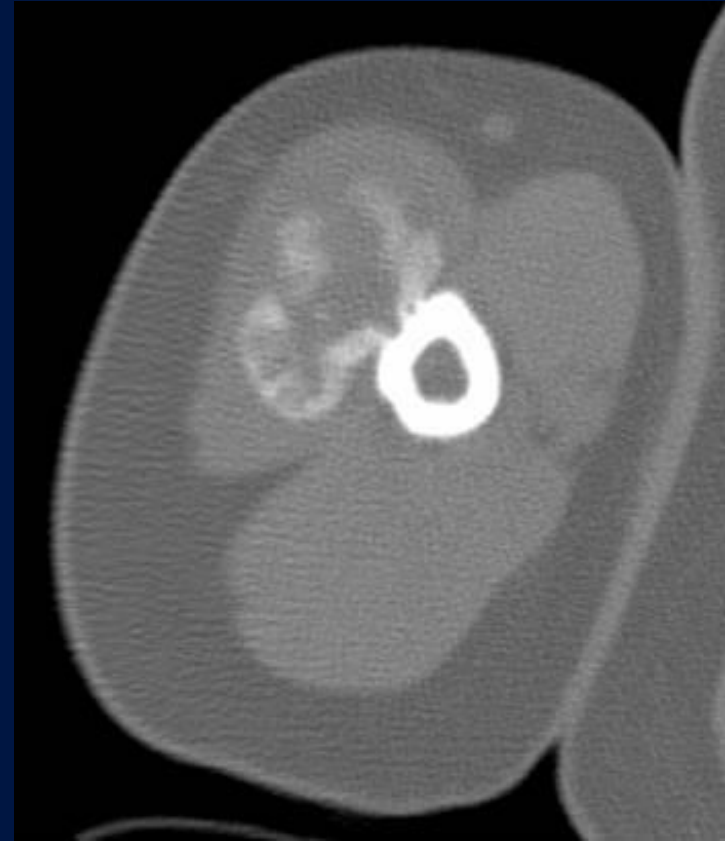
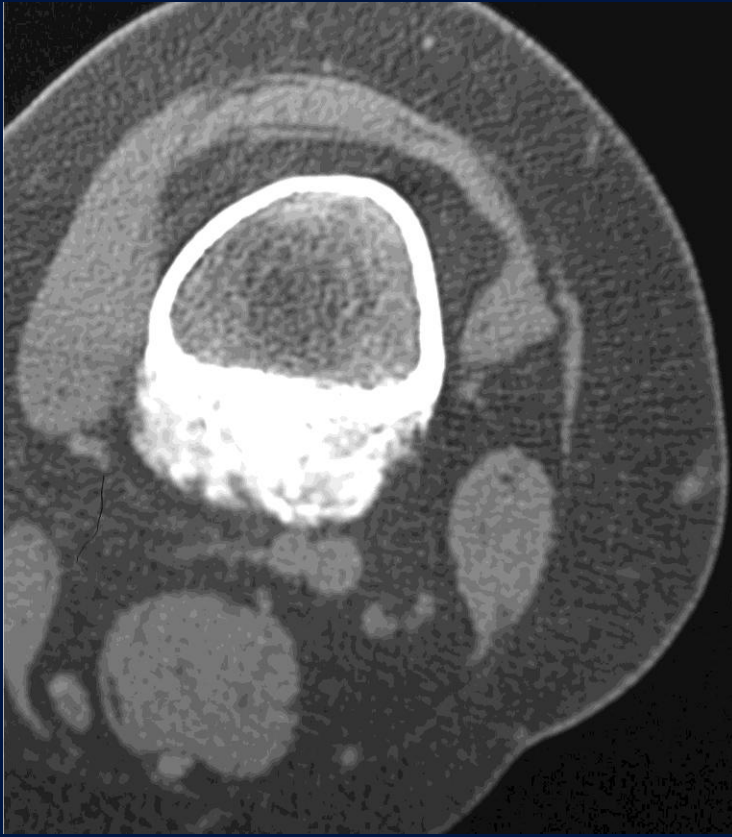- More dense peripherally
- Usually not attached to cortex



Courtesy, George Nomikos

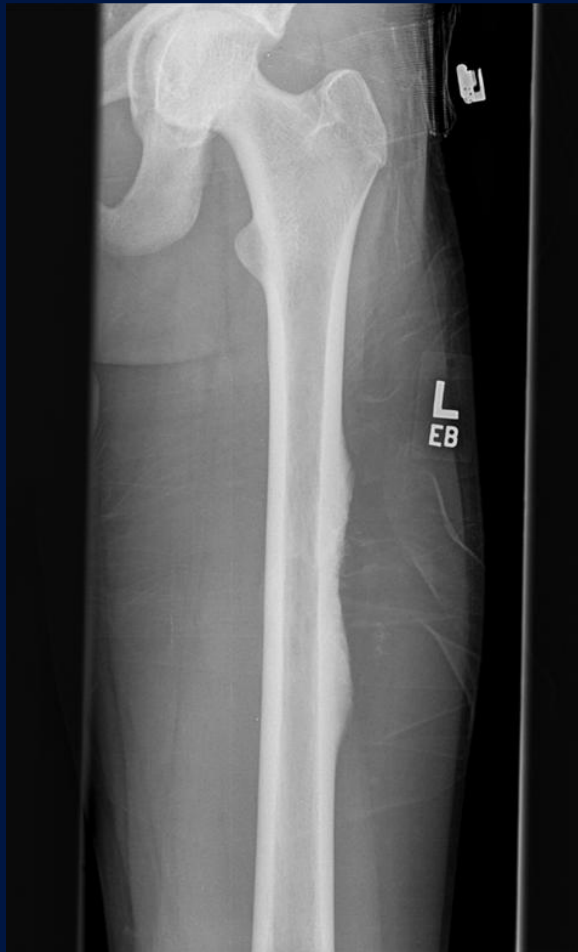# Parosteal OGS Mimic = Myositis Ossificans

---



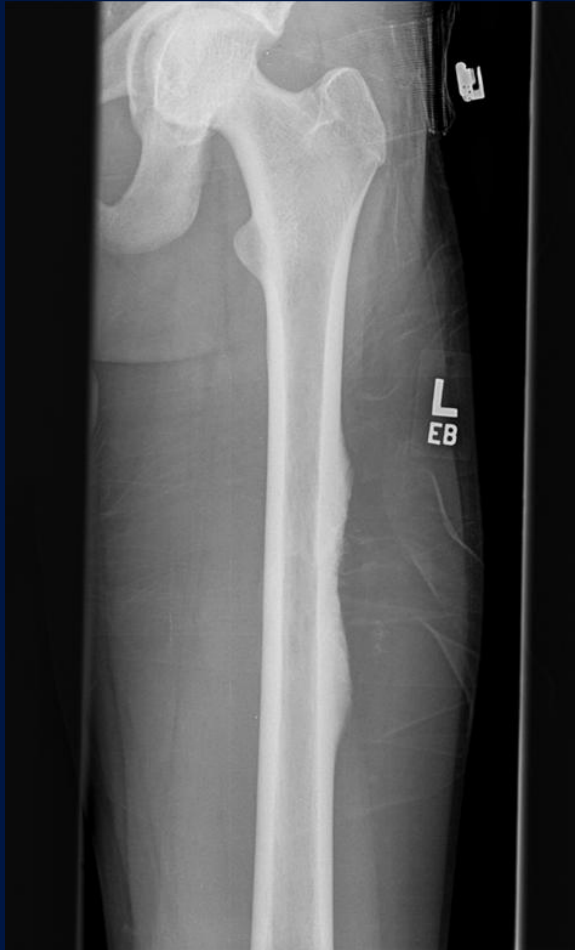Courtesy, George Nomikos

# Periosteal OGS



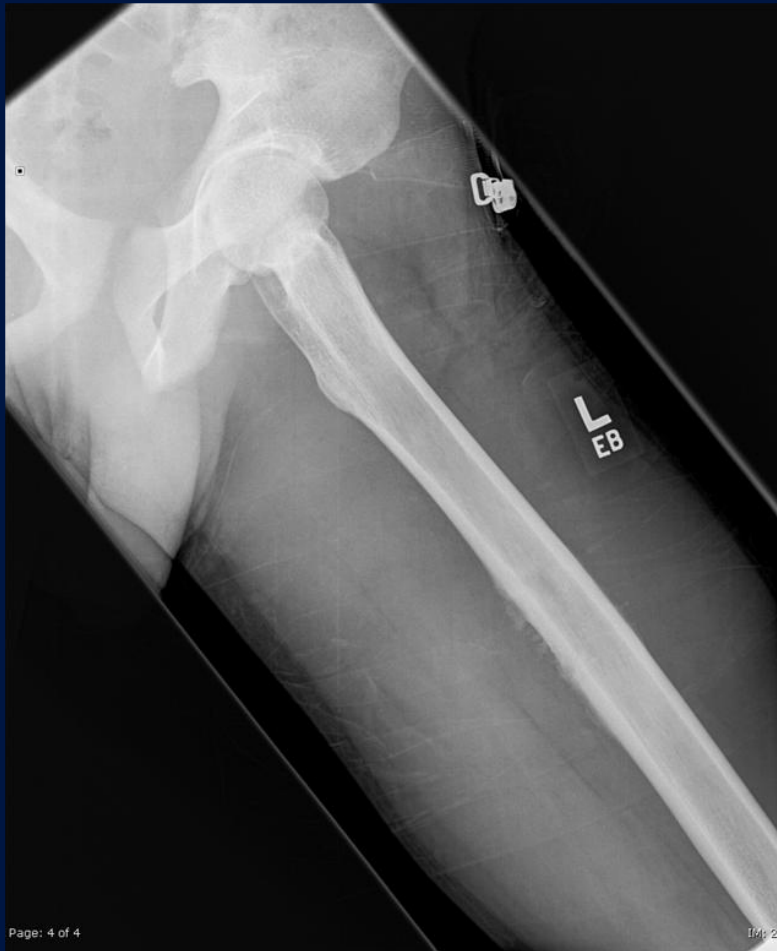- 25% of all juxtacortical osteosarcomas
- 2<sup>nd</sup> – 3<sup>rd</sup> decades, M>F
- Diaphyseal or metadiaphyseal
- Femur & tibia >> ulna & humerus
- Arise f/ deep layer of periosteum
- Cortical thickening, scalloping, w/o intramedullary invasion
- 55-83% long-term survival

# Periosteal OGS



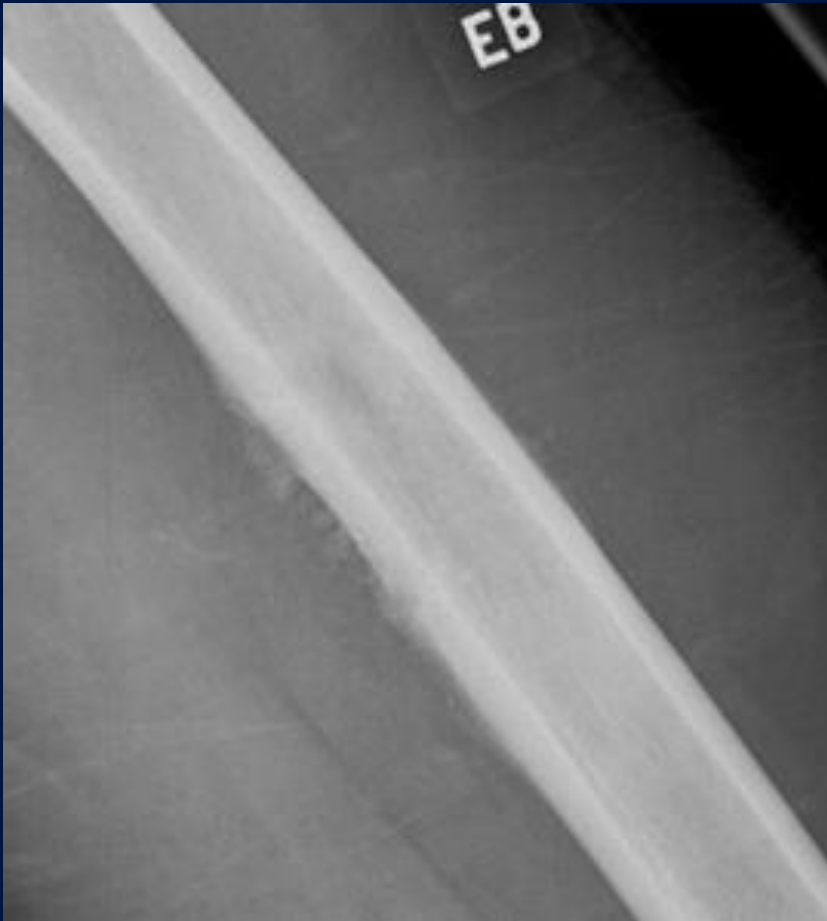- Broad-based surface ST mass
- Causes scalloping of thickened underlying cortex, w/o intramedullary invasion
- Periosteal rxn – perpendicular to bone length axis

# Periosteal OGS



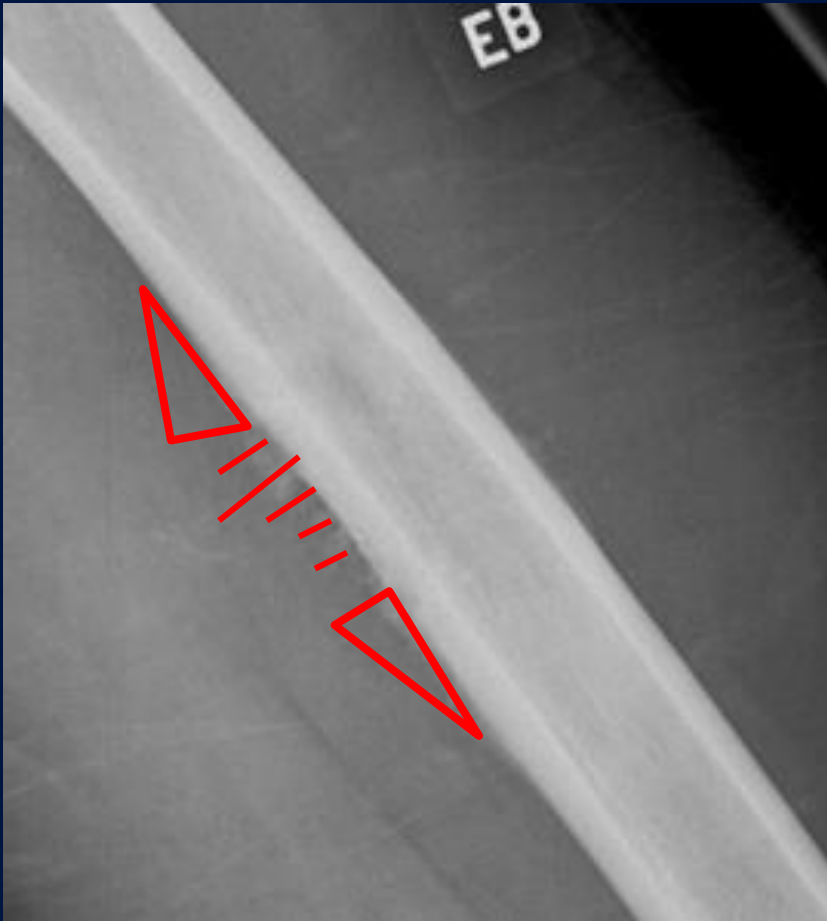- Perpendicular periosteal rxn into a broad-based ST mass
- Codman's triangles at sup & inf margins of the lesion

# Periosteal OGS



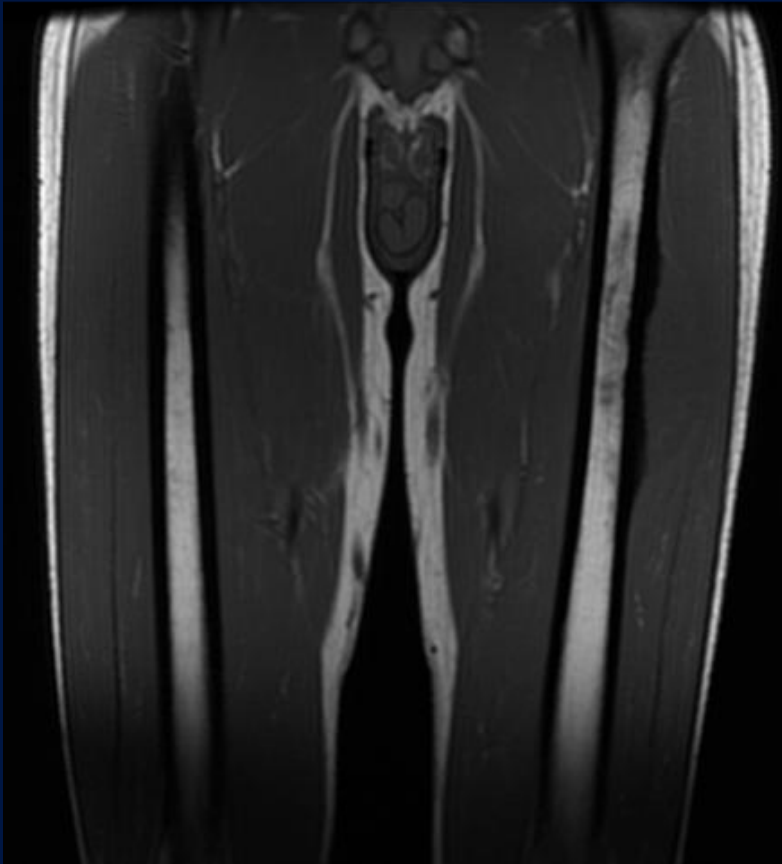- Perpendicular periosteal rxn into a broad-based ST mass
- Codman's triangles at sup & inf margins of the lesion

# Periosteal OGS



- Perpendicular periosteal rxn into a broad-based ST mass
- Codman's triangles at sup & inf margins of the lesion

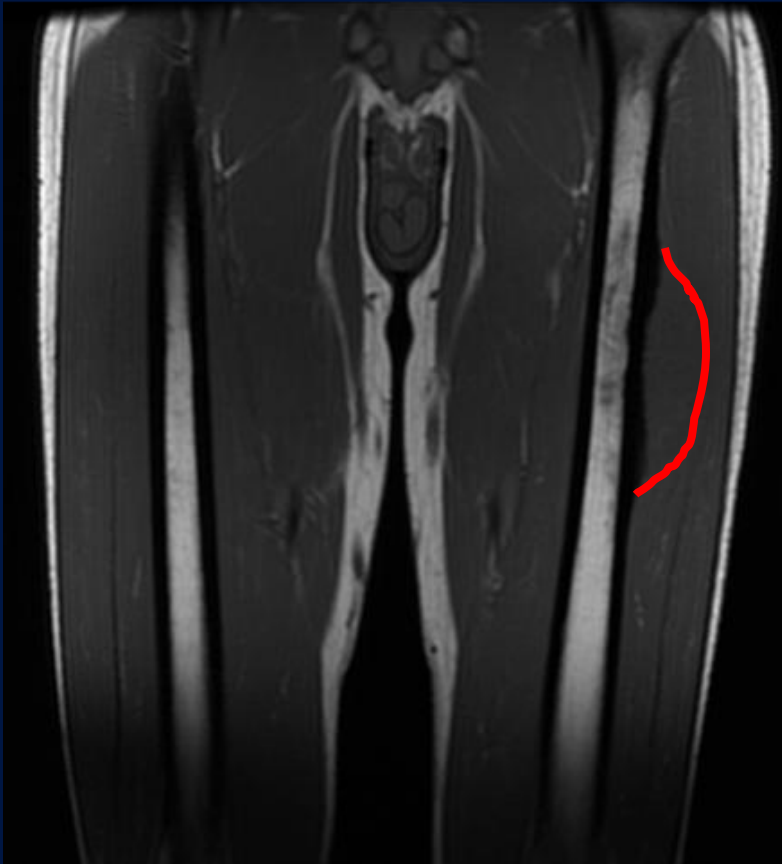# Periosteal OGS



- ST mass of intermed T1 SI
- Erodes thick cortex extrinsically

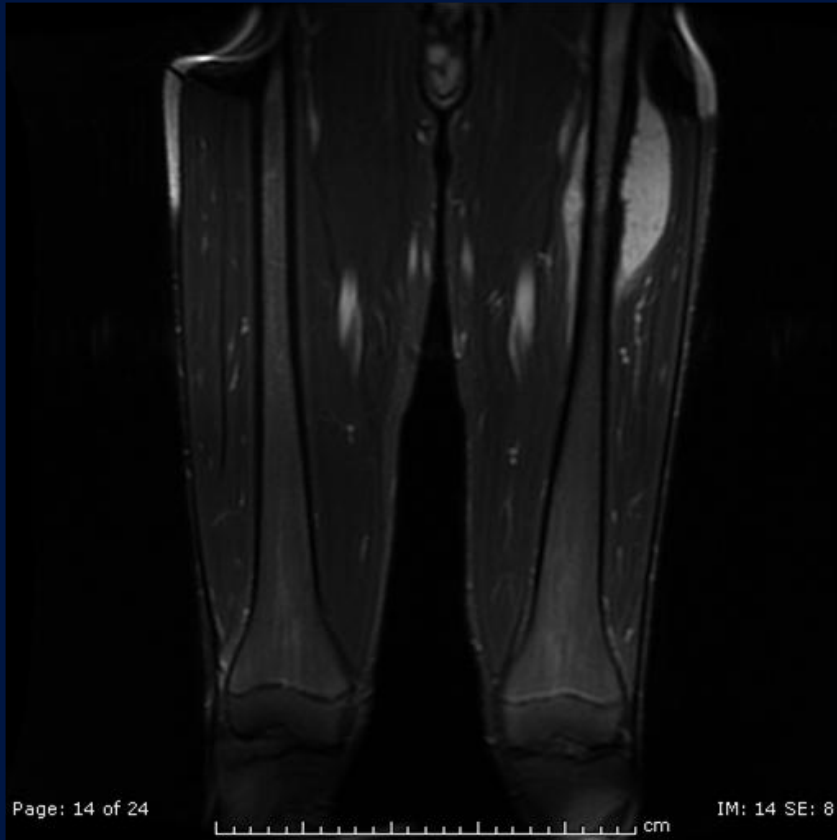


# Periosteal OGS



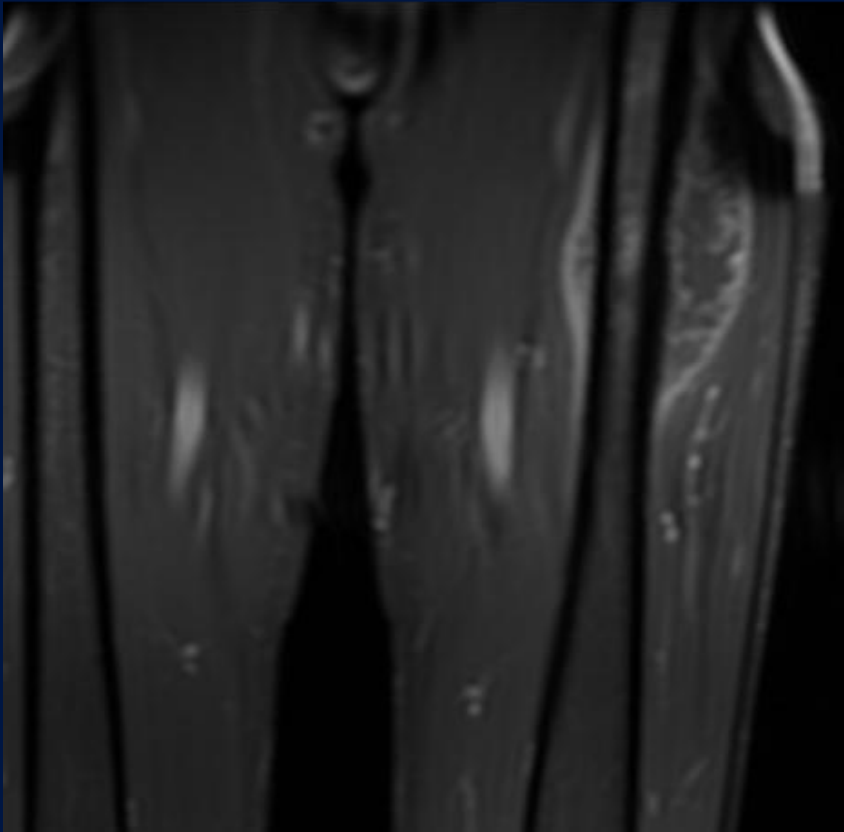
- ST mass of intermed T1 SI
- Erodes thick cortex extrinsically

# Periosteal OGS



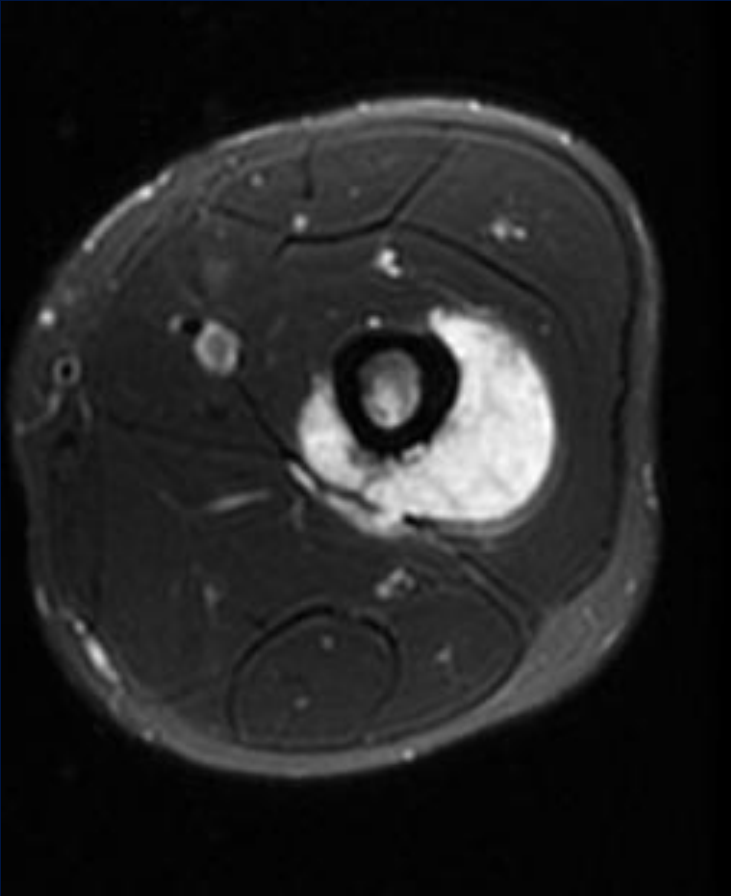
- Fluid sensitive sequence better shows the ST mass
- \*Important to note high water content of ST mass reflects **cartilage** component
  - Biopsy of ST mass may lead to mis-dx of a **chondrosarcoma**
  - Substantial tx implications (no chemotx for chondrosarc, but would for osarc)
  - (Murphey Rad 2004)

# Periosteal OGS



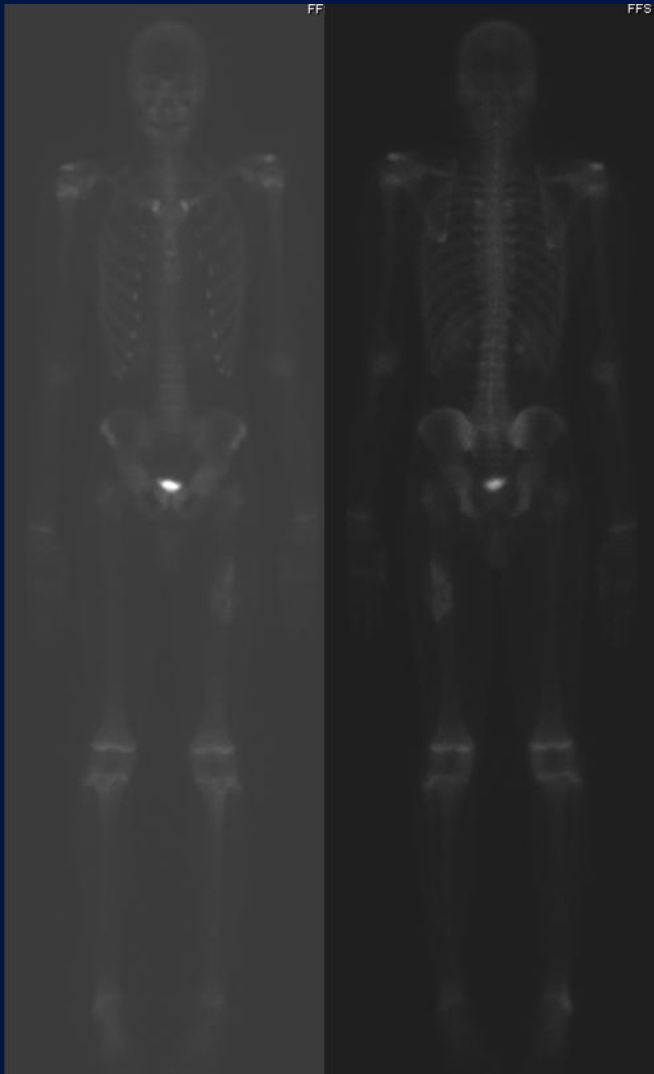
- Enhancing ST mass

# Periosteal OGS



- Axial fluid sensitive images show well-defined ST mass of approximately 75% cortical circumference
- Rays of low SI = periosteal rxn
- Small foci in marrow of high SI are not continuous with ST mass (reactive marrow)

# Periosteal OGS

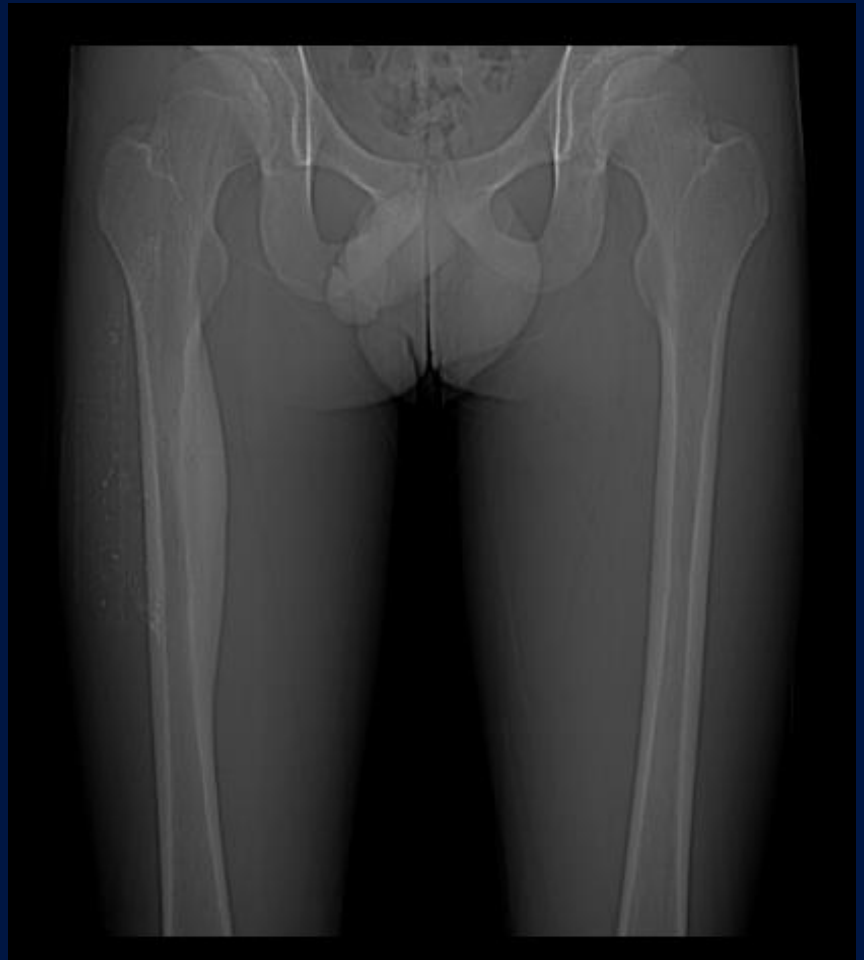


- Bone scan
- Marked, eccentric radionuclide uptake
- No other lesions, good px

# Other lesions that involve the cortex...

---

- Osteoid osteoma
- LCH
- FCD/NOF
- Infn

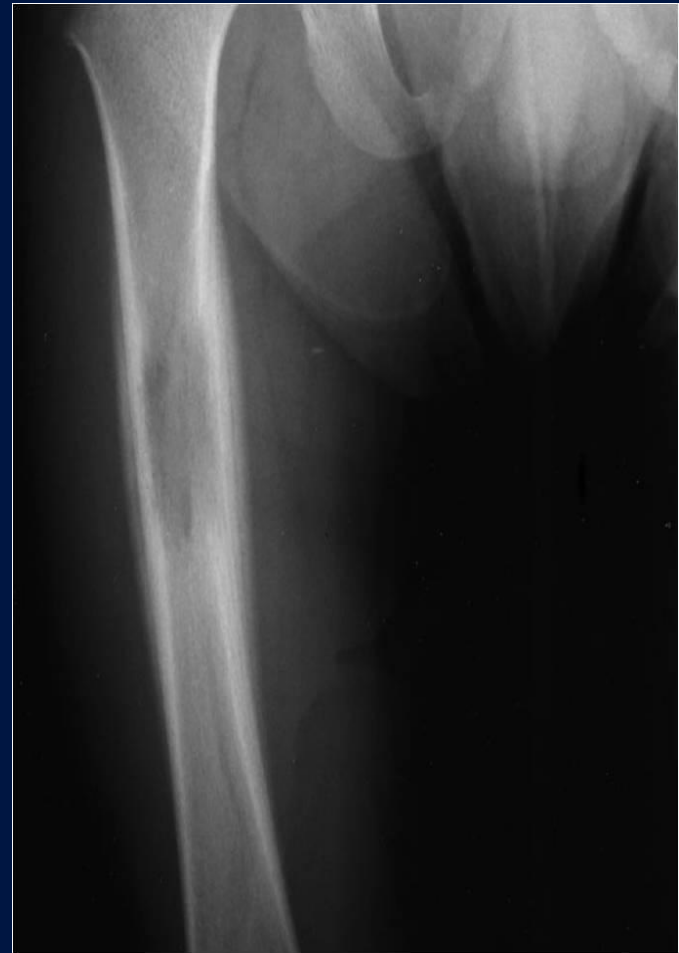

Case from CVI, 2/18/2011 UCSD Teleradiology

# Ddx of Cortical Lesions

---

- Osteiod osteoma
- LCH
- FCD/NOF
- Infn

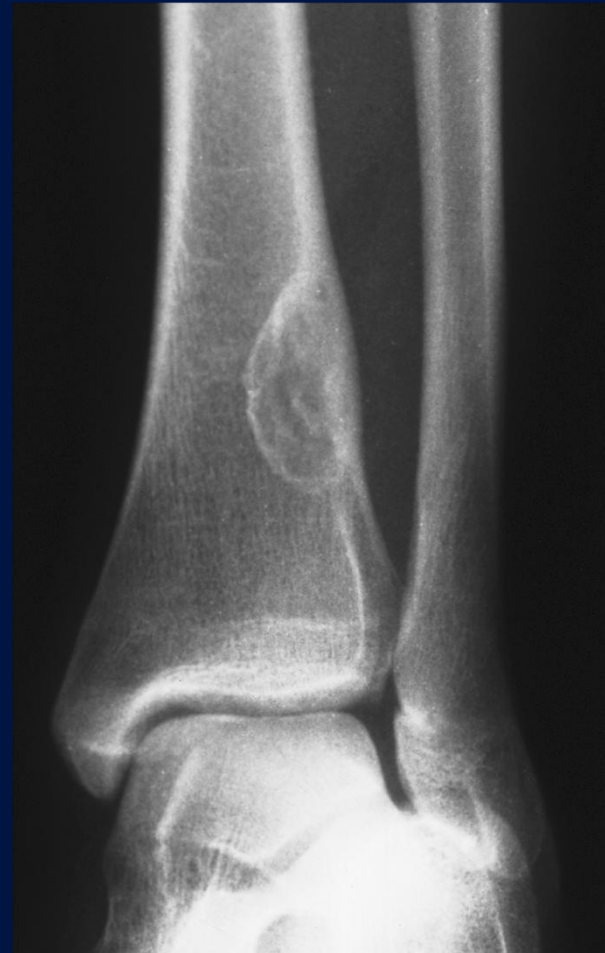

Courtesy, George Nomikos

# Ddx of Cortical Lesions

---

- Osteiod osteoma
- LCH
- FCD/NOF
- Infn



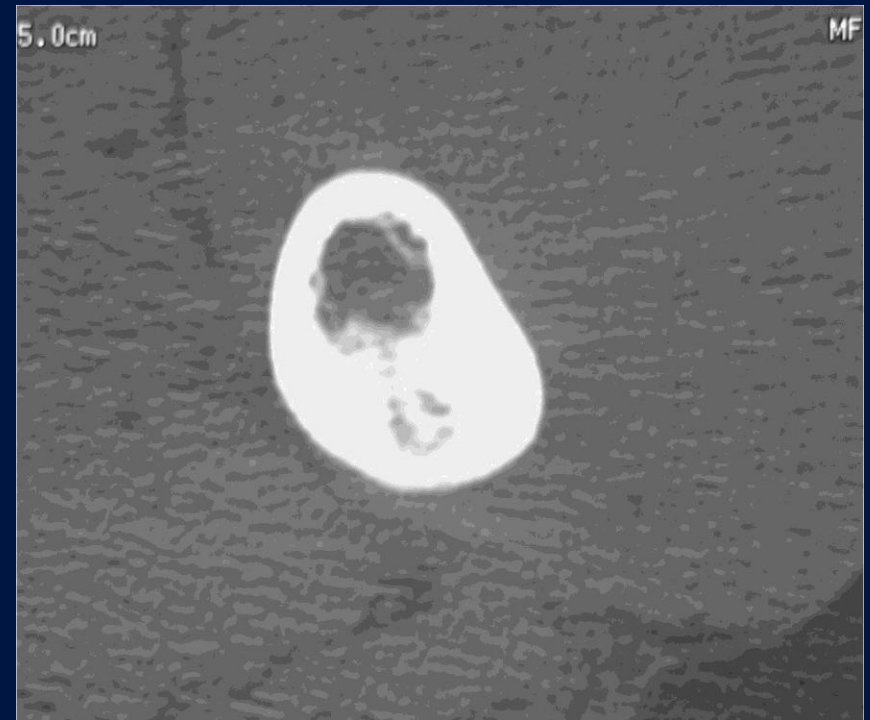Courtesy, George Nomikos



# Ddx of Cortical Lesions

---

- Osteiod osteoma
- LCH
- FCD/NOF
- Infn

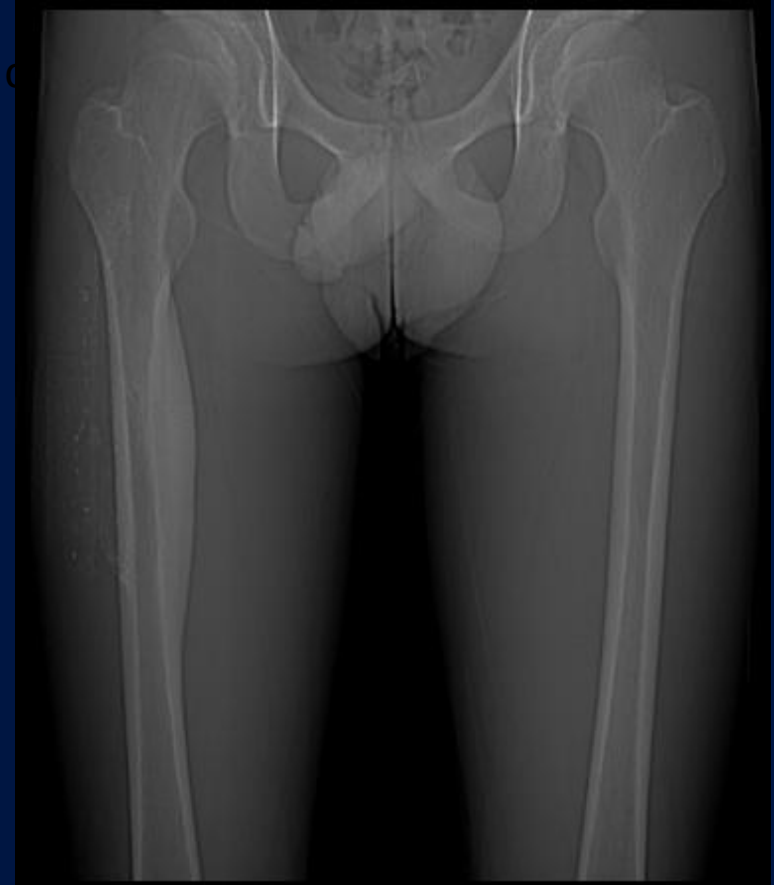

Courtesy, George Nomikos

# Osteoid Osteoma: look closely for the **nidus**

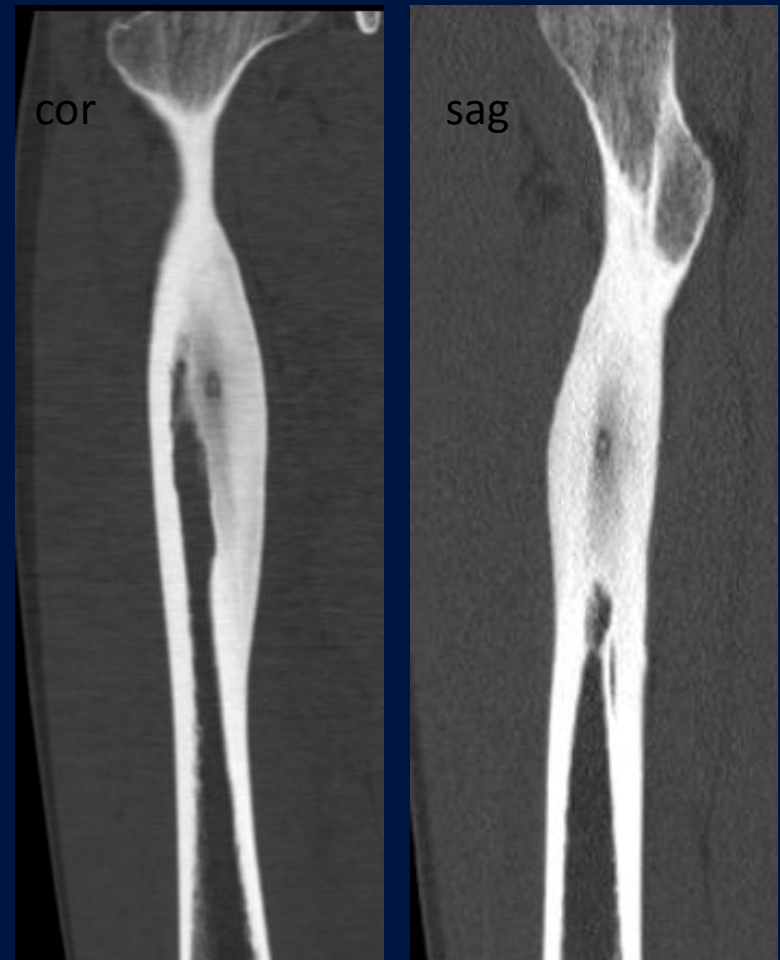---

- Benign
- Nidus consists of bone in various stages of maturity
- Has highly vascular stroma of connective tissue w/ many dilated capillaries



# Osteoid Osteoma: nidus

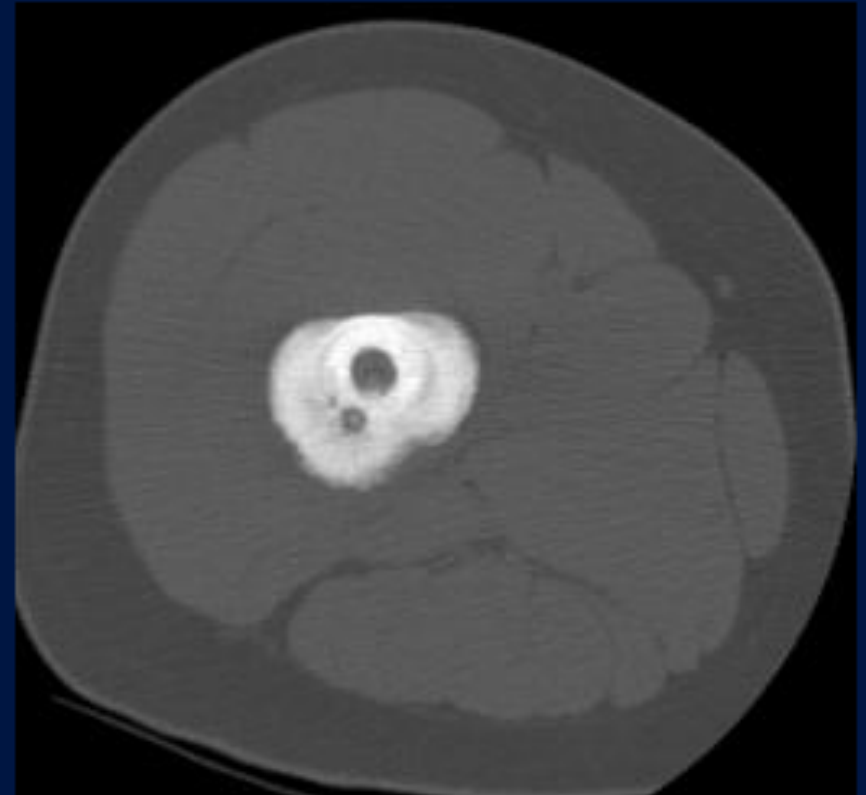
- Osteoid w/in nidus will calcify
  - Associated with irregular trabeculae of woven bone
- Nidus is surrounded by compact lamellar bone made by the periosteum



# Evidence of the Subperiosteal Origin of Osteoid Osteomas in Tubular Bones: Analysis by CT and MR Imaging

Francoise Kayser<sup>1</sup>  
Donald Resnick<sup>1</sup> ←  
Parviz Haghighi<sup>1</sup>  
Elke Do Rosario Husch Pereira<sup>1</sup>  
Guerdon Greenway<sup>2</sup>  
Mark Schweitzer<sup>3</sup>  
Philippe Kindynis<sup>4</sup>

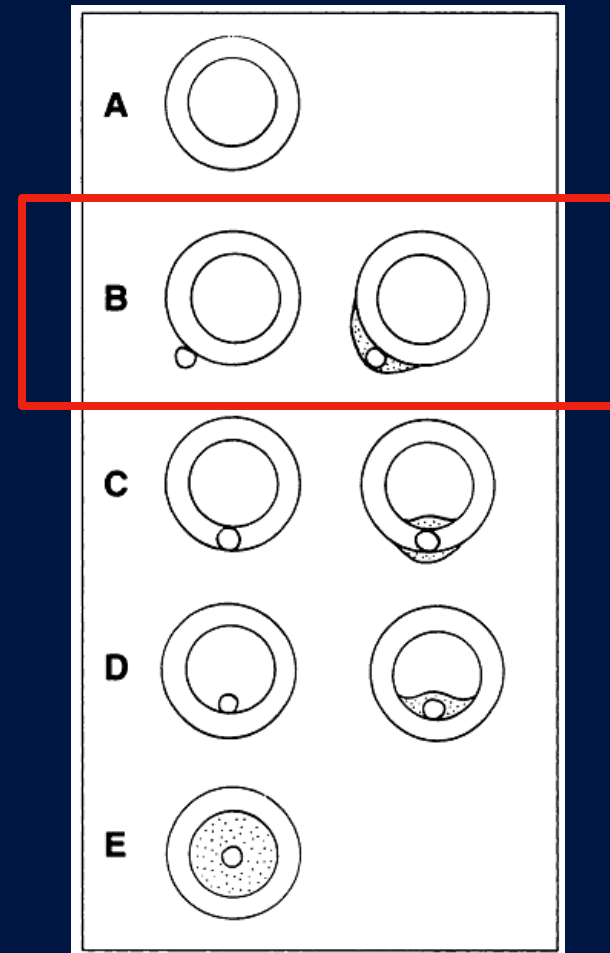
- Reviewed 38 path-proven cases of OO
  - Femur (13), tibia (15), humerus (4)
  - Determined location of nidus center of OO
  - Subperiosteal (18), Intracortical (18), endosteal (0), intramedullary (2)



Courtesy, George Nomikos

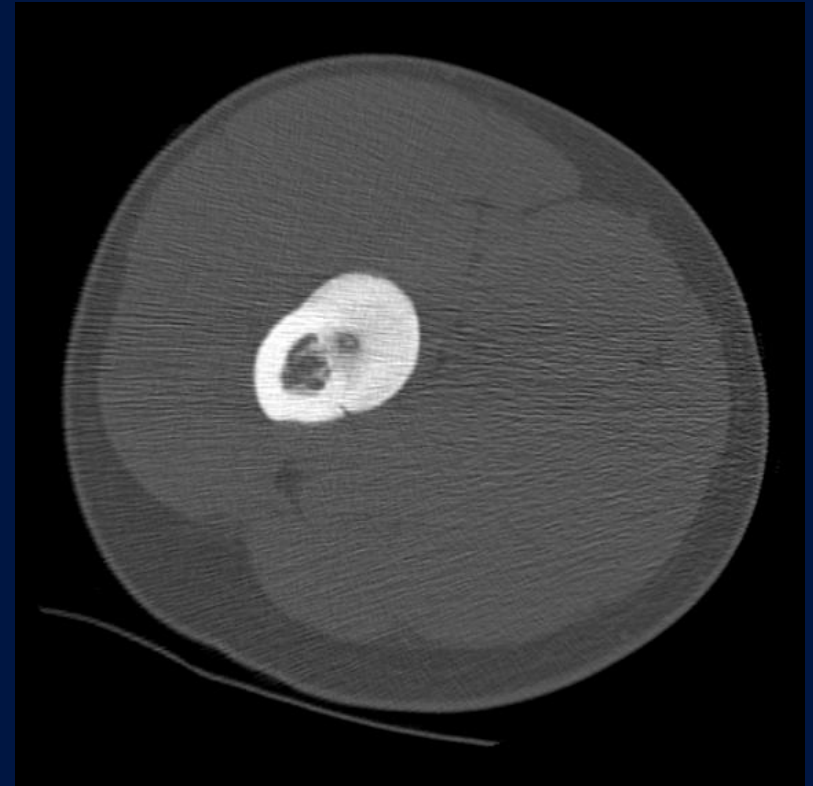# Evidence of the Subperiosteal Origin of Osteoid Osteomas in Tubular Bones: Analysis by CT and MR Imaging

- Proposed that osteoid osteoma arises in a surface location (subperiosteal)
- Inward migration of the nidus (intracortical, endosteal, intramedullary)



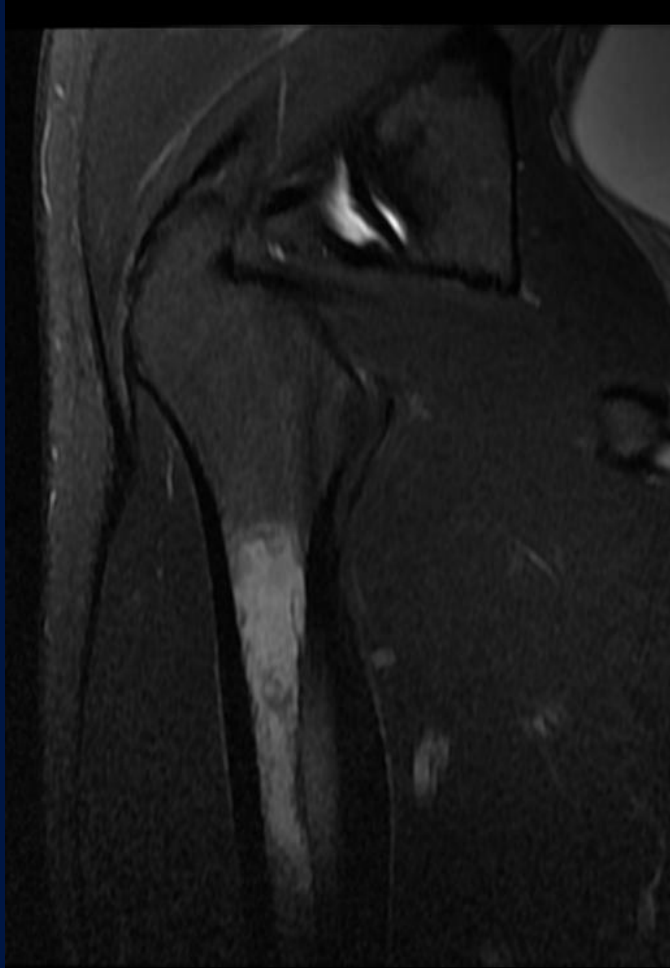
# Evidence of the Subperiosteal Origin of Osteoid Osteomas in Tubular Bones: Analysis by CT and MR Imaging

- Continuous remodeling of bone with subperiosteal deposition, endosteal erosion, & cortical drift
- Cortical drift phenomena of immature bone
  - Bone develops in response to mechanical load, to fracture healing, etc.



# Osteoid Osteoma: extensive marrow edema

---



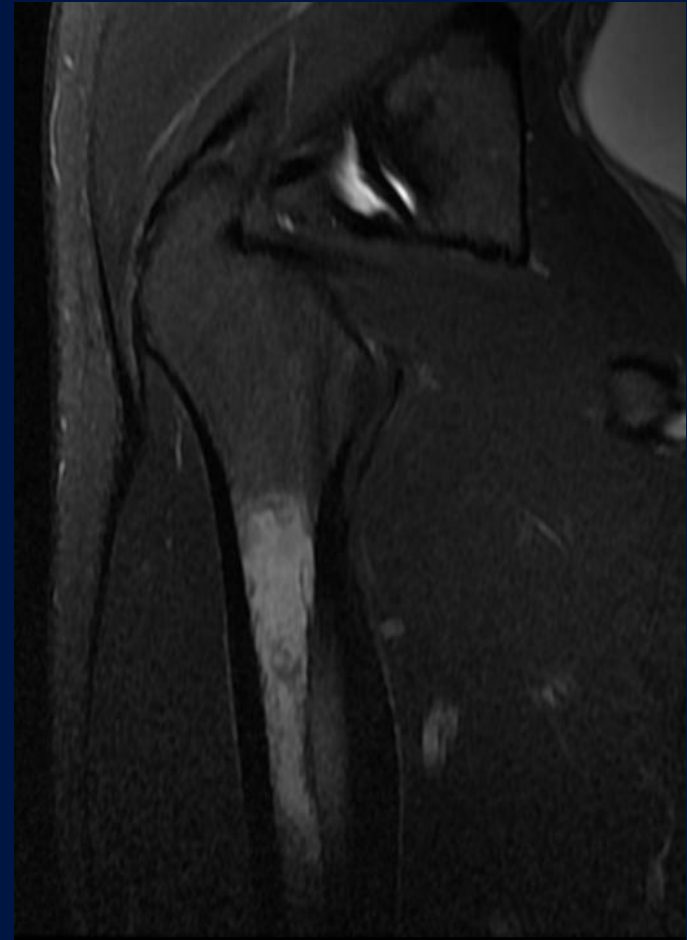
- CVI case was an arthrogram
- Wider FOV coronal fluid sensitive seq showed marrow edema
- Patient brought back for CT with suspicion of OO

Case from CVI, 2/14/2011 UCSD Teleradiology

# Ddx of lesions causing extensive marrow edema

---

- Osteoid osteoma
- Chondroblastoma
- Osteoblastoma
- LCH
- Brodie's abscess

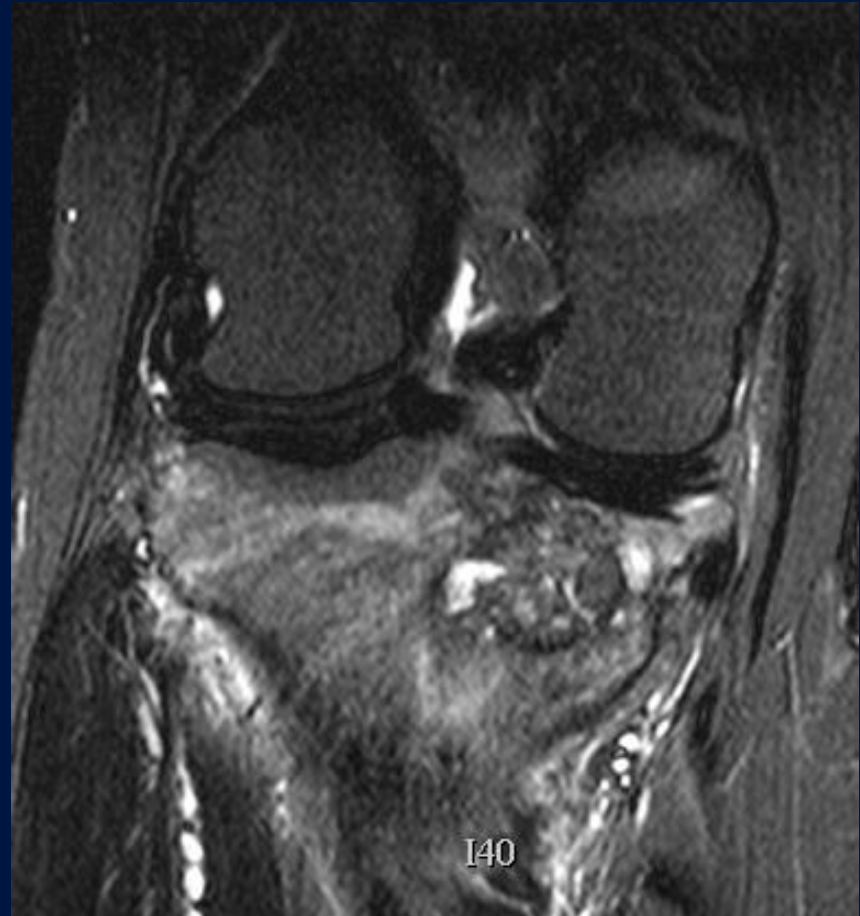




# Ddx of lesions causing extensive marrow edema

---

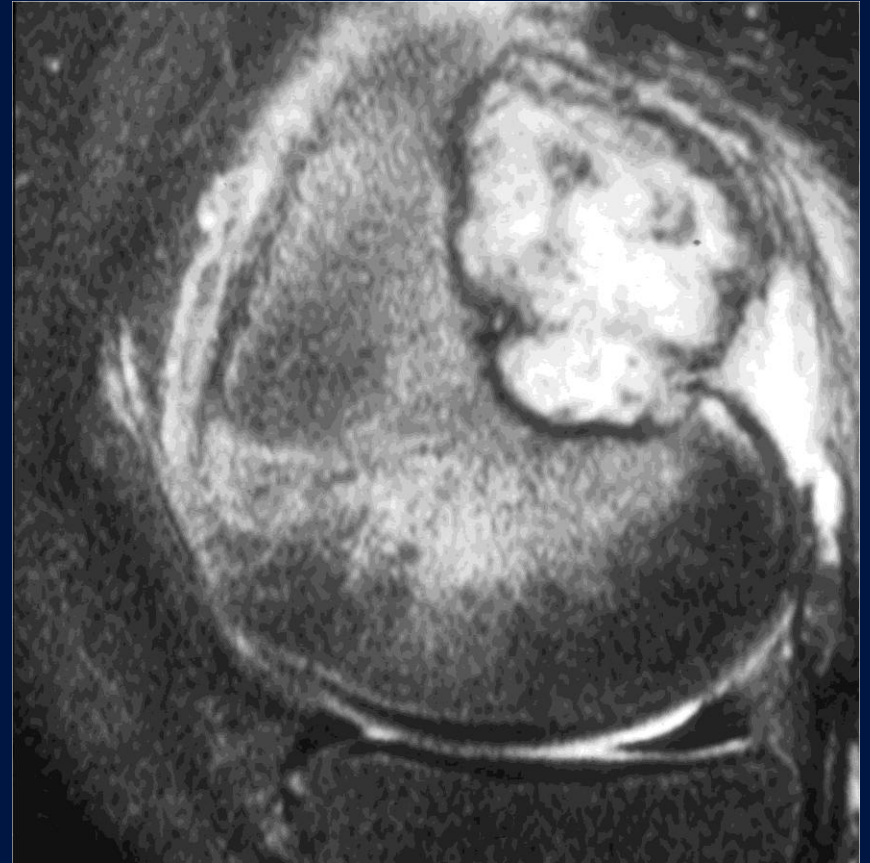- Osteoid osteoma
- Chondroblastoma
- Osteoblastoma
- LCH
- Brodie's abscess



# Ddx of lesions causing extensive marrow edema

---

- Osteoid osteoma
- Chondroblastoma
- Osteoblastoma
- LCH
- Brodie's abscess

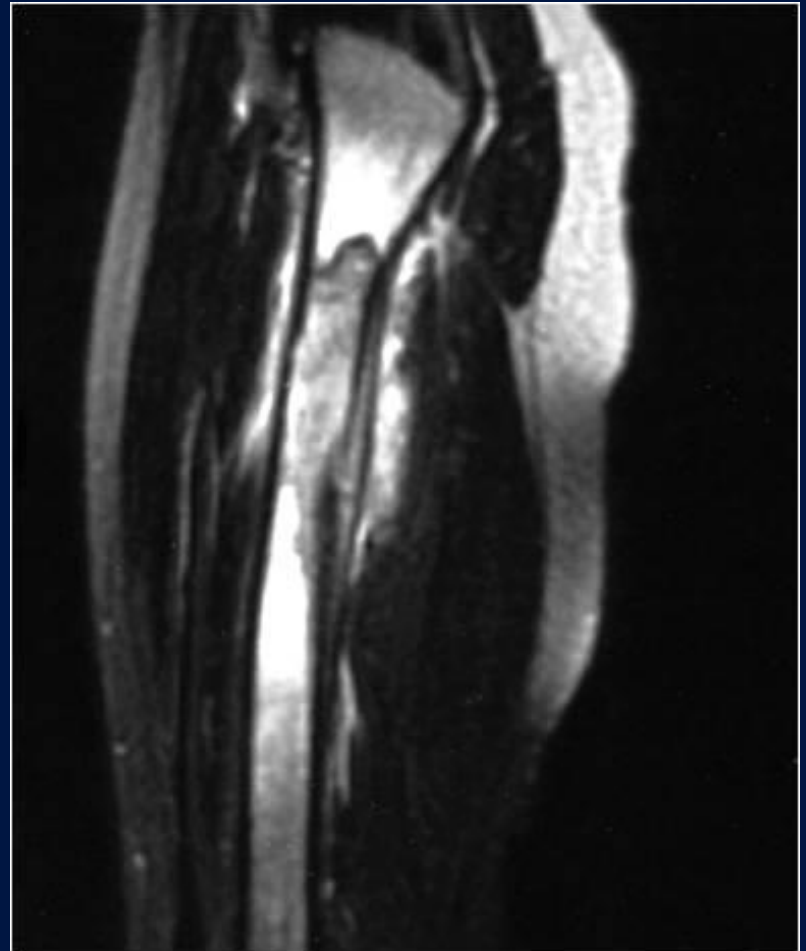


Courtesy, George Nomikos

# Ddx of lesions causing extensive marrow edema

---

- Osteoid osteoma
- Chondroblastoma
- Osteoblastoma
- LCH
- Brodie's abscess

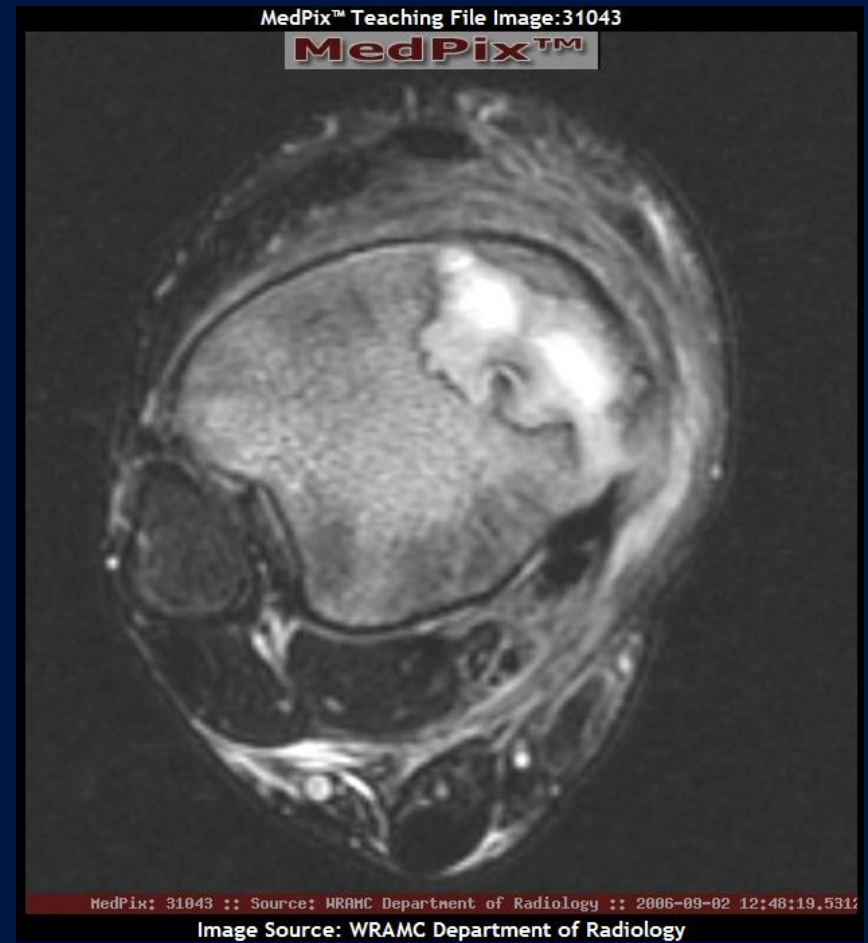


Courtesy, George Nomikos

# Ddx of lesions causing extensive marrow edema

---

- Osteoid osteoma
- Chondroblastoma
- Osteoblastoma
- LCH
- Brodie's abscess



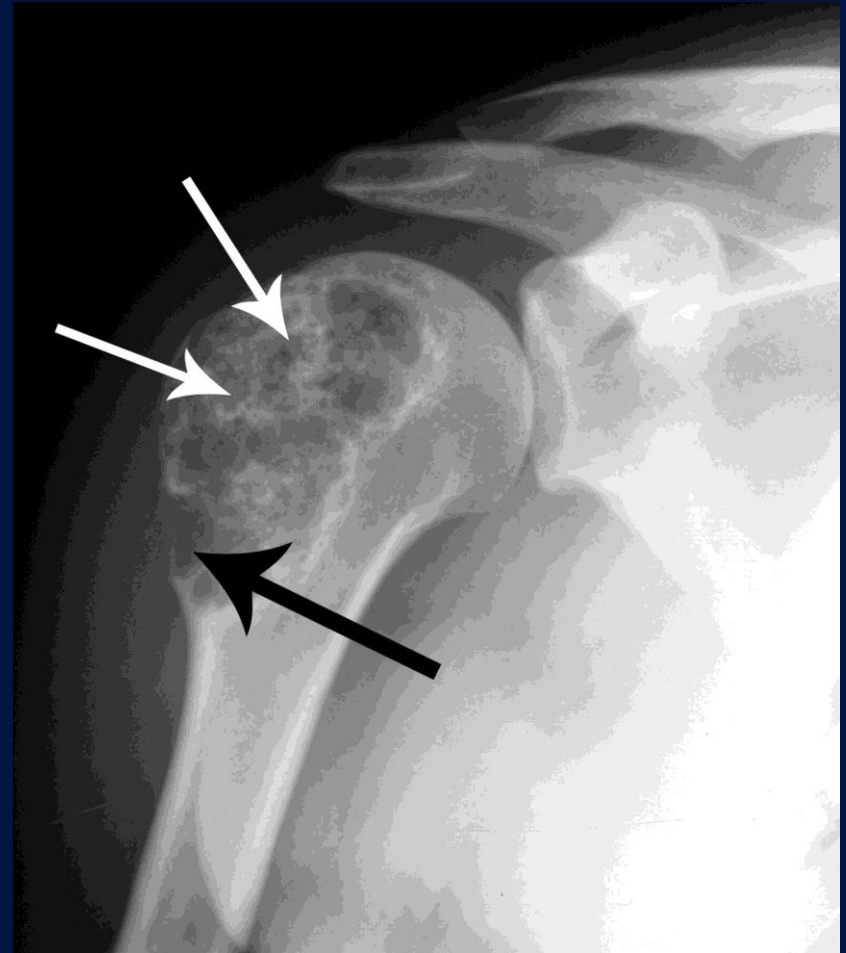
Primary Bone Malignancy

# CHONDROSARCOMA

---

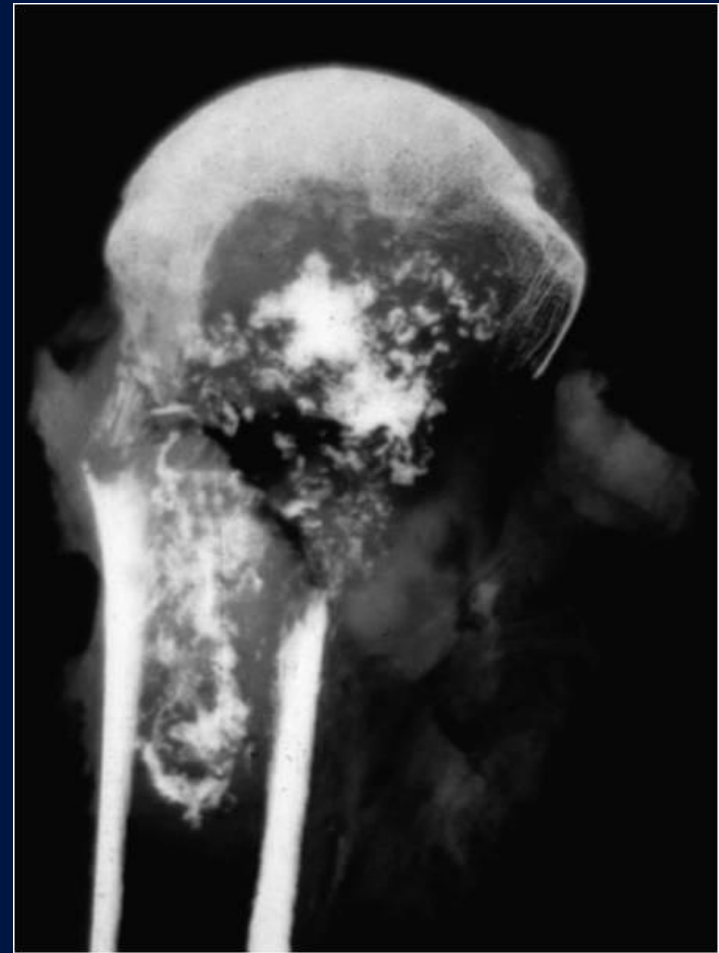# Primary Chondrosarcoma - Epidemiology

- 3<sup>rd</sup> most common primary bone malignancy
  - follows MM & osarc
- 8-17% of all biopsied primary bone tumors
  - Vs. 15% of biopsied primary bone tumors are osteosarcoma
  - (AFIP notes)



# Chondrosarcoma

- Malignancy of **cartilage** cells, often w/ myxoid changes
- “Rings & arcs”
- Deep endosteal scalloping
- Cortical break-through, ST mass
- Pathologic fracture common

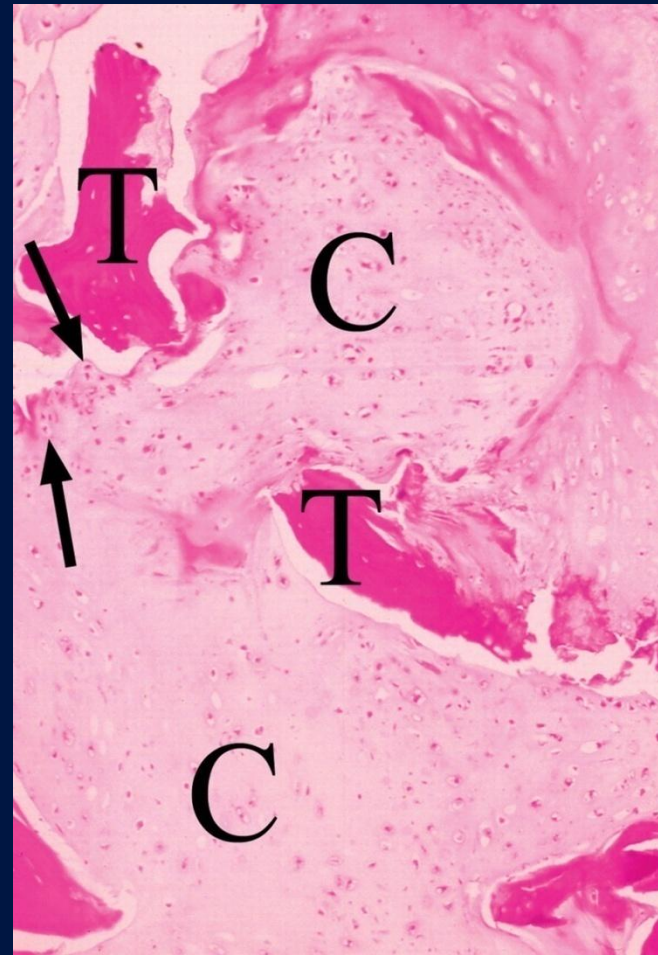


Specimen XR; Courtesy, George Nomikos



# Chondrosarcoma

- Hallmark of dx:
  - Entrapment & destruction of osseous trabeculae (T) by cartilage lobules (C)
  - *“Islands of normal bone within the neoplasm”*
- Higher the grade, more cellular the tumor = less chondroid matrix

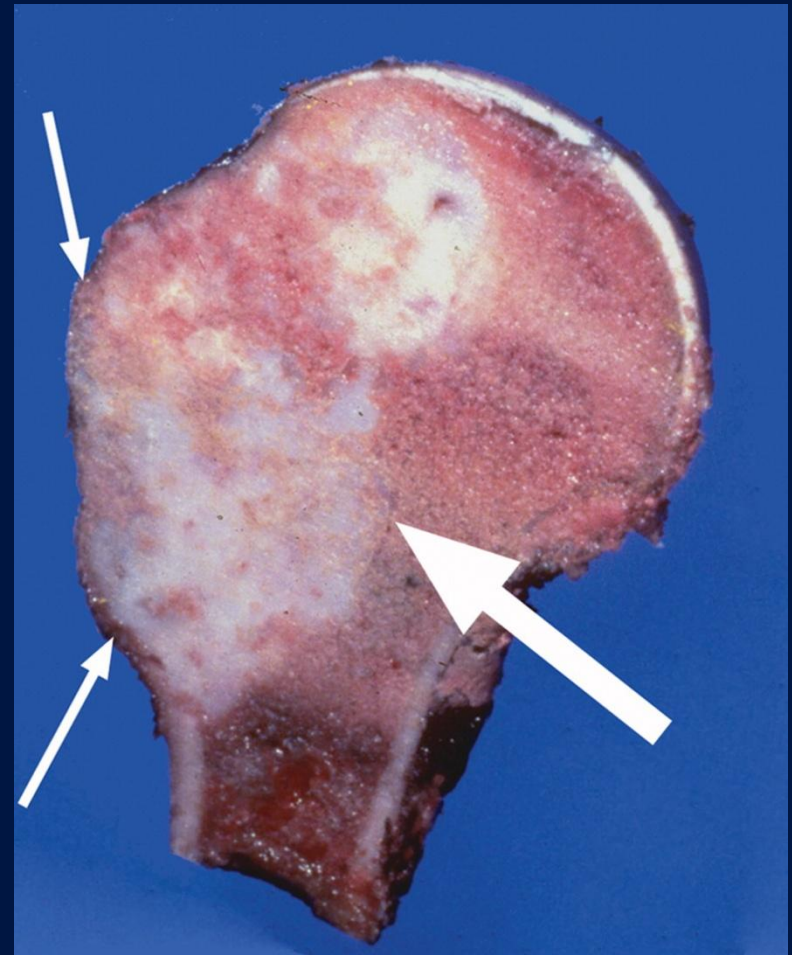


Murphy M D et al. Radiographics 2003;23:1245-1278



# Chondrosarcoma Types

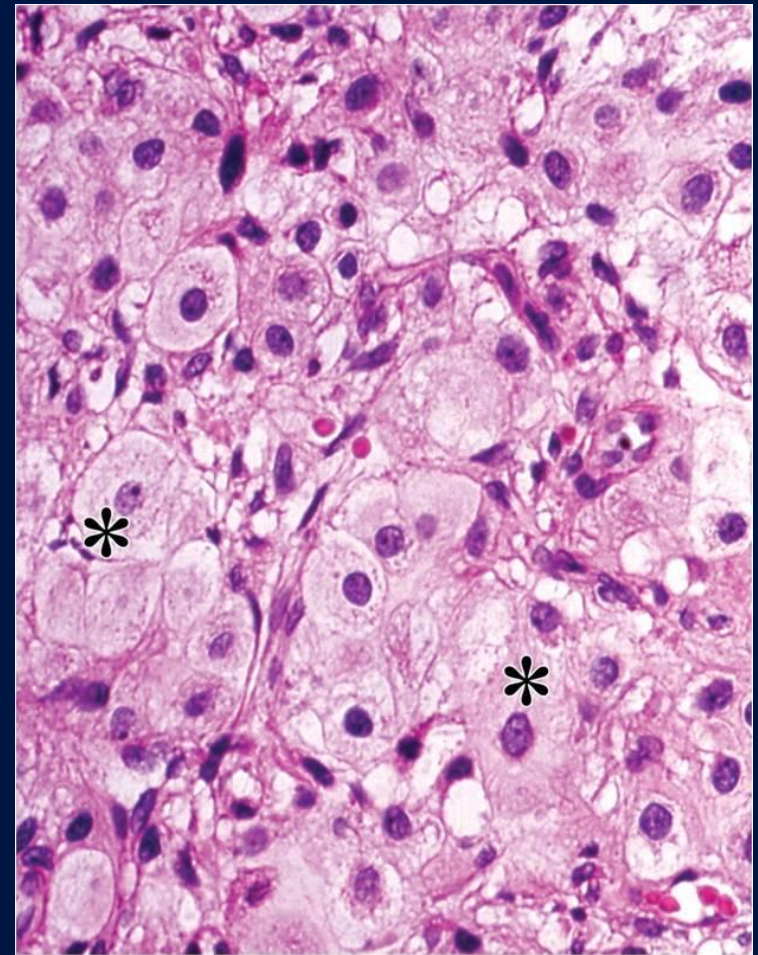
- Primary
- (central or surface)
  - Conventional intramedullary\*
  - Clear cell
  - Juxtacortical
  - Myxoid
  - Mesenchymal
  - Extraskeletal
  - Dedifferentiated\*
- Secondary
  - Enchondroma\*
  - Osteochondroma\*
  - Paget dis
  - XRT-induced



Murphey M D et al. Radiographics 2003;23:1245-1278

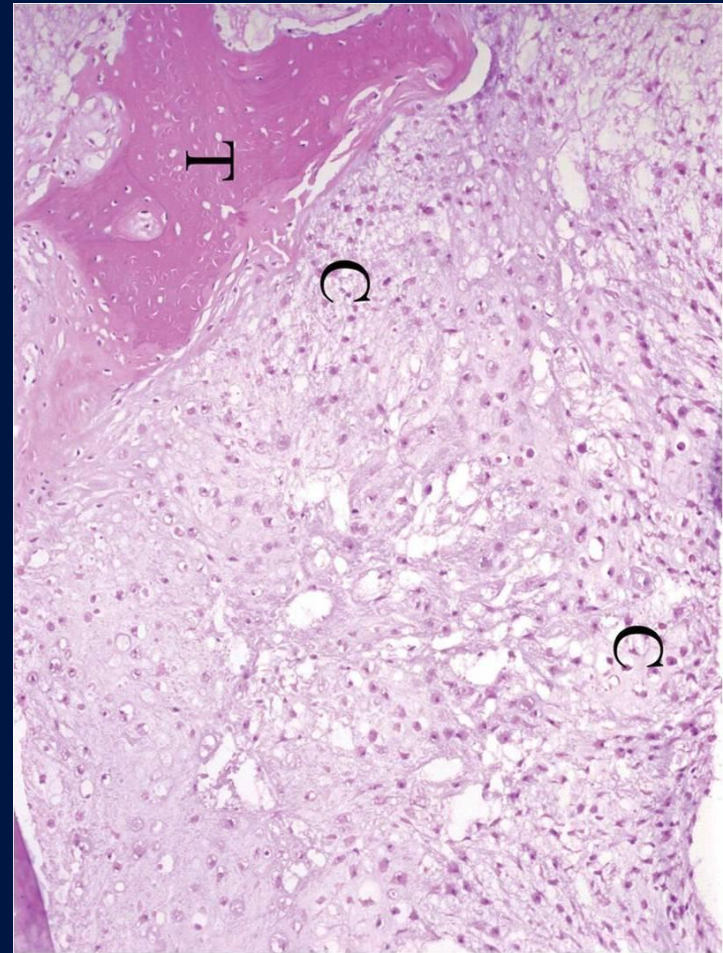
# Chondrosarcoma – Grading System

- Grade 1 – low
  - Clear cell (\*high glycogen)
- Grade 2 – intermediate
- Grade 3 - high



# Chondrosarcoma – Grading System

- Grade 1 – low
- Grade 2 – intermediate
  - Myxoid
- Grade 3 - high

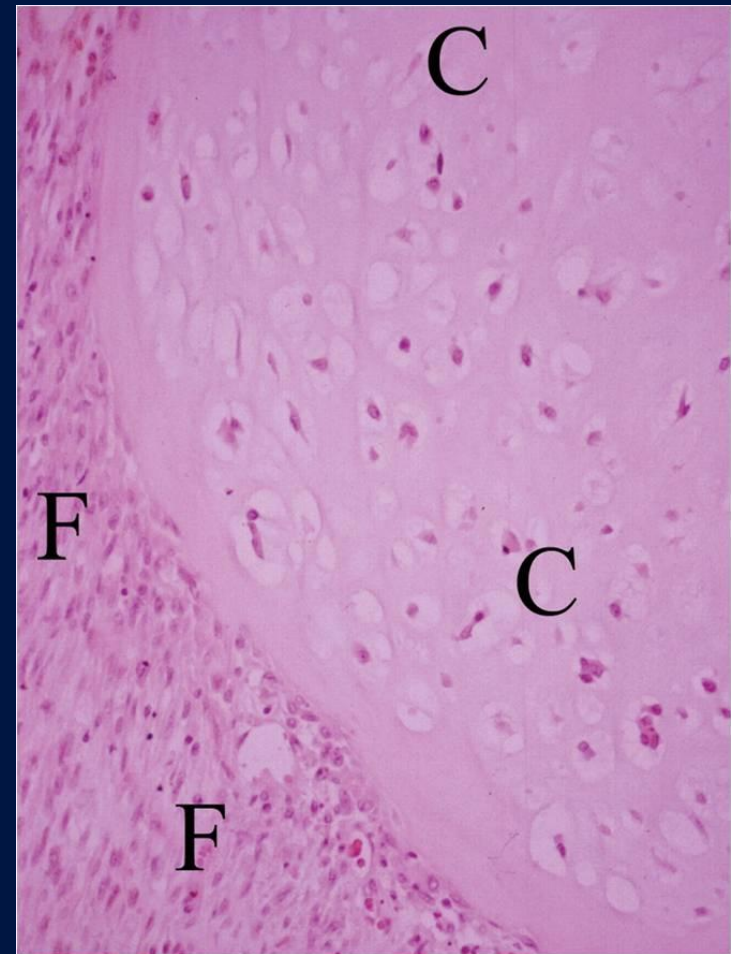


Murphey M D et al. Radiographics 2003;23:1245-1278



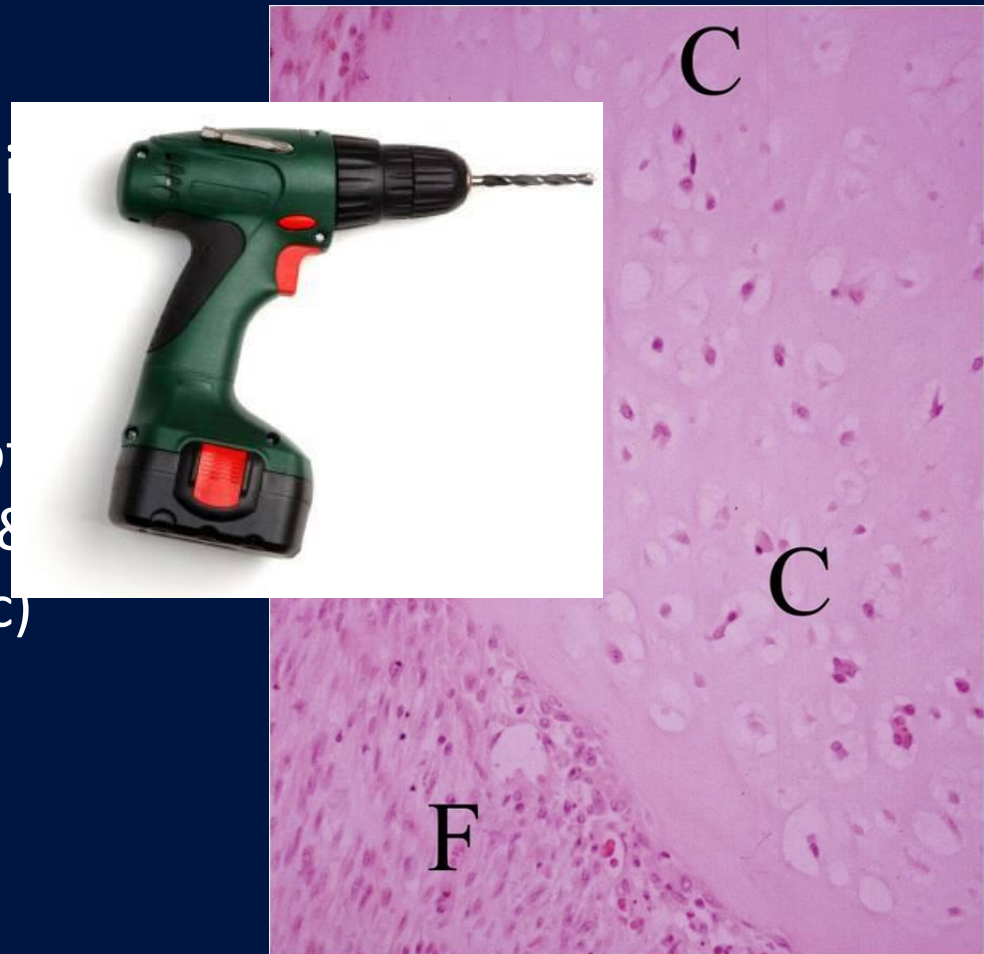
# Chondrosarcoma – Grading System

- Grade 1 – low
- Grade 2 – intermediate
- Grade 3 – high
  - Dedifferentiated (“collision tumor” of low grade chondrosarc & high grade fibrosarc)



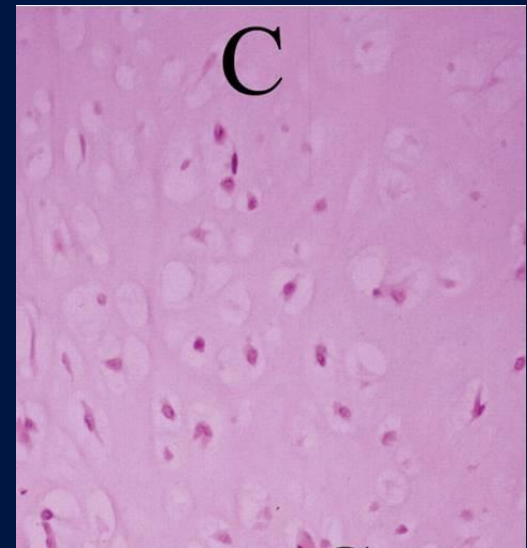
# Chondrosarcoma – Grading System

- Grade 1 – low
- Grade 2 – intermediate
- Grade 3 – high
  - Dedifferentiated (“collision tumor” of low grade chondrosarc & high grade fibrosarc)



# Biopsy & risk of underestimating lesion grade

- Acquire & carefully review images
- Direct biopsy toward aggressive endosteal scalloping, ST component, & diffusely enhancing regions
- Avoid areas of matrix mineralization
- Biopsy tract resected w/ surgical excision

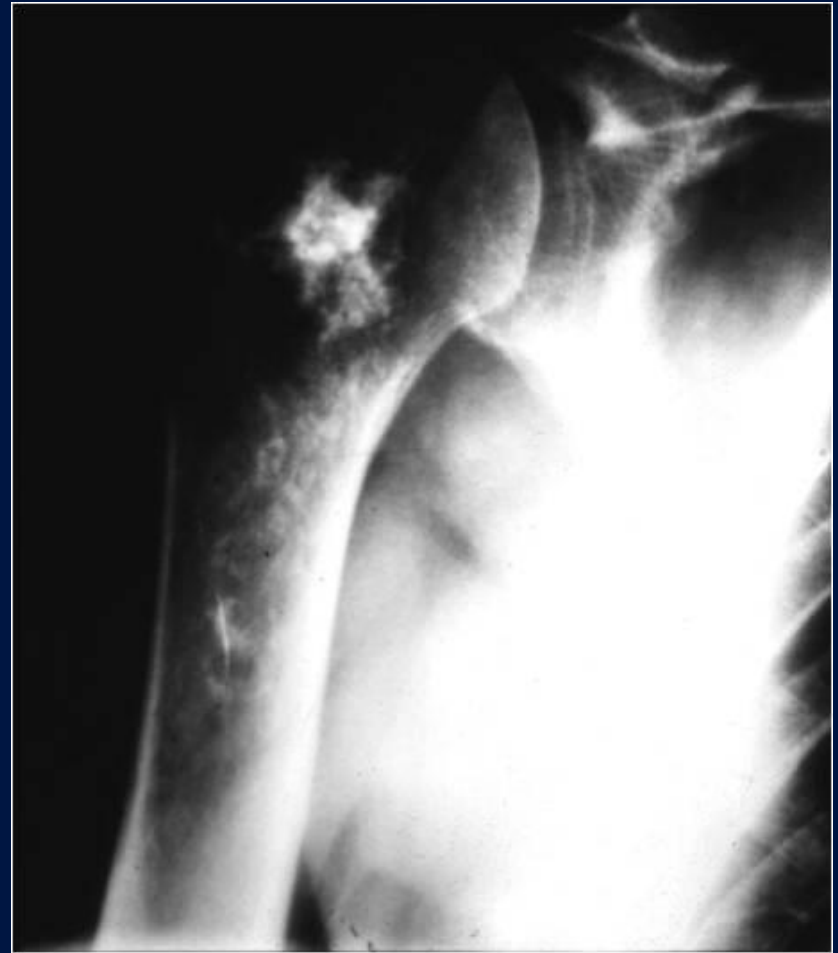

# Grade 1 conventional chondrosarcoma vs. enchondroma of long bone

- Look for signs of higher grade chondrosarc:
  - Cortical destruction
  - ST mass
- If sx-ic intramedullary cartilage tumor of long bone with endosteal scalloping of  $< 2/3$  cortical thickness . . .
  - Follow 4-6 mo intervals x2 yrs
  - Then annually up to 5 yrs

# Chondrosarcoma Imaging: XR

- Mixed lytic and sclerotic
  - Sclerotic = chondroid matrix = rings & arcs, or flocculent calcs
  - Lucent = geographic lysis, multilobulated, corresponds to lobular growth of hyaline cart
- Higher grade = more moth-eaten, permeative
  - (mesenchymal, myxoid, & dedifferentiated types)
  - *Clear cell can appear radiolucent*
- Lobulated endosteal scalloping → cortical breakthrough → ST mass

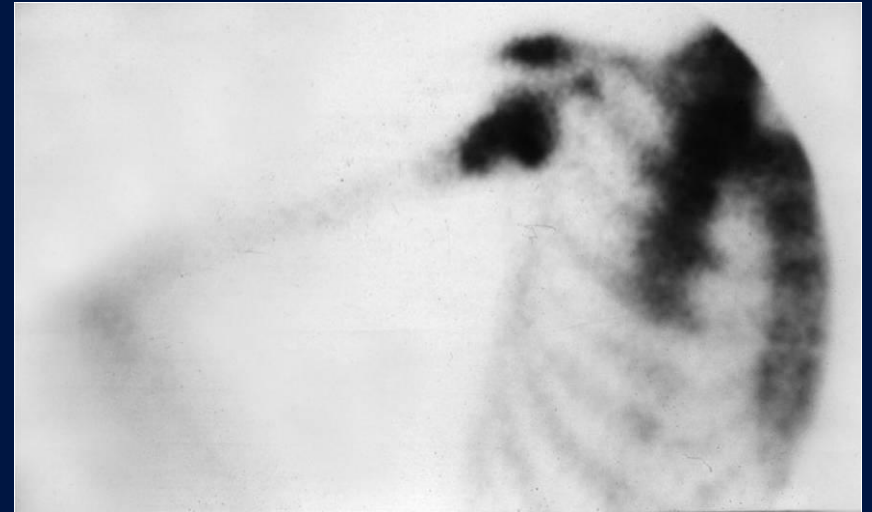

Courtesy, George Nomikos



# Chondrosarcoma Imaging: Scintigraphy

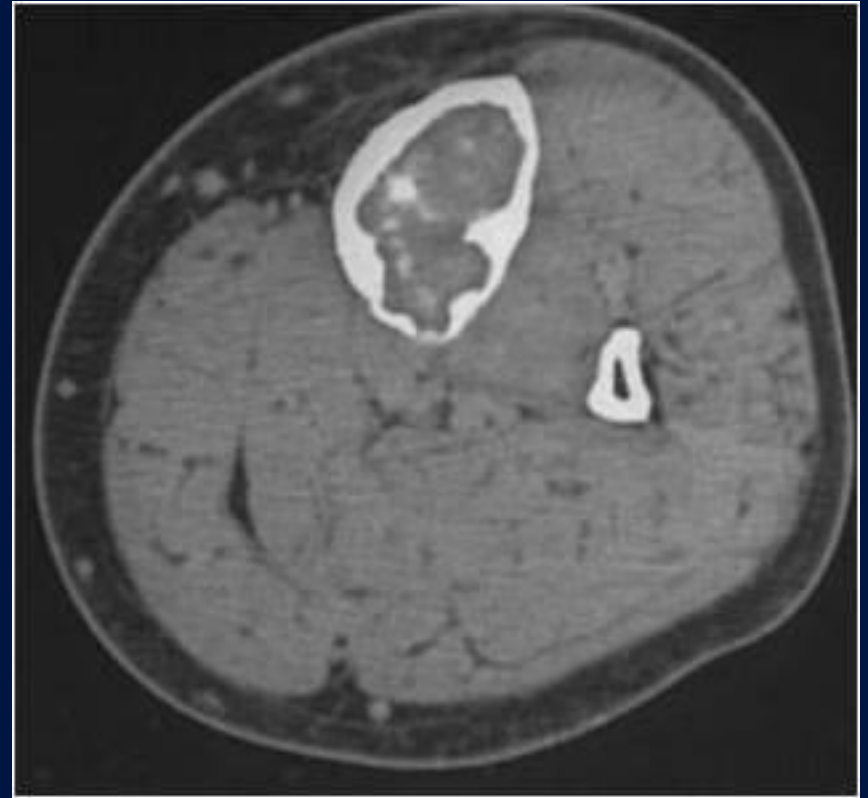
- Marked increased radionuclide uptake >> anterior iliac crest
- Heterogenous pattern if conventional intramedullary chondrosarc



Courtesy, George Nomikos

# Chondrosarcoma Imaging: CT

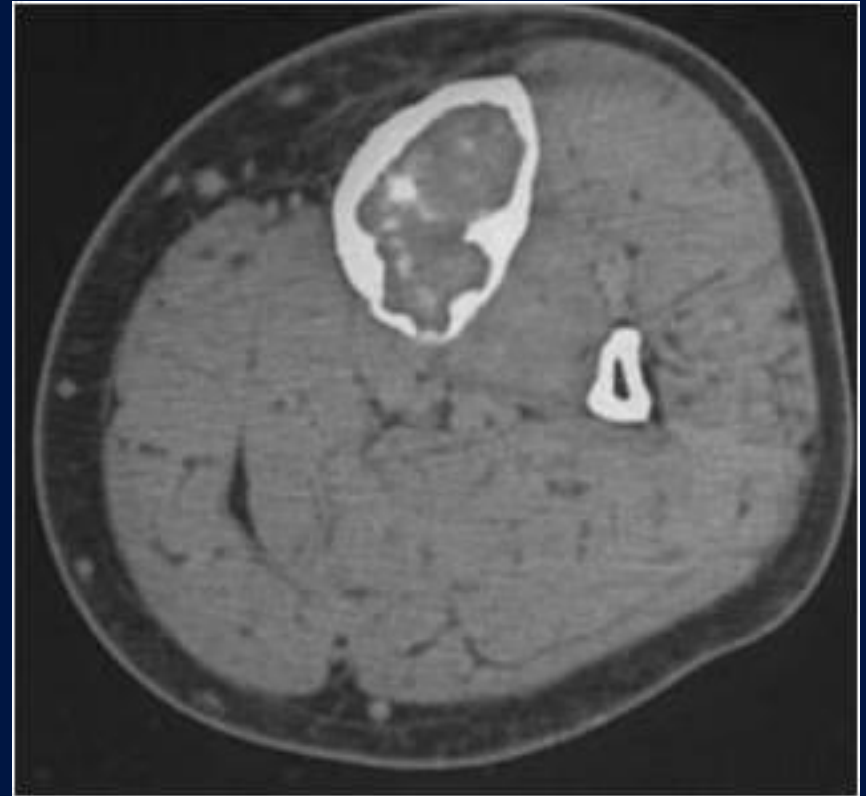
- Deep endosteal scalloping (>2/3 cortical thickness)
- Cortical remodeling, thickening & periosteal rxn, common
- ST component



Courtesy, George Nomikos

# Chondrosarcoma Imaging: CT

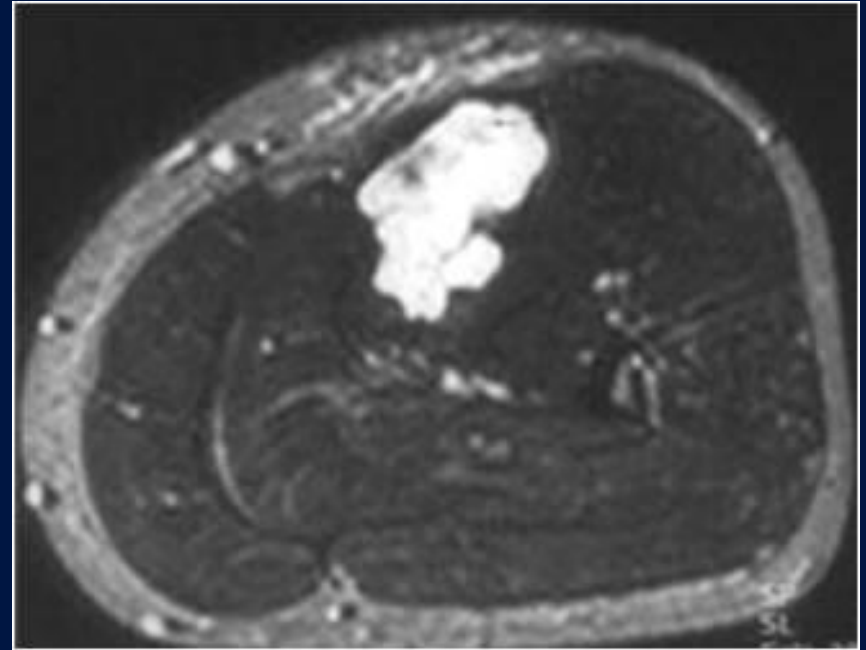
- Best for detection of matrix mineralization
  - Matrix mineralization not helpful in distinguishing chondrosarc f/ enchondroma
  - Less calcification seen with higher grade
- Mild periph rim & septal enhancement
  - Higher grade lesions more diffuse & nodular enh d/t increased cellularity & decr'd water content



Courtesy George Nomikos

# Chondrosarcoma Imaging: MR

- Best for extent of marrow involvement
- Matrix mineralization: low to intermediate on T1
  - Speckled high T1 = entrapped yellow marrow
- Non-mineralized compts are high on T2
  - High water content of hyaline cart
  - Peritumoral edema
- Cart lobules may be surrounded by low SI septa
- PD: best to depict endosteal scalloping



Courtesy George Nomikos

# Chondrosarcoma - Treatment

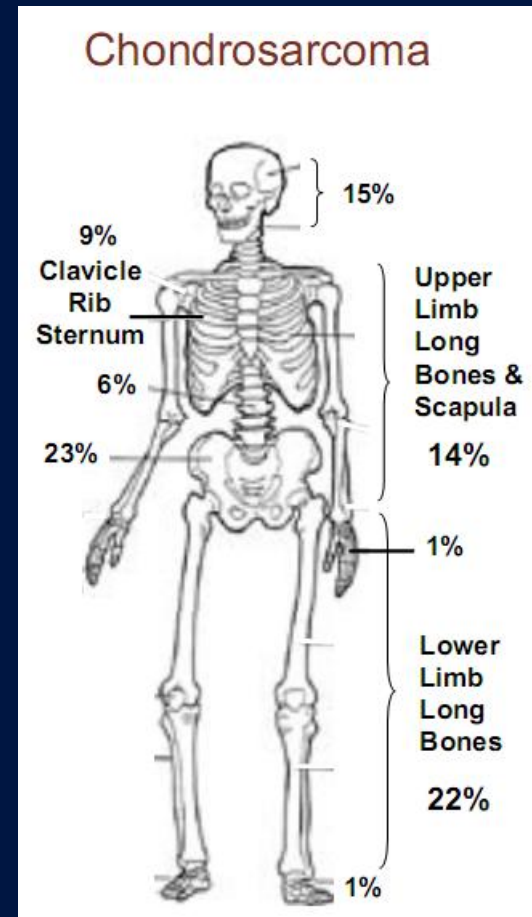
- Low grade:
  - Intralesional curettage, chemical/thermal ablation , cement or bone graft
- Intermediate/high grade:
  - Wide surgical excision
- Chemotx and XRT have limited role
  - Conventional chondrosarc not particularly sensitive
  - XRT for higher-grade conventional chondrosarc (gr 2-3) t/ is incompletely excised
  - More aggressive chondrosarc (mesenchymal, dedifferentiated) – use both
  - Clear cell chondrosarc – use chemotx

# Chondrosarc – Metastatic disease

- Low grade:
  - Relatively non-existent
- Intermediate grade:
  - Lungs
  - Lymph nodes
  - Bones
- High grade:
  - Above + viscera (liver)

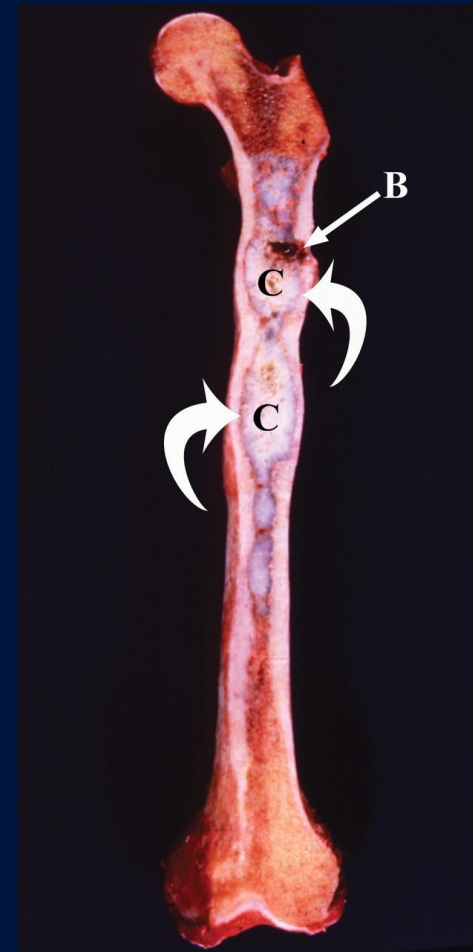# Chondrosarcoma – Conventional Intramedullary

- Most common primary chondrosarcoma
- 4<sup>th</sup>-5<sup>th</sup> decades of life
- Pain & ST mass
- 5 yr survival:
  - Gr1: 90-94%
  - Gr2: 61-81%
  - Gr3: 43-44%
- Long bones & pelvis (65%)
  - Femur > tibia > humerus



# Intramedullary chondrosarcoma

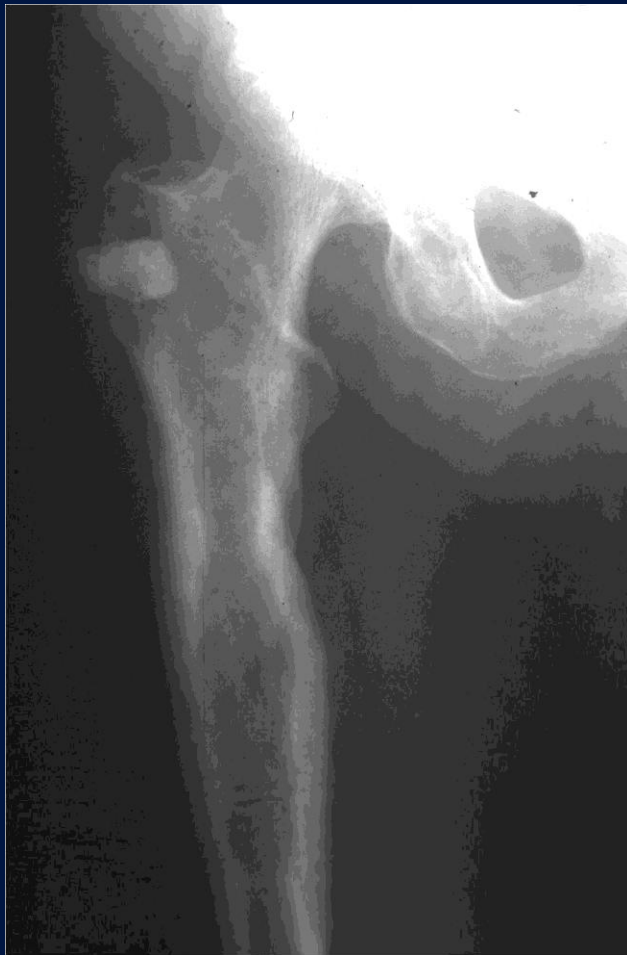- Lobular growth
- Multilobulated lesion replacing the marrow space (C)
- Deep endosteal scalloping (>2/3 cortical thickness) with expansile remodeling of bone (arrows)
  - Reflects slow tumor growth



Murphey M D et al. Radiographics 2003;23:1245-1278



# Intramedullary chondrosarcoma: Sites of involvement

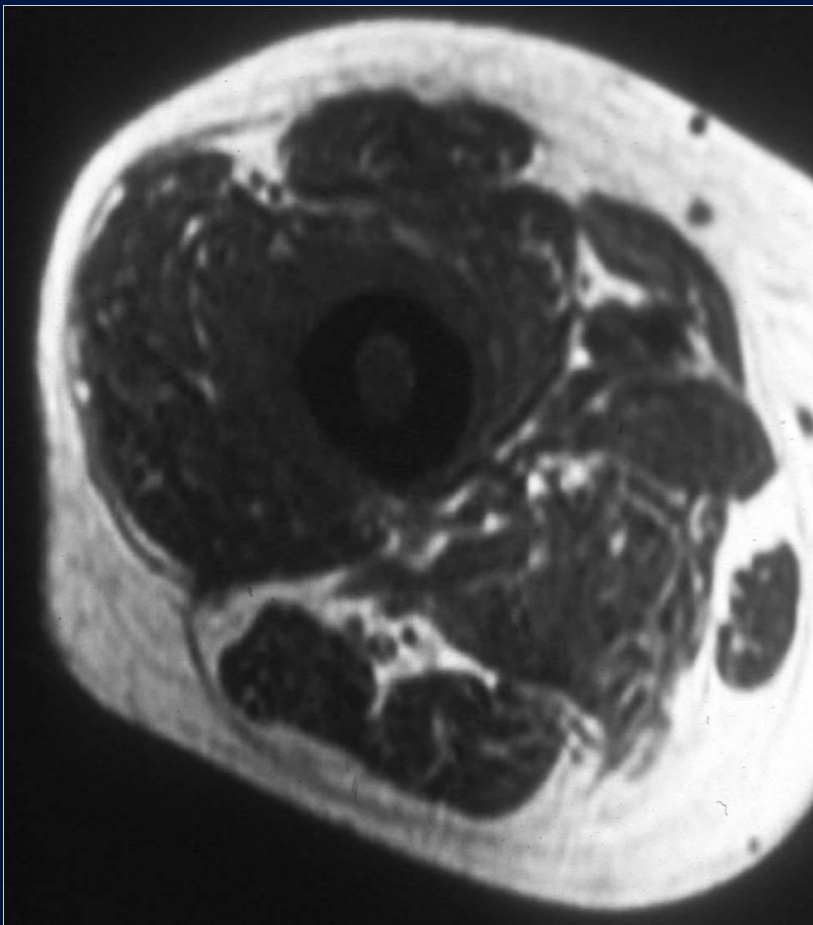


- Large at dx (>4cm length)
- Long tubular bones
  - Metaphysis > diaphysis >> Epiphysis
    - Epiphyseal enchondroma is exceedingly rare
  - Proximal femur > tibia > fibula

Courtesy, George Nomikos, AFIP

# Intramedullary chondrosarcoma:

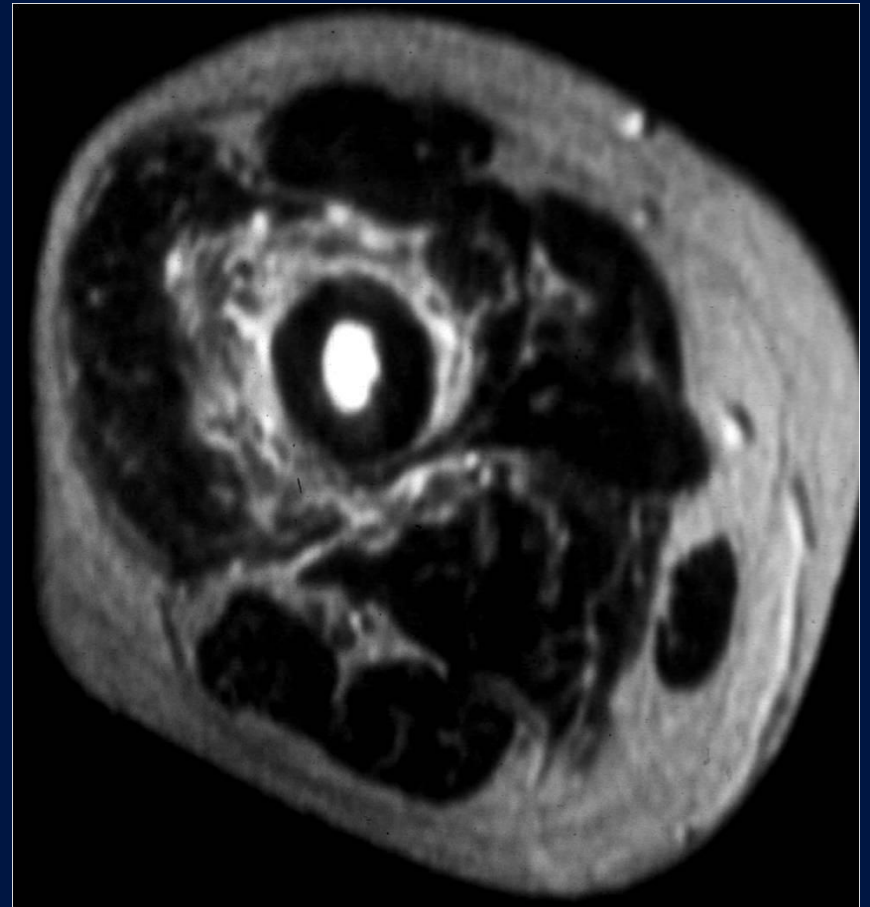
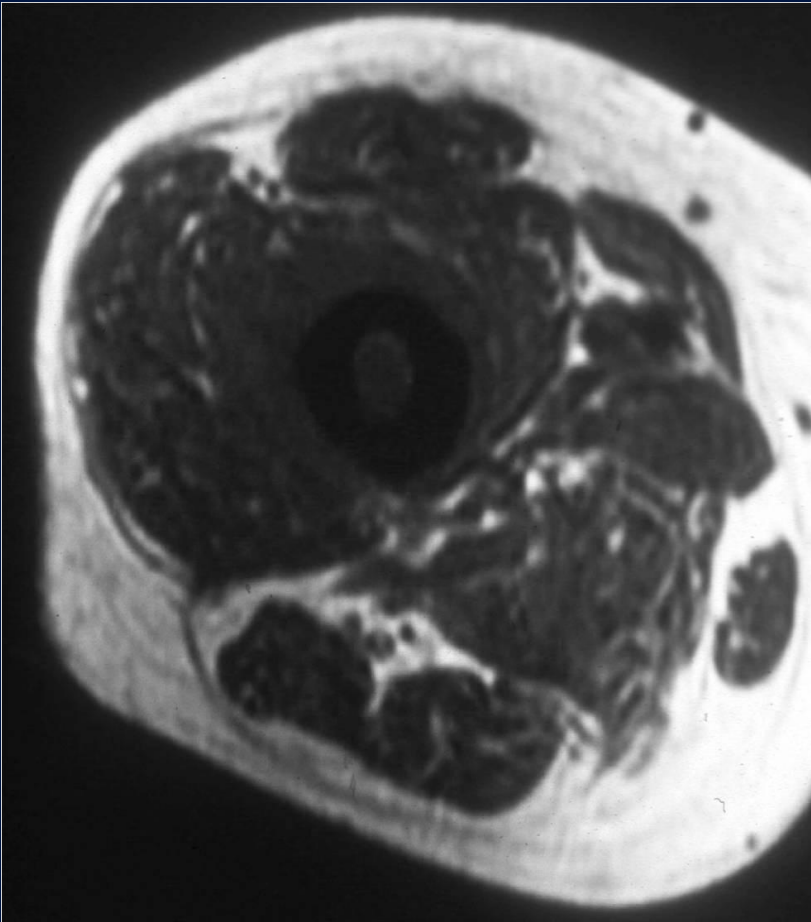
## T1



- Signal of the ST mass follows that of high water content of hyaline cartilage
  - (sim to periosteal osarc, w/o the perpendicular periosteal rxn)

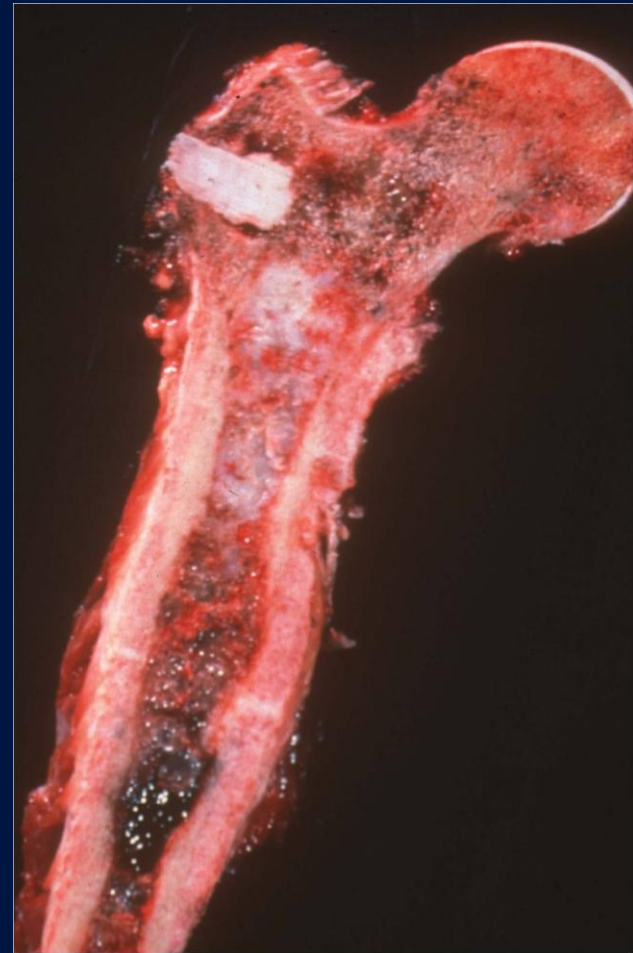
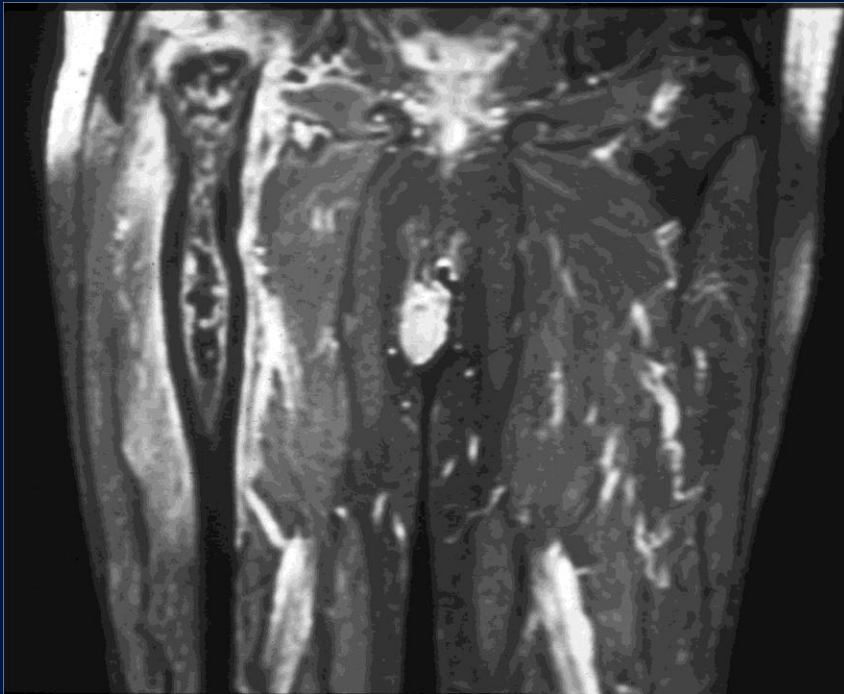
Courtesy, George Nomikos, AFIP

# Intramedullary chondrosarcoma: T1 & T2



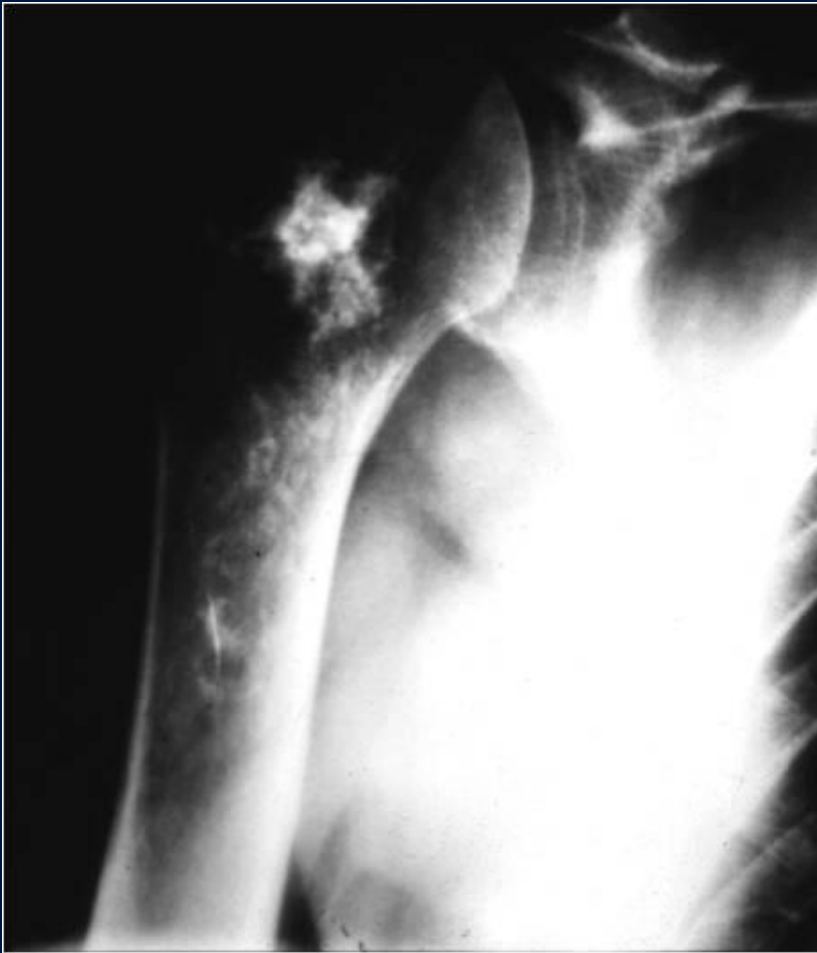Courtesy, George Nomikos, AFIP

# Intramedullary chondrosarcoma: post Gad & gross



Courtesy, George Nomikos, AFIP

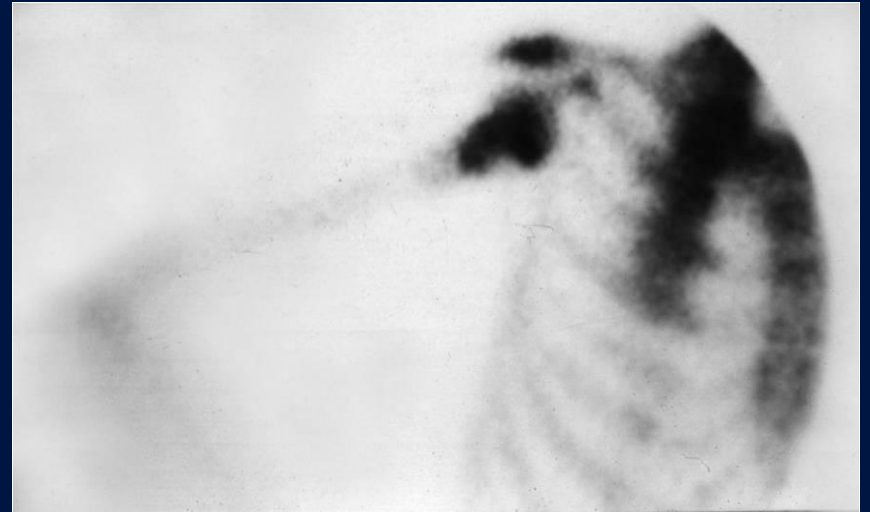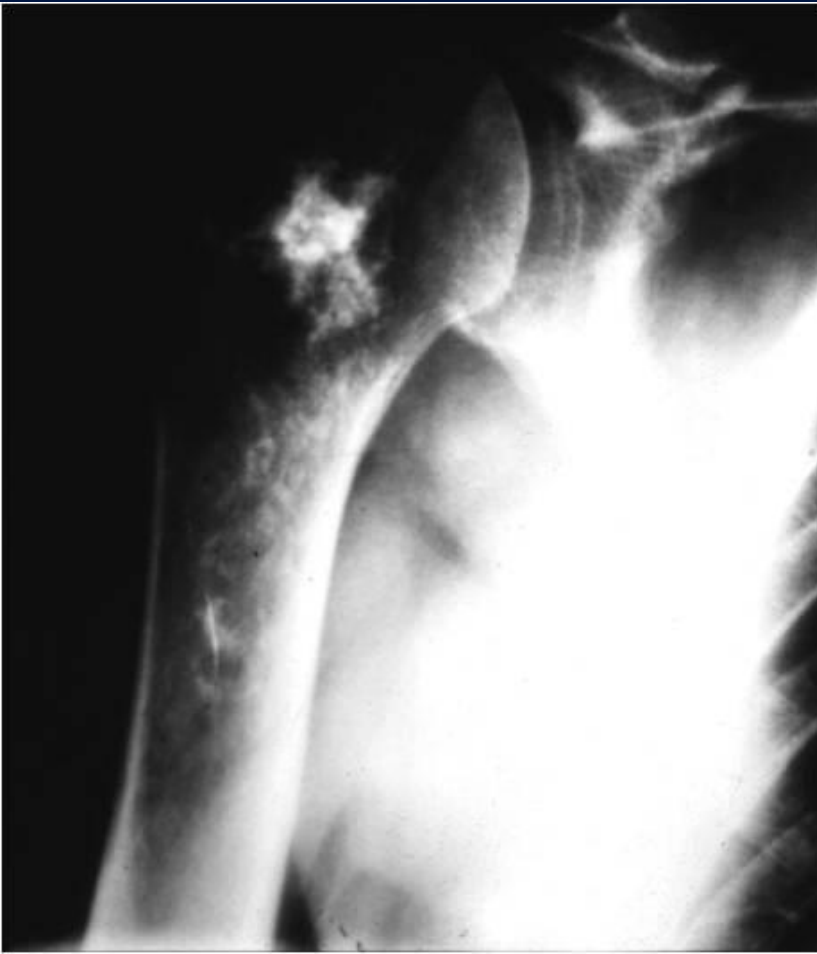# Dedifferentiated



- 10% of chondrosarc
- Consists of conventional low-grade chondrosarcoma with foci of higher-grade non-cartilaginous malignancy
  - such as MFH, osteosarcoma, or fibrosarcoma
- “Collision of two tumors”

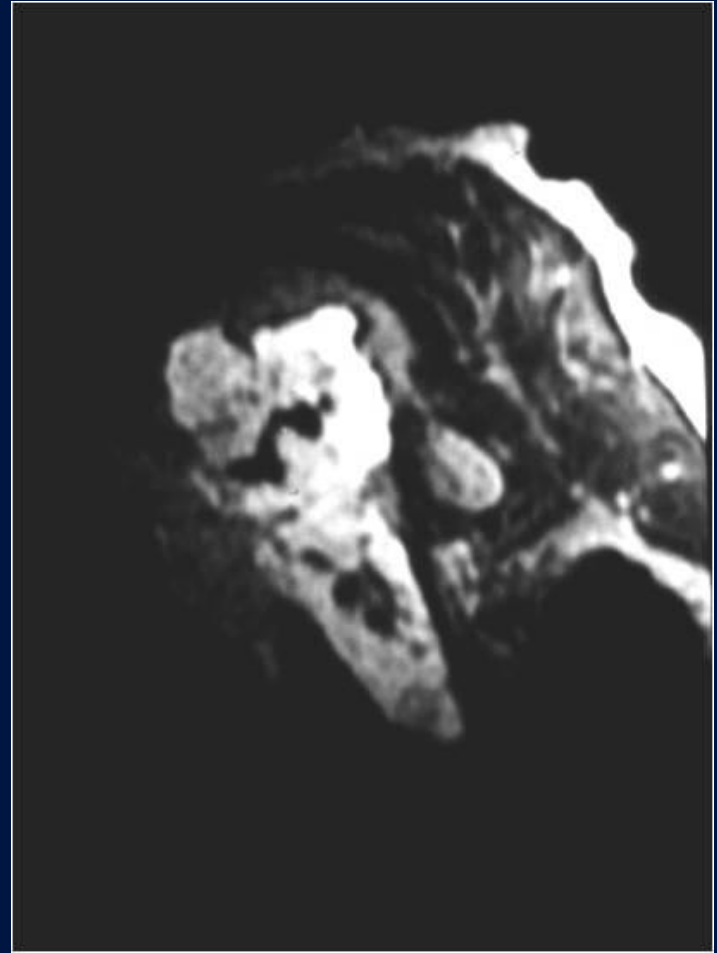
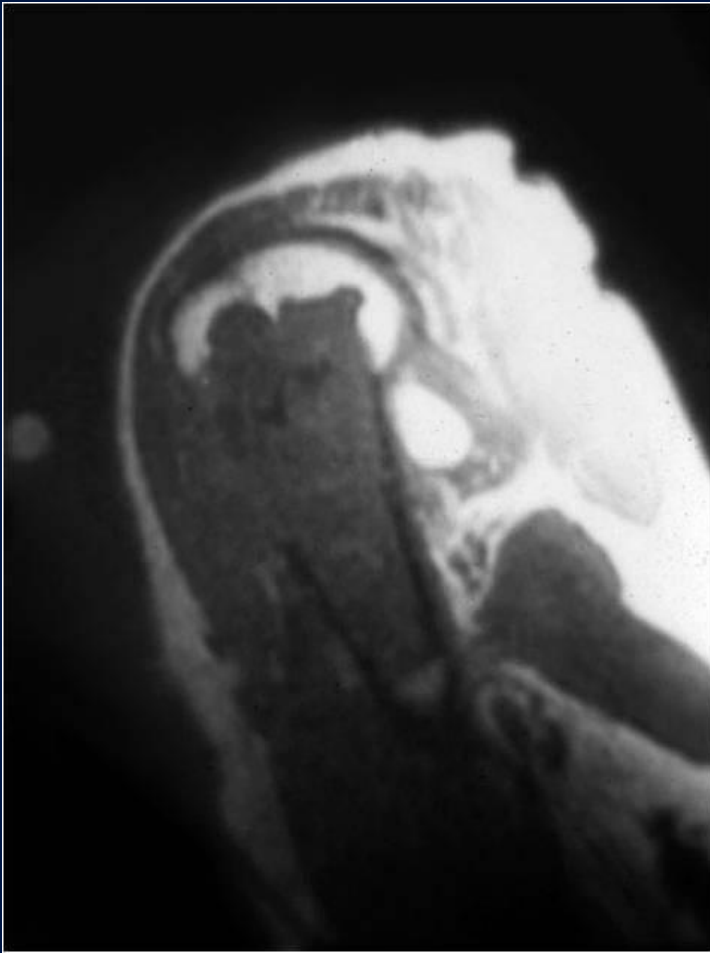
Courtesy, George Nomikos, AFIP

# Dedifferentiated



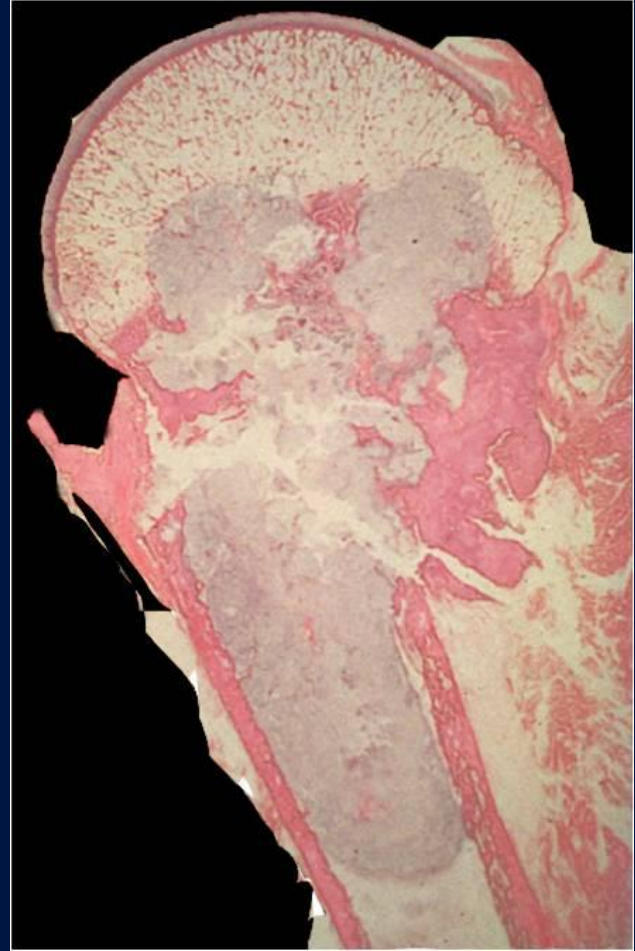
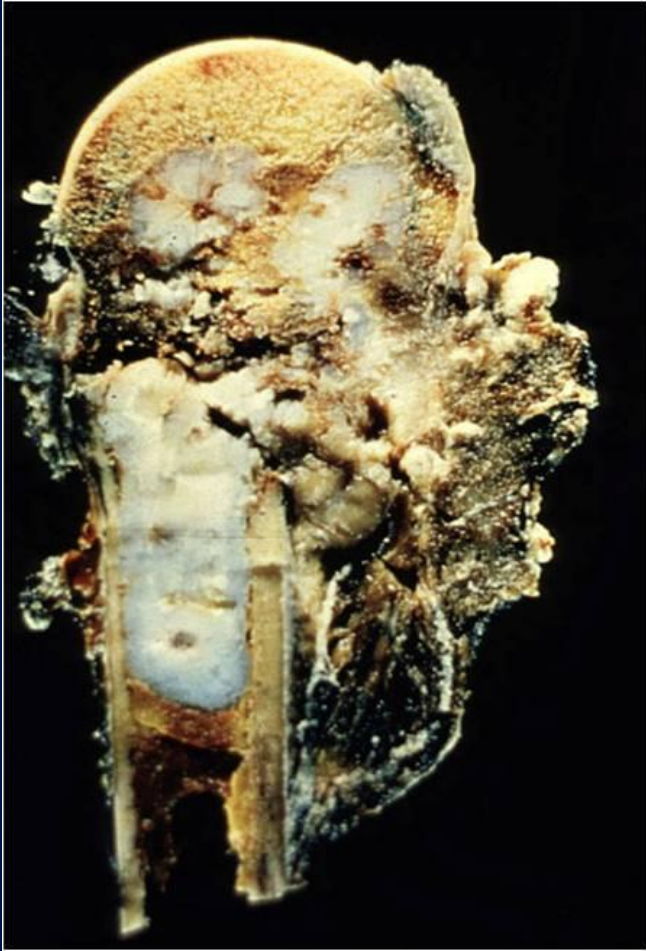Courtesy, George Nomikos, AFIP

# Dedifferentiated



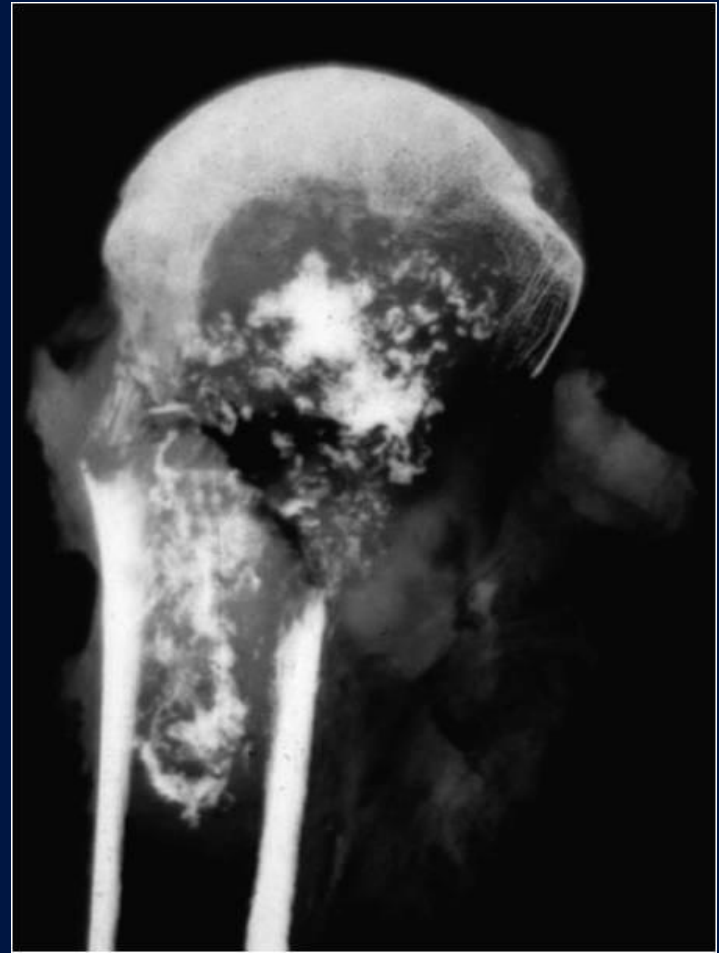
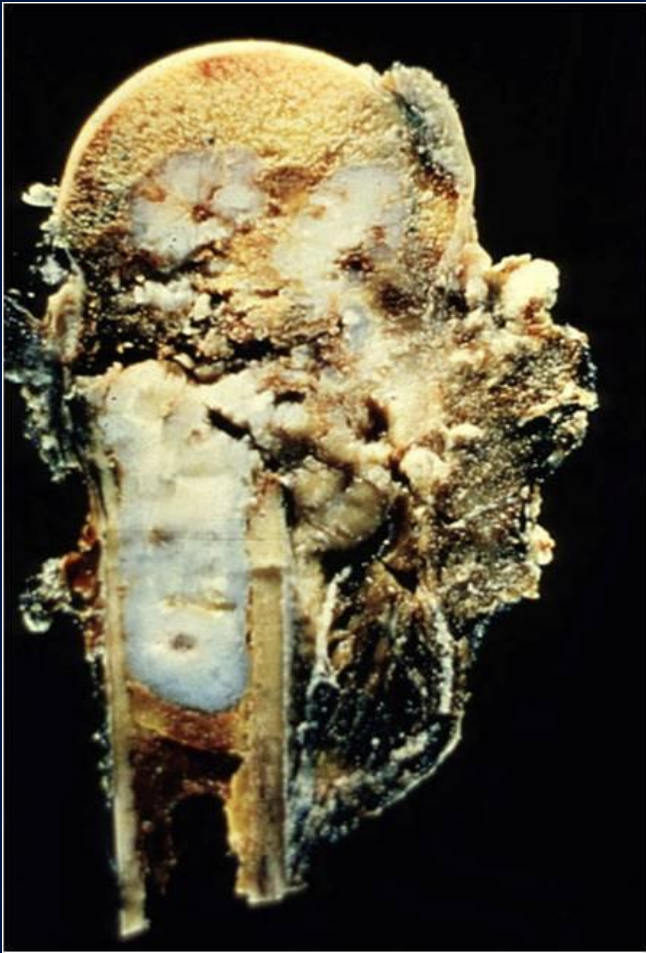
# Dedifferentiated





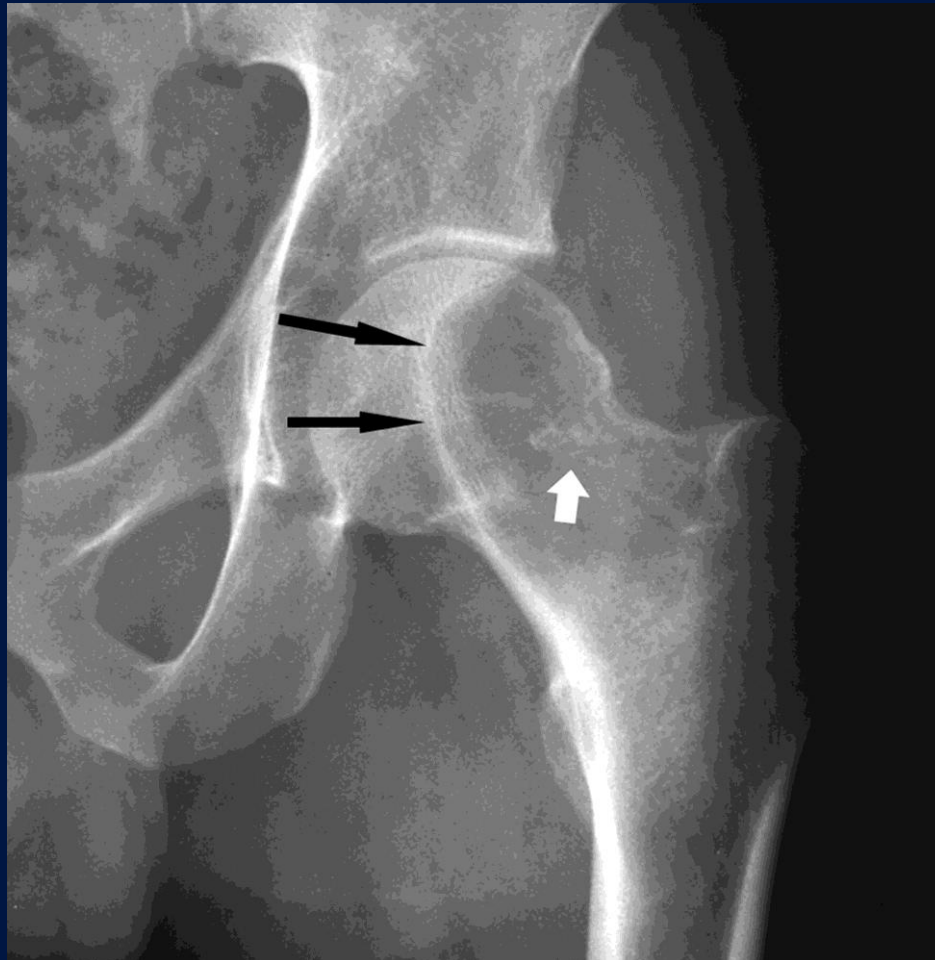
# Dedifferentiated



# Clear Cell Chondrosarcoma

- Rare, low grade malignant cartilaginous tumor
  - (Glycogen-heavy chondrocytes that appear clear/vacuolated)
- Epiphyseal/apophyseal
- *May histologically resemble osteoblastoma*
  - Large areas of hemorrhage and cyst formation, unlike conventional chondrosarcoma
- About ½ of clear cell chondrosarc contain areas of conventional chondrosarcoma

# Clear cell chondrosarcoma in the left proximal femur of a 30-year-old man with hip pain.



Murphey M D et al. Radiographics 2003;23:1245-1278

RadioGraphics

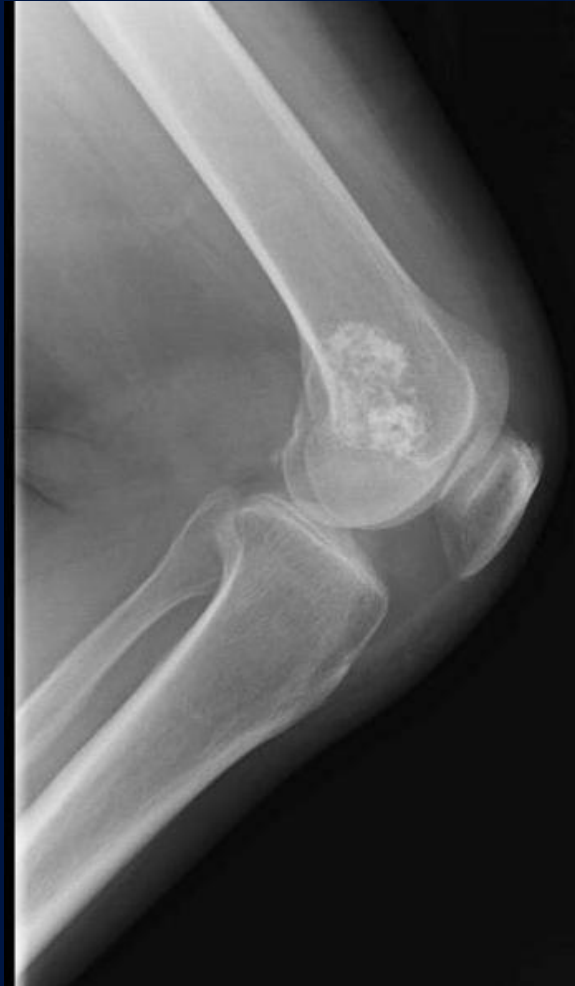# Secondary Chondrosarcomas

- When enchondromas and osteochondromas go bad

# Enchondroma

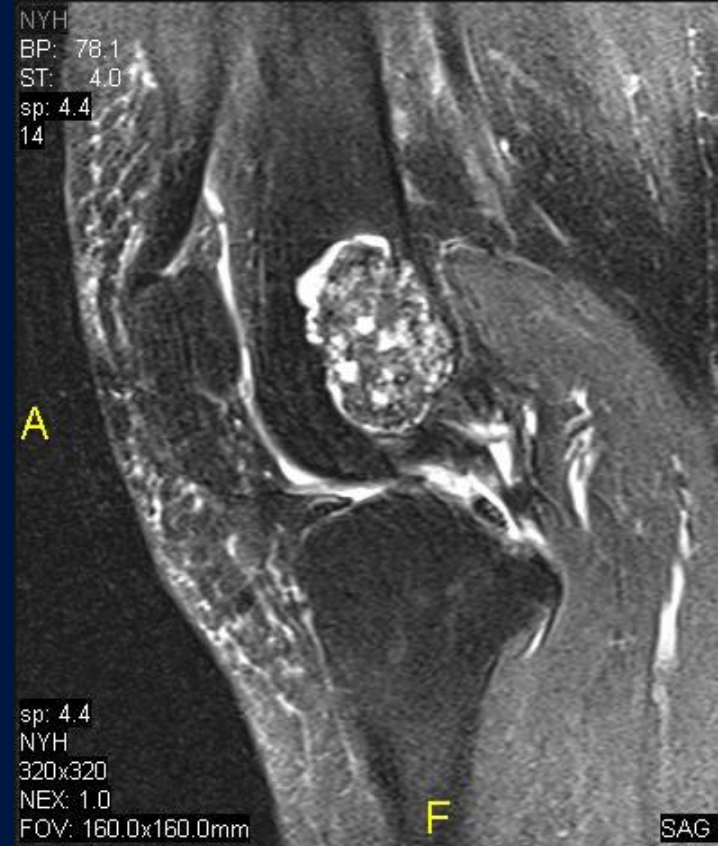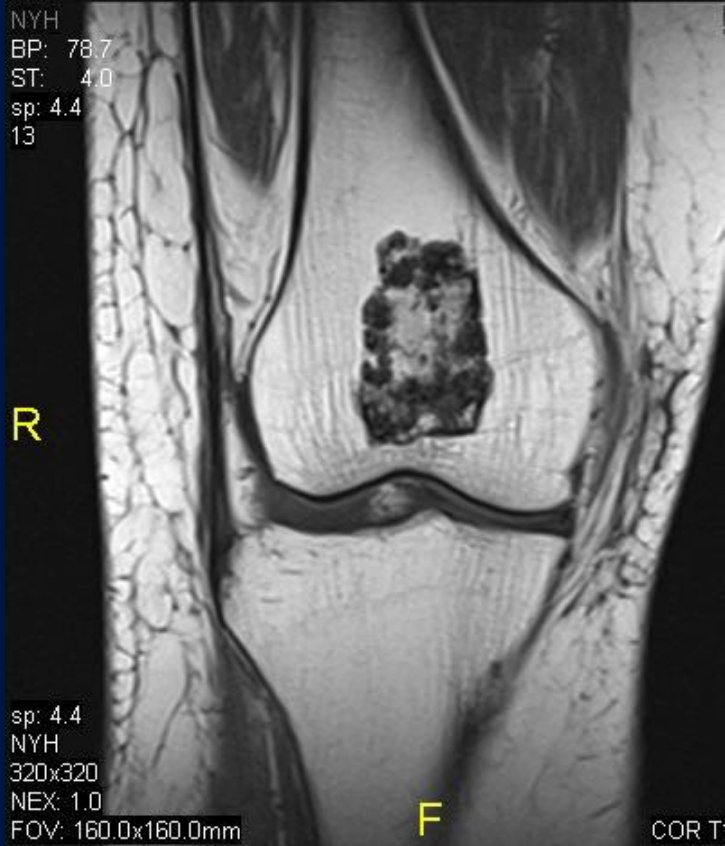---

- Geographic
- Narrow zone of transition
- Chondroid matrix (except hand, may not see matrix)
- Complications:
  - Fracture
  - Malignant transformation to chondrosarcoma
- Multiple:
  - Maffucci (w/ ST hemangiomas) & Olliers
  - Increased risk of malignant transformation



Courtesy, George Nomikos

# Enchondroma

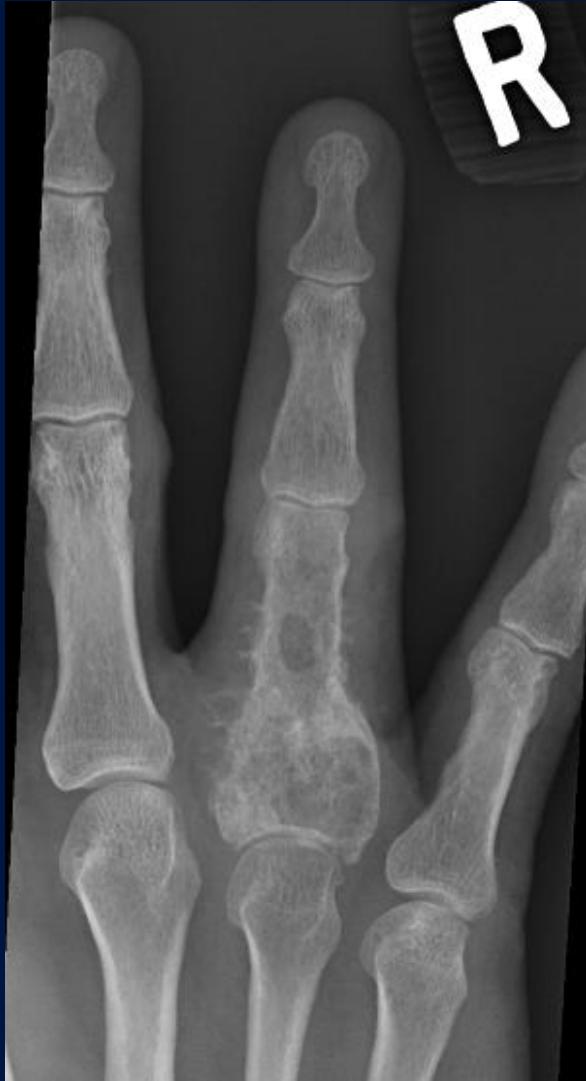

Courtesy, George Nomikos

# Chondrosarcoma features when ddx incl enchondroma:

- Deep endosc scalloping (>2/3 cortical depth)
- Uptake on bone scan > ASIS
- Cortical destruction or ST mass
- Periostitis, cortical thickening
- Size > 5cm
- Epiphyseal location (unlikely for enchondroma)
- Pain directly attributable to lesion

# Enchondroma Gone Bad



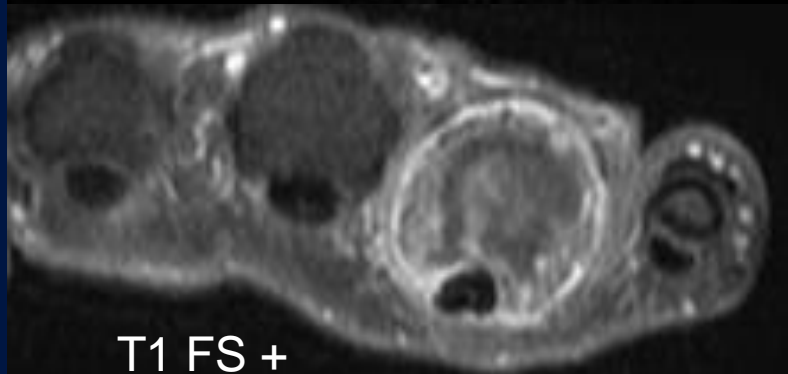
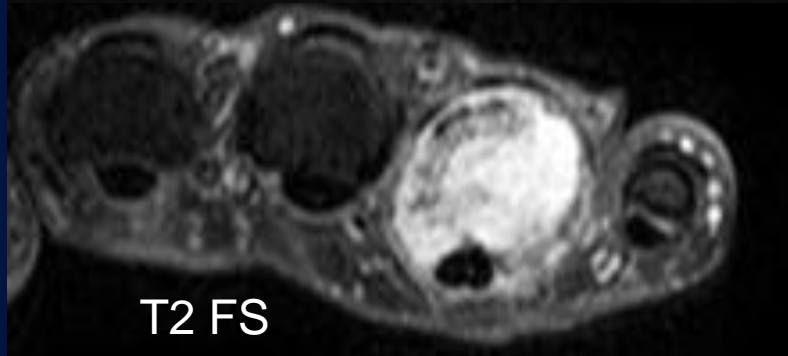
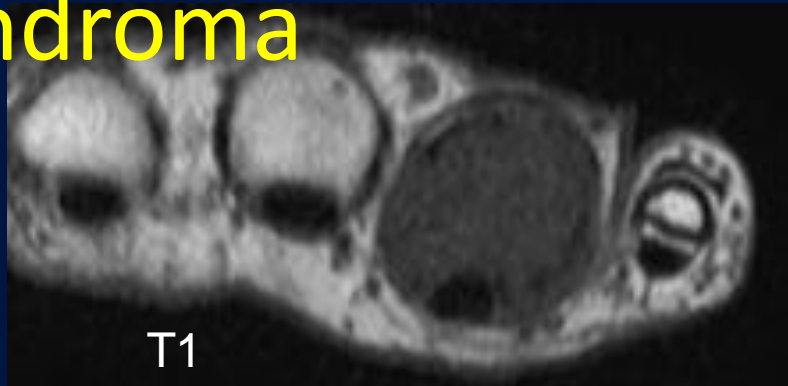
- Brady's case
- 59 yo male with palpable, painful 4<sup>th</sup> digit mass

Courtesy, Brady Huang

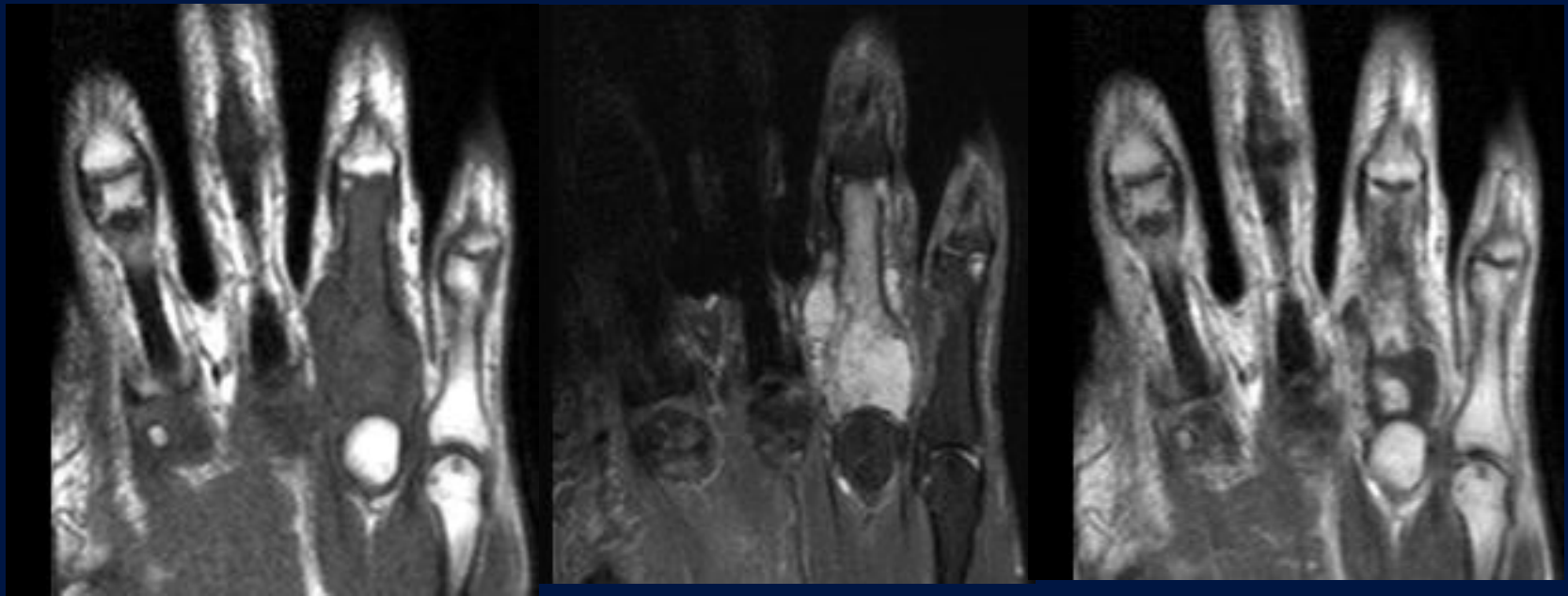


# Secondary Chondrosarcoma from Enchondroma

- 1<sup>st</sup> – clinically sx-ic
- 2<sup>nd</sup> – imaging
  - Expansile
  - Marrow replacing, endosteal thinning
  - Enhancement



# Secondary Chondrosarcoma from Enchondroma



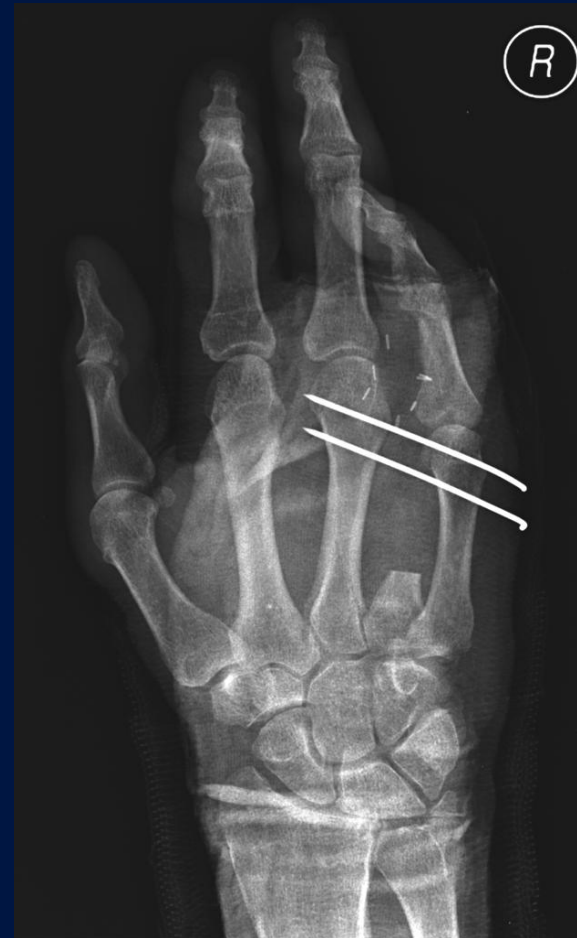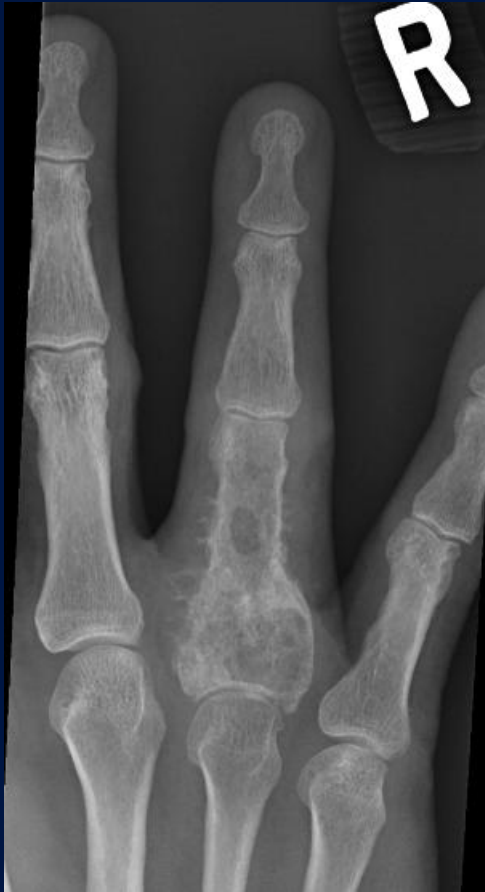T1

T2 FS

T1 FS +

Courtesy, Brady Huang

# Enchondroma Gone Bad

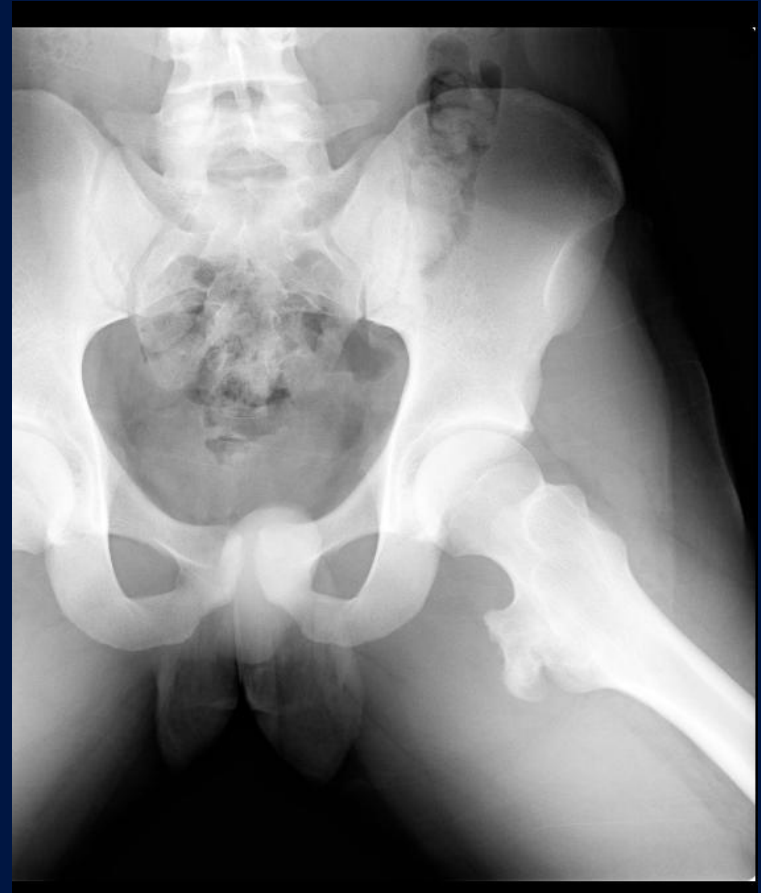

Courtesy, Brady Huang

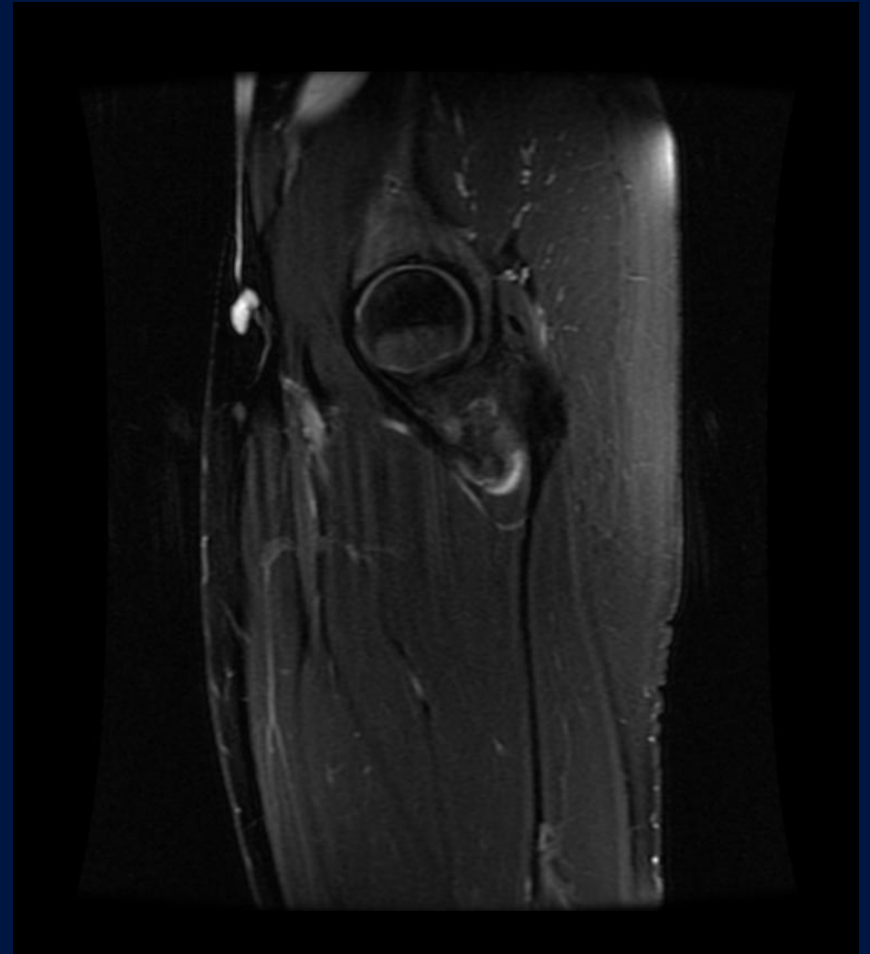
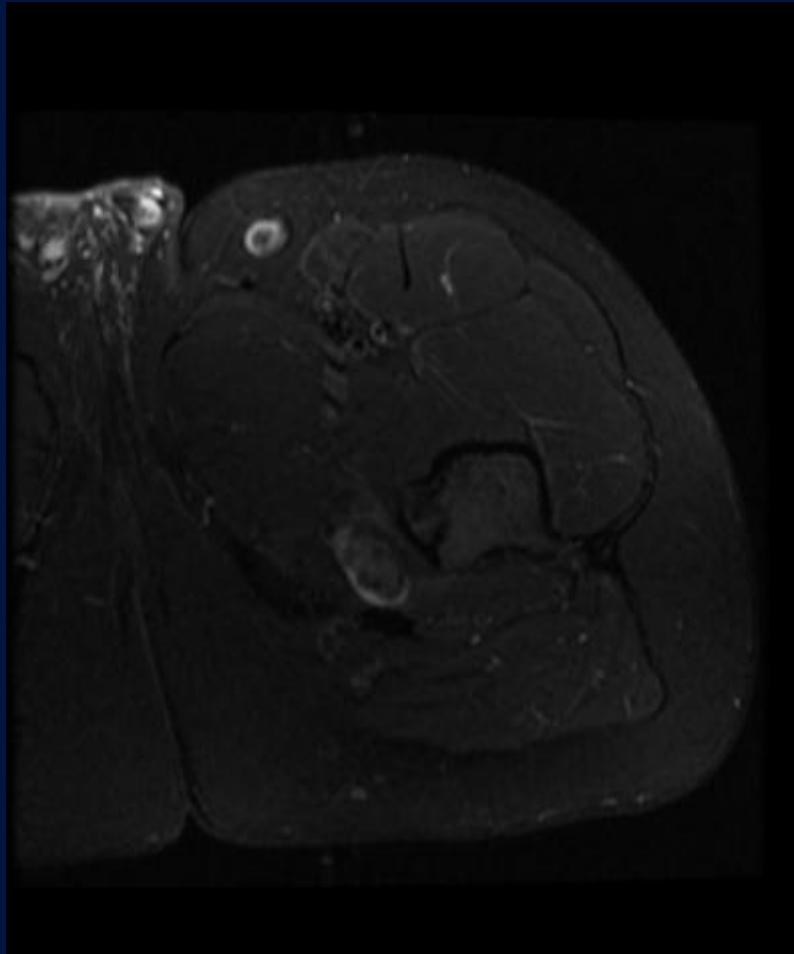
# Osteochondroma

---

- Most common benign bone neoplasm
- 10-15% of all primary bone tumors
- Malig transformation:
  - 1% for solitary osteochondromas
  - 2-5% for hereditary multiple exostoses (HME)



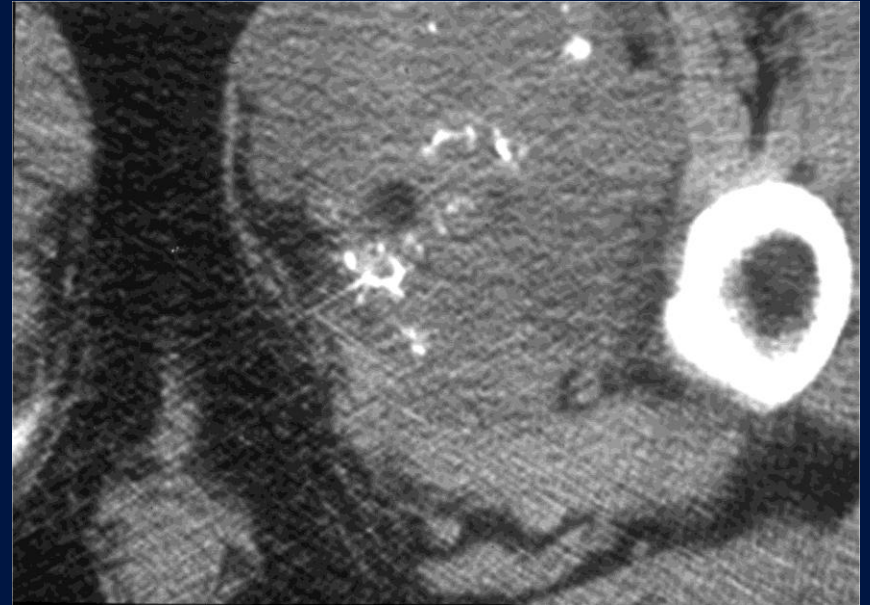
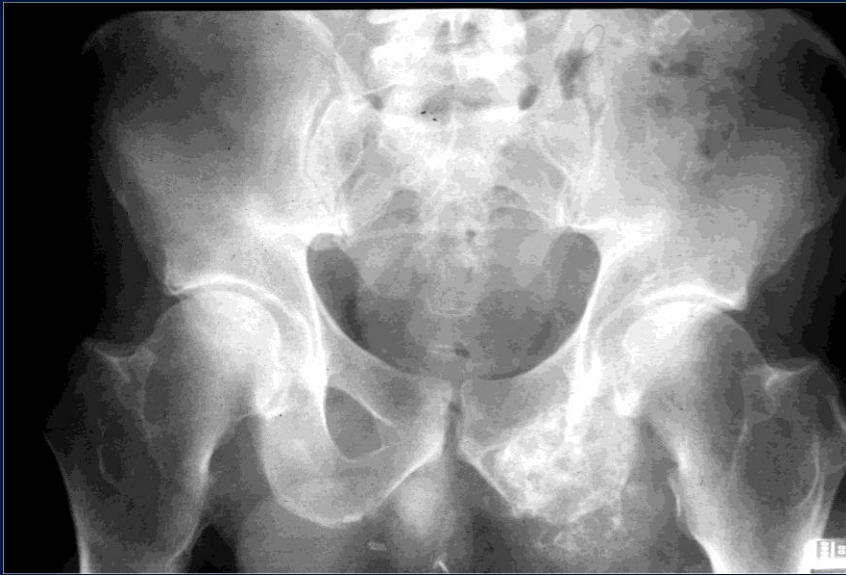# Osteochondroma: Cartilage cap



# Osteochondroma: Malignant Transformation

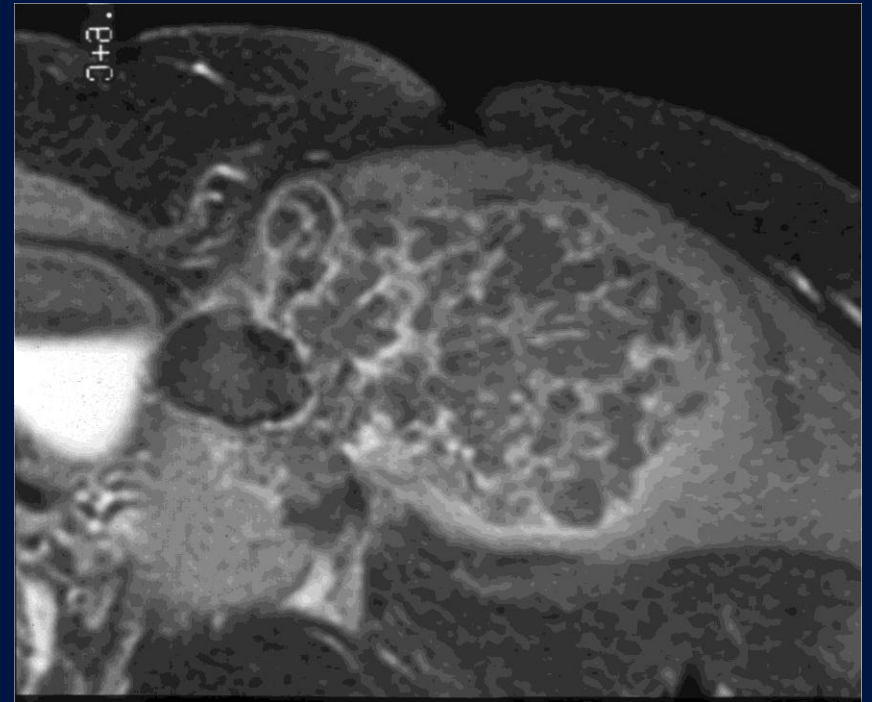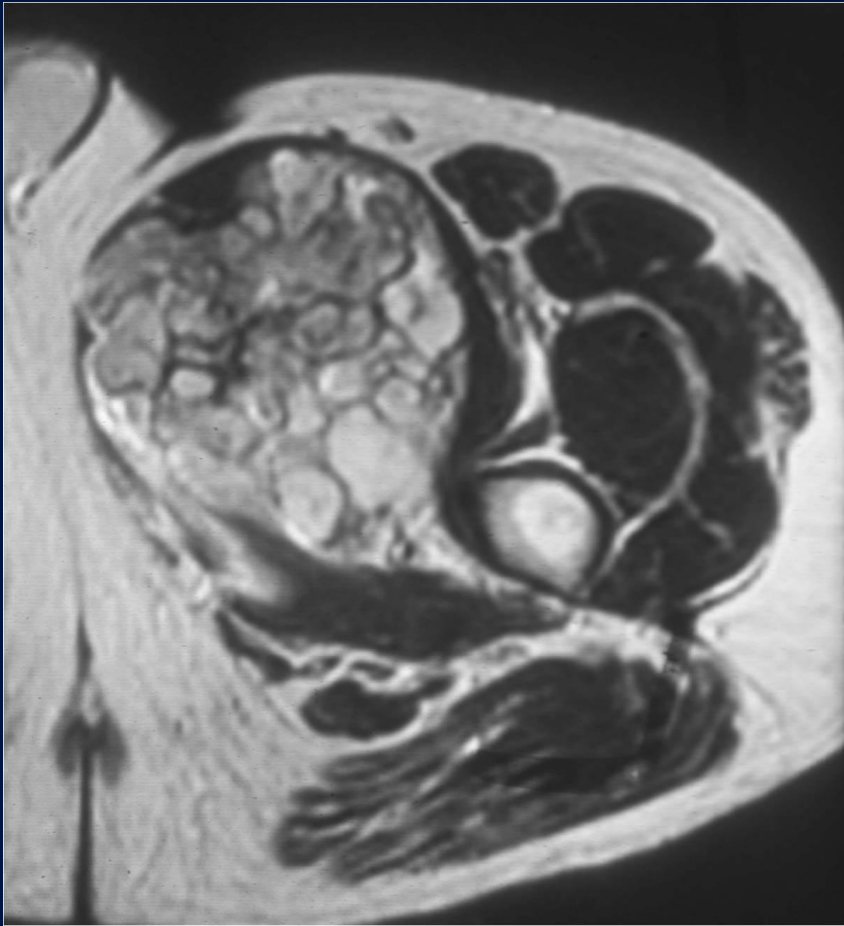
- Growing osteochondroma in a skeletally mature patient
- Irregular or indistinct lesion surface
- Focal radiolucent regions w/in the lesion
- Erosion or destruction of adj bone
- Significant ST mass w/ scattered calc'n
- Hyaline cart cap thickness > 1.5cm sk mature suspicious for harboring malignant transformation
- Bone scan does not help differentiate benign f/ malignant

# Osteochondroma Gone Bad - MHE





# Osteochondroma Gone Bad - MHE





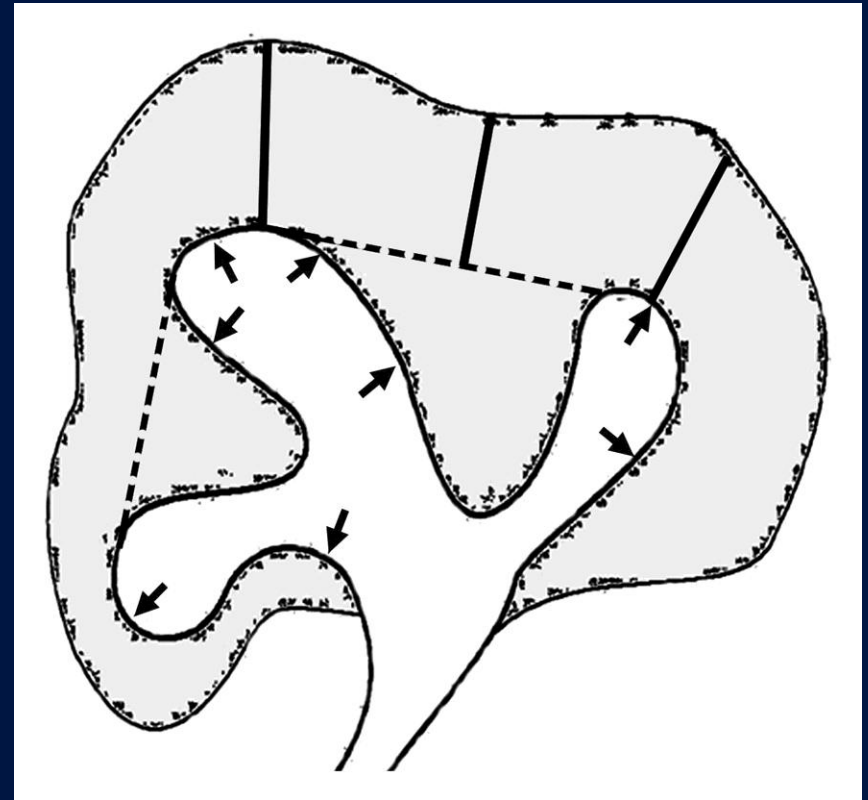
# Improved Differentiation of Benign Osteochondromas from Secondary Chondrosarcomas with Standardized Measurement of Cartilage Cap at CT and MR Imaging.

Bernard SA, et al. Radiology 2010; 255,857-865.

- Murphey and colleagues set out to verify cartilage cap thickness and concern for malignancy
- Reviewed 67 benign enchondromas, 34 exostotic chondrosarcomas
- Greatest percentage of malignancy was in lesions derived from pelvis

# Determining cartilage cap thickness

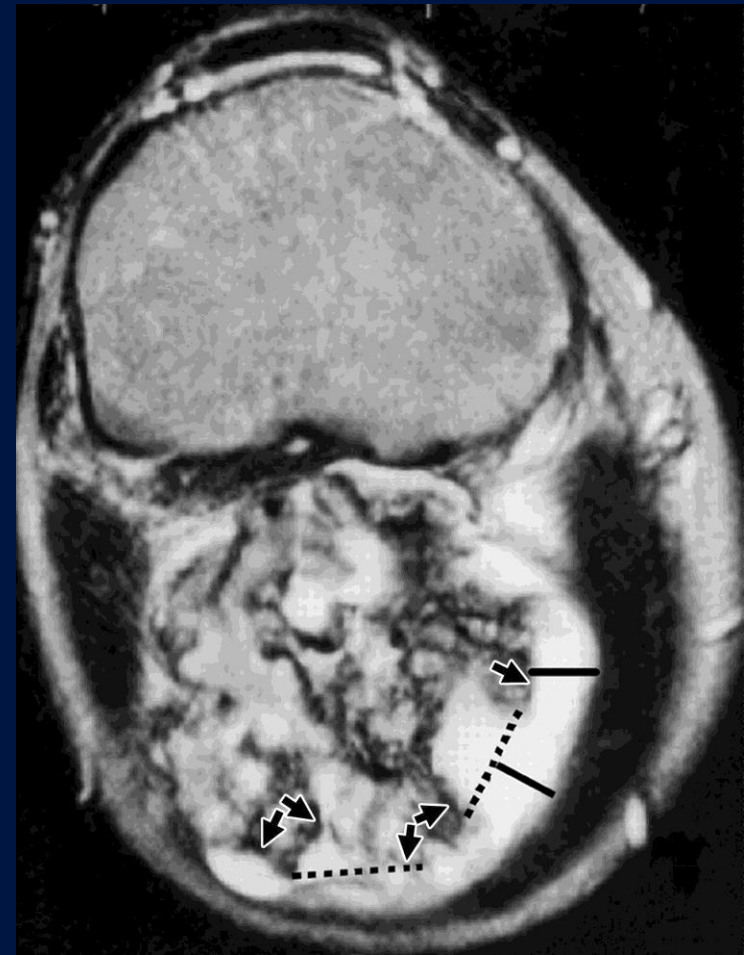
- Identify tidemark (arrows) of mature mineralization at the cartilage interface with the osteochondroma stalk
- Exclude crevases of cartilage b/t undulations in the tidemark (dotted line)



Bernard S A et al. Radiology 2010;255:857-865

# Determining cartilage cap thickness

- Measure cartilage thickness perpendicular to the tidemark
- Include full thickness of relatively high-fluid-content cartilage
  - Fluid attenuation on CT
  - Low-intermed T1
  - Intermed PD
  - High T2

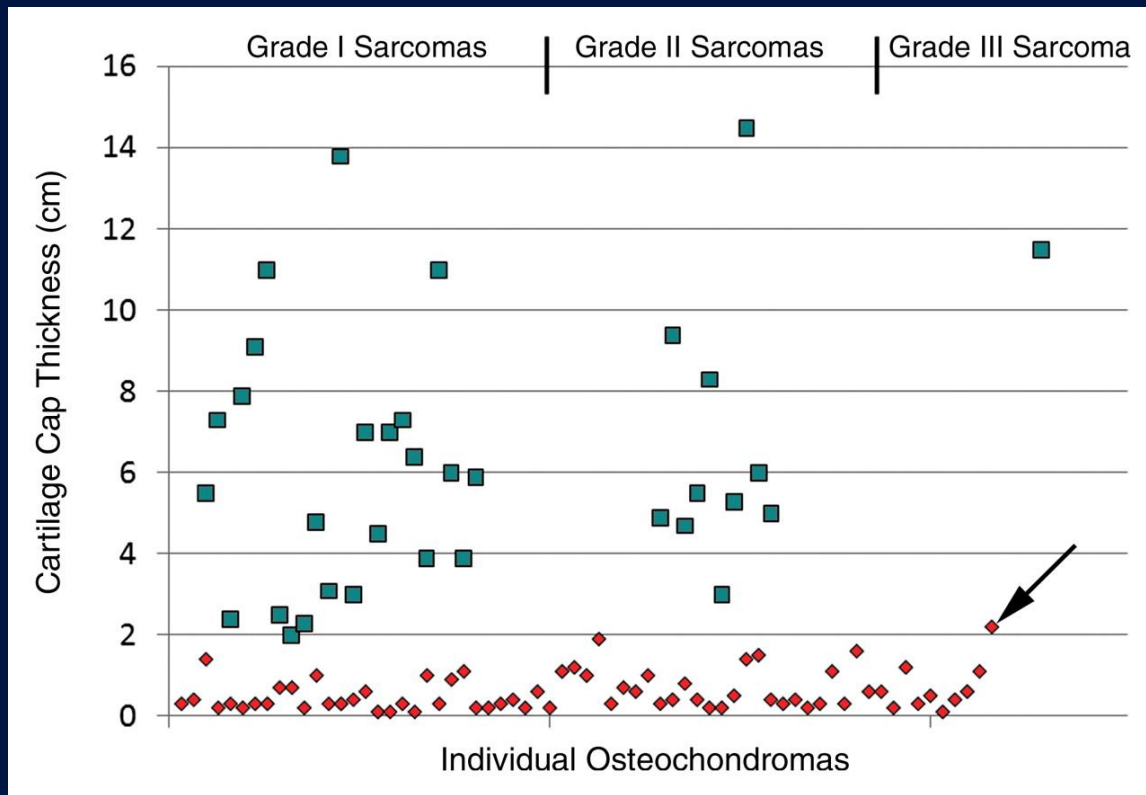


Bernard S A et al. Radiology 2010;255:857-865

# Murphey 2010 article results

- Cartilage cap thickness results:
  - Benign: 79%<1cm; 7%>1.5cm, 18%>1cm
  - Malignant: 2-14cm at CT, 2-17cm at MR; 0<2cm, 79%>3cm
- **2cm** cutoff:
  - Sens/spec = 100%/98% MR (100%/95% CT)
  - PPV/NPV = 96%/100% MR (93%/100% CT)
- If cap > 2cm at CT, confirm with MR or US to exclude bursal fluid
- Consider close surveillance of central lesions, esp pelvic osteochondromas

# Correlation of cartilage cap thickness and pathologic findings.



- Abrupt transition b/t malign (green) & benign (red) at 2cm
- Arrow = 1 exception, benign lesion of 2.2cm

Bernard S A et al. Radiology 2010;255:857-865

Radiology

# In conclusion . . .

- Reviewed imaging criteria
- Discussed imaging modalities and role in staging
- Discussed some of the most common primary malignancies and their importance in deriving useful ddx.



Washington Monument - National Cherry Blossom Festival 2010  
Photo by Brent Shepherd



# Thank you!

- Special thanks to *George Nomikos* and his excellent teaching file which he hoped I would share with all of you.



Tidal Basin, Jefferson Memorial - National Cherry Blossom Festival 2007  
Photo by Brent Shepherd

# References (in order of appearance)

- Stacy GS, Mahal RS, Peabody TD. Staging of Bone Tumors: A Review with Illustrative Examples. AJR 2006; 186:967-976.
- Davies A, Skinner JA, Saifuddin A. Surgical Staging 1: Primary Tumour. Imaging of Bone Tumors and Tumor-Like Lesions. 2009; 163-181.
- Huang AJ, Willis MH, Kattapuram SV, Bredella MA. Surgical Staging 2: Metastatic Disease. Imaging of Bone Tumors and Tumor-Like Lesions: Techniques and Applications. 2009; 183-98.
- Daldrup-Link, et al. Whole Body MRI for Detection of Bone Metastases in Children and Young Adults: Comparison with Skeletal Scintigraphy and FDG PET. AJR 2001; 177:229-336.
- Kayser F, et al. Evidence of the Subperiosteal Origin of Osteoid Osteomas in Tubular Bones: Analysis by CT and MR Imaging. AJR 1998;170:609-614.
- Murphey MD. AFIP Course Notes 1997.
- Murphey MD, et al. From the Archives of the AFIP. The Many Faces of Osteosarcoma. RG 1997;17:1205-1231.
- [http://seer.cancer.gov/publications/aya/8\\_bone.pdf](http://seer.cancer.gov/publications/aya/8_bone.pdf)
- Murphey MD, et al. Telangiectatic Osteosarcoma: Radiologic-Pathologic Comparison. Rad 2003; 229:545-553.
- Jelinek JS, et al. Parosteal Osteosarcoma: Value of MR Imaging and CT in the Prediction of Histologic Grade. Rad 1996; 201:837-842.
- Murphey MD, et al. Imaging of Periosteal Osteosarcoma: Radiologic-Pathologic Comparison. Rad 2004; 233:129-138.
- Murphey MD, et al. From the Archives of the AFIP. Imaging of Primary Chondrosarcoma: Radiologic-Pathologic Correlation. RG 2003; 23:1245-1278.