

Ankle Impingement Syndromes

Vaibhav C. Khasgiwala, MD

Outline

- Review basic ligamentous anatomy
- Important anatomic variations as they relate to impingement syndromes
- Review the major impingement syndromes
- Summary

Introduction

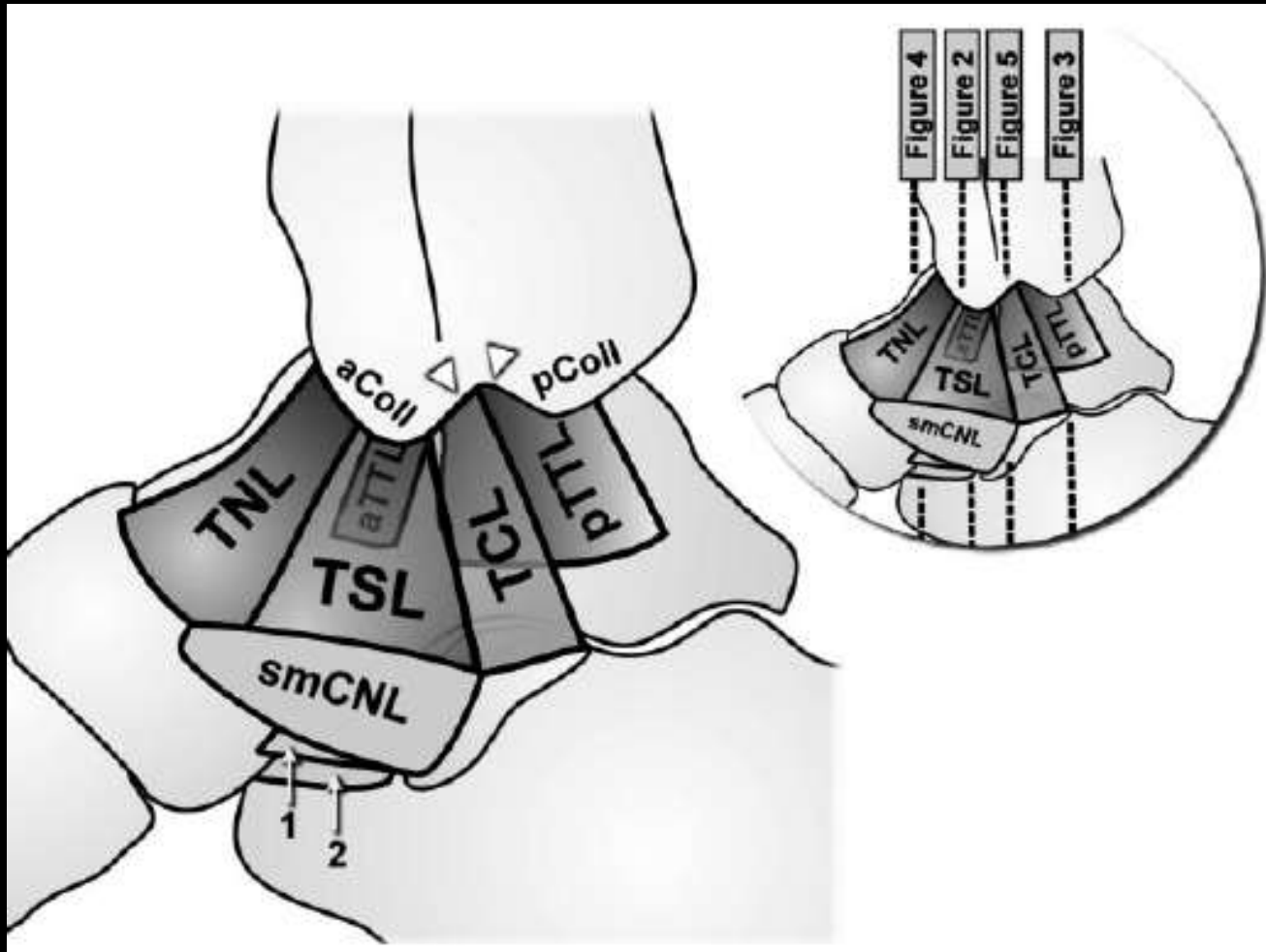
- Anterior impingement first described by Morris in 1943 – “athlete’s ankle.” Again described in the 1950’s by Wolin, et al. in patients with AL ankle pain following inversion injury
- Now recognized as an important cause of chronic ankle pain. Demographics include men/women, athletes/non-athletes of varying ages
- “Impingement” refers to a limitation of ROM of the talus. Initial injury leads to further pathology in the subacute/chronic stages

Introduction, cont.

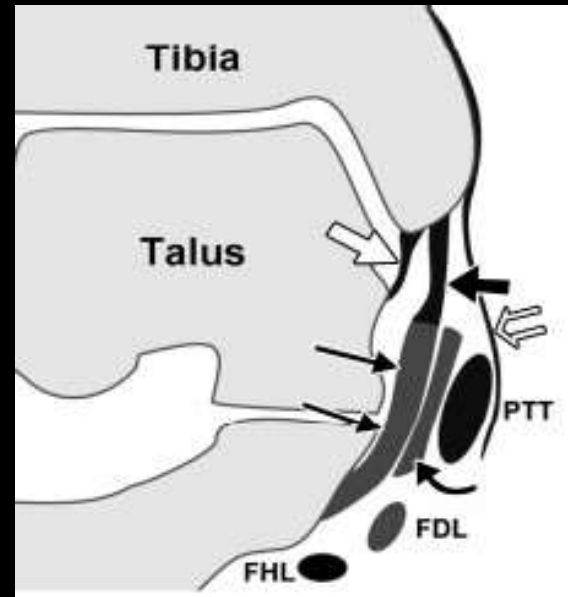
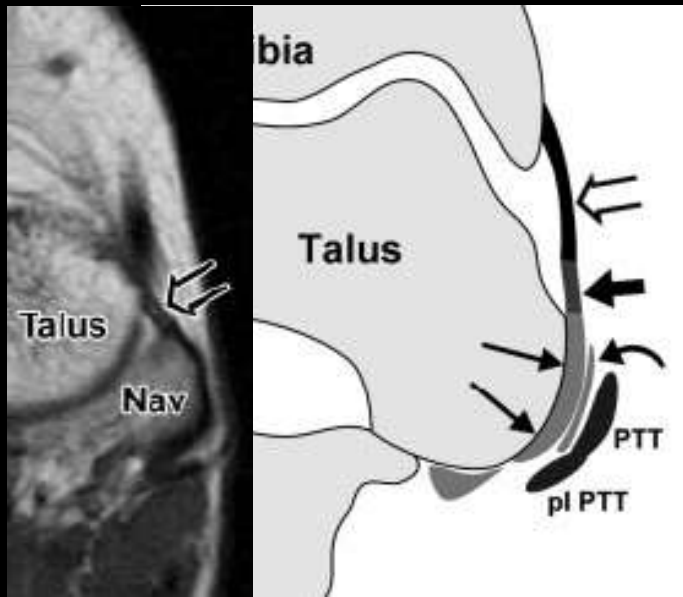
- Impingement may be related to abnormal bony or soft tissue structures
- Various categories
 - Anterior
 - Anteromedial / Anterolateral
 - Posterior
 - Posteromedial
 - Posterolateral

Ankle Ligaments

- Syndesmotic
 - Interosseous ligament
 - Anterior/posterior tibiofibular
 - Transverse tib-fib ligament
- Lateral
 - Anterior / posterior talofibular
 - Calcaneofibular
- Medial
 - Superficial [tibionavicular, tibiospring, tibiocalcaneal]
 - Deep [deep anterior and deep posterior tibiotalar]

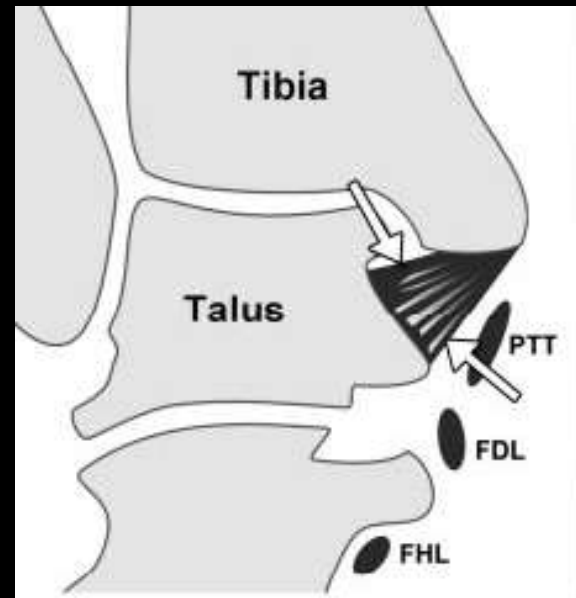
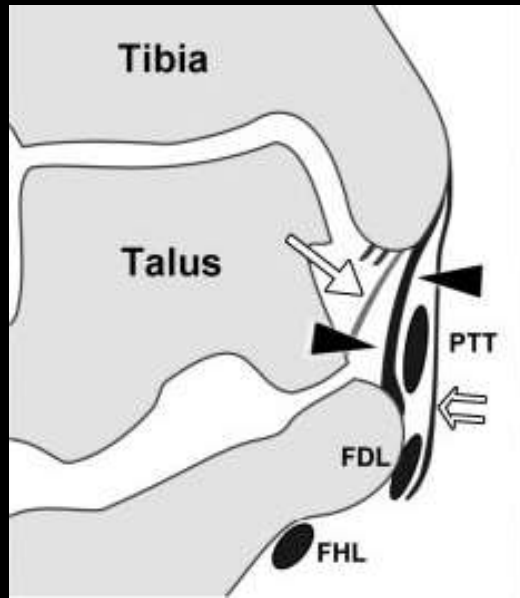


Mengiardi B, et al. Medial Collateral Ligament Complex of the Ankle: MR Appearance in Asymptomatic Subjects. Radiology 2007; 242: 817-824



The TNL (open arrow) originates from the anterior border of the anterior colliculus and inserts onto the dorsomedial surface of the navicular. The most anterior portions of the TSL are in continuity with the TNL and the superomedial calcaneonavicular ligament portion of the spring ligament complex.

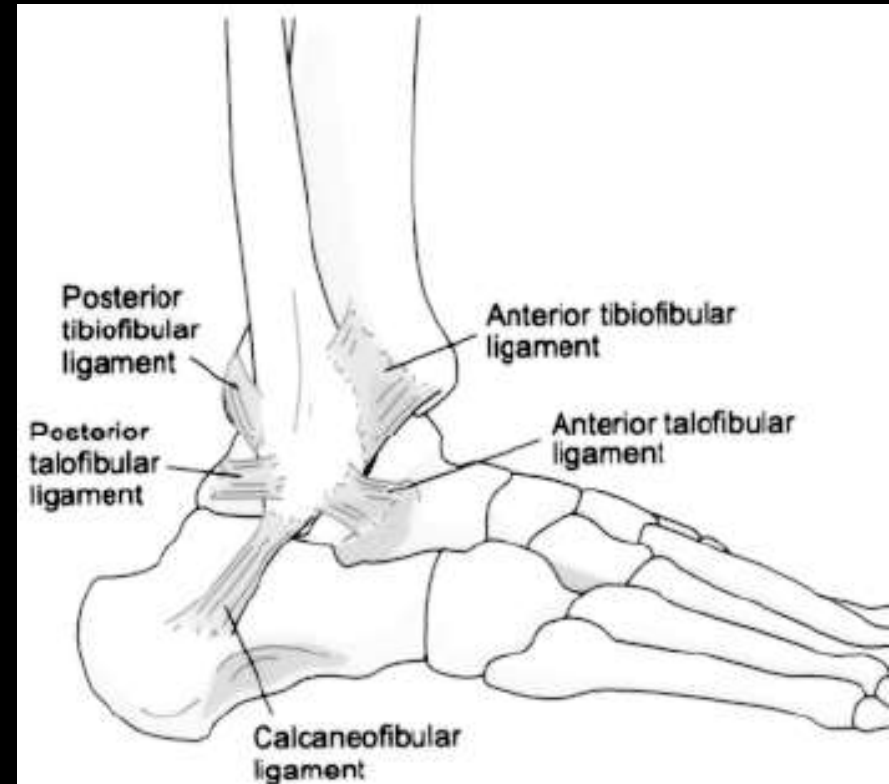
The TSL originates from the anterior segment of the anterior colliculus and inserts on the superomedial calcaneonavicular ligament. The anterior TTL is situated underneath the TSL, originates from the tip of the anterior colliculus and the anterior part of the intercollicular groove, and inserts on the medial surface of the talus just distal to the anterior part of the medial talar articular surface.



The TCL originates from the medial aspect of the anterior colliculus and inserts onto the medial border of the sustentaculum tali.

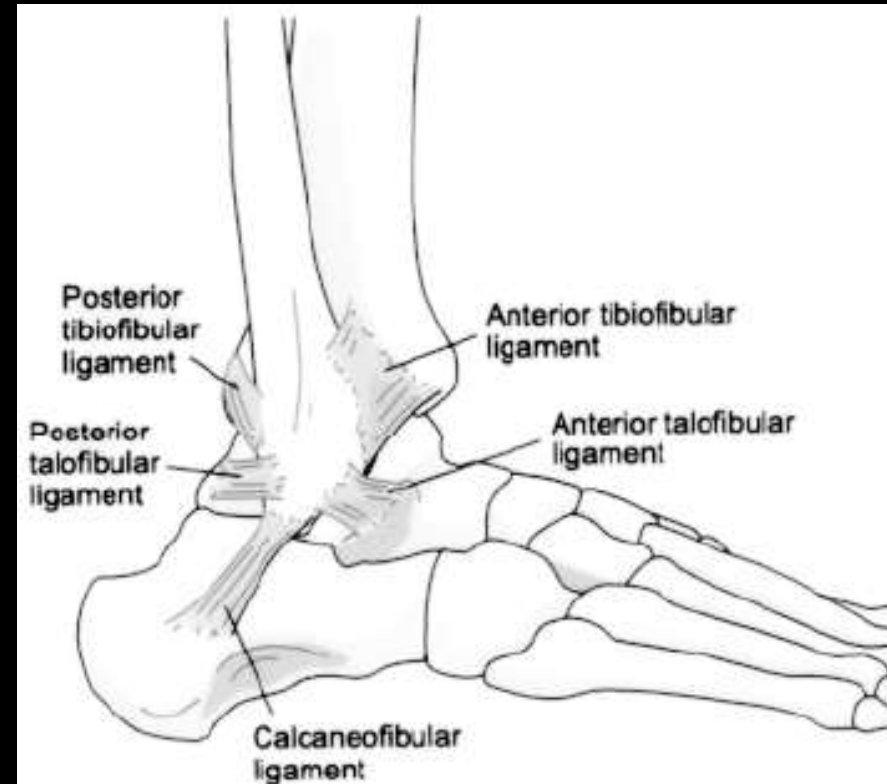
Posterior TTL originates from the upper segment of the posterior surface of the anterior colliculus, the intercollicular groove, and the anterior surface of the posterior colliculus. The fibers insert onto the medial surface of the talus.

- ATiF: AL surface of tibia (Chaput tubercle) to adjacent anterior fibula; multiple fascicles
- PTiF: PL tibia (including posterior tubercle) to adjacent posterior fibula
- Transverse: posterior tibia to upper part of lateral malleolar fossa in PI fibula

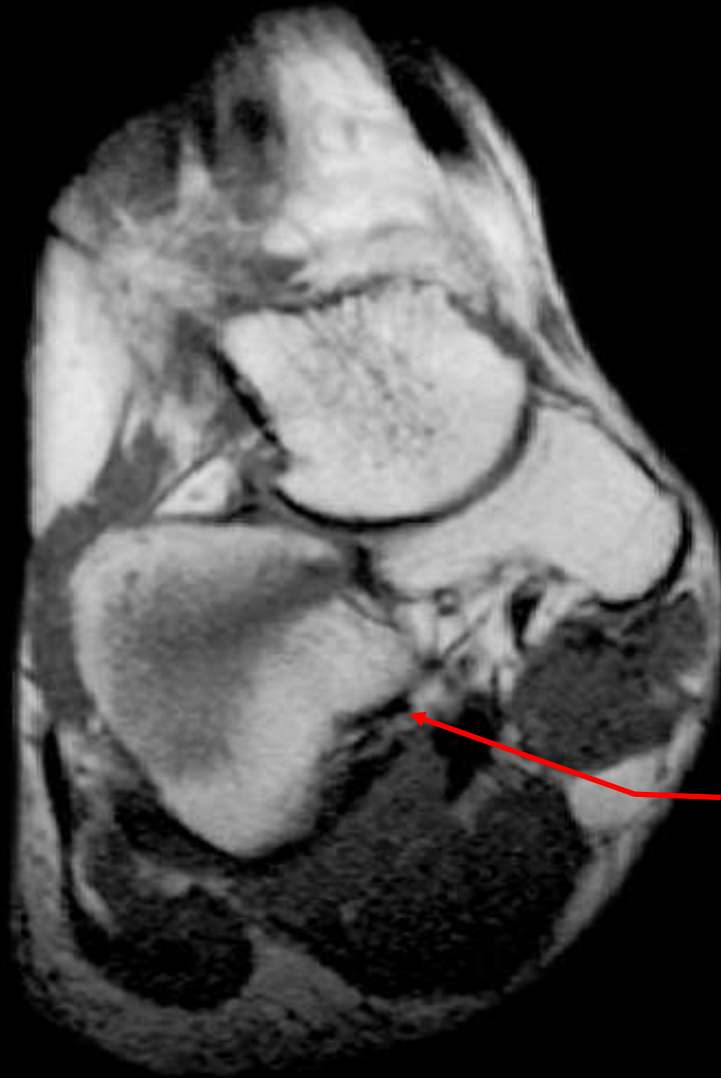


Muhle C, et al. Collateral Ligaments of the Ankle; High Resolution MRI with a Local Gradient Coil & Anatomic Correlation in Cadavers. Radiographics 1999

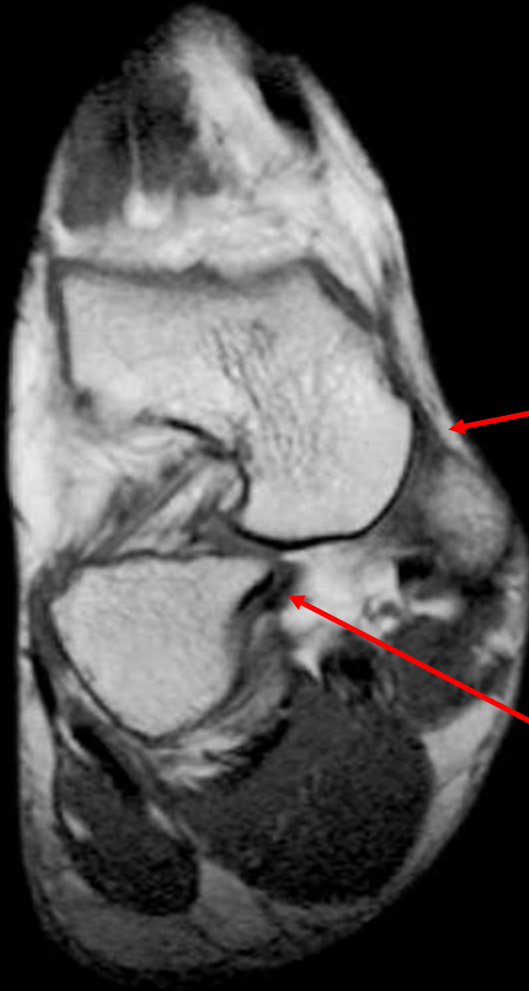
- ATaF: anterior fibular margin to lateral articular facet and lateral aspect of talus
- PTaF: lower part of fossa of lateral malleolus to lateral tubercle of posterior process of talus
- Calc-fib: extends from depression in front of apex of lateral malleolus to lateral surface of calcaneus. Crosses 2 joints



Muhle C, et al. Collateral Ligaments of the Ankle; High Resolution MRI with a Local Gradient Coil & Anatomic Correlation in Cadavers. Radiographics 1999

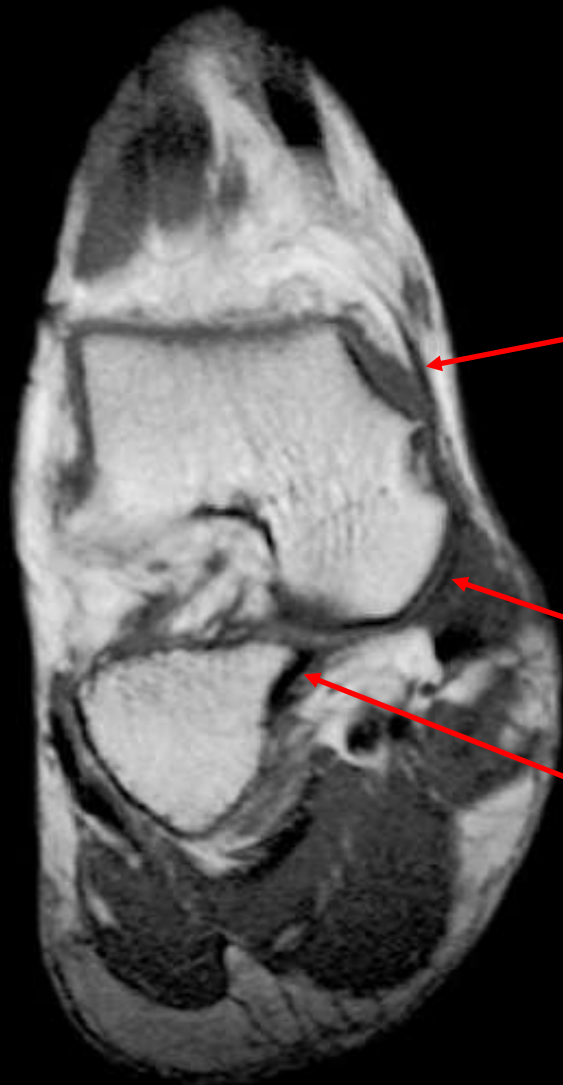


Inferoplantar
Longitudinal
Spring



Tibionavicular

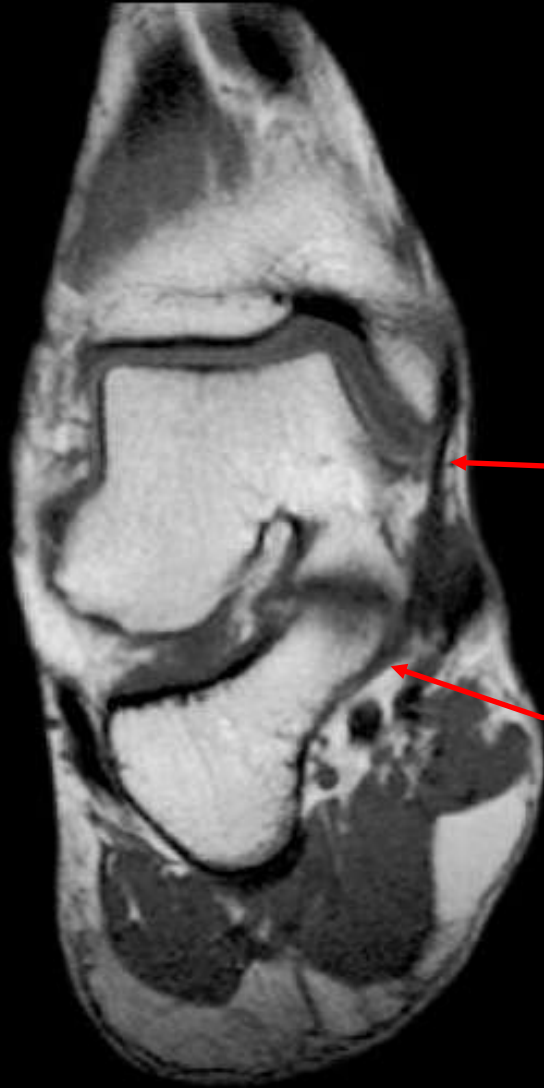Mediolplantar
Oblique Spring



Deep Anterior
Tibiotalar

Superomedial
Spring

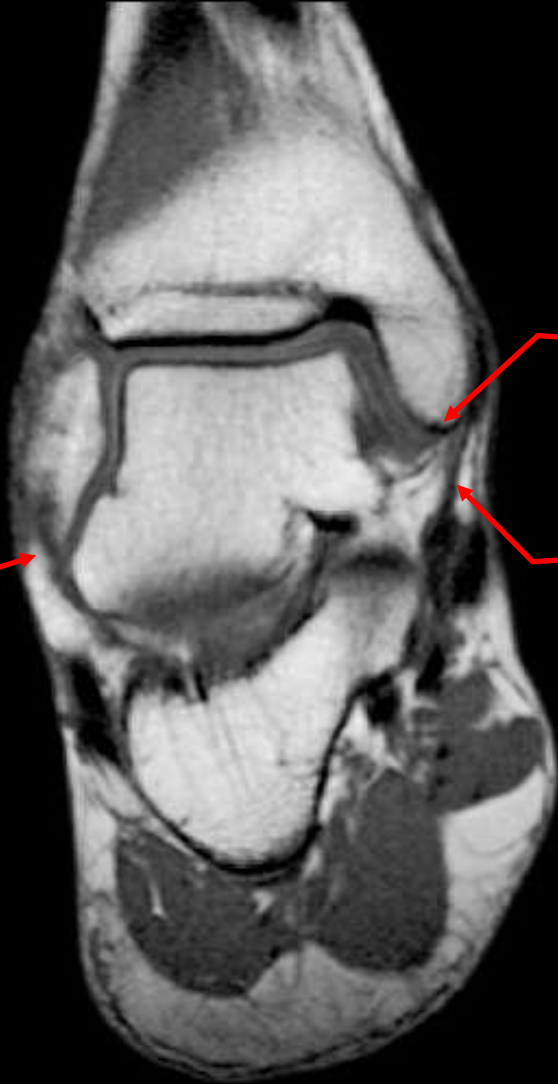
Mediolateral
Oblique Spring



Tibiospring

Superomedial
Spring

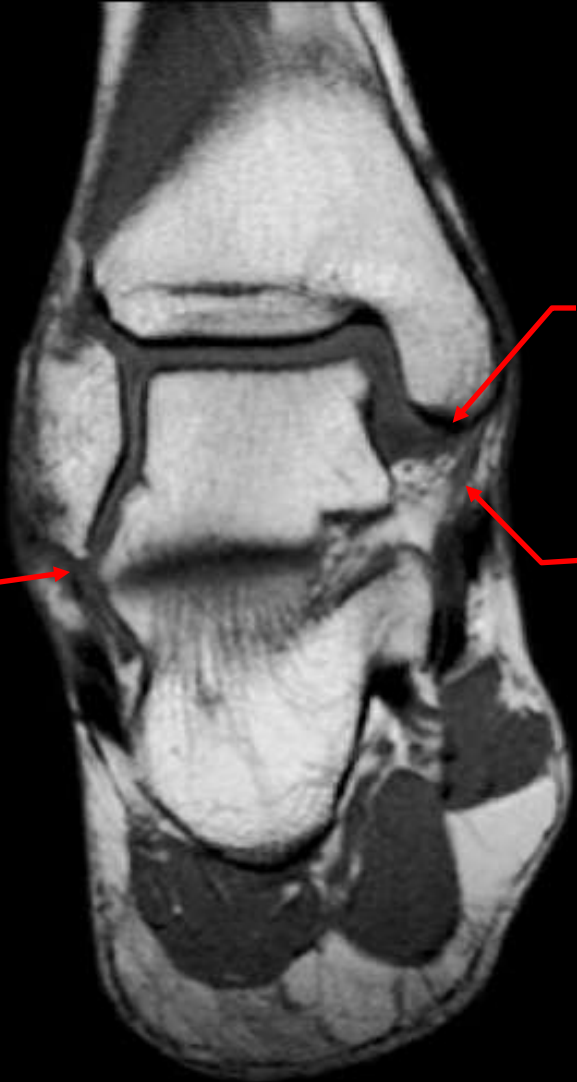
Calcaneofibular



Deep Anterior
Tibiotalar

Tibiocalcaneal

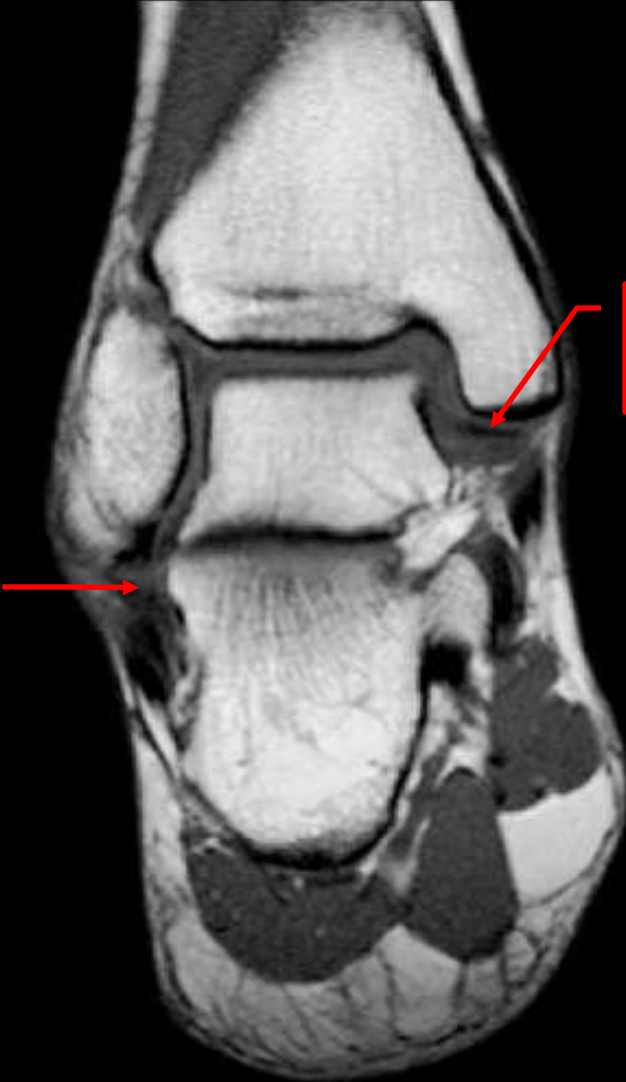
Calcaneofibular



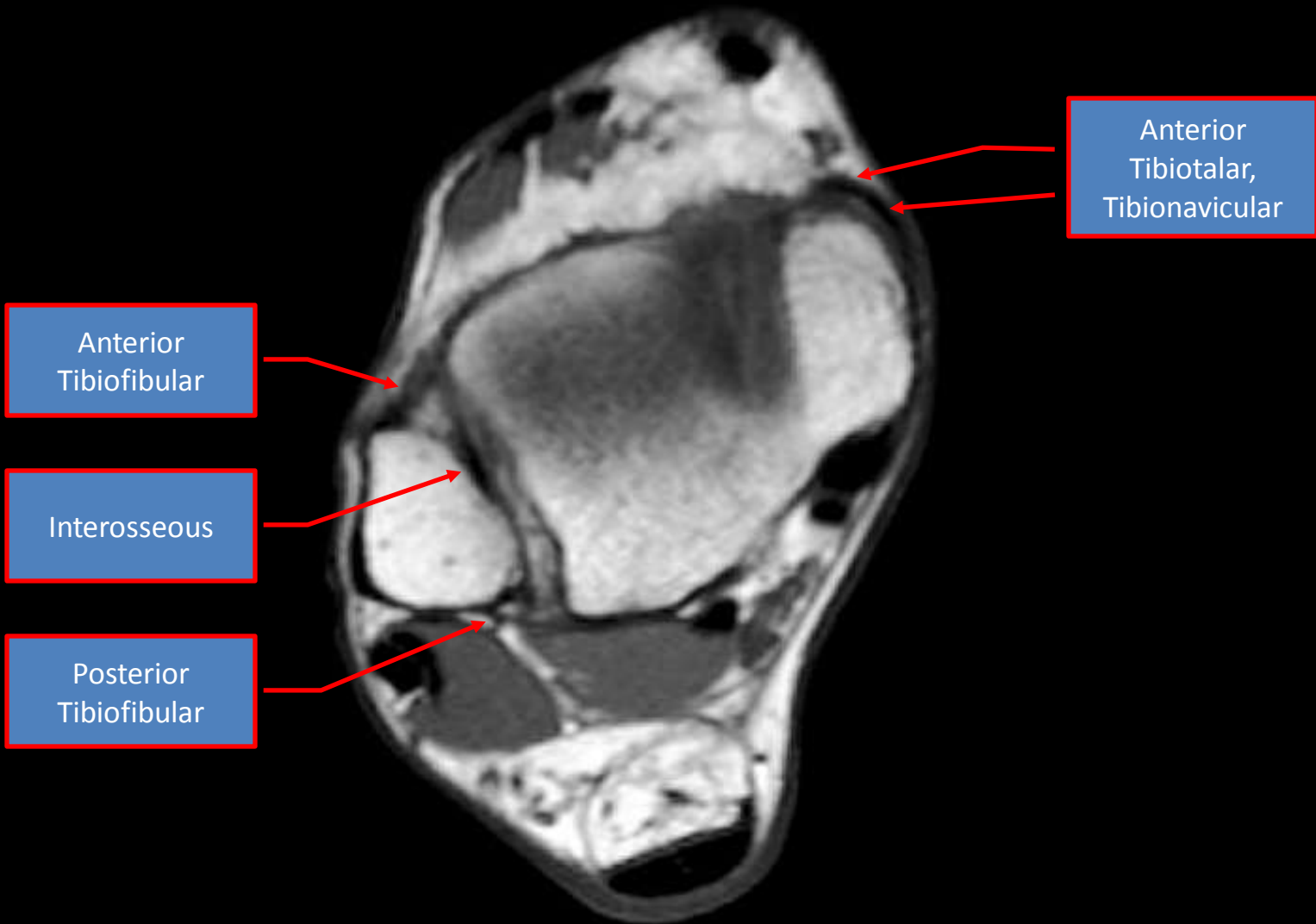
Deep Posterior Tibiotalar

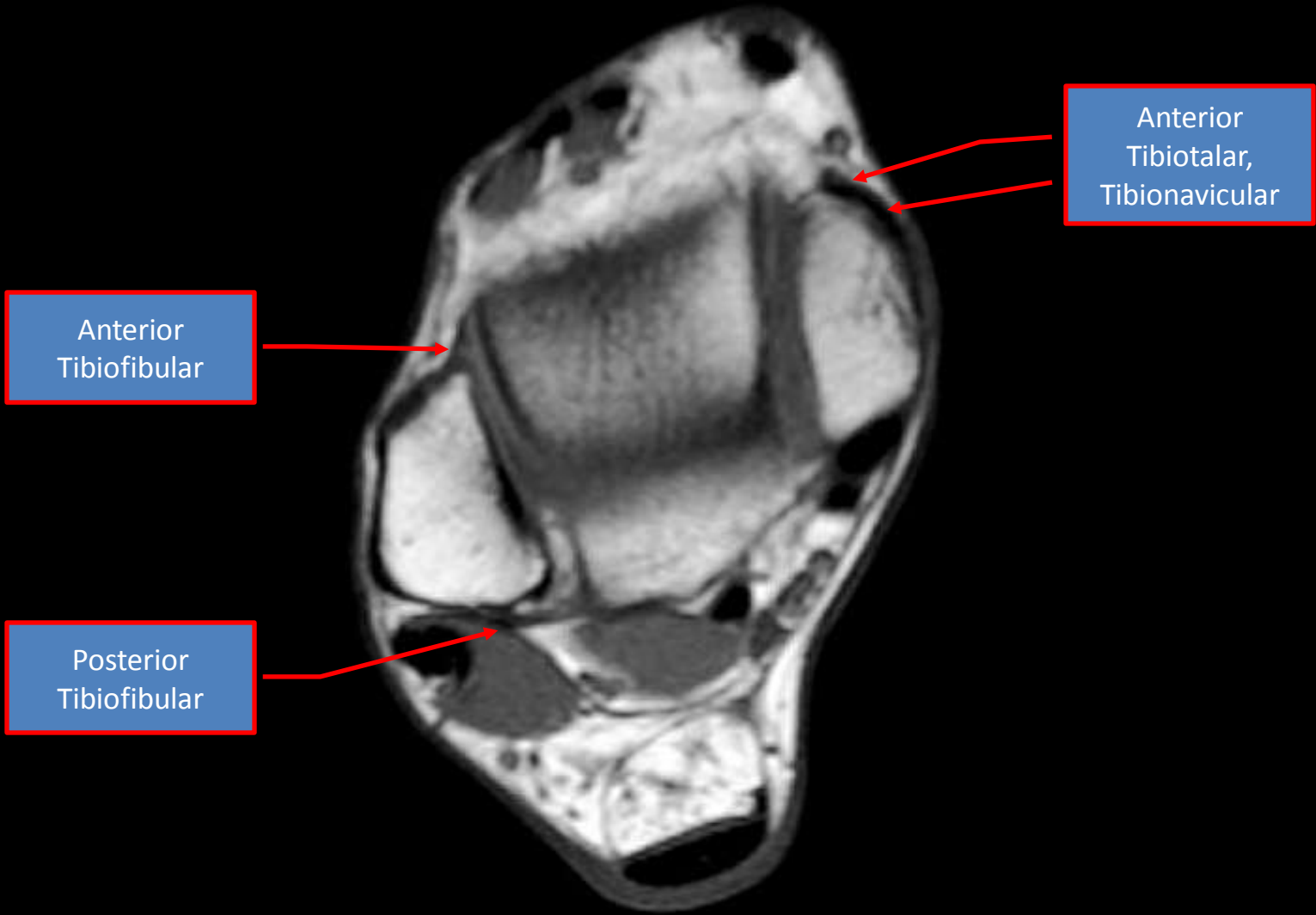
Tibiocalcaneal

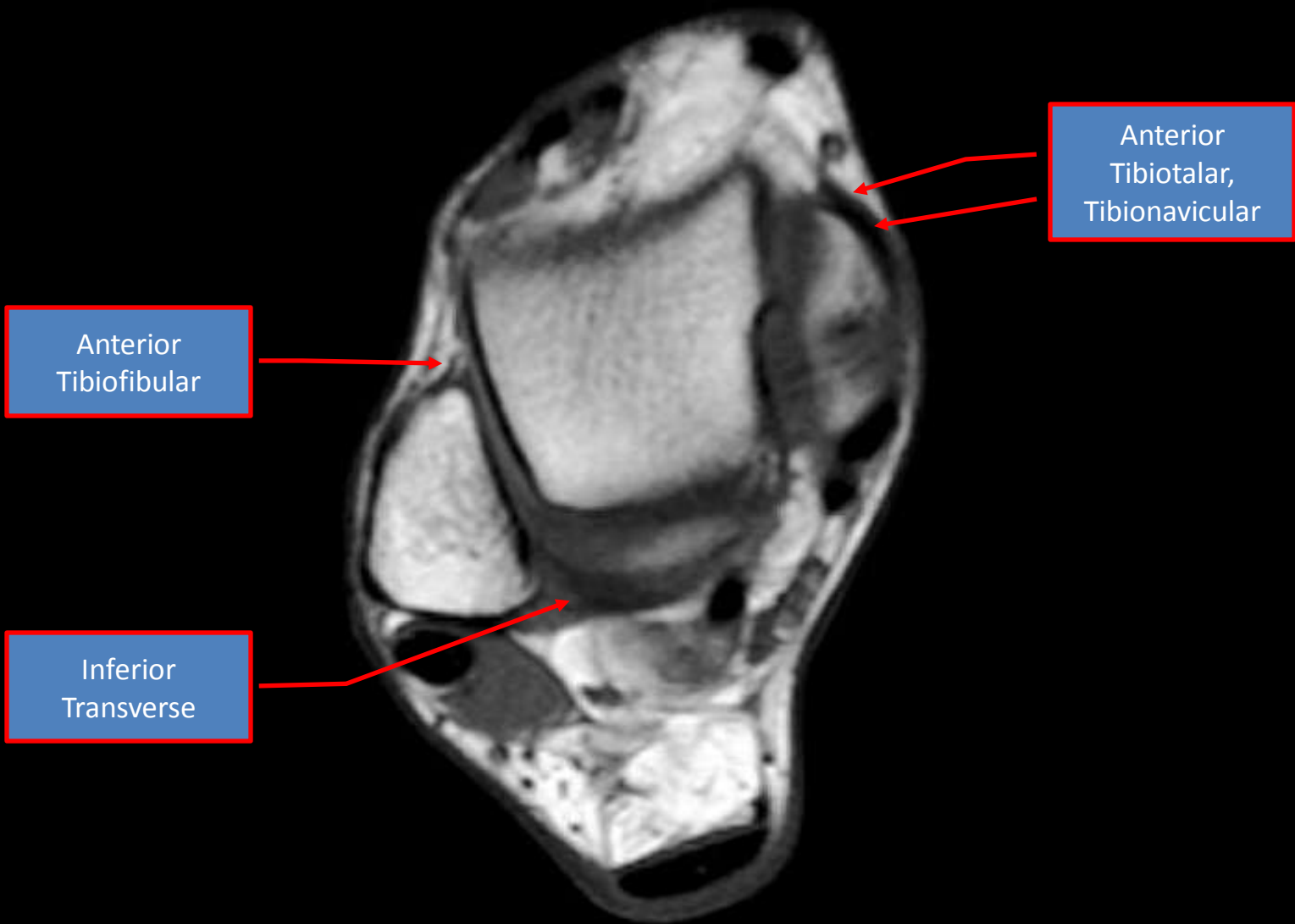
Calcaneofibular

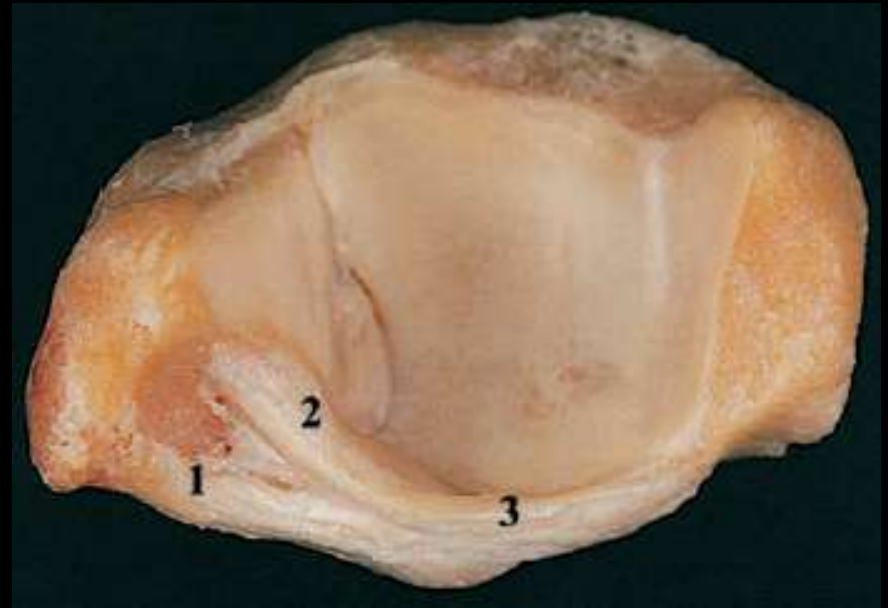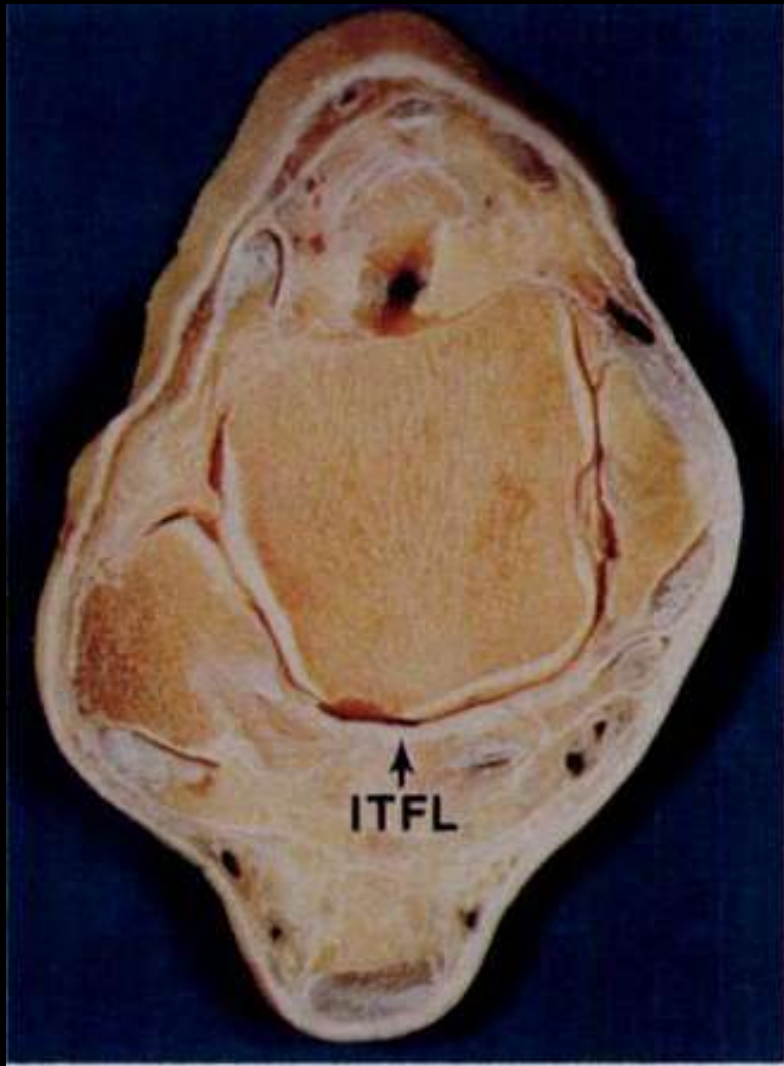


Deep Posterior Tibiotalar

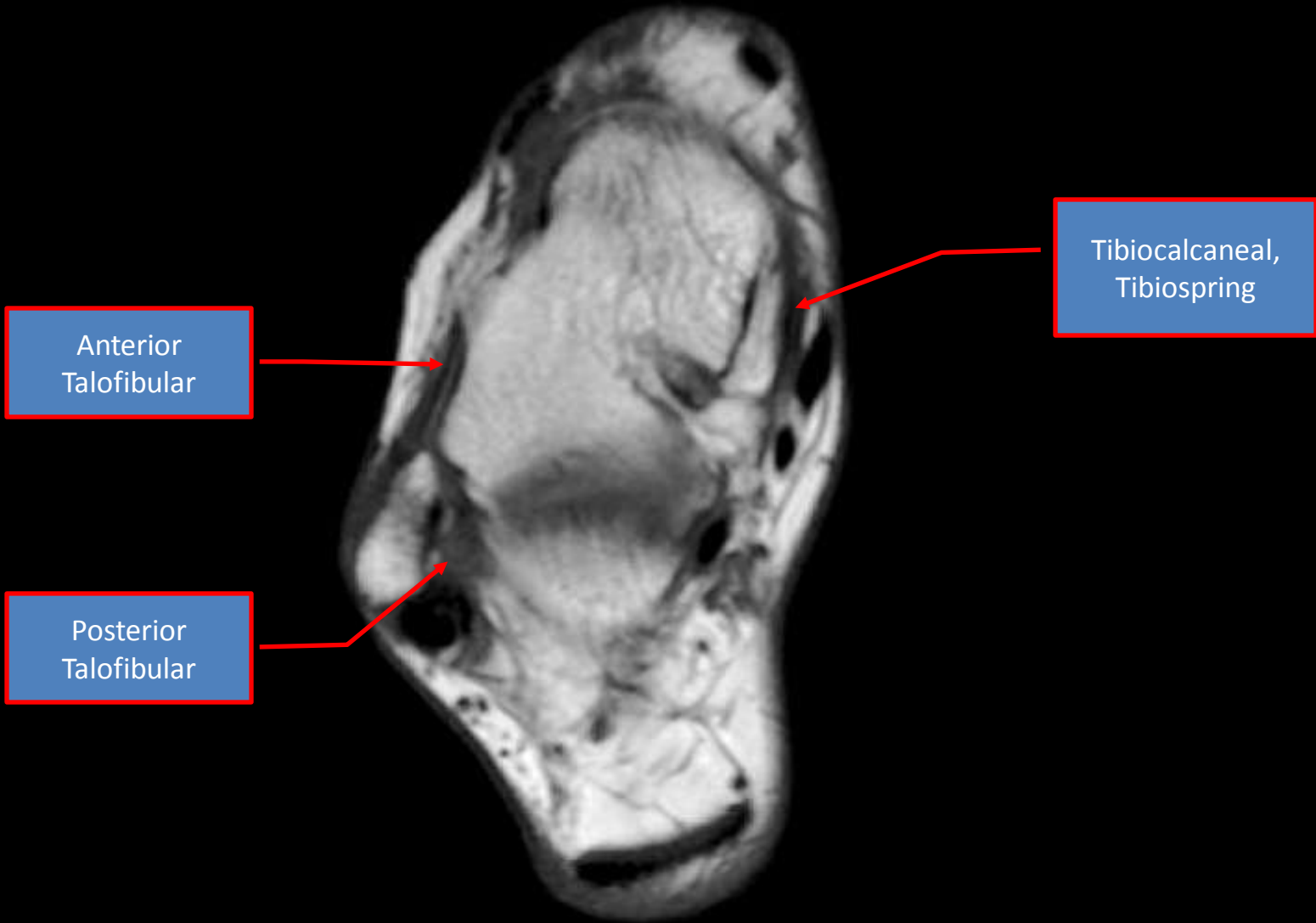








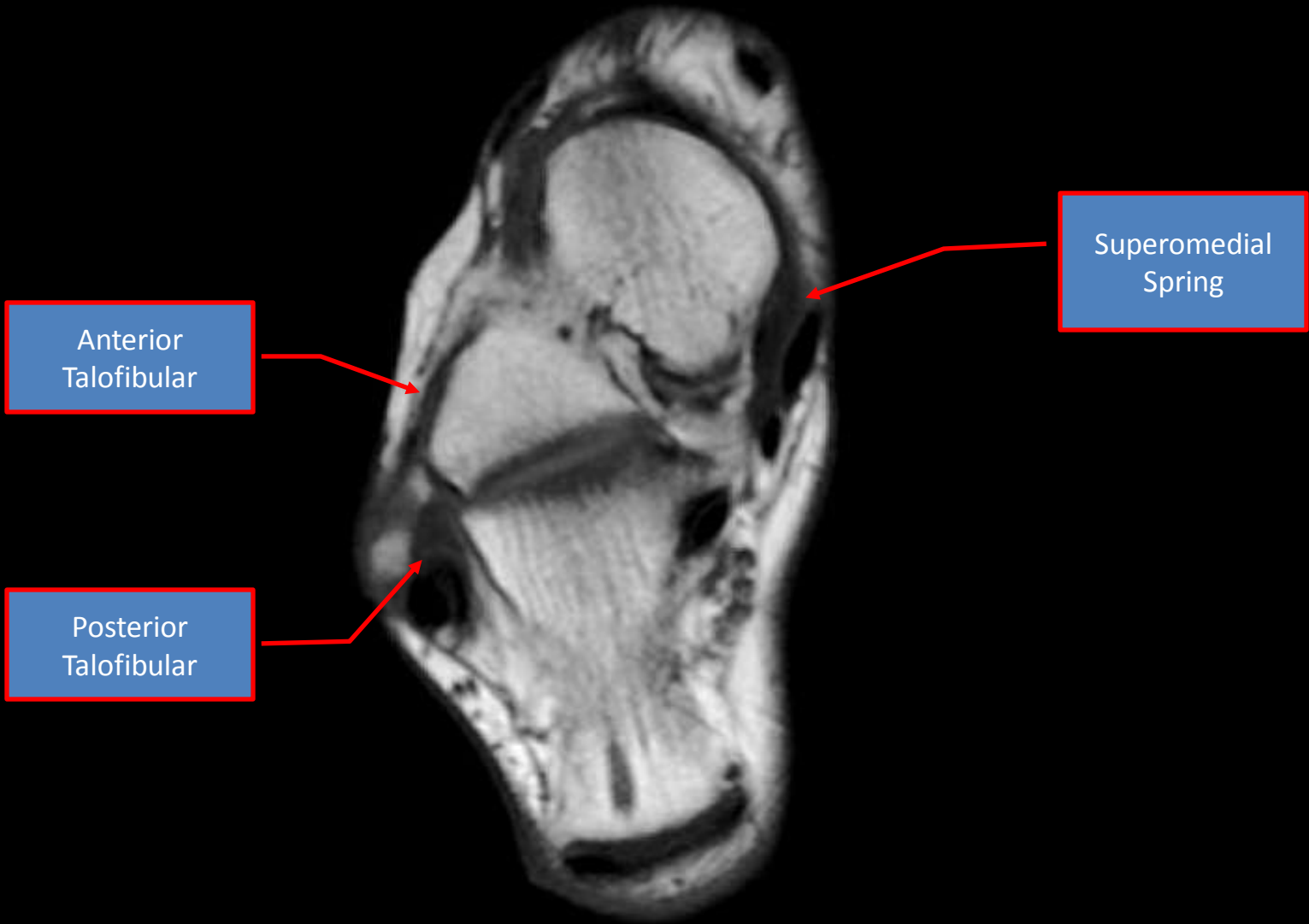
Schneck et al. MR Imaging of the Most Commonly Injured Ankle Ligaments. Radiology 1992
Golano P, et al. Arthroscopic anatomy of the posterior ankle ligaments. Arthroscopy 2002;



Anterior
Talofibular

Posterior
Talofibular

Tibiocalcaneal,
Tibiospring

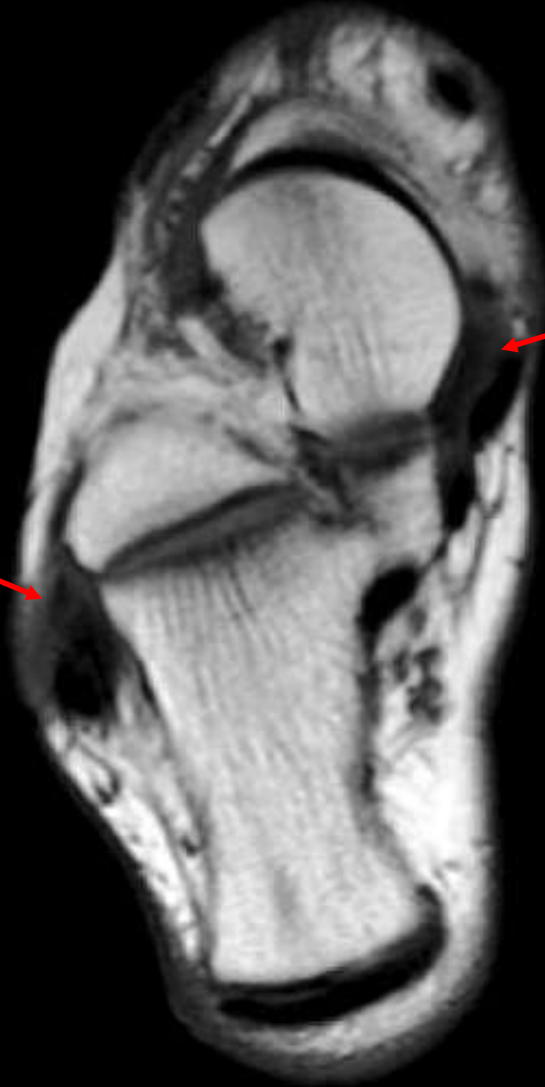

Anterior
Talofibular

Posterior
Talofibular

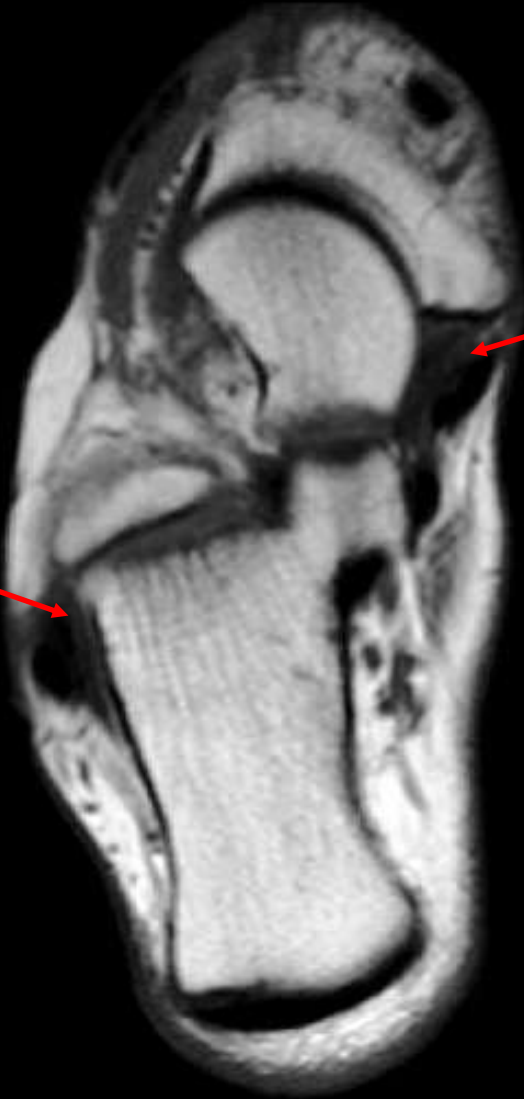Superomedial
Spring

Calcaneofibular

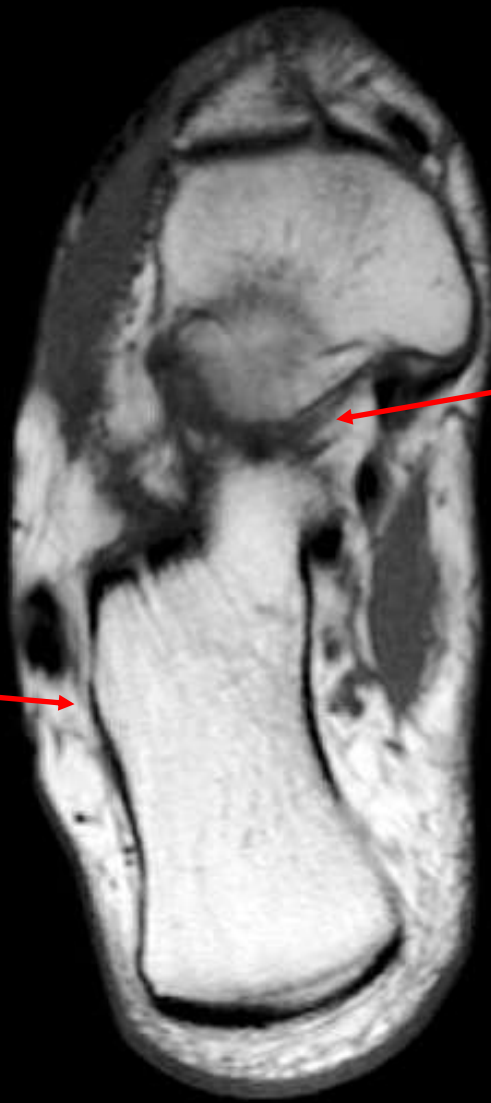


Superomedial Spring

Calcaneofibular



Superomedial
Spring



Calcaneofibular

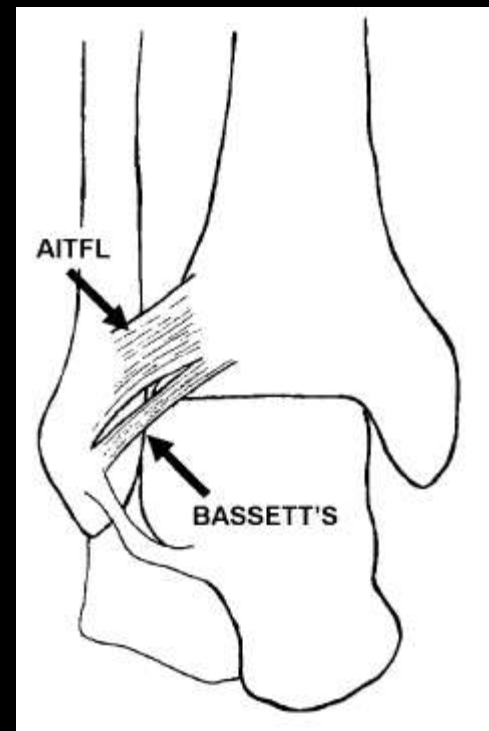
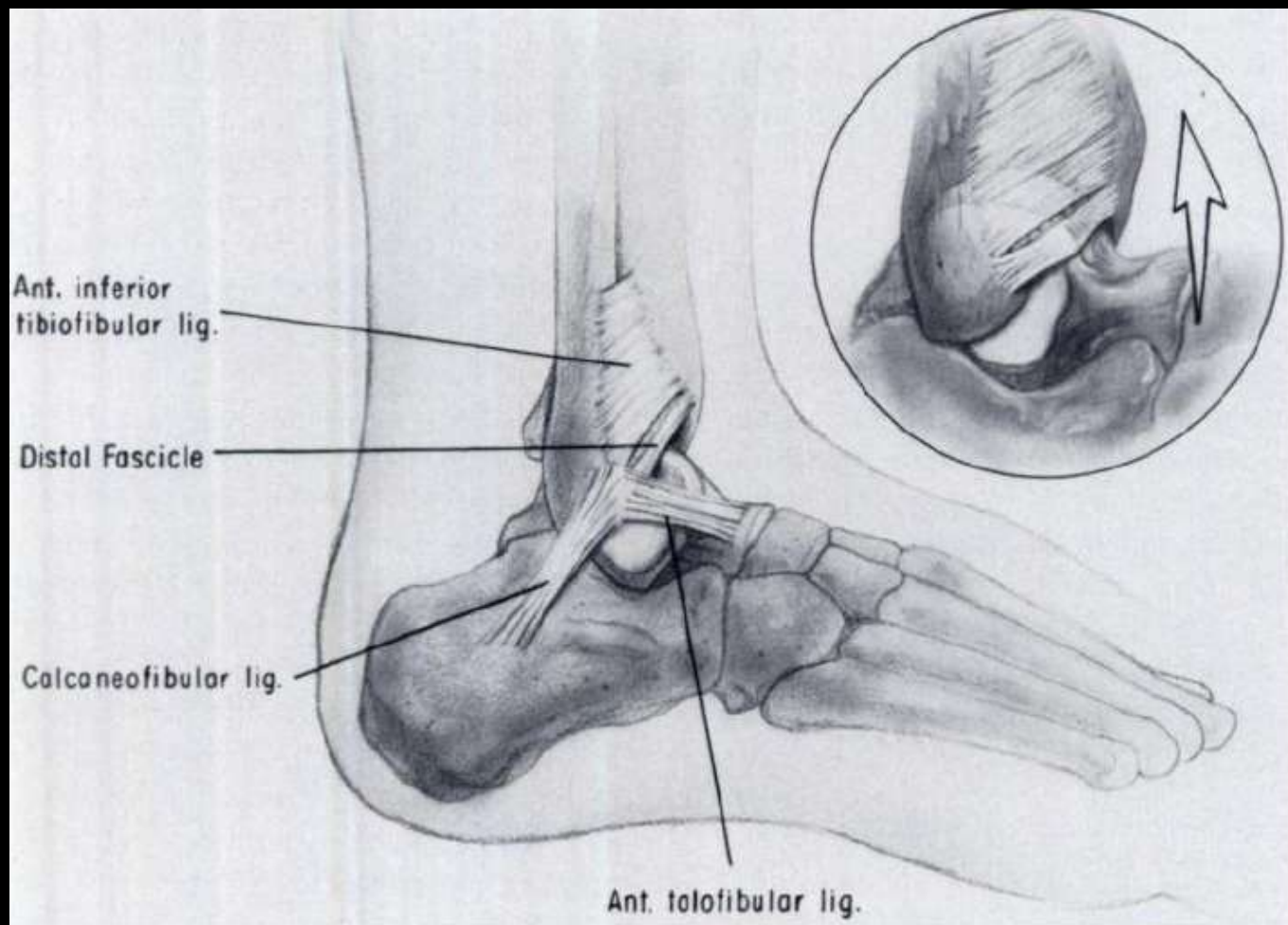
Medial Plantar
Oblique Spring

Anatomic Variations

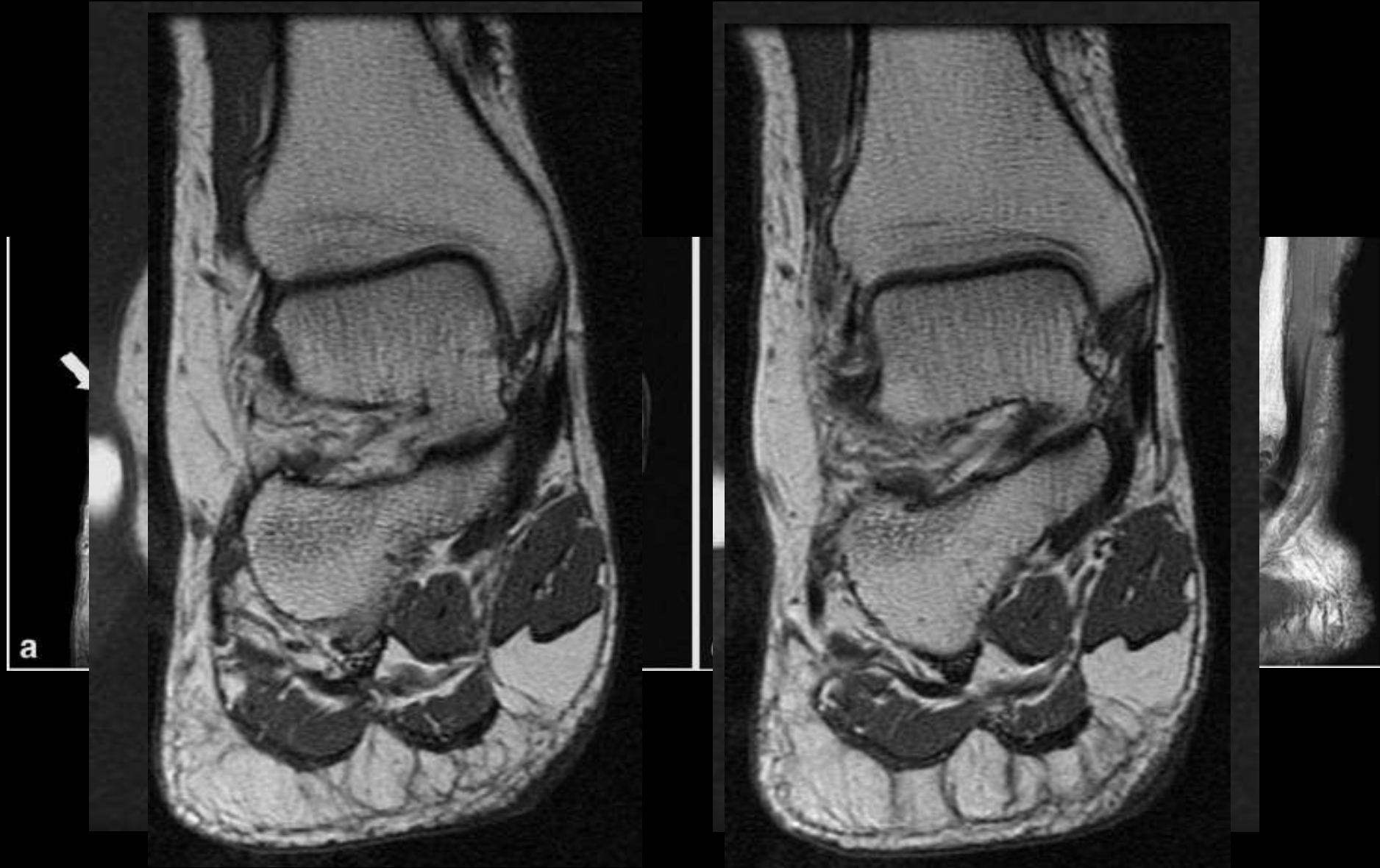
- Anterior tibiofibular ligament (Bassett ligament)
 - Accessory fasicle vs distal fasicle
- Posterior intermalleolar ligament / tibial slip

Anterior Tibiofibular Ligament

- 1982 Nikolopoulos described what he termed an “accessory fasicle” of the anterior tib-fib
- Parallel and inferior to the distal margin of the ATiFL and separated by a fibrofatty septum
- 1990 Bassett functional/anatomical study where they concluded that ligament was a normal distal fasicle
- Postulated that the fasicle causes impingement after inversion injuries, maybe because of instability caused by injury to ATaFL causing anterior extrusion of talus in dorsiflexion



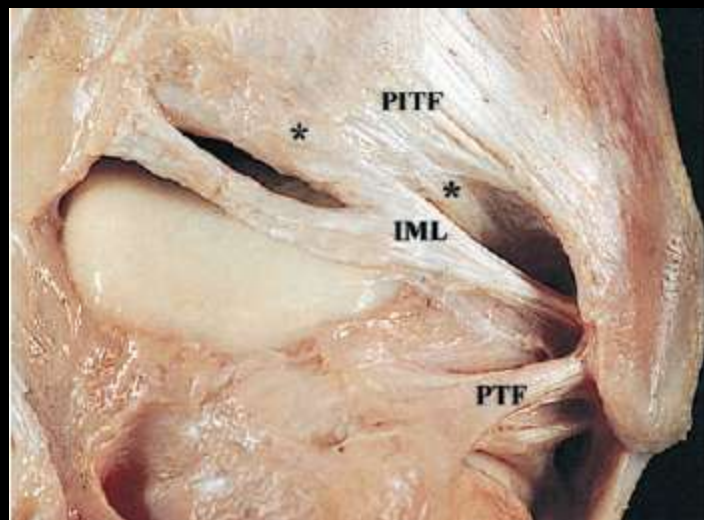
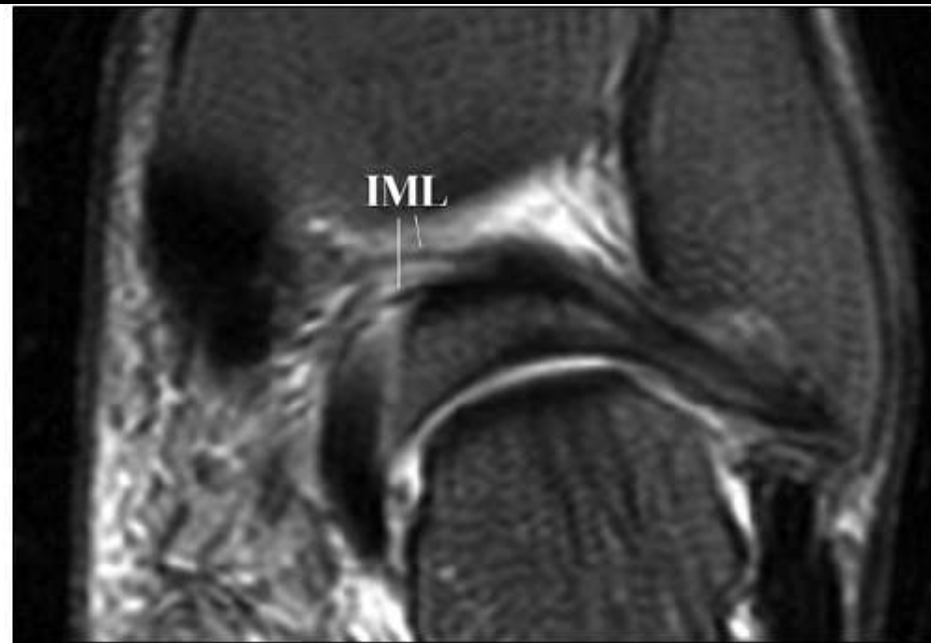
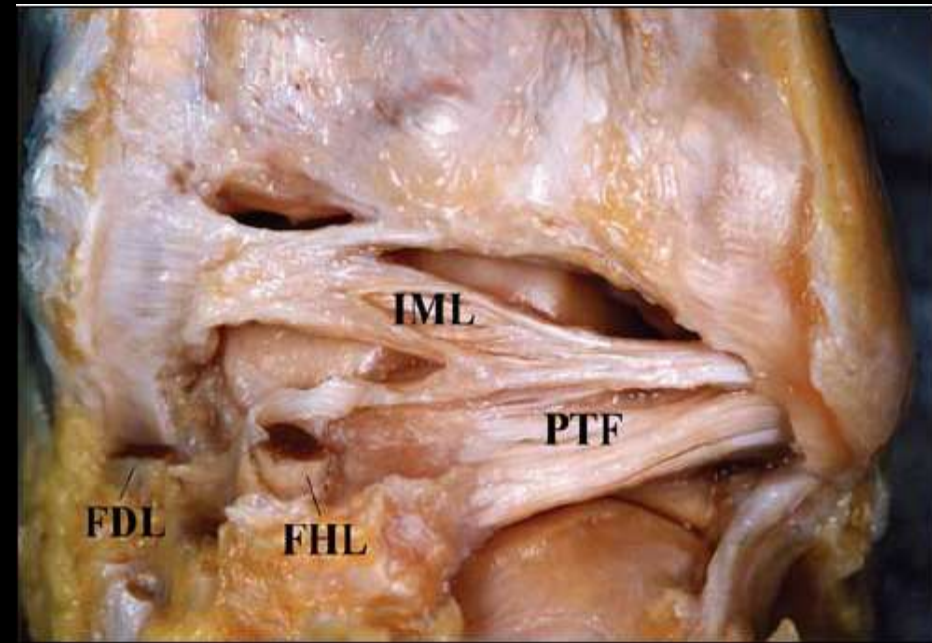
Bassett F. Talar Impingement by the anteroinferior tibiofibular ligament. JBJS 1990



Subhas, N. MRI appearance of surgically proven abnormal anteroinferior tibiofibular ligament (Bassett's ligament). Skeletal Radiology 2008

Posterior Intermalleolar Ligament

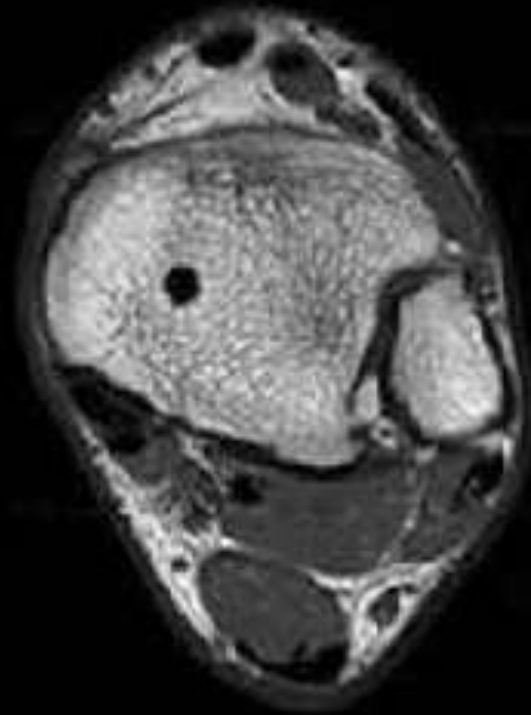
- Confusing nomenclature – IML vs tibial slip
- Entrapment / tearing of the ligament may be a cause of posterior impingement
- Oh et al describe IML as separate from the tibial slip
 - IML seen routinely and has more than 2 fiber bundles
 - Arises from various sites on medial malleolar sulcus
 - Laterally converges into discrete cord separate from PTFL
 - Tibial slip seen in 10% of cases and laterally converges onto PTFL



Oh, et al. Anatomic Variations & MRI of the Intermalleolar Ligament. AJR 2006
Golano, et al. Arthroscopic Anatomy of the Posterior Ankle Ligaments. Arthroscopy 2002

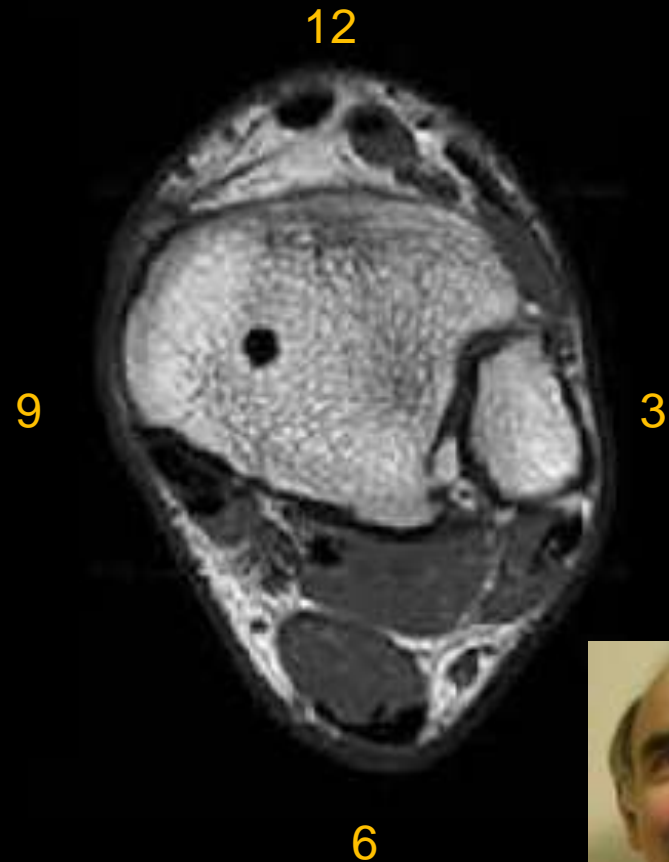
Ankle Impingement

- Anterior
- Anterolateral
- Anteromedial
- Posterior
- Posteromedial
- Posterolateral



Ankle Impingement

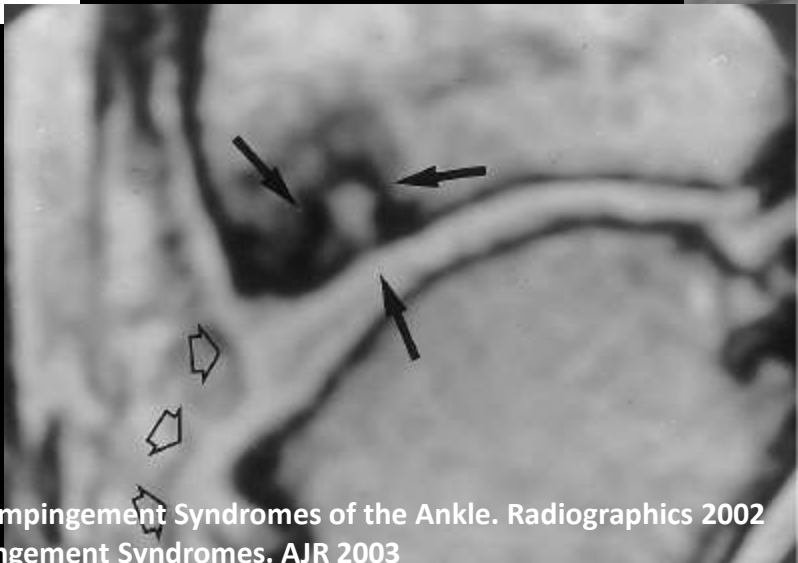
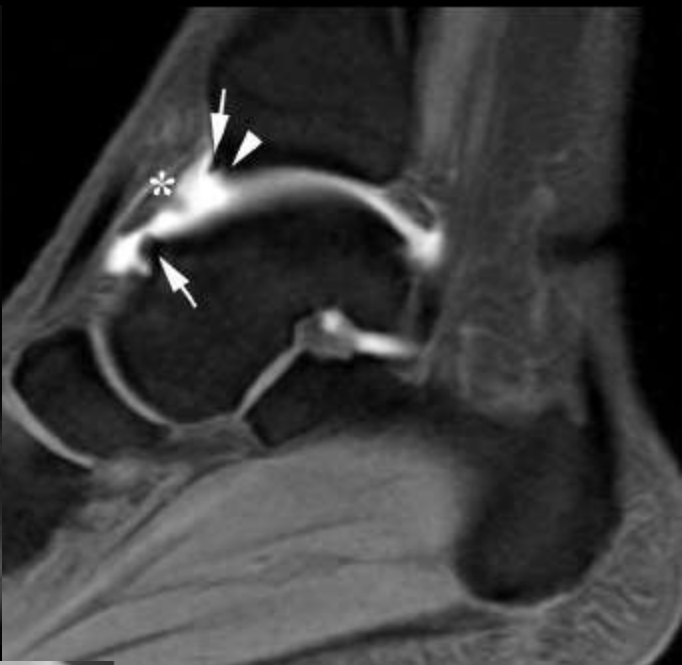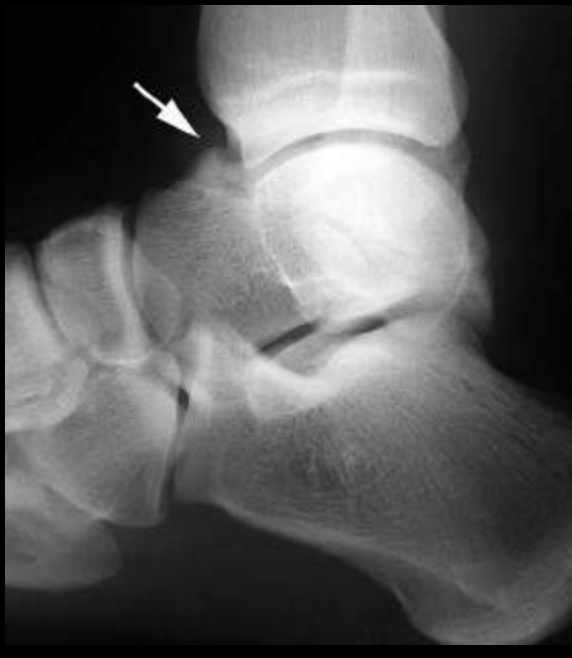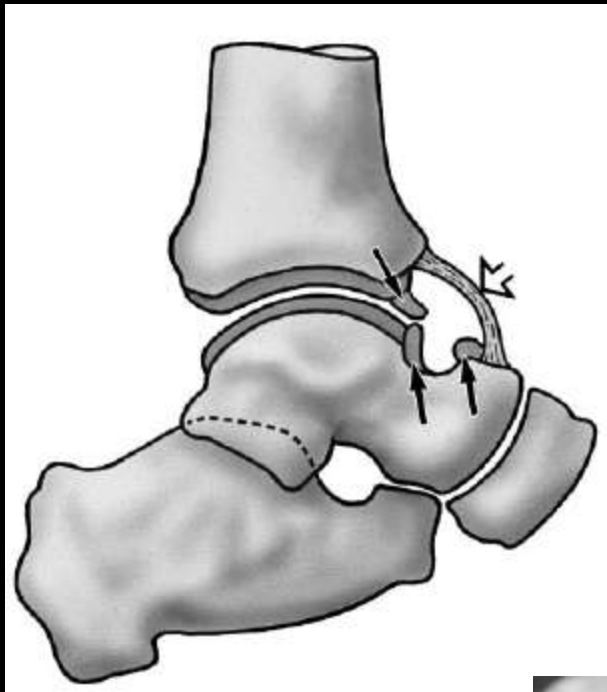
- Anterior
- Anterolateral
- Anteromedial
- Posterior
- Posteromedial
- Posterolateral



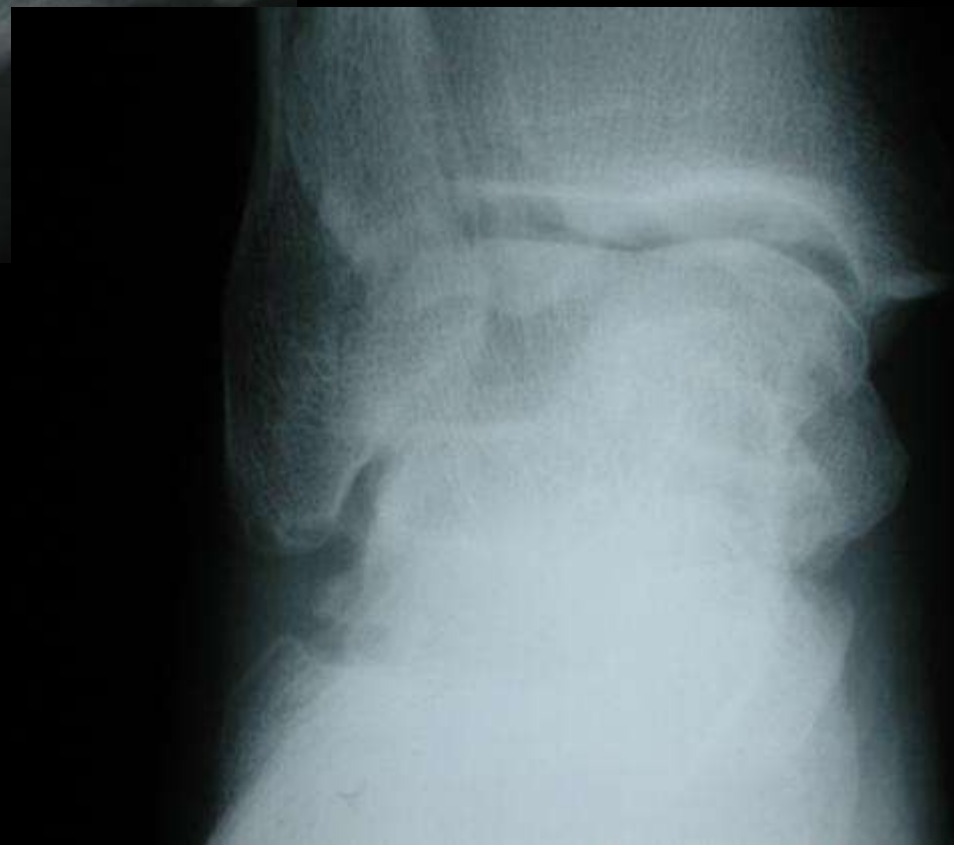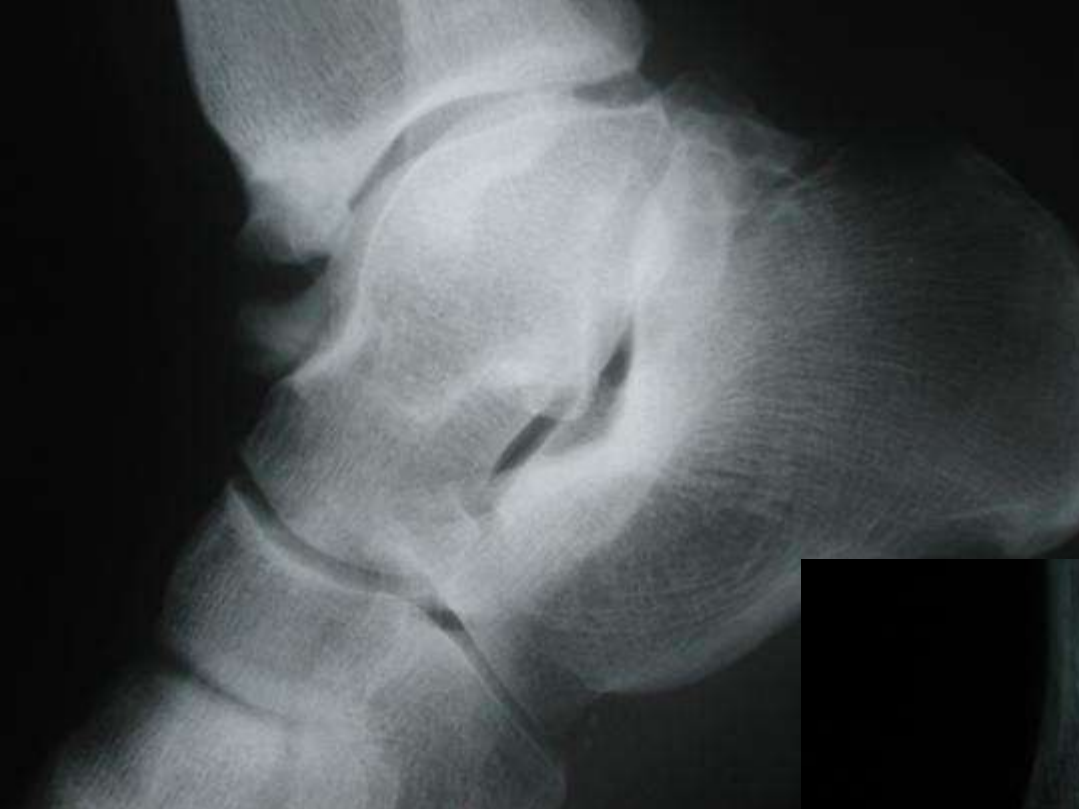Anterior Impingement

- Relatively common, well recognized cause of anterior ankle pain
- “Spurs” on anterior tibial plafond and talus; intracapsular
- Theories:
 - Repetitive dorsiflexion microtrauma (ballet, soccer)
 - supination causing anterior/medial cartilage damage and proliferative fibrosis
 - repetitive direct trauma
 - capsular avulsion from forced plantar flexion

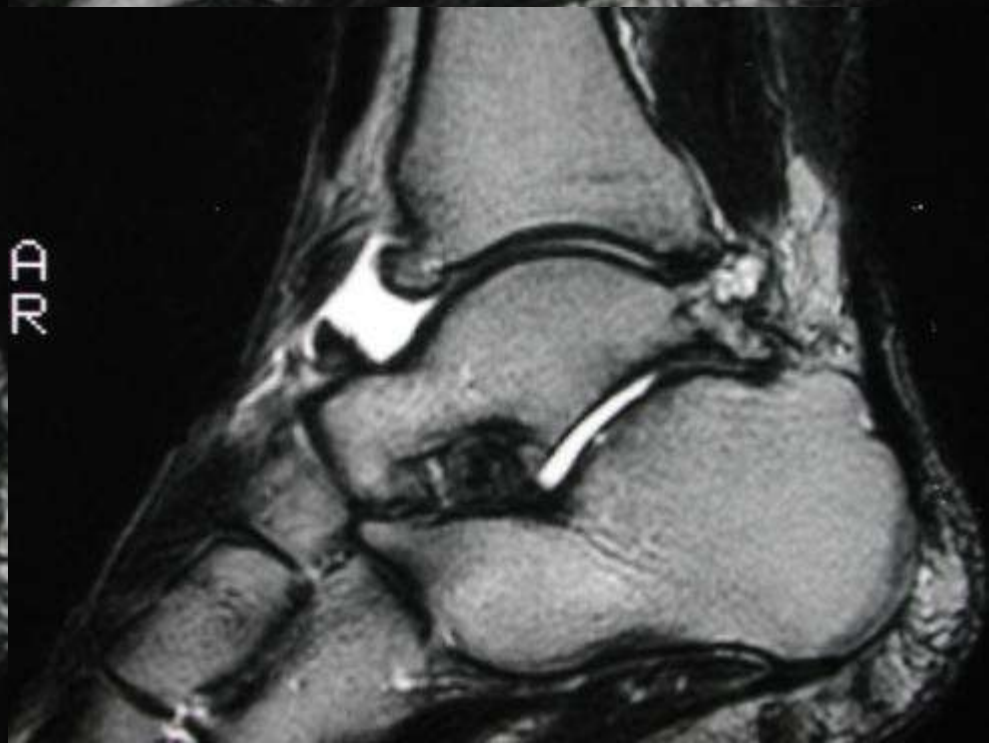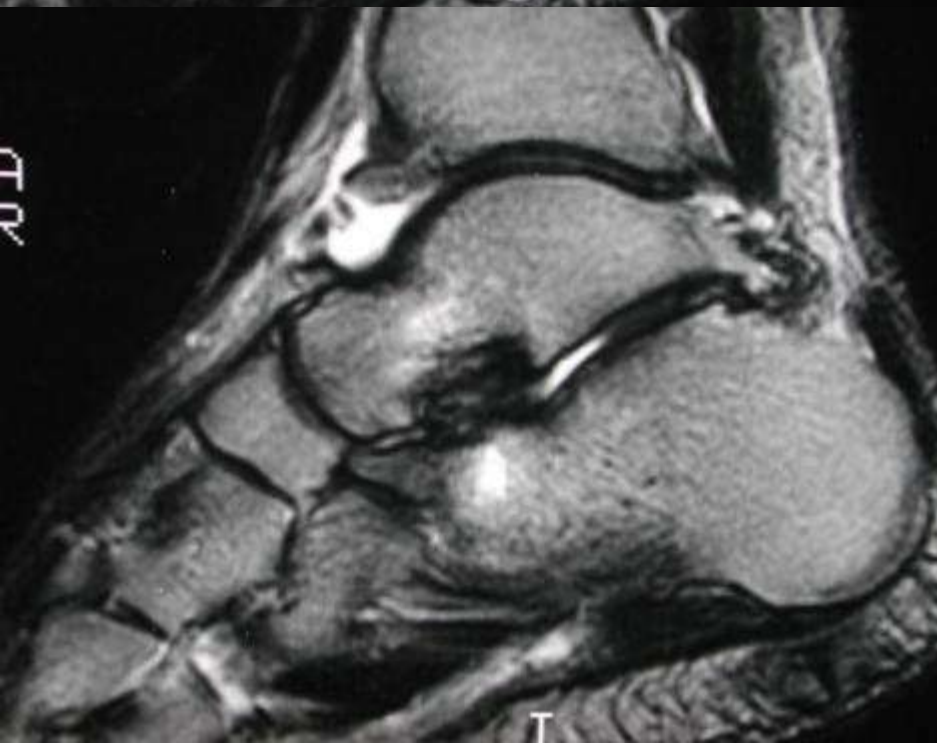
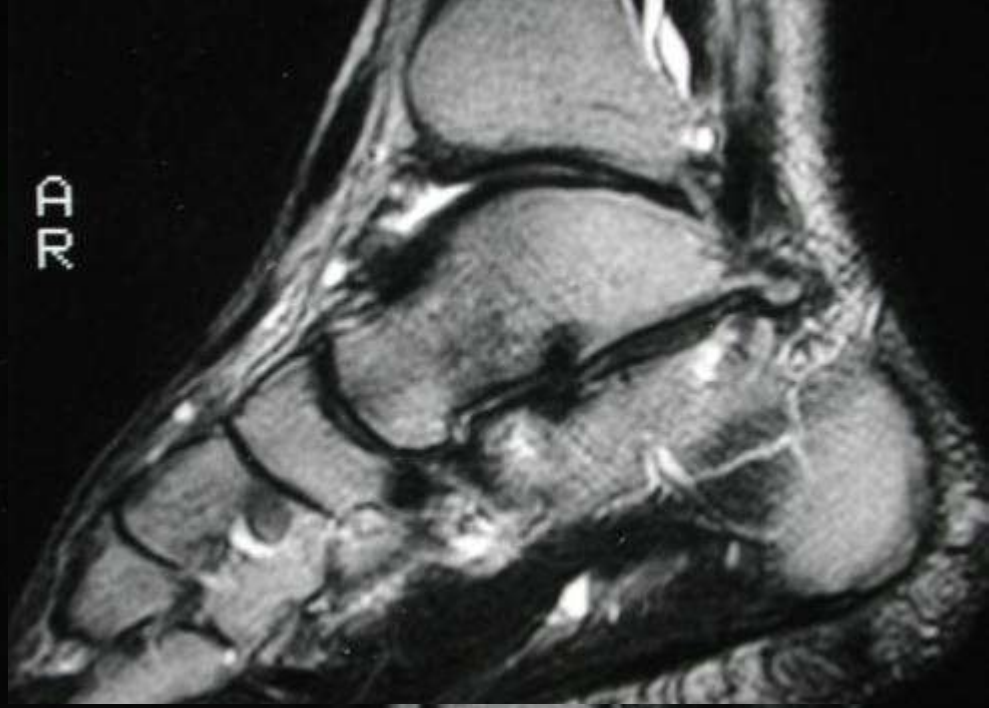
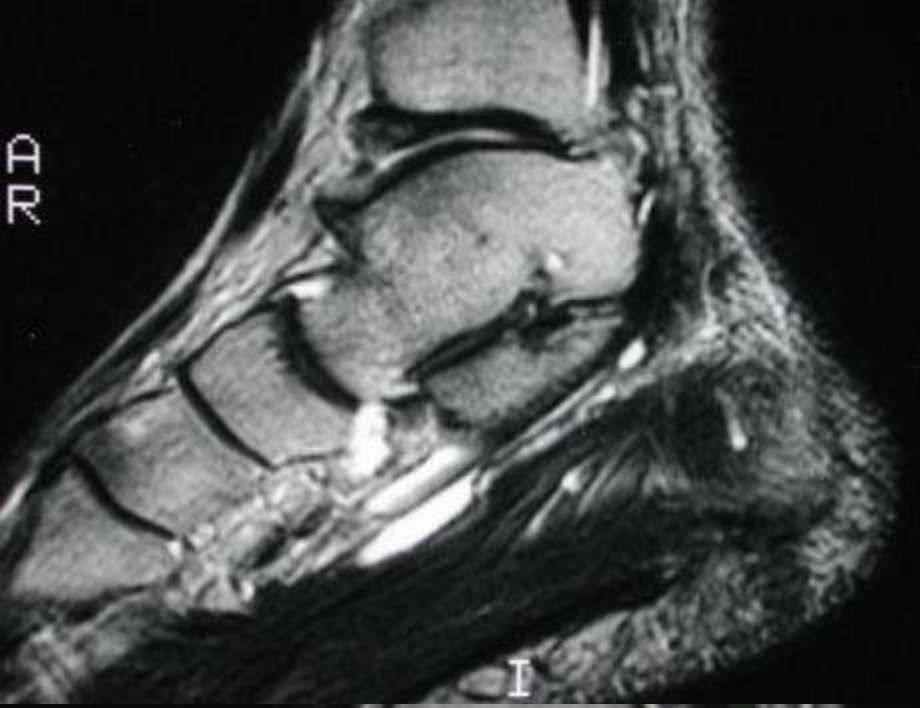
- Presence of spurs *and* associated proliferative synovial response critical in causing symptoms
- Imaging:
 - Anterior intracapsular spurs
 - Synovial response / edema in anterior capsular recess
 - Anterior and medial cartilage abnormalities
 - Bone marrow edema



Robinson et al. Soft tissue and Osseous Impingement Syndromes of the Ankle. Radiographics 2002
Cerezal, et al. MR Imaging of Ankle Impingement Syndromes. AJR 2003
Masiocchi, et al. Ankle Impingement Syndromes. EJR 1998



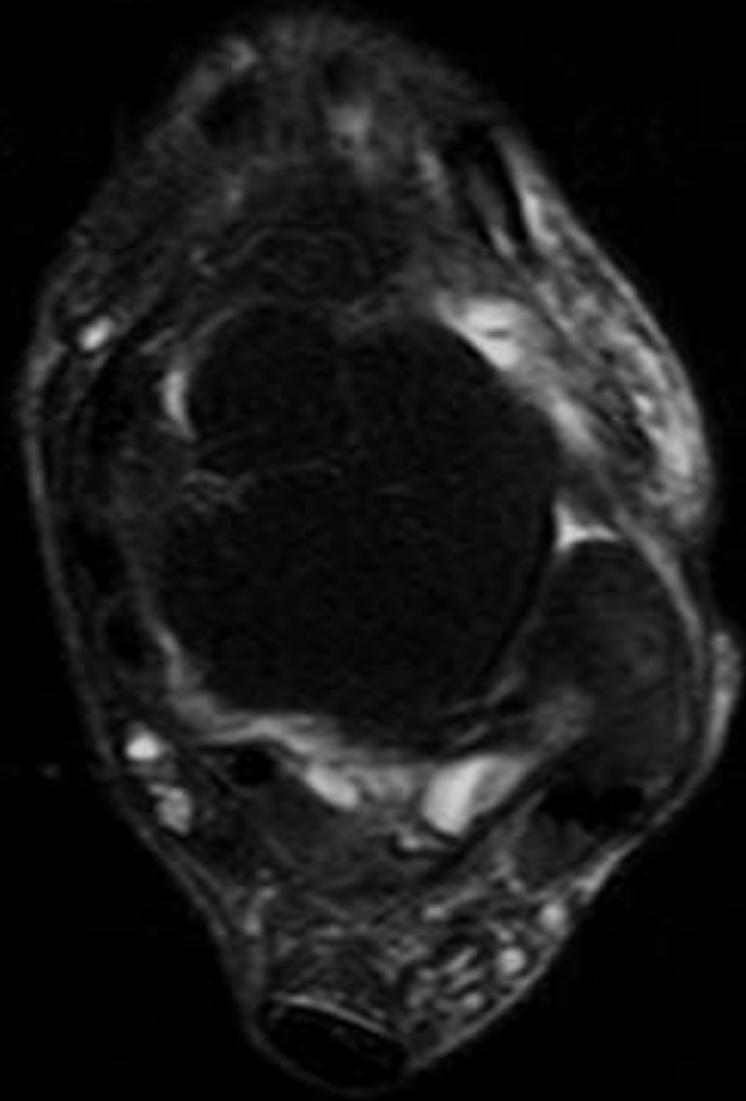
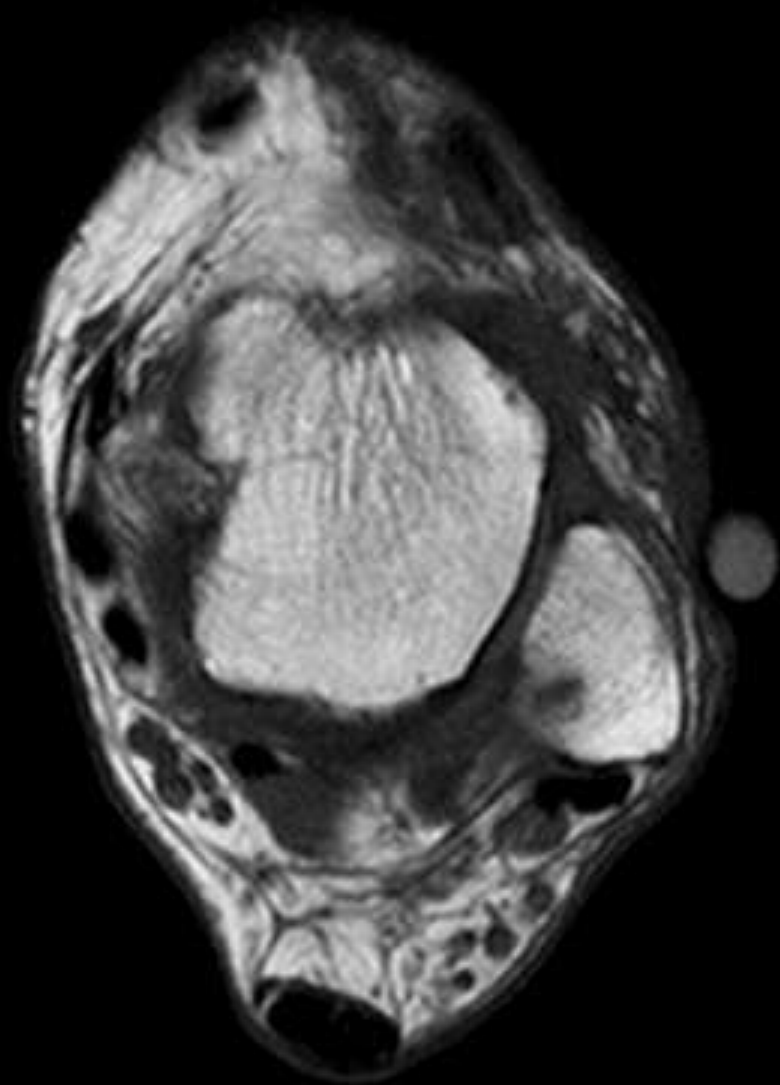
Cases courtesy of Tudor Hughes

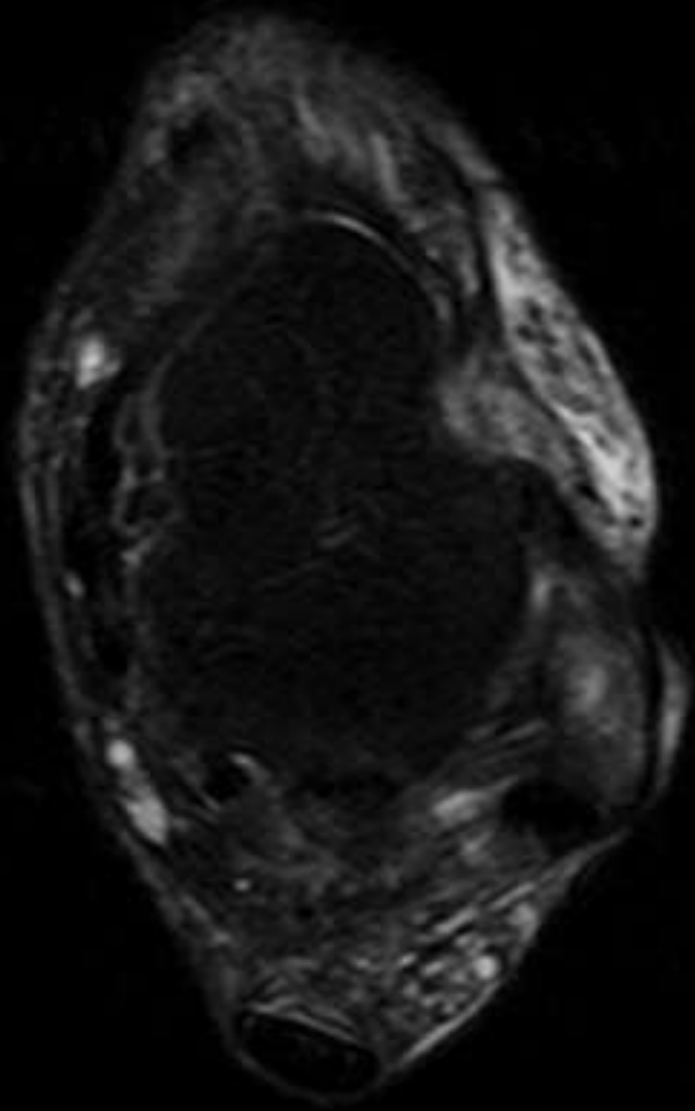
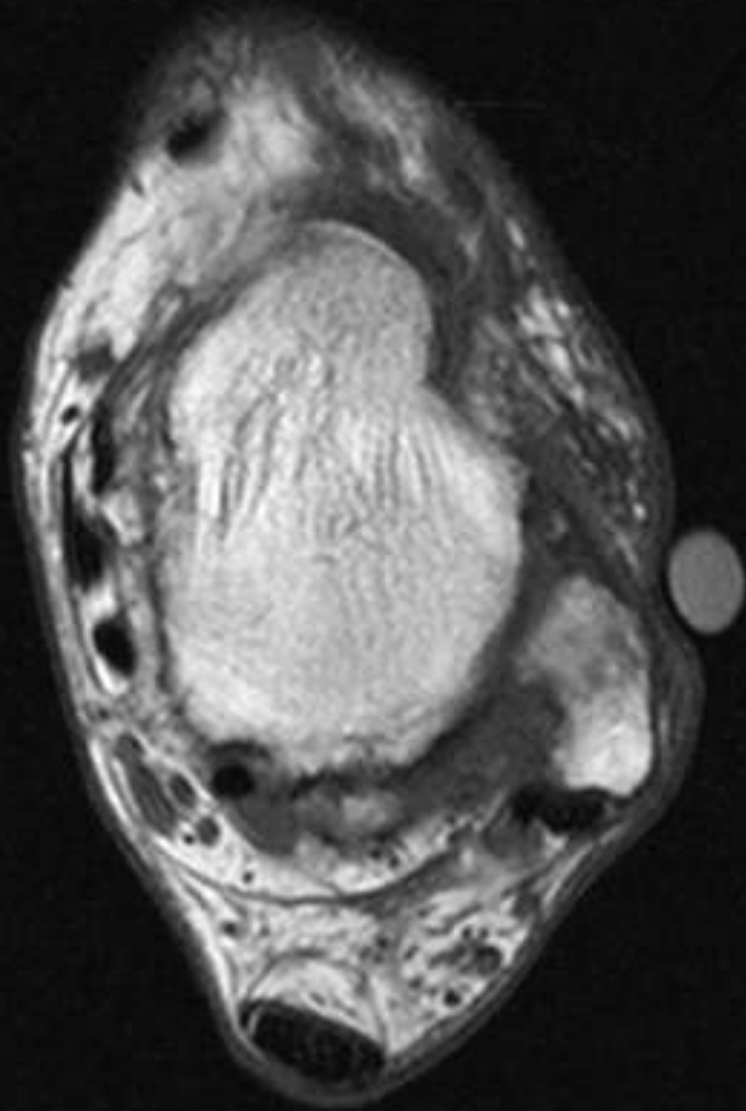


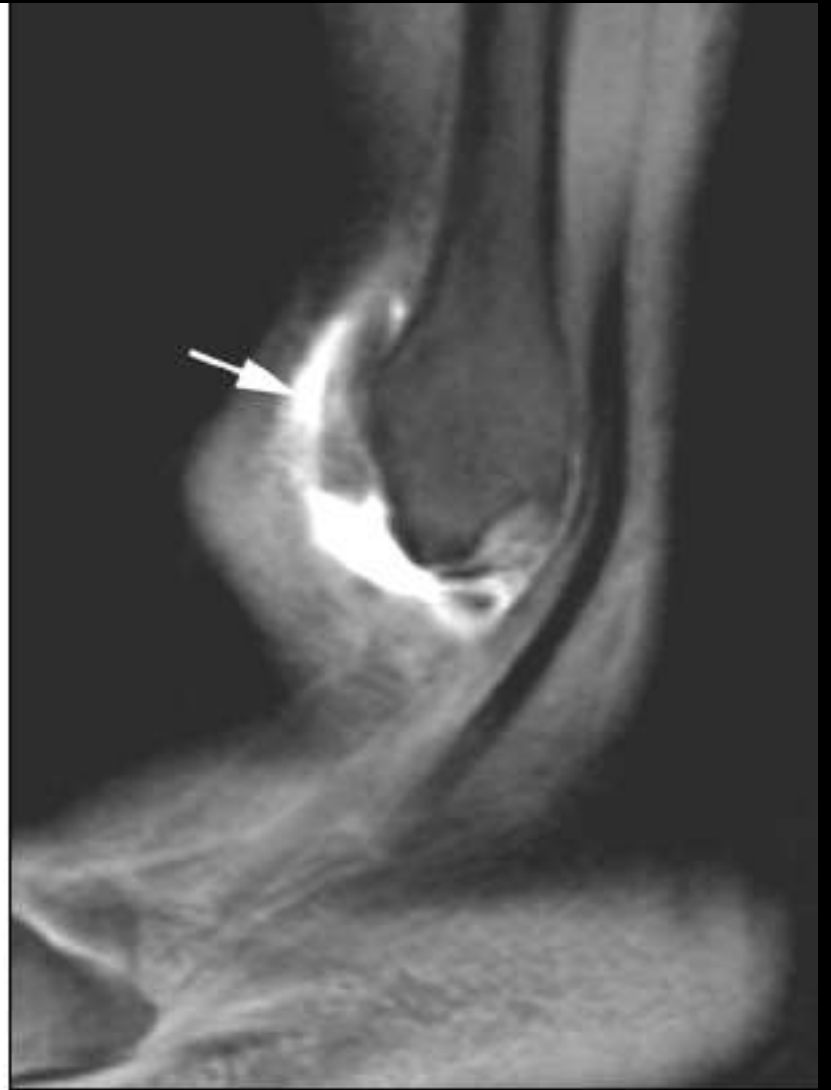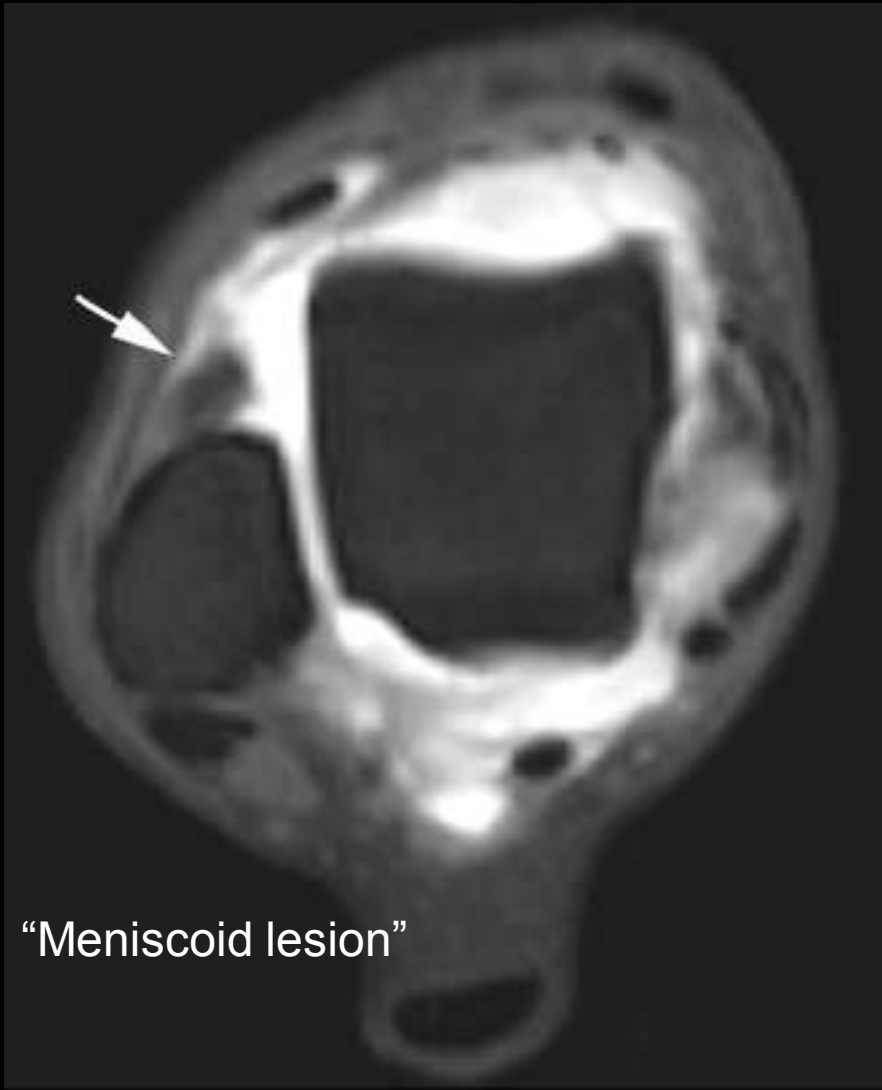
Anterolateral Impingement

- Relatively uncommon; 3% of sprains
- Three theories: chronic injury to ATaFL, scar tissue, hypertrophied anomalous ligament
- Usually occurs after relatively minor inversion/forced plantar flexion trauma; usually not unstable
- Often remains a clinical diagnosis

- MR arthrography superior to standard MR. Reported sensitivity 96% and specificity 100%; NPV 89%, PPV 100%
- Imaging findings include abnl ATaFL, scar tissue, irregular/nodular contour of AL soft tissues, chondral defects, osseous spurs
- Identification of imaging abnormalities does not imply symptoms

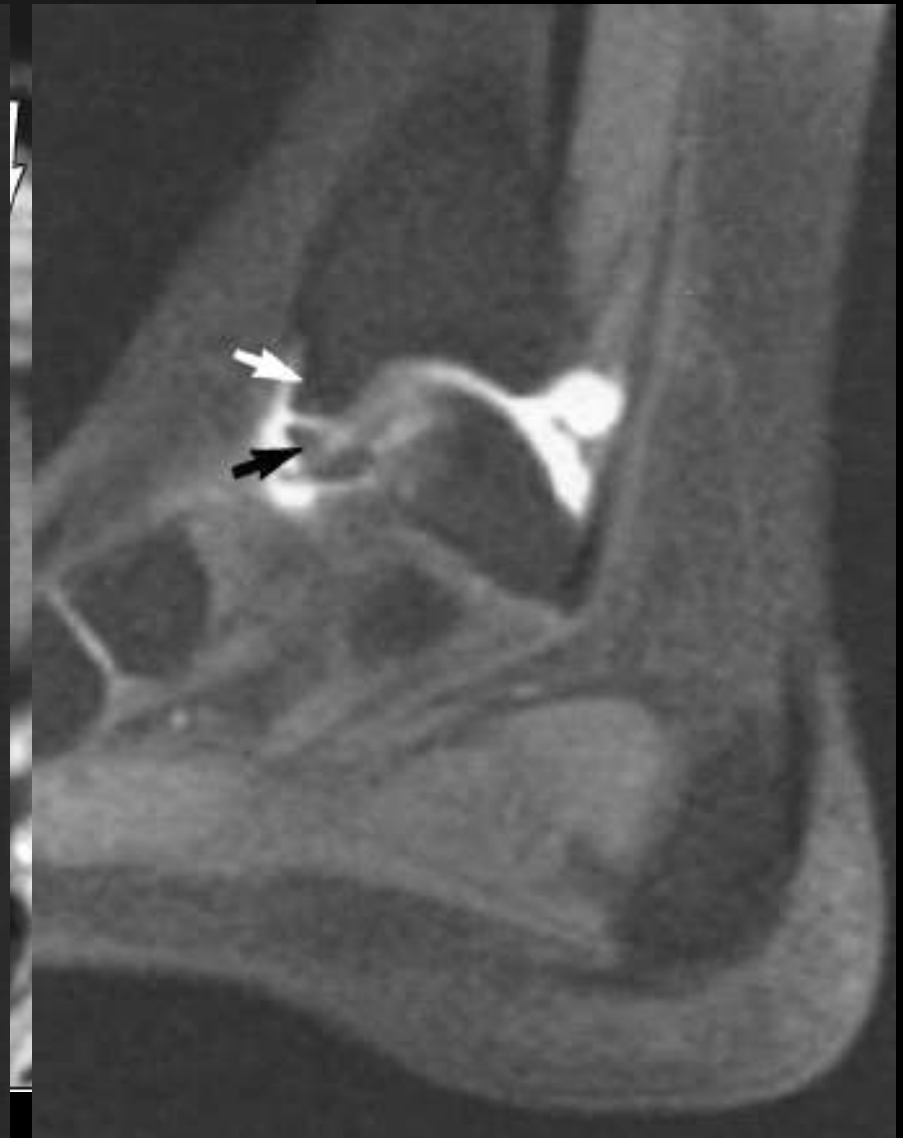
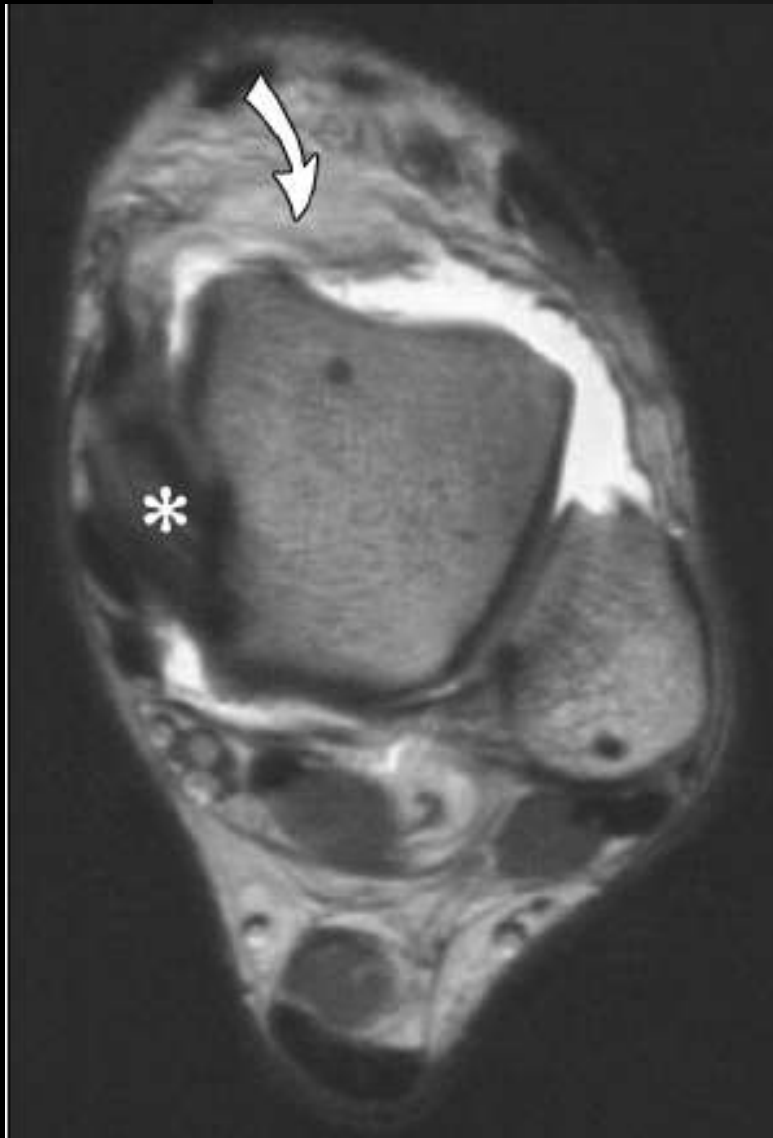




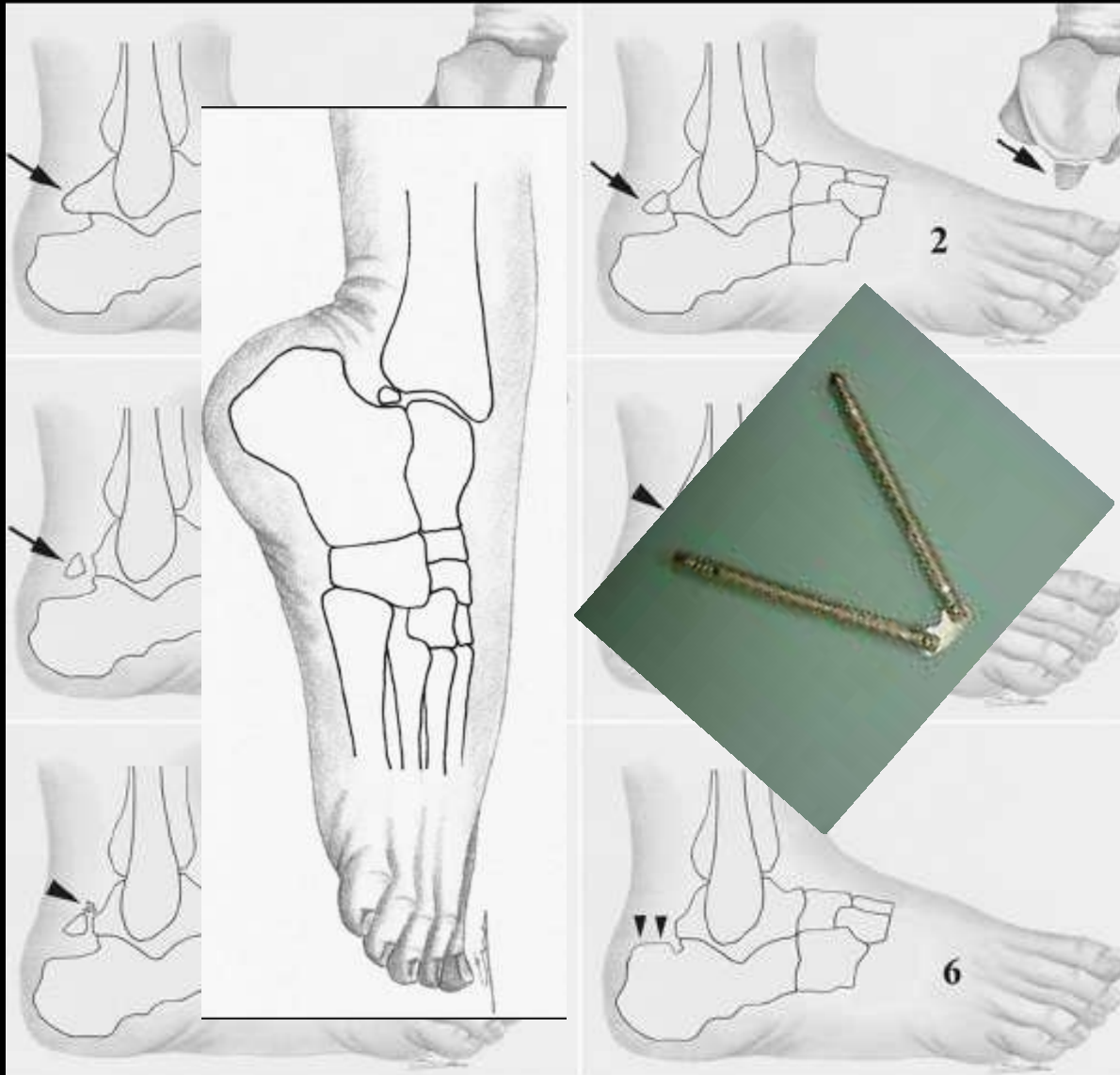
Anteromedial Impingement

- Rare complication of inversion injury with perhaps a rotational component; leads to AM capsular injury, cartilage injury, osteophytes
- Repeated microtrauma causes synovitis and capsular thickening – “meniscoid lesion” anterior to tibiotalar ligament
- MR arthrogram superior to standard MR. ?
Role – assess chondral disease, bony pathology



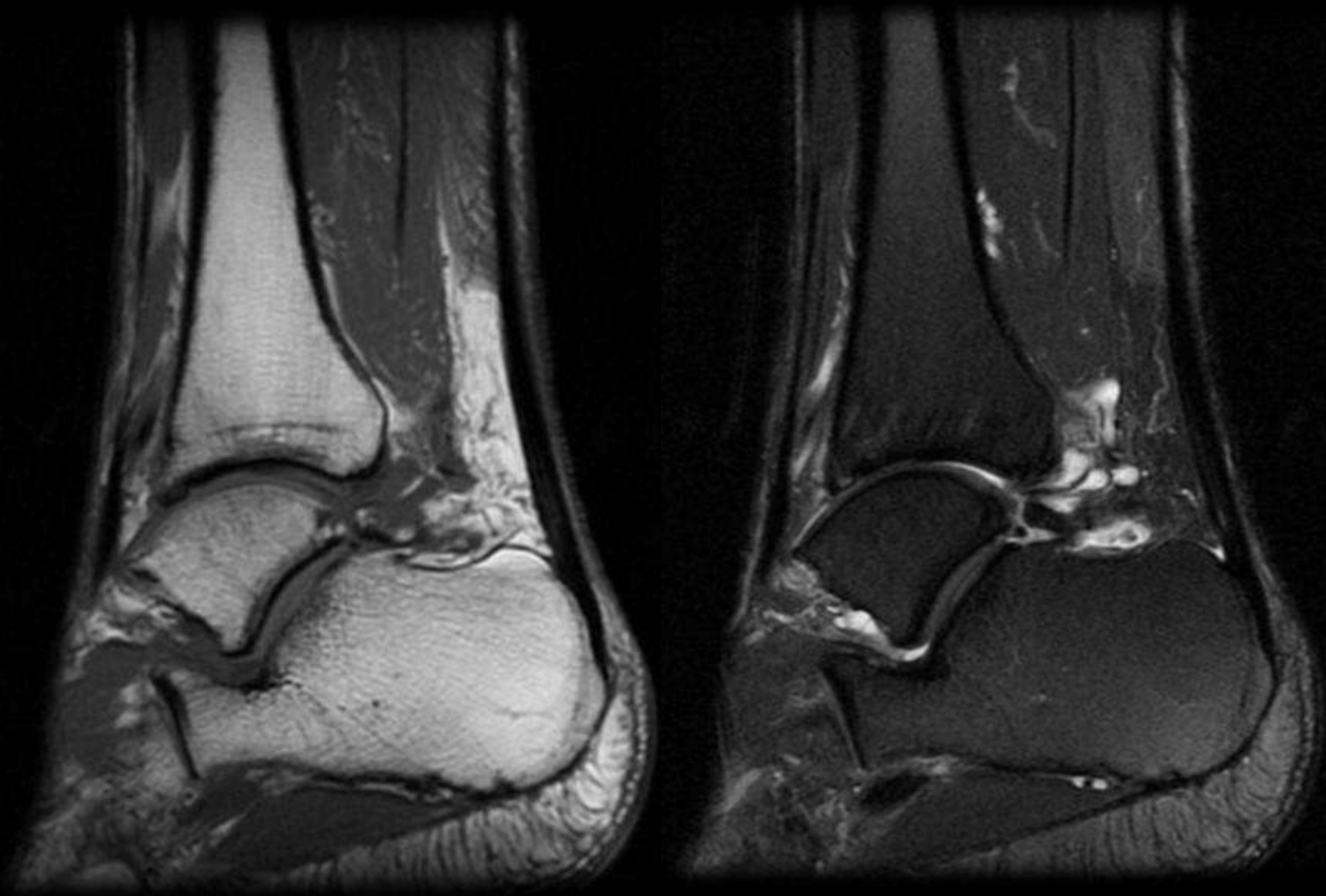
Posterior Impingement

- Arises from compression of posterior talus and soft tissues between posterior calcaneal process and posterior tibia on plantar flexion
- Repetitive / forced plantar flexion. Occurrence after acute traumatic injury relatively rare
- Involved capsular soft tissues include PTaF, PTiF, posterior intermalleolar ligament, FHL

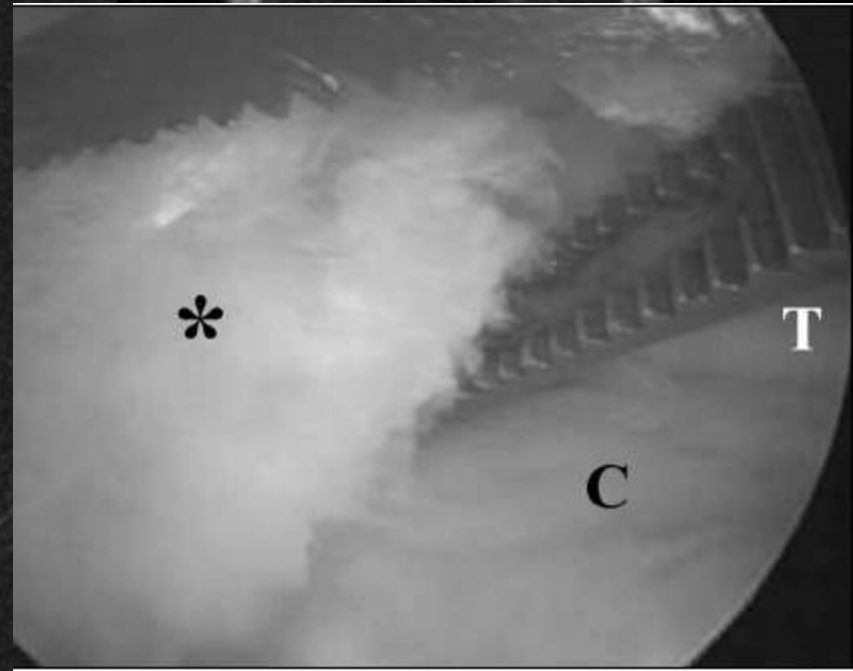
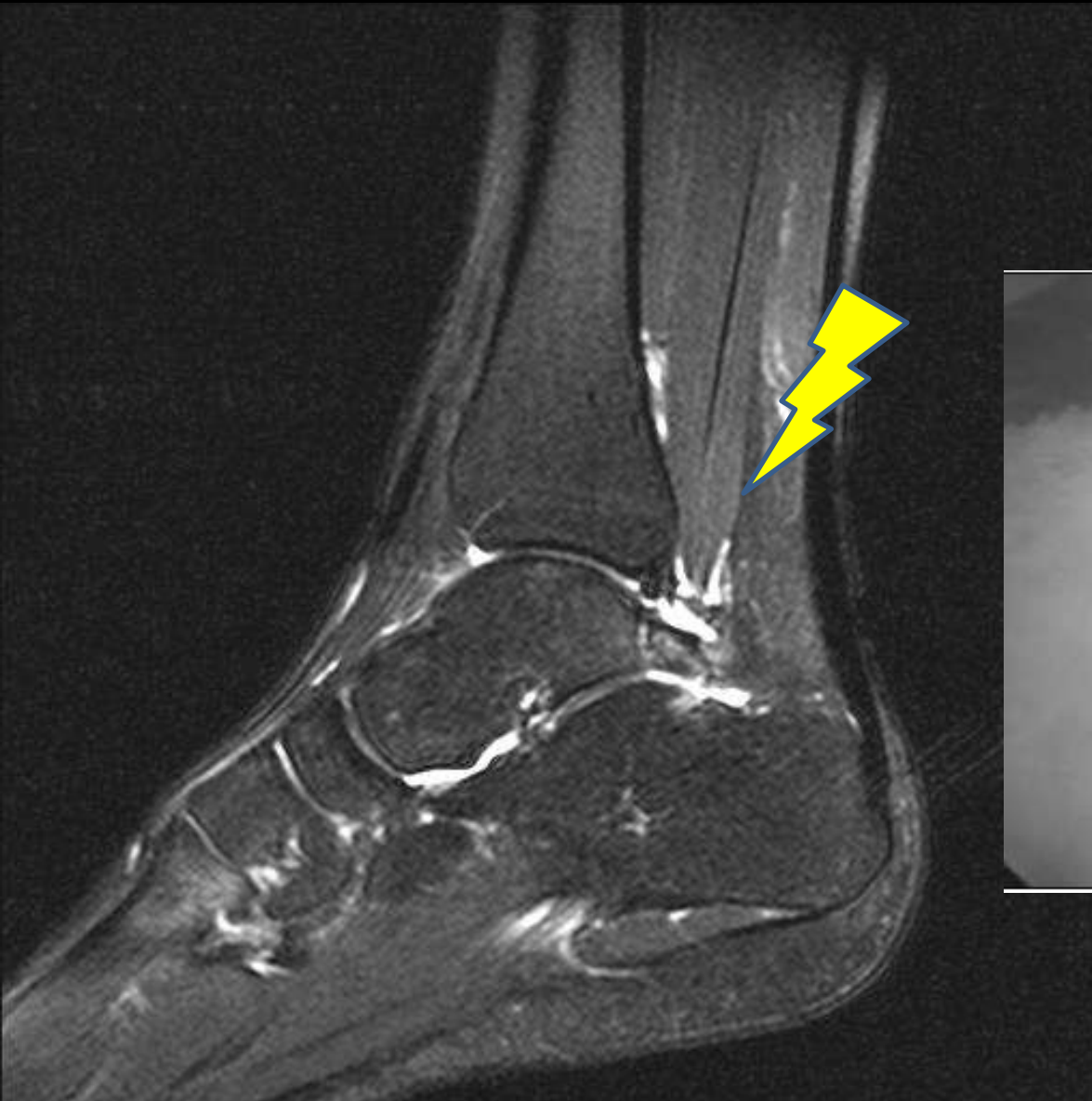

Imaging Findings

- Presence of osseous anatomic variations that predispose to posterior impingement
- Posterior synovitis
- Edema in os, talus, calcaneus, tibia
- PIML
- Tenosynovitis of FHL
- Capsular / posterior ligament thickening



oom: 98%



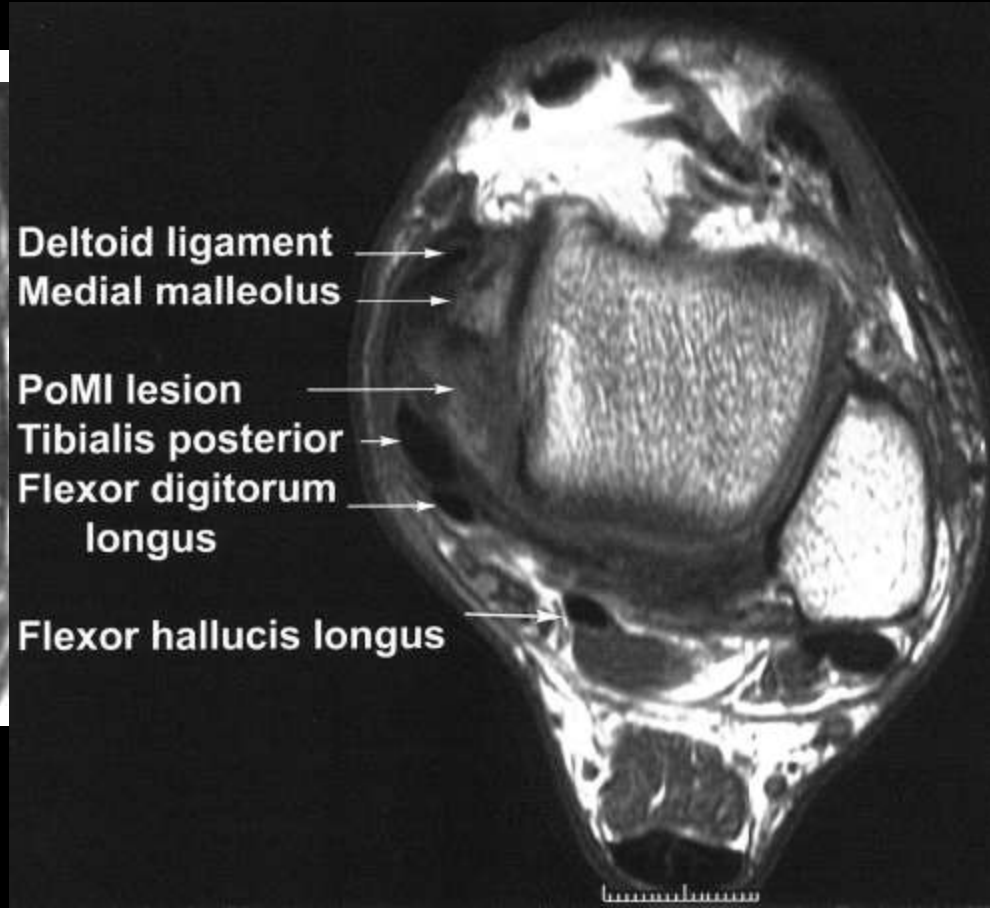
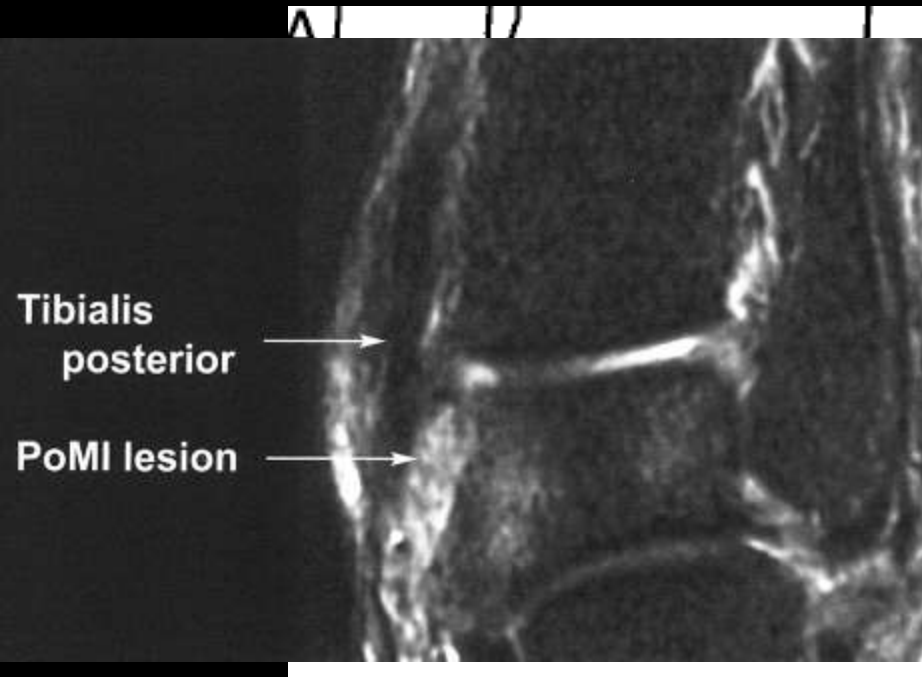
Cases courtesy of Tudor Hughes
Cerezal, et al. MR Imaging of Ankle Impingement Syndromes. AJR 2003

Posteromedial Impingement

- Uncommon; occurs after inversion injury where deep posterior tibiotalar ligament crushed between medial malleolus and medial posterior talar tubercle
- Development of “meniscoid” lesion as in AL and AM impingement
- Clinically patients have persistent, isolated PM ankle pain posterior to medial malleolus, and ST fullness

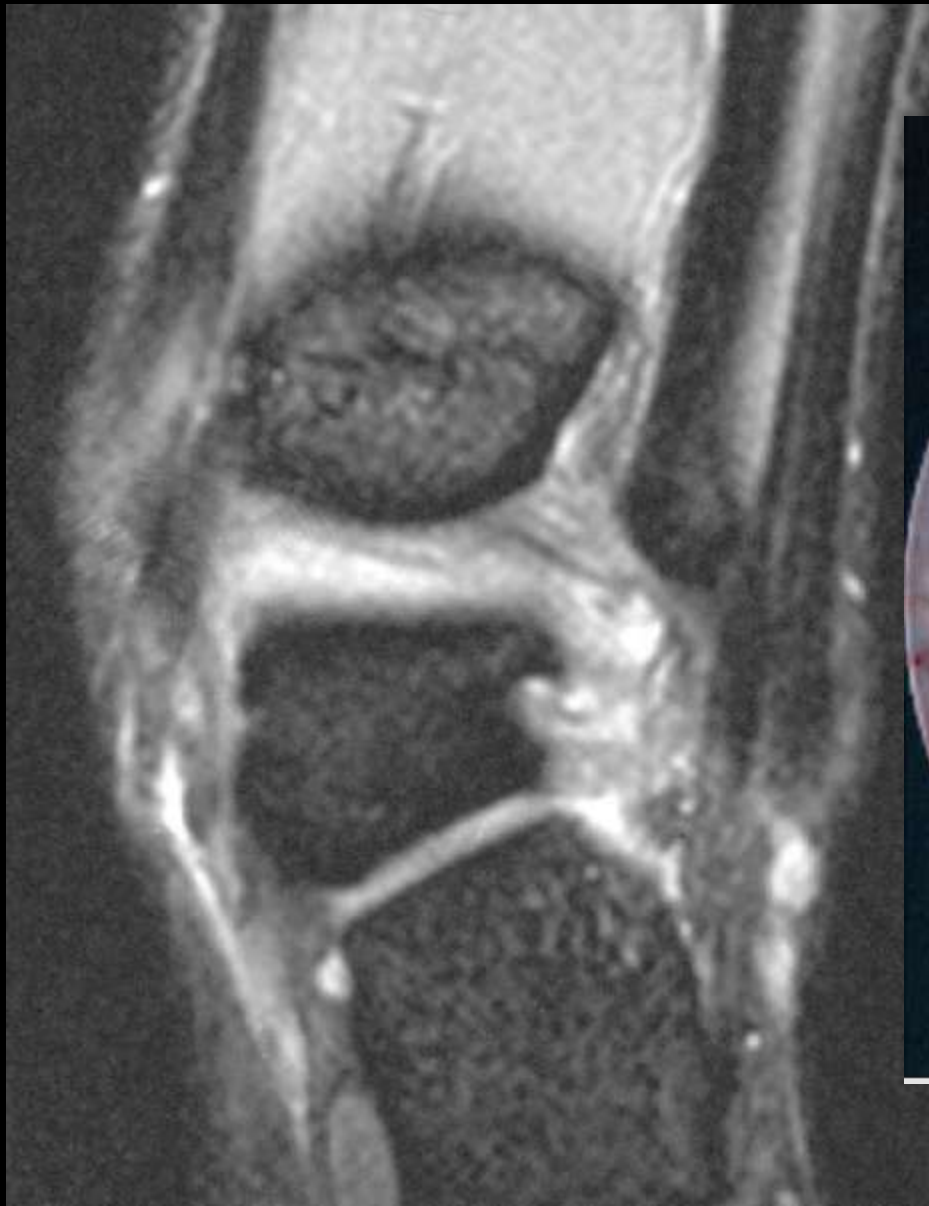Imaging Findings

- CR usually normal, but may show periosteal reaction on medial talus / malleolus
- MRI
 - Marrow edema, bone bruising
 - Chondral damage
 - Thickened soft tissues deep to TPT

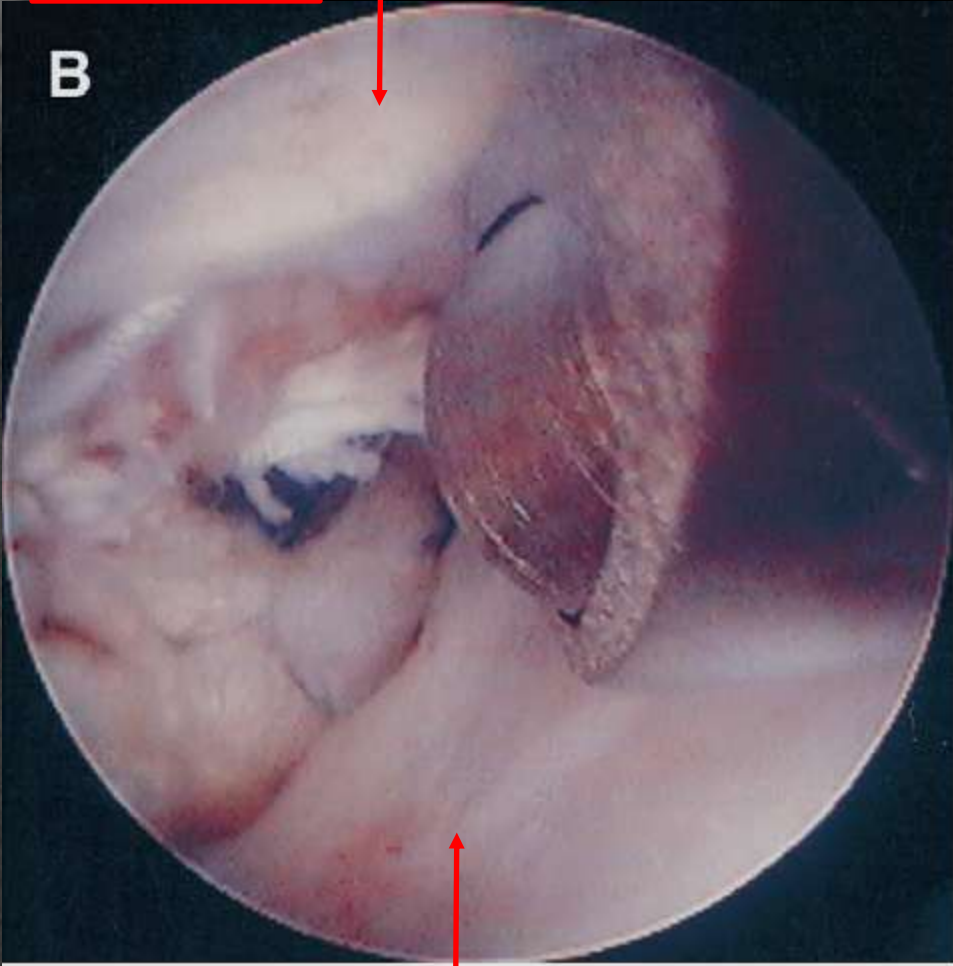


Posterolateral Impingement

- Very rare. Thought to be due to forced plantar flexion and increased pressure on posterior soft tissues and/or inversion injury
- Case report of high level German field hockey player with posterior ankle injury 9 years prior with forced plantar flexion during slip on wet turf. Also with inversion injury 8 years prior
- MRI findings were effusion, meniscoid ST mass posterior talofibular joint space, and thickened PIML



Posterior
Fibular Cartilage

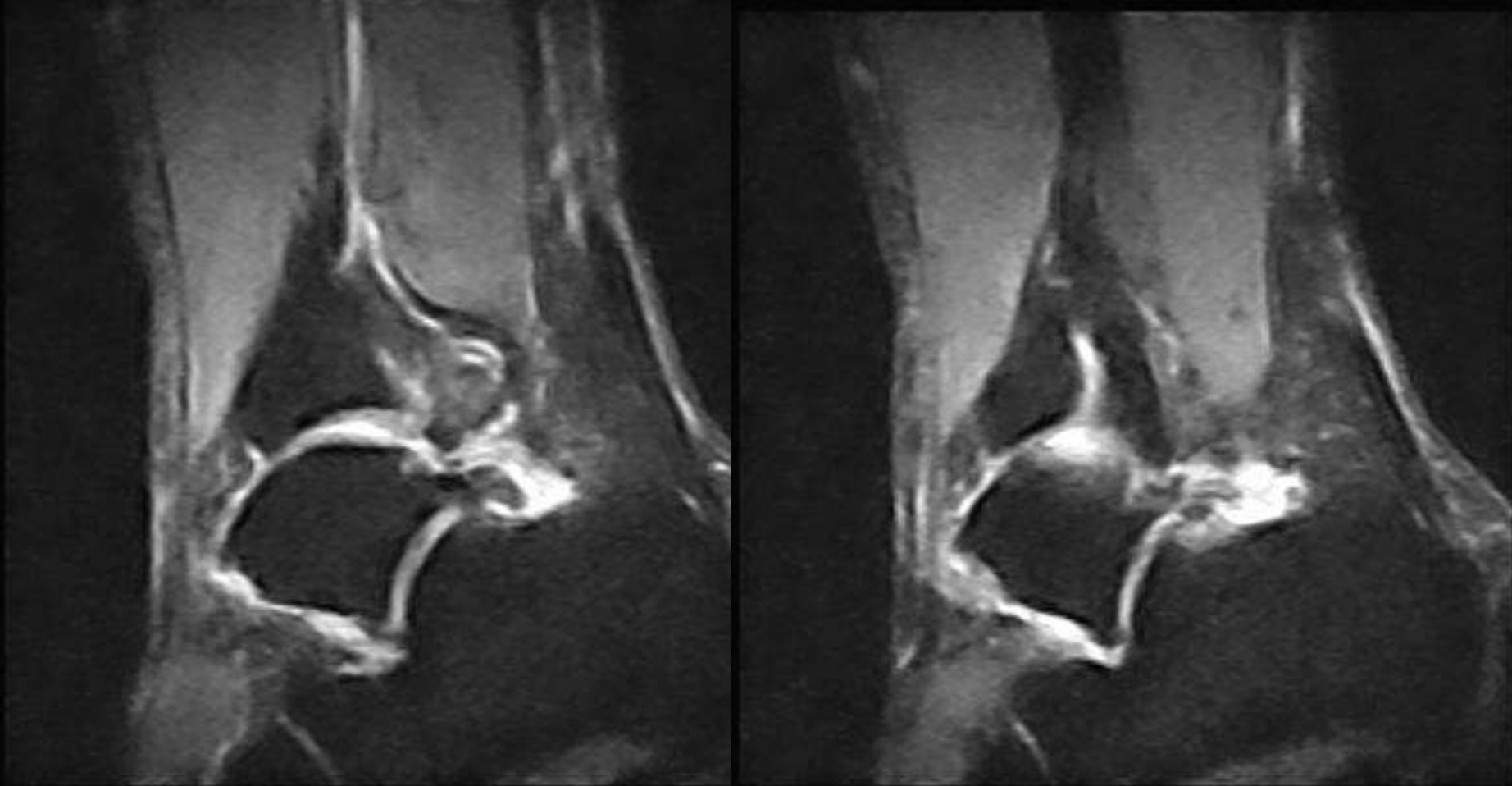


Posterolateral
Talar Cartilage

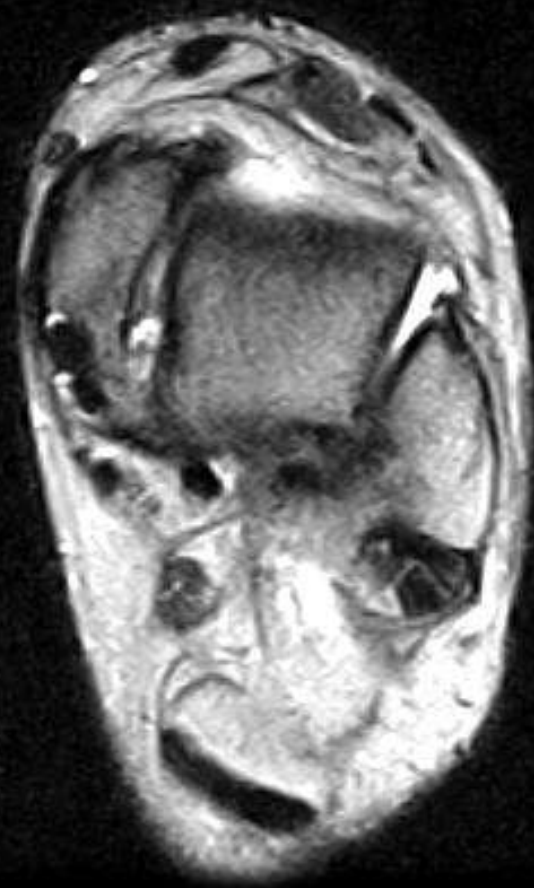Loher H and Arentz S. Posterior Approach for arthroscopic treatment of posterolateral impingement syndrome of the ankle in a top-level field hockey player. Arthroscopy 2004

34yo soccer player with foot pain

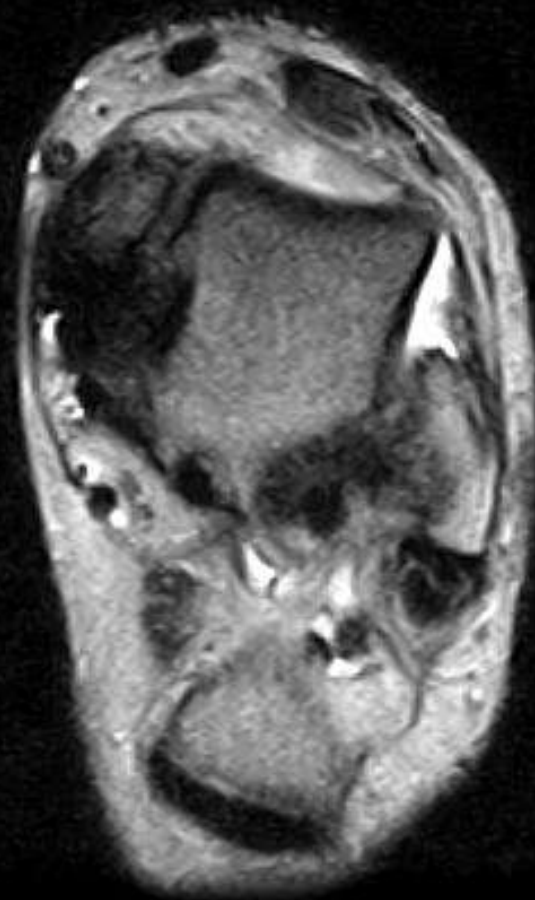OLL



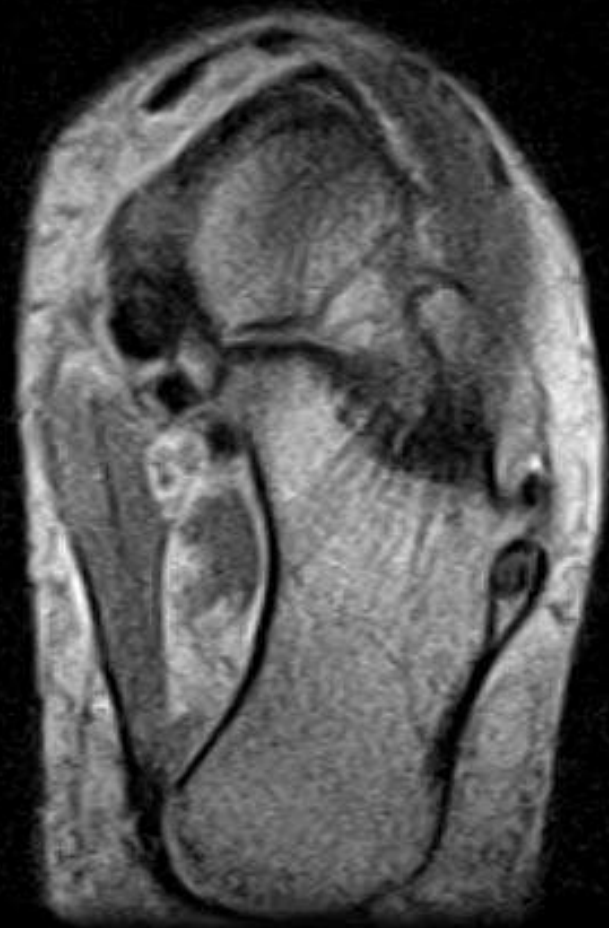Zoom: 191%



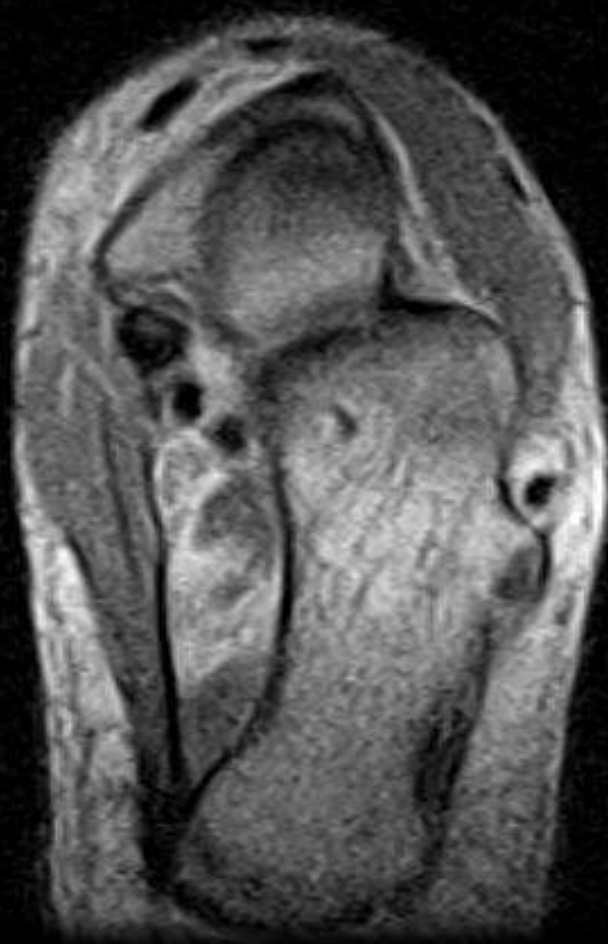0. Zoom: 191%



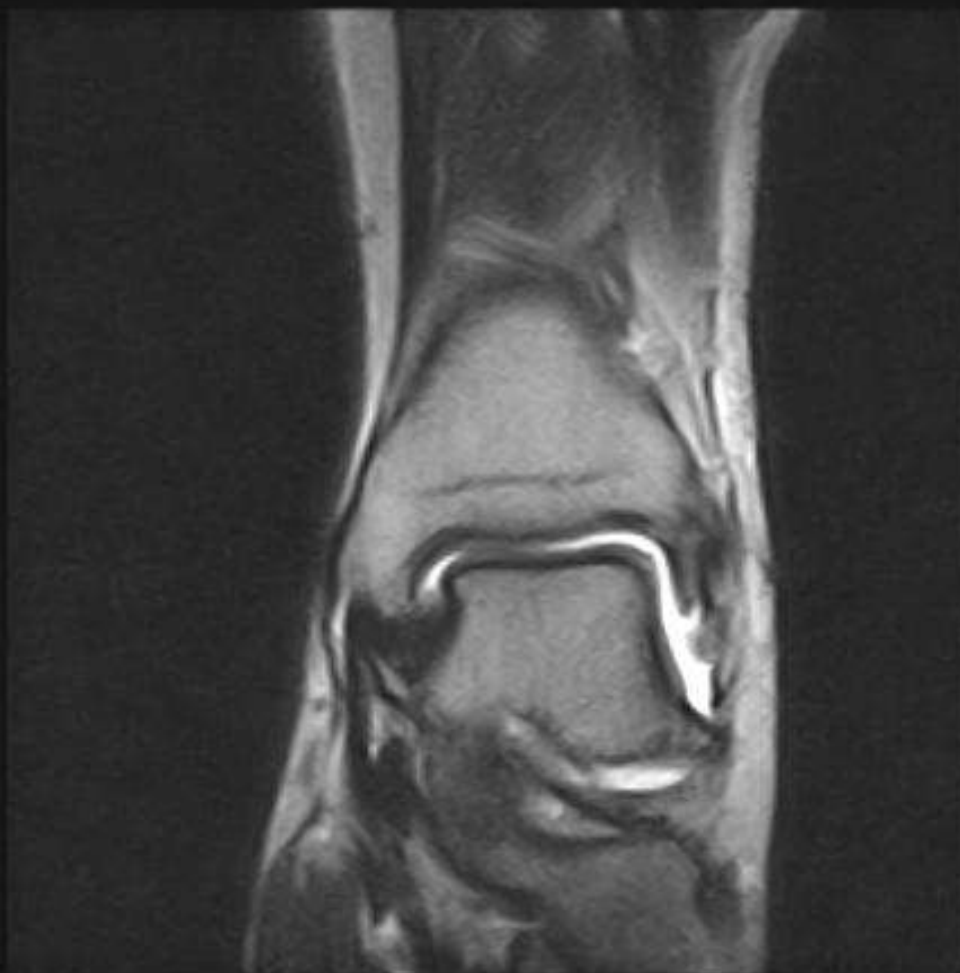
3.0. Zoom: 191%



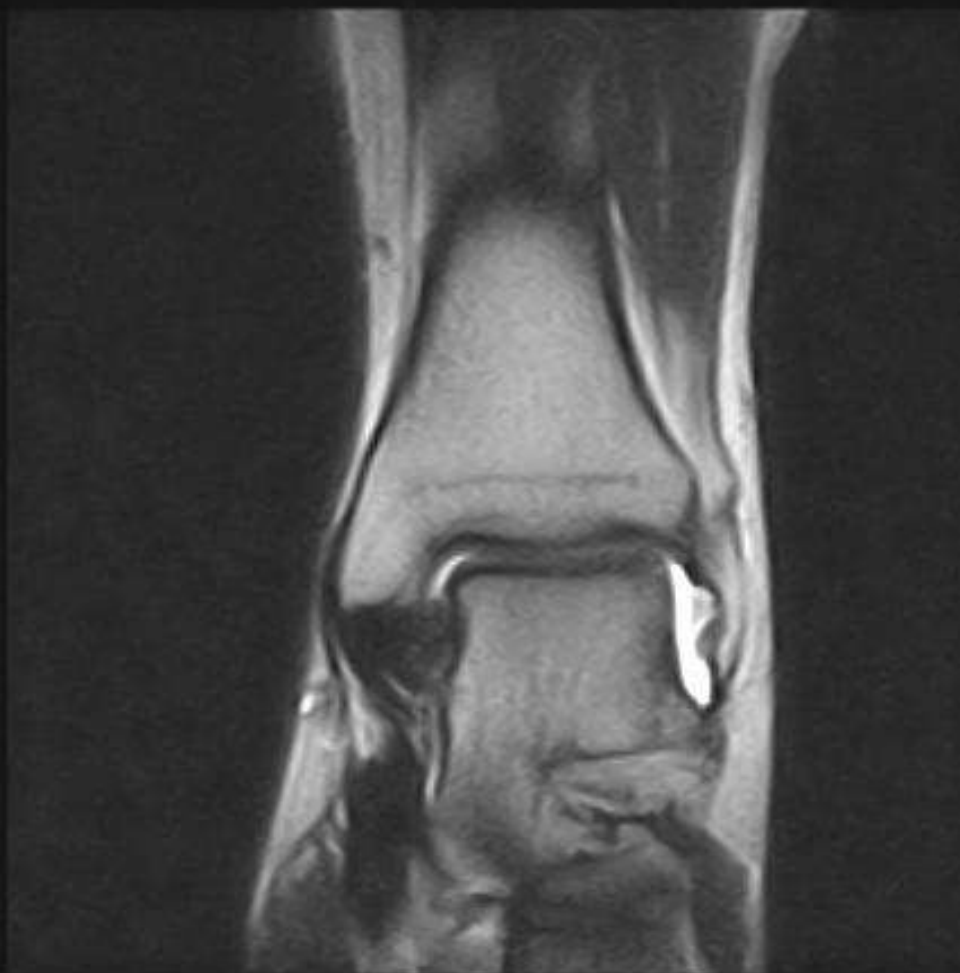
6.0. Zoom: 191%

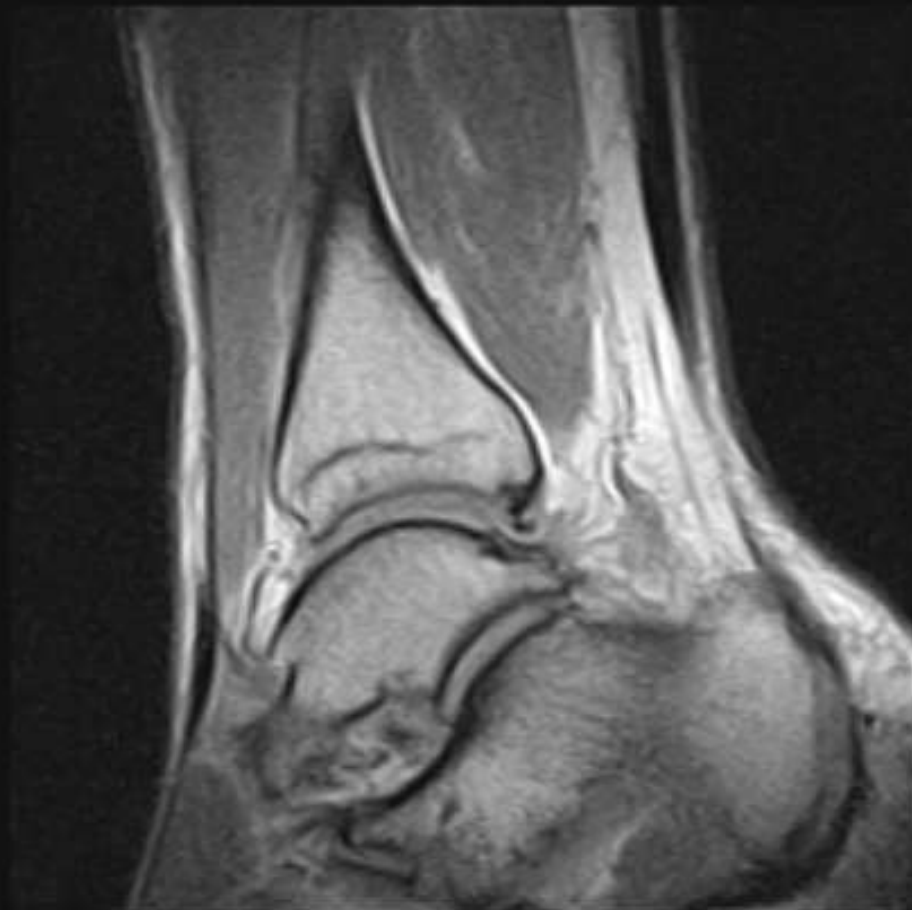

25. Ratio: 6.0. Zoom: 191%



25. Ratio: 6.0. Zoom: 191%





Summary

- Impingement syndromes are increasingly recognized as a cause of chronic ankle pain
- Often is a clinical diagnosis, but MR / arthrography can aid in delineating extent of soft tissue abnormalities. This is particularly true in posterior and posteromedial syndromes
- Knowing the main syndromes and their manifestations can help you to help the clinician

References

- Schneck CD et al. MR Imaging of the Most Commonly Injured Ankle Ligaments Part I Normal Anatomy. *Radiology* 1992; 184:499-506
- Schneck CD et al. MR Imaging of the Most Commonly Injured Ankle Ligaments Part II Ligament Injuries. *Radiology* 1992; 184:507-512
- Masiocchi C. Ankle Impingement Syndromes. *Eur J Rad* 1998; 27:S70-S73
- Robinson P. Soft Tissue and Osseous Impingement Syndromes of the Ankle: Role of Imaging in Diagnosis and Management. *Radiographics* 2002; 22:1457-1471
- Cerezal L. MR Imaging of Ankle Impingement Syndromes. *AJR* 2003; 181: 551-559

References

- Robinson P. Imaging of ankle impingement. *Curr Orthopaedics*. 2003; 17: 206-214
- Schaffler GJ, et al. Impingement syndrome of the ankle following supination external rotation trauma: MR imaging findings with arthroscopic correlation. *Eur Rad* 2003; 13: 1357-1362
- Oh CS et al. Anatomic variations and MRI of the Intermalleolar Ligament. *AJR* 2006; 186: 943-947
- Bassett FH, et al. Talar Impingement by the anteroinferior tibiofibular ligament. *JBJS* 1990; 72A: 55-59
- Rubin DA, et al. Anterolateral Soft tissue Impingement in the ankle. *AJR* 1997; 169: 829-835
- Egol KA & Parisien JS. Impingement syndrome of the ankle caused by a medial meniscoid lesion. *Arthroscopy* 1997; 13: 522-525

References

- Robinson P, et al. Anterolateral ankle impingement: MR Arthrographic assessment of anterolateral recess. *Radiology* 2001; 221: 186-190
- Robinson P, et al. Anteromedial impingement of the ankle: Using MR Arthrography to assess the anteromedial recess. *AJR* 2002; 178: 601-604
- Golano P, et al. Arthroscopic anatomy of the posterior ankle ligaments. *Arthroscopy* 2002; 18: 353-358
- Loher H and Arentz S. Posterior Approach for arthroscopic treatment of posterolateral impingement syndrome of the ankle in a top-level field hockey player. *Arthroscopy* 2004; 20: e15-e21
- Paterson RS, et al. The posteromedial impingement lesion of the ankle. *Am J Sp Med* 2001; 29: 550-557

References

- Fiorella D, et al. The MR Imaging features of the posterior intermalleolar ligament in patients with posterior impingement syndrome of the ankle. *Skel Rad* 1999; 28: 573-576
- Bureau NJ, et al. Posterior ankle impingement syndrome: MR findings in seven patients. *Radiology* 2000; 215: 497-503
- Peace KAL, et al. MRI features of posterior ankle impingement syndrome in ballet dancers: a review of 25 cases. *Clin Rad* 2004; 59: 1025-1033
- Muhle C, et al. Collateral Ligaments of the Ankle; High Resolution MRI with a Local Gradient Coil & Anatomic Correlation in Cadavers. *Radiographics* 1999;19: 673-683
- IDJ, 2nd edition
- El-Khoury GY, et al. *Sectional Anatomy by MRI and CT*. Churchill Livingstone Elsevier. 2007

References

- Mengiardi B, et al. Medial Collateral Ligament Complex of the Ankle: MR Appearance in Asymptomatic Subjects. *Radiology* 2007; 242: 817-824
- Klein MA. MR Imaging of the Ankle: Normal and Abnormal Findings in the Medial Collateral Ligament. *AJR* 1994; 162: 377-383
- Subhas, N, et al. MRI appearance of surgically proven abnormal accessory anterior-inferior tibiofibular ligament (Bassett's ligament). *Skel Rad*; 2008; 37:27-33