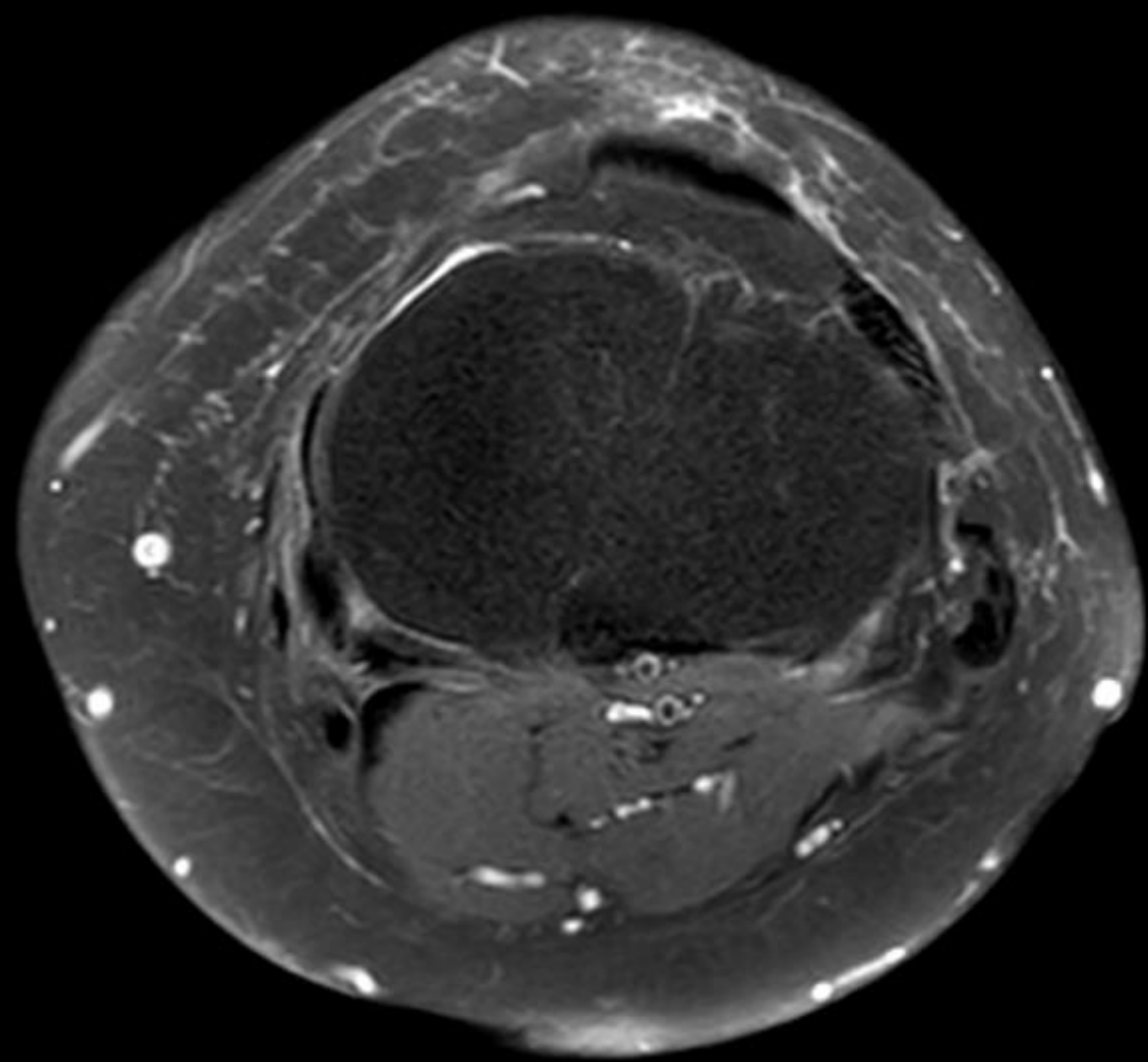
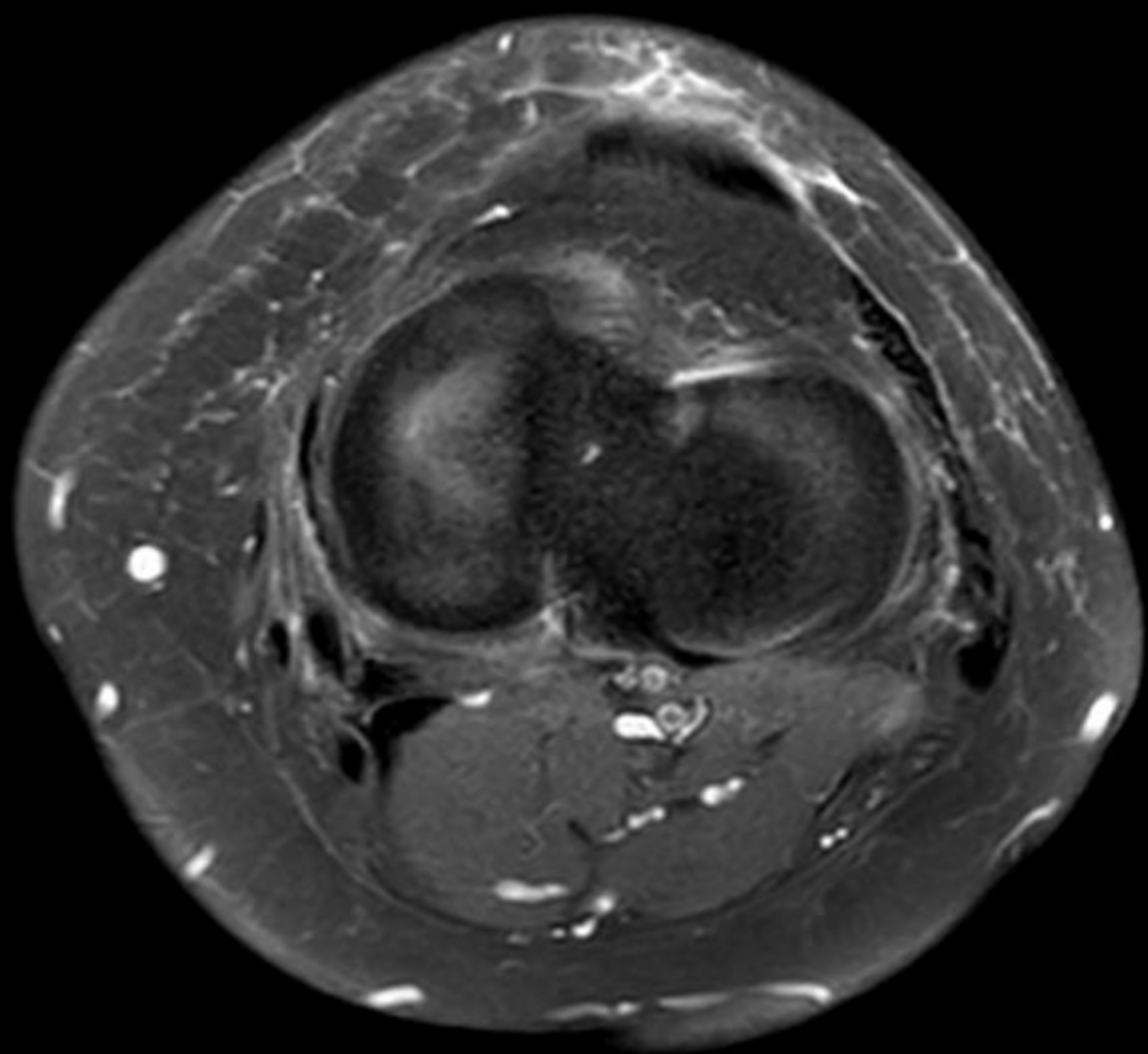
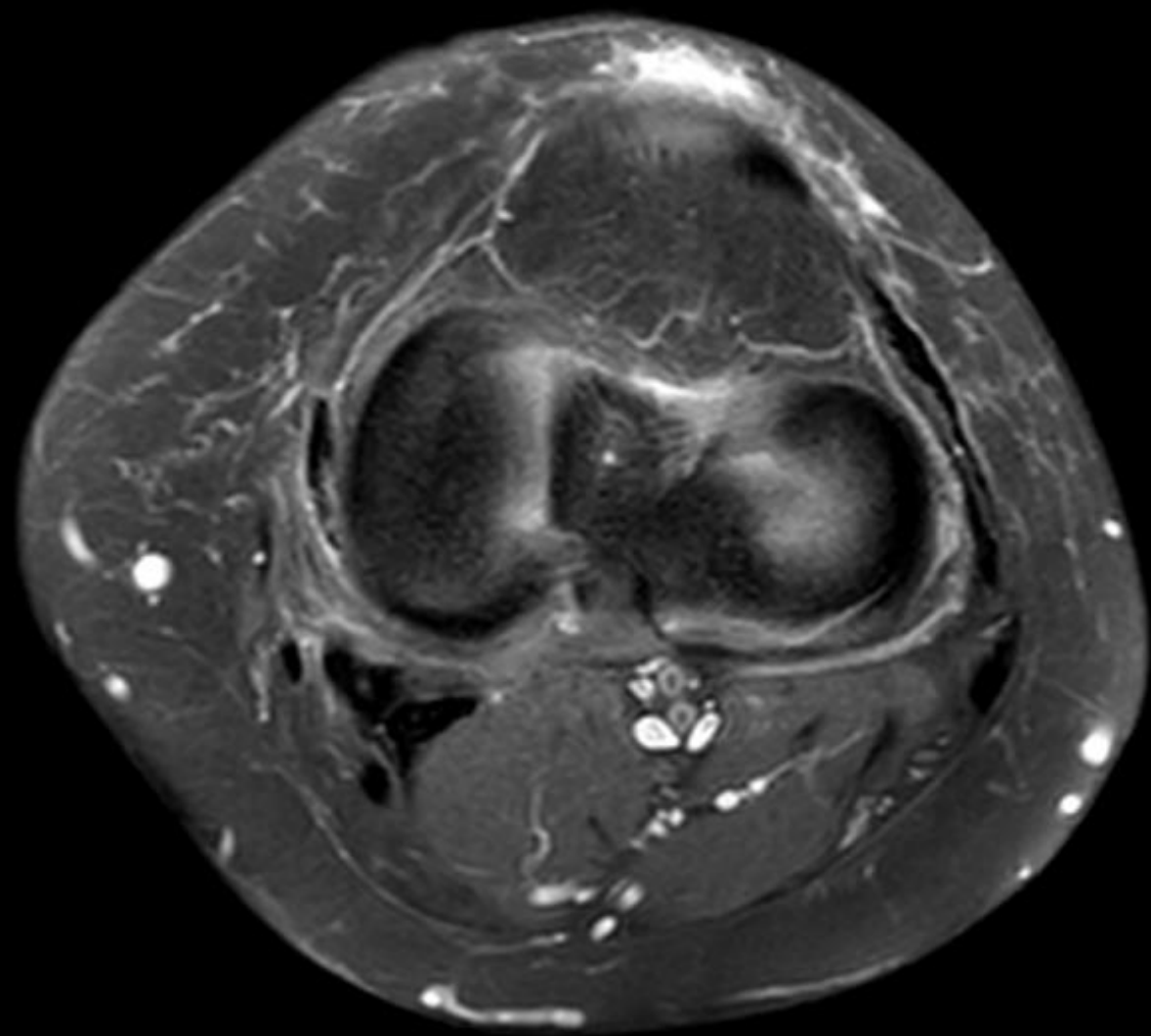


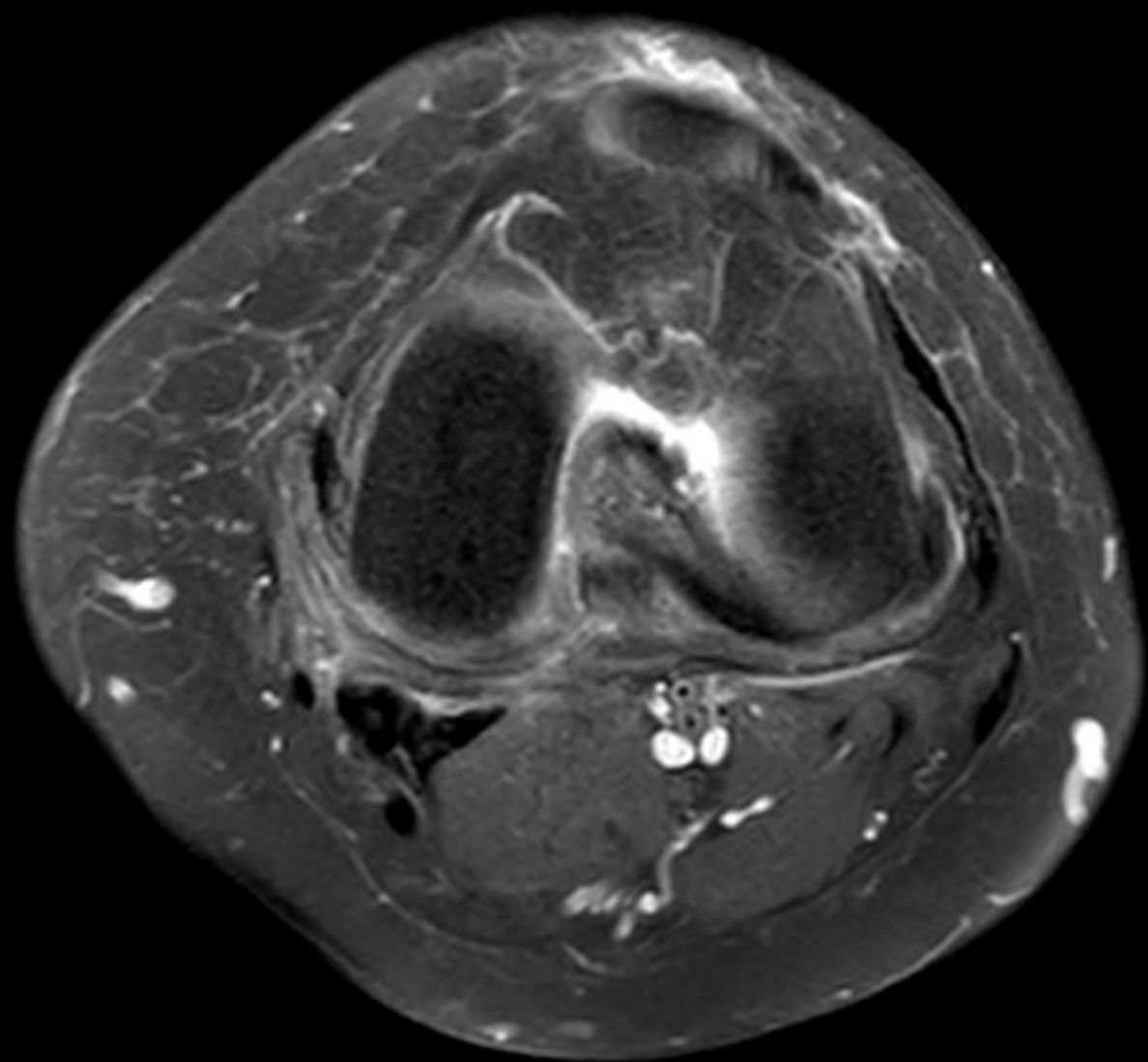


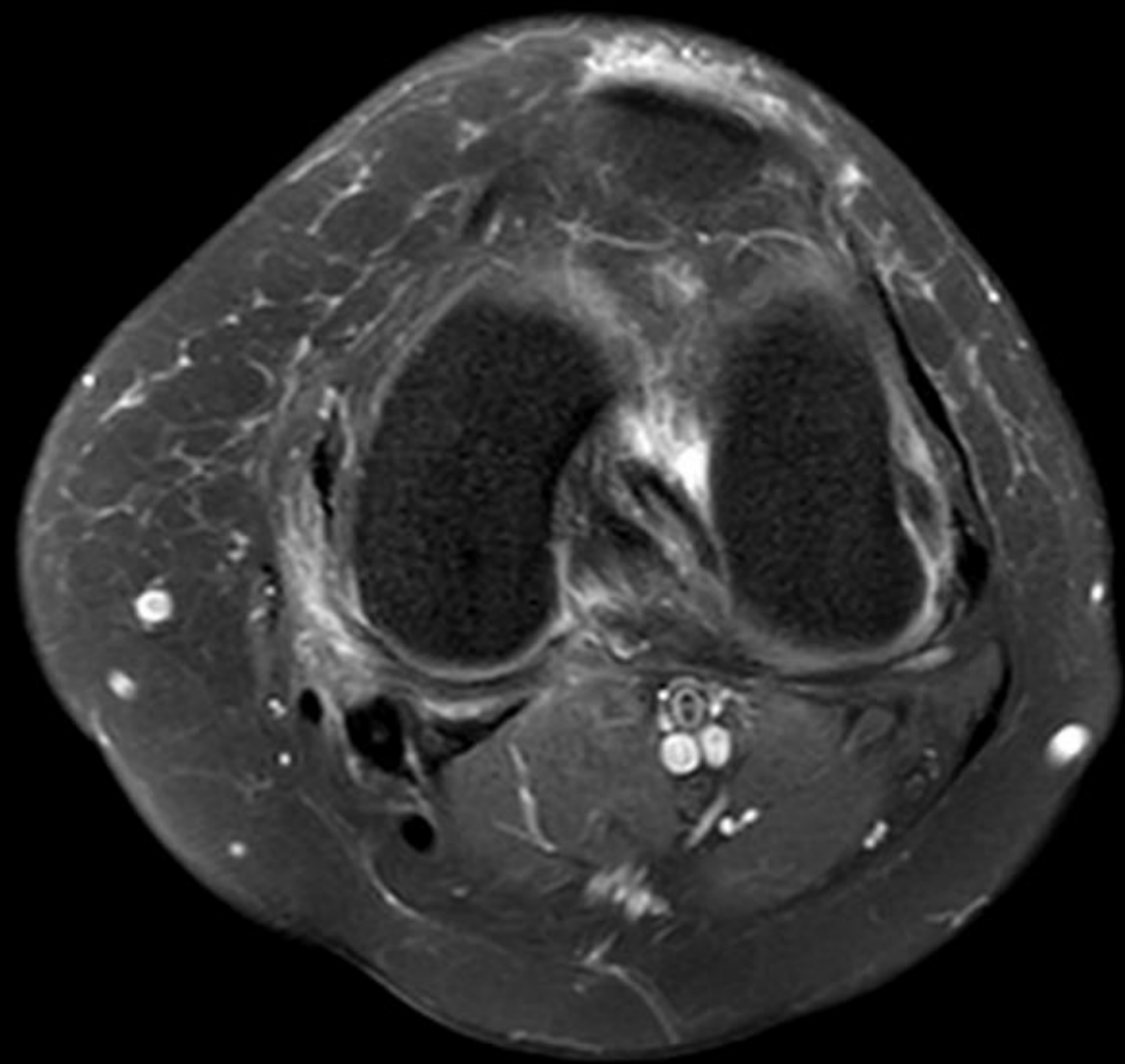
55 yo F complains of trouble with stairs and rising
from seated position x1 month

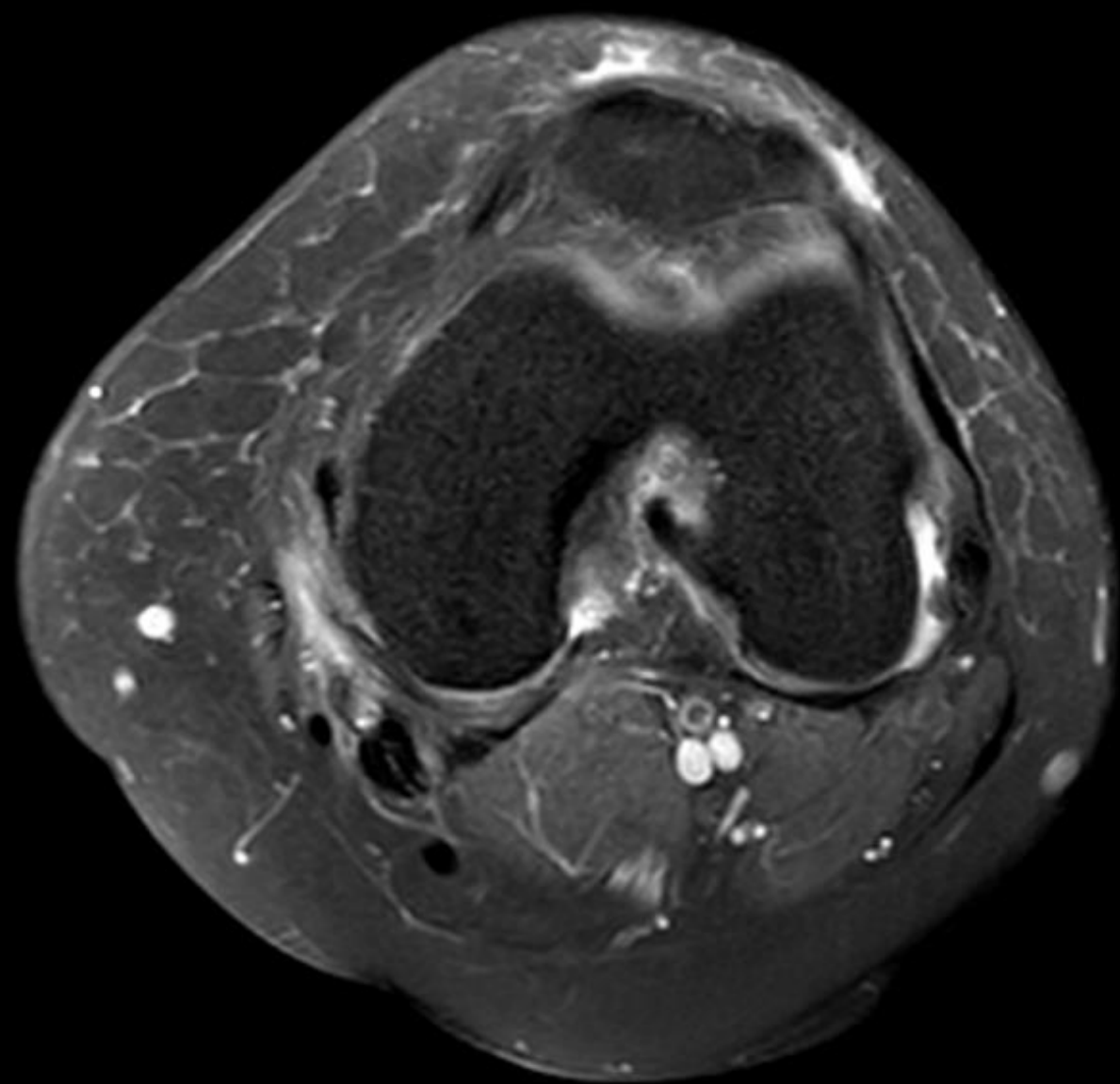


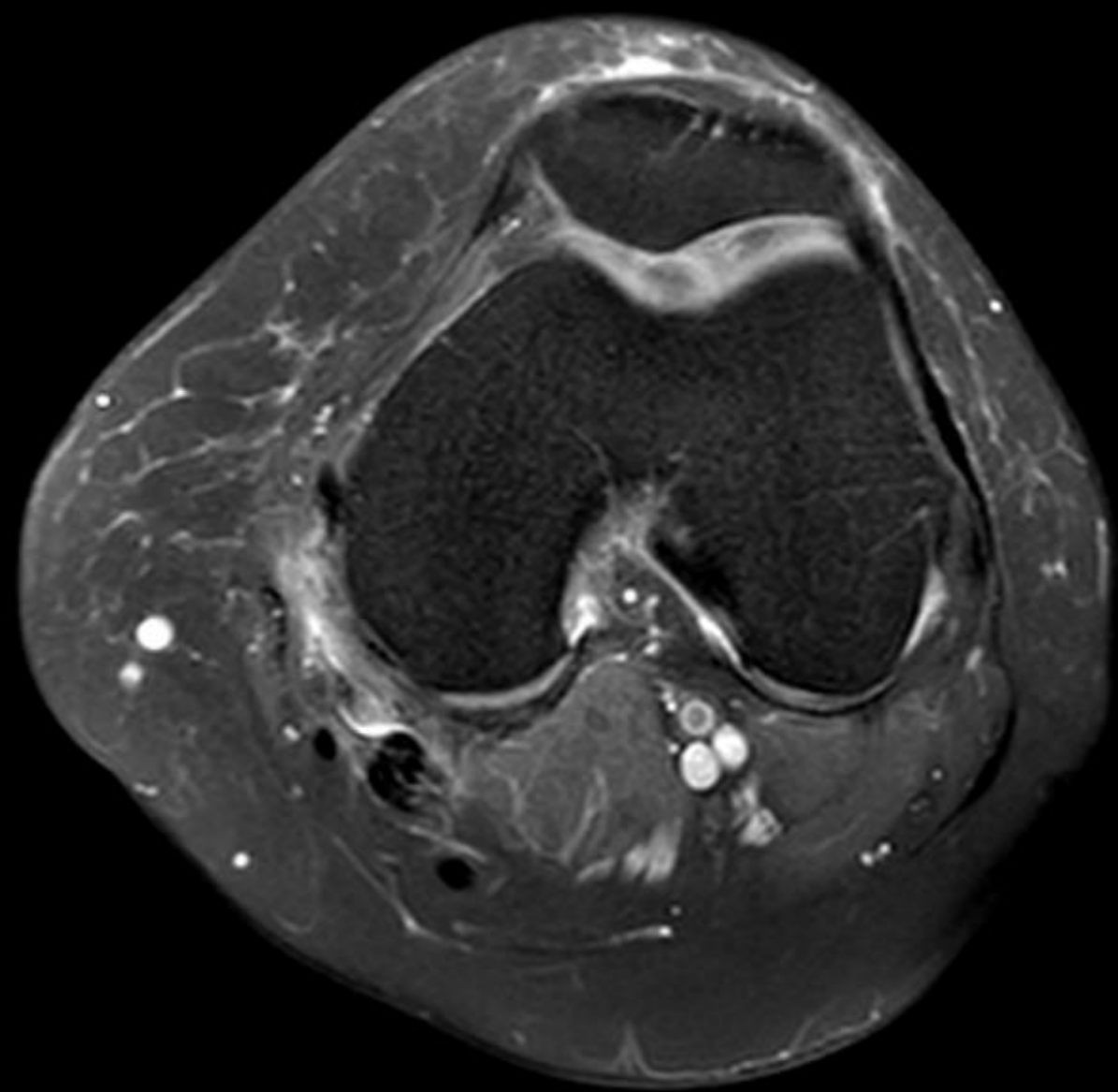


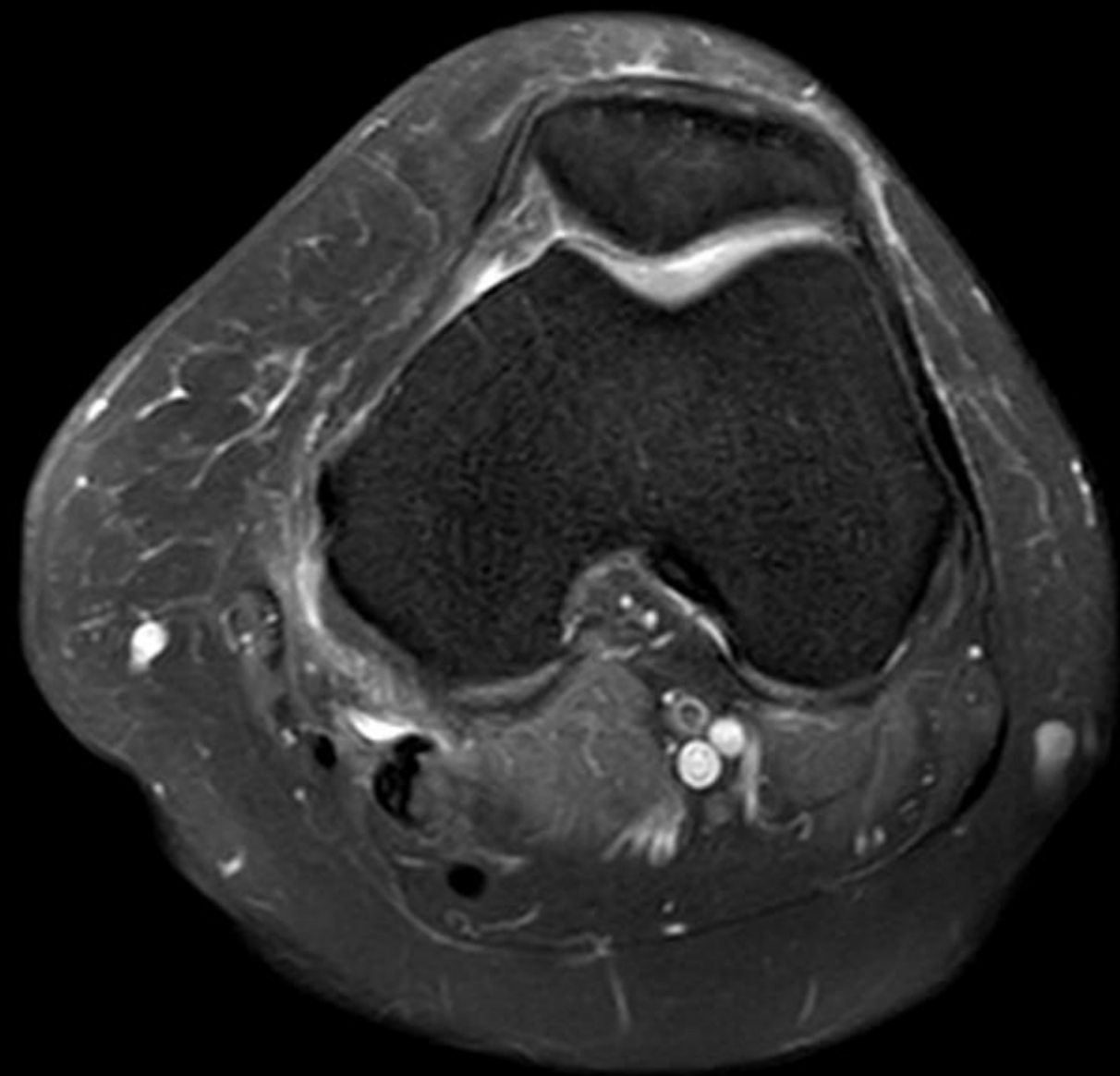


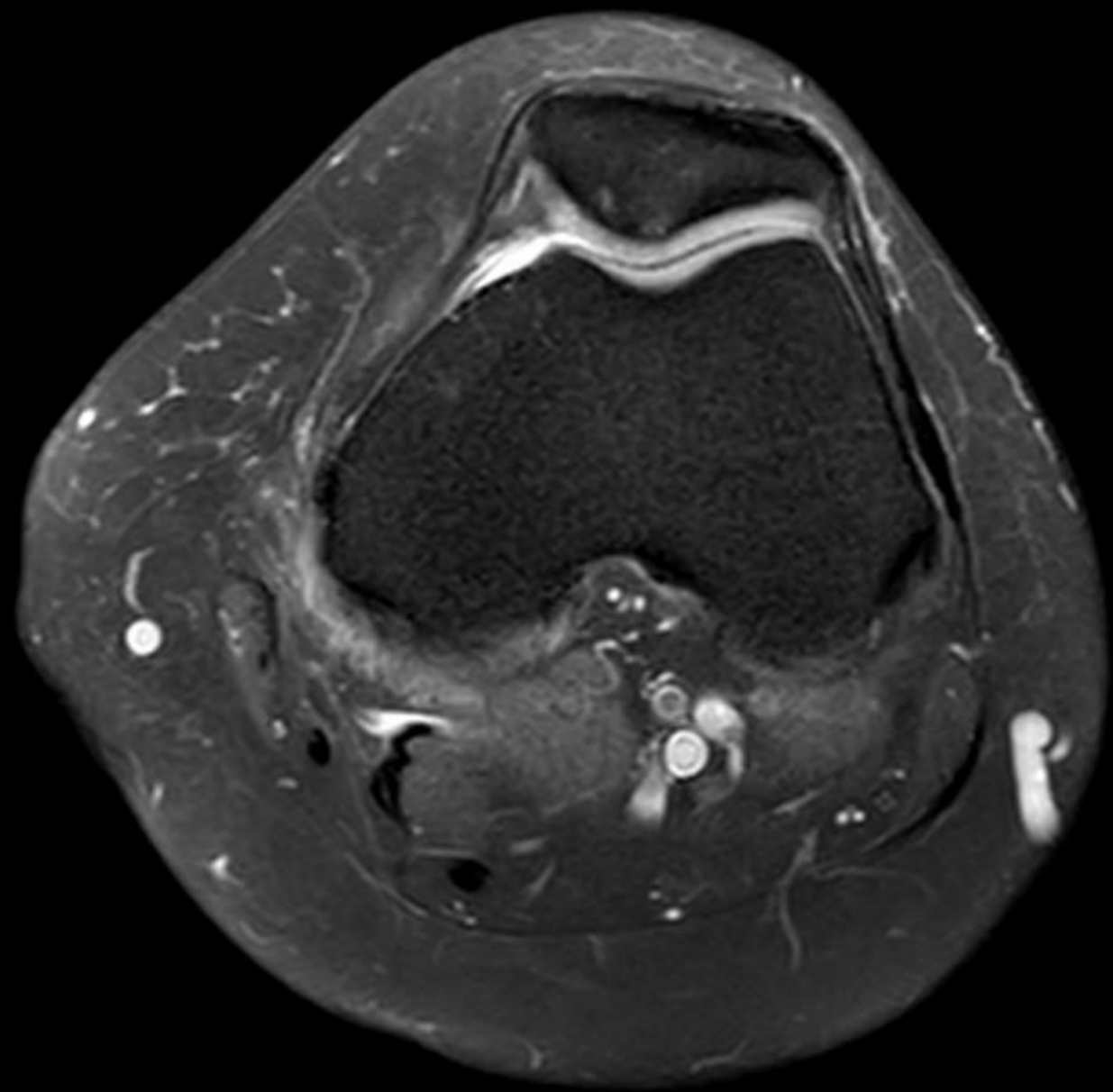


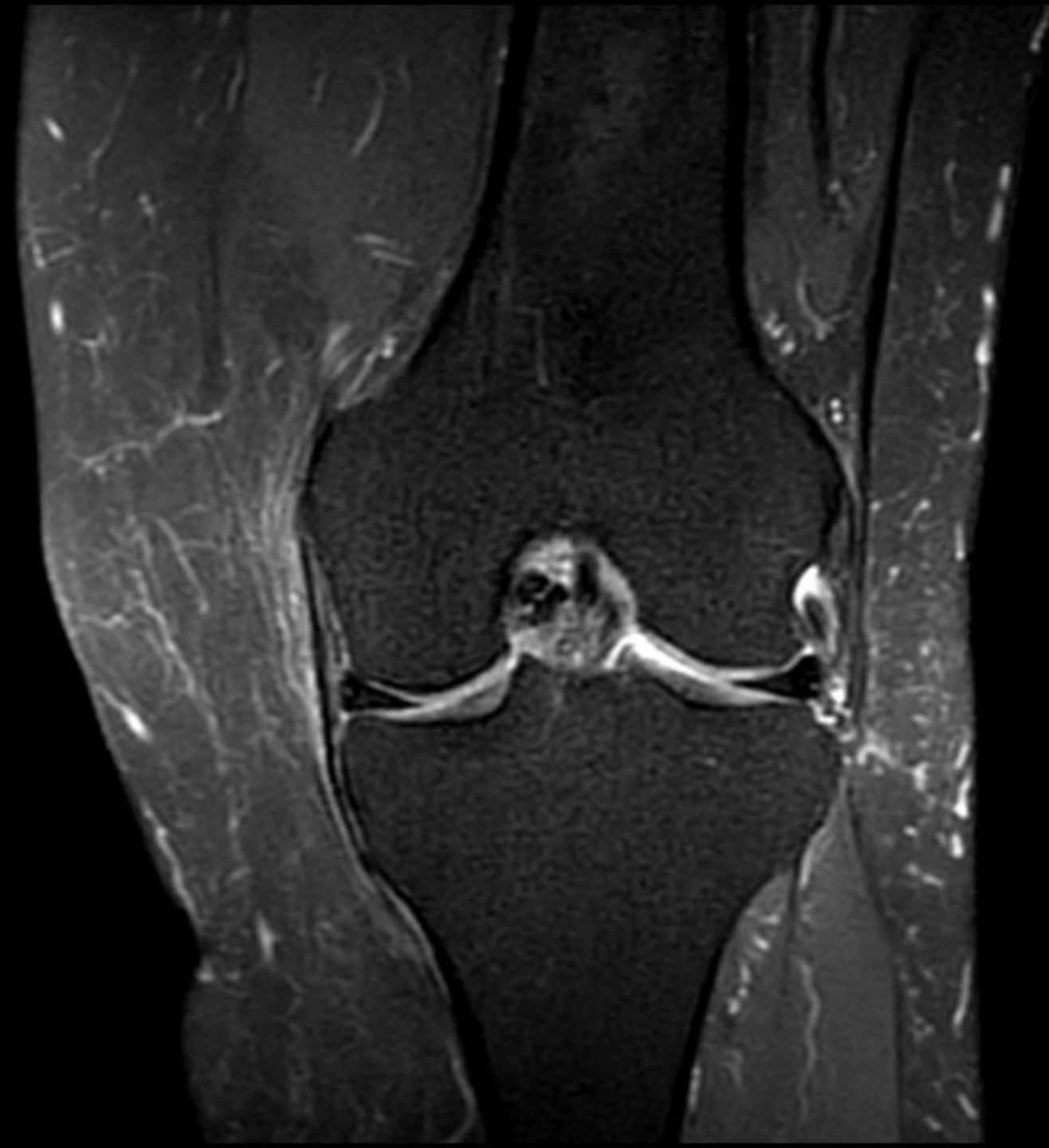


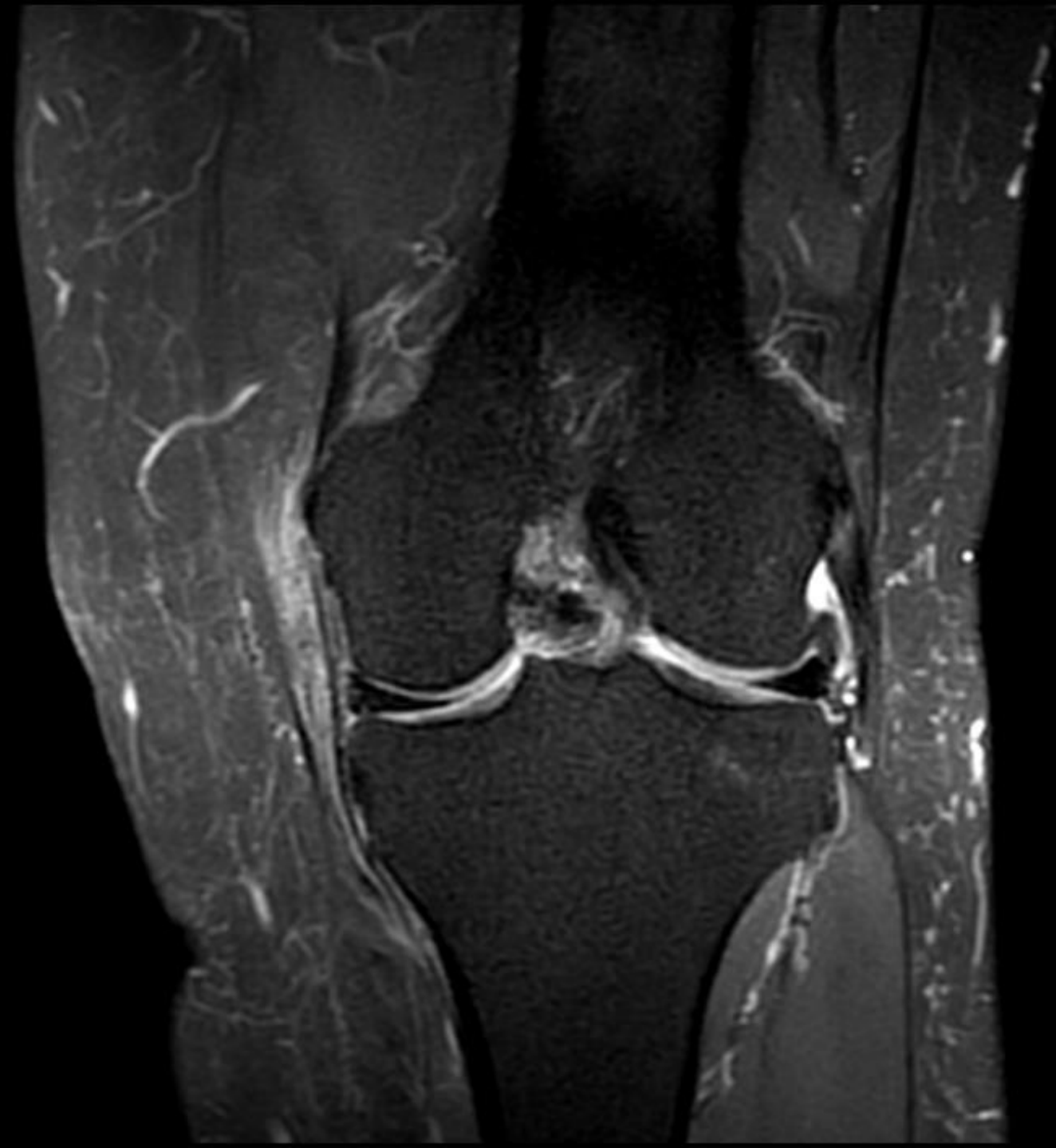


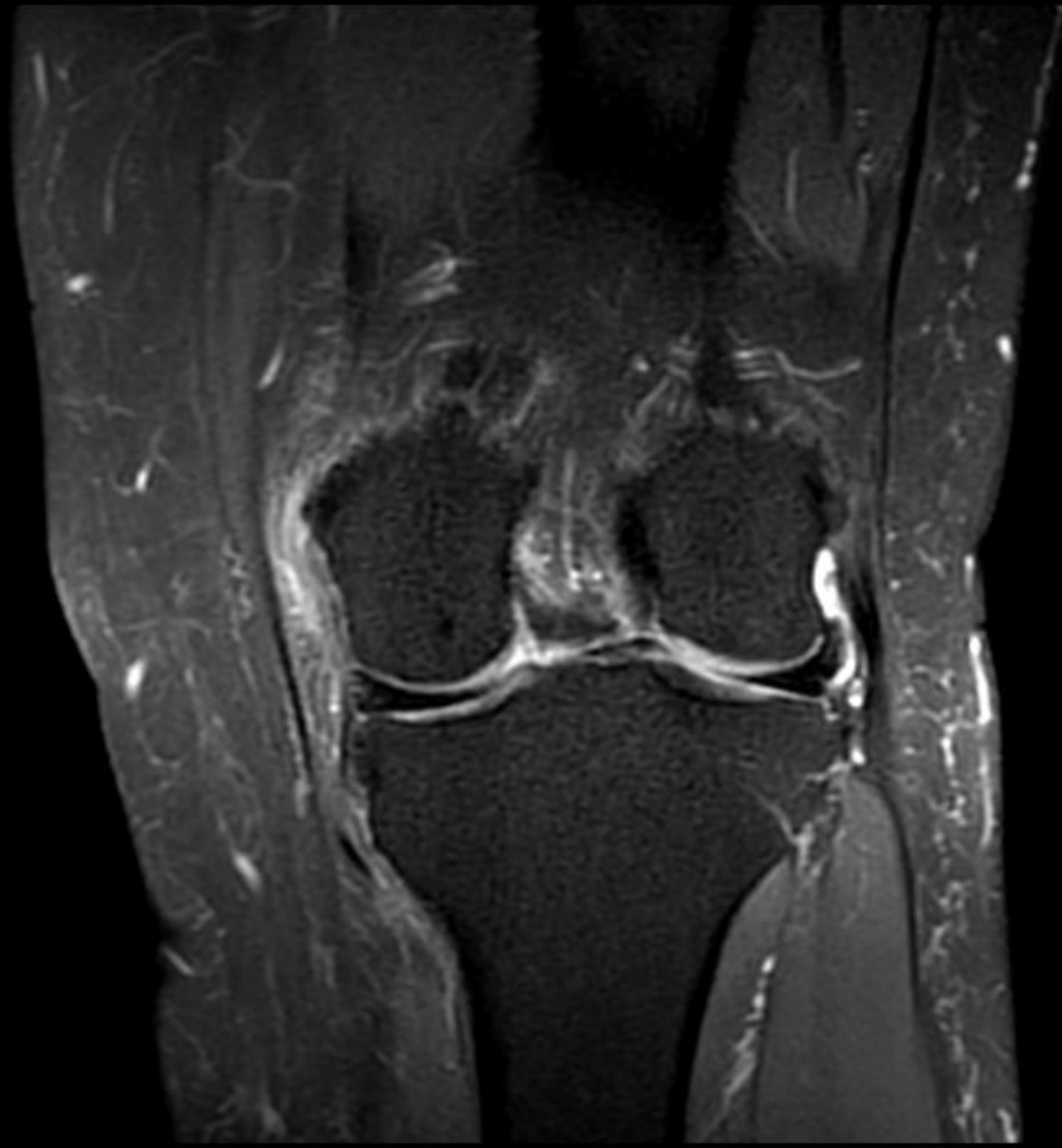


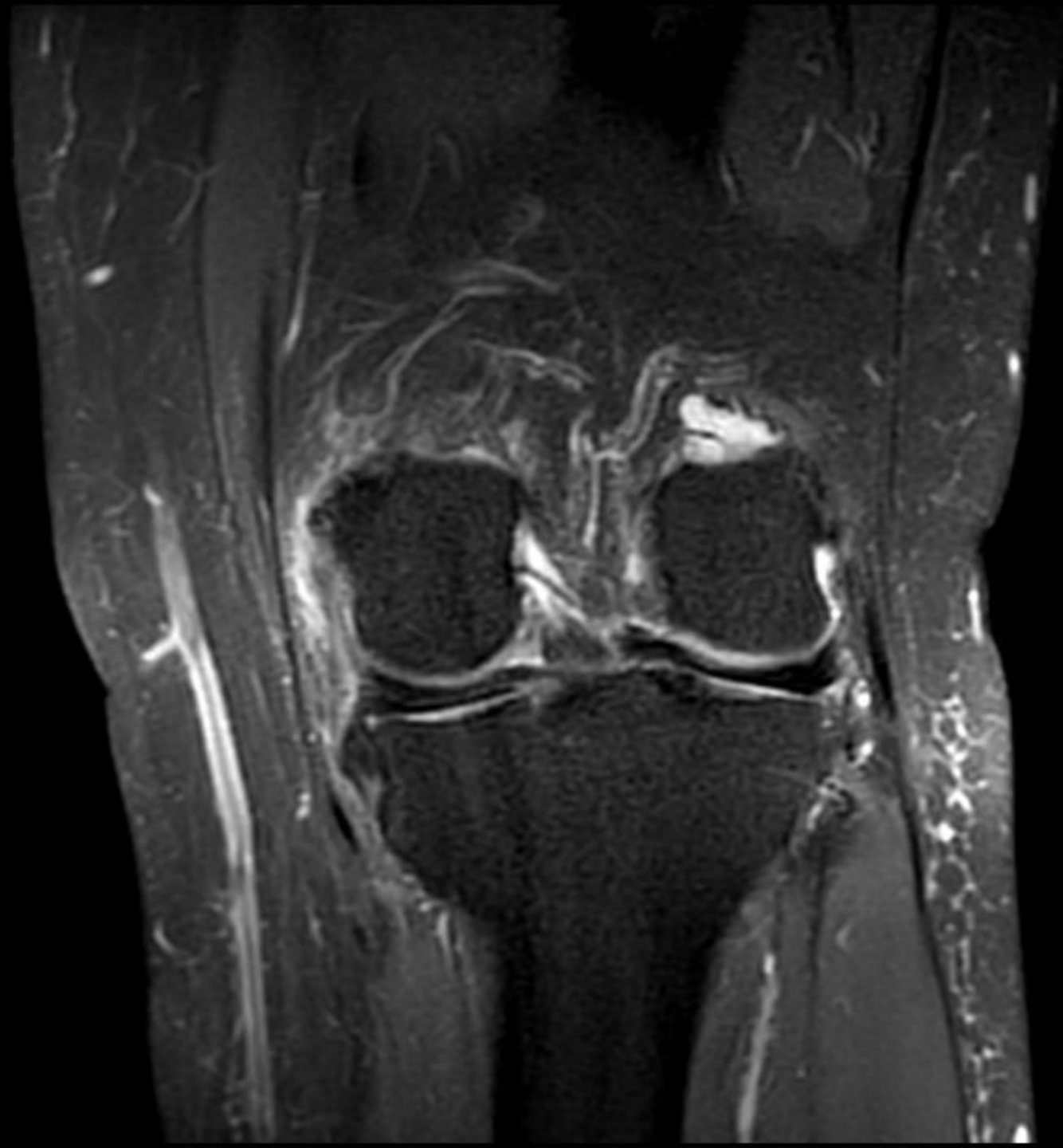


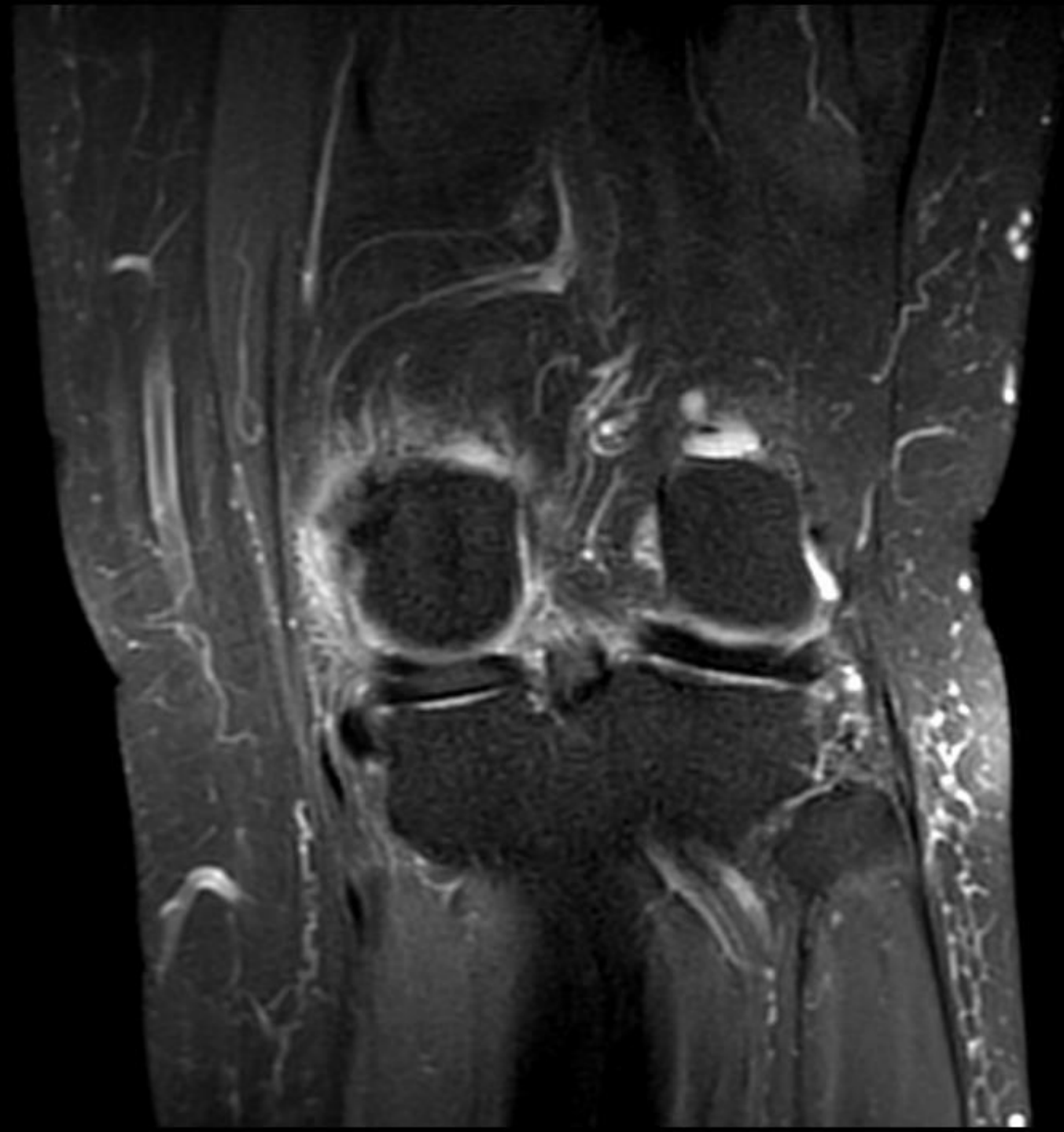


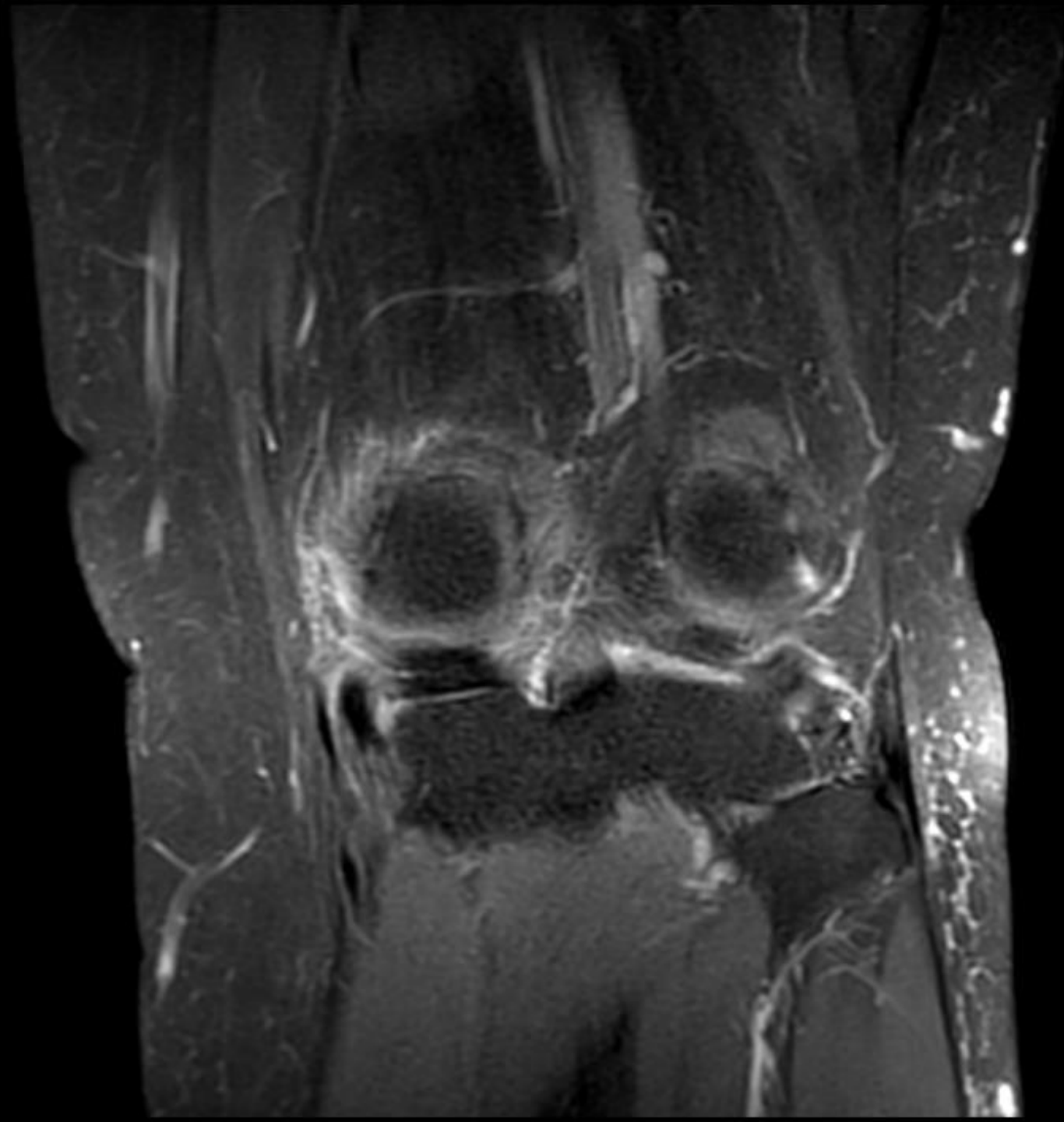
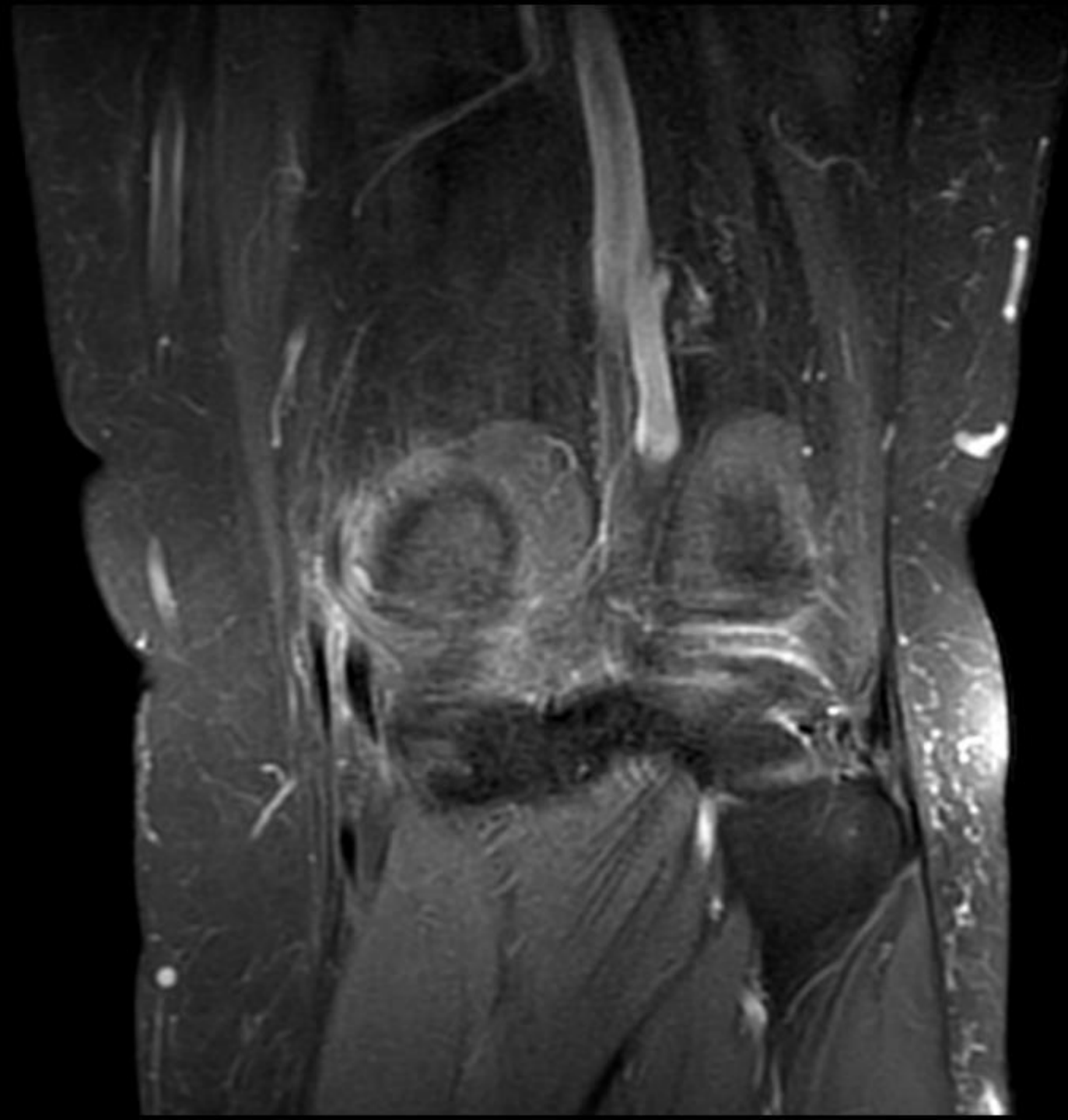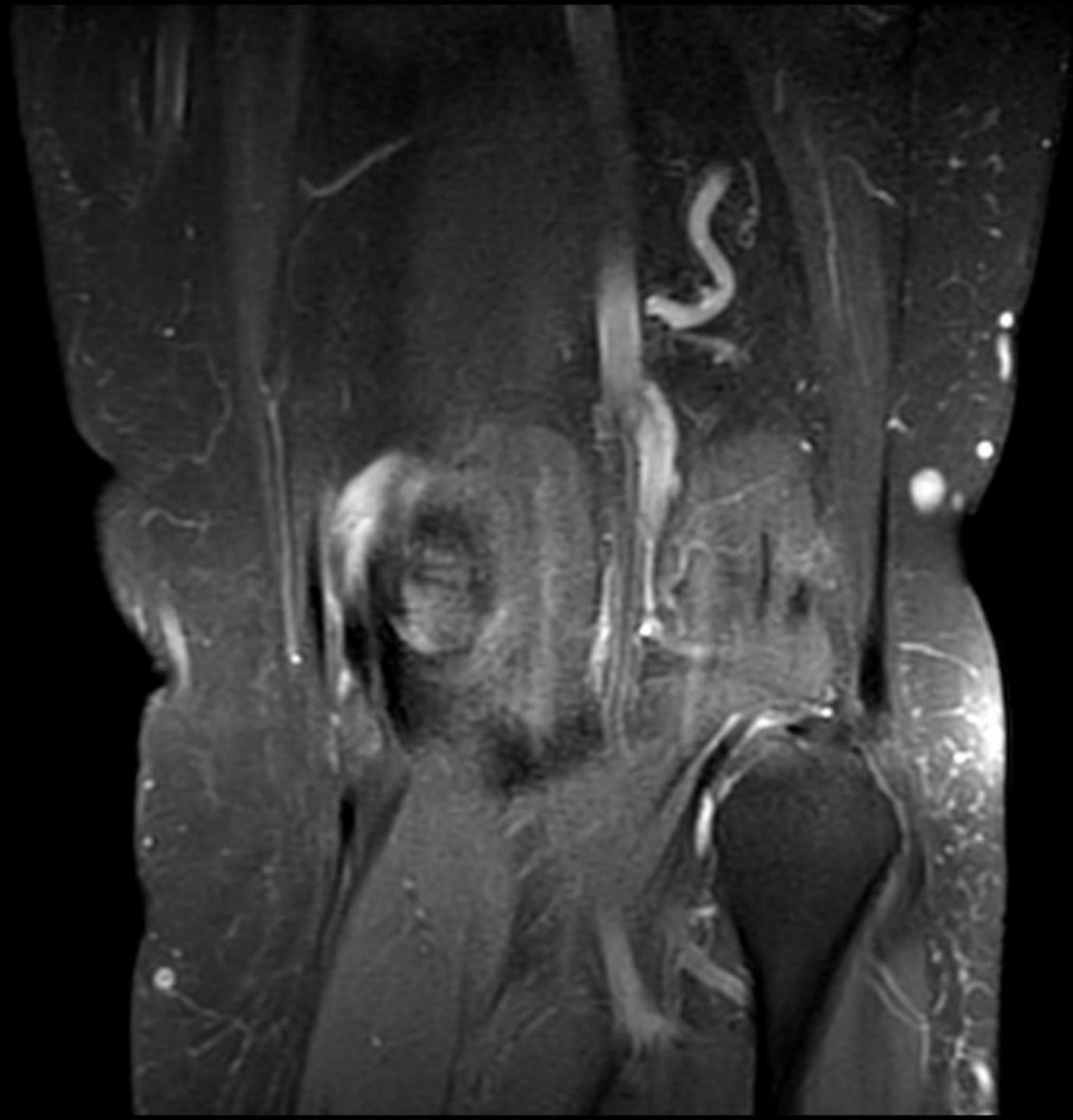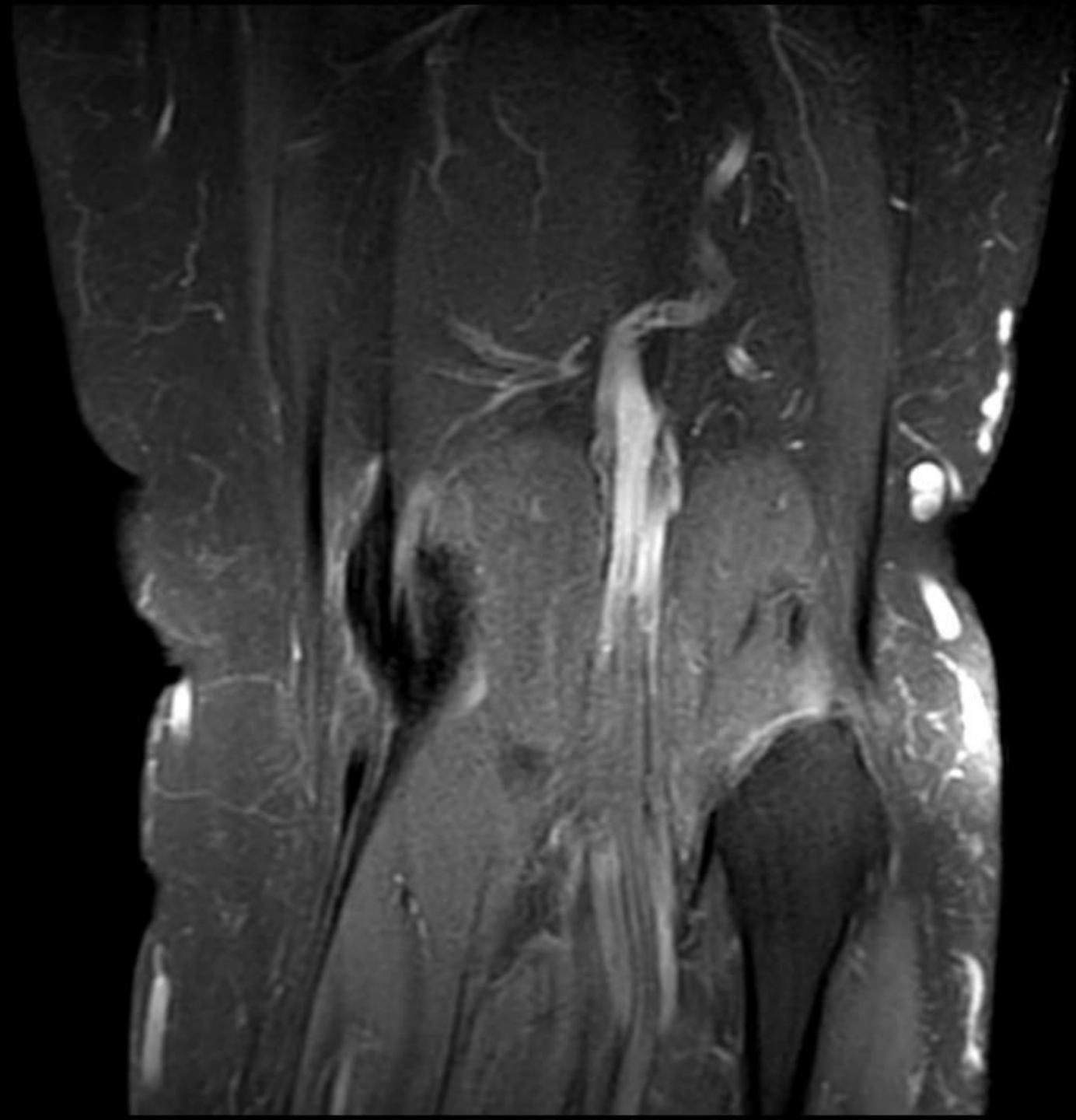


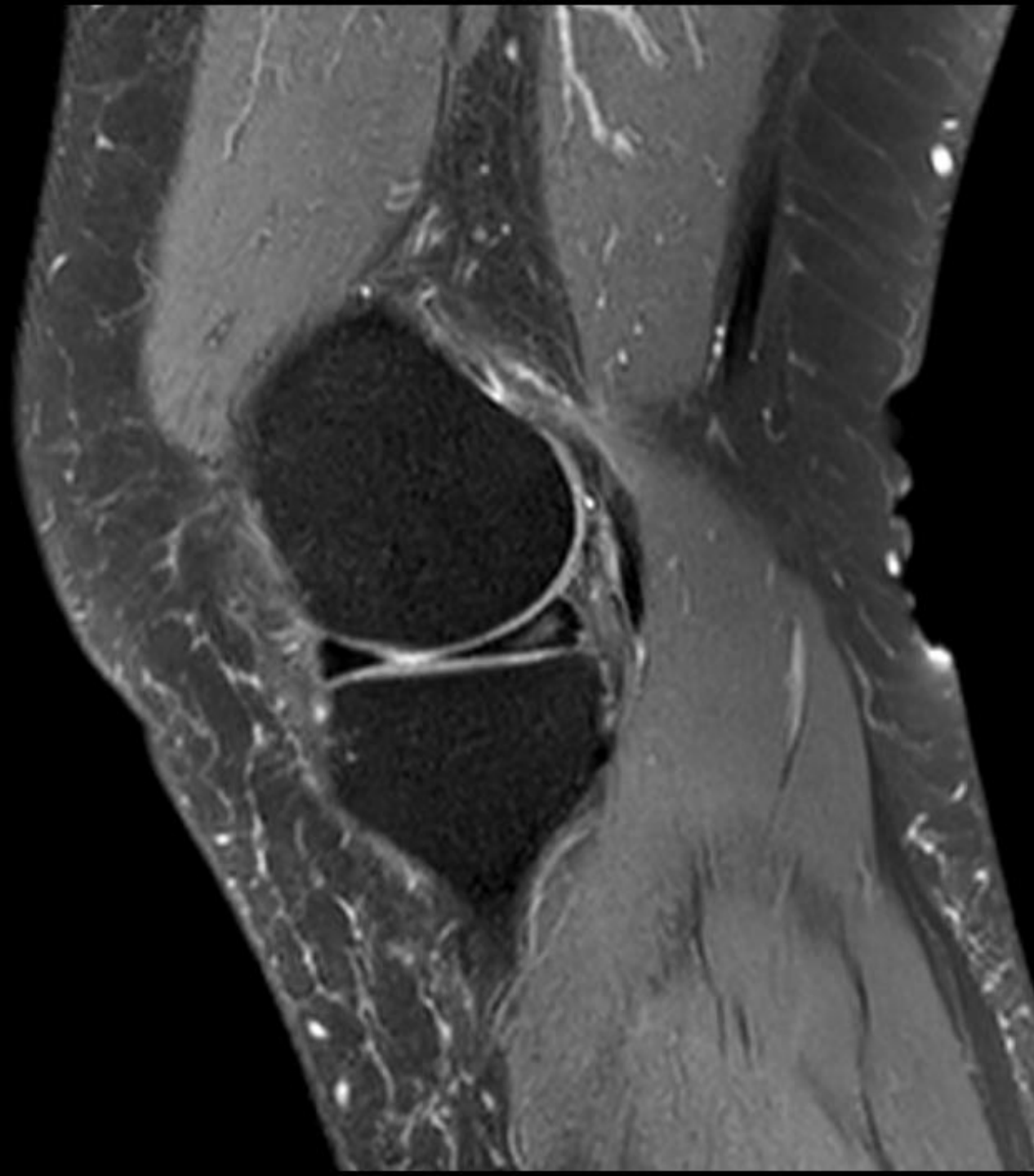




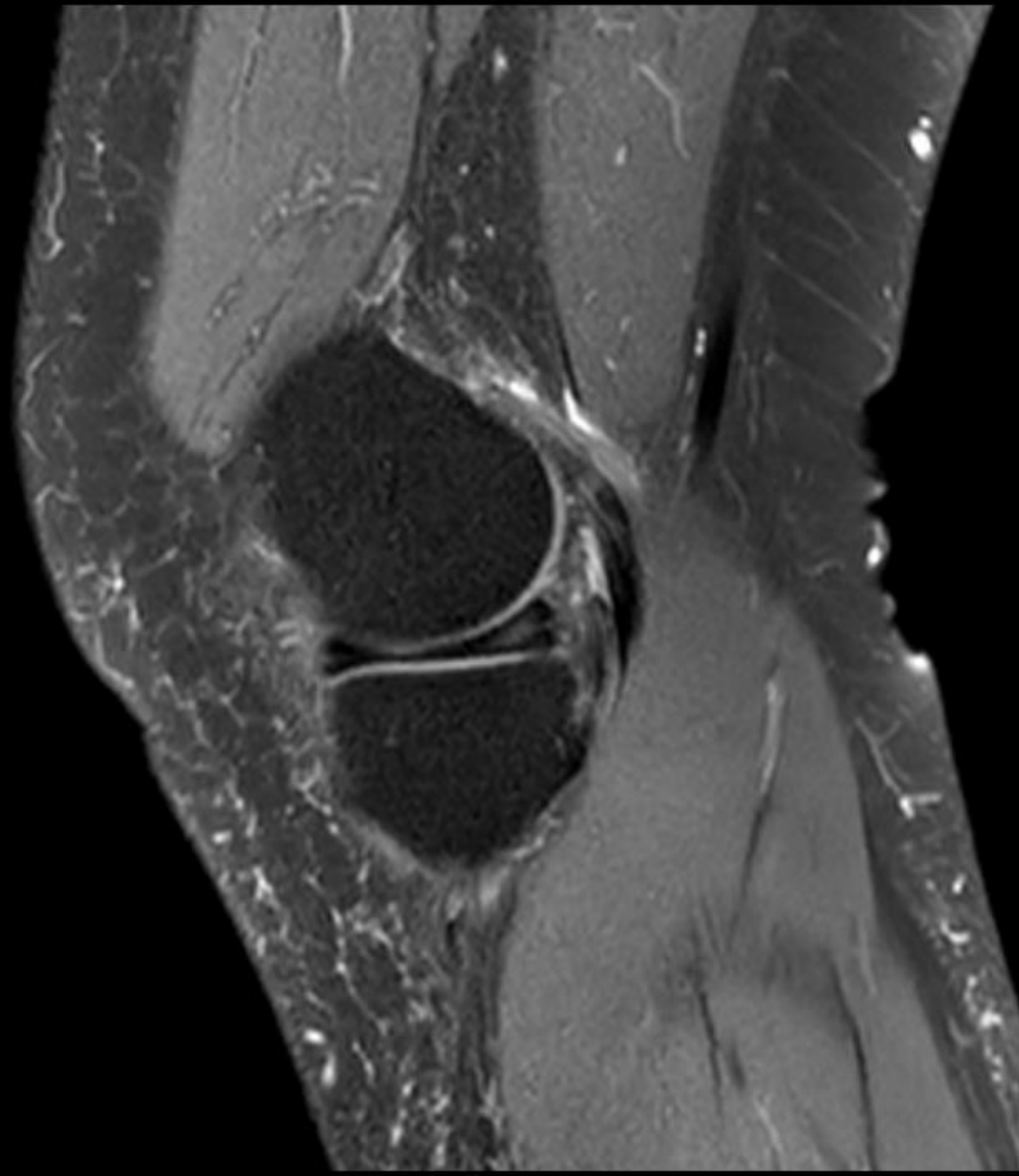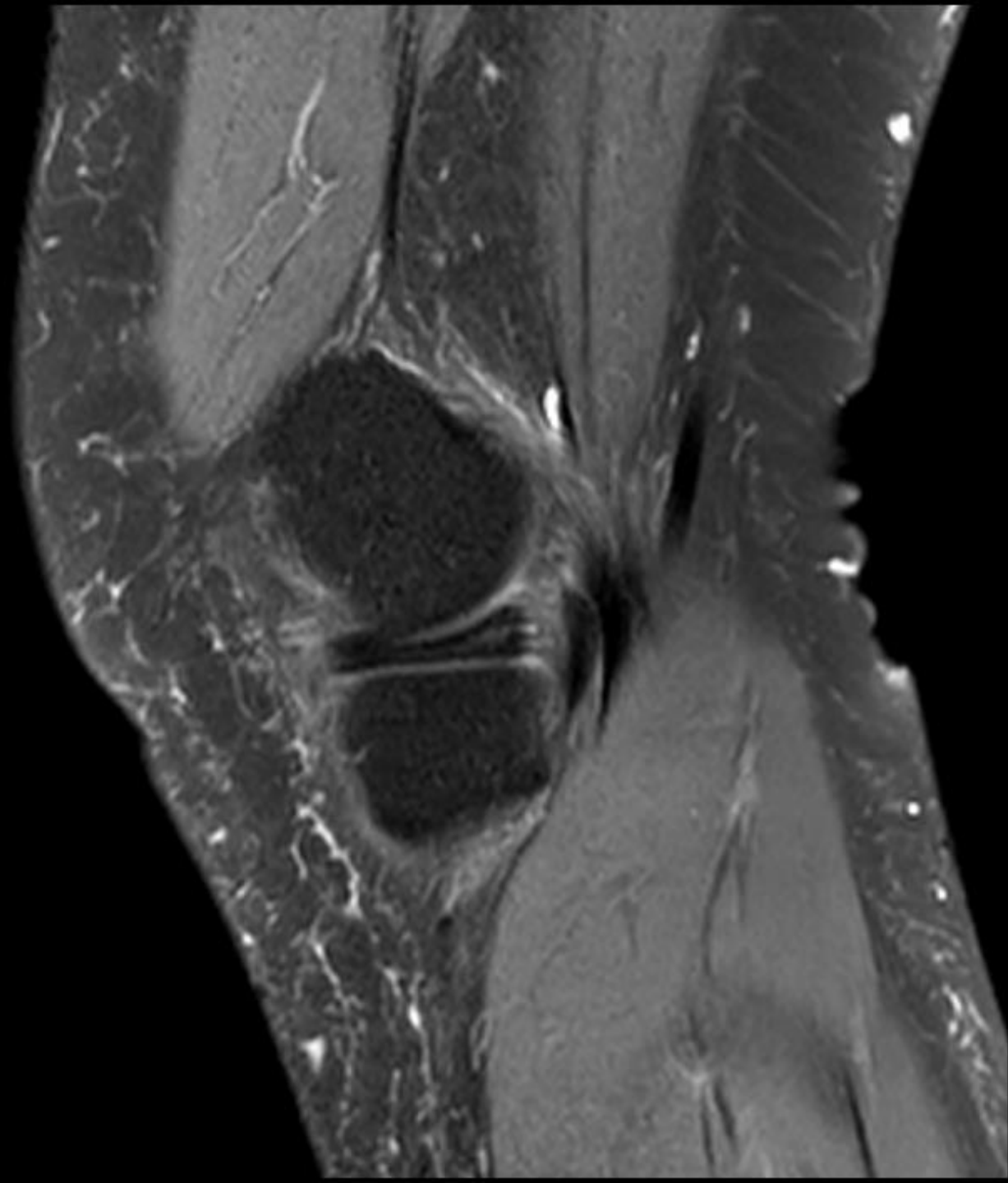


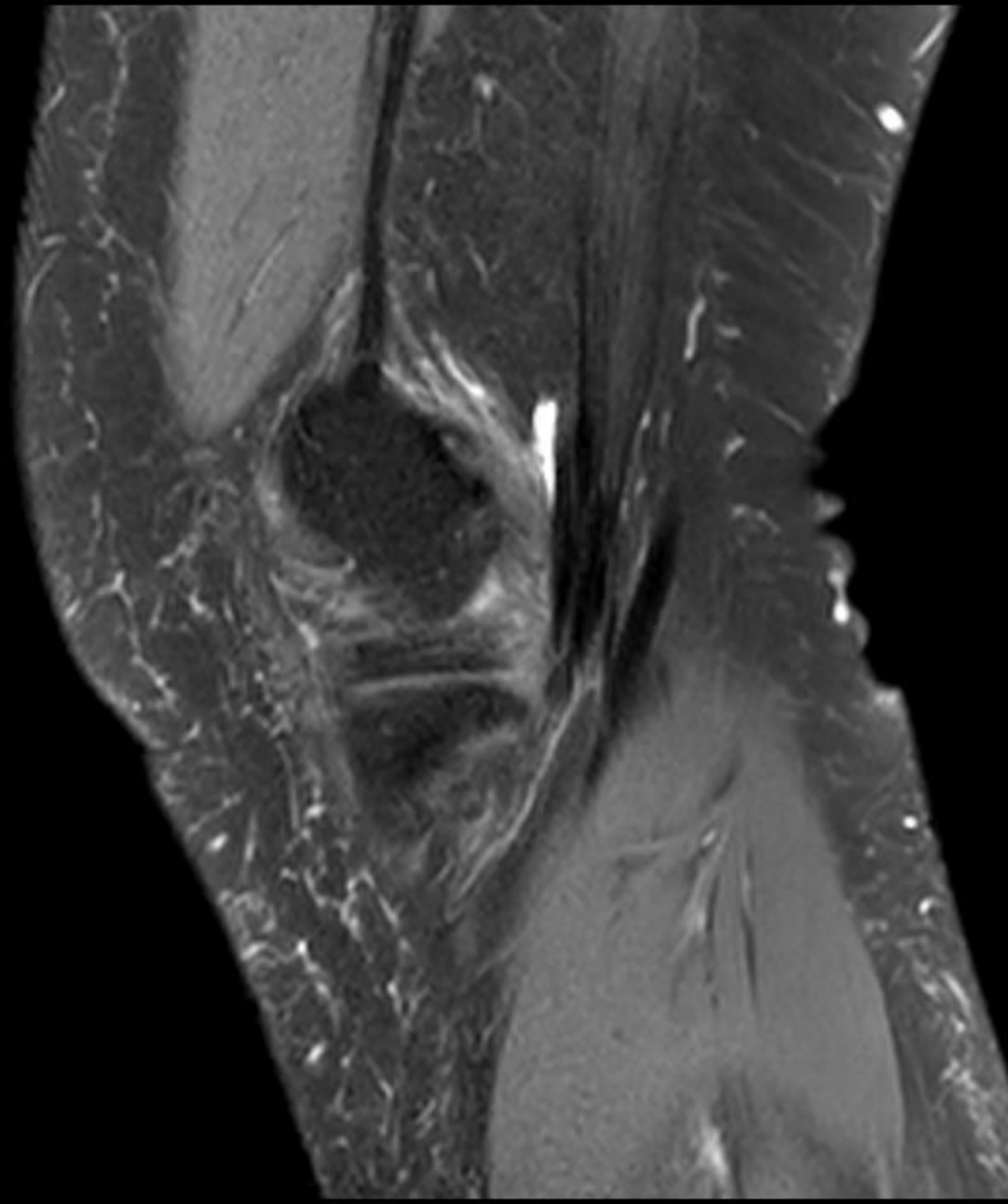


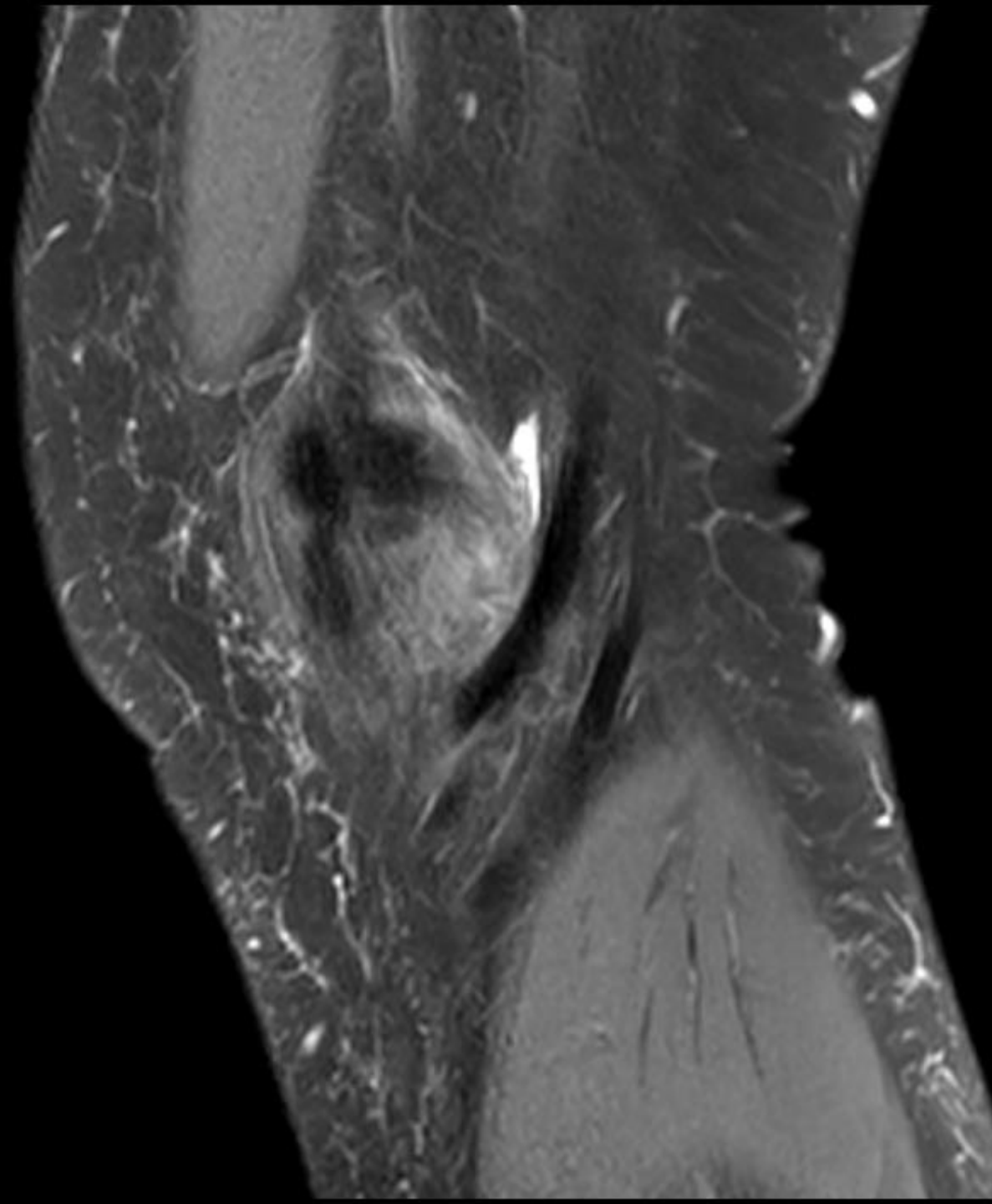


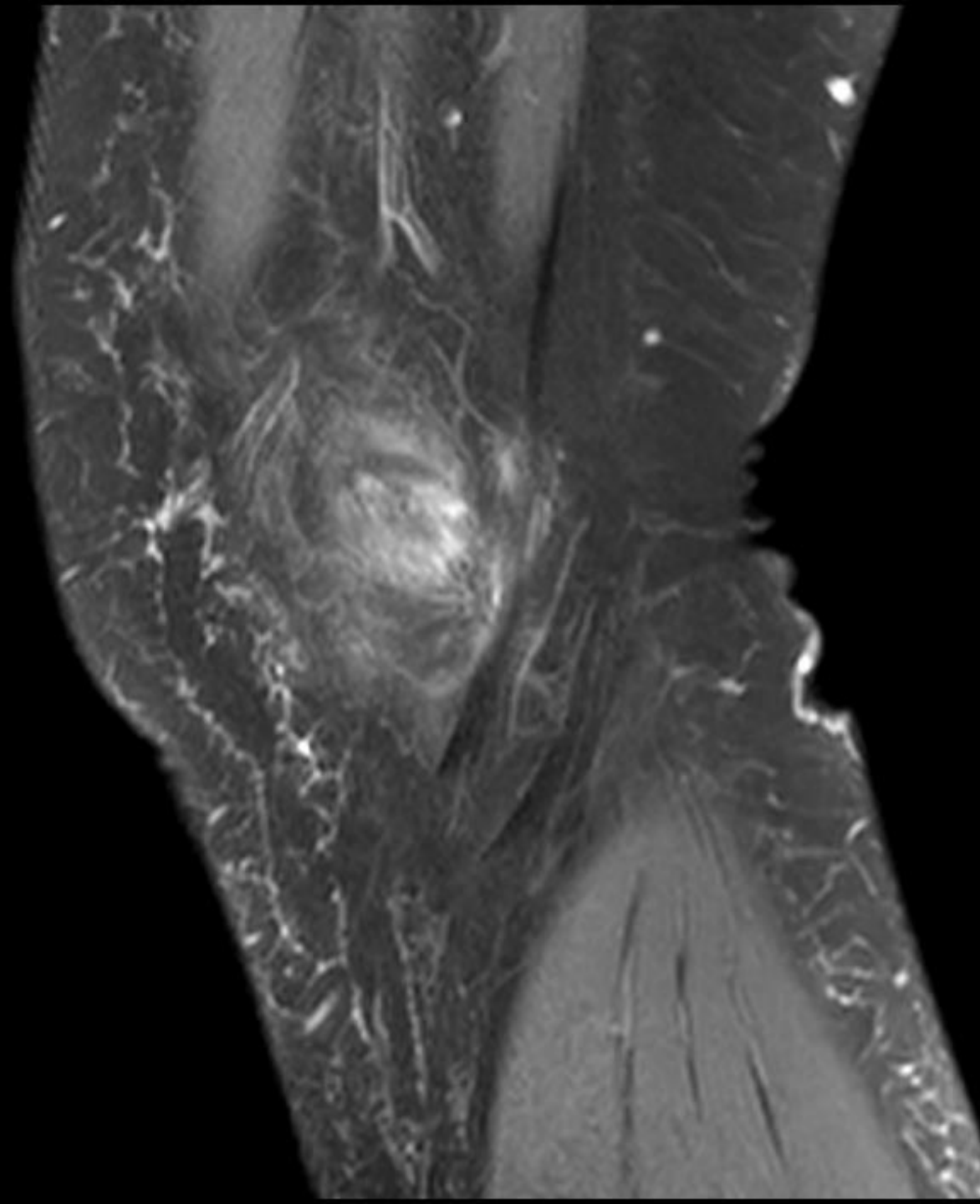


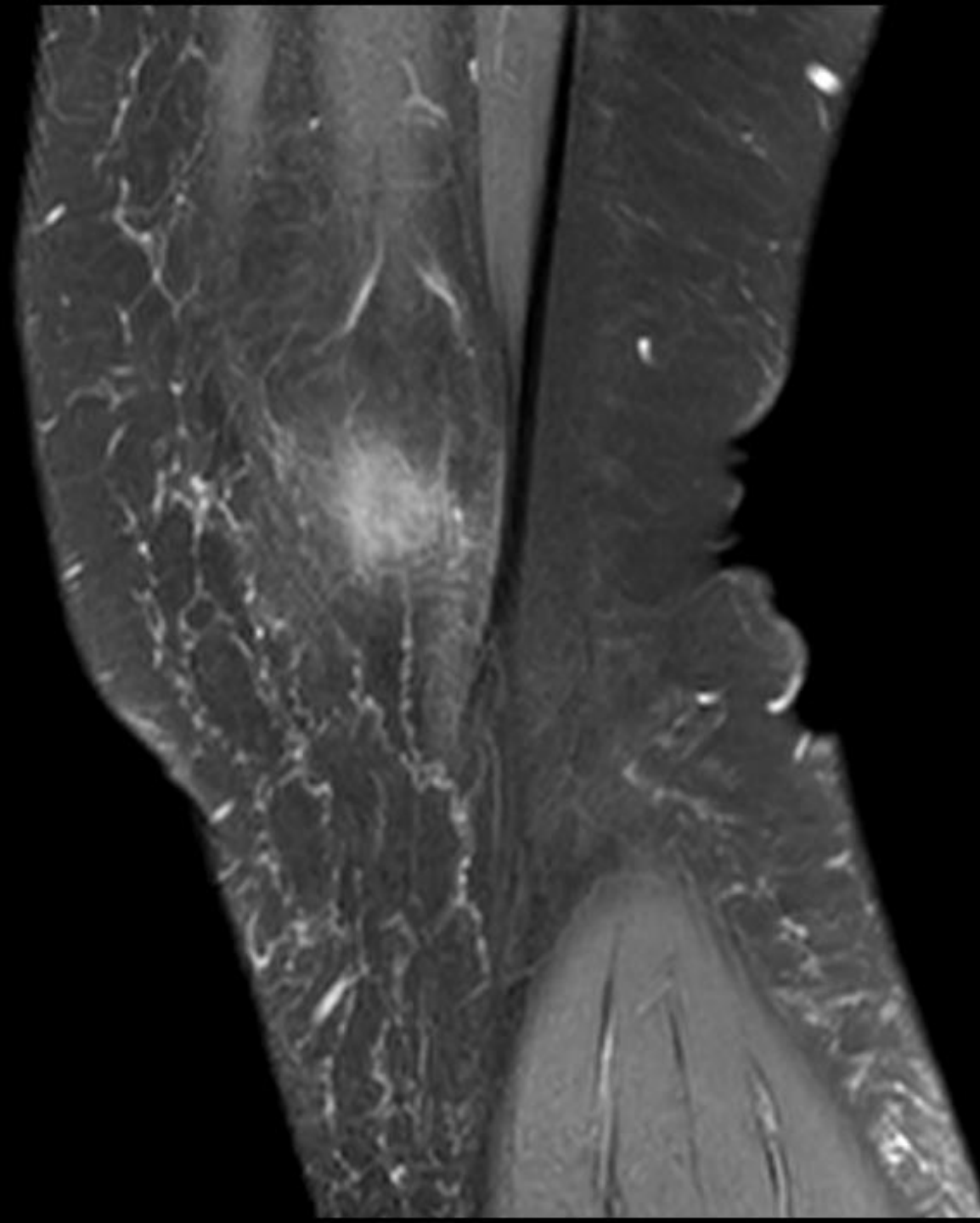


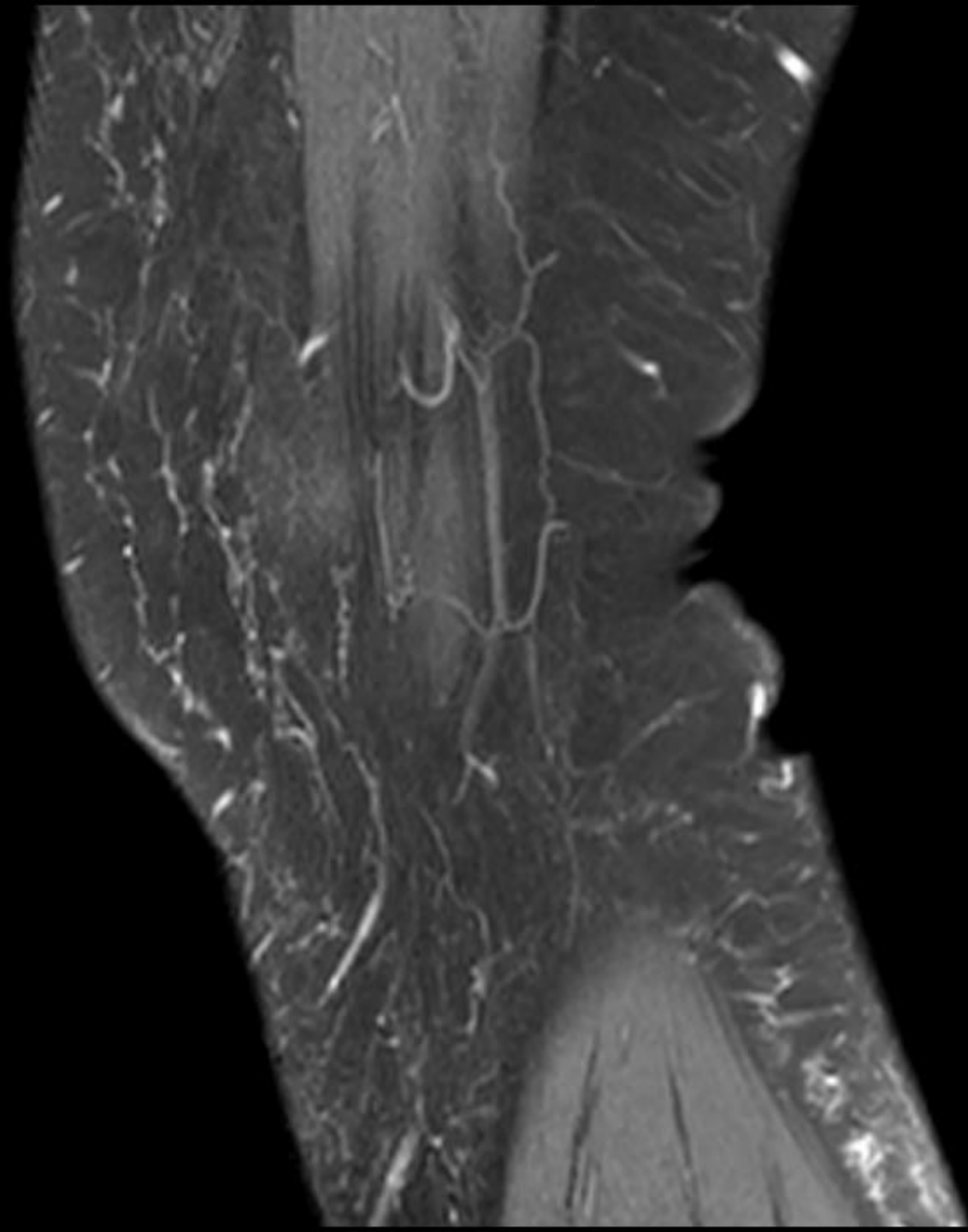


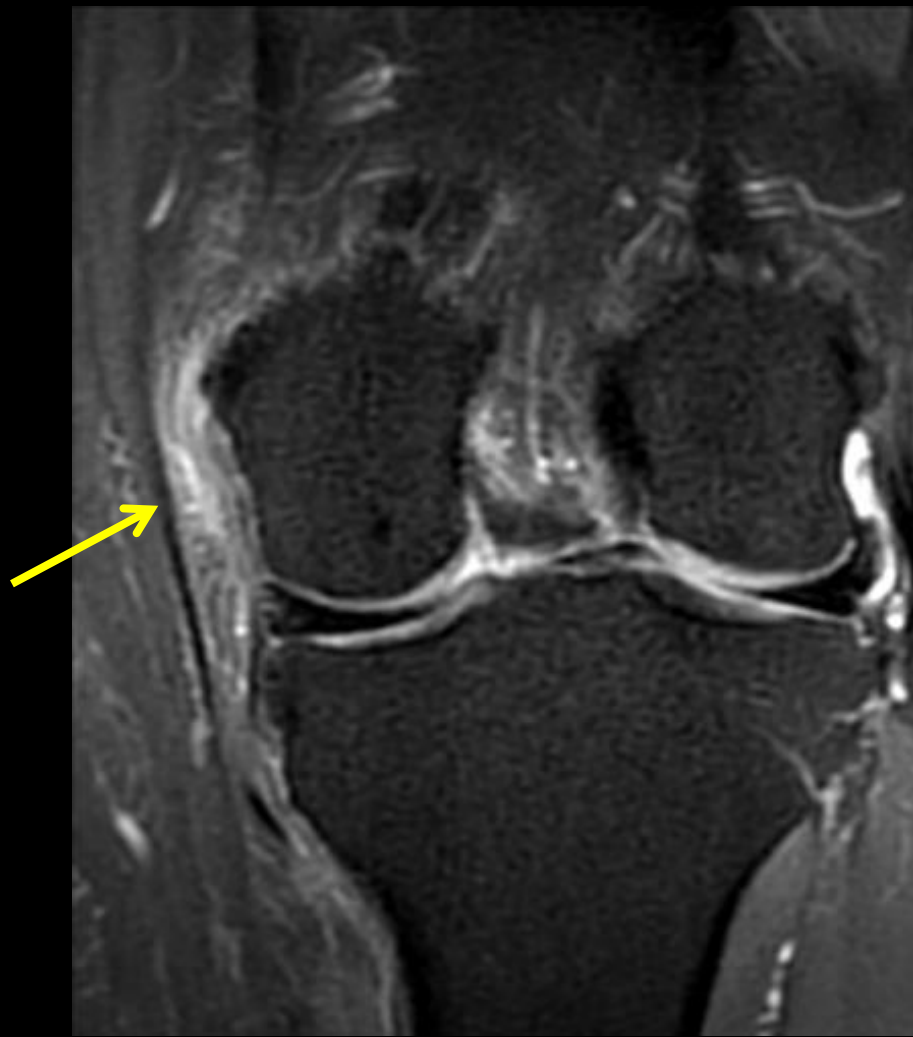
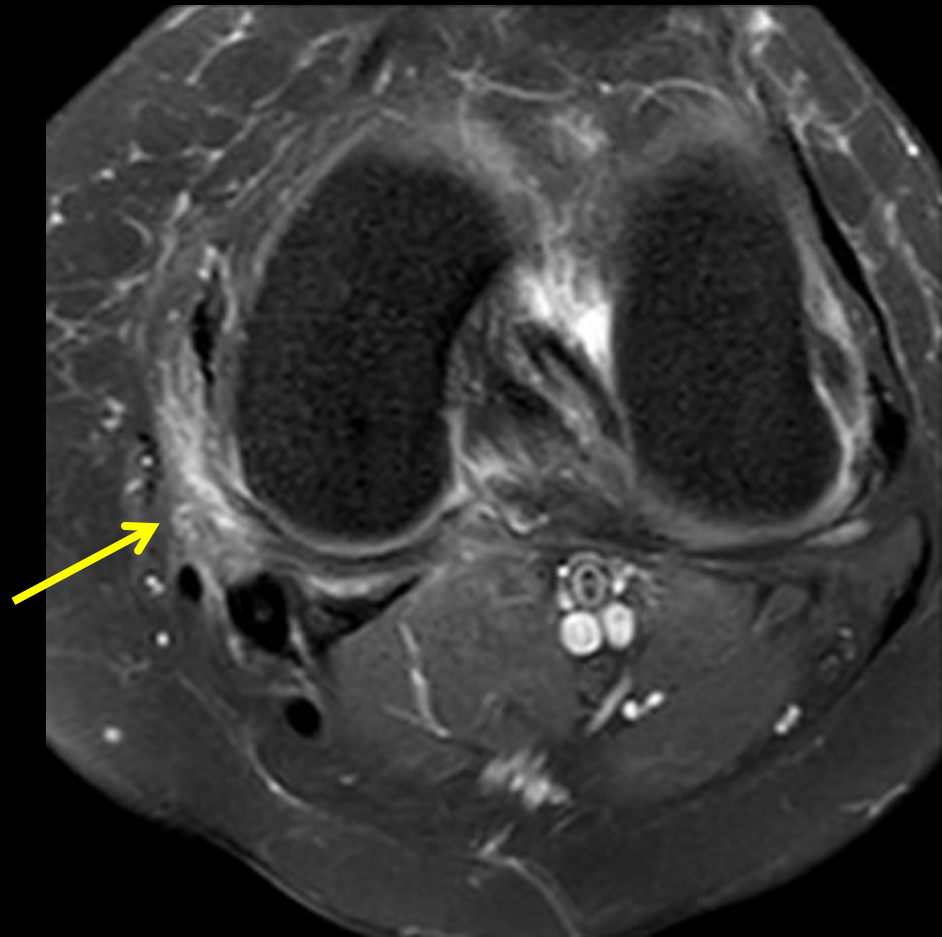













Posteromedial friction syndrome




[Skeletal Radiology](#)

April 2015, Volume 44, [Issue 4](#), pp 557–563

Posteromedial knee friction syndrome: an entity with medial knee pain and edema between the femoral condyle, sartorius and gracilis

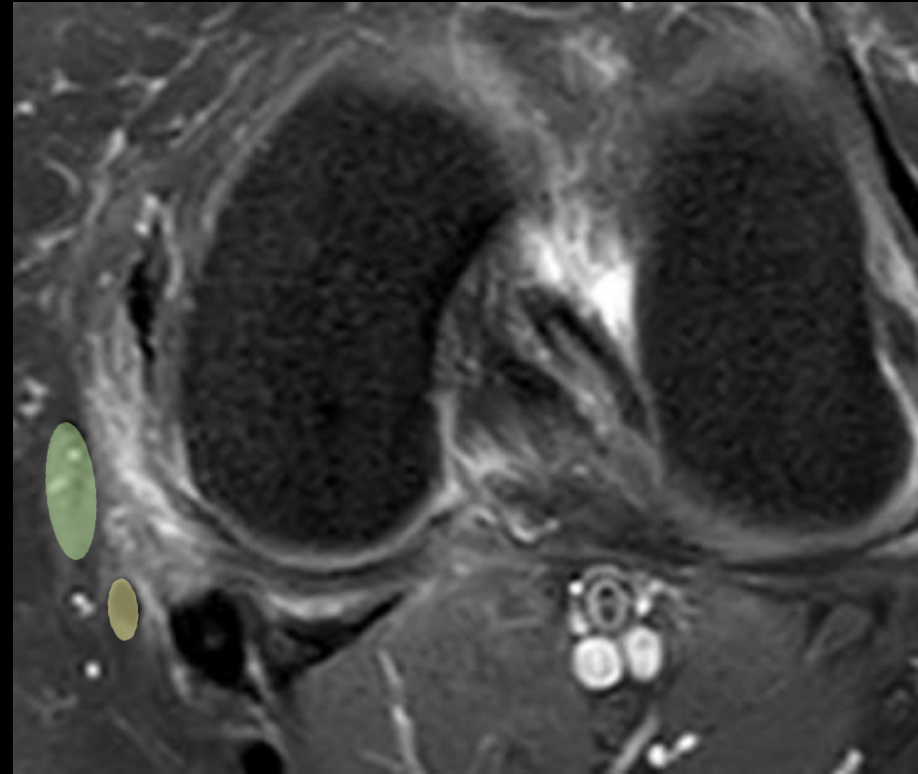
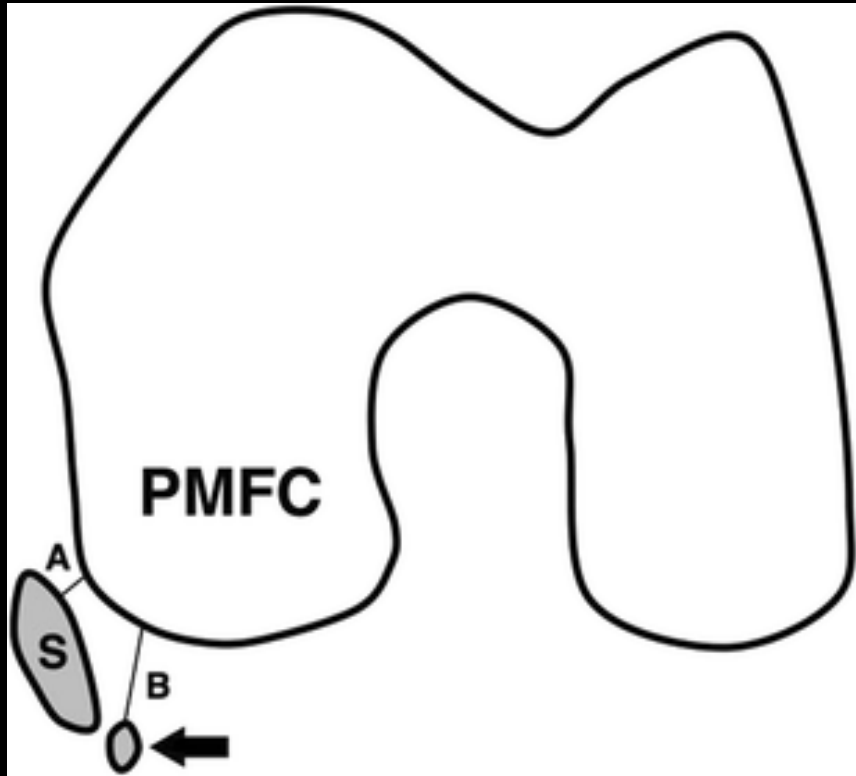
[Authors](#)

[Authors and affiliations](#)

F. Joseph Simeone, Ambrose J. Huang, Connie Y. Chang, Maximilian Smith, Thomas J. Gill, Miriam A. Bredella, Martin Torriani 

Methods

- Retrospective study
 - 26 abnormal knees
 - Complaint of knee pain (58%)
 - Clinical suspicion of meniscal tear (42%)
 - 27 normal controls
- Quantitative assessment
 - Sartorius-PMFC
 - Gracilis-PMFC
- Qualitative assessment
 - Degree of edema (mild-moderate-severe)



Results

- Sartorius-PMFC
 - 1.6 ± 1.0 vs. 2.1 ± 1.2 mm
- Gracilis-PMFC
 - 2.3 ± 2.0 vs. 4.6 ± 3.0 mm
- Sartorius-PMFC
 - 8.8 mm
- Gracilis-PMFC
 - 11 mm



- Degree of edema
 - Mild 14/26
 - Moderate 9/26
 - Severe 3/26

Treatment

- Conservative management with NSAIDS
 - 1/2 improvement
 - 1/2 no change
- Physical therapy
 - 2/7 improvement
 - 4/7 no improvement
 - 1/7 lost to followup
- Ultrasound-guided steroid injection into the area of edema
 - 2/2 sustained improvement of symptoms

References

- Simeone FJ, Huang AJ, Chang CY, et al. Posteromedial knee friction syndrome: an entity with medial knee pain and edema between the femoral condyle, sartorius and gracilis. *Skeletal Radiology*. 2015;44(4):557-563.
- Posteromedial knee friction syndrome.
<https://radiopaedia.org/articles/posteromedial-knee-friction-syndrome>.
Accessed Sep 29, 2016.