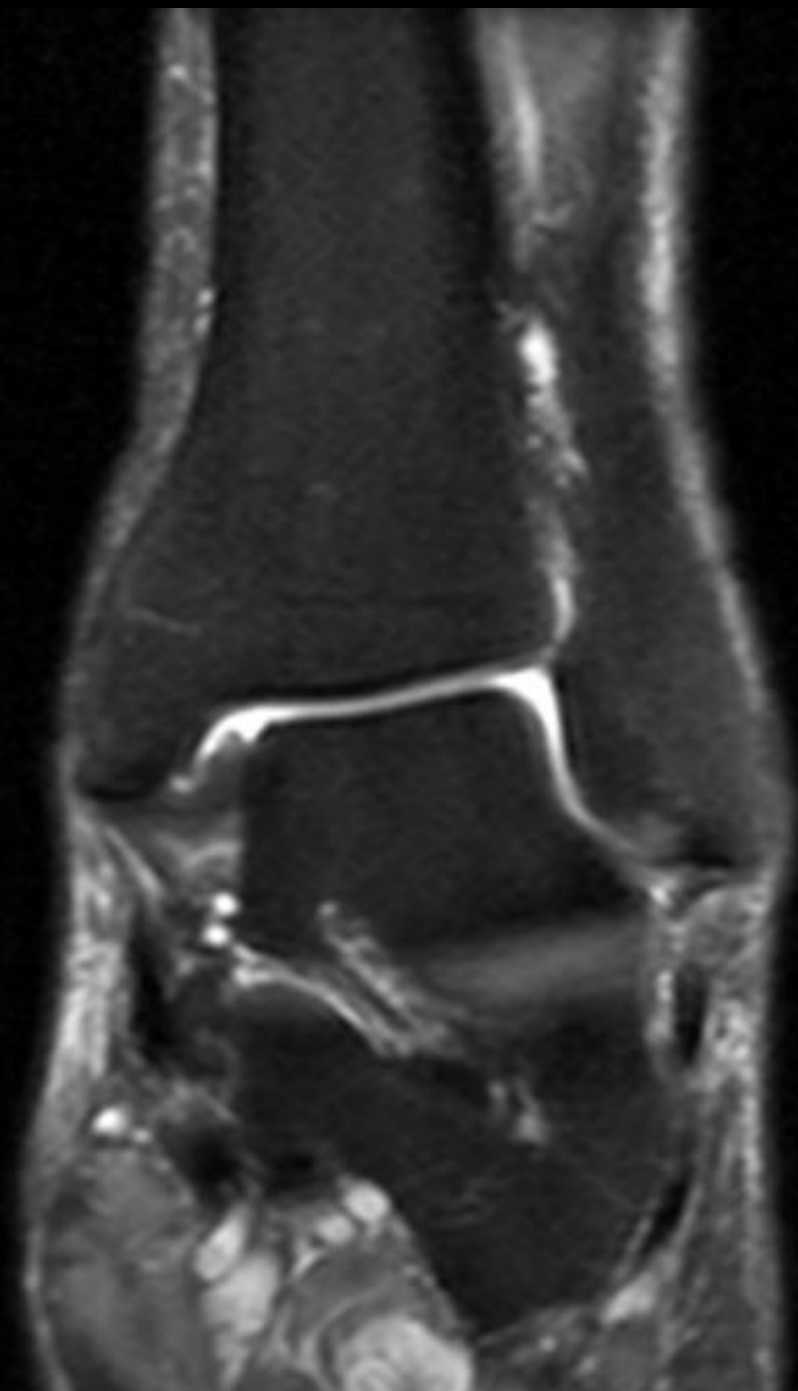
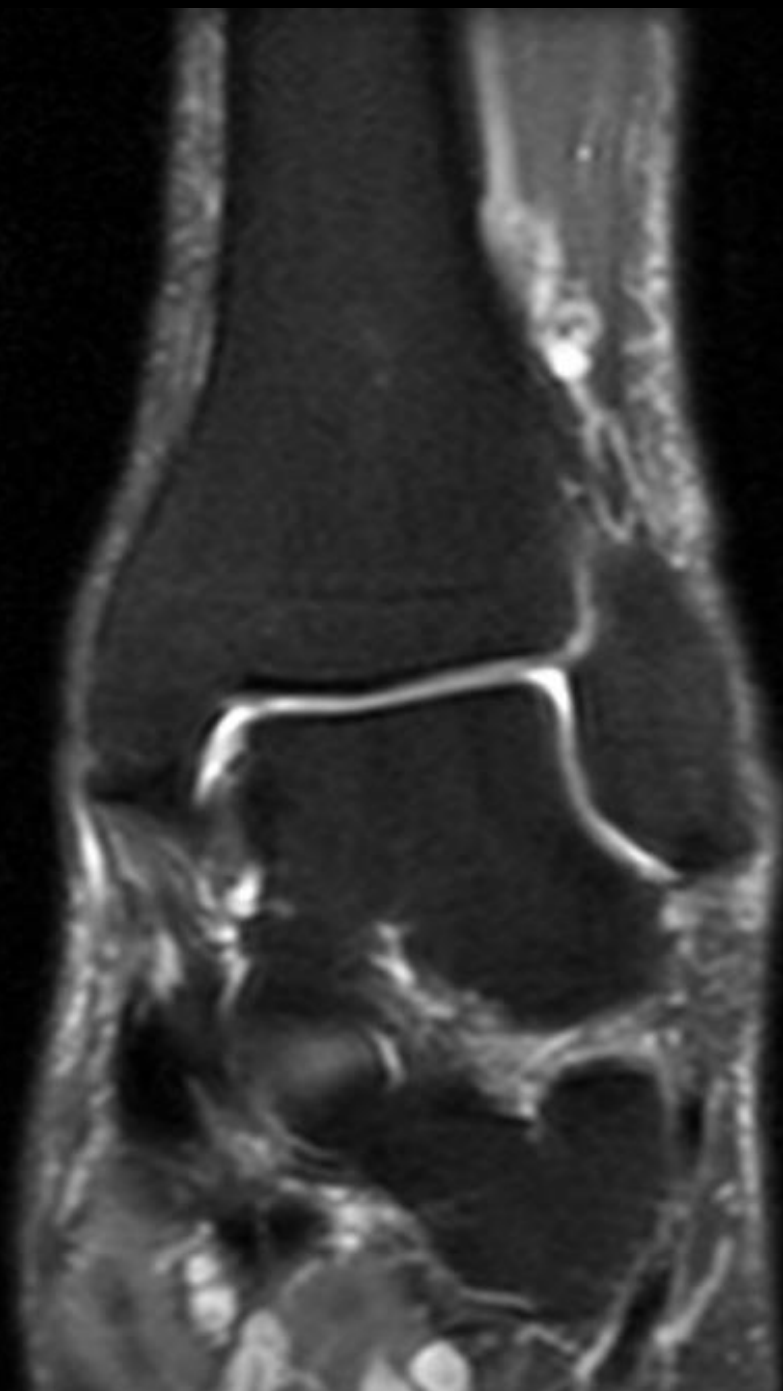


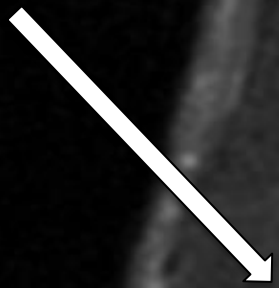


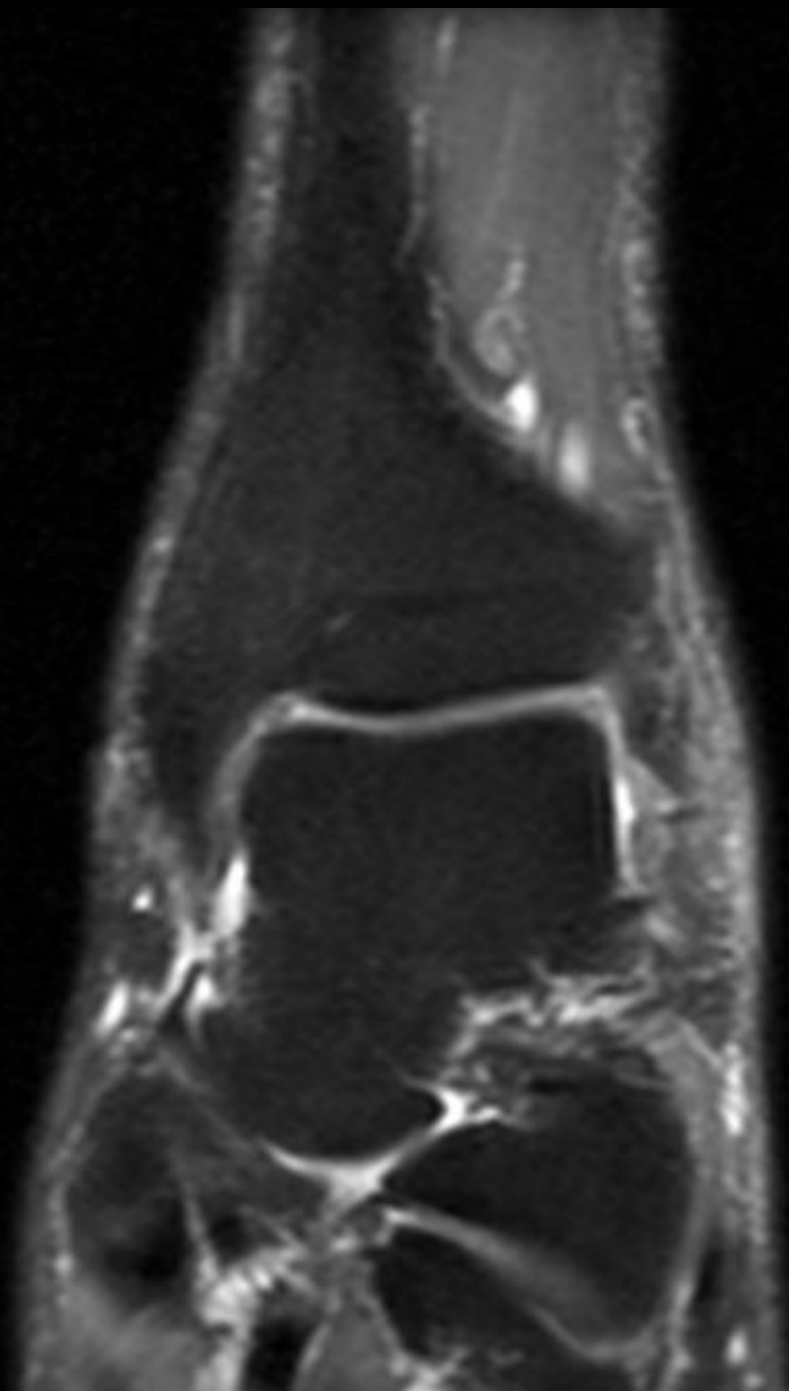
45-year-old male with nonspecific ankle pain

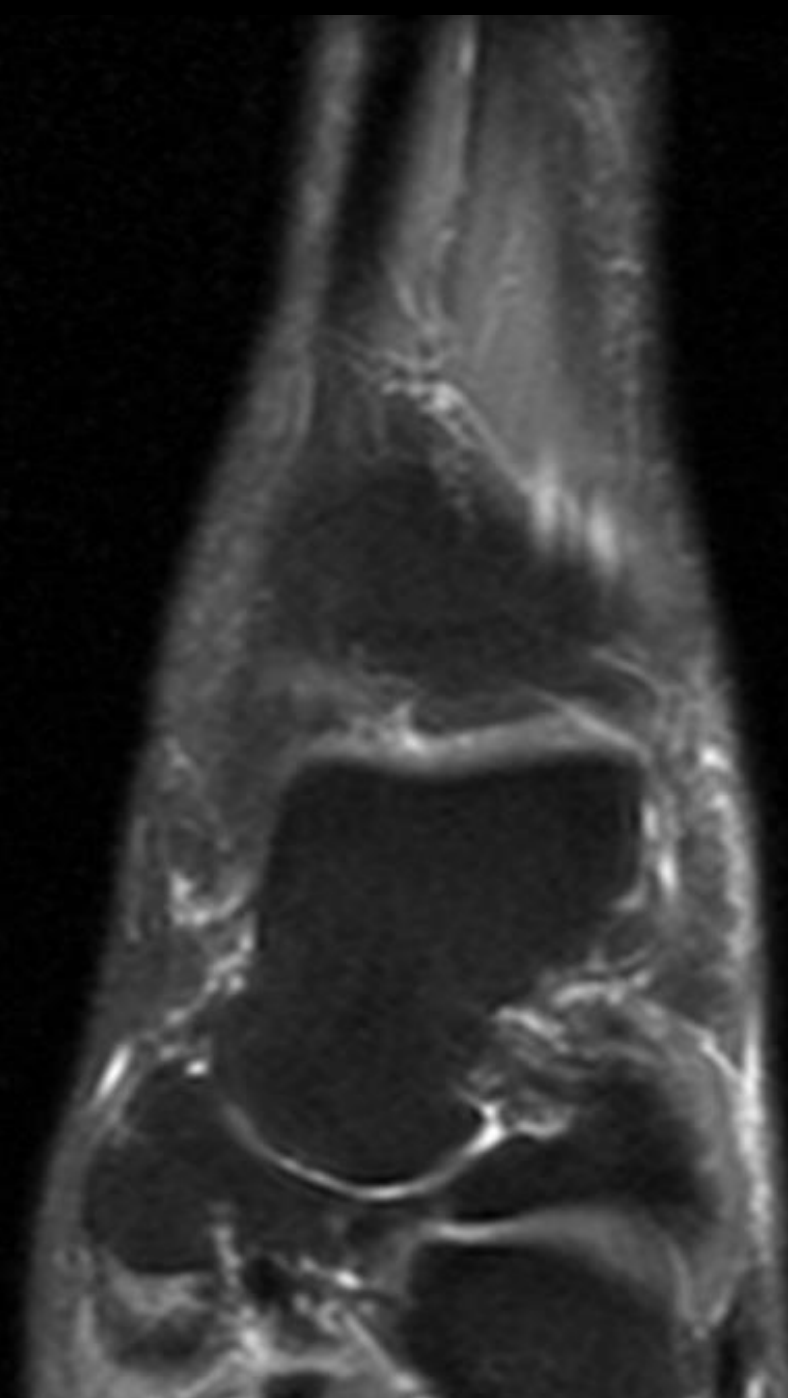
Michael Davis

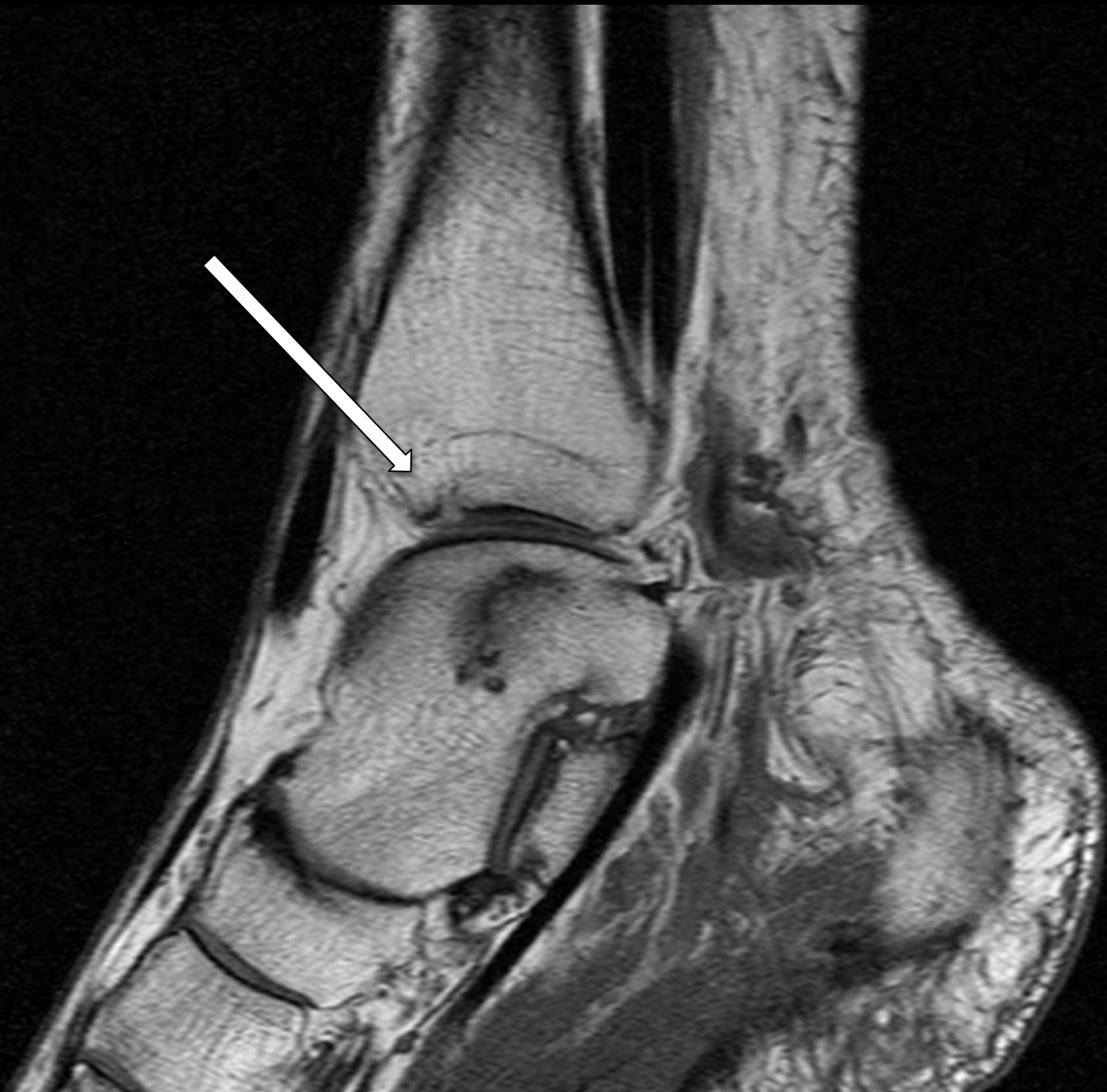

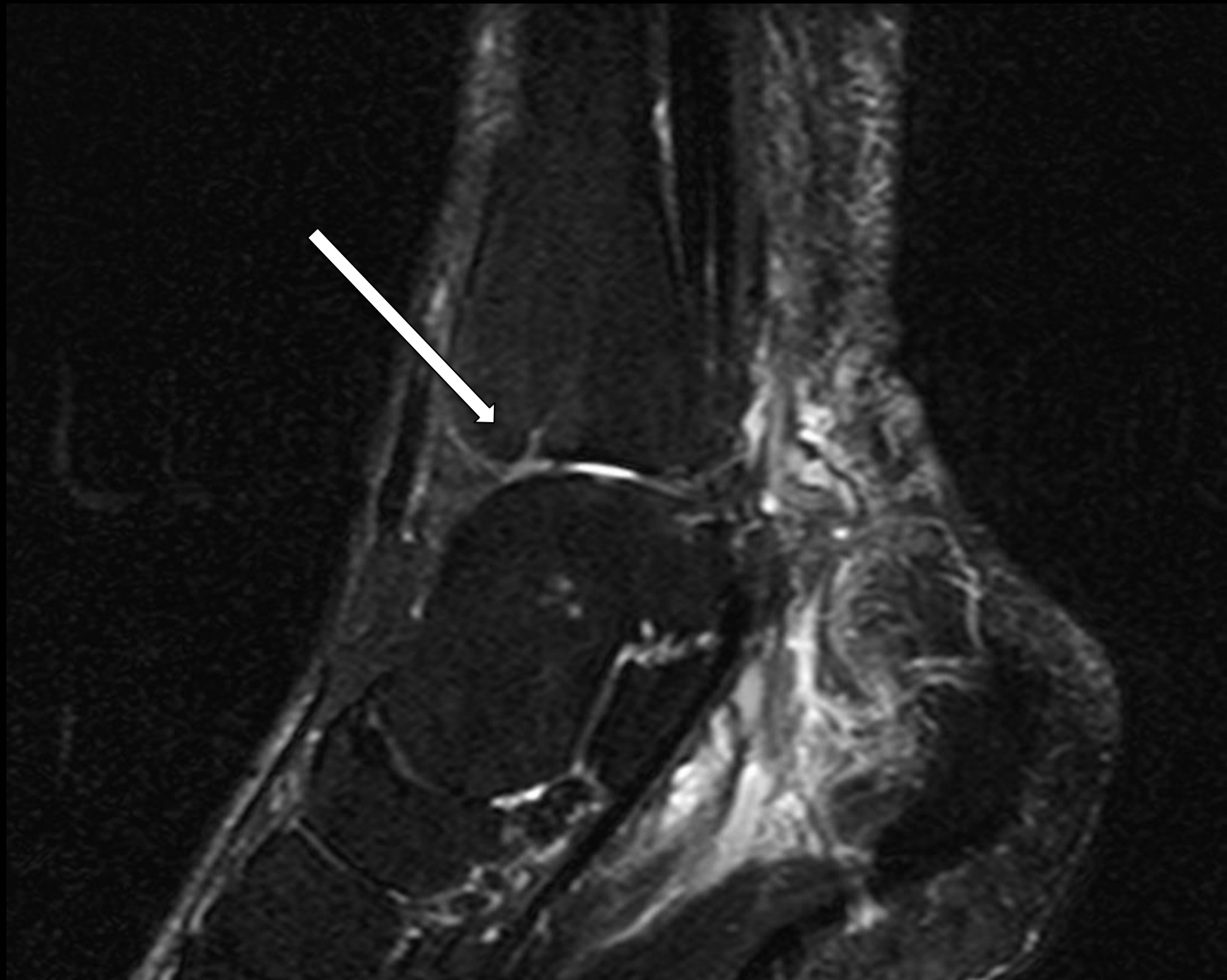





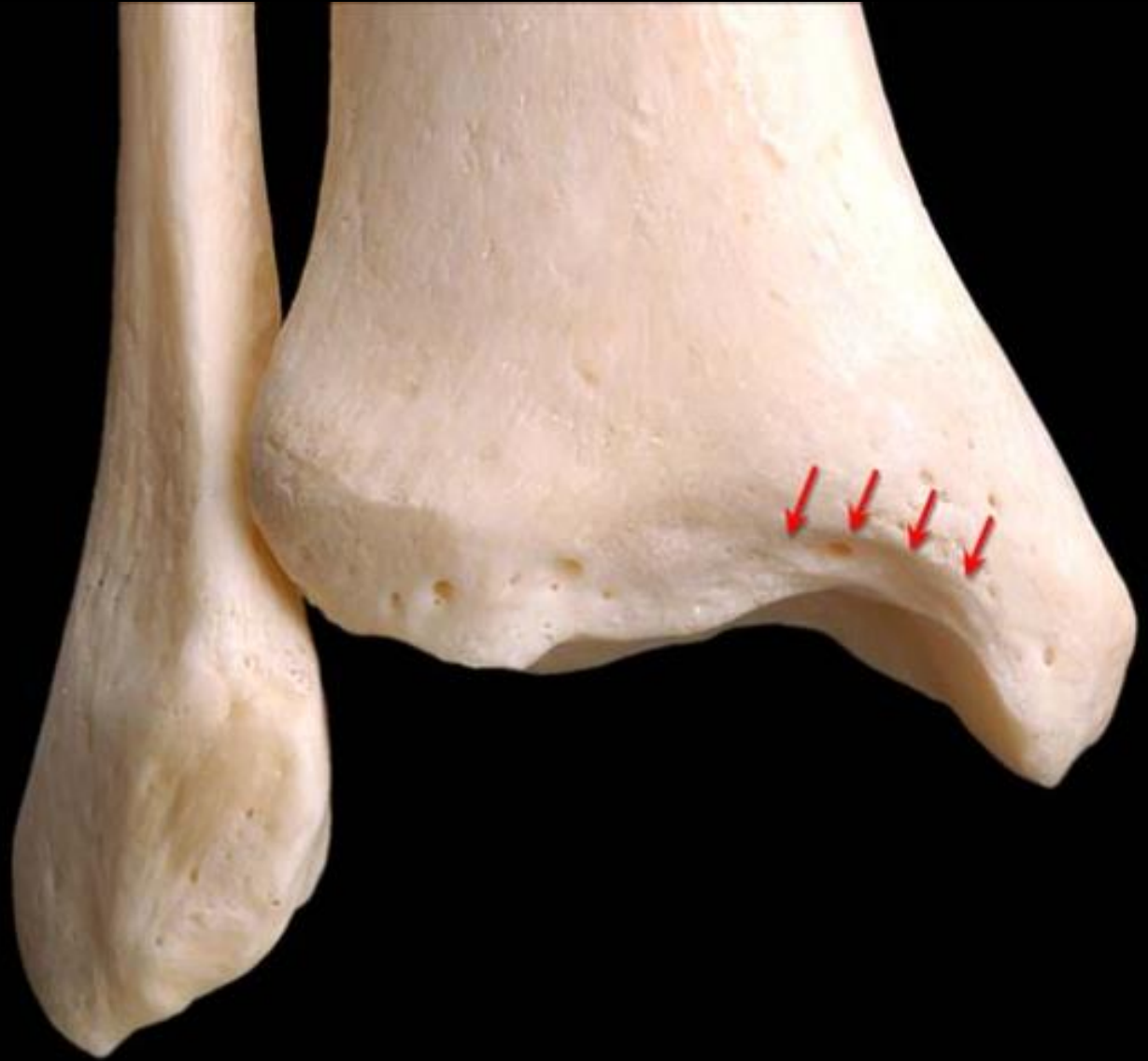


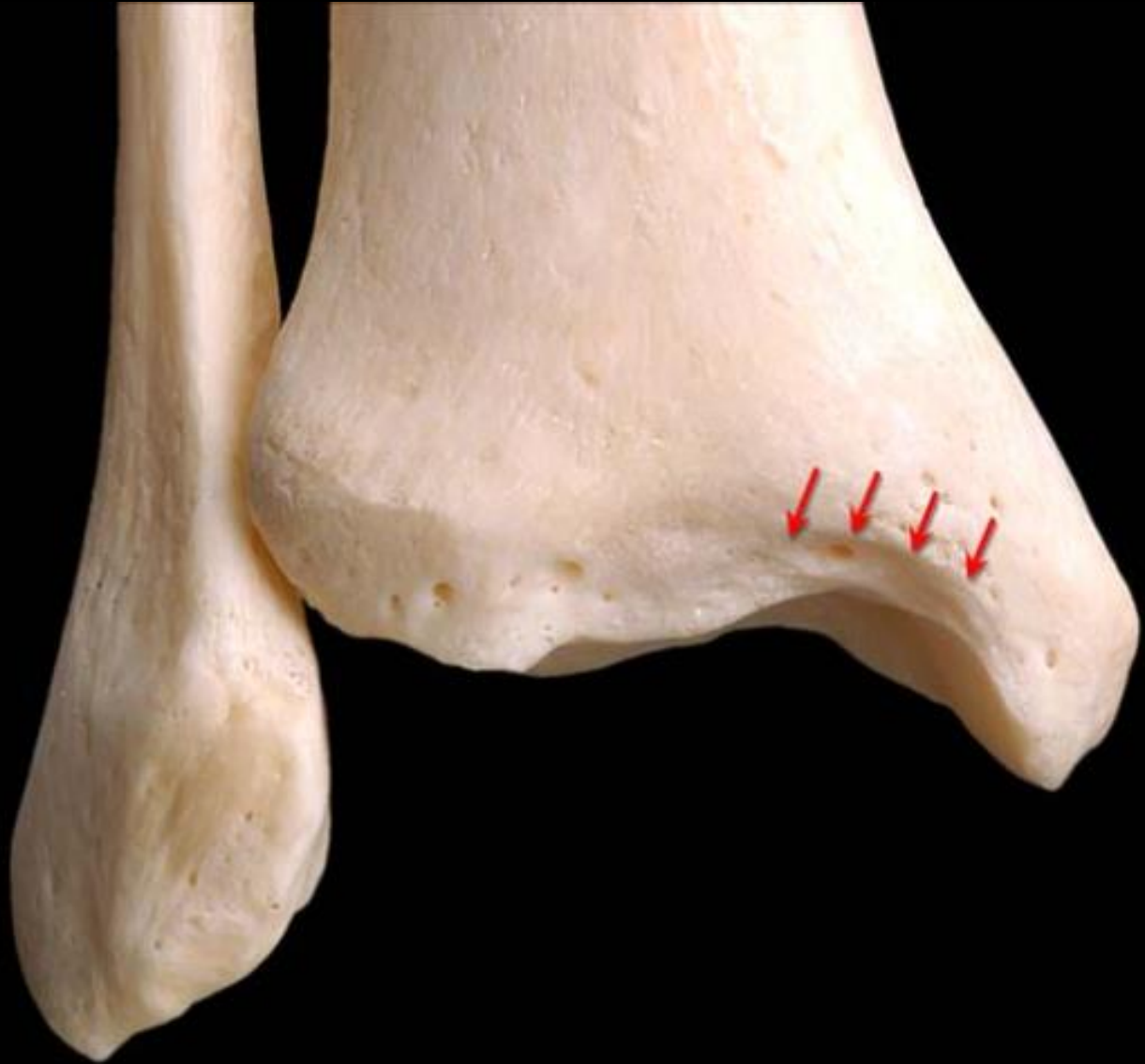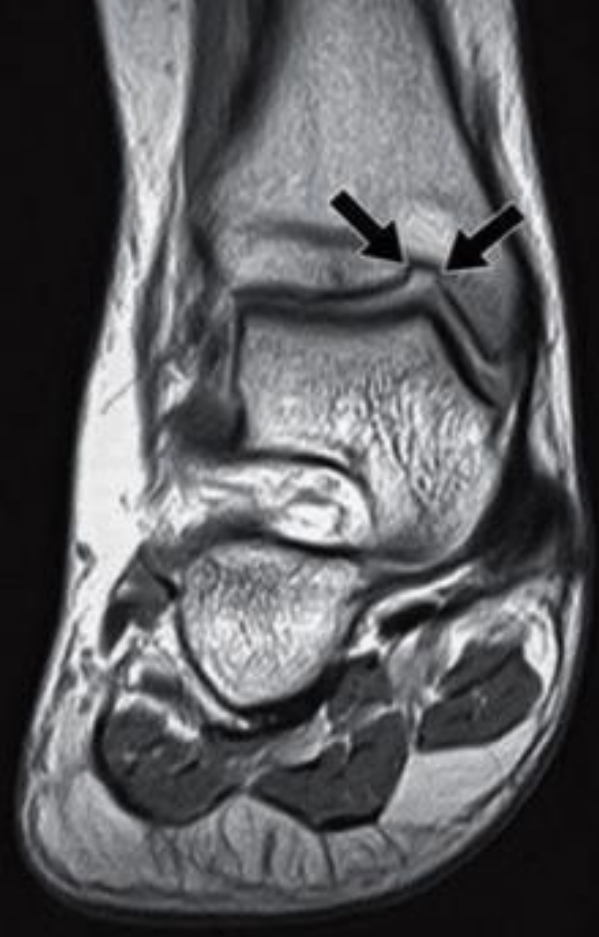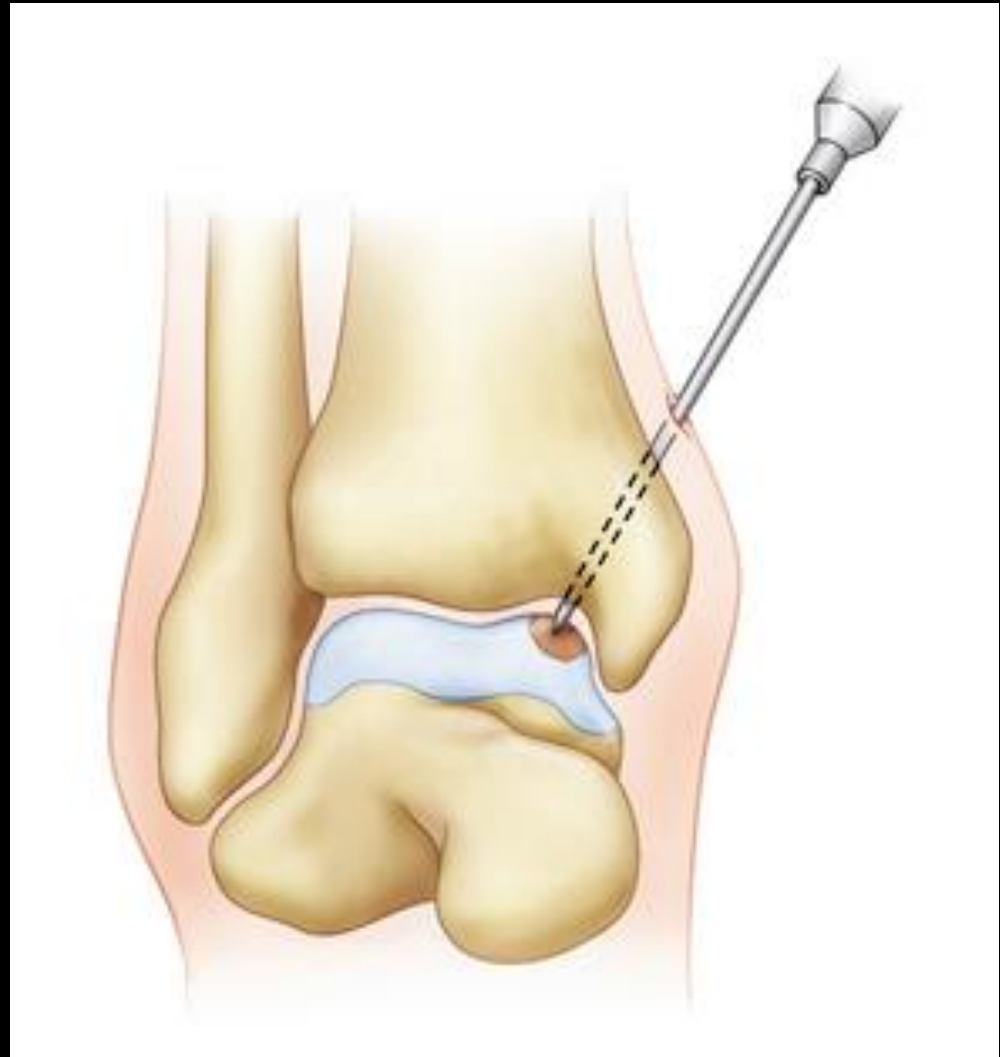




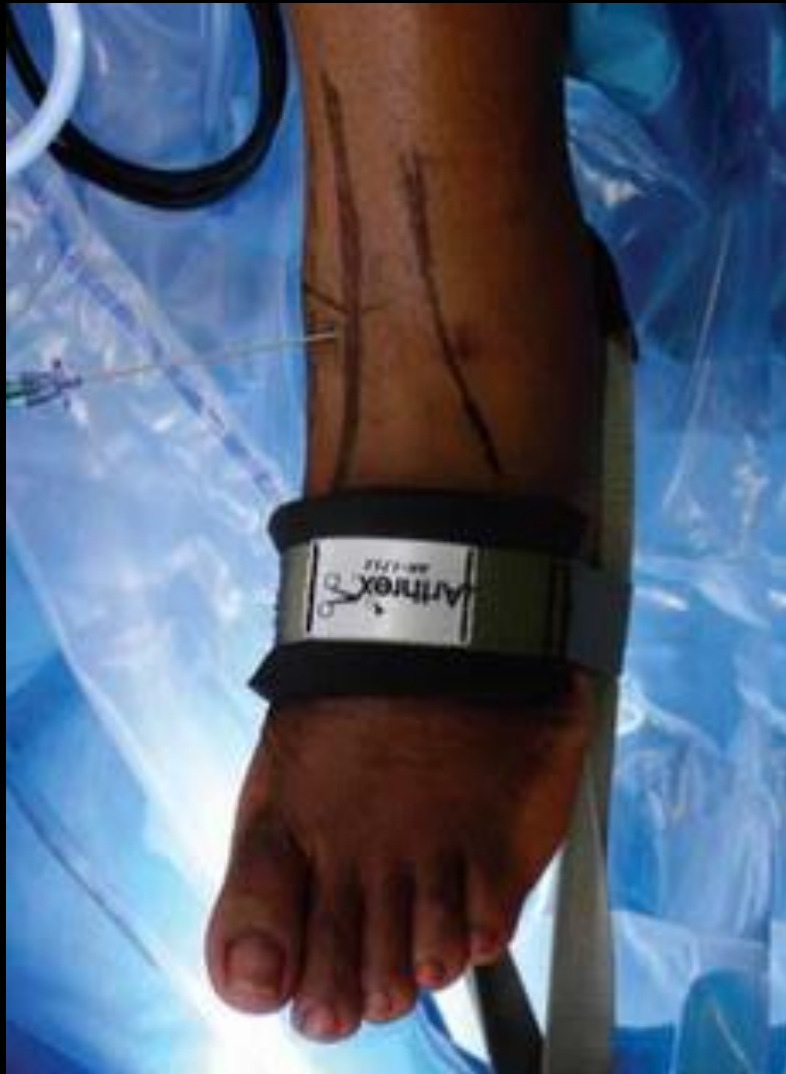Notch
of
Harty

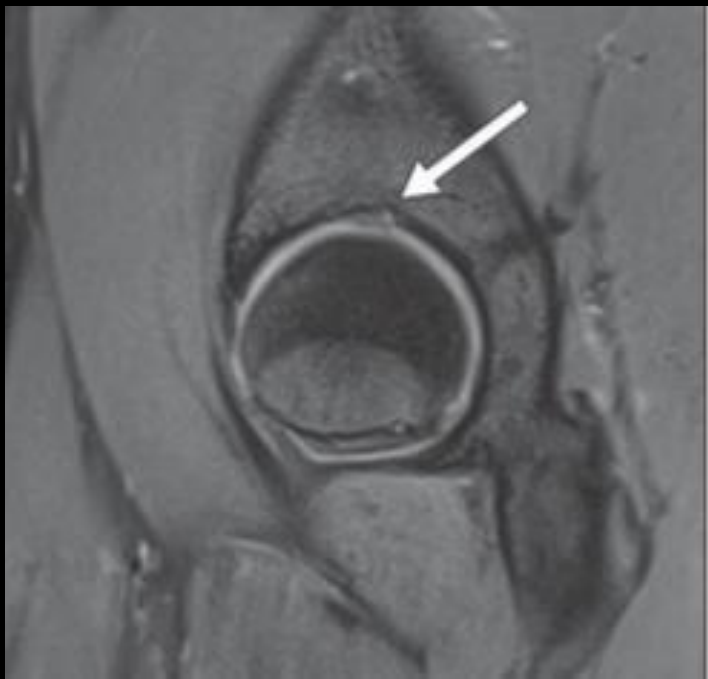
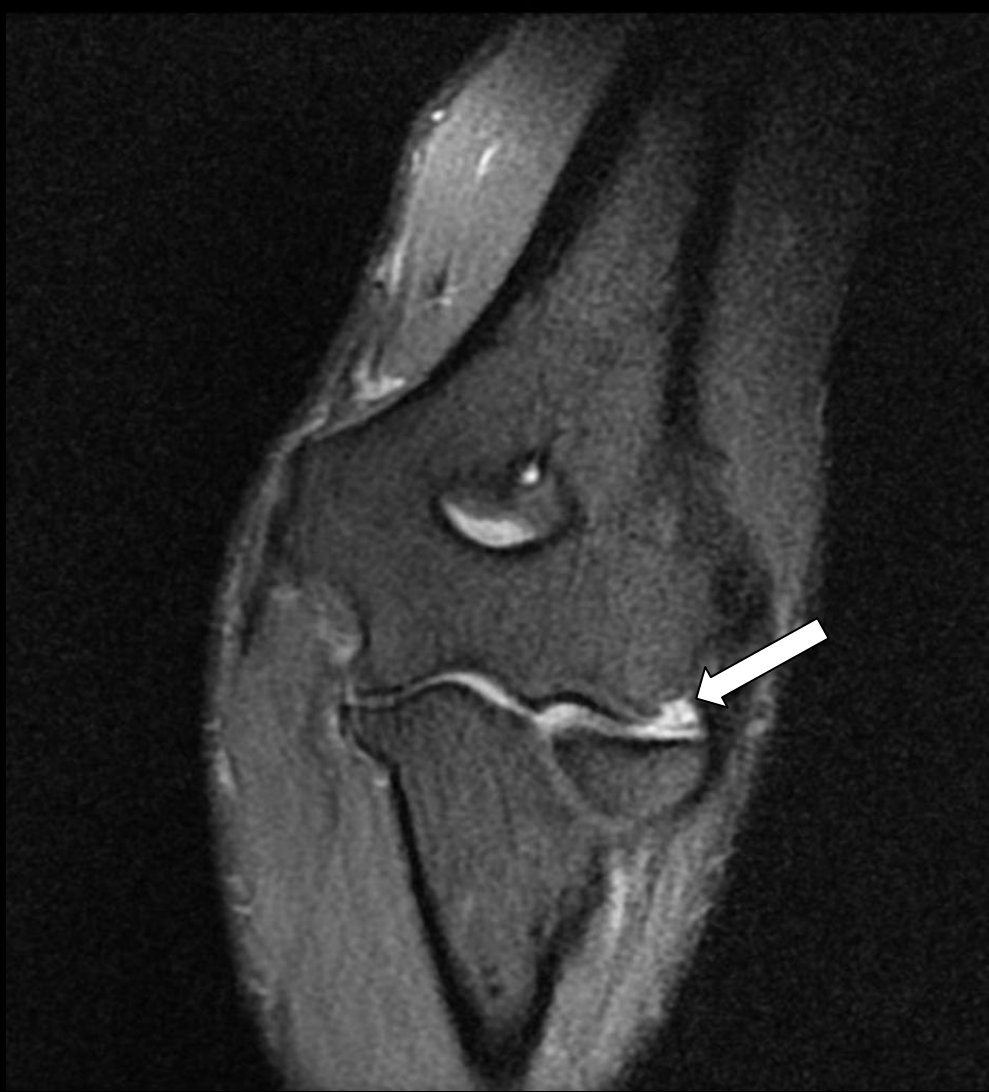
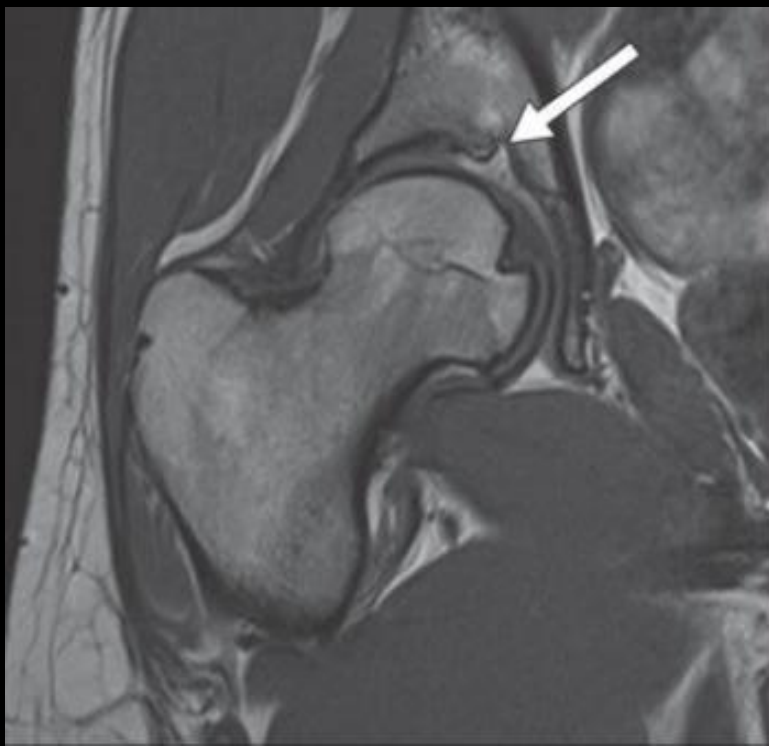



Significance of this Finding?

- Accurate MR interpretation requires knowledge of range of normal findings that should not be misinterpreted as pathologic
- Instances have been reported where the osteochondral contour of the anteromedial margin of the tibial plafond was interpreted by radiologists as pathologic osteochondral lesion/defect.



The Notch of Harty (Pseudodeflect of the Tibial Plafond): Frequency and Characteristic Findings at MRI of the Ankle

Robert D. Boutin¹
Jennifer Chang²
Cyrus Bateni¹
Eric Giza³
Erik R. Wisner⁴
Lawrence Yao⁵

OBJECTIVE. The purpose of this study is to report the frequency and characteristic findings of the notch of Harty as seen on MRI.

MATERIALS AND METHODS. One hundred six consecutive ankle MRI studies performed at 1.5 or 3 T were reviewed retrospectively by two radiologists. Findings relating to the notch of Harty and ankle joint were recorded and analyzed, including qualitative assessment of the presence of the notch, focal chondral thinning or focal subcortical osteosclerosis at the notch, notch width and depth, osteochondral lesions elsewhere in the ankle, subchondral edema signal or cystic change at the tibial plafond, and the presence of an ankle joint effusion.

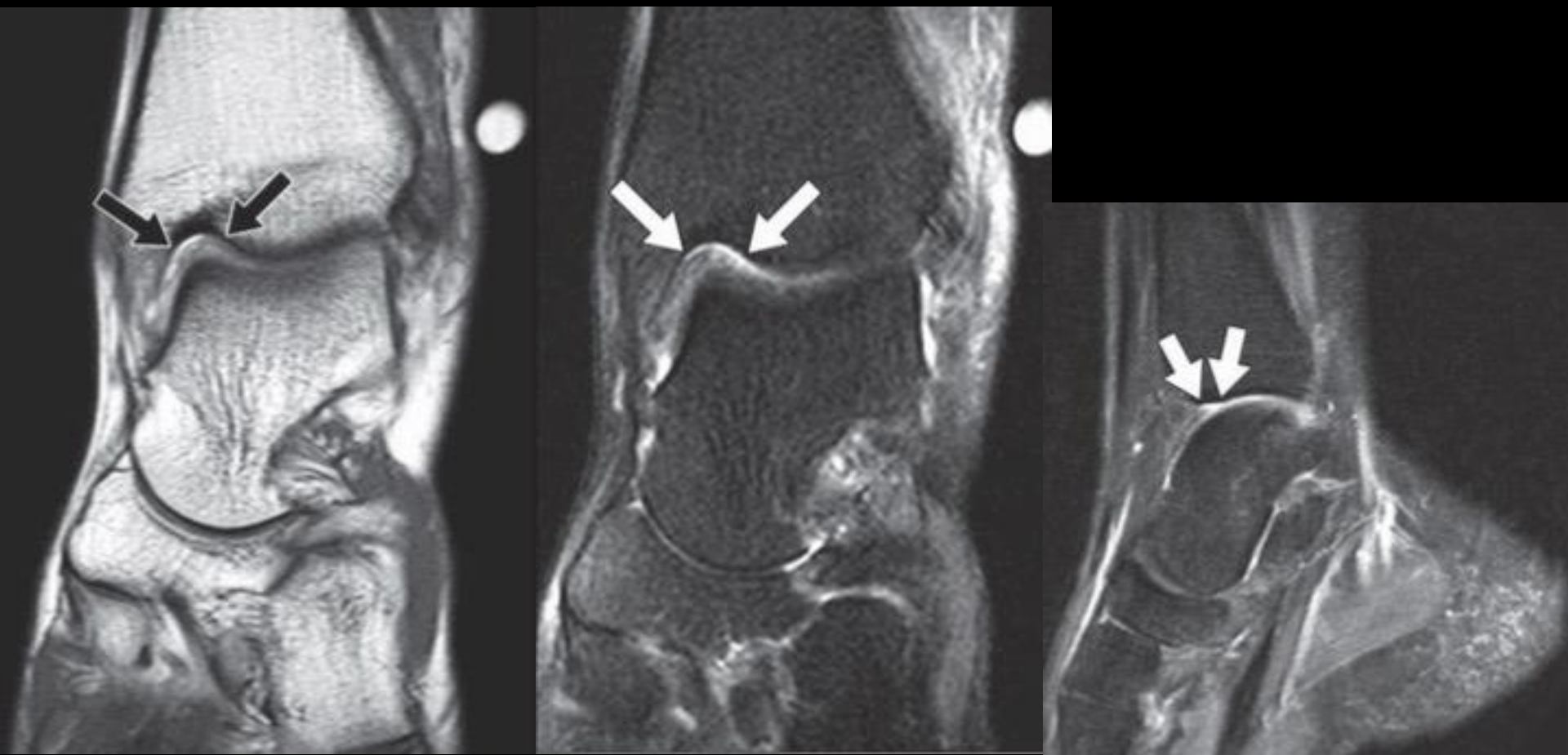
- If the Notch of Harty represents a normal anatomic feature, it should not be associated with bone marrow edema signal, subchondral cystic change, or advanced patient age.
- One hundred six consecutive ankle MRI studies performed at 1.5 or 3 T were reviewed retrospectively by two radiologists.

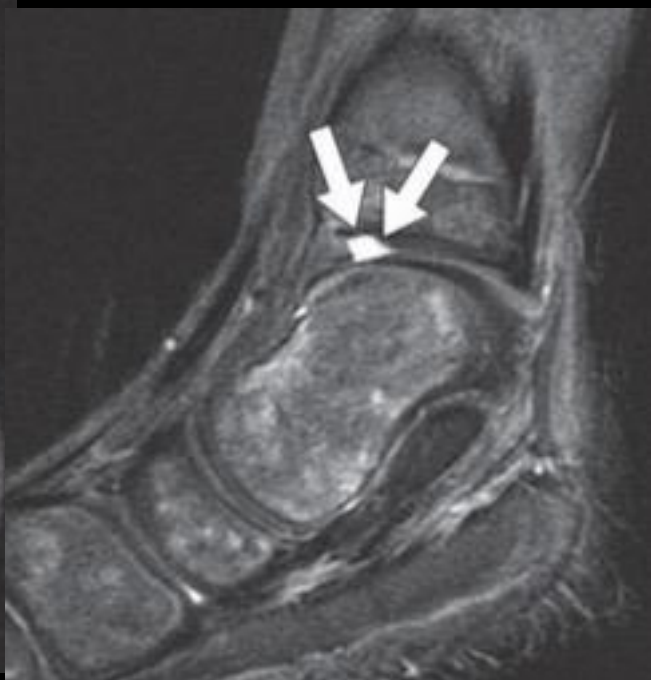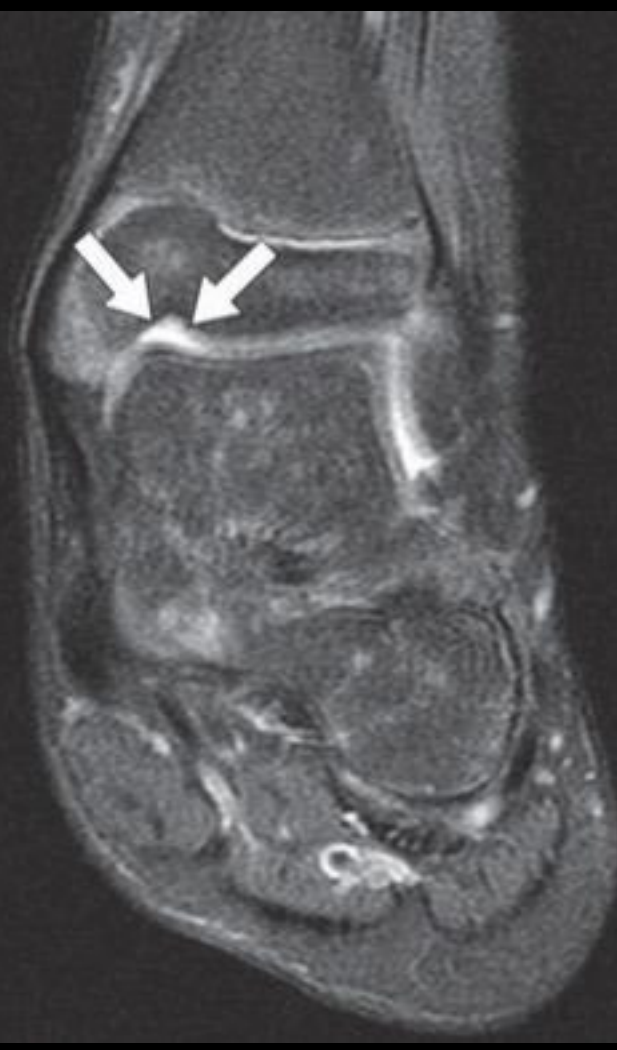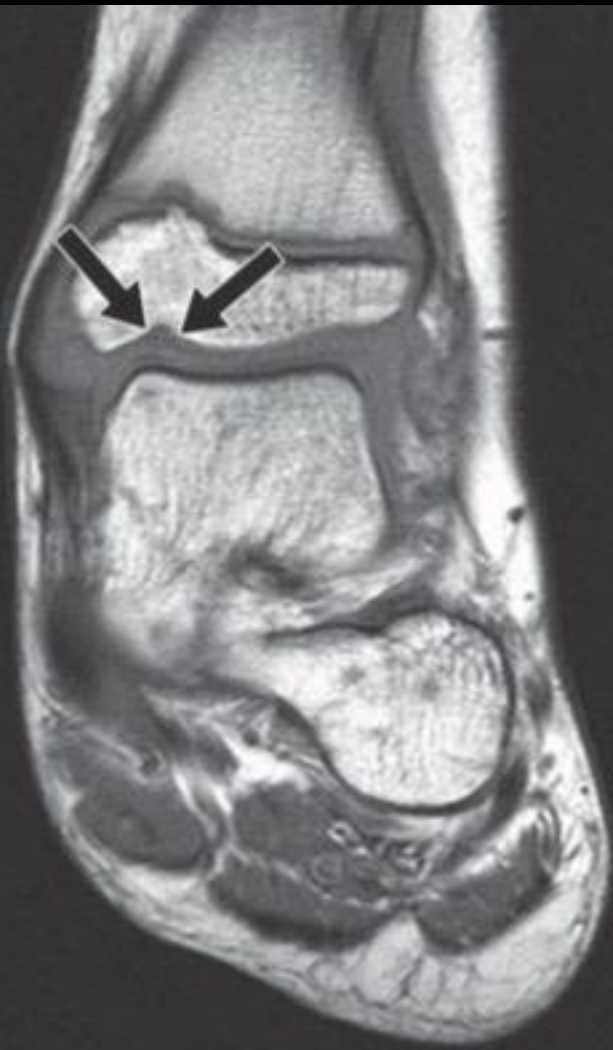TABLE I: Summary of Findings in 106 Subjects

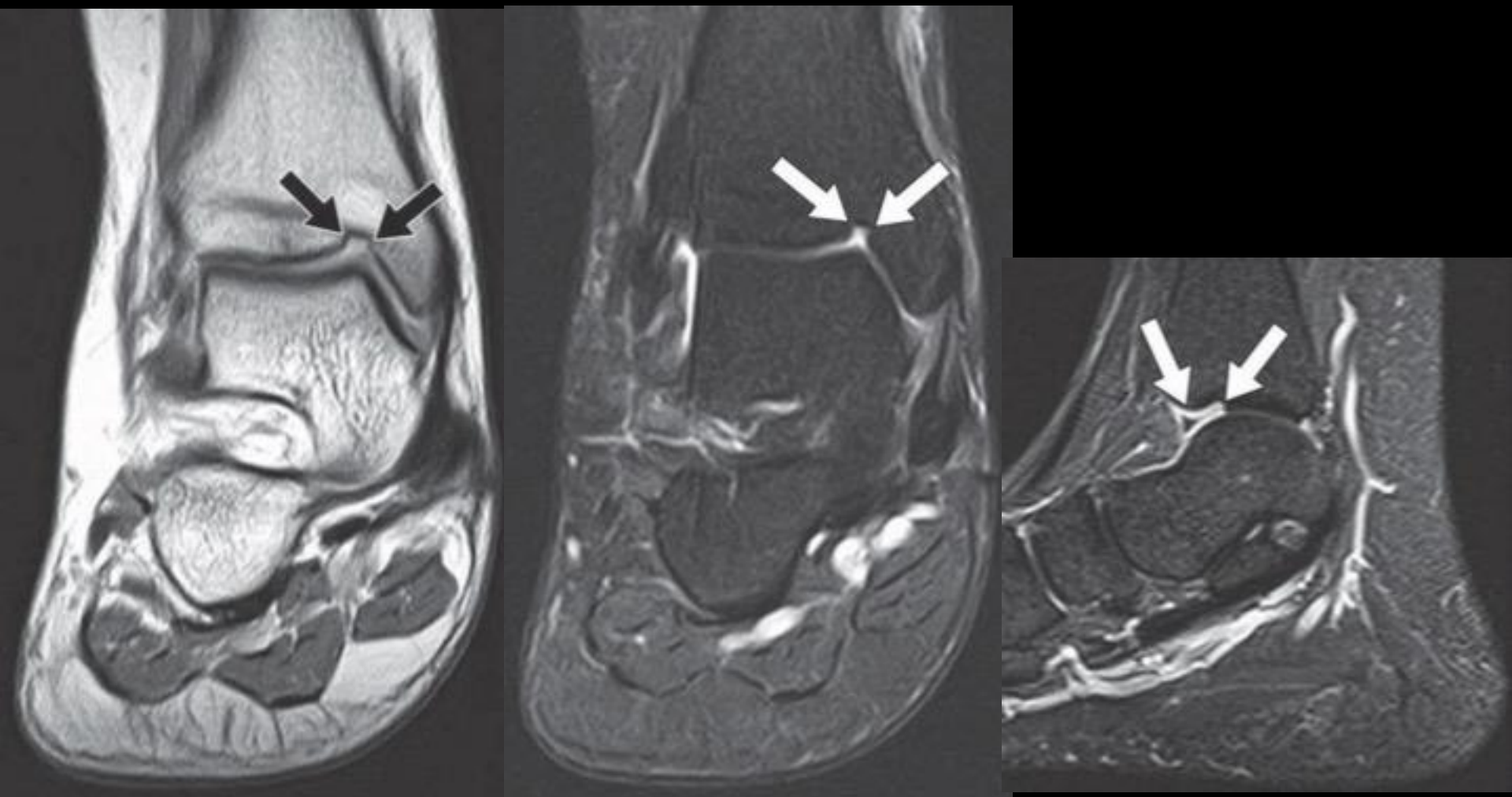
| Notch of Harty Present | Male Sex | Age (y), Mean (SD) | Subchondral Marrow Edema | Effusion | Subcortical Osteosclerosis | Chondral Thinning | Other Osteochondral Lesion |
|------------------------|----------|--------------------|--------------------------|----------|----------------------------|-------------------|----------------------------|
| Yes (<i>n</i> = 48) | 24 | 43.1 (17.5) | 1 | 6 | 38 | 40 | 4 |
| No (<i>n</i> = 58) | 24 | 45.6 (16.4) | 4 | 6 | 36 | 43 | 11 |

Note—Except for age, data are number of subjects.

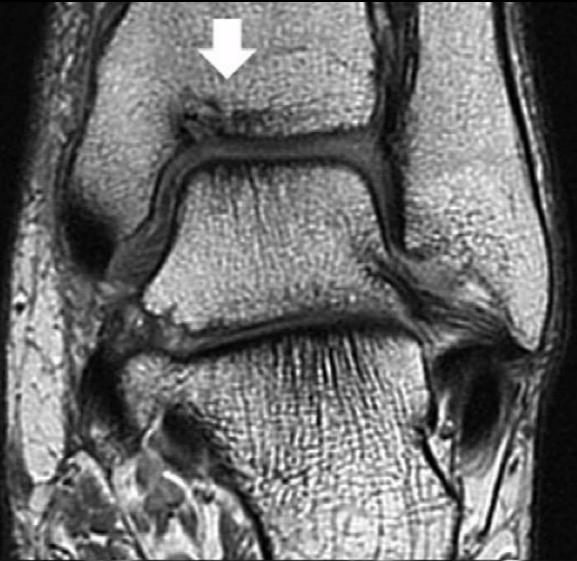- Notch identified in 48 of 106 patients, “prominent” in 6 of them
- Average size 6.2mm width x 1.2mm depth
- No statistically significant difference in age or sex distribution
- No significant association with
 - subcortical osteosclerosis
 - joint effusion
 - osteochondral lesion elsewhere
 - subchondral marrow edema.
- Subchondral edema-like signal or cystic change was not localized to the notch in any case
- Variable cartilage coverage
- **Conclusion: The Notch of Harty is observed as an anatomic variant on MRI and should be differentiated from a traumatic osteochondral lesion**



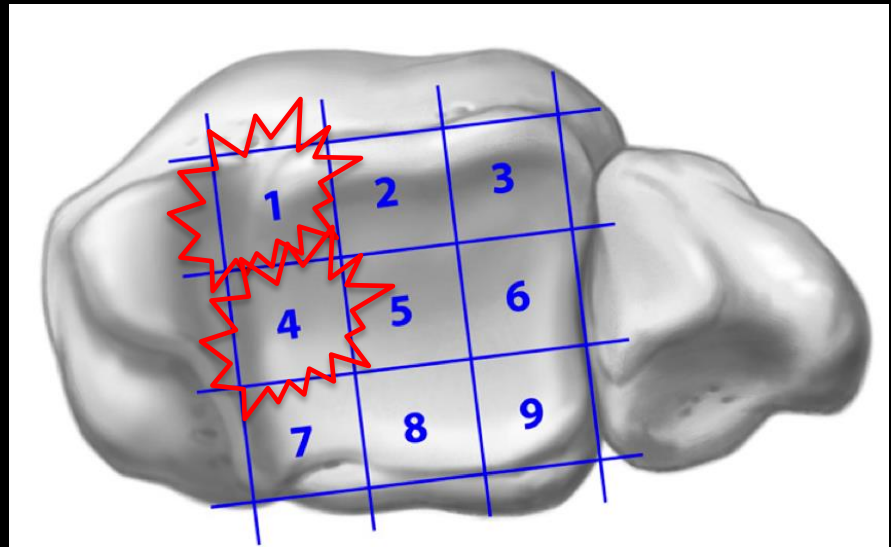
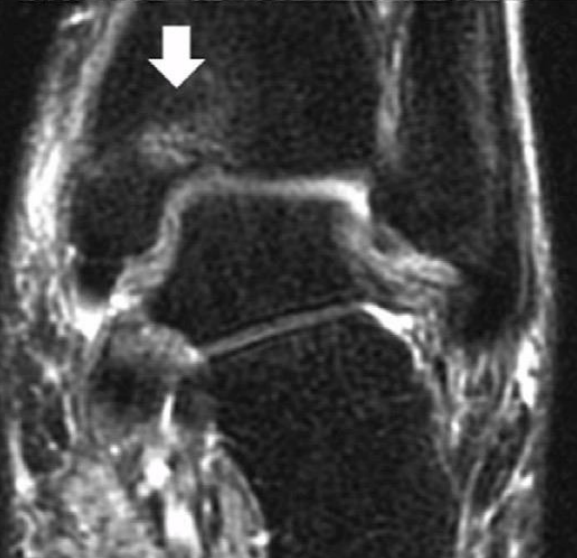
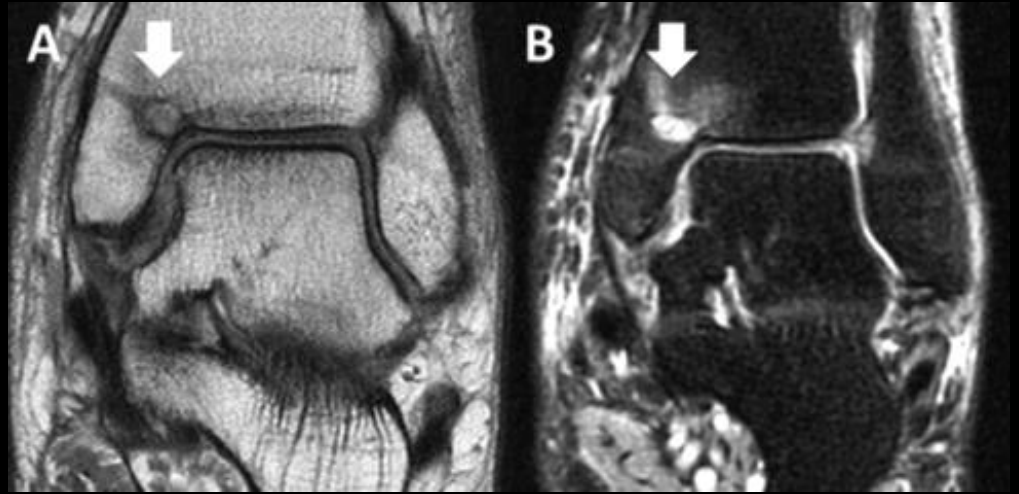




Osteochondral Lesions of the Distal Tibial Plafond



Tibial Plafond



Takeaway points

- The Notch of Harty is an anatomically constant finding at the anteromedial rim of the tibial plafond which is relatively commonly seen on MRI and may be prominent
- It is not associated with subjacent subchondral edema or cystic change which should facilitate appropriate interpretation and differentiate it from a traumatic osteochondral lesion

References

1. Ross, K et al. Functional and MRI Outcomes After Arthroscopic Microfracture for Treatment of Osteochondral Lesions of the Distal Tibial Plafond. J Bone Joint Surg Am. 2014;96:1708-15.
2. Boutin, R et al. The Notch of Harty (Pseudodefekt of the Tibial Plafond): Frequency and Characteristic Findings at MRI of the Ankle. AJR:205, August 2015.
3. Golano, P et al. Ankle Anatomy for the Arthroscopist. Part I: The Portals. Foot Ankle Clin N Am 11 (2006) 253-273.